# Spinal Disorders

Norbert Boos
Max Aebi
*Editors*

## Fundamentals of Diagnosis and Treatment

Springer

Norbert Boos · Max Aebi (Editors)
Spinal Disorders
Fundamentals of Diagnosis and Treatment

Norbert Boos · Max Aebi (Editors)

# Spinal Disorders

## Fundamentals of Diagnosis and Treatment

With 274 Figures in 1290 Parts
and 190 Tables

Springer

Prof. Dr. Norbert Boos
Zentrum für Wirbelsäulen- und Rückenmarkchirurgie
Universität Zürich
Universitätsklinik Balgrist
Forchstraße 340, 8008 Zürich
Switzerland

Prof. Dr. Max Aebi
Institut für Evaluative Forschung in Orthopädischer Chirurgie
MEM Forschungszentrum, Universität Bern
Stauffacherstraße 78, 3014 Bern
Switzerland

ISBN 978-3-540-40511-5 Springer-Verlag Berlin Heidelberg New York

Library of Congress Control Number: 2006927571

© 2008 Springer-Verlag Berlin Heidelberg

This work is subject to copyright. All rights are reserved, whether the whole or part of the material is concerned, specifically the rights of translation, reprinting, reuse of illustrations, recitation, broadcasting, reproduction on microfilm or in any other way, and storage in data banks. Duplication of this publication or parts thereof is permitted only under the provisions of the German Copyright Law of September 9, 1965, in its current version, and permission for use must always be obtained from Springer-Verlag. Violations are liable to prosecution under the German Copyright Law.

Printed in Germany

The use of general descriptive names, registered names, trademarks, etc. in this publication does not imply, even in the absence of a specific statement, that such names are exempt from the relevant protective laws and regulations and therefore free for general use.

Product liability: The publishers cannot guarantee the accuracy of any information about dosage and application contained in this book. In every individual case the user must check such information by consulting the relevant literature.

Cover design: eStudio Calamar, Spain
Illustrations: Alain Blank, Zürich, Switzerland

Printed on acid-free paper
9 8 7 6 5 4 3 2 1
springer.com

# Dedication

To Christa, Anna, Lisa and Sarah *N.B.*

To Christine, Eva and Samuel *M.A.*

For their love, understanding, encouragement and tolerance, without which this book would not have been possible

# Foreword

## Form Follows Function

Congratulations to the editors and authors on a truly outstanding book. Most books recapitulate what many already know, and leave one seeking more. This book is unique in its content and format. "Form follows function", popularized by the great American architect Frank Lloyd Wright, is a principle associated with modern architecture and industrial design in the 20th century. Simply stated, the shape of a building or object should be predicated by or based upon its intended function or purpose. Like this phrase there is often a history that is important to recognize and understand if we are to truly understand its meaning.

The origin of the phrase "Form follows function" can be traced back to the American sculptor Horatio Greenough, but it was American architectural giant Louis Sullivan who adopted it and made it famous. Sullivan actually said, "form ever follows function", but the simpler (and less emphatic) phrase is the one usually remembered. Sullivan's student and assistant Frank Lloyd Wright adopted this principle in slightly different form – perhaps because shaking off the old styles gave them more freedom and latitude.

Drs. Boos and Aebi have adopted a particular form, in this book, in order to give the reader a thorough grounding in the basic knowledge and general principles of spinal disorders. The didactic concept (form) of all the chapters is based on a consistent style and layout, and follows three basic principles of sustainable learning (functions), i.e.: (1) less is more, (2) repetition enhances sustained learning, and (3) case studies are an efficient and complementary means of learning.

The book utilizes learning aids to highlight and repeat core messages throughout all chapters, and visual aids facilitate a repetition-based learning approach, starting with the core messages, leading to an in-depth reading of each chapter. Marginal notes allow for effective repetition of material to facilitate the learning process, and outstanding graphics with pictorial and anecdotal learning methods are used to complement the many detailed case studies to exemplify the core messages. Finally, the use of important references and landmark articles makes this a prized book for everyone's shelf.

Congratulations to Norbert and Max on a fantastic contribution. This book will help those most in need, our patients. "Form and function" are the most important outcomes of this work, especially for those of us who work everyday to care for people with these various spinal disorders. Thank you.

*James N. Weinstein*
Director, The Dartmouth Institute for Health Policy and Clinical Practice
Professor & Chairman, The Department of Orthopaedics
Editor-in-Chief – Spine
Dartmouth College and Medical School
Dartmouth Hitchcock Medical Center
Lebanon, New Hampshire, USA

# Foreword

## Dinosaur or State of the Art?

Long ago, medical observations, advances, innovations and reviews were first presented at meetings and published in books. With the introduction of scientific medical journals, two things happened. First publication time was cut down dramatically compared to books and dissemination of knowledge became faster. Secondly a new approach to scientific publication was introduced in the form of peer review. This again lengthened publication time, yet benefited quality. Some argued that scientific journals would herald the slow death of books. History proved them wrong.

The advent of the internet again mixed up all the cards. Would scientific journals survive the internet? Initially the peer review aspect was lost and the quality of available knowledge suffered. Yet, sites like Wikipedia introduced the very concept of peer review online. So, would the internet kill peer review journals let alone books? Well, here again history demonstrates that both journals and books remain alive and well.

This book on spinal disorders edited by Norbert Boos and Max Aebi is a typical example of the kind of textbook anybody involved with matters regarding the spine wants on her or his desk. Moreover, this work is unique because it is not a classic multi-author textbook. The editors have approached chapter authors with whom they personally collaborated and share a common philosophy on the diagnosis and treatment approach to spinal disorders. By an intensive editing process, the different chapters have been woven into a homogeneous book combining personal experience with evidence based knowledge.

Editors of scientific journals know that so-called "review articles" are very popular, more referenced than other articles and thus excellent for boosting a journal's Impact Factor. Well, this book consists of a succession of reviews bringing us a real "state of the art" regarding the spine but put into perspective through personal experience. This work is truly pluri-disciplinary and reflects the complex and difficult nature of the human spine. Among the authors we find clinicians as well as scientists.

The editors tackle every aspect of the spine in a well balanced way. No topic is superfluous or perceived as more important than another and the book reads as one continuous flow, one topic logically leading to the next. This book can be recommended to anyone involved in clinical or research aspects of the spine. It simply has to lie on the desk of doctors, scientists, physiotherapists and chiropractors, psychologists and health-care specialists interested in the spine.

*Robert Gunzburg*
President 2007–2008
EuroSpine, the Spine Society of Europe
Cavell Spine Center
Brussels, Belgium

# Preface

Spinal disorders are among the most common medical conditions, having a significant impact on health-related quality of life, use of health care resources and socioeconomic costs. As a therapeutic measure, spinal surgery is still one of the most rapidly growing areas in clinical medicine, and is a major contributor to the continuously increasing costs of modern-day medicine. Similarly, the increasingly aging population will have a greater need for the treatment of degenerative spinal disorders, particularly secondary spinal deformities and stenosis. However, at the same time limited health care resources will mean difficult choices in the allocation of treatment modalities. Therefore, a basic knowledge of the state of the art of the diagnosis and treatment of spinal disorders is required, not only for spine specialists but also for general orthopedic surgeons, rheumatologists, neurologists, rehabilitation doctors, psychiatrists, chiropractors, physiotherapists, basic scientists and health care executives, to enable them to choose and/or evaluate appropriate diagnostic and therapeutic approaches.

Owing to the rapid development of knowledge of spinal disorders over the past 20 years, a comprehensive new textbook which incorporates all the latest knowledge has become necessary, and we have become aware again and again of innumerable residents, fellows and colleagues searching for a comprehensive introductory learning tool for the study of spinal disorders. Although excellent textbooks on specific issues of the spine and specifically spinal surgery are already available, none fulfills the criterion of being an easily readable teaching tool that focuses systematically on the fundamentals and basic principles in a standardized manner. Strongly encouraged by our residents and fellows, we have designed a textbook on spinal disorders which is an integration of the evidence-based knowledge in the up-to-date literature and our decade-long personal experience at the source of research and treatment of spinal disorders.

With Springer, we found a dedicated publisher willing to give our book project strong support, and with carefully selected chapter authors we have hopefully succeeded in creating a consistent message throughout the book. Unlike many other spinal textbooks, the editors did not want simply to collect and edit chapters from many different authors, which often leads to an inhomogeneous book with overlapping, redundant and incoherent chapters. We rather aimed to provide a homogeneous syllabus with a consistent didactic strategy to teach the fundamentals and general principles.

Although we have based the information in this book on an extensive survey of the peer-reviewed literature, we have moderated this information in a synthesis with research and clinical experience. We have, however, refrained specifically from an in-depth description of sophisticated surgical procedures. For this field of expertise, there are already a number of excellent manuals and textbooks available.

Although we recognize the difficulty and challenge of our task, we feel that we have fulfilled our goal by choosing authors with whom we have collaborated for a long time and who concur with our own philosophy. The didactic concept is

presented in every single chapter in a consistent manner and is based on three principles:

1. Less is more when concisely written
2. Repetition enhances sustained learning
3. Case studies are an invaluable means of exemplifying important principles

We hope that we have met our objective in providing a modern, up-to-date and easy to read textbook on spinal disorders with an appealing layout, and that the book will inspire and stimulate the reader in the study of spinal disorders. It is our hope that this book may become the standard basic textbook for spinal disorders if you, the reader, decides to make this happen.

We would like to thank all the contributing authors for their major commitment and hard work. We would also like to thank our students, fellows and colleagues for critically proof-reading the chapters and their constructive and encouraging feedback. We owe many thanks to Doris Stettler and Grit Gagelmann for their support and help with the editing process. We further thank William Shufflebotham in the UK for copy-editing the book. We also want to acknowledge the Medical Pictorial Documentation team of the University Hospital Balgrist (Heidi Wylenmann, Helene Uhlmann and Christian Streng) for their invaluable help with the editorial preparation of the medical images and figures.

We are particularly indebted to Alain Blank, who created the unique illustrations with his meticulous and careful attention to the anatomical and surgical details. The major book sections are separated by the paintings of Arnaldo Ricciardi, who perfectly understood how to transform his inspirations of spinal disorders into works of art. We also thank Springer, the publisher, and specifically Gabriele Schröder for making this book happen.

Zürich and Bern, March 2008

Norbert Boos
Centre for Spinal Surgery
University Hospital Balgrist
University of Zürich

Max Aebi
MEM Research Centre for
Orthopaedic Surgery
University of Bern

# Contents


## 1 History of Spinal Disorders
Philipp Gruber, Thomas Boeni

Core Messages . . . . . 1
A Brief Etymology . . . . . 1
Historical Case Introduction . . . . . 2
Spinal Anatomy and Physiology . . . . . 4
Anesthesia and Supportive Techniques . . . . . 6
Laughing Gas, Chloroform and Cocaine . . . . . 6
Antisepsis and Antibiotics . . . . . 6
Diagnostic Imaging . . . . . 8
Scoliosis . . . . . 8
Pathogenesis . . . . . 9
Assessment . . . . . 9
Non-operative Treatment . . . . . 11
Scoliosis Surgery . . . . . 13
Juvenile Kyphosis . . . . . 13
Spondylolisthesis . . . . . 14
An Obstetrical Problem . . . . . 14
Surgery . . . . . 14
Back Pain and Sciatica . . . . . 15
A Wrong Mixture of Fluids . . . . . 15
Disc Herniation . . . . . 17
Historical Case Study . . . . . 19
The Facet Syndrome . . . . . 21
Spinal Stenosis . . . . . 21
Spinal Infections . . . . . 22
Egyptian Mummies and Sir Percival Pott . . . . 22
Treatment . . . . . 24
Ankylosing Spondylitis . . . . . 24
Discovery of a New Disease . . . . . 25
Spinal Injuries . . . . . 27
First Reports . . . . . 27
Spinal Injuries as a Socioeconomic Problem . . 28
Traction Table and Laminectomy . . . . . 29
The Advent of Internal Spinal Fixation . . . . . 29
Recapitulation . . . . . 30
Appendix: History of spinal disorders . . . . . 31
Key Articles . . . . . 33
References . . . . . 34

# Basic Science

## 2 Biomechanics of the Spine
Stephen Ferguson

Core Messages . . . . . 41
The Human Spine . . . . . 41
The Motion Segment . . . . . 42
Anterior Structures . . . . . 42
Posterior Elements . . . . . 46
Ligaments of the Spine . . . . . 47
Motion Segment Stiffness . . . . . 48
Muscles . . . . . 48
Spinal Stability Through Muscular Activity . . 52
Muscle Activity During Flexion and Extension 54
Muscle Activity During Lateral Flexion and Rotation . . . . . 54
Spine Kinematics . . . . . 54
Range of Motion . . . . . 55
Mechanical Response of the Spinal Motion Segment . . . . . 55
Clinical Instability . . . . . 57
Kinetics (Spinal Loading) . . . . . 58
Static Loading . . . . . 58
Loads During Lifting . . . . . 59
Dynamic Loading . . . . . 60
Recapitulation . . . . . 61
Key Articles . . . . . 62
References . . . . . 63

## 3 Spinal Instrumentation
Daniel Haschtmann, Stephen J. Ferguson

Core Messages . . . . . 67
Goals of Spinal Instrumentation . . . . . 67
Basic Biomechanics of Spinal Instrumentation . . 69
Loading and Load Sharing Characteristics . . . 69
Posterior Stabilization Principles . . . . . 71
Anterior Stabilization Principles . . . . . 74
Anterior Tension Band Technique . . . . . 78
Biomechanics of the “Adjacent Segment” . . . . . 79
Non-Fusion Principles . . . . . 80
Disc Arthroplasty . . . . . 80
Nucleoplasty . . . . . 82
Posterior Dynamic Stabilization Technique . . 82

Interspinous Process Distraction Technique 83
Recapitulation . . . . . 84
Key Articles . . . . . 85
References . . . . . 86

4 Age-Related Changes of the Spine
Atul Sukthankar, Andreas G. Nerlich, Günther Paesold
Core Messages . . . . . 91
Epidemiology . . . . . 91
Case Introduction . . . . . 92
General Age-Related Changes . . . . . 92
Functional Spine Unit . . . . . 93
The Intervertebral Disc and Cartilage Endplate 95
Intervertebral Disc . . . . . 95
The Cartilage Endplate . . . . . 107
The Facet Joints . . . . . 109
Normal Anatomy . . . . . 109
Age-Related Changes . . . . . 109
Vertebral Bodies . . . . . 110
Normal Anatomy and Composition . . . . . 110
Age-Related Changes . . . . . 110
Spinal Ligaments . . . . . 111
Normal Anatomy and Composition . . . . . 111
Age-Related Changes . . . . . 111
Spinal Muscles . . . . . 112
Normal Anatomy and Structure . . . . . 112
Age-Related Changes . . . . . 112
Recapitulation . . . . . 114
Key Articles . . . . . 115
References . . . . . 116

5 Pathways of Spinal Pain
Heike E. Künzel, Norbert Boos
Core Messages . . . . . 123
Historical Background . . . . . 123
Precartesian Theories . . . . . 123
Cartesian Theory . . . . . 124
Gate Control Theory . . . . . 124
Modern Pain Theories . . . . . 124
Epidemiology of Chronic Pain . . . . . 125
Definition and Classification . . . . . 125
Temporal Course . . . . . 126
Contemporary Pain Classification . . . . . 126
Pathways of Pain . . . . . 128
Transduction . . . . . 129
Conduction . . . . . 130
Transmission and Modulation . . . . . 130
Pain Projection . . . . . 133
Pain Perception . . . . . 134
Neuroplasticity . . . . . 135
Peripheral Sensitization . . . . . 135
Transcriptional DRG Changes . . . . . 136
Central Sensitization . . . . . 136
Disinhibition . . . . . 137
Endogenous and Environmental Influences on Pain Perception . . . . . 137
Clinical Assessment of Pain . . . . . 138
Differentiating Inflammatory and Neuropathic Pain . . . . . 138
General Concepts of Pain Treatment . . . . . 141
Pharmacological Treatment . . . . . 141
Non-pharmacological Treatment of Spinal Pain . . . . . 143
Biopsychosocial Interventions . . . . . 143
Surgical Treatment . . . . . 144
Recapitulation . . . . . 144
Key Articles . . . . . 145
References . . . . . 146

6 Epidemiology and Risk Factors of Spinal Disorders
Achim Elfering, Anne F. Mannion
Core Messages . . . . . 153
General Scope . . . . . 153
Objectives in Spinal Disorders . . . . . 154
Classification of Spinal Disorders . . . . . 155
Etiology . . . . . 155
Time Course . . . . . 155
Low Back Pain . . . . . 156
Neck Pain . . . . . 157
Pain, Impairment and Disability . . . . . 157
Burden of Spinal Disorders . . . . . 159
Economic Costs . . . . . 159
Risk Factors . . . . . 161
Individual Risk Factors . . . . . 161
Morphological Risk Factors . . . . . 162
Psychosocial Factors . . . . . 162
Occupational Physical Risk Factors . . . . . 163
Occupational Psychological Risk Factors . . . . 163
Absence of Evidence for Certain Risk Factors 164
Geographical Variation . . . . . 164
Flag System for the Risk Factors . . . . . 165
Red Flags . . . . . 165
Yellow Flags . . . . . 166
Blue Flags . . . . . 166
Black Flags . . . . . 166
Direction for Future Epidemiological Research 167
Recapitulation . . . . . 167
Key Articles . . . . . 168
References . . . . . 169

7 Predictors of Surgical Outcome
Anne F. Mannion, Achim Elfering
Core Messages . . . . . 175
Epidemiology . . . . . 175
Outcome Measures . . . . . 179
What Constitutes a “Successful Outcome” . . . 180

The Outcome of Common Spine Surgical Procedures . . . 182
Predictors of Outcome of Spinal Surgery . . . 183
Medical Factors . . . 184
Biological and Demographic Variables . . . 186
Health Behavioral and Lifestyle Factors . . . 187
Psychological Factors . . . 187
Sociological Factors . . . 189
Work-Related Factors . . . 189
Risk Factor Assessment in Clinical Practice . . . 190
Recapitulation . . . 192
Key Articles . . . 193
References . . . 194

## Patient Assessment

### 8 History and Physical Examination
Clément M.L. Werner, Norbert Boos
Core Messages . . . 201
Epidemiology . . . 201
Case Introduction . . . 202
History . . . 203
Pain . . . 204
Function . . . 210
Spinal Deformity . . . 210
Physical Examination . . . 211
Walking . . . 211
Standing . . . 211
Sitting . . . 216
Lying Supine . . . 220
Lying on Left/Right Side . . . 220
Lying Prone . . . 221
Abnormal Illness Behavior . . . 221
Reproducibility . . . 221
Differential Diagnosis of Spinal Pain Syndromes 222
Recapitulation . . . 222
Key Articles . . . 223
References . . . 224

### 9 Imaging Studies
Marius R. Schmid, Jürg Hodler
Core Messages . . . 227
Imaging Methods . . . 227
Standard Radiographs . . . 227
Magnetic Resonance Imaging . . . 229
Computed Tomography . . . 241
Additional Imaging Methods . . . 244
Indications for Spinal Imaging . . . 247
Acute Low Back Pain Without Radicular Symptoms, Without Trauma . . . 247
Acute Low Back Pain With Radicular Symptoms . . . 248
Spinal Cord and Cauda Compression Syndromes . . . 249
Acute Trauma . . . 249
Chronic Low Back Pain . . . 251
Postoperative Imaging . . . 251
Whiplash-Associated Disorders . . . 252
Pain Relating to the Sacroiliac Joint . . . 253
Disease of the Spinal Cord . . . 255
Recapitulation . . . 255
Key Articles . . . 256
References . . . 257

### 10 Spinal Injections
Massimo Leonardi, Christian W. Pfirrmann
Core Messages . . . 261
Rationale for Spinal Injections . . . 261
Lumbar and Cervical Nerve Root Blocks . . . 262
Indications . . . 262
Technique . . . 263
Complications . . . 265
Diagnostic and Therapeutic Efficacy . . . 265
Epidural and Caudal Blocks . . . 267
Indications . . . 267
Technique . . . 268
Complications . . . 268
Therapeutic Efficacy . . . 268
Provocative Discography . . . 271
Indications . . . 271
Technique . . . 272
Complications . . . 273
Diagnostic Efficacy . . . 273
Facet Joint Blocks . . . 275
Indications . . . 275
Technique . . . 276
Complications . . . 277
Diagnostic and Therapeutic Efficacy . . . 278
Sacroiliac Joint Blocks . . . 280
Indications . . . 280
Technique . . . 280
Complications . . . 280
Diagnostic Efficacy . . . 281
Contraindications for Spinal Injections . . . 281
Algorithm for Spinal Injections . . . 282
Recapitulation . . . 283
Key Articles . . . 284
References . . . 285

### 11 Neurological Assessment in Spinal Disorders
Uta Kliesch, Armin Curt
Core Messages . . . 291
Epidemiology . . . 291
Case Introduction . . . 292
Anatomy and Somatotopic Background . . . 294
Classification . . . 295
Neurological Assessment . . . 298
Pain . . . 298

Sensory Deficits . . . . . 298
Motor Deficits . . . . . 299
Reflex Deficits . . . . . 299
Gait Disorders . . . . . 301
Bowel and Bladder Dysfunction . . . . . 303
Disorders of the Autonomic System . . . . . 303
Spinal Cord Injury . . . . . 304
Spinal Cord Syndrome . . . . . 304
Differential Diagnosis . . . . . 306
Differentiation of Central and Peripheral Paresis . . . . . 306
Differentiation of Radicular and Peripheral Nerve Lesions . . . . . 306
Differential Diagnosis of Spinal Cord Compression Syndromes . . . . . 311
Miscellaneous Differential Diagnoses . . . . . 311
Recapitulation . . . . . 312
Key Articles . . . . . 313
References . . . . . 314

12 Neurophysiological Investigations
Armin Curt, Uta Kliesch
Core Messages . . . . . 319
Historical Background . . . . . 319
Neuroanatomy . . . . . 320
Neurophysiological Modalities . . . . . 321
Electromyography . . . . . 321
Nerve Conduction Studies . . . . . 322
F-Wave Recordings . . . . . 324
H-Reflex . . . . . 325
Somatosensory Evoked Potentials . . . . . 326
Motor Evoked Potentials (Transcranial Magnetic Stimulation) . . . . . 328
Intraoperative Neuromonitoring . . . . . 329
Role of Neurophysiology in Specific Disorders . . 330
Spinal Cord Injury . . . . . 330
Cervical/Lumbar Radiculopathy . . . . . 330
Cervical Myelopathy . . . . . 331
Lumbar Spinal Canal Stenosis . . . . . 331
Neurophysiology in Differential Diagnosis . . . . 332
Peripheral Nerve Lesion Versus Radiculopathy 332
Neuropathy Versus Spinal Canal Stenosis . . . 332
Myopathy and Myotonic Disorders . . . . . 333
Hereditary and Neurodegenerative Disease . 333
Recapitulation . . . . . 334
Key Articles . . . . . 334
References . . . . . 335

13 Surgical Approaches
Norbert Boos, Claudio Affolter, Martin Merkle, Frank J. Ruehli
Core Messages . . . . . 337
Surgery and Planning . . . . . 337
Anterior Medial Approach to Cervical Spine . . . 337
Indications . . . . . 338
Patient Positioning . . . . . 338
Surgical Exposure . . . . . 339
Pitfalls and Complications . . . . . 341
Posterior Approach to the Cervical Spine . . . . . 342
Indications . . . . . 342
Patient Positioning . . . . . 342
Surgical Exposure . . . . . 343
Pitfalls and Complications . . . . . 345
Right-Sided Thoracotomy . . . . . 345
Indications . . . . . 346
Patient Positioning . . . . . 346
Surgical Exposure . . . . . 346
Pitfalls and Complications . . . . . 349
Left-Sided Thoraco-Phrenico-Lumbotomy . . . . 350
Indications . . . . . 350
Patient Positioning . . . . . 350
Surgical Exposure . . . . . 350
Pitfalls and Complications . . . . . 353
Anterior-Lateral Retroperitoneal Approach to L2–L5 . . . . . 353
Indications . . . . . 353
Patient Positioning . . . . . 353
Surgical Exposure . . . . . 353
Pitfalls and Complications . . . . . 355
Anterior Lumbar Retroperitoneal Approach . . . 355
Indications . . . . . 355
Patient Positioning . . . . . 355
Surgical Exposure . . . . . 356
Pitfalls and Complications . . . . . 358
Posterior Approach to the Thoracolumbar Spine 358
Indications . . . . . 358
Patient Positioning . . . . . 358
Surgical Exposure . . . . . 359
Pitfalls and Complications . . . . . 361
Landmarks for Screw Insertion . . . . . 361
Cervico-occipital Spine . . . . . 361
Recapitulation . . . . . 368
Key Articles . . . . . 369
References . . . . . 369

Peri- and Postoperative Management

14 Preoperative Assessment
Stephan Blumenthal, Youri Reiland, Alain Borgeat
Core Messages . . . . . 373
Aim of Preanesthetic Evaluation . . . . . 373
Information and Instructions . . . . . 374
Patient Assessment . . . . . 374
History . . . . . 374
Physical Examination . . . . . 375
Laboratory Studies . . . . . 375

Organ-Specific Assessment . . . . . 376
Airway Assessment . . . . . 376
Respiratory System . . . . . 376
Cardiovascular Assessment . . . . . 378
Neurological Assessment . . . . . 379
Perioperative Drug Therapy . . . . . 379
What to Stop, to Continue and to Add? . . . . . 379
Premedication . . . . . 380
Thromboembolic Prophylaxis . . . . . 380
Special Conditions Requiring Spinal Surgery . . 382
Spinal Deformity . . . . . 382
Neuromuscular Disease . . . . . 383
Cerebral Palsy . . . . . 383
Malignancy . . . . . 384
Spinal Cord Injury . . . . . 384
Recapitulation . . . . . 385
Key Articles . . . . . 386
References . . . . . 387

15 Intraoperative Anesthesia Management
Juan Francisco Asenjo
Core Messages . . . . . 389
Historical Background . . . . . 389
Goals of Anesthesia in Spinal Surgery . . . . . 389
Preoperative Patient Assessment . . . . . 390
Induction of Anesthesia . . . . . 390
Airway Control and Endotracheal Intubation 391
Antibiotic Prophylaxis . . . . . 393
Patient Positioning . . . . . 394
Maintenance of Anesthesia . . . . . 396
Intraoperative Monitoring Techniques . . . . . 397
Advanced Monitoring of Vital Functions . . . . 397
Monitoring Depth of Anesthesia (Consciousness) . . . . . 400
Intraoperative Blood Preserving Techniques . . . 400
Controlled Hypotensive Anesthesia . . . . . 401
Intrathecal Opiates . . . . . 402
Blood Predeposit and Erythropoietin Injection . . . . . 402
Cell Salvage . . . . . 402
Pharmacological Measures . . . . . 403
Blood Transfusion and Coagulation Factor Substitution . . . . . 403
Intraoperative Spinal Cord Monitoring . . . . . 405
Anesthetic Effects on SSEPs . . . . . 406
Anesthetic Effects on MEPs . . . . . 407
Nerve Root Monitoring . . . . . 408
Wake-up Test . . . . . 408
End of Anesthesia . . . . . 409
Postoperative Pain Management . . . . . 409
Recapitulation . . . . . 411
Key Articles . . . . . 411
References . . . . . 412

16 Postoperative Care and Pain Management
Stephan Blumenthal, Alain Borgeat
Core Messages . . . . . 417
Postoperative Care . . . . . 417
Postoperative Ventilation or Extubation . . . . 418
Hemodynamic Assessment . . . . . 419
Neurological Assessment . . . . . 419
Gastrointestinal Function . . . . . 420
Thromboembolic Prophylaxis . . . . . 420
Postoperative Pain Management . . . . . 420
Consequences of Pain . . . . . 420
Non-narcotics . . . . . 421
Non-steroidal Drugs . . . . . 421
Opioids . . . . . 421
Local Anesthetics . . . . . 422
*N*-Methyl-D-aspartate Antagonists . . . . . 422
Recapitulation . . . . . 423
Key Articles . . . . . 423
References . . . . . 424

Degenerative Disorders

17 Degenerative Disorders of the Cervical Spine
Massimo Leonardi, Norbert Boos
Core Messages . . . . . 429
Case Introduction . . . . . 430
Epidemiology . . . . . 430
Pathogenesis . . . . . 432
Neck Pain . . . . . 432
Cervical Disc Herniation . . . . . 432
Cervical Spondylotic Radiculopathy . . . . . 433
Cervical Spondylotic Myelopathy . . . . . 433
Clinical Presentation . . . . . 435
History . . . . . 436
Physical Findings . . . . . 437
Functional Assessment . . . . . 439
Diagnostic Work-up . . . . . 439
Imaging Studies . . . . . 439
Neurophysiological Assessment . . . . . 444
Differential Diagnosis . . . . . 444
Non-operative Treatment . . . . . 444
Natural History . . . . . 445
Conservative Treatment Modalities . . . . . 446
Operative Treatment . . . . . 448
General Principles . . . . . 448
Surgical Techniques . . . . . 449
Case Study 1 . . . . . 451
Case Study 2 . . . . . 454
Case Study 3 . . . . . 456
Surgical Decision-Making . . . . . 459
Complications . . . . . 463
Recapitulation . . . . . 464
Key Articles . . . . . 466
References . . . . . 468

## 18 Disc Herniation and Radiculopathy
Massimo Leonardi, Norbert Boos
Core Messages . . . 481
Epidemiology . . . 481
Case Introduction . . . 482
Pathogenesis . . . 483
Risk Factors . . . 483
Radiculopathy . . . 484
Clinical Presentation . . . 486
History . . . 486
Physical Findings . . . 487
Diagnostic Work-up . . . 488
Imaging Studies . . . 488
Neurophysiologic Assessment . . . 490
Urologic Assessment . . . 490
Differential Diagnosis . . . 491
Classification . . . 491
Non-operative Treatment . . . 493
Natural History . . . 494
Conservative Measures . . . 494
Operative Treatment . . . 496
General Principles . . . 496
Case Study 1 . . . 497
Surgical Techniques . . . 497
Case Study 2 . . . 499
Conservative Versus Operative Treatment . . . 503
Complications . . . 504
Recapitulation . . . 505
Key Articles . . . 506
References . . . 507

## 19 Lumbar Spinal Stenosis
Patrick O. Zingg, Norbert Boos
Core Messages . . . 513
Epidemiology . . . 513
Case Introduction . . . 514
Pathogenesis . . . 515
Anatomy . . . 515
Pathogenesis . . . 515
Spinal Claudication Syndrome . . . 517
Classification . . . 517
Clinical Presentation . . . 519
History . . . 519
Physical Findings . . . 520
Diagnostic Work-up . . . 520
Imaging Studies . . . 520
Neurophysiologic Studies . . . 523
Differential Diagnosis . . . 524
Non-operative Treatment . . . 524
Natural History . . . 525
Non-operative Options . . . 525
Operative Treatment . . . 526
General Principles . . . 526
Surgical Techniques . . . 526
Case Study 1 . . . 527
Case Study 2 . . . 529
Operative Risks and Complications . . . 530
Recapitulation . . . 531
Key Articles . . . 532
References . . . 533

## 20 Degenerative Lumbar Spondylosis
Martin Merkle, Beat Wälchli, Norbert Boos
Core Messages . . . 539
Epidemiology . . . 539
Case Introduction . . . 540
Pathogenesis . . . 541
Disc Degeneration and Discogenic Back Pain 542
Facet Joint Osteoarthritis . . . 543
Segmental Instability . . . 544
Clinical Presentation . . . 545
History . . . 546
Case Study 1 . . . 547
Physical Findings . . . 548
Diagnostic Work-up . . . 548
Imaging Studies . . . 549
Case Study 2 . . . 550
Injection Studies . . . 551
Temporary Stabilization . . . 552
Patient Selection for Treatment . . . 552
Non-operative Treatment . . . 553
Operative Treatment . . . 554
General Principles . . . 554
Biology of Spinal Fusion . . . 555
Surgical Techniques . . . 558
Comparison of Treatment Modalities . . . 568
Complications . . . 569
Recapitulation . . . 570
Key Articles . . . 571
References . . . 573

## 21 Non-specific Low Back Pain
Florian Brunner, Sherri Weiser, Annina Schmid, Margareta Nordin
Core Messages . . . 585
Epidemiology . . . 585
Case Introduction . . . 586
Classification of Back Pain . . . 587
Pathogenesis of NSLBP . . . 587
Patient Assessment and Triage for Non-operative Treatment . . . 588
Management of NSLBP . . . 590
Management of Acute NSLBP (< 4 weeks) . . . 590
Management of Subacute NSLBP (4 – 12 weeks) 592
Management of Chronic Non-specific LBP (> 12 weeks) . . . 595
Recapitulation . . . 596

Key Articles . . . . . 596
References . . . . . 598

22 Postoperative Rehabilitation
Florian Brunner, Shira Schecter-Weiner, Annina Schmid, Rudolf Kissling
Core Messages . . . . . 603
Epidemiology . . . . . 603
Conceptional Background . . . . . 604
Theoretical Considerations . . . . . 604
Anatomical and Surgical Considerations . . . . 605
Individual and Societal Considerations . . . . . 606
Indications for Postoperative Spinal Rehabilitation . . . . . 606
General Goals . . . . . 607
Specific Goals . . . . . 607
Principles of Postoperative Rehabilitation . . . . . 607
Preoperative Assessment . . . . . 607
Postoperative Rehabilitation . . . . . 608
Obstacles for Rehabilitation . . . . . 616
Morphological Obstacles and General Medical Obstacles . . . . . 616
Psychosocial Obstacles . . . . . 617
Work-Related Obstacles . . . . . 617
Recapitulation . . . . . 617
Key Articles . . . . . 618
References . . . . . 619

Spinal Deformities and Malformations

23 Idiopathic Scoliosis
Mathias Haefeli, Kan Min
Core Messages . . . . . 623
Epidemiology . . . . . 623
Case Introduction . . . . . 624
Pathogenesis . . . . . 625
Genetic Factors . . . . . 625
Connective Tissue and Skeletal Muscle Abnormalities . . . . . 625
Thrombocyte Abnormalities, Calmodulin and Melatonin . . . . . 626
Classification . . . . . 626
Age-Related Classification . . . . . 626
Radiological Classification . . . . . 627
Clinical Presentation . . . . . 627
History . . . . . 627
Physical Examination . . . . . 629
Diagnostic Work-up . . . . . 632
Imaging Studies . . . . . 632
Neurophysiologic Evaluation . . . . . 637
Treatment . . . . . 637
General Considerations . . . . . 637
Natural History . . . . . 637
Non-operative Options . . . . . 639
Operative Treatment . . . . . 641
Indications for Surgery . . . . . 641
General Principles . . . . . 642
Case Study 1 . . . . . 646
Surgical Decision Making . . . . . 647
Case Study 2 . . . . . 651
Complications . . . . . 651
Recapitulation . . . . . 652
Key Articles . . . . . 653
References . . . . . 654

24 Neuromuscular Scoliosis
Jean A. Ouellet, Vincent Arlet
Core Messages . . . . . 663
Epidemiology . . . . . 663
Case Introduction . . . . . 664
Disease Specific Spinal Deformity . . . . . 666
Pathogenesis . . . . . 667
Classification . . . . . 667
Clinical Presentation . . . . . 669
History . . . . . 669
Physical Examination . . . . . 670
Case Study 1 . . . . . 671
Diagnostic Work-up . . . . . 673
Medical Assessment . . . . . 673
Case Study 2 . . . . . 674
Imaging Studies . . . . . 675
Non-operative Treatment . . . . . 677
Natural History . . . . . 677
Non-operative Treatment Options . . . . . 678
Operative Treatment . . . . . 678
Surgical Indications . . . . . 678
General Principles . . . . . 679
Surgical Techniques . . . . . 680
Case Study 3 . . . . . 680
Case Study 4 . . . . . 686
Recapitulation . . . . . 689
Key Articles . . . . . 690
References . . . . . 691

25 Congenital Scoliosis
Francis H. Shen, Vincent Arlet
Core Messages . . . . . 693
Epidemiology . . . . . 693
Case Introduction . . . . . 694
Pathogenesis . . . . . 694
Classification . . . . . 695
Clinical Presentation . . . . . 696
History . . . . . 696
Physical Findings . . . . . 697
Diagnostic Work-up . . . . . 698
Imaging Studies . . . . . 698
Specific Investigations . . . . . 700
Non-operative Treatment . . . . . 700

Natural History and Progression ..... 700
Operative Treatment ..... 701
General Principles ..... 701
Surgical Techniques ..... 702
Corrective Surgery Procedures ..... 702
Case Study 1 ..... 703
Case Study 2 ..... 704
Miscellaneous Surgical Techniques ..... 707
Recapitulation ..... 708
Key Articles ..... 709
References ..... 710

26 Degenerative Scoliosis
Max Aebi
Core Messages ..... 713
Epidemiology ..... 713
Case Introduction ..... 714
Pathogenesis ..... 715
Classification ..... 716
Clinical Presentation ..... 717
History ..... 717
Physical Findings ..... 719
Diagnostic Workup ..... 720
Imaging Studies ..... 720
Interventional Radiological Procedure ..... 721
Additional Diagnostic Tools ..... 722
Non-operative Treatment ..... 722
Operative Treatment ..... 723
Decompression Procedure ..... 724
Correction Procedures ..... 724
Surgical Techniques ..... 725
Case Study 1 ..... 728
Case Study 2 ..... 729
Recapitulation ..... 729
Key Articles ..... 730
References ..... 731

27 Spondylolisthesis
Clayton N. Kraft, Rüdiger Krauspe
Core Messages ..... 733
Epidemiology ..... 733
Case Introduction ..... 734
Pathogenesis ..... 735
Classification ..... 735
Clinical Presentation ..... 736
History ..... 736
Physical Findings ..... 738
Differential Diagnosis ..... 738
Diagnostic Work-up ..... 739
Imaging ..... 739
Case Study 1 ..... 742
Invasive Imaging Studies ..... 743
Non-operative Treatment ..... 745
Natural History ..... 745
Conservative Treatment Options ..... 745
Operative Treatment ..... 747
General Principles ..... 747
Surgical Techniques ..... 748
Case Study 2 ..... 751
Complications ..... 756
Recapitulation ..... 757
Key Articles ..... 758
References ..... 759

28 Juvenile Kyphosis (Scheuermann's Disease)
Dietrich Schlenzka, Vincent Arlet
Core Messages ..... 765
Epidemiology ..... 765
Case Introduction ..... 766
Pathogenesis ..... 767
Normal Sagittal Profile ..... 768
Definition and Classification ..... 771
Clinical Presentation ..... 773
History ..... 773
Physical Findings ..... 774
Diagnostic Work-up ..... 775
Imaging Studies ..... 775
Neurophysiological Tests ..... 777
Lung Function Test ..... 777
Differential Diagnosis ..... 777
Non-operative Treatment ..... 779
Natural History ..... 779
Bracing and Casting ..... 780
Case Study 1 ..... 780
Operative Treatment ..... 782
Preoperative Assessment ..... 782
General Principles ..... 783
Operative Technique ..... 784
Case Study 2 ..... 786
Results of Operative Treatment ..... 788
Complications ..... 790
Recapitulation ..... 791
Key Articles ..... 792
References ..... 793

29 Malformations of the Spinal Cord
Dilek Könü-Leblebicioglu, Yasuhiro Yonekawa
Core Messages ..... 797
Epidemiology ..... 797
Case Introduction ..... 798
Pathogenesis ..... 799
Embryological Aspects ..... 799
Relevant Embryogenetic Steps ..... 800
Risk Factors ..... 801
Pathophysiology of Tethered Cord Syndrome 802
Terminology and Classification ..... 802
Classification of Spinal Malformation ..... 803

Case Study 1 . . . . . 805
Classification of Tethered Spinal Cord . . . . . 811
Clinical Presentation . . . . . 812
History . . . . . 812
Physical Findings . . . . . 813
Diagnostic Work-up . . . . . 814
Prenatal Diagnosis . . . . . 814
Postnatal Diagnostic Tests . . . . . 815
Treatment . . . . . 815
In Utero Treatment . . . . . 816
Postnatal Surgery . . . . . 816
Recapitulation . . . . . 818
Key Articles . . . . . 819
References . . . . . 819

## Fractures

### 30 Cervical Spine Injuries
Michael Heinzelmann, Karim Eid, Norbert Boos
Core Messages . . . . . 825
Case Introduction . . . . . 826
Epidemiology . . . . . 827
Pathomechanisms . . . . . 828
Normal Anatomy . . . . . 828
Biomechanics of Cervical Spine Trauma . . . . 830
Spinal Cord Injury . . . . . 832
Pathomechanism of Whiplash-Associated Disorders . . . . . 833
Clinical Presentation . . . . . 834
History . . . . . 834
Physical Findings . . . . . 835
Classification of Whiplash-Associated Disorders . . . . . 836
Diagnostic Work-up . . . . . 836
Imaging Studies . . . . . 836
Neurophysiology . . . . . 842
Vascular Assessment . . . . . 842
Synopsis of Assessment Recommendations . . 842
General Treatment Principles . . . . . 844
Whiplash-Associated Disorders . . . . . 844
Non-operative Treatment Modalities . . . . . 845
Spinal Cord Injuries . . . . . 848
Specific Treatment of Upper Cervical Spine Injuries . . . . . 850
Fractures of the Occipital Condyle . . . . . 850
Atlanto-occipital Dislocation . . . . . 851
Fractures of the Atlas . . . . . 852
Atlantoaxial Instabilities . . . . . 853
Dens Fractures . . . . . 854
Case Study 1 . . . . . 858
Traumatic Spondylolisthesis of the Axis . . . . 860
Case Study 2 . . . . . 862
Combined Atlas/Axis Fractures . . . . . 863
Classification and Treatment of Subaxial Injuries 863
Classification . . . . . 864
Treatment . . . . . 866
Case Study 3 . . . . . 870
Complications . . . . . 871
Recapitulation . . . . . 871
Key Articles . . . . . 873
References . . . . . 874

### 31 Thoracolumbar Spinal Injuries
Michael Heinzelmann, Guido A. Wanner
Core Messages . . . . . 883
Epidemiology . . . . . 883
Case Introduction . . . . . 884
Pathomechanisms . . . . . 885
Axial Compression . . . . . 885
Flexion/Distraction . . . . . 886
Hyperextension . . . . . 886
Rotational Injuries . . . . . 886
Shear . . . . . 887
Classification . . . . . 887
Denis Classification . . . . . 888
AO Classification . . . . . 888
Clinical Presentation . . . . . 892
Spinal Injuries . . . . . 892
Neurological Deficit . . . . . 892
Concomitant Non-spinal Injuries . . . . . 893
History . . . . . 893
Physical Findings . . . . . 894
Diagnostic Work-up . . . . . 895
Imaging Studies . . . . . 895
Non-operative Treatment . . . . . 898
Steroid Treatment of Spinal Cord Injury . . . . 899
Non-operative Treatment Modalities . . . . . 899
Case Study 1 . . . . . 900
Operative Treatment . . . . . 903
General Principles . . . . . 903
Surgical Techniques . . . . . 905
Case Study 2 . . . . . 906
Case Study 3 . . . . . 911
Outcome of Operative Versus Non-operative Treatment . . . . . 914
Recapitulation . . . . . 918
Key Articles . . . . . 919
References . . . . . 920

### 32 Osteoporotic Spine Fractures
Paul F. Heini, Albrecht Popp
Core Messages . . . . . 925
Epidemiology . . . . . 925
Case Introduction . . . . . 926
Pathogenesis and Definition . . . . . 926
Classification of Vertebral Body Compression Fractures . . . . . 929

Clinical Presentation . . . . . 930
History . . . . . 930
Physical Findings . . . . . 933
Diagnostic Work-up . . . . . 933
Imaging Studies . . . . . 933
Radionuclide Studies . . . . . 934
Densitometry . . . . . 934
Bone Biopsy . . . . . 935
Laboratory Investigations . . . . . 935
Non-operative Treatment . . . . . 936
Conservative Fracture Management . . . . . 936
Medical Treatment . . . . . 936
Operative Treatment . . . . . 937
General Principles . . . . . 937
Surgical Principles . . . . . 937
Recapitulation . . . . . 942
Key Articles . . . . . 943
References . . . . . 944

## Tumors and Inflammation

### 33 Primary Tumors of the Spine

Bruno Fuchs, Norbert Boos

Core Messages . . . . . 951
Epidemiology . . . . . 951
Case Introduction . . . . . 952
Tumor Biology . . . . . 953
Molecular Tumor Biology . . . . . 953
Pathways of Metastasis . . . . . 954
Histology and Biology of Spinal Tumors . . . . 956
Clinical Presentation . . . . . 957
History . . . . . 957
Physical Findings . . . . . 957
Diagnostic Work-up . . . . . 958
Imaging Studies . . . . . 958
Case Study 1 . . . . . 960
Case Study 2 . . . . . 961
Biopsy . . . . . 964
Laboratory Investigations . . . . . 964
Tumor Staging . . . . . 964
Benign Tumors . . . . . 965
Malignant Tumors . . . . . 966
Non-operative Treatment . . . . . 967
Non-steroidal Anti-inflammatory Drugs . . . 967
Adjuvant Therapy . . . . . 967
Operative Treatment . . . . . 968
General Principles . . . . . 968
Surgical Techniques . . . . . 969
Case Study 3 . . . . . 971
Recapitulation . . . . . 973
Key Articles . . . . . 974
References . . . . . 974

### 34 Spinal Metastasis

Dante G. Marchesi

Core Messages . . . . . 977
Epidemiology . . . . . 977
Case Introduction . . . . . 978
Pathogenesis . . . . . 978
Clinical Presentation . . . . . 980
History . . . . . 980
Physical Findings . . . . . 980
Diagnostic Work-up . . . . . 981
Imaging Studies . . . . . 981
Biopsy . . . . . 983
Laboratory Investigation . . . . . 983
Classification . . . . . 984
Non-operative Treatment . . . . . 985
Steroids . . . . . 985
Radiotherapy . . . . . 985
Operative Treatment . . . . . 986
General Principles . . . . . 986
General Surgical Techniques . . . . . 987
Specific Surgical Techniques . . . . . 988
Case Study 1 . . . . . 989
Case Study 2 . . . . . 992
Case Study 3 . . . . . 993
Postoperative Patient Management . . . . . 993
Recapitulation . . . . . 994
Key Articles . . . . . 995
References . . . . . 995

### 35 Intradural Tumors

Yashuhiro Yonekawa, Richard Marugg

Core Messages . . . . . 997
Epidemiology . . . . . 997
Case Introduction . . . . . 998
Etiology and Pathogenesis . . . . . 998
Classification of Intradural Tumors . . . . . 999
Intradural-Extramedullary Tumors . . . . . 999
Differential Diagnosis . . . . . 1000
Case Study 1 . . . . . 1001
Intradural-Intramedullary Tumors . . . . . 1002
Case Study 2 . . . . . 1004
Clinical Presentation . . . . . 1005
History . . . . . 1005
Physical Findings . . . . . 1006
Diagnostic Work-up . . . . . 1006
Imaging Studies . . . . . 1007
Lumbar Puncture . . . . . 1008
Treatment . . . . . 1009
Non-surgical Treatment . . . . . 1009
Surgical Treatment . . . . . 1009
Surgical Techniques . . . . . 1010
Intrinsic Spinal Cord Tumor Resection . . . . 1012
Case Study 3 . . . . . 1013
Recapitulation . . . . . 1016

Key Articles . . . . . 1017
References . . . . . 1018

36 Infections of the Spine
Norbert Boos
Core Messages . . . . . 1021
Epidemiology . . . . . 1021
Case Introduction . . . . . 1022
Pathogenesis . . . . . 1023
Classification . . . . . 1023
Clinical Presentation . . . . . 1024
History . . . . . 1024
Physical Findings . . . . . 1025
Diagnostic Work-up . . . . . 1025
Labaratory Investigations . . . . . 1025
Imaging Studies . . . . . 1026
Biopsy . . . . . 1028
Nonoperative Treatment . . . . . 1029
Case Study 1 . . . . . 1030
Operative Treatment . . . . . 1031
General Principles . . . . . 1031
Surgical Techniques . . . . . 1031
Case Study 2 . . . . . 1035
Recapitulation . . . . . 1036
Key Articles . . . . . 1037
References . . . . . 1037

37 Rheumatoid Arthritis
Dieter Grob
Core Messages . . . . . 1041
Epidemiology . . . . . 1041
Pathogenesis . . . . . 1041
Case Introduction . . . . . 1042
Classification . . . . . 1044
Clinical Presentation . . . . . 1045
History . . . . . 1045
Physical Findings . . . . . 1045
Diagnostic Work-up . . . . . 1045
Imaging Studies . . . . . 1045
Case Study 1 . . . . . 1047
Injection Studies . . . . . 1048
Neurophysiological Investigations . . . . . 1048
Non-operative Treatment . . . . . 1048
Operative Treatment . . . . . 1048
General Principles . . . . . 1048
Indications . . . . . 1049
Surgical Techniques . . . . . 1050
Case Study 2 . . . . . 1053
Recapitulation . . . . . 1054
Key Articles . . . . . 1054
References . . . . . 1055

38 Ankylosing Spondylitis
Thomas Liebscher, Kan Min, Norbert Boos
Core Messages . . . . . 1057
Epidemiology . . . . . 1057
Case Introduction . . . . . 1058
Pathogenesis . . . . . 1060
Clinical Presentation . . . . . 1061
History . . . . . 1061
Physical Findings . . . . . 1062
Diagnostic Work-up . . . . . 1063
Laboratory Investigations . . . . . 1063
Imaging Studies . . . . . 1063
Diagnostic Criteria . . . . . 1066
Non-operative Treatment . . . . . 1067
Natural History . . . . . 1067
Non-operative Management . . . . . 1068
Physiotherapy . . . . . 1069
Treatment Recommendations . . . . . 1069
Operative Treatment . . . . . 1070
General Principles . . . . . 1070
Planning of Osteotomies . . . . . 1071
Surgical Techniques . . . . . 1072
Case Study 1 . . . . . 1076
Case Study 2 . . . . . 1078
Complications . . . . . 1080
Recapitulation . . . . . 1080
Key Articles . . . . . 1081
References . . . . . 1082

39 Treatment of Postoperative Complications
Martin Krismer, Norbert Boos
Core Messages . . . . . 1087
Frequency of Complications . . . . . 1087
Cervical Spine Surgery . . . . . 1087
Case Introduction . . . . . 1088
Anterior Spinal Surgery . . . . . 1089
Disc Herniation and Spinal Stenosis . . . . . 1089
Lumbar Spinal Fusion . . . . . 1090
Comparison of Complications . . . . . 1090
Preventive Measures . . . . . 1090
Screening of Risk Factors . . . . . 1091
Preoperative Planning . . . . . 1093
Profound Knowledge of Anatomy . . . . . 1094
Patient Positioning . . . . . 1094
Neuromonitoring . . . . . 1095
Approach-Related Complications . . . . . 1095
Anteromedial Cervical Approach . . . . . 1096
Case Study 1 . . . . . 1097
Anterior Approach to the Cervicothoracic Junction . . . . . 1098
Thoracotomy . . . . . 1098
Thoracolumbar Approach . . . . . 1100

Anterior Lumbar and Lumbosacral Approach . . . 1100
Posterior Approach to the Cervical Spine . . 1103
Posterior Approaches to the Thoracic and Lumbar Spine . . . 1104
Procedure Related Complications . . . 1104
Decompressive Cervical and Lumbar Surgery . . . 1104
Deformity Correction . . . 1106
Reduction of High-Grade Spondylolisthesis 1108
Corpectomy/Osteotomy . . . 1108
Postoperative Complications . . . 1109
Homeostasis Related Complications . . . 1109
Neurological Complications . . . 1110
Postoperative Wound Problems . . . 1110
Cerebrospinal Fluid Fistula . . . 1112
Vascular Complications . . . 1112
Pulmonary Problems . . . 1113
Gastrointestinal Problems . . . 1113
Urogenital Complications . . . 1114
Retrograde Ejaculation . . . 1114
Recapitulation . . . 1115
Key Articles . . . 1116
References . . . 1117

## 40 Outcome Assessment in Spinal Surgery

Mathias Haefeli, Norbert Boos

Core Messages . . . 1123
General Concepts of Outcome Assessment . . . 1123
Pain . . . 1125
General Aspects . . . 1125
Instruments . . . 1126
Disability . . . 1128
General Aspects . . . 1128
Instruments . . . 1128
Quality of Life . . . 1130
General Aspects . . . 1130
Instruments . . . 1130
Psychosocial Aspects, Work Situation and Fear Avoidance Beliefs . . . 1133
General Aspects . . . 1133
Instruments . . . 1133
Clinical Feasibility and Practicability . . . 1134
Recapitulation . . . 1135
References . . . 1136

**Subject Index** . . . 1143

**The Editors** . . . 1163

**The Medical Illustrator** . . . 1164

**The Artist** . . . 1165

# List of Contributors

**Max Aebi**
Institut für Evaluative Forschung in Orthopädischer Chirurgie,
MEM Forschungszentrum, Universität Bern,
Stauffacherstr. 78, 3014 Bern, Schweiz
e-mail: max.aebi@MEMcenter.unibe.ch

**Claudio Affolter**
Anatomisches Institut, Universität Zürich, Winterthurerstr. 190, 8057 Zürich, Schweiz

**Vincent Arlet**
Division of Scoliosis and Spine Surgery, Department of Orthopedic Surgery,
University of Virginia, Charlottesville, VA 22908-0159, USA
e-mail: va3e@hscmail.mcc.virginia.edu

**Juan Francisco Asenjo**
Department of Anaesthesia, Montreal General Hospital, McGill University Health Centre, 1650 Cedar Avenue, Room D8.132, Montreal (Quebec), H3G 1A4, Canada
e-mail: Jfasenjo@yahoo.com

**Stephan Blumenthal**
Anästhesie, Universitätsklinik Balgrist, Forchstr. 340, 8008 Zürich, Schweiz
e-mail: stephan.blumenthal@balgrist.ch

**Thomas Boeni**
Orthopädie, Universitätsklinik Balgrist, Forchstr. 340, 8008 Zürich, Schweiz
Medizinhistorisches Museum, Universität Zürich, Rämistrasse 69, 8091 Zürich, Schweiz
e-mail: thomas.boeni@balgrist.ch

**Norbert Boos**
Zentrum für Wirbelsäulen- und Rückenmarkchirurgie, Universität Zürich,
Universitätsklinik Balgrist, Forchstr. 340, 8008 Zürich, Schweiz
e-mail: norbert.boos@balgrist.ch

**Alain Borgeat**
Anästhesie, Universitätsklinik Balgrist, Forchstr. 340, 808 Zürich, Schweiz
e-mail: alain.borgeat@balgrist.ch

**Florian Brunner**
Rheumatologie, Universitätsklinik Balgrist, Forchstr. 340, 8008 Zürich, Schweiz
e-mail: florian.brunner@balgrist.ch

**Armin Curt**
Spinal Cord Rehabilitation, ICORD, University of British Columbia,
2469–6270 University Blvd., V6T 1Z1, Vancouver, Canada
e-mail: curt@icord.org

**Karim Eid**
Zentrum für Wirbelsäulen- und Rückenmarkchirurgie, Universität Zürich,
Universitätsklinik Balgrist, Forchstr. 340, 8008 Zürich, Schweiz
e-mail: karim.eid.@balgrist.ch

**Achim Elfering**
Psychologisches Institut, Universität Bern, Muesmattstr. 43, 3000 Bern 9,
Schweiz
e-mail: Achim.elfering@psy.unibe.ch

**Stephen Ferguson**
Institut für chirurgische Technologien und Biomechanik,
MEM Forschungszentrum, Universität Bern, Stauffacherstr. 78, 3014 Bern,
Schweiz
e-mail: stephen.ferguson@MEMcenter.unibe.ch

**Bruno Fuchs**
Universitätsklinik Balgrist, Forchstr. 340, 8008 Zürich, Schweiz
e-mail: bruno.fuchs@reasearch.balgrist.ch

**Dieter Grob**
Wirbelsäulenzentrum, Schulthessklinik, Lengghalde 2, 8008 Zürich, Schweiz
e-mail: dieter.grob@kws

**Philipp Gruber**
Orthopädie, Universitätsklinik Balgrist, Forchstr. 340, 8008 Zürich, Schweiz
Medizinhistorisches Museum, Universität Zürich, Rämistrasse 69, 8091 Zürich,
Schweiz
e-mail: ph.gruber@bluewin.ch

**Mathias Haefeli**
Zentrum für Wirbelsäulen- und Rückenmarkchirurgie, Universität Zürich,
Universitätsklinik Balgrist, Forchstr. 340, 8008 Zürich, Schweiz
e-mail: mhaefeli@research.balgrist.ch

**Daniel Haschtmann**
Institut für chirurgische Technologien und Biomechanik,
MEM Forschungszentrum, Universität Bern, Stauffacherstr. 78, 3014 Bern,
Schweiz
e-mail: daniel.haschtmann@MEMcenter.unibe.ch

**Paul Heini**
Orthopädische Universitätsklinik, Inselspital Bern, 3010 Bern, Schweiz
e-mail: paul.heini@insel.ch

**Michael Heinzelmann**
Zentrum für Wirbelsäulen- und Rückenmarkchirurgie, Universität Zürich,
Klinik für Unfallchirurgie, Universitätsspital Zürich, Rämistr. 100, 8091 Zürich,
Schweiz
e-mail: michael.heinzelmann@usz.ch

**Jürg Hodler**
Radiologie, Universitätsklinik Balgrist, Forchstr. 340, 8008 Zürich, Schweiz
e-mail: juerg.hodler@balgrist.ch

**Rudolf Kissling**
Rheumatologie, Universitätsklinik Balgrist, Forchstr. 340, 8008 Zürich, Schweiz
e-mail: rudolf.kissling@balgrist.ch

**Uta Kliesch**
Paraplegikerzentrum, Universitätsklinik Balgrist, Forchstr. 340, 8008 Zürich, Schweiz
e-mail: uta.kliesch@balgrist.ch

**Dilek Könü-Leblebicioglu**
Zentrum für Wirbelsäulen- und Rückenmarkchirurgie, Universität Zürich, Neurochirurgische Klinik, Universitätsspital Zürich, Frauenklinikstr. 10, 8091 Zürich, Schweiz
e-mail: dilek.koenue@usz.ch

**Clayton Kraft**
Orthopädie, Universitätsklinikum Düsseldorf, Moorenstr. 5, 40225 Düsseldorf, Deutschland
e-mail: hemmers@med.uni-duesseldorf.de

**Rüdiger Krauspe**
Orthopädie, Universitätsklinikum Düsseldorf, Moorenstr. 5, 40225 Düsseldorf, Deutschland
e-mail: hemmers@med.uni-duesseldorf.de

**Martin Krismer**
Universitätsklinik für Orthopädie, Anichstr. 35, 6020 Innsbruck, Österreich
e-mail: Martin.Krismer@uibk.ac.at

**Heike Künzel**
Zentrum für Psychiatrie, Krumenauerstr. 25, 85049 Ingolstadt, Deutschland
e-mail: heike.kuenzel@klinikum-ingolstadt.de

**Massimo Leonardi**
Zentrum für Wirbelsäulen- und Rückenmarkchirurgie, Universität Zürich, Universitätsklinik Balgrist, Forchstr. 340, 8008 Zürich, Schweiz
e-mail: massimo.leonardi.@balgrist.ch

**Thomas Liebscher**
Zentrum für Wirbelsäulen- und Rückenmarkchirurgie, Universität Zürich, Universitätsklinik Balgrist, Forchstr. 340, 8008 Zürich, Schweiz

**Anne Mannion**
Wirbelsäulenzentrum, Schulthessklinik, Lengghalde 2, 808 Zürich, Schweiz
e-mail: afm@kws.ch

**Dante Marchesi**
Clinique Bois-Cerfs, Avenue d'Ouchy 31, 1006 Lausanne, Schweiz
e-mail: dante.marchesi@hirslanden.ch

**Richard Marugg**
Zentrum für Wirbelsäulen- und Rückenmarkchirurgie, Universität Zürich, Neurochirurgische Klinik, Universitätsspital Zürich, Frauenklinikstr. 10, 8091 Zürich, Schweiz
e-mail: richard.marugg@usz.ch

**Martin Merkle**
Klinik für Neurochirurgie, Universitätsklinikum Tübingen, Hoppe-Seyler-Strasse 3, 72076 Tübingen, Deutschland

**Kan Min**
Zentrum für Wirbelsäulen- und Rückenmarkchirurgie, Universität Zürich, Universitätsklinik Balgrist, Forchstr. 340, 808 Zürich, Schweiz
e-mail: kan.min@balgrist.ch

**Andreas Nerlich**
Pathologisches Institut, Krankenhaus München-Bogenhausen, Englschalkinger Strasse 77, 81925 München, Deutschland
e-mail: andreas.nerlich@extern.lrz-muenchen.de

**Margareta Nordin**
Department of Orthopaedic and Environmental Medicine, School of Medicine, New York University, OIOC, Hospital for Joint Diseases, Mount Sinai NYU, 63 Downing Street, New York, USA
e-mail: margareta.nordin@nyu.edu

**Jean Ouellet**
Department of Orthopedics, Montreal Children's Hospital, 2300 Tupper, C521 Montreal, H3H 1P3, Canada
e-mail: jaouellet@hotmail.com

**Günther Paesold**
Universitätsklinik Balgrist, Zentrum für Wirbelsäulen- und Rückenmarkchirurgie, Universität Zürich, Forchstr. 340, 8008 Zürich, Schweiz
e-mail: gpaesold@research.balgrist.ch

**Christian Pfirrmann**
Radiologie, Universitätsklinik Balgrist, Forchstr. 340, 8008 Zürich, Schweiz
e-mail: christian.pfirrmann@balgrist.ch

**Albrecht Popp**
Poliklinik für Osteoporose, Inselspital, Universität Bern, 3010 Bern, Schweiz

**Youri Reiland**
Orthopädie, Universitätsklinik Balgrist, Forchstr. 340, 808 Zürich, Schweiz
e-mail: youri.reiland@balgrist.ch

**Frank Ruehli**
Anatomisches Institut, Universität Zürich, Winterthurerstr. 190, 8057 Zürich, Schweiz
e-mail: fr@anatom.unizh.ch

**Shira Schecter-Weiner**
Occupational and Industrial Orthopaedic Center, Hospital for Joint Diseases, New York University Medical Center, 63 Downing Street, New York, NY 20014, USA
e-mail: sswpt@aol.com

**Dietrich Schlenzka**
Orton Orthopaedic Hospital, Invalid Foundation, Tenholantie 10, 00280 Helsinki, Finland
e-mail: dietrich.schlenzka@invalidisaatio.fi

**Annina Schmid**
Physiotherapie, Universitätsklinik Balgrist, Forchstr. 340, 8008 Zürich, Schweiz
e-mail: annina.schmid@balgrist.ch

**Marius Schmid**
Radiologie, Universitätsklinik Balgrist, Forchstr. 340, 8008 Zürich, Schweiz
e-mail: marius.schmid@balgrist.ch

**Francis H. Shen**
Department of Orthopaedic Surgery, Division of Spine Surgery, University of Virginia, PO Box 800159, Charlottesville, VA 22908, USA
e-mail: fhs2g@virginia.edu

**Atul Sukthankar**
Orthopädie, Universitätsklinik Balgrist, Forchstr. 340, 8008 Zürich, Schweiz
e-mail: atul.sukthankar@balgrist.ch

**Beat Wälchli**
Spital Zollikerberg, Aerztezentrum Prisma, Trichtenhauserstr. 12, 8125 Zollikerberg, Schweiz
e-mail: info@beatwaelchli.ch

**Guido Wanner**
Zentrum für Wirbelsäulen- und Rückenmarkchirurgie, Universität Zürich, Klinik für Unfallchirurgie, Universitätsspital Zürich, Rämistr. 100, 8091 Zürich, Schweiz
e-mail: guido.wanner@usz.ch

**Sherri Weiser**
Department of Orthopaedic and Environmental Medicine, School of Medicine, New York University, OIOC, Hospital for Joint Diseases, Mount Sinai NYU, 63 Downing Street, New York, NY 10014, USA
e-mail: sherri.weiser@nyu.edu

**Clément Werner**
Orthopädie, Universitätsklinik Balgrist, Forchstr. 340, 8008 Zürich, Schweiz
e-mail: cwerner@gmx.ch

**Yasuhiro Yonekawa**
Zentrum für Wirbelsäulen- und Rückenmarkchirurgie, Universität Zürich, Neurochirurgische Klinik, Universitätsspital Zürich, Frauenklinikstr. 10, 8091 Zürich, Schweiz
e-mail: yasuhiro.yonekawa@usz.ch

**Patrick Zingg**
Orthopädie, Universitätsklinik Balgrist, Forchstr. 340, 8008 Zürich, Schweiz
e-mail: patrick.zingg@balgrist.ch

# Guided Tour

The aim of this textbook is not to provide the most comprehensive overview of spinal disorders, but rather to give a thorough grounding in the basic knowledge and general principles of the subject. The **didactic concept** of all the chapters of the book is therefore based on a consistent style and layout, and follows three basic principles of **sustained learning**, i.e.:

- less is more
- repetition enhances sustained learning
- case study learning

This didactic concept is enhanced by many **learning aids** to highlight and repeat core messages throughout all chapters. The ample use of **visual aids** mediates the core messages and allows for a gradual and repetition-based learning approach starting with the core messages and going on to an in-depth reading of each chapter. Marginal notes and a short recapitulation facilitate the learning by repetition. A **pictorial and anecdotal learning method** is enabled by the many case studies, which exemplify the core messages.

**Core messages** highlight the most important learning objectives and guide the reader through the chapter.

Fractures Section 883

31 Thoracolumbar Spinal Injuries

Michael Heinzelmann, Guido A. Wanner

Core Messages

- Spinal fractures are frequently located at the thoracolumbar junction for biomechanical reasons
- The AO classification has gained widespread acceptance in Europe for the grading of thoracolumbar fractures: Type A: vertebral compression fractures; Type B: anterior and posterior column injuries with distraction; Type C: anterior and posterior element injury with rotation
- The initial focus of the physical examination of a patient with a spinal injury is on the vital and neurological functions, because effective resuscitation is critical to the management of polytraumatized patients and patients with spinal cord injury
- The imaging modalities of choice are standard radiographs and CT scans. A CT scan should routinely be made to visualize bony injury. MRI is helpful to diagnose discoligamentous injuries and to identify a possible cord lesion
- Primary goals of treatment are prevention and limitation of neurological injury as well as restoration of spinal stability, regardless of whether operative or non-operative therapy is chosen
- Secondary goals consist of correction of deformities, minimizing the loss of motion, and facilitating rapid rehabilitation
- Early stabilization and fusion is generally accepted for patients with unstable fractures and neurological deficits
- The optimal treatment for patients with less instability, moderate deformity and absence of neurological compromise is not based on scientific evidence and remains a matter of debate.
- Good clinical outcome can be achieved with non-operative as well as operative treatment

Epidemiology

Systematic epidemiologic data on traumatic thoracolumbar fractures are rare and differ depending on the area studied and on the treating center. The studies available from western countries reveal typical and comparable data on incidence, localization, and mechanisms of injury. Thoracolumbar fractures are more frequent in men (2/3) than in women (1/3) and peak between the ages of 20 and 40 years [30, 47, 65, 81, 94]. Approximately, 160 000 patients/year sustain an injury of the spinal column in the United States. The majority of these injuries comprise cervical and lumbar (L3–L5) spine fractures. However, between 15% and 20% of traumatic fractures occur at the thoracolumbar junction (T11–L2), whereas 9–16% occur in the thoracic spine (T1–T10) [36, 46]. Hu and coworkers [56] studied the total population of a Canadian province over a period of 3 years. The incidence of spine injuries was 64/100 000 inhabitants per year, predominantly younger men and older women. A total of 2063 patients were registered and 944 patients were treated in hospital: 182 patients (20%) with a cervical spine injury, 286 patients (30%) with a thoracic spine injury and 403 patients (50%) with an injury of the lumbosacral spine. Traumatic cross-section spinal cord injury occurred in 40 out of 1 million inhabitants. About

Fractures most frequently affect the thoracolumbar junction

884 Section Fractures

Case Introduction

This 23-year-old female sustained a motor vehicle accident as an unrestrained passenger. Clinically, she presented with an incomplete paraplegia (ASIA C) and an incomplete conus-cauda syndrome. The initial CT (a–d) scan demonstrates an unstable complete burst fracture of L1 (Type A3.3). The 3D reconstruction (a, b) gives a good overview of the degree of comminution and the deformity; the posterior fragment is best visualized in the lateral 2D reconstruction (c) and the axial view (d). In an emergency procedure, the myelon was decompressed by laminectomy and the fracture was reduced and stabilized with an internal fixator (e–h). Interestingly, the prone position alone (e) reduced the fracture to a certain degree when compared to the CT scan taken with the patient in a supine position. With the internal fixator (Recofix), the anatomical height and physiological alignment was restored (f) and the posterior fragment was partially reduced (g, h). This indirect reduction of bony fragments, called ligamentotaxis, is possible if the posterior ligaments and the attachment to the anulus fibrosus are intact. We performed a complete clearance of the spinal canal by an anterior approach 5 days later (i–l). In this minimally invasive technique, the spine is approached by a small thoracotomy from the left, the ruptured disc and bony fragments are removed, and an expandable cage is inserted. One of the first steps in this technique is the positioning of a K-wire in the upper disc space of the fractured vertebra (i). In this figure, the four retractors of the Synframe and the endoscopic light source are seen. The final result after 9 months (j–l) demonstrates the cage (Synex), the physiological alignment without signs of implant failure or kyphosis, a good clearance of the spinal canal from anterior and the laminectomy from posterior (k), and a bony healing of the local bone transplant of the lateral side of the cage (l). Fortunately, the patient completely recovered from her neurological deficit (ASIA E).

50–60% of thoracolumbar fractures affect the transition T11–L2, 25–40% the thoracic spine and 10–14% the lower lumbar spine and sacrum [80, 86].

In a study by Magerl and Engelhardt [81] on 1446 thoracolumbar fractures, most injuries concerned the first lumbar vertebra, i.e., 28% ($n = 402$), followed by T12 (17%, $n = 246$) and L2 (14%, $n = 208$). The epidemiologic multicenter study on fractures of the thoracolumbar transition (T10–L2) by the German Trauma Society studied 682 patients and revealed 50% ($n = 336$) L1 fractures, 25%

**Introductory cases** introduce the topic by reporting typical cases representative of the specific pathology. These cases are intended to serve as a stand-alone tool in mediating core messages of each chapter.

**Figures** illustrate and exemplify essential knowledge and stimulate a pictorial learning.

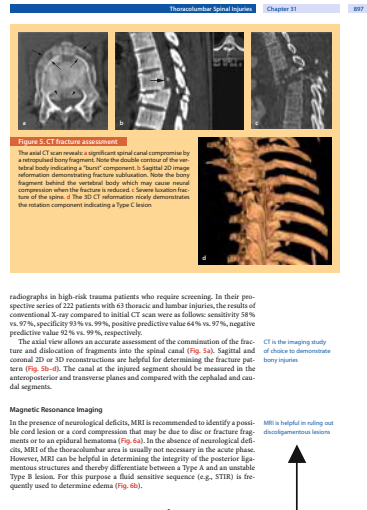

Thoracolumbar Spinal Injuries Chapter 31 897

Figure 5. CT fracture assessment

The axial CT scan reveals: a significant spinal canal compromise by a retropulsed bony fragment. Note the double contour of the vertebral body indicating a "burst" component. b Sagittal 2D image reformation demonstrating fracture subluxation. Note the bony fragment behind the vertebral body which may cause neural compression when the fracture is reduced. c Severe luxation fracture of the spine. d The 3D CT reformation nicely demonstrates the rotation component indicating a Type C lesion

radiographs in high-risk trauma patients who require screening. In their prospective series of 222 patients with 63 thoracic and lumbar injuries, the results of conventional X-ray compared to initial CT scan were as follows: sensitivity 58 % vs. 97 %, specificity 93 % vs. 99 %, positive predictive value 64 % vs. 97 %, negative predictive value 92 % vs. 99 %, respectively.

The axial view allows an accurate assessment of the comminution of the fracture and dislocation of fragments into the spinal canal (Fig. 5a). Sagittal and coronal 2D or 3D reconstructions are helpful for determining the fracture pattern (Fig. 5b–d). The canal at the injured segment should be measured in the anteroposterior and transverse planes and compared with the cephalad and caudal segments.

CT is the imaging study of choice to demonstrate bony injuries

**Magnetic Resonance Imaging**

In the presence of neurological deficits, MRI is recommended to identify a possible cord lesion or a cord compression that may be due to disc or fracture fragments or to an epidural hematoma (Fig. 6a). In the absence of neurological deficits, MRI of the thoracolumbar area is usually not necessary in the acute phase. However, MRI can be helpful in determining the integrity of the posterior ligamentous structures and thereby differentiate between a Type A and an unstable Type B lesion. For this purpose a fluid sensitive sequence (e.g., STIR) is frequently used to determine edema (Fig. 6b).

MRI is helpful in ruling out discoligamentous lesions

**Marginal notes** summarize important facts and allow for a rapid repetition of learning objectives.

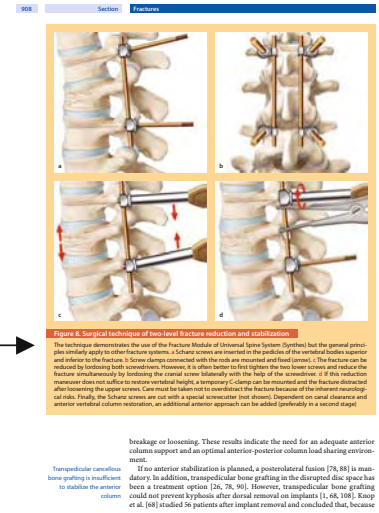

908 Section Fractures

Figure 8. Surgical technique of two-level fracture reduction and stabilization

The technique demonstrates the use of the Fracture Module of Universal Spine System (Synthes) but the general principles similarly apply to other fracture systems. a Schanz screws are inserted in the pedicles of the vertebral bodies superior and inferior to the fracture. b Screw clamps connected with the rods are mounted and fixed (arrow). c The fracture can be reduced by lordosing both screwdrivers. However, it is often better to first tighten the two lower screws and reduce the fracture simultaneously by lordosing the cranial screw bilaterally with the help of the screwdriver. d If this reduction maneuver does not suffice to restore vertebral height, a temporary C-clamp can be mounted and the fracture distracted after loosening the upper screws. Care must be taken not to overdistract the fracture because of the inherent neurological risks. Finally, the Schanz screws are cut with a special screwcutter (not shown). Dependent on canal clearance and anterior vertebral column restoration, an additional anterior approach can be added (preferably in a second stage)

breakage or loosening. These results indicate the need for an adequate anterior column support and an optimal anterior-posterior column load sharing environment.

If no anterior stabilization is planned, a posterolateral fusion [78, 88] is mandatory. In addition, transpedicular bone grafting in the disrupted disc space has been a treatment option [26, 78, 90]. However, transpedicular bone grafting could not prevent kyphosis after dorsal removal on implants [1, 68, 108]. Knop et al. [68] studied 56 patients after implant removal and concluded that, because

Transpedicular cancellous bone grafting is insufficient to stabilize the anterior column

**Figures** provide a schematic illustration of surgical procedures.

**Tables** summarize important facts such as classifications, treatment objectives and indications for non-operative and surgical treatment.

892 Section Fractures

Table 4. Frequency of neurological deficits

| Types and groups | Number of injuries | Neurological deficit (%) |
|---|---|---|
| **Type A** | **890** | **14** |
| A1 | 501 | 2 |
| A2 | 45 | 4 |
| A3 | 344 | 32 |
| **Type B** | **145** | **32** |
| B1 | 61 | 30 |
| B2 | 82 | 33 |
| B3 | 2 | 50 |
| **Type C** | **177** | **55** |
| C1 | 99 | 53 |
| C2 | 62 | 60 |
| C3 | 16 | 50 |
| **Total** | **1212** | **22** |

Based on an analysis of 1212 cases (Magerl et al. [80])

## Clinical Presentation

The clinical assessment of patients with a putative trauma to the spine has **three major objectives**, i.e., to identify:

- the spinal injury
- neurological deficits
- concomitant non-spinal injuries

### Spinal Injuries

About 30 % of polytraumatized patients have a spinal injury

It is obvious that the management and the priorities differ between a life-threatening polytrauma that includes a spinal injury and a monotrauma of the spine. In the case of a polytrauma, about one-fourth to one-third of patients have a spinal injury [120]. In our institution, we found spinal injuries in 22 % of polytraumatized patients. In a series of 147 consecutive patients with multiple trauma, Dai et al. [24] found a delayed diagnosis of thoracolumbar fractures in 19 %, confirming an earlier study by Anderson et al. [5], in which 23 % of patients with major thoracolumbar fractures were diagnosed after the patient had left the emergency department. A delay in the diagnosis of thoracolumbar fractures is frequently associated with an unstable patient condition that necessitates higher-priority procedures than thoracolumbar spine radiographs in the emergency department. However, with the routine use of multi-slice computed tomography (CT) in polytraumatized patients, the diagnostic work-up is usually adequate [57, 106] and delayed diagnosis of spine fractures should become rare. Multiple burst fractures occur in approximately 10–34 % [10, 11, 53].

Polytraumatized patients should be screened for spinal fracture by CT

### Neurological Deficit

Sacral sparing indicates an incomplete lesion with a better prognosis

An accurate and well-documented neurological examination is of great importance. With an inaccurate or incomplete examination and a subsequent variation of the patient's neurological deficit, it will be unclear if the situation has changed or if the initial assessment was simply inappropriate. In the case of a progressive neurological deficit, this may hinder urgent further management, i.e., the need for a surgical intervention with spinal decompression. Neurological assessment is usually done according to the guidelines of the **American Spinal Injury Association** (see Chapter 11). Importantly, the examination has to include the "search for a sacral sparing" which will determine the completeness of the deficit and the prognosis.

**Cross references** facilitate a quick orientation throughout the textbook.

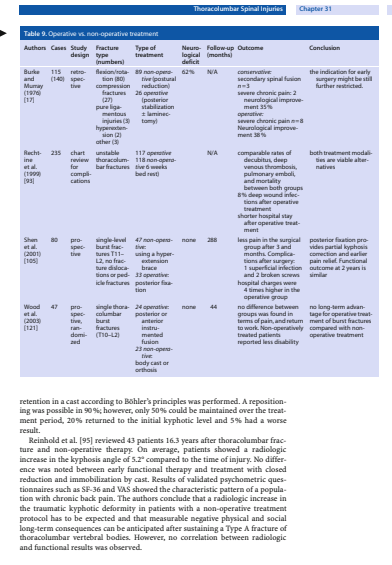

Thoracolumbar Spinal Injuries Chapter 31 915

Table 9. Operative vs. non-operative treatment

| Authors | Cases | Study design | Fracture type (numbers) | Type of treatment | Neurological deficit | Follow-up (months) | Outcome | Conclusion |
|---|---|---|---|---|---|---|---|---|
| Burke and Murray (1976) [17] | 115 (140) | retrospective | flexion/rotation (80) compression fractures (27) pure ligamentous injuries (3) hyperextension (2) other (3) | 89 *non-operative* (postural reduction) 26 *operative* (posterior stabilization ± laminvectomy) | 62 % | N/A | *conservative:* secondary spinal fusion *n* = 3 severe chronic pain: 2 neurological improvement 35 % *operative:* severe chronic pain *n* = 8 Neurological improvement 38 % | the indication for early surgery might be still further restricted. |
| Rechtine et al. (1999) [93] | 235 | chart review for complications | unstable thoracolumbar fractures | 117 *operative* 118 non-operative 6 weeks bed rest) | | N/A | comparable rates of decubitus, deep venous thrombosis, pulmonary emboli, and mortality between both groups 8 % deep wound infections after operative treatment shorter hospital stay after operative treatment | both treatment modalities are viable alternatives |
| Shen et al. (2003) [105] | 80 | prospective | single-level burst fractures T11–L2, no fracture dislocations or pedicle fractures | 47 *non-operative:* using a hyperextension brace 33 *operative:* posterior fixation | none | 288 | less pain in the surgical group after 3 and months. Complications after surgery: 1 superficial infection and 2 broken screws hospital charges were 4 times higher in the operative group | posterior fixation provides partial kyphosis correction and earlier pain relief. Functional outcome at 2 years is similar |
| Wood et al. (2003) [121] | 47 | prospective, randomized | single thoracolumbar burst fractures (T10–L2) | 24 *operative:* posterior or anterior instrumented fusion 23 *non-operative:* body cast or orthosis | none | 44 | no difference between groups was found in terms of pain, and return to work. Non-operatively treated patients reported less disability | no long-term advantage for operative treatment of burst fractures compared with non-operative treatment |

retention in a cast according to Böhler's principles was performed. A repositioning was possible in 90 %; however, only 50 % could be maintained over the treatment period, 20 % returned to the initial kyphotic level and 5 % had a worse result.

Reinhold et al. [95] reviewed 43 patients 16.3 years after thoracolumbar fracture and non-operative therapy. On average, patients showed a radiologic increase in the kyphosis angle of 5.2° compared to the time of injury. No difference was noted between early functional therapy and treatment with closed reduction and immobilization by cast. Results of validated psychometric questionnaires such as SF-36 and VAS showed the characteristic pattern of a population with chronic back pain. The authors conclude that a radiologic increase in the traumatic kyphotic deformity in patients with a non-operative treatment protocol has to be expected and that measurable negative physical and social long-term consequences can be anticipated after sustaining a Type A fracture of thoracolumbar vertebral bodies. However, no correlation between radiologic and functional results was observed.

**Tables** also provide a topical state-of-the-art review of the literature and stimulate evidence based learning

**Case studies** aim to mediate the fundamentals and basic principles of the chapters and enhance recollection by the principle of case study learning.

**Recapitulations** summarize the essential teaching objectives and provide a quick overview for the busy reader.

**Key articles** introduce landmark papers which had a substantial impact on our current understanding of the pathology, diagnosis or non-operative and surgical treatment.







**References** provide an in-depth library for further reading.

# 1 History of Spinal Disorders

Philipp Gruber, Thomas Boeni

## Core Messages

- ✔ Paleopathological investigators have found clear evidence of spinal disorders in prehistoric times
- ✔ Full and accurate descriptions of spinal disorders and various treatment attempts survive from antiquity
- ✔ At the end of antiquity (7th century A.D.), Paulus of Aegina (625–690 A.D.) performed the first successful laminectomies
- ✔ During the whole of the Middle Ages, there was little progress in the diagnosis and treatment of spinal disorders
- ✔ At the end of the 18th century and the beginning of the 19th century, the first advanced attempts at spinal surgery were performed in Europe
- ✔ At the end of the 19th century, with the new techniques of anesthesia, radiology and aseptic surgery, more sophisticated and even more successful spinal surgery became possible
- ✔ In the middle of the 20th century, low back pain disability became an increasing socioeconomic problem
- ✔ In the 1970s and 1980s, powerful imaging systems (CT/MRI) improved the diagnosis for spinal disorders but also led to some overdiagnosis of spinal disorders
- ✔ In the 1980s and 1990s, spinal instrumentation became widely available and enabled even complex spinal disorders to be tackled
- ✔ During the 20th century, the focus on spinal disorders dramatically changed: at the beginning of the 20th century spinal disorders were predominantly caused by infectious diseases; nowadays the focus is more on degenerative spinal disorders
- ✔ At the beginning of the 21st century, spinal surgery has become more evidence based, but it is still technology driven in many areas

## A Brief Etymology

Nicholas Andry coined the word "*orthopaedic*" in 1741

The French pediatrician Nicholas Andry (1658–1742), considered the father of orthopedics, coined the word "*orthopaedic*", which is made up of two Greek words, "*orthos*", meaning straight, and "*paidion*", meaning child (Fig. 1a) [3]. The term "*orthopaedic*" was used for the first time in the epoch-making textbook of Andry published in 1741.

Andreas Vesalius coined the word "vertebra"

The origin of the word **spine** derives from the Latin word "*spina*" meaning "backbone". The word **vertebra**, first found in the medical texts of Celsus (34 B.C.–14 A.D.), a Roman encyclopedist, derives from the Latin word "*vertebra*", which is related to the Latin verb "*vertere*" meaning "to turn". The great anatomist Andreas Vesalius (1514–1564) finally introduced the word "vertebra" as an anatomical term [116].

The Greek word "scoliosis" means curvature

The term **scoliosis** is derived from the Greek word "*scolios*" meaning "curvature" and was coined by the Greek physician Galen of Pergamon (130–200 A.D.) (Fig. 1b) [36]. Nowadays, it is used to describe a specific clinical condition consisting of lateral deviations of the spine associated with vertebral rotation.

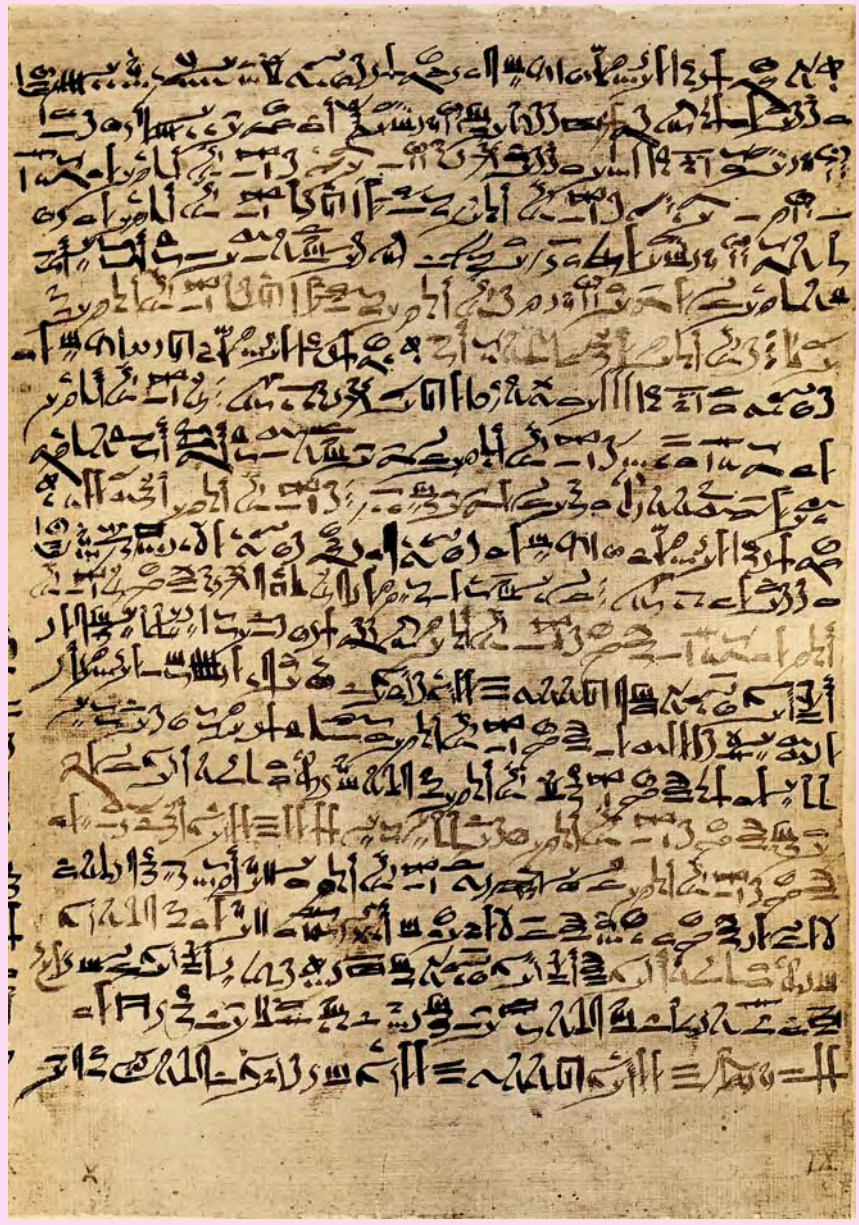

## Historical Case Introduction

This papyrus shows Column X of the *Edwin Smith Surgical Papyrus*, written in hieratic script, which encompasses a description of a spinal injury. The *Edwin Smith Surgical Papyrus* dates back to 1550–1500 B.C. and is therefore the oldest known written evidence of spinal injuries [10]. This medical papyrus is an outstanding witness of a very accurate and rational medicine in Old Egypt foremost in traumatology. The papyrus reveals an astonishing knowledge of human anatomy at the Pharaonic time in Egypt:

Case 29: Instruction concerning a gaping wound of vertebra of his neck

Examination: If thou examinest a man having a gaping wound in a vertebra of his neck, penetrating to the bone, (and) perforating a vertebra of his neck; if thou examinest that wound, (and) he shudders exceedingly, (and) he is unable to look at his two shoulders and his breast.

Diagnosis: Thou shouldst say concerning him: (One having) a wound in his neck, penetrating to the bone perforating a vertebra of his neck, (and) he suffers with stiffness in his neck. An ailment with which I will contend.

Treatment: Thou shouldst bind the fresh meat the first day. Now afterward moor (him) at his mooring stakes until the period of his injuries passes by.

Translation by the famous American Egyptologist J.H. Breasted (1930).




b

**Figure 1. The roots**

a This drawing of scoliosis therapy in Nicholas Andry's (1658–1742) epoch-making textbook *L'Orthopédie* (1742) serves as a general symbol of orthopedics. b Galen of Pergamon (130–200 A.D.).

**Kyphosis** is also derived from the Greek word "*kyphos*" meaning "hunchback" or "bent". Galen of Pergamon [36] first coined this term in medical language. The term **lordosis** belongs also to the Greek word family and is derived from the Greek word "*lordos*" standing for "forward curving". Galen of Pergamon first used the word "lordosis" as a medical term [36]. **Sciatica** is of Greek origin and is derived from the word "*ishion*" standing for hip, buttocks, sacrum, loin and also upper limb. Since the time of Hippocrates of Cos (460–370 B.C.), this term has related to pain syndrome of the lower back and the upper parts of the lower limbs [57].

The Greek word "*kyphos*" means "hunchback"

The term **spondylolisthesis** is originally derived from two Greek words, "*spondylos*" for spine and "*(o)listhesis*" for forward gliding. Therefore, it means the "(forward) slipping of the spine". In 1854, Herman Friedrich Kilian (1800–1863) coined the term "spondylolisthesis" [64].

The Greek word "*olisthesis*" means "forward gliding"

**Spondylophyte** is composed of two Greek words, "*spondylos*", standing for spine, and "*phytein*", a Greek verb meaning "to grow". The whole term means "spinal outgrowth". The term "isthmic" frequently used in spinal surgery is derived from the Greek word "*isthmos*", which means in its natural sense "isthmus" and also "strait or narrow" [59].

## Spinal Anatomy and Physiology

Herophilus and later Galen studied spinal anatomy

Successful modern spine surgery only became possible because of the large body of knowledge of anatomy and physiology which had been acquired. The first steps were already taken in antiquity: Herophilus of Chalcedon (circa 300 B.C.), known as the father of anatomy, and later **Galen of Pergamon** (130–200 A.D.) made the first observations on the nervous system and the spine. Galen identified the number of vertebrae in each segment of the spinal column, and described the ligamentum flavum as a ligamentous structure distinct from the underlying dura and pia mater. He was also able to correlate neurological findings with a specific spinal level, because he performed frequent experiments on primates.

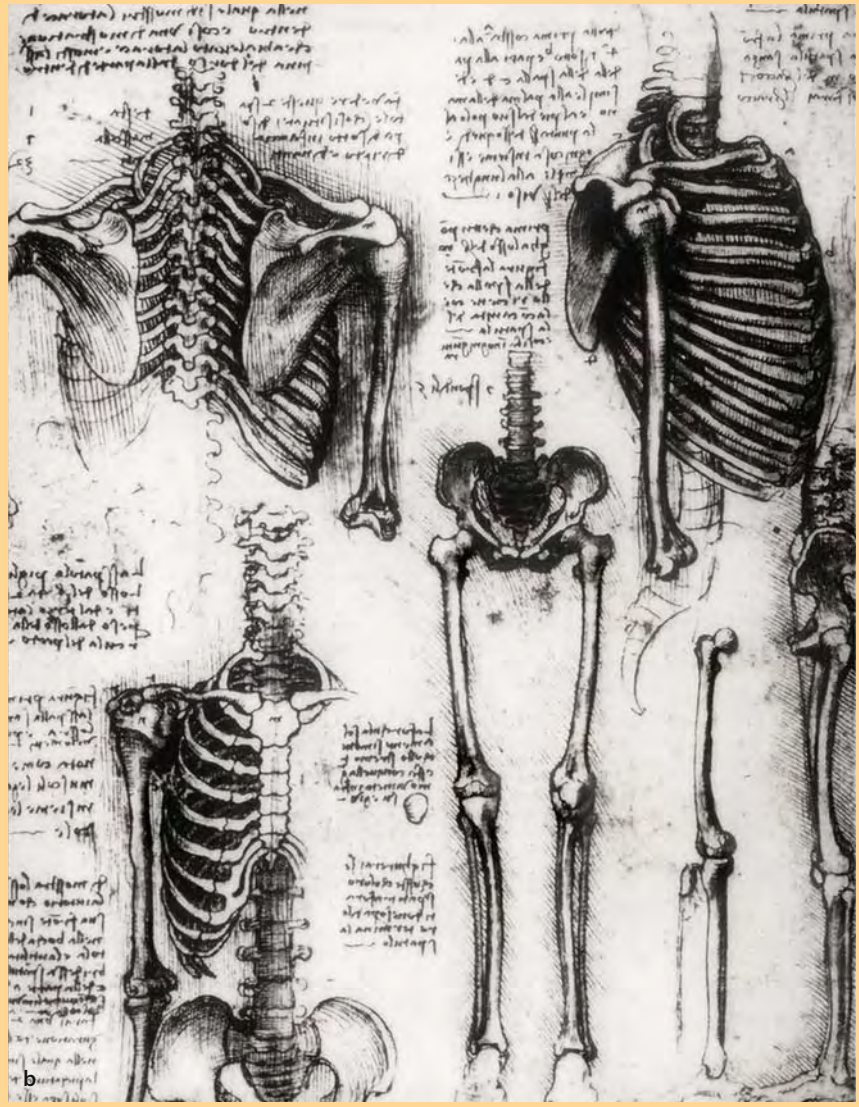


**Figure 2. Spinal anatomy and physiology**

a Leonardo da Vinci (1452–1519). b This sketch drawn by Leonardo da Vinci is the first correct depiction of the human spine.

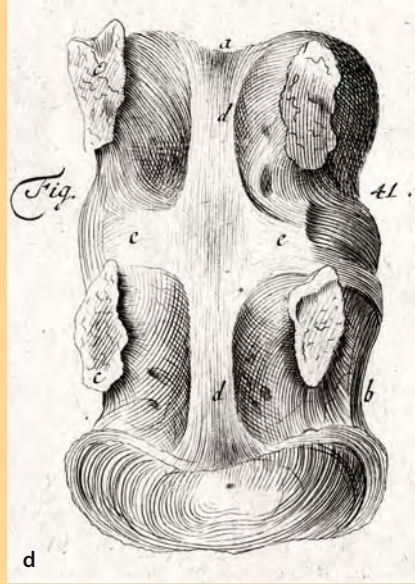


**Figure 2.** (*Cont.*)

**c** Andreas Vesalius (1514 – 1564). **d** Josias Weitbrecht's (1702 – 1747) *Syndesmologia* (1742) precisely described the spinal ligaments.

During the Middle Ages, no progress was made in the understanding of spinal anatomy.

In the Renaissance, **Leonardo da Vinci** (1453 – 1519) was probably the first to accurately describe the spine with the correct curvatures, articulations and number of vertebrae (Fig. 2a, b). Sadly, he never published his anatomical drawings and therefore his anatomical discoveries remained unknown for centuries.

Leonardo da Vinci's drawings are the first to show the spinal anatomy

**Andreas Vesalius** (1514 – 1564) broke with the Galenic anatomy and presented the most integrated and accurate anatomy (Fig. 2c). He is therefore credited with describing the spinal anatomy in a modern sense [116]. By publishing the cutting-edge anatomical textbook *De Humani Corporis Fabrica Libri Septi*, Vesalius became the founder of modern spinal anatomy in 1543.

Andreas Vesalius (1514 – 1564) is the founder of modern spinal anatomy

The Dutch anatomist **Gerard Blasius** (1625 – 1692) wrote the first significant work on spinal cord anatomy. In his text *On the Anatomy of the Spinal Nerves* (*Anatome Medullae Spinalis et Nervorum indeprovenientium*) (1666), Blasius was the first to provide a demonstration of the origin of the spinal nerve roots and a differentiation between the gray matter of the spinal cord [6].

Blasius wrote the first significant work on spinal cord anatomy

In *De Motu Animalium* (*On the Movement of Animals*) written by Giovanni **Alfonso Borelli** (1608 – 1680), a professor of mathematics and the father of biomechanics, the intervertebral disc was described for the first time as exhibiting viscoelastic properties (published posthumously in 1688) [8].

Borelli first recognized the viscoelastic intervertebral disc behavior

The German physician and anatomist Albrecht von Haller (1708 – 1777) worked in Berne, and is credited as the founder of modern physiology. He illustrated the blood supply of the spinal cord with an accuracy that is still unsurpassed.

The Italian physician **Domenico Felice Antonio Cotugno** (1736 – 1822), a professor of medicine at the University of Naples, was the first to fully describe the cerebrospinal fluid and its circulation in his epoch-making *Commentary on Nervous Sciatica* in 1764 [21].

Cotugno first described the cerebrospinal fluid

At the same time in 1742, the German anatomist **Josias Weitbrecht** (1702 – 1747) published his monumental work on human ligaments, *Syndesmologia Sive Historia Ligamentorum Corporis Humani*, which for the first time also gave a concise and accurate description of the spinal ligaments (Fig. 2d) [121]. Weitbrecht is also credited with providing a very concise description of the intervertebral disc for his time.

"Centers of feeling" were thought to be located in the spinal cord

At the beginning of the 19th century, it was still believed that some parts of the spinal cord contained the "centers of feeling". Furthermore it was believed that the spinal cord consisted of bundles of nerve fibers grouped into columns. After the microscope entered clinical and pathological practice, the cellular contents of the gray matter were identified, and since then there have been steady advances in our understanding of the spinal cord.

## Anesthesia and Supportive Techniques

An invasive and effective spinal surgery would not have been possible without major advances in anesthesia and supportive techniques such as antisepsis, antibiotics and diagnostic imaging.

### Laughing Gas, Chloroform and Cocaine

Wells first narcotized patients with laughing gas

In 1799, the English chemist **Sir Humphrey Davy** (1778 – 1829), a former scholar of Joseph Priestley, discovered that pure nitrous oxide was respirable. He tried the effect of this substance first on himself and recommended that nitrous oxide ("laughing gas") could be useful for narcotizing patients during operations. In 1844, it was the American dentist Horace Wells (1815 – 1848) who tried extracting teeth by narcotizing patients with laughing gas.

Morton popularized narcotics for surgery

**William Thomas Green Morton** (1819 – 1868), a former colleague of Horace Wells, made the use of narcotics for surgery popular. On 16 October 1846, Morton presented his narcotizing method to the public in the operating theater of the Massachusetts General Hospital in Boston (Fig. 3a).

Bier first performed lumbar anesthesia

Further improvements were made by Sir James Simpson, an English gynecologist and obstetrician, who introduced chloroform as a narcotizing agent after a large series of heroic self-experiments. In 1884, the Austrian ophthalmologist Karl Koller (1875 – 1944) first used cocaine for narcotizing mucous membranes. In 1885, the young American surgeon **William S. Halstead** (1852 – 1922), who was enthusiastic about the effect of cocaine and also addicted to it, developed the first intravenous anesthesia block with cocaine. The world's first lumbar anesthesia using cocaine as agent was performed in 1898 by the German surgeon **August Bier** (1861 – 1949). He was inspired by the lumbar puncture technique introduced by the German physician Heinrich Quincke (1842 – 1922) 7 years earlier [5]. In 1894, the famous neurosurgeon **Harvey Cushing** (1869 – 1939) introduced the narcotic protocol for better surveillance of patients during the narcotizing procedure.

### Antisepsis and Antibiotics

Infections were thought to be a divine punishment

For a long period of history, infections were thought to be a divine punishment. It was a contemporary of Cesar, Marcus Terentius Varro (116 – 27 B.C.), who assumed in his work on rural labor *Rerum Rusticarum* that infections are caused by very small animals, which he called "**contagiatum animatum**" (infectious animals). In 1546, the Italian Renaissance physician **Girolamo Fracastoro** (1478 – 1553), who coined the name "**syphilis**", postulated in his famous work



**Figure 3. Anesthesia and supportive techniques**

a Public demonstration of a narcotization by William Thomas Green Morton (1819 – 1868), Massachusetts General Hospital, Boston (16 October 1846). b Joseph Lister (1827 – 1912). c William Conrad Roentgen (1845 – 1923).

*On Infection, Infectious Diseases and Their Cure* (*De Contagiosis Morbis Eorumque Curatione*) that infections are not only transmitted by air but also by human contact. The Dutchman Antony van Leeuwenhoek (1632 – 1724) gave the first evidence of microbes in his work on the microscope. Finally, it was the German physician and bacteriologist **Robert Koch** (1843 – 1910) who showed that specific germs are responsible for specific infections, for example, *Mycobacterium* for tuberculosis or anthrax bacillus for anthrax disease.

Koch discovered that *Mycobacterium* is responsible for tuberculosis

The famous English surgeon **Joseph Lister** (1827 – 1912), who was the son-in-law of James Syme (1799 – 1870), famous for his ankle amputation, introduced aseptic surgery in 1866 (Fig. 3b) [70, 71]. Based on studies of the French microbi-

Lister first introduced aseptic surgery

ologist **Louis Pasteur** (1822 – 1895), he believed that infections were transmitted by air. Therefore, he proposed irrigation and disinfection of the operation field by using a weak solution of carbolic acid [71]. He called his procedure "**carbolization**".

The first steam sterilizer was installed in 1882

In 1882, the German surgeon **Friedrich Trendelenburg** (1844 – 1924) was inspired by the discovery of Robert Koch, that carbol acid is not able to kill germs in contrast to steamed air. Therefore, he installed the world's first steam sterilizer in his clinic in Bonn. Finally, it was the German physician Curt Schimmelbusch (1860 – 1895) who improved the technique of sterilization and popularized it.

Halstead introduced rubber gloves

A further great step towards aseptic surgery was made by **William S. Halstead** (1852 – 1922) working as professor of surgery at Johns Hopkins University. In 1880, he introduced rubber gloves because his fiancée, who was working as an operating nurse at the same hospital, had developed a severe skin irritation due to exposure to mercury solution.

Fleming discovered penicillin

The Scottish bacteriologist **Alexander Fleming** (1881 – 1955) accidently discovered that the mold *Penicillium notatum* had a bacteria-toxic effect on *Staphylococcus* cultures. After several experiments he was able to extract a liquid substance, which he called penicillin, because of the name of the mold, *Penicillium notatum*, and he published his results in 1929.

However, there was no initial response to his report. It was only in the late 1930s that the pathologist Howard Floery (1898 – 1968) and the biochemist Ernst Chain (1906 – 1979) repeated and confirmed Fleming's work while searching for effective antagonists against microorganisms. In 1945, Fleming, Florey and Chain received the Nobel Prize for their work.

## Diagnostic Imaging

Roentgen accidentally discovered X-rays in 1895

Without the appropriate imaging modalities, the development of a comprehensive treatment regime for spinal disorders would not have been possible. In 1895, the physicist **William Conrad Roentgen** (1845 – 1923) accidently discovered the relevance of X-rays for medical imaging while he was performing experiments on a cathode beamer (Fig. 3c). In 1896, he published his discovery and X-rays became immediately popular [99]. He was honored by the Nobel Prize in 1901. The famous American neurosurgeon **Walter E. Dandy** (1886 – 1946) introduced air myelography for spinal imaging in 1918 [24].

The first brain CT scan became possible in 1971

A revolutionary step forward in diagnostic assessment of spinal disorders was the introduction of computed tomography (CT) in the early 1970s. This imaging device was a step-by-step development. Three individuals contributed to this landmark invention, i.e. the English engineer **Godfrey N. Hounsfield**, the American physicist **Allan M. Cormack** and the American neurologist **William Oldendorf**. Oldendorf first suggested that by means of CT brain tumors can be diagnosed. The first brain image of a patient with a brain cyst was made in 1971. In 1974, the American **Raymond Damadian** (1936 –) patented an imaging device using principles of the nuclear magnetic resonance phenomenon, first described by the Swiss physicist and Nobel Prize winner **Felix Bloch** (1905 – 1983) in 1952.

The first brain MR image became possible in 1979

The first brain scan by MR imaging became possible in 1979.

## Scoliosis

Since the beginning of written history, scoliosis has been a major concern in medical texts. The clinical image of scoliosis very much impressed ancient physicians and treatment remained poor for centuries. Even today, treatment is unsatisfactory since correction of scoliosis is not possible without spinal fusion.

## Pathogenesis

During **antiquity** and the **Middle Ages**, the pathogenesis of scoliosis was not clear and it has still not been unraveled today. It was often supposed that the spinal deformities were caused by luxation of spinal elements. Therefore, spinal deformities were called "**spina luxata**". No distinctions were made between scoliosis, kyphosis, and a gibbus. Treatment regimes did not differentiate between these entities. The first picture of a scoliotic spine (Fig. 4a) appeared in the important surgical textbook of the German surgeon Guilhelmus Fabricius Hildanus (1560 – 1634) in 1646 [56].

Spinal deformities were called "spina luxata" without distinction between scoliosis and kyphosis

It was the Frenchman **Jean Méry** (1645 – 1722) who first suggested that both lateral deviation and rotation of the spine are responsible for scoliosis [84]. When research on scoliosis started, it was commonly believed that muscle dysfunction was the cause. Only after Pott's description of spinal tuberculosis was a distinction was made between spinal deformities caused by tuberculosis and spinal deformities of other etiologies. During the second half of the 19th century, research focused on the spinal osseous changes in patients suffering from scoliosis.

Méry first realized the importance of spinal rotation for scoliosis

The French surgeon Sauveur-Henri Victor Bouvier (1799 – 1877) is credited as the first to further differentiate between rickets caused scoliosis and idiopathic scoliosis [9].

## Assessment

Before the advent of X-rays, it was very difficult to measure scoliosis and treatment outcome. The French surgeon Jacques-Mathieu Delpech (1777 – 1832) made plaster molds of his scoliosis patients to assess the extent of the curvature. In 1850, an employee of **Johann Julius Bühring** (1815 – 1855), head of an orthopedic clinic in Berlin, invented a measuring machine that made it possible to depict correctly a spinal curvature. The measuring machine consisted of a glass plate with engraved squares on which a sheet of paper was fixed. The patient was placed in front of the machine. Defined parts of the patient's back were marked and then transferred onto the paper by tracing.

Bühring invented a scoliosis measuring machine

In 1885, the Swiss pediatrician and physician **Wilhelm Schulthess** (1855 – 1917), founder of the first orthopedic clinic in Zürich, constructed a measuring machine, based on the principles of Bühring. This apparatus allowed the depiction of a three-dimensional representation of the scoliosis [107]. Schulthess also invented stereotactic machines to produce calibrated corrections and to measure rotation (Fig. 4b). In 1906, he published a very comprehensive book on scoliosis, which served for many years as a reference textbook [108]. With the advent of X-ray machines at the beginning of the 20th century, the American orthopedic surgeon **John Robert Cobb** (1903 – 1967) introduced the **"Cobb angle",** which was popularized by the American orthopedic surgeon Robert Korn Lipmann (1898 – 1969) in 1935 [19].

Schulthess constructed a 3D measuring machine for scoliosis

The American surgeon **Joseph Charles Risser** (1892 – 1982) was a great advocate of early scoliosis treatment and frequently used plaster casts as a non-operative treatment. He also thought that it was better to operate on patients at an early age rather than waiting for the development of large curves. He popularized the assessment of the osseous fusion of the iliac crest apophysis as an estimate for the child's growth potential, which became later known as the **Risser sign** [98].

Risser first assessed the growth potential by iliac crest apophysis ossification

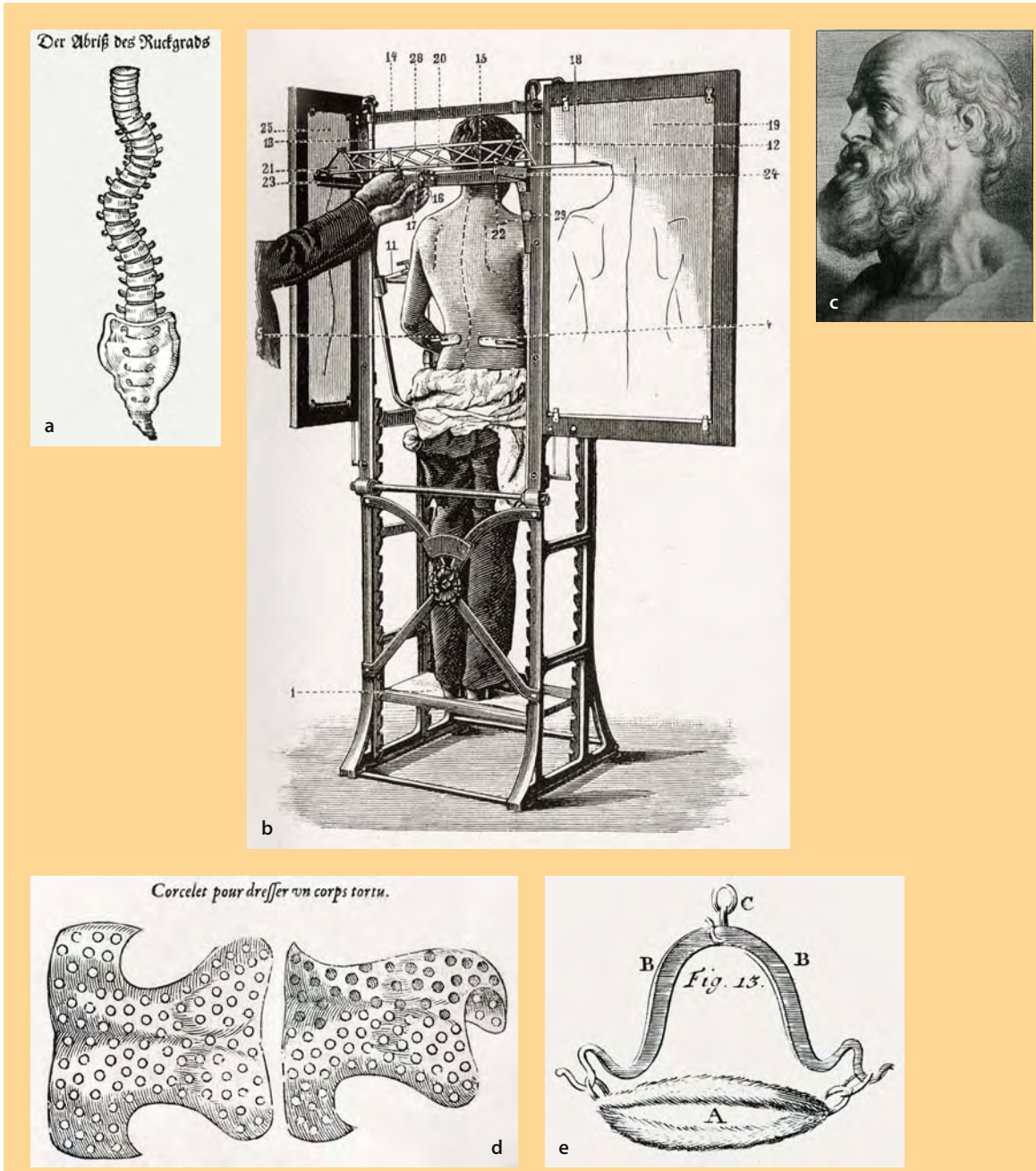


**Figure 4. Scoliosis**

**a** The first picture of a scoliotic spine published by Guilhelmus Fabricius Hildanus (1560–1634). **b** Measuring apparatus for scoliosis constructed by the Swiss physician and pediatrician Wilhelm Schulthess (1855–1917) in 1885. **c** Hippocrates of Cos (460–370 B.C.). **d** The scoliosis brace made of iron plates by Ambroise Paré (1510–1590). **e** The "Glisson swing" developed by Francis Glisson (1616–1691).




**Figure 4.** (*Cont.*)

f Heister's iron cross invented by the German surgeon Lorenz Heister (1683–1758). g *"Appareil du jour"* for scoliosis patients developed by Jean-André Venel (1740–1791). h *"Appareil de la nuit"* developed by Venel. i Paul Randall Harrington (1911–1980). j Harrington hooks and rods for the treatment of scoliosis.

## Non-operative Treatment

Probably the first description of the treatment of spinal deformity is recorded in the *Srimad Bhagwat Mahapuranam*, an ancient Indian epic written between 3500 and 1800 B.C. [111]. There, the Indian god Lord Krishna cures the hunchback of one of his female devotees named Kubja by applying axial traction.

An ancient Indian epic first described scoliosis treatment (3500–1800 B.C.)

The state of the art medical textbook of antiquity *On Articulation* (part of the monumental and famous *Corpus Hippocraticum*) was probably written by the Greek physician Hippocrates (Fig. 4c) of Cos (460–370 B.C.) and his scholars. In this text collection numerous descriptions concerning normal and abnormal spinal curvatures can be found [57]. However, spinal deformities provoked by tuberculosis were not differentiated from true scoliosis. The treatment was poor and consisted of the famous "**Traction Table**" also known as the "**Hippocratic**

Hippocrates invented the first traction table

**bench**" or "*scamnum*" (the Latin expression for traction table) with which patients were stretched, both horizontally and with underarm and leg distraction in suspension. In later times, only little progress was made regarding the etiology and treatment of spinal deformities.

Spinal deformities were thought to result from spinal luxation

Even at the end of the Middle Ages, the common belief was that a spinal deformity was caused by a spinal luxation. Therefore, such deformities were called "**spina luxata**" and the term included every kind of scoliosis and kyphosis. In 1544, the famous Italian surgeon **Guido Guidi** (1508 – 1569) proposed treating such spinal deformities by using the techniques of a traction table as introduced by Hippocrates and elaborated by Oribasius (325 – 405 A.D.) [91]. The surgical textbook *Chirurgia è Graeco in Latinum Conuersa*, written by Guido Guidi (alias Vidus Vidius) contains many illustrations depicting different types of extension machines also known as traction tables [42].

Paré (1510 – 1590) introduced a brace for scoliosis treatment

A less cruel method of treating spinal deformities was developed by **Ambroise Paré** (1510 – 1590). The father of French surgery also reintroduced the ligature of vessels. He suggested treating scoliosis by an iron plate brace (Fig. 4d) [79], which had to be changed in size during the acceleration phase of child growth at least every 3 months.

Blount introduced the Milwaukee brace

A revolutionary step forward in scoliosis bracing was made by the American orthopedic surgeon **Walter Putnam Blount** (1900 – 1992), who was devoted to scoliosis and its treatment. In 1945, Blount introduced the so-called "Milwaukee brace", which is still in use today [7].

Glisson developed a swing suspension by the head and armpits

The English physician **Francis Glisson** (1616 – 1691), professor of medicine for over 41 years at Cambridge, wrote extensively on rickets in his pioneering book *On Rickets* (*De Rachitide, Sive Morbo Puerili, qui Vulgo The Rickets Dicitur Tractatus*) in 1650. He assumed that scoliosis was caused by rickets and that the pathomechanism was based on the unequal and asymmetric bone growth of the spine [39]. Therefore, he developed a swing suspension by head and armpits known as the "**English swing**" or "**Glisson swing**" (Fig. 4e) [39].

Heister's iron cross served as a prototype for later scoliosis braces

Since then, many spinal extension machines have been developed and propagated, for example, the extension chair introduced by the French surgeon Pierre Dionis (birth date unknown – 1718) in 1707 [30]. In his *Cours d'Opération de Chirurgie*, **Pierre Dionis** also mentioned for the first time the use of an iron cross for correcting spinal scoliosis. The cross became well known as **Heister's cross**, because the German surgeon **Lorenz Heister** (1683 – 1758) first depicted the iron cross in his textbook of surgery [49, 50]. Heister's cross was used as a kind of scoliosis brace and served as a prototype for later scoliosis braces (Fig. 4f).

The book "*Orthopedia*" made Nicholas Andry the father of modern orthopedics

In 1741, the French pediatrician **Nicholas Andry** (1658 – 1742) published his epoch-making and pioneering textbook "***Orthopédie***" and became the father of modern orthopedics [3]. A great part of his book dealt with the description of scoliosis prevention, giving especial attention to sitting and postural habits and recommending for example physical exercises and a specially designed chair.

Venel invented a spinal extension machine (orthopedic bed)

Influenced by the Enlightenment, the Swiss orthopedic and former obstetrician **Jean-André Venel** (1740 – 1791) founded the world's first orthopedic hospital in the small Swiss town of Orbe in 1780. He developed a new treatment regime for spinal deformities in 1785 [113]. Venel believed that two kinds of procedures were suitable: first axial extension along the spine and second application of forces in transverse planes at the region of deviation. Furthermore, he was convinced that the treatment of scoliosis does not tolerate any interruption. Based on such ideas, he developed a brace for daily activities called an "***appareil du jour***" and an **orthopedic bed**, an extension machine, for the night called an "***appareil de la nuit***" (Fig. 4g, h). Venel's invention resulted in a hype boom during the fol-

lowing half century and all sorts of different orthopedic beds were developed. In 1829, Johann Friedrich Diefenbach (1792–1847), one of the most important orthopedic surgeons of the 19th century in Germany, catalogued the various extension beds and chairs, filling 70 pages [61].

## Scoliosis Surgery

Tenotomy and myotomy was the early but unsuccessful treatment for severe scoliosis

In the first half of the 19th century, tenotomy and myotomy were used for severe scoliosis both because of the prominent paraspinal muscles and the muscle dysfunction theory as outlined above. A very prominent advocate of tenotomy was the French surgeon **Jules René Guérin** (1801–1886), who developed this technique in 1835 and treated 1349 patients [41].

After the initial enthusiasm, some terrible outcomes were experienced by patients and the method was abandoned. It may be of interest that the controversy over this technique was one of the first incidences of doctors criticizing and attacking each other in print and in court.

Hibbs performed the first spinal fusion for scoliosis

In 1911, the American surgeon **Russel A. Hibbs** (1869–1933) fused the spine for tuberculosis and suggested extending this method also to scoliosis, as explained in more detail below [46]. He first performed an in situ fusion in 1914 and later corrected the curve with a cast until fusion had occurred. He gave several reports of his technique and advocated a long fusion before the deformity became severe [53, 54].

After the first successful instrumentations of the spine performed by **W.F. Wilkins** (1845–1935) [122] and a little bit later by **Berthold Ernst Hadra** (1842–1903) [45], many efforts were made to stabilize the spine with instrumentation, e.g. by the German orthopedic surgeon **Fritz Lange** (1864–1952) [69].

Harrington developed a milestone spinal instrumentation system

Finally, however, it was the American orthopedic surgeon **Paul Randall Harrington** (1911–1980) who succeeded in developing an appropriate system for scoliosis instrumentation (Fig. 4i) [37]. This spinal instrumentation system known as "Harrington instrumentation" consisted of stainless steel hooks and rods, which allows the correction of the spinal curvature by distraction (Fig. 4j). Harrington invented this spinal instrumentation system after a severe poliomyelitis epidemic in the late 1950s. He popularized spinal instrumentation in his milestone paper *Treatment of Scoliosis: Correction and Internal Fixation by Spine Instrumentation* published in 1962 [47]. The early technique consisted only of instrumentation. Fusion was later added because of the initial poor outcome.

Dwyer developed the first anterior spinal instrumentation system

Luque introduced segmental spinal correction

Cotrel and Dubousset introduced the concept of spinal derotation

In 1969, the Australian surgeon **Alan Frederick Dwyer** (1920–1975) introduced the first anterior spinal compression system for scoliosis correction [31]. More than a decade later the Mexican surgeon **Eduardo Luque** developed a posterior segmental fixation system, which allowed segmental stabilization without the need for a postoperative cast [74]. In 1984, the French surgeons **Yves Cotrel** and **Jean Dubousset** introduced their posterior derotation system, a system consisting of stainless steel pedicle screws, rods, hooks and transverse traction devices [22]. By means of this system, it was possible not only to address lateral deviation of the spine but also apical rotation and thereby improve the sagittal profile of the spine. Cotrel-Dubousset instrumentation started a new area in spinal surgery.

## Juvenile Kyphosis

Scheuermann first described juvenile kyphosis

The Danish radiologist **Holger Werfel Scheuermann** (1877–1960), head radiologist at the Cripple's Hospital in Denmark, first described juvenile kyphosis in his thesis which he presented to the University of Copenhagen in 1921. Scheuermann

reported on a series of 105 adolescent patients (80 % males) suffering from a sagittal curvature but with only a minimal coronal deviation [105]. Thus, he postulated a new group of spinal disorder, which begins during puberty and is associated with a genuine thoracic kyphosis. Initially, his thesis was rejected by the university committee. In 1957, he was finally awarded an honorary doctorate in recognition of his work. Nevertheless the entity became known as **Scheuermann's disease**.

The German pathologist **Christian George Schmorl** (1891 – 1932) performed pathoanatomical studies on more than 5 000 spinal specimens which he later published in his famous book *The Human Spine*. Schmorl first described the intercorporal disc prolapses known nowadays as **Schmorl's node** [106], which are frequently seen in juvenile kyphosis.

## Spondylolisthesis

### An Obstetrical Problem

Herbiniaux described the first case of spondylolisthesis

Spondylolisthesis must have been observed in ancient times but was probably first mentioned in 1782 by the Belgian surgeon and obstetrician **G. Herbiniaux** (1740 – end of the 18th century). He claimed that it interfered with childbearing and resulted in the death of both mother and child [52].

Kilian coined the term "spondylolisthesis"

In 1854, **Herman Friedrich Kilian** (1800 – 1863) coined the term "spondylolisthesis", which means the "downward gliding of the spine" [64].

In 1882, **Franz Ludwig Neugebauer** (1856 – 1914), an obstetrician in Warsaw, published a monograph on spondylolisthesis in which he described exactly the clinical features of spondylolisthesis also in relation to obstetrical problems of a narrowing birth canal in patients with severe spondylolisthesis [89]. In 1976, **Wiltse, Newmann and Macnab** were the first to classify spondylolisthesis into five categories: dysplastic, isthmic, degenerative, traumatic and pathological types [124].

### Surgery

In 1893, Sir **William Arbuthnot Lane** (1856 – 1938), who became famous for introducing the "no touch" or fully instrumental technique of surgery, performed a decompressive laminectomy on a 34-year-old woman who suffered from progressive gait disturbance, leg weakness and loss of sensation in the lower limbs. During the operation, he found a forward slipping of the body and neural arch of L5 on the sacrum without any defect [67].

The first anterior interbody fusion was performed by Burns

In this context, the history of the anterior interbody fusion technique should briefly be reviewed because this surgical technique was first successfully performed in a 14-year-old boy with spondylolisthesis by the English surgeon Burns in 1933 [14]. Burns' technique consisted of driving an autologenous tibia dowel through the fifth lumbar vertebra into the sacrum (Fig. 5).

**Lane and Moore** published the first routine series of anterior interbody fusion in 1948 and shortly after Harmon brought his series to the public in 1950 and 1960 [46, 68]. Since then, many modifications have been made. In the late 1950s, the American surgeon Humphries and his team first introduced the plate system for anterior interbody fusion, which consisted of an especially designed compression plate primarily for the lumbosacral joint that was fastened onto the anterior surface of the vertebra by screw [60]. At the same time, the orthopedic surgeon **Arthur Ralph Hodgson** (1915 – 1993), head of the Orthopedic and Trauma Unit at the University of Hong Kong, developed an anterior fusion by using bone grafts for tuberculosis treatment as explained in more detail below

Hodgson developed an anterior fusion technique with bone graft insertion

**Figure 5. Spondylolisthesis**

Anatomical drawing of the first successful interbody fusion by B.H. Burns in 1933 [14] (with Permission from Elsevier).

[58]. In 1936, Jenkins tried to reduce the slip with traction and fusion [63]. Three decades later, Paul Harrington used his spinal instrumentation system to reduce severe spondylolisthesis [48].

## Back Pain and Sciatica

Back pain has been known since the start of written history. Probably the first report of back pain and sciatica can be found in an ancient text, the so-called *Edwin Smith Surgical Papyrus* presumably written around 1550 B.C. [10].

The *Edwin Smith Surgical Papyrus* first described back pain (1550 B.C.)

In the industrialized countries, back pain today is the second most common reason for seeking medical care. Back pain accounts for 15 % of all sick leaves and is the most common cause of disability for persons under 45 years of age. However, in historical textbooks, only little information is available on backache. Waddell stated: "At first glance, backache appears to be a problem only since World War II. At second glance, we realize that not back pain but back related disability became a medical problem at the end of the last century" [118].

Not back pain but back related disability has dramatically increased in the last five decades

## A Wrong Mixture of Fluids

The first descriptions of spinal pain, called sciatica, are also found in the Hippocratic texts *Predictions II* (*Praedictiones II*) [57].

Hippocratic texts first described sciatica

The *Predictions* are a collection of medical texts concerning especially symptoms, course, differential diagnosis and prognosis of a selection of different diseases. It is assumed that the famous Greek physician, Hippocrates of Cos (460 – 370 B.C.), the father of the Hippocratic oath, and his scholars contributed to this ancient medical textbook. Of note, Hippocrates did not differentiate between symptoms caused by spinal and femoral problems. Both entities were called "sciatic" at that time.

The outstanding and important Greek physician **Galen of Pergamon** (130 – 200 A.D.), who became physician to the Emperor Marcus Aurelius (121 – 180), described low back pain in his *Definition of Medicine* (*Definitiones Medicae*) similar to the Hippocratics [36]. Both the Hippocratics and Galen assumed a wrong

mixture of fluids to be the cause of such symptoms according to the so-called "fluid doctrine" of Hippocrates. Other ancient physicians had more or less the same explanation for the sciatic pain syndrome. During antiquity and the Middle Ages, this view persisted and the term "sciatic" served as a description for hip, buttocks, loins and leg pain.

Initially "sciatica" described hip, buttocks, loin as well as leg pain

The Italian physician **Domenico Felice Antonio Cotugno** (1736–1822) first differentiated sciatica from hip related pain in his pioneering study *De Ischiade Nervosa Commentarius* (*Commentary on Nervous Sciatica*) (1764). The nervous sciatica was called "*iscias nervosa Cotunni*" also known as the "*malum Cotunni*" or "Cotugno syndrome" (Fig. 6a) [21]. He was such a skilled clinical examiner he was able to divide his Cotugno syndrome into two entities:

- anterior "*iscias nervosa postica*"
- posterior "*iscias nervosa antica*"

Cotugno first differentiated nervous sciatica from musculoskeletal leg pain

The anterior "*iscias nervosa postica*" was described as pain radiating from the groin along the inside of the thigh and down the lower leg. The posterior "*iscias nervosa antica*" corresponded to pain radiating from the greater trochanter major along the outside of the thigh and down into the lower leg. Cotugno thereby became the first author to describe the lumboradicular syndrome.

Brown first assumed neural irritation to be a cause of back pain

However, the true cause of the nervous sciatica still remained unknown. He was still very close to the antique fluid doctrine. Cotugno is also known for his discovery of cerebrospinal fluid as outlined above, his discovery of aqueductus of the inner ear and his description of the typhoid ulcers. It was finally the English physician Brown of Glasgow in 1828 who first suggested that irritation of the nervous system could be responsible for back pain [13].





DIE

HALBGELENKE

DES

MENSCHLICHEN KÖRPERS.

EINE MONOGRAPHIE

VON

DR. HUBERT LUSCHKA,

PROFESSOR DER ANATOMIE IN TÜBINGEN.

MIT SECHS KUPFERTAFELN.

BERLIN, 1858.

DRUCK UND VERLAG VON GEORG REIMER.



**Figure 6. Back pain and sciatica**

a Domenico Felice Antonio Cotugno (1736–1822). b *The Half Joints of the Human Body* published in 1858 by the German pathologist Hubert von Luschka (1820–1875).

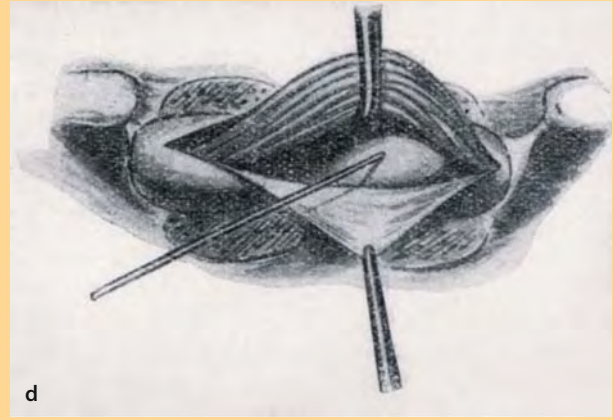

**Figure 6.** (*Cont.*)

**c** The illustration depicted in *The Half Joints of the Human Body* shows a nucleus protrusion of the intervertebral disc between the 12th thoracic and 1st lumbar vertebra. **d** The drawing shows removal of a so-called "extradural chondroma" depicted in the paper by Fedor Krause (1857–1937) and Heinrich O. Oppenheim (1858–1919) in 1908. **e** This drawing shows the concept of a disc compressing the cauda equina as seen by Joel E. Goldthwait (1867–1961).

## Disc Herniation

Luschka (1820–1875) first described a protruded disc

After a brief report of protruded disc written by the great pathologist Virchow in 1858, the German pathologist **Hubert von Luschka** (1820–1875) published a detailed and concise description and illustration of a protruded disc in his epoch-making monograph *The Half Joints of the Human Body* (Fig. 6b) [75].

He supposed that these disc protrusions were caused by a tumor like cartilage outgrowth of the nucleus pulposus and called such protrusions anomalies of intervertebral discs (Fig. 6c). Notwithstanding Luschka's descriptions of a subligamentary and intraligamentary outgrowth of a cartilage-gelatinous mass from the nuclear material with a consecutive transligamentary burst, the effective origin of these disc protrusions and the clinical link to the sciatica were still unexplained for another 70 years. Luschka's scientific publications and anatomic textbooks became the gold standard of the time because of their clear presentation and excellent drawings.

Christian George Schmorl (1862–1932), Director of the Pathological Institute in Dresden, studied more than 5000 spine specimens. In 1928, he published two

cases of disc protrusion, which he interpreted as supplementary nuclei pulposi, remnants of the primitive chorda, respectively.

Andrea first proposed a degenerative origin of disc protrusion

Finally, in 1929, it was a disciple of Schmorl, **Rudolf Andrae**, who gave the accurate explanation for the disc protrusion. In his work *On Cartilage Node in the Posterior End of Intervertebral Disc Near by the Spinal Canal*, Andrae confirmed Schmorl's observations by describing 56 similar cases in 365 examined spines. Furthermore, he proposed that disc protrusion is based on a degenerative disruption of annular fibers which permits extrusion or sequestration of nuclear material. In addition he could exclude the theory of a neoplastic process as cause for disc protrusion [2]. Even though the pathophysiological mechanism was elucidated, there was no link to the clinical symptom of sciatica.

Krause and Oppenheim (1958 – 1919) first performed a discectomy

With the advent of neurotopic diagnosis using dermatomes at the end of the 19th century, specific operative intervention for the spine and spinal cord became possible. On 23 December 1908, the German surgeon **Fedor Krause** (1857 – 1937), who worked at the Augusta Hospital in Berlin together with the German neurologist **Heinrich O. Oppenheim** (1858 – 1919), was the first to operate on a disc prolapse in a patient who had suffered from severe sciatic pain for several years and had developed an **acute cauda equina syndrome** [90]. The operation (Fig. 6d) consisted of:

- laminectomy L2–L4
- splitting the dura
- mobilizing the cauda equina by a retractor
- exploring the operation field
- removing a small tumor mass

After the operation, the patient felt much better and the neurological problems disappeared. Following the theory of Luschka, Krause and Oppenheim supposed that this fibrocartilage mass was an enchondroma.

Goldthwait first proposed that sciatica is caused by a disc prolapse

In 1911, the American physician **Joel E. Goldthwait** (1866 – 1961) reported on a 39-year-old patient who initially suffered from an affection of the sacroiliac joint. The patient underwent inadequate manipulations and subsequently developed a cauda equina syndrome. Based on this case, he proposed that a prolapse of the intervertebral disc could be an explanation for many cases of lumbago, sciatica and paraplegia (Fig. 6e) [40]. At the same time, the physicians George S. Middleton (1853 – 1928) and John H. Teacher (1869 – 1930) reported a case of a laborer who had sustained a disabling injury during work while lifting a heavy object [74, 85]. The patient suffered from sciatica and paraplegia. The authors suggested that a disc rupture caused the severe clinical condition of that patient.

## Disc Surgery

In 1929, the famous Walter E. Dandy (1886 – 1946), professor of neurosurgery at Johns Hopkins, discovered that nodules of discal origin could produce sciatica by compression and that their removal would cure pain. He published this hypothesis in the *Archives of Surgery* [25], but unfortunately little attention was paid to this article, because he called the protrusions and prolapses tumors. However, it was not until 1934 that the American neurosurgeon **William Jason Mixter** (1880 – 1958) and the orthopedic surgeon **Joseph Seaton Barr** (1901 – 1963), working at the Massachusetts General Hospital, established that the supposed neoplastic process was just a prolapse of the disc (Historical Case Study).

Mixter and Barr established the link between disc prolapse and sciatica

They also discovered the long missing link between sciatica and disc protrusion [86].

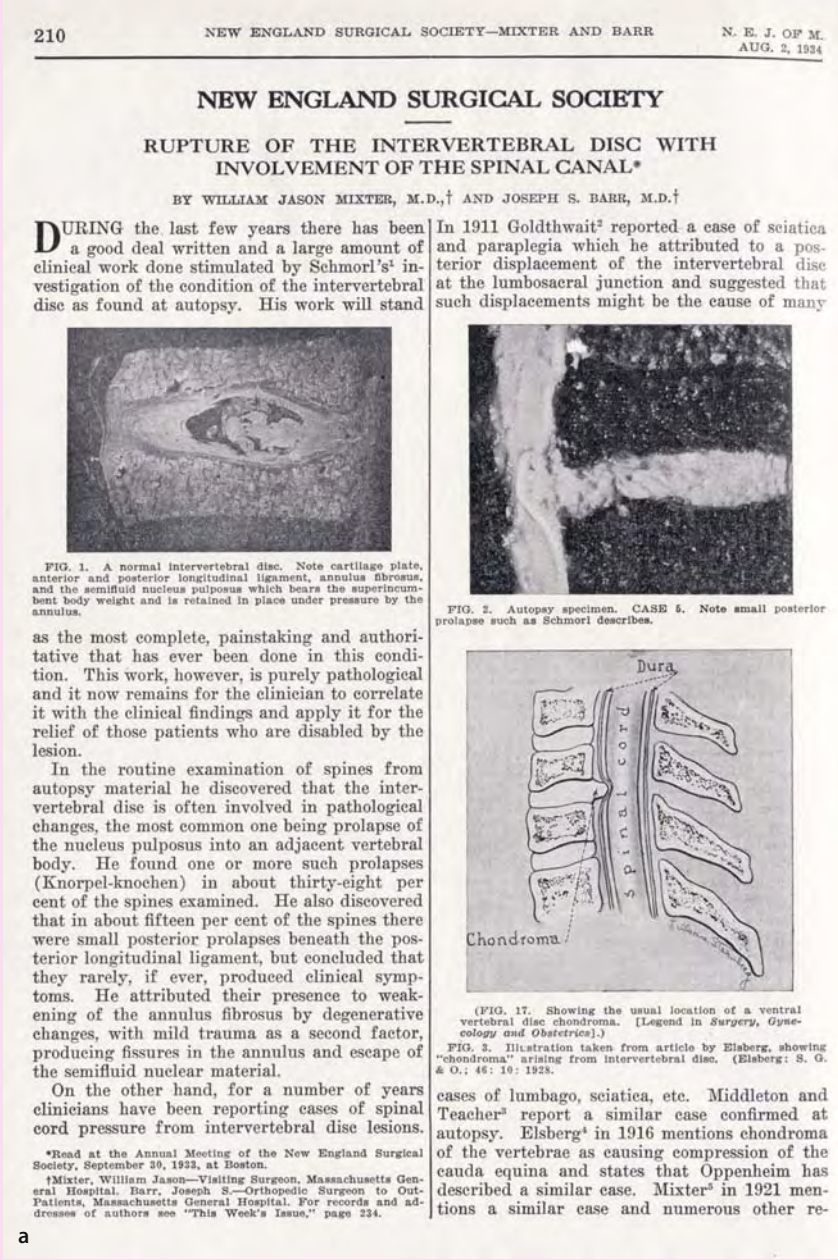

210 NEW ENGLAND SURGICAL SOCIETY—MIXTER AND BARR N. E. J. OF M. AUG. 2, 1934

NEW ENGLAND SURGICAL SOCIETY

RUPTURE OF THE INTERVERTEBRAL DISC WITH INVOLVEMENT OF THE SPINAL CANAL*

BY WILLIAM JASON MIXTER, M.D.,† AND JOSEPH S. BARR, M.D.†

DURING the last few years there has been a good deal written and a large amount of clinical work done stimulated by Schmorl's[1] investigation of the condition of the intervertebral disc as found at autopsy. His work will stand as the most complete, painstaking and authoritative that has ever been done in this condition. This work, however, is purely pathological and it now remains for the clinician to correlate it with the clinical findings and apply it for the relief of those patients who are disabled by the lesion.

In the routine examination of spines from autopsy material he discovered that the intervertebral disc is often involved in pathological changes, the most common one being prolapse of the nucleus pulposus into an adjacent vertebral body. He found one or more such prolapses (Knorpel-knochen) in about thirty-eight per cent of the spines examined. He also discovered that in about fifteen per cent of the spines there were small posterior prolapses beneath the posterior longitudinal ligament, but concluded that they rarely, if ever, produced clinical symptoms. He attributed their presence to weakening of the annulus fibrosus by degenerative changes, with mild trauma as a second factor, producing fissures in the annulus and escape of the semifluid nuclear material.

On the other hand, for a number of years clinicians have been reporting cases of spinal cord pressure from intervertebral disc lesions.

*Read at the Annual Meeting of the New England Surgical Society, September 30, 1933, at Boston.

†Mixter, William Jason—Visiting Surgeon, Massachusetts General Hospital. Barr, Joseph S.—Orthopedic Surgeon to Out-Patients, Massachusetts General Hospital. For records and addresses of authors see "This Week's Issue," page 234.

FIG. 1. A normal intervertebral disc. Note cartilage plate, anterior and posterior longitudinal ligament, annulus fibrosus, and the semifluid nucleus pulposus which bears the superincumbent body weight and is retained in place under pressure by the annulus.

In 1911 Goldthwait[2] reported a case of sciatica and paraplegia which he attributed to a posterior displacement of the intervertebral disc at the lumbosacral junction and suggested that such displacements might be the cause of many cases of lumbago, sciatica, etc. Middleton and Teacher[3] report a similar case confirmed at autopsy. Elsberg[4] in 1916 mentions chondroma of the vertebrae as causing compression of the cauda equina and states that Oppenheim has described a similar case. Mixter[5] in 1921 mentions a similar case and numerous other re-

FIG. 2. Autopsy specimen. CASE 5. Note small posterior prolapse such as Schmorl describes.



(FIG. 17. Showing the usual location of a ventral vertebral disc chondroma. [Legend in *Surgery, Gynecology and Obstetrics*].)

FIG. 3. Illustration taken from article by Elsberg, showing "chondroma" arising from intervertebral disc. (Elsberg: S. G. & O.; 46: 10: 1928.

a

## Historical Case Study

The following text represents a short extract of the milestone article "Rupture of the intervertebral disc with involvement of the spine canal" (a) (Massachusetts Medical Society, with permission): written by William Jason Mixter (b) and Joseph Seaton Barr (c) in 1934 [86]:

"The symptoms and signs of these so-called chondromata, which we believe in most instances represent rupture of the intervertebral disc, have been discussed at length by Elsberg and Stookey. The symptoms depend entirely on the location and size of the lesion. There is often a history of trauma not immediately related to the present condition. Numbness and tingling, anaesthesia, partial or complete loss of power of locomotion, are usually present. Bladder and rectal sphincter may be involved. The condition of the reflexes varies with the level of the lesion. If it is compressing the cauda equina the tendon reflexes may be absent; if higher, compressing the cord, the legs may be spastic and the reflexes exaggerated with positive Babinski sign. If the lesion is low in the spine, the physical examination may be suggestive of low back strain or sacro-iliac strain. X-ray examination may be entirely negative, but narrowing of the intervertebral space is often present and is of significance, as it ordinarily means escape of the nucleus pulposus, not necessarily but possibly into the spinal canal... Therefore we have developed certain ideas as to the operation when we suspect this lesion to be present.

b


c

**Historical Case Study** *(Cont.)*

Exposure of the spine and laminectomy are performed as usual except that the laminectomy is narrow and on the side where the lesion is suspected, for we believe that a ruptured disc is a weakened disc and the strength of the spine should be preserved as much as possible. The dura is opened and the spinal canal carefully explored, particular attention being given to the intervertebral discs in front of the cord and the intervertebral foramina. If the lesion is found in the midline it is approached by incising the dura over it as suggested by Elsberg. If it is lateral, the dura is closed and the dissection carried out to the side between the dura and the bone. If lesion is suspected in the intervertebral foramen it may be necessary to carry the removal of bone well out to the side, even taking in part of the pedicle. After removal the tumor is exposed. It frequently comes away without any dissection and if not, section across its base or removal with curette is bloodless. Though we have done it in only two cases, we believe that it may be advisable to slip bone chips in between the stumps of the laminae before closing the wound, in order to facilitate fusion. After removal of the tor piece of the disc one frequently finds an opening through which a probe may be passed into the nucleus pulposus... We conclude from this study: a that herniation of the nucleus pulposus into the spinal canal, or as we prefer to call it, rupture of the intervertebral disc, is a not uncommon cause of symptoms. That the lesion frequently has been mistaken for cartilaginous neoplasm arising from the intervertebral disc... That the treatment of this disease is surgical and that the results obtained are very satisfactory if compression has not been too prolonged."

This finding rapidly attracted surgeons and basic researchers to the intervertebral disc. The enthusiasm to solve back pain and sciatica surgically by disc excision started as Macnab called it "**the dynasty of disc**" [77]. The disc was thereafter made responsible for all kinds of back and leg pain and many treatment failures were the consequence.

Love developed the interlaminar "key hole" approach for discectomy

In the early days, the disc prolapse was removed by a full transdural approach with laminectomy. In 1939, **Grafton Love**, a surgeon at the Mayo Clinic, published a new method which he called "**key hole**" laminectomy, an intralaminar approach for disc prolapse removal, which preserved spinal stability. Therefore, his approach served also as a precursor to the microscopically assisted approach [73].

Lyman Smith introduced chemonucleolysis for disc prolapses

The American physician Lyman Smith developed a less invasive method for disc protrusions and reported his results in 1964 [109]. He injected chymopapain into the disc to shrink the disc protrusion. Although chemonucleolysis was effective, this method went out of fashion because of some cases of anaphylactic reaction and transverse myelitis.

Caspar and Williams introduced microdiscectomy

In 1975, Hijkata of Japan first reported on a percutaneous lumbar nucleotomy technique by a posterolateral approach [35]. In the late 1970s, the German neurosurgeon **Caspar** and the American neurosurgeon **Williams** introduced the use of the microscope for minimally invasive discectomy, which today has become the standard technique in many centers [17, 123].

In 1986, **P.W. Ascher** performed the first percutaneous laser decompression of intervertebral discs [14], but this technique never demonstrated clinical efficacy.

A further milestone in the treatment of degenerative disc disease was the development of an artificial disc, which allowed lumbar motion to be preserved. U. Fernström first implanted a rudimentary lumbar disc replacement consisting of a single steel ball in the late 1950s [34].

U. Fernström implanted the first lumbar disc prothesis

After several less promising developments of different designs, K. Schellnack and K. Büttner-Janz developed the SB Charite disc prothesis at the Charité (Hospital) in Berlin in the early 1980s [15]. Further developments of this prothesis type resulted in the first FDA approved total disc arthroplasty device.

## The Facet Syndrome

It was the Belgian anatomist **Andreas Vesalius** (1514 – 1564), professor of anatomy at the University of Padua, who first correctly described the facet joint in his epoch-making anatomical textbook *De Humani Corporis Fabrica Libri Septi* in 1543 [116]. The American **Joel E. Goldthwait** (1867 – 1961), first surgeon-in-chief of the Orthopedic Department at the Massachusetts General Hospital, first realized that the facet joints also play an important role in low back pain [40]. Finally, in 1933, **R.K. Ghormley** is credited as having coined the term "**facet syndrome**" for back pain caused by altered facet joints [38]. This syndrome was re-popularized by Vert Mooney in 1976 [87], but debate continues about the clinical entity.

Ghormley coined the term "facet syndrome"

## Spinal Stenosis

The first evidence of spinal stenosis can be found in Egyptian mummies. The first report of a spinal stenosis is attributed to the French surgeon **Antoine Portal** (1742 – 1832) in 1803. He observed at autopsy three specimens with narrowing of the spinal canal [93]. He was also able to relate the pathological findings to the typical clinical symptoms of spinal stenosis.

Portal made the first description of spinal stenosis in 1803

The Italian orthopedic surgeon **Vittori Putti** (1880 – 1940), one of the most outstanding European orthopedic surgeons of the first half of the 20th century, emphasized the relevance of anomalies or acquired degenerative alterations of

Vittorio Putti was the first to report the relevance of foraminal stenosis

**Figure 7. Spinal stenosis**

a Vittorio Putti (1880 – 1940). b Henk Verbiest (1909 – 1997).

the intervertebral foramina and lateral recess, for causing sciatica by causing an entrapment of the existing root (Fig. 7a) [94]. In his article, published in *The Lancet* in 1927, Putti gained international attention and it was a further step in the understanding of the pathomechanism of sciatica in cases which are not caused by a slipped disc [95].

Henk Verbiest discovered the relevance of a narrow spinal canal

With the Dutch neurosurgeon Henk Verbiest (1909–1997), also known as the "pope of spinal stenosis", lumbar stenosis became a well-defined pathological entity (Fig. 7b) [4]. He introduced the concept of developmental stenosis, which is caused by an abnormally short midsagittal diameter of the spinal canal [114, 115].

## Spinal Infections

Despite the advent of chemotherapy and improved surgical techniques, spinal infections are still a potentially life threatening disease even in the industrialized world. In the past, tuberculosis has played an important role as a cause of spinal deformities and was one of the most common "orthopedic" diseases all over the world.

### Egyptian Mummies and Sir Percival Pott

Spinal tuberculosis is older than written history

Spinal tuberculosis is older than written history, because the first evidence of spinal tuberculosis was found in a skeleton from about 5000 B.C. [51]. Further evidence of spinal infection most likely caused by tuberculosis was found in Egyptian mummies dating from the Predynastic time, 3000 B.C. and earlier. A very good example of spinal tuberculosis was found in Neshparenhan, from the cache of 44 priests of Amun (21st Dynasty, 1100 B.C.) reported by Ruffer in 1910. The mummy reveals the typical features of Pott's disease with an acute angulation of the spine caused by the collapsed thoracic vertebral bodies and a psoas abscess (Fig. 8a) [103].

In the Hippocratic textbook *On Articulations*, extended descriptions about spinal deformities are in particular very similar to those of Pott's disease [50]. **Hippocrates of Cos** (460–375 B.C.) and his scholars have suggested treatment of patients by bench stretching and this became a very popular therapy for a long time. In 1896, the French orthopedic surgeon **Jean-Francois Calot** (1861–1944) tried to cure tuberculosis related spinal deformities by his "*redressment brusque*" (or "*redressment forcé*") based on the Hippocratic procedure (Fig. 8b) [16]. But after some brief enthusiasm, this treatment was abandoned because of various severe complications.

Pott recognized the link between tuberculosis, kyphosis and paraplegia

In 1779, the English surgeon **Sir Percival Pott** (1714–1788), author of classic monographs on head injuries and fractures, is credited as having recognized the tuberculous nature of this disease. He published his account of tuberculous paraplegia entitled *Remarks on that kind in palsy of the lower limbs, which is frequently found to accompany a curvature of the spine, and is supposed to be caused by it* (Fig. 8c) [94, 95]. The first association of paraplegia with kyphotic deformity was obviously made by the French surgeon **Jacques Dalechamps** (1513–1577) in 1570 [28].

Dalechamps first described the association of paraplegia and kyphotic deformity

Dalechamps still believed in the method of mechanical treatment of a "*spina luxata*" by performing extension and simultaneously sitting on the patient's hunchback as propagated by the famous Italian physician **Guido Guidi** (1500–1569) [42]. Although the tuberculous nature of spinal deformity had been surmised by Hippocrates and confirmed by Galen, it was Pott's classic description that finally brought the condition to clarity for the practitioner (Fig. 8d).



**Figure 8. Spinal infection**

a The Old Egyptian mummy Neshparenhan, a priest of Amun (circa 1100 B.C.), shows the typical features of Pott's disease: collapsed thoracic vertebral bodies with kyphotic angulation. b This painting illustrates the "*redressement forcé*" by the French orthopedic surgeon Jean-Francois Calot (1861 – 1944). c Sir Percival Pott (1714 – 1788). d The drawing of the so-called "carious spine" depicted in Pott's work in 1779.

He showed that there was not a luxation of vertebrae but an inflammatory abscess that compromises the spinal cord. **Pott's trias** was defined by three findings:

- paraplegia
- gibbus
- abscess

The true nature of "**spinal caries**" as tuberculous spondylitis was recognized by **Jacques-Mathieu Delpech** (1777 – 1832), murdered by a patient on whom he had performed a varicocele operation, and Carl Freiherr von Rokitansky (1804 – 1878) in 1842 [29, 100]. Finally, it was the famous German physician and bacteriologist **Robert Koch** (1843 – 1910), founder of modern experimental bacteriology

Robert Koch first discovered *Mycobacterium tuberculosis*

and Nobel prize winner in 1905, who succeeded in isolating and describing the germ of tuberculosis: *Mycobacterium tuberculosis*.

## Treatment

Before the 19th century, treatment was just based on bed rest and/or cruel traction. It can be imagined what torture it was. Spinal frames and, later, plaster beds, plaster jackets and back supports came into almost universal use but without any proven benefit.

Despite the first experience of abscess drainage reported by Pott, this procedure seemed to be very dangerous because of the high death rate leading to controversies. With the advent of new surgical and supporting techniques in the late 19th century, more and more surgical approaches to the treatment of tuberculosis were developed. In 1909, the German surgeon **Fritz Lange** (1864 – 1952) tried to stabilize the tuberculous spine by fixing it up by means of celluloid bars and silk wire. Later he also used steel rods and wires [69].

Lange was a pioneer of internal spinal fixation

Albee performed the first successful spinal fusion

**Fred Houdlette Albee** (1876 – 1945), a great American orthopedic surgeon at the beginning of the 20th century and co-founder of the International Society of Orthopaedic Surgery and Traumatology (SICOT), first reported on a successful lumbar spinal fusion. Albee tried to stabilize the spine of a patient suffering from spinal tuberculosis. He first sagittally split the spinous processes, and then he laid a strip of autologous tibia between the two halves of them [1]. During this time, Albee was very interested in bone graft techniques and he therefore performed many bone graft experiments on dogs.

Albee's report was shortly followed by another account of lumbar spinal fusion written by his colleague **Russel A. Hibbs** (1869 – 1932), who became the surgeon-in-chief of the later New York Orthopedic Hospital in 1897. Hibbs also tried to produce a posterior fusion by using autologous bone graft.

Procedures were also developed which aimed to drain the abscess, e.g. abscess enucleation described in 1894 by the French orthopedic surgeon Victor Ménard [83]. However, none of these operative techniques produced satisfactory results.

Hodgson introduced radical debridement and anterior spinal fusion for tuberculosis

In the 1950s, **Arthur Ralph Hodgson** (1915 – 1993) (born in Uruguay to British parents) was a protagonist in what became known as the Hong Kong school of tuberculosis treatment [82]. Hodgson and his coworkers suggested a **new surgical technique** which consisted of:

- radical surgical debridement
- anterior spinal fusion with autologous bone-graft (rib, ilium) [58]
- chemotherapy

In the 1950s, although the first effective chemotherapies with streptomycin, isoniazid and paraamino-salicyclic acid were successful in the treatment of pulmonary tuberculosis, orthopedic surgeons were suspicious of the effectiveness for spinal tuberculosis [65, 88]. Based on the experience of the **Hong Kong school**, radical debridement, fusion and chemotherapy became the **gold standard** for cases with deformity and neurologic compromise [82].

## Ankylosing Spondylitis

Ankylosing spondylitis is a highly heritable, common rheumatic condition, primarily affecting the axial skeleton. There is still no causative cure and for patients it remains a very disabling disease (Fig. 9a). The first evidence of ankylosing spondylitis was found in many Egyptian mummies ranging from 3000 B.C. up to the Roman

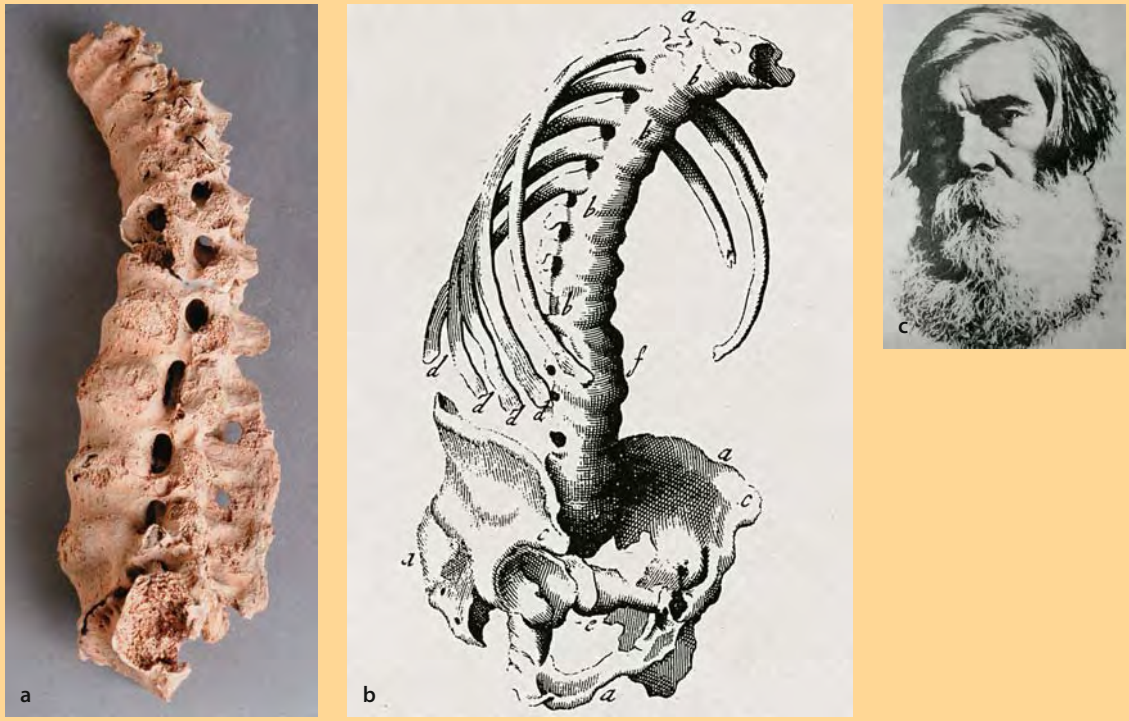


**Figure 9. Ankylosing spondylitis**

a Typical features of ankylosing spondylitis in the skeletal remains of a Late Medieval/Early Modern Times male 50 years of age from La Neuveville, Switzerland. b The peculiar skeleton as described by the Irish physician Bernard Connor (1666–1698). c Vladimir von Bechterew (1857–1927).

period [103]. A most likely case of ankylosing spondylitis is the one of Ramses II (1200 B.C.). He was one of the most powerful Egyptian kings ever and is remembered for his countless monuments, for example the temple in Abu Simbel [81].

## Discovery of a New Disease

Conner first described ankylosing spondylitis

The Irish physician **Bernard Connor** (1666–1698) gave a first accurate description of ankylosing spondylitis. He practiced for several years at the French Court during the regency of Louis XIV (1638–1715). He later became appointed physician to the Polish King John Sobieski in 1694. In 1693, he described an unusual skeleton consisting of a unified spine that was found in a local cemetery (Fig. 9b) [20]. He suggested that the deformity originated in utero as a consequence of pressure from abscess tumor in the womb or elsewhere.

Travers and Lyons both described cases of ankylosing spondylitis

First clinical reports of two putative cases of ankylosing spondylitis were both published in early issues of *The Lancet*. The first case, known as **Traver's case**, was reported by the St. Thomas Hospital (London) in 1824. The article deals with a young girl of good condition, who had suffered from a totally stiff spine caused by an ossification of the intervertebral disc as her treating physician **Benjamin Travers** (1783–1858) had assumed [112]. The second case report, published in 1832, was by **Philip Moyle John Lyons** (1804–1837) and dealt with a 36-year-old bricklayer who had been suffering from a severely stiffened immobilizing spine over several years with accompanying back and joint pain [76]. For the first time, the whole complex of ankylosing spondylitis was described fully and at length in

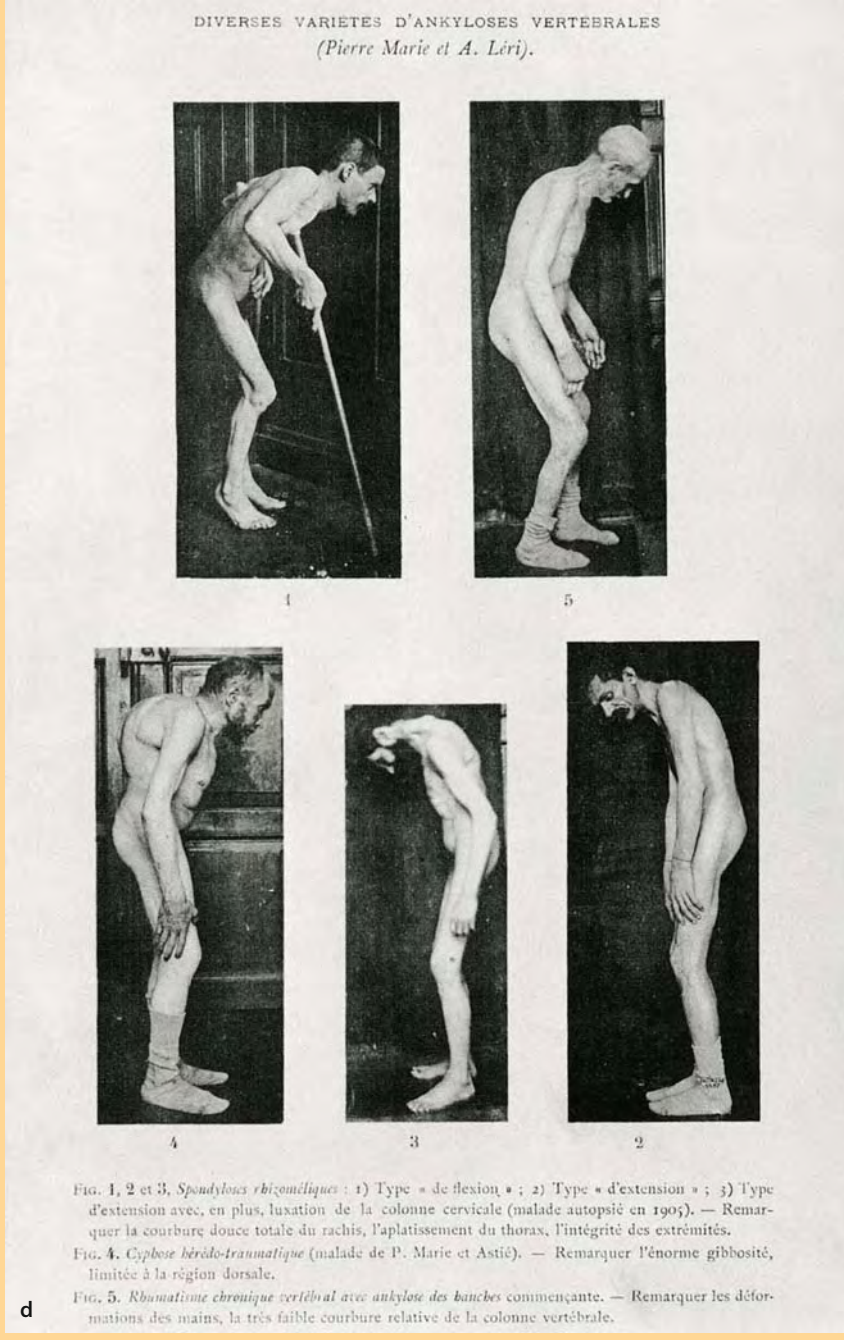


d

**Figure 9.** (*Cont.*)

d The photographic plate from the treatise on ankylosing spondylitis written by the French neurologist Pierre Marie (1853 – 1940) published in 1906.

Bechterew popularized ankylosing spondylitis in Continental Europe

1877 by the English physician **Charles Hilton Fagge** (1838 – 1883), who worked at Guy's Hospital in London [33]. The Russian **Vladimir von Bechterew** (1857 – 1927), Professor of Neurology in St. Petersburg, was interested in ankylosing spondylitis (Fig. 9c). With his report on ankylosing spondylitis in 1893, he made it very popular in Europe [117]. That is why nowadays ankylosing spondy-

litis is often called "**Morbus Bechterew**". But he misconceived the etiology of ankylosing spondylitis, because he believed that the spinal stiffness was caused by a neurological disorder.

Finally, it was the German pathologist and bacteriologist **Eugen Fraenkel** (1853–1925), credited for his great work on pathology and differential diagnosis, who first introduced the name "ankylosing spondylitis" in 1904 [35].

The term "ankylosing spondylitis" was coined by Fraenkel

Another neurologist, **Pierre Marie** (1853–1940), professor in Paris, finally defined ankylosing spondylitis as an individual entity and proposed the name "*spondylose rhizomelique*". Solely by means of good clinical assessment (Fig. 9d) and without any technical devices, he was able to describe this disease as precisely and concisely as no one before him [80]. He also postulated that the etiology of ankylosing spondylitis is an osteopathy caused by infection or toxin, which finally leads to a hyperostotic process of the facet joints.

## Spinal Injuries

Spinal injuries have been diagnosed and treated since antiquity and are still one of the most severe injuries which lead to handicap and disability. In the past, most of the patients with spinal cord injuries died after a short time because of a combination of pressure sores and urinary tract infection. Thanks to the good supportive techniques and rehabilitation developed since World War II, patients suffering from spinal cord injuries have better lifetime prognosis and living conditions.

Spinal injuries have been diagnosed and treated since antiquity

### First Reports

Evidence of spinal fractures can be found in prehistory. The oldest known case of a spinal fracture in a presumably 34 000-year-old Early Stone Age (Upper Palaeolithic) skeleton from Stetten in Germany reveals a healed lumbar L3–L4 fracture [119].

A first description of spinal cord injuries is found in the *Edwin Smith Surgical Papyrus* [10]. The manuscript, written on papyrus, is dated to the 16th century B.C. (Historical Case Introduction). But it is widely believed that it is a copy of a much earlier work possibly 1 000 years older. In this text, collections of different instructions are found concerning for example a crushed cervical vertebra or cervical displacement of a vertebra.

The *Edwin Smith Papyrus* gives the first description of spinal injuries

Further evidence of spinal injuries is also given in the Hippocratic texts. According to the Hippocratic orthopedic textbook *On Articulations*, spinal injuries are classified into three different types [57] based on the direction of vertebrae displacement and the spine deformity:

Hippocrates provided the first classification of spinal injuries

- anterior displacement
- posterior displacement
- injuries with no visible deformity

Each of these types is described with their prognosis.

Galen of Pergamon (130–200 A.D.) described spinal injuries in the same way as Hippocrates [36]. Additionally, **Galen** performed different experiments on spinal cord and spinal cord lesion in primates as outlined above, and he also made observations on patients with spinal injuries notably gladiators falling from chariots, perhaps the earliest recorded spinal injuries from road accidents. On this basis, Galen was able to diagnose the level of the injury by observing the paralyzed muscles and the area of sensational loss.

Galen already had a good knowledge of neurological topography

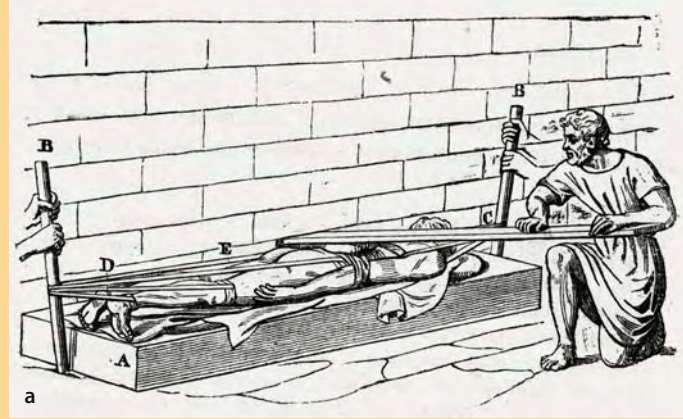




**Figure 10. Spinal trauma**

a Hippocates' Traction Table by E. Littré, who published the whole work of Hippocrates of Cos in the first half of the 19th century. b Hippocrates' Traction Table modified by Oribarius (325–400 A.D.) depicted in the surgical textbook of Guido Guidi (1500–1569). c Sir Ludwig Guttmann (1899–1985).

## Spinal Injuries as a Socioeconomic Problem

The "railway spine" is a perfect example of the socioeconomic problems related to the spine

When the railways became popular in the first half of the 19th century, there were suddenly many patients claiming back pain and spinal injuries related to the use of the railway. Therefore, this phenomenon was called "railway spine". The medical textbook *On Railway and Other Injuries of the Nervous System* published by **John Erichsen** in 1866 was fully devoted to this subject [32].

There was great public and medical debate on railway spine and its enormous amount of compensation. This culminated for example in the medical advice of the Lancet Commission on the railway spine in 1862 [66]. At the end of the 19th century the "railway spine syndrome" fully disappeared as a real disease entity. The "**railway spine**" was epidemic between 1866 and 1880.

Harold Crowe coined the term "whiplash injury"

Another socioeconomic problem is the so-called whiplash injury, a traumatically caused cervical strain associated with rear-end collisions that leads to disability. The whiplash injury became epidemic with the increase in traffic accidents. The American surgeon **Harold Crowe** coined the term "**whiplash injury**" in 1928 [23].

## Traction Table and Laminectomy

Traction tables were first used for fracture treatment

Since antiquity and through the whole of the Middle Ages, there were different kinds of treatment for spinal injuries available. The first one was the Hippocrates traction table, a popular device for treating every kind of spinal deformity, luxation and spinal injury (Fig. 10a). The Greek physician **Oribasius** (325–400 A.D.) improved Hippocrates' traction table (Fig. 10b) by adding a cross bar, which could be used as a lever for treatment of fracture dislocation [91]. This technique was still recommended at the end of the Middle Ages, for example by the famous Italian surgeon **Guido Guidi** (1508–1569) in 1544. Another approach to treating spinal fractures was introduced by the Greek physician **Paulus of Aegina** (625–690 A.D.), who was trained at the Alexandrian school and was the last of the great Byzantian physicians. He seems to have performed the first laminectomies in cases in which the posterior elements were fractured and pushed into the cord [92].

Paulus of Aegina first performed successful laminectomies for spinal injuries

The next historical description of a successful laminectomy was given by the American surgeon **Alban Gilpin Smith** (1788–1869) [109]. He performed surgery on a young man who had progressive paresis after falling off a horse 2 years before. Despite poor operating conditions, the patient recovered from the operation and experienced a return of sensation in the lower extremities.

During the Middle Ages, there were few descriptions on treatment of spinal injuries, and mostly physicians recommended conservative procedures. The Italian surgeon and anatomist **Guglielmo da Saliceto** (1210–1277) suggested in his work *On Surgery* (*Cyrurgia*) reducing cervical spine dislocation by manual traction on the extended head and then applying supportive braces and bandages [27]. The French surgeon **Guy de Chauliac** (1300–1368) is remembered as the father of surgery. He suggested in his profound work "*Surgery*" (*Ars Chirurgica*), which was based on Arabic physicians (such as Albucasis [936–1013] or Avicenna [981–1037]) and Galen, to "not labour to cure" in the case of spinal fracture [26].

## The Advent of Internal Spinal Fixation

Ambroise Paré reintroduced surgery for spinal cord injuries

**Ambroise Paré** (1510–1590), the famous French surgeon, reintroduced the surgical approach to spinal cord injuries [79].

In 1646, **Guilhelmus Fabricus Hildanus** (1560–1634) described his attempts to replace fracture dislocation of the neck by means of clamping the soft tissues and spinous processes with large forceps [56]. In 1829, **Alban Gilpin Smith** (1788–1869) succeeded in performing a laminectomy. Other surgeons failed, because the patients died soon afterwards.

Smith performed the first successful laminectomy in 1829

Brodie propagated conservative treatment for spinal cord injuries

After that date, there was a great debate on the necessity of "decompressive laminectomy" which still continues today. In 1836, the famous **Sir Benjamin Brodie** (1783–1862), who is also famous for his description of the so-called "Brodie abscess", propagated in his *Pathological and Surgical Observations Relating to Injuries of the Spinal Cord* conservative treatment with bed rest and intermittent catheterization [12].

The treatment of spinal cord lesions was promoted by the special experience of army surgeons treating battle casualties. A further important step in the treatment of spinal injuries was the evolvement of anesthesia and aseptic surgery in the second half of the 19th century. The discovery of X-rays by **William Conrad Roentgen** (1853–1923) in 1895 and their clinical application since 1896 has also played an important role. During World War I, there was a big advance in neurological diagnosis and assessment, but not in the treatment of spinal injuries. Most patients died after a few weeks from urogenital infections. With the advent of

In the early 20th century most patients died shortly after a spinal cord injury

Wilkins introduced internal fixation for spinal fractures

supportative techniques at the end of the 19th century, the American surgeon W.F. Wilkins (1848 – 1935) was able to perform the first successful internal fixation of the spine. In 1887, he fixed a dislocated T12/L1 fracture by using a carbolized silver wire [112].

Four years later, the former Silesian obstetrician **Berthold Earnest Hadra** (1842 – 1903) used a similar technique in a case of a C6 – C7 fracture of the cervical spine [43]. He just wired the spinous processes of C6 and C7 and reported that the result was successful. A great step forward in internal spine fixation was made when pedicle screw fixation was first introduced by **Raymond Roy-Camille** (1927 – 1994), appointed chief of orthopedics and traumatology at L'Hôpital de la Pitié-Salpétrière in 1963 [101, 102]. Another pioneer of spinal fixation is the Austrian surgeon **Friedrich Magerl**, who practiced at the Kantonspital in St. Gallen. He particularly contributed to the fixation techniques of the cervical spine (C1/2 screw fixation, lateral mass screw fixation, hock plate) and developed an external skeletal fixation system for the thoracolumbar spine which formed the basis for a new generation of angle-stable pedicular fixation systems [78].

Roy-Camille first introduced pedicle screw fixation

The first wheelchair for spinally injured patients was developed in 1930

The treatment of spinal injuries is not only based on surgical procedures, but also on non-operative care, which has significantly contributed to the increase in long-term survival. In 1930, the first wheelchair for patients suffering from spinal injury was developed and the focus of treatment slowly changed to rehabilitation, initiating spinal cord rehabilitation units.

Guttmann (1899 – 1985) first propagated rehabilitation for spinal cord injured patients

Since World War II and the early 1950s, major progress was made because of antibiotics and the great efforts of the neurosurgeon **Sir Ludwig Guttmann** (1899 – 1985), who was dedicated to the research and treatment of spinal cord injuries (Fig. 10c).

He propagated intensive rehabilitation and sports. He also wrote a profound and epoch-making textbook of spinal cord injuries in 1973 [44]. The death rate among spinal cord injured patients dramatically decreased as a result of these efforts. In World War I, 80 % of patients with spinal cord injuries died within the first 3 years, while in World War II this rate fell to about 7 %.

## Recapitulation

**Since the beginning of history**, there has been evidence of spinal disorders and related treatments. The **Edwin Smith Surgical Papyrus**, dating from the 16th century B.C., reported different spinal disorders such as spinal injuries, backache and back sprain. Spinal tuberculosis is older than written history.

**In antiquity**, the famous **Hippocrates of Cos** (460 – 370 B.C.) and his scholars wrote on spinal disorders and described tuberculous spondylitis, spinal injuries and other spinal deformities. Hippocrates also invented a long-lasting device, the **Hippocratic Traction Table**, which was used for nearly every spinal deformity. The Greek physician **Galen of Pergamon** (130 – 200 A.D.) preserved the Hippocratic knowledge of medicine and spinal disorders, respectively. Additionally, he coined the word "scoliosis" and performed experiments on the spinal cord, which led to a better understanding of the nervous system.

**At the end of antiquity**, the Greek physician **Paulus of Aegina** (625 – 690 A.D.) first performed successful laminectomies.

**The Middle Ages** were practically devoid of any major advancement in the treatment of spinal disorders.

**In the Renaissance**, the studies of **Andreas Vesalius** (1514 – 1564), the father of modern anatomy, led to a better understanding of spinal anatomy based on the publication of his pioneering anatomical textbook in 1543. The famous French surgeon **Ambroise Paré** (1510 – 1590) developed the first scoliosis brace, which was in use for nearly 500 years.

**In the Time of Enlightenment**, **Sir Percival Pott's** (1714 – 1788) description showed the relation of tuberculosis, paraplegia and spinal deformities, which was an epoch-making discovery, because there was a high prevalence of tuberculosis at that time. **Domeni-**

**co Cotugno** (1736–1822) first described the difference between real sciatica and pain caused by the hip and related structures in 1764. Inspired by the philosophical ideas of that time, new therapeutic regimes for spine disorders were proposed and propagated, e.g. with the self-help book for parents *L'Orthopédie* written by **Nicholas Andry** (1658–1742) in 1741 or the foundation of the world's first orthopedic hospital by Jean André Venel (1740–1791) in 1780.

**In the 19th century**, general anesthesia started in 1846 with **William Morton**. Antiseptic principles were introduced by **John Lister** and others. **William Conrad Roentgen** discovered the diagnostic relevance of X-rays in 1895. The first successful laminectomy in modern times was performed by **Alban Gilpin Smith** (1788–1869) in 1829. An even better understanding of the pathology of different spinal diseases was gained, for example in scoliosis.

**At the beginning of the 20th century**, **William Jason Mixter** (1880–1958) and **Joseph Seaton Barr** (1901–1963) discovered the link between disc herniation and sciatica (1934). This discovery boosted the surgical treatment of sciatica but also led to overtreatment of this entity. Therefore, this period is called the "**dynasty of the intervertebral disc**". The Dutch neurosurgeon **Henk Verbiest** (1909–1997) clearly defined the clinical entity of a narrow spinal canal and popularized claudication symptoms in 1954. **Sir Ludwig Guttmann** (1899–1985) propagated a better treatment based on rehabilitation and sports activities for the spinally injured, which dramatically decreased mortality. Since the 1970s, the advent of new generation **spinal instrumentation devices** and **imaging modalities** has significantly improved the treatment of spinal disorders.

**Appendix:** History of spinal disorders

| Time | Surgical procedures | Non-surgical procedures | Diagnostic modalities and other special facts |
|---|---|---|---|
| 1550 B.C. | | | First description of spinal disorders in the *Edwin Smith Surgical Papyrus* |
| 5th century B.C. | | Hippocratic Traction Table | |
| 7th century A.D. | First laminectomies performed by Paulus of Aegina | | |
| 1543 | | | First accurate description of the spine by Vesalius |
| 16th century | | Ambroise Paré first developed a scoliosis brace | |
| 1664 | | | First picture of a scoliotic spine published by Hildanus |
| 1741 | | | Nicholas Andry published his textbook L'Orthopédie |
| 1776 | | | Domenico Cotugno first differentiated between a sciatica caused and a hip caused back pain |
| 1779 | | | Potts first recognized the link between tuberculosis, kyphosis, abscess and paraplegia |
| 1780 | | Venel founded the world's first orthopedic hospital in Orbe, Switzerland | |
| 1782 | | | First description of spondylolisthesis by Herbiniaux |
| 1803 | | | Portal first described spinal stenosis |
| 1828 | First successful laminectomy in modern times performed by Alban Gilpin Smith | | |
| 1846 | | | Anesthesia gained popularity after the public operation by Morton in Boston |

**Appendix:** (*Cont.*)

| Time | Surgical procedures | Non-surgical procedures | Diagnostic modalities and other special facts |
|---|---|---|---|
| 1858 | | | Concise description of disc protrusion by Luschka |
| 1866–1880 | | | Epidemic of the "railway spine" syndrome |
| 1891 | First internal fixation of a C6/C7 fracture by Hadra | | |
| 1895 | | | Roentgen discovered X-rays |
| 1898 | | | First lumbar anesthesia by Bier |
| 1900 | First posterior fusion of C1/C2 by Pilcher | | |
| 1908 | First report of a disc prolapse operation performed by Krause and Oppenheim | | |
| 1909 | Stabilization of tuberculous spine by internal skeletal fixation performed by Lange | | |
| 1911 | First lumbar spinal fusion performed by Albee | | |
| 1921 | | | First description of Scheuermann's disease by Scheuermann |
| 1928 | | | First description of the "whiplash injury" by Crowe |
| 1929 | | | Discovery of penicillin by Fleming |
| 1933 | | | The term "facet syndrome" coined by Ghormley |
| 1933 | First anterior interbody fusion performed by Burns | | |
| 1934 | | | Publication of the epoch-making article of Mixter and Barr about the pathophysiology of protruded disc and its clinical correlation |
| 1935 | | | Introduction of the measurement of Cobb by Lipmann |
| 1944 | First posterior interbody fusion performed by Briggs and Milligan | | |
| 1945 | | Milwaukee brace invented by Blount | |
| 1956 | | Treatment of spinal tuberculosis with antibiotics suggested by Mukopadhaya | |
| 1962 | Harrington instrumentation | | |
| 1963 | Introduction of pedicle screws by Roy-Camille | | |
| 1964 | Chemonucleolysis invented by Lyman Smith | | |
| 1972 | | | First CT image of the brain |
| 1977 | Introduction of external spinal fixation by Magerl | | |
| 1979 | | | First MR image of the brain |
| 1982 | First artificial disc invented by Buttner and Shellnack | | |
| 1984 | Cotrel-Dubousset instrumentation | | |

## Key Articles

**Breasted JH (1930) Edwin Smith Surgical Papyrus, in Facsimile and Hieroglyphic Transliteration and with Translation and Commentary, 2 Vols. Chicago: University of Chicago Oriental Publications**
*The Edwin Smith Surgical Papyrus* edited by the American Egyptologist Henry Breasted encompasses different cases of spinal disorders. This medical text was probably written at the beginning of the New Kingdom of Ancient Egypt (around 1550 – 1500 B.C.). Therefore, these descriptions represent the earliest written witnesses of spinal disorders and its treatment in history.

**Luschka H (1858) Die Halbgelenke des menschlichen Körpers. Eine Monographie. Berlin: Reimer**
*The Half Joints of the Human Body* is a very important anatomical monograph written by the German pathologist Hubert von Luschka (1820 – 1875) in 1858.
In this monograph, there are detailed and concise descriptions and illustrations of protruded discs [64]. Luschka supposed that the disc protrusions were caused by a tumor like cartilage outgrowth of the nucleus pulposus and called such protrusions anomalies of intervertebral discs.

**Cotunnius D (1764) De ischiade nervosa commentarius. Naples: Typographia Simoniana**
Another milestone of spinal surgery is represented by *De ischiade nervosa commentaries* written by the Italian physician Domenico Felice Antonio Cotugno (1736 – 1822) in 1764. This work encompasses for the first time in medical history a concise and precise differentiation of hip or lower back derived back pain. Cotugno's descriptions are very accurate and so he was already able to distinguish a L5 radiculopathy from a L3/4 radiculopathy. Thus, he became the first to describe the lumboradicular syndrome.

**Pott P (1779) Remarks on that kind of the lower limbs, which is frequently found to accompany a curvature of the spine, and is supposed to be caused by it. London: J. Johnson**
This paper represents a further remarkable text on spinal surgery in respect to history. This medical text was published by the English surgeon Sir Percival Pott (1714 – 1788) in 1779. In this work, he described the tuberculous paraplegia and considered the tuberculous nature of the disease.

**Mixter WJ, Barr JS (1934) Rupture of the intervertebral disc with involvement of the spinal canal. N Engl J Med 211:210 – 215**
This landmark paper is a key to the pathophysiology of the lumbar disc protrusion and the correlation to sciatica.

**Harrington PR (1962) Treatment of scoliosis and internal fixation by spine instrumentation. J Bone Jt Surg Am 44:591 – 610**
Paul R. Harrington (1911 – 1980) has popularized spinal internal instrumentation for scoliosis. In this article, the Harrington spinal instrumentation system, a method of spine curvature correction by means of a metal system of hooks and rods, is for the first time extensively described. Harrington developed this surgical procedure after a poliomyelitis epidemic, where thousands of people were affected. This article is a milestone in spinal surgery because of the introduction of internal spinal instrumentation for deformity surgery.

## References


1. Albee FH (1911) Transplantation of a portion of the tibia into the spine for Pott's disease. JAMA 57:885
2. Andrea R (1929) Über Knorpelknötchen am hinteren Ende im Bereiche des Spinalkanals. Beitr Pathol Anat 82:464 – 474
3. Andry N (1741) L'Orthopédie ou l'Art de prévenir et de corriger dans les Enfants les difformités du corps: les Tout par des moyens a la portée des Pères et des Mères, et de toutes les Personnes, qui ont des Enfants a élever. 2 vols. Paris: La veuve Alix, Lambert et Durant
4. Benini A (1986) Ischias ohne Bandscheibenvorfall: Die Stenose des lumbalen Wirbelkanals. Bern: Verlag Hans Huber
5. Bier AKG (1899) Versuche über Cocainisierung des Rückenmarks. Dtsch Z Chir 51:361 – 369
6. Blasius G (1666) Anatome Medullae Spinalis et Nervorum indeprovenientium. Amsterdam
7. Blount WP, Schmidt AC, Bidnell RG (1958) Making the Milwaukee Brace. J Bone Jt Surg Am 4:523 – 530
8. Borelli GA (1680) De Motu Animalium. Angeli Bernabo, Rome
9. Bouvier H (1858) Leçons cliniques sur les maladies chroniques de l'appareil locomoteur. Paris: JB Bailliere
10. Breasted JH (1930) Edwin Smith Surgical Papyrus, in Facsimile and Hieroglyphic Transliteration and with Translation and Commentary, 2 vols. Chicago: University of Chicago Oriental Publications
11. Briggs H, Milligan PR (1944) Chip fusion of the low back following exploration of the spinal canal. J Bone Joint Surg 26:125 – 130
12. Brodie B (1836) Pathological and surgical observations relating to injuries of the spinal cord. Medical Chirurgical Transactions 20:158 – 164
13. Brown T (1828) On irritation of the spinal nerves. Glasgow Med J 1:131 – 160
14. Burns BH (1933) An operation for spondylolisthesis. Lancet 1:1233
15. Buttner-Janz K, Schellnak K, Zippel H (1988) Experience and results with SB Charite lumbar intervertebral prosthesis. Klin Med 43(20):3 – 7
16. Calot F (1896) Des moyens de guérir la bosse du mal de Pott du moyen de la prévenir (compte rendu dùne communication faite à l'Académie de Médecine le 22 décembre 1896). La france medicale no. 52:839 – 840
17. Caspar W (1977) A new surgical procedure for lumbar disc herniation causing less tissue damage through a microsurgical approach. Adv Neurosurg 4:74 – 80
18. Choy J, Ascher PW (1989) Percutaneous laser decompression of intervertebral discs. Lasers Med Surg News
19. Cobb J (1948) Outline for the study of scoliosis, AAOS Instructional course, vol. 5:261 – 275
20. Connor B (1693) Lettre écrite à Monsieur le chevalier Guillaume de Waldegrave, premier médecin de sa Majesté Britannique, Paris
21. Cotunnius D (1764) De ischiade nervosa comentarius. Neapel: Typographia Simoniana
22. Cotrel Y, Dubousset J (1984) Nouvelle technique d'osteosynthese rachidienne segmentoire par vol posterieure. Rev Chir Orthop 70:489 – 494
23. Crowe H (1928) Injuries to the cervical spine, paper presented at the meeting of the Western Orthopaedic Association, San Francisco
24. Dandy WE (1918) Ventriculography following the injection of air into cerebral ventricles. Ann Surg 68:5 – 11
25. Dandy WE (1929) Loose cartilage from the intervertebral disc simulating tumor of the spinal cord. Arch Surg 68:5 – 11
26. de Chauliac G (1923) Ars Chirurgica, Venice, Juntas, 1546, "On wounds and fractures", trans. by WA Brennan
27. de Saliceto Guglielmo, Chirurgie de Guillaume de Salicet. Achevée en 1275, Traduction et commentaire par Paul Pifteau. Toulouse: Imprimerie Saint-Cyprien, 1898
28. Delachamps J (1573) Chirurgie Françoise, Lyon
29. Delpech JM (1828) De l'orthomorphie, Paris
30. Dionis P (1707) Cours d' operation de chirurgie, Paris
31. Dwyer AF, Newton NC, Sherwood AA (1969) An anterior approach to scoliosis. A preliminary report. Clin Orthop 62:192 – 202
32. Erichsen JE (1866) On railway and other injuries of the nervous system. Six lectures on certain obscure injuries of the nervous system commonly met with as a result of shock to the body received in collisions in railways. London: Walton & Maberley
33. Fagge CH (1877) A case of simple synostosis of the ribs to the vertebrae, and of the arches and the articular processes of the vertebrae themselves, and also of one hip-joint. Transactions of the Pathological Society of London 28:201 – 206
34. Fernström U (1966) Arthroplasty with intercorporal endoprosthesis in herniated disc and in painful disc. Acta Orthop Scand Suppl 10:287 – 9

35. Fraenkel E (1903/4) Über chronische ankylosierende Wirbelsäulenversteifung. Fortschr Röntgenstr 11:117
36. Galen (1830) Definitiones medicae. Opera omnia. Vol. XIX
37. Geraud (1753) Observations sur un coup de feu à l'épine. Mem. de laced. Roy De Chirur 2: 515 – 517
38. Ghormley RK (1933) Low back pain, with special reference to the articular facets with presentation of an operative procedure JAMA 101:1773 – 1777
39. Glisson F (1650) De rachitide, sive morbo puerili, qui vulgo The Rickets dicitur Tractatus, London
40. Goldthwait JE (1911) The lumbo-sacral articulation. An explanation of many cases of lumbago, sciatica and paraplegia. Boston Med Surg J 164:365 – 372
41. Guérin J (1839) Traité des deviations laterals de l'épine par myotomie rachidienne. Paris
42. Guidi G (1544) Chirurgia è Graeco in Latinum conuersa
43. Haak W, Gruber P et al. (2005) Molecular evidence of HLA B27 in a historic case of ankylosing spondylitis. JAR 25(10):3318 – 3319
44. Guttmann L (1973) Spinal cord injuries. Oxford: Blackwell
45. Hadra BE (1891) Wiring the spinous processes in Pott's disease. Trans Am Orthop Assoc 4: 206 – 210
46. Harmon P (1960) Anterior extraperitoneal lumbar disc excision and vertebral body fusion. Clin Orthop 18:169 – 198
47. Harrington PR (1962) The treatment of scoliosis. J Bone Jt Surg Am 44:591 – 610
48. Harrington PR, Dickson JH (1976) Spinal instrumentation in the treatment of severe spondylolisthesis. Clin Orthop 117:157 – 163
49. Heister L (1719) Chirurgie, Nürnberg, 1779
50. Heister L (1768) A general system of surgery in 3 parts, containing the doctrine and management of wound fractures, luxations, tumours and ulcers of all kinds, London: J Whiston, L Davis, et al.
51. Henschen F (1962) Sjukdomarnas historia och geografi, Stockholm, Albers Bonniers Forläg. English trans. by Tate J. London: Longmans Green, 1966
52. Herbiniaux G (1782) Traite sur divers accouchemens laborieux et sur les polypes de la matrice. Brussels
53. Hibbs RA (1911) An operation for progressiv spinal deformities. NY Med J 93:1013
54. Hibbs RA (1924) A report of 59 cases of scoliosis treated by fusion operation. J Bone Jt Surg 6:3 – 37
55. Hijikata SA, Yamagishi M, Nakayama T, Oomori K (1975) Percutaneous discectomy, a new treatment method for lumbar disc herniation. J Toden Hosp 39:5 – 13
56. Hildanus FG (1646) Opera observationem et curationum Medico-Chirurgicarum quae extant omnia, Frankfurt
57. Hippokrates (1895 – 1900) Sämmtliche Werke. Translation into German and commentary by R. Fuchs. Lüneberg, Munich, 1895 – 1900
58. Hodgson AR, Stock FS (1956) Anterior spinal fusion. Br J Surg 44:266 – 75
59. Hyrtel J (1880) Onomatologica Anatomica, Geschichte und Kritik der anatomischen Sprache der Gegenwart. Georg Olms Verlag, Hildesheim New York, 1970
60. Humphries AW, Hawk WA, Berndt AL (1959) Anterior fusion of the lumbar spine using an internal fixation device. J Bone Joint Surg (Am) 41a:371
61. Henkel JF (1829) Anleitung zum chirurgischen Verbande. Revised by J.C. Stark and newly revised by Dieffenbach, Berlin, pp 425
62. James R (1745) Fractures of vertebrae in "A medical dictionary including physic, surgery, anatomy, chemistry and botany in all their branches relative to medicine". London: T. Osborne, Vol. 2
63. Jenkins JA (1936) Spondylolisthesis. Br J Surg 24:80
64. Kilian HF (1854) Schilderung neuer Beckenformen und ihres Verhalten im Leben. Mannheim: Bassermann and Mathy
65. Konstam PG, Konstam ST (1958) Spinal tuberculosis in Southern Nigeria. JBJS 40B:26 – 32
66. Lancet Commission (1862) The influence of railway travelling on public health. Lancet: 15 – 19, 48 – 53, 79 – 84
67. Lane A (1893) Case of spondylolisthesis associated with progressive paraplegia; laminectomy. Lancet 1:991
68. Lane JD, Moore ES (1948) Transperitoneal approach to the intervertebral disc in the lumbar area. Am Surg 127:537
69. Lange F (1910) Support for the spondylitic spine by means of buried steel bars, attached to the vertebrae. Am J Orthop Surg 8:344 – 361
70. Lister J (1866) On the antiseptic principle in surgery. Lancet 2:353
71. Lister J (1867) On the antiseptic principle in the practice of surgery. Br Med J 2:246
72. Littré E (1844) Oeuvres complete d'Hippocrate. Tome quatrième. Paris: J-B Baillière, 1884
73. Love JG (1939) Removal of intervertebral discs without laminectomy. Proceedings of staff meeting. Mayo Clin 14:800

74. Luque ER (1982) The anatomic basis and development of segmental spinal instrumentation. Spine 7:256 – 259
75. Luschka H (1858) Die Halbgelenke des menschlichen Körpers. Eine Monographie. Berlin: Reimer
76. Lyons PMJ (1831/32) Remarkable case of pure general anchylosis. Lancet 1:27 – 29
77. Macnab I (1977) Backache, Baltimore: Williams & Wilkins, 1977
78. Magerl F (1982) External skeletal fixation of the lower thoracic and upper lumbar spine: current concepts of external fixation of fractures. Berlin: Springer-Verlag
79. Malgaigne JF (1840) Oeuvres completes d'Ambroise Paré, Paris
80. Marie P (1898) Sur la spondylose rhizomélique. Revue de Médecine 18:285 – 315
81. Massare C (1979) Anatomo-radiologie et vérité historique a propos du bilan xéroradiographique de Ramsès II. Bruxelles Med 59:163 – 170
82. Medical Research Council (1978) Five-year assessments of controlled trials of ambulatory treatment, debridement and anterior spinal fusion in the management of tuberculosis of the spine. JBJS 60B:163 – 177
83. Ménard V (1894) Causes de paraplégie dans le mal de Pott. Son traitement chirurgical par ouvertures directe du foyer tuberculeux des vertebras. Rev Orthop 5:47
84. Méry J (1706) Observations faites sur un squelet dune jeune femme âgée de 16 ans, mort à l'Hôtel-Dieu de Paris, le 22 février. Hist Acad Roy Sci Paris, pp 472, 480
85. Middleton GE, Teacher JH (1911) Injury of the spinal cord due to rupture of an intevertebral disc during muscular effort. Glasgow Med J 76:1 – 6
86. Mixter WJ, Barr JS (1934) Rupture of the intevertebral disc with involvement of the spinal canal. N Engl J Med 211:210 – 215
87. Mooney V, Robertson J (1976) The facet syndrome. Clin Orthop 115:149 – 156
88. Mukopadhahya B (1958) The role of excisional surgery in the treatment of bone and joint tuberculosis. Ann Roy Coll Surg Engl 18:288 – 313
89. Neugebauer FL (1882) A new contribution to the history and aetiology of spondylolisthesis, reprinted in London: New Sydenham Society and published in Clin Orthop Rel Res 117:2
90. Oppenheim H, Krause F (1909) Über Einklemmung bzw. Strangulation der Cauda equina. Dtsch Med Wochenschr 35:697 – 700
91. Oribasius (1862) Oeuvres d' Oribase, vol. 4., Paris: Darenberg Edition
92. Paulus of Aegina (1844 – 1847) Seven Books of Paulus of Aegina translated by Adams F. London: Sydenham Society
93. Portal A (1803) Cours d'Anatomie Médicale ou Eléments de l' Anatomie de l'homme, vol. 1, Paris: Baudovin
94. Pott P (1783) The Chirurgical Works of Percivall Pott, 3 vols. London
95. Pott P (1779) Remarks on that kind of the lower limbs, which is frequently found to accompany a curvature of the spine, and is supposed to be caused by it. London: J. Johnson
96. Putti V (1927) New conception in the pathogenesis of sciatic pain. Lancet 2:53 – 60
97. Putti V (1936) Lomboartrite e sciatica Vertebrale. Saggio Clinico. Bologna: Cappelli
98. Risser JC (1958) The iliac apophysis. Clin Orthop Rel Res 11:111
99. Roentgen WC (1895) Über eine neue Art von Strahlen. Sitzber Physik Med Ges Würzburg:24 – 132
100. Rotkitansky C (1842) Handbuch der pathologischen Anatomie. Vienna: Braumüller und Seidel
101. Roy-Camille R, Roy-Camille M, Demeulenaere C (1970) Osteosynthesis of dorsal, lumbar, and lumbosacral spine with metallic plates screwed into vertebral pedicles and articular apophyses, Presse Med 78:1447 – 1448
102. Roy-Camille R, Saillant G, Mazel C (1986) Internal fixation of the lumbar spine with pedicle screw plating. Clin Orthop 203:7 – 17
103. Ruffer MA (1918) Arthritis deformans and spondylitis in ancient Egypt. J Pathol Bacteriol 22:212 – 226
104. Ruffer MA (1910) Pott'sche Krankheit an einer ägyptischen Mumie aus der Zeit der 21. Dynastie. Zur historischen Biologie der Krankheitsereger, 3 Heft, Giessen
105. Scheuermann HW (1921) Kyphosis dorsalis juvenalis (trans by Dr. Hirsch). Z Orthop Chir 51:305 – 317
106. Schmorl CG (1932) Die gesunde und kranke Wirbelsäule im Röntgenbild. Leipzig, Thieme
107. Schulthess W (1887) Ein neuer Zeichnungsappart für Rückgratsverkrümmungen. Centralbl Orthop Chir 4:25 – 44
108. Schulthess W (1905 – 1907) Die Pathologie und Therapie der Rückgratsverkümmung. In: Handbuch der Chirurgie (Georg Joachimstal, ed.) Jena: Gustav Fischer, 1905 – 1907
109. Smith AG (1829) Account of case in which portions of three dorsal vertebrae were removed for the relief of paralysis from fracture, with partial success. North American Medical and Surgical Journal 8:94 – 97
110. Smith L (1964) Enzyme dissolution of nucleus pulposus in humans. JAMA 187:137 – 140
111. Subramanian K (1979) Srimad Bhagavatam. Bombay: Bharatiya Vidya Bhavan

112. Travers B (1824) Curious case of anchylosis of great part of the vertebral column, probably produced by an ossification of the intervertebral substance. Lancet 5:254
113. Venel JA (1789) Description de plusieurs nouveaux moyens mécaniques, proper à preévenir, borner et meme corriger, dans certains cas, les courbures laterals et la torsin de l'épine du dos. Histoire et mémoires de la Société des sciences physiques de Lausanne, 1: 66, 2: 197 – 207 (separate edition by Lausanne: J. Mourer, 1788)
114. Verbiest H (1954) A radicular syndrome from development narrowing of the lumbar vertebral canal. J Bone Joint Surg 36A:230
115. Verbiest H (1955) Further experiences on the pathological influence of a developmental narrowness of the bony lumbar vertebral canal. J Bone Joint Surg 37-B:576
116. Vesalius A (1543) De Humani Corporis Fabrica Liberi Septum, Basel: Ex officina Ionnis Oporini
117. von Bechterew W (1893) Steifigkeit der Wirbelsäule und ihre Verkrümmung als besondere Erkrankungsform, Neurologisches Zentralblatt 12:426 – 434
118. Waddle G (1987) A new clinical method for the treatment of low back pain. Spine 12:632 – 644
119. Weber J et al. (2004) Lumbar spine fracture in a 34 000 year-old skeleton: The oldest known prehistoric spine fracture. Neurosurgery 55:705 – 707
120. Wenger PR, Frick SL (1999) Scheuermann Kyphosis. Spine 24:2630 – 2639
121. Weitbrecht J (1742) Syndesmologia sive historia ligamentorum corporis humanis. St. Petersburg: Akademie der Wissenschaft
122. Wilkins WF (1888) Separation of vertebrae with protrusion of hernia between same-operation cure. St. Louis Med Surg J 54:340 – 341
123. Williams RW (1979) Microsurgical lumbar discectomy. Report to American Association of Neurology and Surgery, 1975. Neurosurgery 4(2):140
124. Wiltse LL, Newman PH, Macnab I (1976) Classification of spondylolysis and spondylolisthesis. Clin Orthop 117:23

# 2 Biomechanics of the Spine

Stephen Ferguson

## Core Messages

- ✔ The main functions of the spine are to protect the spinal cord, to provide mobility to the trunk and to transfer loads from the head and trunk to the pelvis
- ✔ The trabecular bone bears the majority of the vertical compressive loads
- ✔ The vertebral endplate plays an important role in mechanical load transfer and the transport of nutrients
- ✔ Axial disc loads are borne by hydrostatic pressurization of the nucleus pulposus, resisted by circumferential stresses in the anulus fibrosus
- ✔ Approximately 10–20% of the total fluid volume of the disc is exchanged daily
- ✔ Combined axial compression, flexion and lateral bending have been shown to cause disc prolapse
- ✔ The facet joints guide and limit intersegmental motion
- ✔ The ligaments surrounding the spine guide segmental motion and contribute to the intrinsic stability of the spine by limiting excessive motion
- ✔ The spatial distribution of muscles determines their function. Changes to segmental laxity ("neutral zone") are associated with trauma and degeneration
- ✔ The highest loads on the spine are produced during lifting

## The Human Spine

The human spinal column is a complex structure composed of 24 individual vertebrae plus the sacrum. The principal functions of the spine are to protect the spinal cord, to provide mobility to the trunk and to transfer loads from the head and trunk to the pelvis. By nature of a natural sagittal curvature and the relatively **flexible intervertebral discs** interposed between **semi-rigid vertebrae**, the spinal column is a compliant structure which can filter out shock and vibrations before they reach the brain. The intrinsic, passive stability of the spine is provided by the discs and surrounding ligamentous structures, and supplemented by the actions of the spinal muscles. The **seven intervertebral ligaments** which span each pair of adjacent vertebrae and the two synovial joints on each vertebra (facets or zygapophyseal joints) allow controlled, fully three-dimensional motion.

The main functions are to protect the spinal cord, provide mobility and transfer loads

The spine can be divided into **four distinct regions**: cervical, thoracic, lumbar and sacral. The cervical and lumbar spine are of greatest interest clinically, due to the substantial loading and mobility of these regions and associated high incidence of trauma and degeneration. The thoracic spine forms an integral part of the ribcage and is much less mobile due to the inherent stiffness of this structure. The sacral coccygeal region is formed by nine fused vertebrae, and articulates with the left and right ilia at the sacroiliac joints to form the pelvis.

The spine can be divided into four distinct regions

## The Motion Segment

The functional spinal unit is the smallest spine segment that exhibits the typical mechanical characteristics of the entire spine

The motion segment, or **functional spinal unit**, comprises two adjacent vertebrae and the intervening soft tissues. With the exception of the C1 and C2 levels, each motion segment consists of an anterior structure, forming the vertebral column, and a complex set of posterior and lateral structures. The C1 (atlas) and C2 (axis) vertebrae, in contrast, have a highly specialized geometry which allows for an extremely wide range of motion at the junction of the head and neck (see Chapter 30). The **neural arch**, consisting of the pedicles and laminae, together with the vertebral body posterior wall form the spinal canal, a structurally significant protective structure around the spinal cord. The transverse and spinous processes provide attachment points for the **skeletal muscles**, while the right and left superior and inferior articular processes of the **facet joints** form natural kinematic constraints for the guidance of spinal intersegmental motion.

## Anterior Structures

### The Vertebral Body

The trabecular bone bears the majority of the vertical compressive loads

The **principal biomechanical function** of the vertebral body is to support the compressive loads of the spine due to body weight and muscle forces. Correspondingly, vertebral body dimensions increase from the cervical to lumbar region. The architecture of the vertebral body comprises highly porous trabecular bone, but also a fairly dense and solid shell (Fig. 1). The shell is very thin throughout, on average only 0.35–0.5 mm [82]. The **trabecular bone** bears the

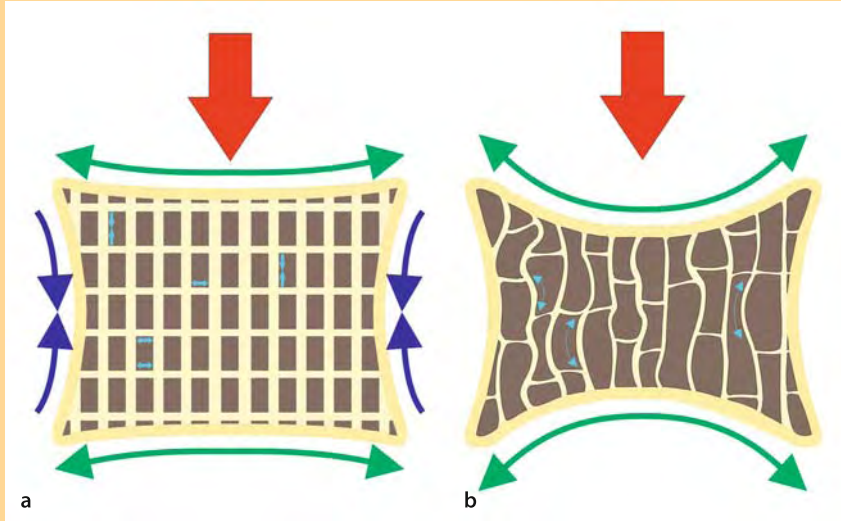


**Figure 1. Vertebral body architecture and load transfer**

a In the healthy vertebral body, the majority of trabeculae are oriented in the principal direction of compressive loading, with horizontal trabeculae linking and reinforcing the vertical trabecular columns. b With advancing osteoporosis, the thickness of individual trabeculae decreases and there is a net loss of horizontal connectivity. The consequences are an increased tendency for individual vertical trabeculae to buckle and collapse under compressive load, as the critical load for buckling of a slender column is proportional to the cross-sectional area of the column and the stiffness of the material and inversely proportional to the square of the unsupported length of the column. Therefore, architectural remodelings which lead to a loss of horizontal connecting trabeculae are perhaps the most critical age-related changes to the vertebral body.

majority of the vertical compressive loads, while the outer shell forms a reinforced structure which additionally resists torsion and shear. Previous analysis of load sharing in the vertebral body has shown that the removal of the **cortex** decreases vertebral strength by only 10% [52]. However, more recent computational analyses have proposed that the cortex and trabecular core share compressive loading in an interdependent manner. The predominant orientation of individual trabeculae is vertical, in line with the principal loading direction, while adjoining horizontal trabeculae stabilize the vertical trabecular columns. Bone loss associated with aging can lead to a loss of these horizontal tie elements, which increases the effective length of the vertical structures and can facilitate the failure of individual trabeculae by buckling.

Removal of the cortex decreases vertebral strength by only 10%

The **vertebral endplate** forms a structural boundary between the intervertebral disc and the cancellous core of the vertebral body. Comprising a thin layer of semi-porous subchondral bone, approximately 0.5 mm thick, the **principal functions** of the endplate are to prevent extrusion of the disc into the porous vertebral body, and to evenly distribute load to the vertebral body. With its dense cartilage layer, the endplate also serves as a **semi-permeable membrane**, which allows the transfer of water and solutes but prevents the loss of large proteoglycan molecules from the disc. The local material properties of the endplate demonstrate a significant spatial dependence [33]. The vertebral endplate and underlying trabecular bone together form a non-rigid system which demonstrates a significant deflection under compressive loading of up to 0.5 mm [16].

The vertebral endplate is important for mechanical load transfer and nutrient transport

The endplate has been shown to be the weak link in maintaining vertebral body integrity, especially with decreasing bone density, as the heterogeneity of endplate strength is even more pronounced [34]. High compressive loads lead to **endplate failure** due to pressurization of the nucleus pulposus. Nuclear material is often extruded into the adjacent vertebral body following fracture (Schmorl's nodes), thereby establishing a possible source of pain from increased intraosseous pressure [101].

The endplate is often the initial site of vertebral body failure

**Vertebral strengths** as measured from in vitro tests on cadaver specimens vary by an order of magnitude (0.8 – 15.0 kN) [38, 98] due to the natural variation in bone density, bone architecture and vertebral body geometry. A strong correlation has been demonstrated between quantitative volumetric bone density and vertebral strength [17]. Vertebral geometry and structure are equally important factors for the determination of vertebral strength [21]. The increase in vertebral strength caudally is mostly due to the increased vertebral body size, as bone density is fairly constant between individual vertebral levels. The **fatigue life** of vertebrae, the resistance to failure during repetitive loading, depends on the magnitude and duration of compressive loading. Brinckmann et al. [15] have documented in vitro measurements of the fatigue strength of vertebrae which provide valuable information for predicting fracture risks in vivo or specifying safe activity levels (Table 1).

Vertebral body geometry, bone density and architecture determine vertebral strength

**Table 1.** Fatigue strength of vertebrae

| Probability of failure<br>Load | Loading cycles | | | | |
|---|---|---|---|---|---|
| % VCS | 10 | 100 | 500 | 1 000 | 5 000 |
| 30 – 40% | 0% | 0% | 21% | 21% | 36% |
| 40 – 50% | 0 | 38 | 56 | 56 | 67 |
| 50 – 60% | 0 | 45 | 64 | 82 | 91 |
| 60 – 70% | 8 | 62 | 76 | 84 | 92 |

VCS signifies vertebral compressive strength; 5 000 cycles of loading is approximately equivalent to 2 weeks of athletic training

## The Intervertebral Disc

The disc consists of a gel-like nucleus surrounded by a fiber-reinforced anulus

The intervertebral disc is the **largest avascular structure** of the body. The disc transfers and distributes loading through the anterior column and limits motion of the intervertebral joint. The disc must withstand significant compressive loads from body weight and muscle activity, and bending and twisting forces generated over the full range of spinal mobility. The disc is a specialized structure with a heterogenous morphology consisting of an inner, **gelatinous nucleus pulposus** and an outer, **fibrous anulus**. The nucleus pulposus consists of a hydrophilic, **proteoglycan** rich gel in a loosely woven collagen gel. The nucleus is characterized by its ability to bind **water** and swell. The anulus fibrosus is a lamellar structure, consisting of 15–26 distinct concentric fibrocartilage layers with a criss-crossing fiber structure [50]. The **fiber orientation** alternates in successive layers, with fibers oriented at 30° from the mid-disc plane and 120° between adjacent fiber layers. From the outside of the anulus to the inside, the concentration of **Type I collagen** decreases and the concentration of **Type II collagen** increases [27], and consequently there is a regional variation in the mechanical properties of the anulus [12, 83].

Axial disc loads are borne by hydrostatic pressurization of the nucleus pulposus, resisted by circumferential stresses in the anulus fibrosus

The intervertebral disc is loaded in a complex combination of compression, bending, and torsion. Bending and torsion loads are resisted by the strong, oriented fiber bundles of the anulus. In the healthy disc, axial loads are borne by hydrostatic pressurization of the nucleus pulposus, resisted by circumferential stresses in the anulus fibrosus [62], analogous to the function of a pneumatic tyre (Fig. 2). Pressure within the nucleus is approximately 1.5 times the externally applied load per unit disc area. As the nucleus is incompressible, the **disc bulges** under load – approximately 1 mm for physiological loads [85] – and considerable tensile stresses are generated in the anulus. The stress in the anulus fibers is approximately 4–5 times the applied stress in the nucleus [31, 61, 62]. Anulus fibers elongate by up to 9% during torsional loading, still well below the ultimate elongation at failure of over 25% [84].

Approximately 10–20% of the disc's total fluid volume is exchanged daily, resembling a "pumping effect"

Compressive forces and pretension in the longitudinal ligaments and anulus are balanced by an **osmotic swelling pressure** in the nucleus pulposus, which is proportional to the concentration of the **hydrophilic proteoglycans** [93]. Proteoglycan content and disc hydration decreases with age due to degenerative processes. The intrinsic swelling pressure of the unloaded disc is approximately 10 N/cm$^2$, or 0.1 MPa [61]. As the applied force increases above this base level, disc hydration decreases as water is expressed from the disc [3, 49] and consequently the net concentration of proteoglycans increases. The rate of fluid expression is slow, due to the low intrinsic permeability of the disc [39]. A net daily fluid loss of approximately 10–20% has been observed in vivo and in vitro [49, 55]. Fluid lost during daily loading is regained overnight during rest, and it has been postulated that this **diurnal fluid exchange** is critical for disc nutrition [30].

Disc degeneration substantially alters load transfer

Disc degeneration have a profound effect on the mechanism of load transfer through the disc. With degeneration, dehydration of the disc leads to a lower elasticity and viscoelasticity. Loads are less evenly distributed, and the capacity of the disc to store and dissipate energy decreases. Using the technique of "**stress profilometry**", it has been shown that age-related changes to the disc composition result in a shift of load from the nucleus to the anulus [5, 6, 56].

Degeneration exposes the posterior anulus to a high failure risk

Therefore, structural changes in the anulus and endplate with degeneration may lead to a transfer of load from the nucleus to the **posterior anulus**, which may cause pain and also lead to annular rupture.

The mechanical response of the disc to complex loading has been well described. The response of the disc to compressive loading is characterized by

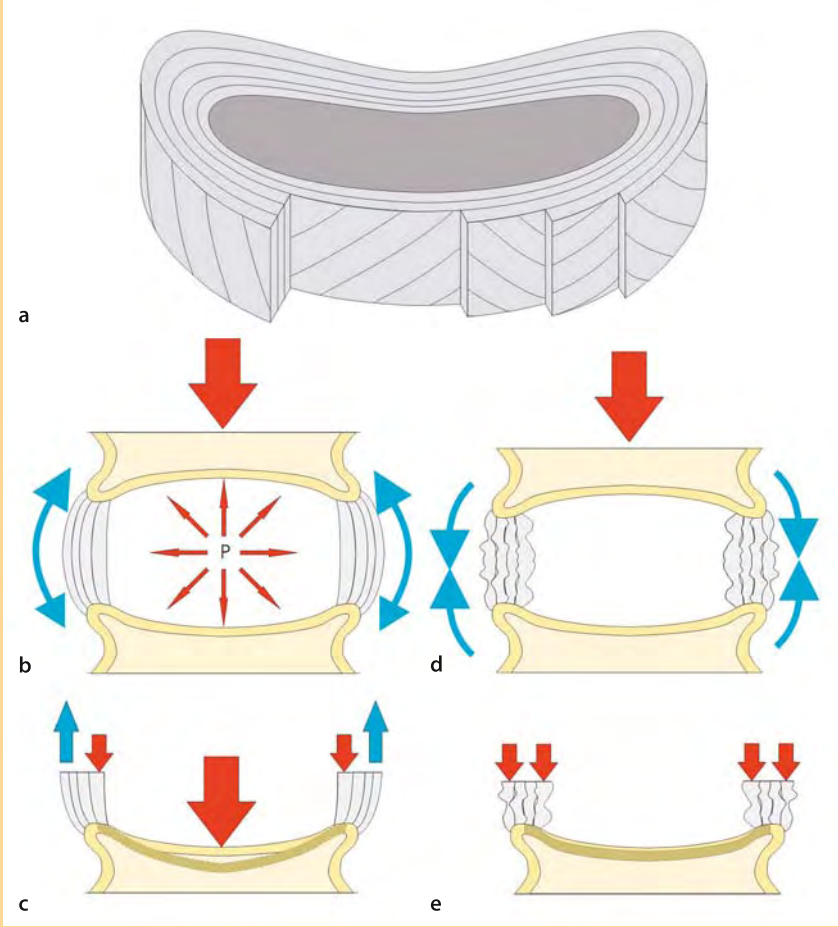


**Figure 2. Load transfer in normal and degenerated discs**

a The intervertebral disc consists of a gel-like nucleus surrounded by a fibrous anulus consisting of multiple concentric lamellae. b In the healthy disc (*left*), compressive loads create a hydrostatic pressure within the fluid nucleus, which is resisted by tensile stresses in the outer anulus. c Loads are transferred through the central portion of the vertebral endplate, causing substantial deflection of the endplate (up to 0.5 mm). d, e In the degenerated disc, the nucleus is dehydrated and compressive loads are transferred by compressive stresses in the anulus. This may lead to an inward bulge of the inner anulus, buckling of the lamellae and cleft formation. Endplate loading is reduced, as stresses are transferred through the stronger and stiffer outer endplate region.

flexibility at low loads and increasing stiffness at high loads [98]. Likewise, a highly non-linear response of disc to torsion has been demonstrated [28]. Very little torque is required for the first 0–3° of rotation, between 3° and 12° rotation there is a linear relationship between torque and rotation and failure of the anulus fibers occurs at a rotation of more than 20° rotation. Measurements of **internal disc displacements** during loading [80, 90] have shown a characteristic motion of the nucleus away from the direction of applied bending load (e.g. a posterior shift of the anulus during flexion).

The nucleus shifts depending on the loading direction

Nucleus pressurization and displacement results in heterogenous disc bulging. Posterior disc bulging is greatest during extension and least during flexion, which has implications for the most common disc injury, disc protrusion and prolapse. **Extrusion of nuclear material** through the anulus usually occurs in the **posterolateral direction** and can cause compression of the dura and/or nerve

Nucleus extrusion usually occurs posterolaterally

roots. It has been postulated that this is due to fatigue failure of inner anulus fibers [2, 4], as fissures in the anulus allow the expression of nuclear material under pressure. While pure compressive loading does not cause herniation, even at high loads and with deliberate anulus injury [95], combined axial compression, flexion and lateral bending have been shown to cause prolapse [1], loading conditions which result in a 50 % increase in posterior anulus deformation and a considerable increase in nuclear pressure.

Combined axial compression, flexion and lateral bending have been shown to cause disc prolapse

## Posterior Elements

The facet joints guide and limit intersegmental motion

The posterior elements guide the motion of the spinal segments and limit the extent of torsion and anterior-posterior shear. The transverse and spinous processes are the important attachment points for the ligaments and muscles which initiate spine motion and which are exceptionally important for stability [47]. The **orientation of the facet joints** is of key importance for guiding spinal kinematics. The three-dimensional orientation of the facets changes along the spine from cervical to sacral [70] (Table 2). **Facet asymmetry** is observed in approximately 25 % of the population [98] with an average asymmetry, or facet tropism, of 10° (maximum 42°). With tropism, compression and shear loading can lead to an induced rotation towards the more oblique facet [22].

Deformity of the facets or fracture of the pars interarticularis compromises segmental shear resistance

**Load sharing in the facet joints** can be measured directly [25, 46] or calculated with mechanical models [57, 81, 100]. In hyperextension, approximately 30 % of the load is transmitted through the facets. In an upright standing position, 10 – 20 % of the compressive load is carried by the facets. The facet joints resist more than 50 % of the anterior shear load in a forward flexed position, up to 2 000 N without failure [23]. If this capacity to resist shear is compromised (e.g. by genetic malformation of the facets, stress fractures of the pars interarticularis, facet trophism) an anterior slip of one vertebra relative to the adjacent vertebra can occur. **Isthmic spondylolisthesis** is most prevalent at L5–S1 and degenerative spondylolisthesis of L4–L5 has been associated with the predominantly sagittal orientation of the facets [36]. During torsion, the contralateral facet is heavily loaded. Facet joint pressure is also influenced by disc height: a 1-mm decrease in disc height results in a 36 % increase in facet pressure; a 4-mm decrease in disc height a 61 % increase in facet joint pressure [24]. Due to the innervation of the facet capsules, there is therefore the potential for disc degeneration to cause facet joint pain.

**Table 2.** Facet joint orientation and functional significance

| Spine region | Facet orientation | Consequence |
|---|---|---|
| C1–C2 | Parallel to transverse | Substantial rotation |
| Cervical | 45° to transverse<br>Parallel to frontal | Flexion, extension and rotation<br>Substantial motion coupling |
| Thoracic | 60° to transverse<br>20° to frontal | Lateral bending, rotation<br>Limited flexion and extension |
| Lumbar | 45° to frontal<br>Parallel to sagittal | Flexion, extension and lateral bending<br>Negligible rotation |
| Lumbosacral | Oblique | Substantial rotation |

Data derived from [70]

## Ligaments of the Spine

The ligaments guide segmental motion and contribute to the intrinsic stability by limiting excessive motion

The ligaments surrounding the spine guide segmental motion and contribute to the intrinsic stability of the spine by limiting excessive motion. There are two primary ligament systems in the spine, the intrasegmental and intersegmental systems. The **intrasegmental system** holds individual vertebrae together, and consists of the ligamentum flavum, facet capsule, and interspinous and intertransverse ligaments. The **intersegmental system** holds many vertebrae together and includes the anterior and posterior longitudinal ligaments, and the supraspinous ligaments. All ligaments except the ligamentum flavum have a high collagen content. The **ligamentum flavum**, connecting two adjacent neural arches, has a high elastin content, is always under tension and pre-stresses the disc even in the neutral position [26].

Ligament response to load is non-linear: initially flexible neutral zone and subsequent stiffening

The properties of lumbar ligaments have been most extensively studied (Table 3). **Tensile properties** have been reported for the ligamentum flavum [26], anterior longitudinal and posterior longitudinal [88], inter- and supraspinous [97] and intertransverse ligaments [20]. The response to tensile loading is typically non-linear, with an initial low stiffness **neutral zone**, an **elastic zone** with a linear relationship between load and displacement, followed by a plastic zone where permanent non-recoverable deformation of the ligament occurs. The neutral zone plus the elastic zone represent the physiological range of deformation. **Physiological strain levels** in ligaments have been determined by conducting in vitro tests on cadaveric specimens, using motion extents determined from radiographic in vivo measurements of spinal motion [69]:

- flexion: supraspinous, 30 %; interspinous, 27 %; posterior longitudinal, 13 %
- extension: anterior longitudinal, 13 %
- rotation: capsular ligaments, 17 %

The ligaments resist various spinal movements

The **functional role** of individual ligaments and the relative contribution of each to overall segmental stability can be determined in vitro by repetitive loading and sequential sectioning of individual anatomical structures [71]. During flexion, the ligamentum flavum, capsular ligaments and interspinous ligaments are highly strained. During extension, the anterior longitudinal ligament is loaded. During side bending, the contralateral transverse ligaments, the ligamentum flavum and the capsular ligaments are tensioned, whereas rotation is resisted by the capsular ligaments [69]. A larger relative distance between individual ligaments and the rotation center of the intervertebral joint corresponds with a greater stabilizing potential.

**Table 3.** Typical values for lumbar ligament strength and stiffness

| Ligament | Failure load (N) | Failure strain (% elongation) |
|---|---|---|
| Anterior longitudinal | 450 | 26 % |
| Posterior longitudinal | 324 | 26 % |
| Ligamentum flavum | 285 | 26 % |
| Interspinous | 125 | 13 % |
| Supraspinous | 150 | 32 % |

Data derived from [20, 98]

## Motion Segment Stiffness

Degenerations and injury alter spinal stiffness

In vitro testing of cadaveric specimens has been performed to determine the intrinsic functional stiffness of spinal motion segments. In general, the **functional stiffness** is adapted to the loading which each spine segment experiences. Degeneration and/or injury can have a significant influence on stiffness. Typical stiffness values are as follows [11, 54, 58, 68, 79]:

- cervical spine: lateral shear 33 N/mm, compression 1 317 N/mm
- thoracic spine: lateral shear 100 N/mm, anterior posterior shear 900 N/mm, compression 1 250 N/mm
- lumbar spine: shear 100 – 200 N/mm; compression 600 – 700 N/mm
- sacroiliac joint: shear, 100 – 300 N/mm

**Muscle forces** can significantly alter the mechanical response of the spine. Compressive preload leads to a significant stiffening of the spinal motion segment [40].

Posterior elements contribute significantly to overall segmental stiffness

At the sacroiliac joint, coordinated activity of the pelvic, trunk and hip muscles creates a medially oriented force which locks the articular surfaces of the sacroiliac joints and the pubic symphysis, stiffening the pelvis [96]. The posterior elements contribute significantly to the overall stiffness of the motion segment. **Removal of posterior elements** in sequential testing in vitro produced a 1.7 times increase in shear translation, a 2.1 times increase in bending displacement and a 2.7 times increase in torsion [54].

Trunk muscles stabilize the spine and redistribute loads

The spine is an elastic column, with enhanced stability due to the complex curvature of the spine (kyphosis and lordosis), the support of the longitudinal ligaments, the elasticity of the ligamentum flavum, and most importantly the active muscle forces. While cadaver spines have been shown to buckle with the application of very low vertical loads (20 – 40 N) [35], the **extrinsic support** provided by trunk muscles stabilizes and redistributes loading on the spine and allows the spine to withstand loads of several times body weight.

## Muscles

The spatial distribution of muscles determines their function

The spatial distribution of muscles generally determines their function. The trunk musculature can be divided functionally into extensors and flexors. The **main flexors** are the abdominal muscles (rectus abdominis, internal and external oblique, and transverse abdominal muscle) and the psoas muscles (Fig. 3).

The trunk musculature can be divided functionally into extensors and flexors

The **main extensors** are the sacrospinalis group, transversospinal group, and short back muscle group (Fig. 4). Symmetric contraction of extensor muscles produces extension of the spine, while asymmetric contraction induces lateral bending or twisting [8]. The most **superficial layer** of trunk muscles on the posterior and lateral walls are broad, connecting to the shoulder blades, head and upper extremities (rhomboids, latissimus dorsi, pectoralis, trapezius) (Fig. 5). Some lower trunk muscles connect to a strong superficial fascial sheet, the **lumbodorsal fascia**, which is a tensile-bearing structure attached to the upper borders of the pelvis (e.g. transversus abdominis) [13]. The iliopsoas muscle originates on the anterior aspect of the lumbar spine and passes over the hip joint to the inside of the femur. Vertebral muscle is composed of 50 – 60 % **type I muscle fibers**, the so-called "**slow twitch**", fatigue-resistant muscle fibers found in most postural muscles [9].

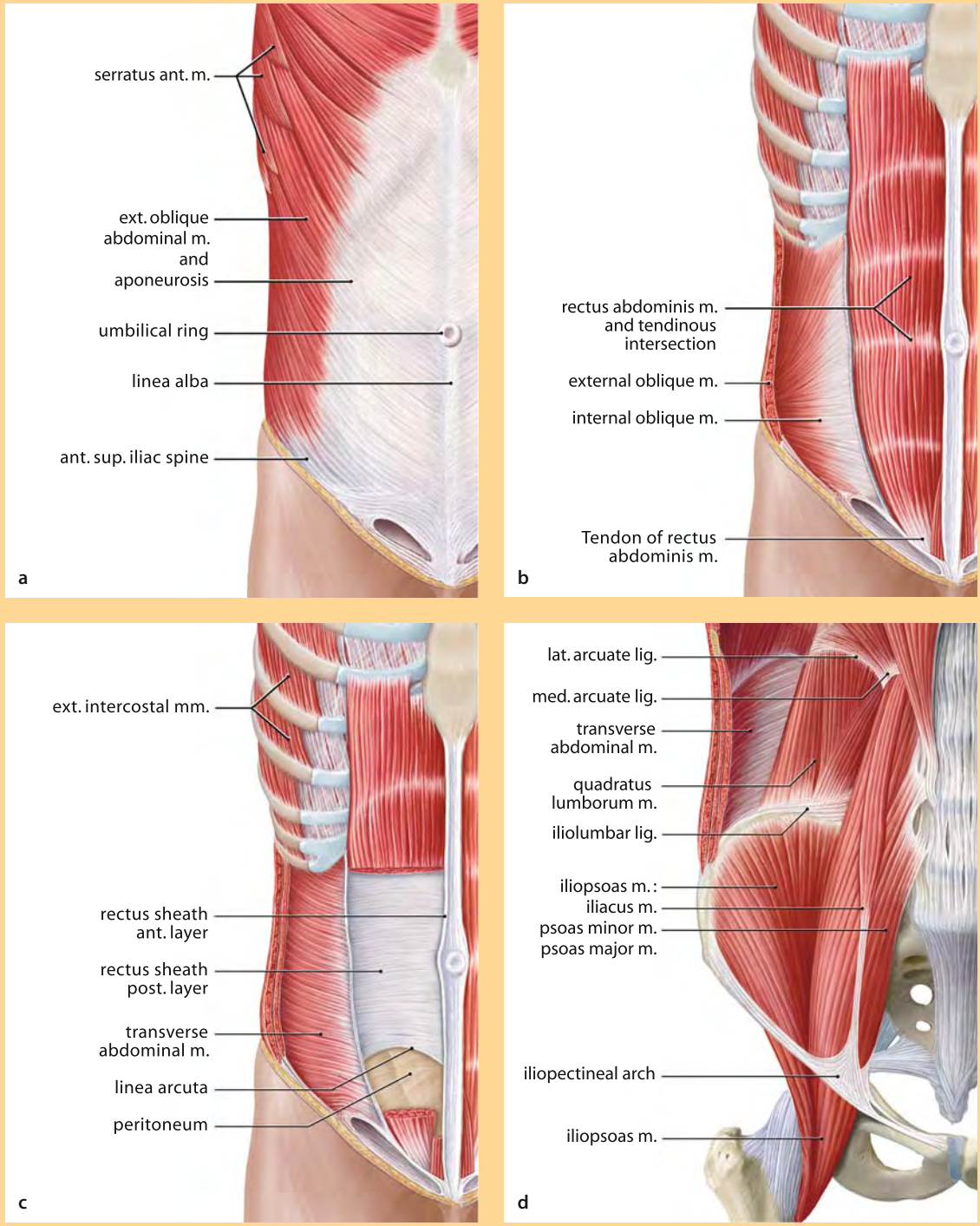


**Figure 3. Anterior spinal muscles**

a Abdominal muscles with a superficial layer, b intermediate layer, c deep layer. d The psoas muscle is an important stabilizer of the spine.

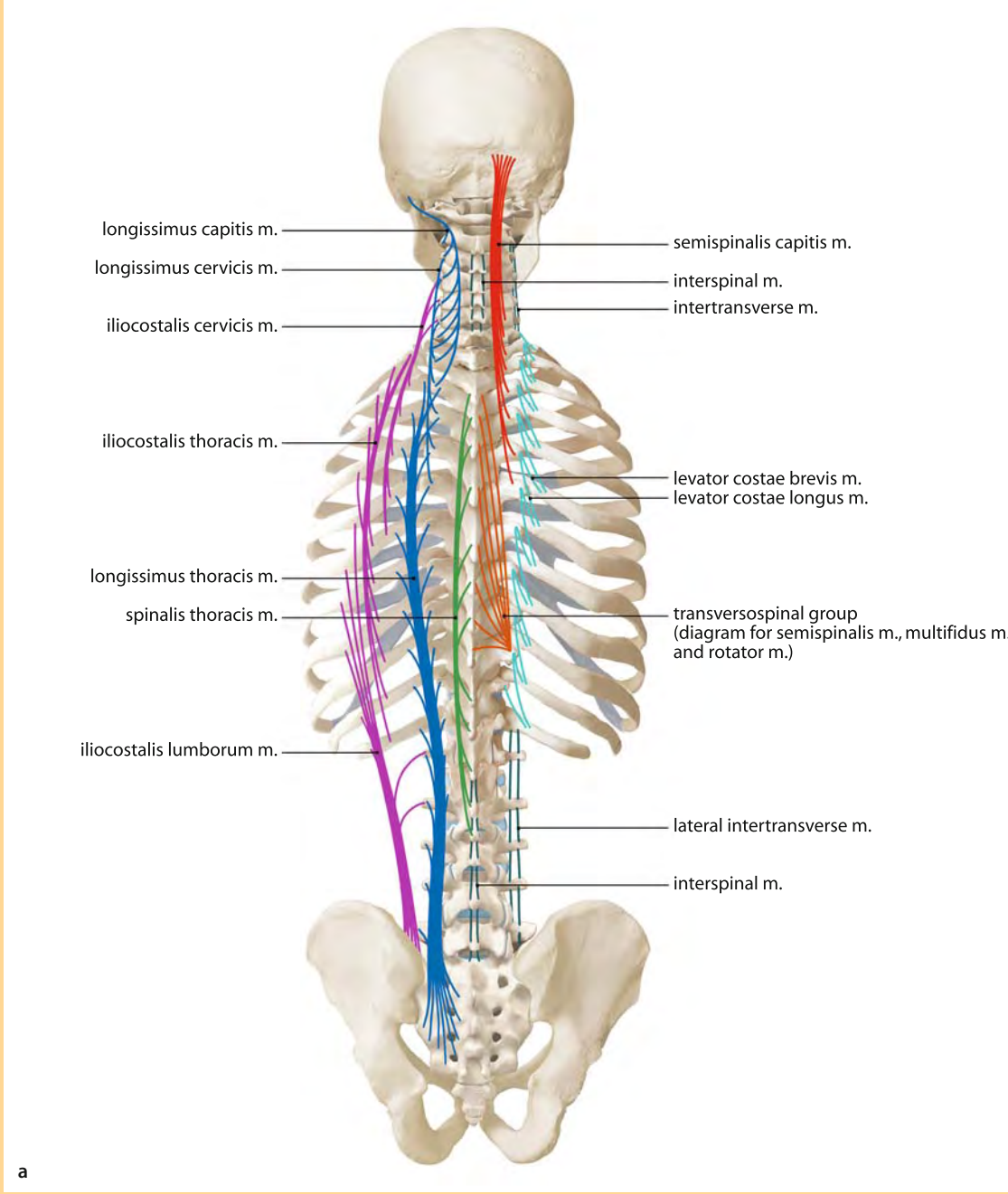


**Figure 4. Deep muscles of the back**

**a** The deep muscles of the back can be separated into the sacrospinalis (erector spinae) group (left side), the transversospinal group (right side), and the short back muscles group. The sacrospinalis group consists of the iliocostalis muscles, longissimus muscles and spinalis muscles. The transversospinal group consists of semispinalis muscles, multifidus muscles and the rotator muscles. The short back muscle group consists of the intertransverse and interspinal muscles.

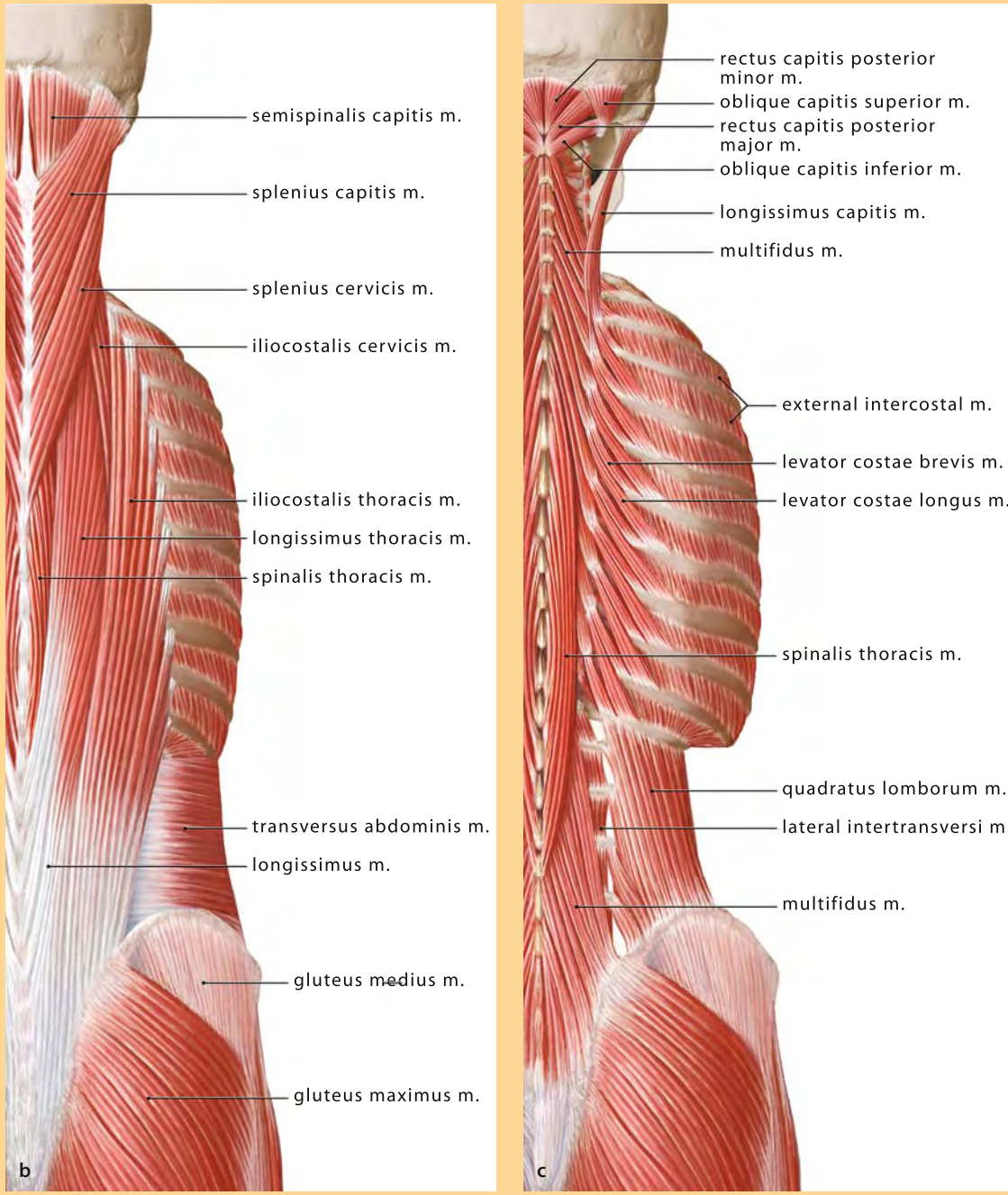


**Figure 4.** (*Cont.*)

b, c The spatial distribution of the deep spinal muscles determines their function. c The suboccipital muscles consist of rectus capitis posterior major muscle, rectus capitis posterior minor muscle, oblique capitis superior muscles, and oblique capitis inferior muscle.

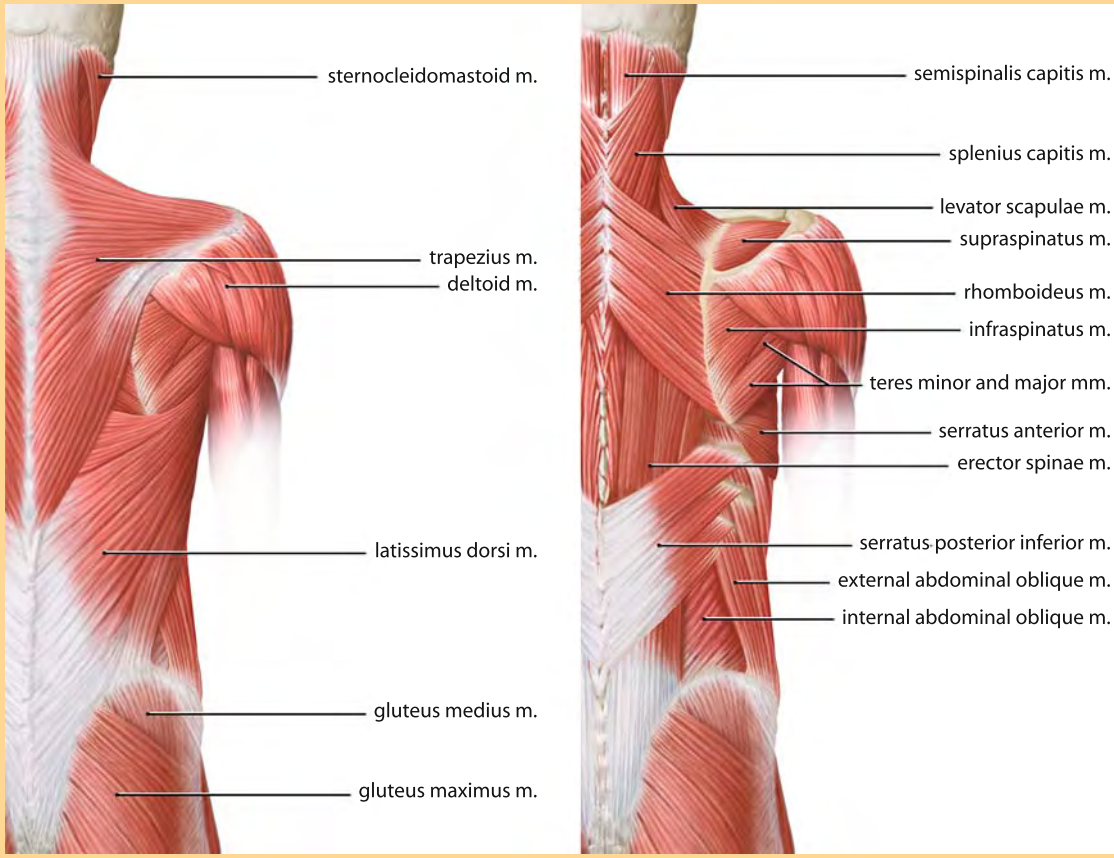


Figure 5. Superficial muscles of the back

The geometric relationship between the muscle line of action and the intervertebral center of rotation determines the functional potential

**Spinal muscle activity** can be determined by direct electromyographic measurement or by using mathematical models of the spine, which include a detailed description of the origin and insertion points of muscles, muscle cross sections, muscle fiber length and muscle type. Of particular importance is the geometric relationship of the muscle line of action to the rotation center of the joint in consideration (the moment arm: larger moment arm → greater potential to produce torque). **Moment arms** for cervical and lumbar spine muscles have been determined from MR and CT images [53, 64, 89, 91]. Detailed descriptions of the anatomy of spinal muscles have been published, which include the variation in moment arm length resulting from changing posture [14, 48, 65, 92]. Owing to the large number of muscles, the inherent redundancy, and the possibility for muscular co-contraction, the calculation of muscle activity with mathematical models often requires the use of additional formulae which consider optimal muscle stress levels or maximum contraction forces to obtain a unique solution.

## Spinal Stability Through Muscular Activity

Spine stability is enhanced by the activity of the transverse abdominis, multifidus and psoas muscles

The **muscular system** can also be divided into three functional groups [10]:

- local stabilizers
- global stabilizers
- global mobilizers

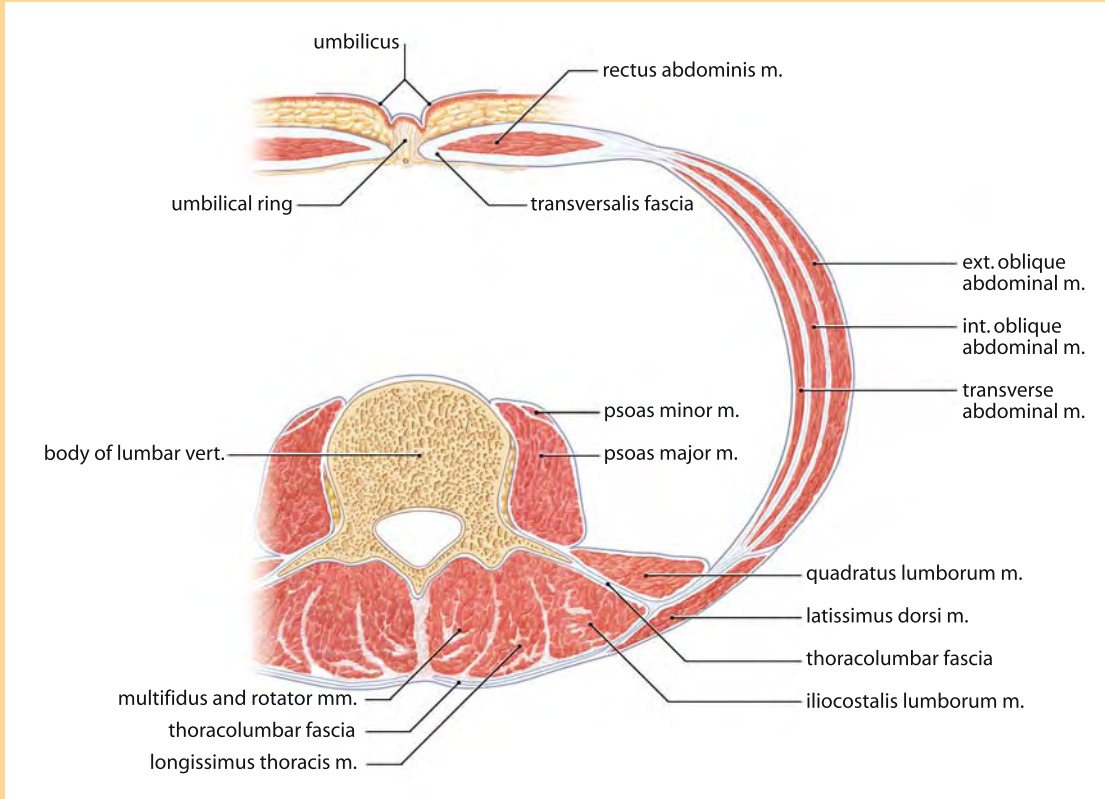


**Figure 6. Interplay of anterior and posterior spinal muscles**

The transverse abdominis, the deep lumbar multifidus and the psoas are among the local stabilizing muscles best suited to control the neutral zone in the lumbar spine. The transverse abdominis attaches directly to the lumbar spine and stiffens the spine by creating an extensor moment on the lumbar spine and by creating pressure on the anterior aspect of the spine (intra-abdominal pressure), resisting collapse of the natural curvature of the spine. The multifidus attaches directly to each segment of the lumbar spine and intrinsically stiffens the intervertebral joint by direct contraction. The psoas' prime fiber orientation on the anterior aspect of the vertebrae facilitates spinal stabilization.

**Local stabilizers** (Fig. 6) attach directly to the lumbar spine, usually spanning single spinal segments, and control the neutral position of the intervertebral joint. Examples of local stabilizers are the transverse abdominis, the deep lumbar multifidus and the psoas. **Local stabilizers** operate at low loads and do not induce motion, but rather serve to stiffen the spinal segment and control motion. A dysfunction of the local stabilizer can result in poor segmental control and pain due to abnormal motion. The **global muscle** system comprises the larger torque-producing muscles which contract concentrically or eccentrically to produce and control movement. Contraction of these muscles can also enhance spinal rigidity. Examples of global muscles are the oblique abdominis, rectus abdominus and erector spinae (spinalis, longissimus and iliocostalis). Although global muscles are traditionally targeted for treating patients with low back pain, there is compelling evidence that retraining of the local stability system may be most beneficial. **Clinical instability** has been defined as a significant decrease in the ability to maintain the intervertebral neutral zone within physiological limits [67], and the muscles best suited to control the neutral zone in the lumbar spine are the transverse abdominis, the deep lumbar multifidus and the psoas [41]. The transverse abdominis attaches directly to the lumbar spine via the lumbodorsal fascia and

Training of local stabilizers improves spinal stability

stiffens the spine by inducing an extensor moment on the lumbar spine and by creating pressure on the anterior aspect of the spine (intra-abdominal pressure), resisting collapse of the natural curvature of the spine. The **multifidus** attaches directly to each segment of the lumbar spine and intrinsically stiffens the intervertebral joint by direct contraction. The **psoas** has been described functionally as a hip flexor. However, the presence of multiple fascicles of the psoas attaching to the individual lumbar vertebrae, and the predominant fiber orientation on the anterior aspect of the vertebrae, facilitate its function as a spine stabilizer [74].

The psoas is an important spine stabilizer

### Muscle Activity During Flexion and Extension

Flexion is achieved through the forward weight shift of the upper body and controlled by compensatory activity of the extensor muscles

Due to the nearly oblique configuration of thoracic facets and the intrinsic stiffness of the ribcage, the majority of spine flexion and extension occurs in the lumbar spine, augmented by pelvic tilt [19, 29]. **Flexion** is initiated by the abdominal muscles and the vertebral portion of the psoas. Additional flexion is achieved through the weight shift of the upper body, which induces an increasing forward bending moment, and is controlled by compensatory activity of the extensor muscles. Posterior hip muscles control the forward tilting of the pelvis. In full flexion, it has been proposed that the forward bending moment is counteracted passively by the elasticity of the muscles and posterior ligaments of the spine, which are initially slack but progressively tightened as the spine flexes [29]. However, more recent studies with measurements of muscle activity have shown that deep lateral lumbar erector spinae muscles are still active in full flexion [7], perhaps for stabilization. During **hyperextension** from upright, extensor muscles are active to initiate the motion, but as extension progresses, the shifting body weight is sufficient to produce a backward bending moment which is modulated by increasing activity of the abdominal muscles.

### Muscle Activity During Lateral Flexion and Rotation

**Lateral flexion** of the trunk can occur in the lumbar and thoracic spine. The spinotransversal and transversospinal systems of the erector spinae muscles and the abdominal muscles are active during lateral bending. Ipsilateral contractions initiate the motion and contralateral contractions control the progression of bending [8]. During **axial rotation**, the back and abdominal muscles are active, and both ipsilateral and contralateral contractions contribute to the motion. High degrees of coactivation have been measured during axial rotation, perhaps due to the suboptimal muscle lines of action for this motion [44].

## Spine Kinematics

The sum of limited motion at each segment creates considerable spinal mobility in all planes

The spine provides mobility to the trunk. Only limited movements are possible between adjacent vertebrae, but the sum of these movements amounts to considerable spinal mobility in all anatomical planes. The range of motion differs at various levels of the spine and depends on the structural properties of the disc and ligaments and the orientation of the facet joints. Motion at the intervertebral joint has **six degrees of freedom**: rotation about and translation along the inferior-superior, medial-lateral and anterior-posterior axis (Fig. 7a). Spinal motion is often a complex, combined motion of simultaneous flexion or extension, side bending and rotation.

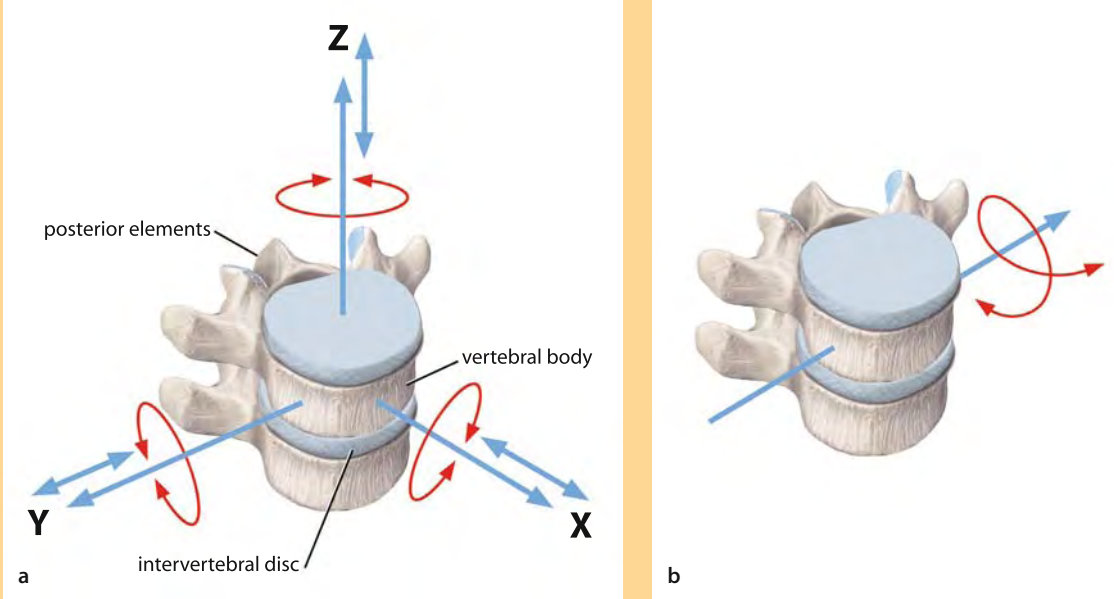


**Figure 7. Motion characteristics of the spinal segment**

a The subaxial motion segments exhibit six degrees of freedom (3 translations, 3 rotations). Spinal motion is often a complex combination of translations and rotations. b The instantaneous helical axis of motion can be regarded as a screw motion.

## Range of Motion

Spinal kinematics and spinal range of motion can be determined in vivo using, e.g. surface markers, goniometers, pantographs, or computerized digitizers. While these methods are adequate for postural measurements, they lack the accuracy required for intersegmental motion measurement [51, 76]. More reliable in vivo radiographic and in vitro cadaveric measurements have been performed to determine the average range of motion for various levels of the spine [43, 72, 73]. **Intersegmental range of motion** is site specific, determined by local anatomical geometry and functional demands (Fig. 8).

Intersegmental motion is site specific

## Mechanical Response of the Spinal Motion Segment

A common method for measuring and expressing the complex structural properties and motion of the spinal segment is through three-dimensional flexibility testing. **Flexibility** is the ability of a structure to deform under the application of a load. The mechanical response of the spine is typically determined by applying pure bending moments, with or without the addition of an axial compressive preload, in each of the three physiological directions of flexion-extension, lateral bending and axial rotation, and recording the overall principal and coupled motion of the specimen. Measuring the flexibility of individual functional spinal units or multisegment spine segments, i.e. the total motion achieved for a given load, is somewhat analogous to the clinical concepts of range of motion and spinal instability. The **load-displacement curve** of the spine is generally non-linear. For small loads, displacements are relatively large due to ligament and intervertebral disc laxity about the neutral position of the spine. At higher loads, the resistance to deformation increases substantially. The overall motion in the low load region of the response curve has been termed the neutral zone and is a quantitative measure of joint laxity around the neutral position. The displacement

For small loads displacements are relatively large due to ligament and disc laxity about the neutral position

The load-displacement curve of the spine is non-linear

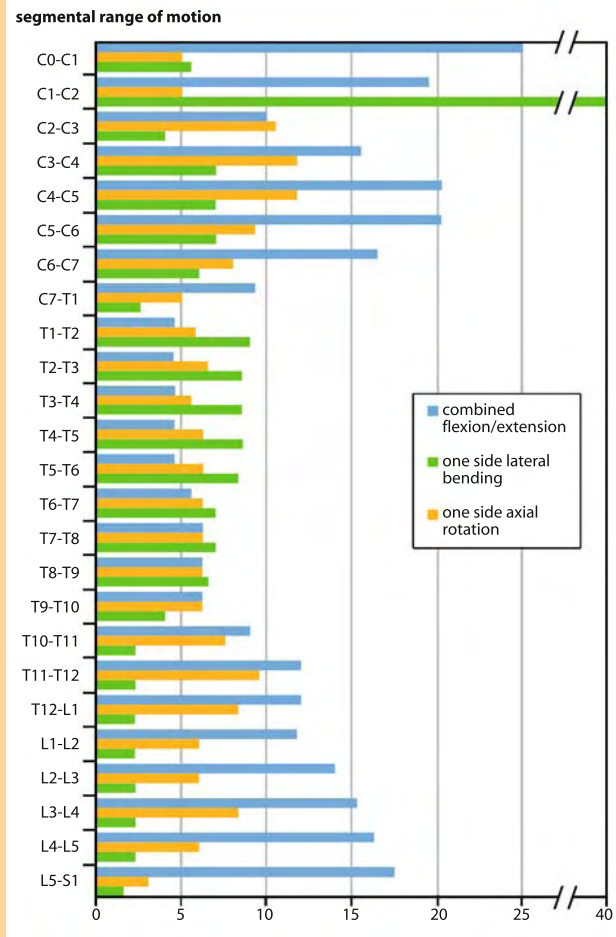


**Figure 8. Average segmental range of spinal motion**

Intersegmental range of motion is site specific, determined by local anatomical geometry and functional demands. The extensive mobility of the cervical spine in all anatomical directions is apparent. The specific geometry of the C1–C2 joint can be recognized by the substantial rotation at this level. Motion in the thoracic spine is limited by the stiffening effect of the ribcage. In the lumbar spine, substantial flexion-extension motion is possible, but rotation is limited by the geometry of the facet joints. Summarized from [98].

beyond the **neutral zone** and up to the maximum physiological limit has been termed the **elastic zone**. The sum of the neutral zone and elastic zone provides the total physiological range of motion of the spine. Flexibility coefficients for the spine reported in the literature are generally calculated from the elastic zone of the response curve (Table 4).

Changes to the neutral zone are associated with trauma and degeneration and resemble clinical instability

The neutral zone is a parameter that correlates well with other signs indicative of **instability of the spine**. The extent of the neutral zone increases following disc degeneration [98], surgical injury (e.g. facetectomy), high speed trauma [66] and repetitive cyclic loading [45]. Together, the neutral zone and total range of motion provide a quantitative measure of normal segmental motion, hypermobility due to injury or degeneration, or the relative merits of stabilizing implants or interventions.

**Table 4.** Typical average flexibility coefficients of the functional spinal unit

| Region | Flexion | Extension | Lateral bending | Rotation |
|---|---|---|---|---|
| Cervical | 2.33°/Nm | 1.37 | 1.47 | 0.86 |
| Thoracic | 0.45 | 0.36 | 0.36 | 0.40 |
| Lumbar | 0.74 | 0.48 | 0.57 | 0.20 |
| Lumbosacral | 1.00 | 0.78 | 0.13 | 0.55 |

Data derived from in vitro testing [11, 54, 58, 68, 79, 86, 87]

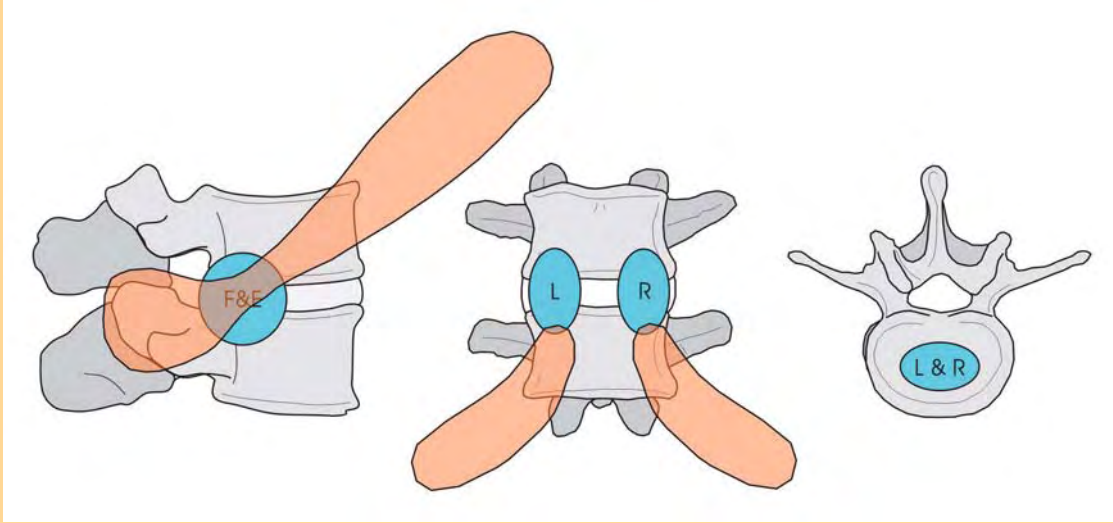


**Figure 9. Typical instant center of lumbar rotation**

For planar motion, there is a unique instant center of rotation which fully describes the motion between two adjacent vertebrae. For the healthy spine segment, the center of rotation generally lies within the intervertebral disc. With degeneration, segmental instability can result in a significant alteration of the motion patterns of the spine. Changes to the instant center of rotation may have consequences for the loading of peripheral structures of the spine. As determined from in vitro and in vivo spinal motion analysis studies [41, 69, 70, 98].

There is a unique center of rotation for every intersegmental motion

Quantitative measurements of the extent of motion only partially describe spinal kinematics. A common simplification for the analysis of spinal kinematics is to consider the motion only in a single principal plane (e.g. flexion-extension). For planar motion, there is a unique **instant center of rotation** which fully describes the motion between two adjacent vertebrae (Fig. 9). The instant center of rotation generally lies within the disc space for healthy spines, but with disc degeneration the center of rotation pathway can be significantly altered [32]. With improvement in dynamic, in vivo methods for measuring spinal kinematics, a detailed analysis of the instant center of rotation and its variations may provide a tool for diagnosing particular pathological conditions of the spine. Furthermore, a complete knowledge of the normal motion characteristics of a spine segment is of crucial importance for the design of next-generation functional spinal implants such as disc prostheses. A more complete three-dimensional description of the relative motion between two vertebrae is offered by the **helical axis of motion** (Fig. 7b). Any discrete motion in three-dimensional space can be expressed as a simple screw motion; the motion consists of a rotation about and a translation along a single unique axis in space. Although more complex, the helical axis of motion allows a three-dimensional visualization of the unique motion coupling in spinal kinematics [42].

## Clinical Instability

Spinal instability is not well defined

Clinical instability has been defined as an abnormal response of the spine to applied loads and is often characterized by excessive motion of spinal segments. The biomechanical definition of spinal instability has been further refined to encompass changes to the neutral zone, implying that motion extremes alone are not indicative of pathology. The abnormal response of the spine generally reflects incompetence of the passive and active structures (e.g. ligaments, muscles) that hold the spine in a stable position.

Definition of spinal instability remains a matter of debate

The diagnosis of **spinal stability** remains an important yet controversial task for the practitioner, as many treatment decisions are based on this assessment. However, an objective and clinically relevant definition of spine instability remains elusive due to the multi-faceted nature and etiology of instability.

Classification systems have been proposed which are designed to categorize instability of the cervical, thoracic and lumbar spine resulting from traumatic injuries [98], but these do not take into account other causes of instability such as idiopathic disc and facet degeneration. **Clinical instability** as a definition can be applied equally well to soft-tissue pathologies which impart a laxity to the spine.

There is no reliable imaging based definition of spinal instability

Diagnosis of spinal instability is routinely based on established imaging methods. Plain radiography is perhaps the most commonly used diagnostic tool but this has often questionable value and provides only indirect evidence of spinal instability. In many cases instability is only recognizable using functional radiography (flexion/extension) but this technique has limited reproducibility. Functional computed tomography offers a higher sensitivity than radiography for identifying abnormal motion potentially causing or aggravating a neurological deficit. MR imaging facilitates the identification of soft tissue abnormalities associated with instability. Nevertheless, there is no single imaging modality which discriminates with sufficient certainty "normal" and "abnormal" motion, therefore raising questions about the value of imaging-based methods for the diagnosis of instability.

Instability cannot be defined by imaging studies

Investigation using multiple **imaging techniques** likely provides the most objective assessment of instability. However, a significant barrier to reliable diagnosis is the non-specific nature of back pain and the uncertain relationship between instability and pain. Most researchers therefore define instability by clinical terms, rather than mechanical [75]. In the absence of a universally accepted definition of spinal instability we concur with the working definition of White and Panjabi [98] (Table 5):

**Table 5.** Definition of spinal instability

| |
|---|
| Clinical instability is the loss of the ability of the spine under physiologic loads to maintain its pattern of displacement so that there is no initial or additional neurologic deficit, no major deformity, and no incapacitating pain. |

## Kinetics (Spinal Loading)

Spinal loads are generated by a combination of body weight, muscle activity, pre-tension in ligaments and external forces

Loads on the spine are generated by a combination of body weight, muscle activity, pre-tension in ligaments and external forces. Simplified calculations of spinal loading are possible using force diagrams ("free-body diagram") for coplanar forces. **Direct measurements of spinal loading** are not possible, but can be inferred from, e.g. measurements of internal disc pressure [61] or forces acting on internal spinal fixation hardware [78]. Alternatively, the electromyographic activity of trunk muscles can be measured and correlated with calculated values for muscle contraction forces. This muscle activity data can then be included in mathematical models to estimate total spinal loading for a variety of physical activities.

### Static Loading

Posture influences the loading of the spine

Posture influences the loading of the spine. In addition to the weight of the trunk, the spine is further compressed by the active postural muscles during standing. The **center of gravity line** of the body generally falls ahead of the lumbar spine,

**Table 6.** Typical spinal loads

| Activity | Load on L3 disc (N) |
|---|---|
| Supine, awake | 250 |
| Supine, traction | 0 |
| Supine, arm exercises | 500 |
| Upright sitting without support | 700 |
| Sitting with lumbar support, 110° incline | 400 |
| Standing at ease | 500 |
| Coughing | 600 |
| Forward bend 20° | 600 |
| Forward bend 40° | 1 000 |
| Forward bend 20° with 20 kg | 1 200 |
| Forward bend, 20° and rotated 20° with 10 kg | 2 100 |
| Sit up exercises | 1 200 |
| Lifting 10 kg, back straight, knees bent | 1 700 |
| Lifting 10 kg, back bent | 1 900 |
| Holding 5 kg, arms extended | 1 900 |

Data derived from in vivo pressure measurements from over 100 subjects [63]

which creates a net forward bending moment. This moment must be counteracted by elastic ligament forces muscle activity in the erector muscles. Abdominal muscles and the psoas are active due to the natural postural sway during standing [59]. Pelvic tilt can alter spine loading. A backward tilt of the pelvis decreases the sacral angle and flattens the lumbar spine, the thoracic spine extends slightly to compensate changes to the body's center of gravity and muscle exertion is consequently decreased. Conversely, a forward tilt of pelvis increases the sacral angle, accentuating lumbar lordosis and thoracic kyphosis, and increasing muscle forces.

In vivo spinal loading during daily activities can be derived from disc pressure measurements

The loads on the anterior column during a variety of static postures have been derived from in vivo **disc pressure measurements** [60]. Employing a mathematical relationship between applied spinal compressive loading and disc pressure established in carefully controlled in vitro experiments, Nachemson et al. [63] have published extensive data on spinal loading (Table 6). In subsequent experiments, Wilke et al. [99] have provided additional data demonstrating similar disc pressures for lying prone and lying on the side, and, paradoxically, lower disc pressures for slouched sitting compared to sitting upright. Incidentally, this study also confirmed the intrinsic disc swelling and uptake of fluid overnight during rest.

## Loads During Lifting

The highest loads on the spine are produced during lifting

The highest loads on the spine are produced during **lifting**. Consequently this is the subject of considerable research in the fields of biomechanics and ergonomics. Loads during lifting can be extremely high and may approach the failure load of single vertebrae (5 000 – 8 000 N).

Lifting forces are directly influenced by the weight of the object, spinal posture, lifting speed and lifting technique

As previously mentioned, the **vertebral endplate** is the weak link and often will fail before the intervertebral disc is compromised. Microdamage near the endplate due to repeated application of high loads [37] is a possible consequence of heavy lifting, and a decreased capacity for vertebral loading has been observed following this initial yielding of the vertebral body [77]. **Lifting forces** are directly influenced by the weight of the object being lifted, the size of object, spinal posture, lifting speed, and lifting technique, although no significant differences have been shown between spine compression and shear forces for stoop or squat lifting techniques [94] (Fig. 10). It is possible that other mechanisms to reduce the load on the spine, such as intra-abdominal pressure or muscular co-contraction, may somewhat compensate for poor lifting technique.

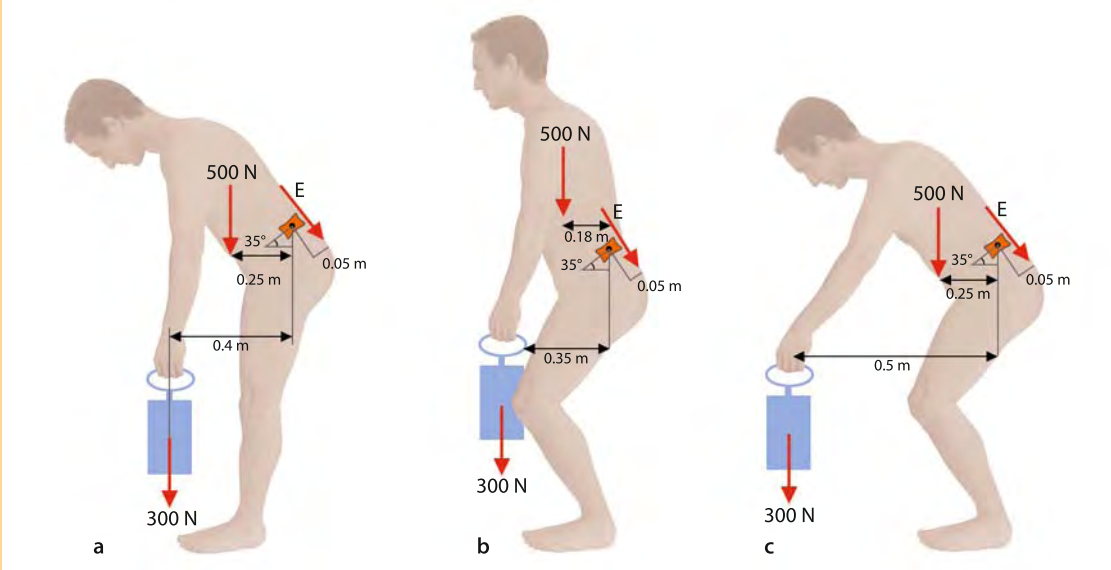


**Figure 10. Influence of lifting technique on spinal forces**

a–c Three different methods of lifting an object are shown in the diagrams, and the forces a lumbar disc experiences in each case are calculated. The disc is subject to three forces, as depicted in the diagrams: the force exerted by the upper body weight, the force exerted by the weight of the object and the force produced by the erector spinae muscles. The upper body weight and the weight of the object act in front of the disc and therefore create forward bending moments about the disc. To counteract these bending moments, the erector spinae muscles contract to create a balancing extension moment about the disc. Bending moments are a product of the force being applied and the distance at which the force is applied. Consequently, an increase in the distance between the object being lifted and the spine increases the forward bending moment, and furthermore the limited distance between the disc and the line of action of the erector spinae muscles necessitates a correspondingly high force in the muscles to produce the necessary balancing extension moment. Three examples are shown below for possible lifting postures, with a calculation of the net bending moments induced by the weight of the torso and the object being lifted, the required muscle force to counterbalance this and the resulting load which the disc experiences. b Lifting with a straight back and bringing the object closer to the body centerline has obvious benefits for minimizing spinal loading. c On the other hand, reaching too far for the object can induce substantially higher spinal loading.

| a: | b: | c: |
|---|---|---|
| Total forward bending moment = 245 Nm | Total forward bending moment = 195 Nm | Total forward bending moment = 275 Nm |
| Force produced by erector spinae muscles = 4900 N | Force produced by erector spinae muscles = 3900 N | Force produced by erector spinae muscles = 5500 N |
| Total reaction force on disc = 5574 N | Total reaction force on disc = 4578 N | Total reaction force on disc = 6172 N |

## Dynamic Loading

Motion increases muscle activity and spinal loads considerably in comparison to static and quasistatic postures. Inertial forces generated during the acceleration and deceleration of the trunk and extremities can add substantially to the overall load transferred along the spinal column. For example, the loads on the lumbar spine are approximately 0.2 – 2.5 times body weight during walking [18]. With a higher walking cadence, loading increases. Posture during motion also influences spinal loading. The greater the degree of forward flexion of the trunk during walking, the larger the muscle forces which are required to maintain the position of the trunk and consequently compressive forces at the individual discs increase.

**Table 7.** Glossary of biomechanical terms

| | |
|---|---|
| **Force:** | A directed interaction between two objects that tends to change the physical state of both (i.e. acceleration or internal stresses). Force has both direction and magnitude. |
| **Moment:** | A turning force produced by a linear force acting at a distance from a given rotation axis. The concept of the moment arm, this characteristic distance, is key to the operation of the lever and most other simple machines capable of generating a mechanical advantage. |
| **Stress:** | The internal distribution and intensity of forces within a body that balance and react to the externally applied loads. Stress is expressed in force per unit area and is calculated on the basis of the original dimensions of the cross section of the specimen. |
| **Deformation:** | The change in shape or form in a material caused by stress or force. |
| **Strain:** | Deformation of a physical body under the action of applied forces. Strain is expressed as a change in size and/or shape relative to the original undeformed state. |
| **Stiffness:** | The resistance of an elastic body to deflection by an applied force. A stiff material is difficult to stretch or bend. |
| **Young's modulus:** | Young's modulus, or the tensile elastic modulus, is a parameter that reflects the resistance of a material to elongation. The higher the Young's modulus, the larger the force needed to deform the material. |
| **Elasticity:** | The theory of elasticity describes how a solid object moves and deforms in response to external stress. Elasticity expresses the tendency of a body to return to its original shape after it has been stretched or compressed. |

## Recapitulation

**Human spine.** The main functions of the spine are to **protect** the spinal cord, to **provide mobility** to the trunk and to **transfer loads** from the head and trunk to the pelvis. The spine can be divided into **four distinct functional regions**: cervical, thoracic, lumbar and sacral. The cervical and lumbar regions are of greatest interest clinically, due to the substantial loading and mobility of these regions and the associated high incidence of trauma and degeneration.

**Motion segment.** The motion segment, or **functional spinal unit**, comprises two adjacent vertebrae and the intervening soft tissues. Each motion segment consists of an anterior structure, forming the **vertebral column**, and a complex set of posterior and lateral structures. The anterior column supports compressive spinal loads, while the **posterior elements** control spinal motion, protect the spinal cord and provide attachment points for muscles and ligaments.

**Vertebral body.** The principal biomechanical function of the vertebral body is to support the **compressive loads** of the spine due to body weight and muscle forces. The vertebral body comprises a highly porous trabecular core and a dense, solid shell. The trabecular bone bears the majority of the vertical compressive loads, while the outer shell forms a reinforced structure which additionally resists torsion and shear. The **vertebral endplate** plays an **important role in load transfer** and is often the initial site of vertebral body failure. A strong correlation has been demonstrated between quantitative volumetric bone density and vertebral strength. Vertebral geometry and structure are equally important factors for the determination of vertebral strength.

**Intervertebral disc.** The intervertebral disc is the **largest avascular structure** of the body. The disc consists of a **gel-like nucleus** surrounded by a strong, **fiber-reinforced anulus**. Axial disc loads are borne by hydrostatic pressurization of the nucleus pulposus, resisted by circumferential stresses in the anulus fibrosus. Interstitial fluid is expressed from the disc during loading. Approximately 10–20% of the total fluid volume of the disc is exchanged daily. **Disc degeneration** substantially **alters** the mechanism of **load transfer**. Combined axial compression, flexion and lateral bending have been shown to cause disc prolapse.

**Posterior elements.** The facet joints guide and **limit intersegmental motion**. Deformity of the facets or fracture of the pars interarticularis may compromise **segmental shear resistance** and can lead to spondylolisthesis.

**Spinal ligaments.** The ligaments surrounding the spine **guide segmental motion** and contribute to

the intrinsic stability of the spine by limiting excessive motion. **Ligament response** to load is non-linear, with an initially flexible neutral zone and a subsequent stiffening under increasing load. Physiological strain levels in the ligaments approach 30% total elongation.

**Muscles.** The spatial distribution of muscles determines their function. The trunk musculature can be divided functionally into **extensors** and **flexors**, or **local stabilizers** and **global mobilizers**. The geometric relationship between the muscle line of action and the intervertebral center of rotation determines the functional potential of a muscle.

**Spine kinematics.** Spinal motion is often a complex, combined motion of simultaneous flexion/extension, side bending and rotation. The sum of limited motion at each motion segment creates considerable spinal mobility in all planes.

**Motion segment mechanical response.** The functional stiffness of the motion segment is adapted to the loading which each spine segment experiences. Compressive spine loads (i.e. muscle loads) stiffen the spine segment. **Posterior elements contribute** significantly to overall **segmental stiffness.** The extrinsic support provided by trunk muscles stabilizes and redistributes loading on the spine and allows the spine to withstand loads of several times body weight without buckling. For small loads, displacements are relatively large due to ligament and disc laxity about the neutral position (neutral zone). At higher loads, resistance increases substantially. Changes to the neutral zone are associated with trauma and degeneration (i.e. "clinical instability"). There is a unique **center of rotation** for each intersegmental motion.

**Spinal loading.** Spinal loads are generated by a combination of body weight, muscle activity, pretension in ligaments and external forces. In vivo spinal loading during daily activities can be derived from disc pressure measurements. The **highest loads** on the spine are produced **during lifting.** Lifting forces are directly influenced by the weight of the object, spinal posture, lifting speed and lifting technique. Inertial effects during dynamic activities substantially increase spinal loading.

## Key Articles

**Nachemson A, Morris JM (1964) In vivo measurements of intradiscal pressure: discometry, a method for the determination of pressure in the lower lumbar discs. J Bone Joint Surg Am 46:1077 – 1092**

A report on the first series of in vivo disc pressure measurements conducted in 19 patients. This study provided new insight into the loading of the spinal column during daily activities. Study subjects covered a variety of gender, body types, and medical conditions. All subjects had normal discs, as determined from discogram. All subjects experienced back pain; some had already undergone fusion. A good correlation was shown between the body weight of segments above disc and the calculated load on disc. A qualitative relationship was found between the posture and disc loading (e.g. lowest for lying prone, higher for standing and highest for sitting slouched). Loads of 100 – 175 kg were reported for lower lumbar discs when seated. Standing loads ranged from 90 to 120 kg. This study laid the groundwork for a broad range of future studies on disc mechanics, spinal loading, and ergonomics.

**White AA, Panjabi MM (1990) Clinical biomechanics of the spine, 2nd edn. Philadelphia: J.B. Lippincott Company**

In an extensive research career, Prof. Manohar M. Panjabi has contributed several landmark publications on the topic of spinal biomechanics. This volume, co-authored with Prof. Augustus A. White, must be considered the most important single-source reference on the topic. Combining orthopedic surgery with biomechanical engineering, this reference and teaching text reviews and analyzes the clinical and scientific data on the mechanics of the human spine. The text covers all aspects of the physical and functional properties of the spine, kinematics and kinetics, scoliosis, trauma, clinical instability, the mechanics of pain, functional bracing and surgical management of the spine. Although our knowledge of the latter topic has progressed since the publication of this volume, the book as a whole remains timeless.

**Panjabi MM (1992) The stabilizing system of the spine. Part I: Function, dysfunction, adaptation and enhancement. J Spinal Disord 5:383 – 389**

**Panjabi MM (1992) The stabilizing system of the spine. Part II: Neutral zone and instability hypothesis. J Spinal Disord 5:390 – 396**
The first paper presents the conceptual basis for the assertion that the spinal stabilizing system consists of three subsystems. Passive stability is provided by the vertebrae, discs and ligaments. Active stability is provided by the muscles and tendons surrounding the spinal column. The nerves and central nervous system provide the necessary control and feedback systems to provide stability. Dysfunction of any of these three systems can lead to immediate or long term response which compromise stability and may cause pain. The second paper describes the neutral zone of intervertebral motion, around which little resistance is offered by the passive stabilizing components of the spine. Panjabi presents evidence for the correlation between the neutral zone with other parameters indicative of spinal instability. The clinical importance of the neutral zone is outlined, as are the influence of injury and pathology on the neutral zone and the compensatory mechanisms which are employed to maintain the neutral zone within certain physiological thresholds. Together, these two papers present a thorough definition of the concept of clinical instability and provide the context for interpreting the effectiveness of current spinal stabilization methods.

**Pope MH, Frymoyer JW, Krag MH (1992) Diagnosing instability. Clin Orthop Relat Res 279:60 – 67**
This review paper summarizes the problems associated with diagnosing clinical instability. The various definitions of instability are reviewed and preference is given to the definition of instability as a loss of stiffness. The authors emphasize that roentgenographic changes, particularly those associated with degeneration, have no relationship to instability. Various imaging methods are compared and contrasted, including multiple roentgenographic images and stereoroentgenography. Further kinematic measurement techniques employing kinematic frames attached directly to external fixation techniques are cited as promising for the fidelity of the data they may provide. The limitations of a purely mechanical definition of clinical instability are discussed.

## References


1. Adams MA, Dolan P (1995) Recent advances in lumbar spinal mechanics and their clinical significance. Clin Biomech 10:3 – 19
2. Adams MA, Hutton WC (1982) Prolapsed intervertebral disc. A hyperflexion injury. 1981 Volvo Award in Basic Science. Spine 7:184 – 191
3. Adams MA, Hutton WC (1983) The effect of posture on the fluid content of lumbar intervertebral discs. Spine 8:665 – 671
4. Adams MA, Hutton WC (1985) Gradual disc prolapse. Spine 10:524 – 531
5. Adams MA, McMillan DW, Green TP, Dolan P (1996) Sustained loading generates stress concentrations in lumbar intervertebral discs. Spine 21:434 – 438
6. Adams MA, McNally DS, Dolan P (1996) 'Stress' distributions inside intervertebral discs. The effects of age and degeneration. J Bone Joint Surg Br 78:965 – 972
7. Andersson EA, Oddsson LI, Grundstrom H, Nilsson J, Thorstensson A (1996) EMG activities of the quadratus lumborum and erector spinae muscles during flexion-relaxation and other motor tasks. Clin Biomech 11:392 – 400
8. Andersson GBJ, Lavender SA (1997) Evaluation of muscle function. In: Frymoyer JW, eds. The Adult Spine: Principles and Practice. New York: Lippincott-Raven, 1997.
9. Bagnall KM, Ford DM, McFadden KD, Greenhill BJ, Raso VJ (1984) The histochemical composition of human vertebral muscle. Spine 9:470 – 473
10. Bergmark A (1989) Stability of the lumbar spine. A study in mechanical engineering. Acta Orthop Scand Suppl 230:1 – 54
11. Berkson MH, Nachemson AL, Schultz AB (1979) Mechanical properties of human lumbar spine motion segments – Part 2: responses in compression and shear; influence of gross morphology. J Biomech Eng 101:52 – 57
12. Best BA, Guilak F, Setton LA, Zhu W, Saed-Nejad F, Ratcliffe A, Weidenbaum M, Mow VC (1994) Compressive mechanical properties of the human anulus fibrosus and their relationship to biochemical composition. Spine 19:212 – 221
13. Bogduk N, Macintosh JE (1984) The applied anatomy of the thoracolumbar fascia. Spine 9:164 – 170

14. Bogduk N, Macintosh JE, Pearcy MJ (1992) A universal model of the lumbar back muscles in the upright position. Spine 17:897 – 913
15. Brinckmann P, Biggeman M, Hilweg D (1988) Fatigue fracture of human lumbar vertebrae. Clin Biomech 3:1 – 23
16. Brinckmann P, Frobin W, Hierholzer E, Horst M (1983) Deformation of the vertebral endplate under axial loading of the spine. Spine 8:851 – 856
17. Burklein D, Lochmuller E, Kuhn V, Grimm J, Barkmann R, Muller R, Eckstein F (2001) Correlation of thoracic and lumbar vertebral failure loads with in situ vs. ex situ dual energy X-ray absorptiometry. J Biomech 34:579 – 587
18. Cappozzo A (1984) Compressive loads in the lumbar vertebral column during normal level walking. J Orthop Res 1:292 – 301
19. Carlsöö S (1961) The static muscle load in different work positions: an electromyographic study. Ergonomics 4:193 – 198
20. Chazal J, Tanguy A, Bourges M, Gaurel G, Escande G, Guillot M, Vanneuville G (1985) Biomechanical properties of spinal ligaments and a histological study of the supraspinal ligament in traction. J Biomech 18:167 – 176
21. Crawford RP, Cann CE, Keaveny TM (2003) Finite element models predict in vitro vertebral body compressive strength better than quantitative computed tomography. Bone 33: 744 – 750
22. Cyron BM, Hutton WC (1980) Articular tropism and stability of the lumbar spine. Spine 5:168 – 172
23. Cyron BM, Hutton WC, Troup JD (1976) Spondylolytic fractures. J Bone Joint Surg Br 58-B:462 – 466
24. Dunlop RB, Adams MA, Hutton WC (1984) Disc space narrowing and the lumbar facet joints. J Bone Joint Surg Br 66:706 – 710
25. el Bohy AA, Yang KH, King AI (1989) Experimental verification of facet load transmission by direct measurement of facet lamina contact pressure. J Biomech 22:931 – 941
26. Evans JH, Nachemson AL (1969) Biomechanical study of human lumbar ligamentum flavum. J Anat 105:188 – 189
27. Eyre DR, Muir H (1976) Types I and II collagens in intervertebral disc. Interchanging radial distributions in anulus fibrosus. Biochem J 157:267 – 270
28. Farfan HF (1973)Mechanical disorders of the low back. Philadelphia: Lea & Febiger
29. Farfan HF (1975) Muscular mechanism of the lumbar spine and the position of power and efficiency. Orthop Clin North Am 6:135 – 144
30. Ferguson SJ, Ito K, Nolte LP (2004) Fluid flow and convective transport of solutes within the intervertebral disc. J Biomech 37:213 – 221
31. Galante JO (1967) Tensile properties of the human lumbar anulus fibrosus. Acta Orthop Scand 100(Suppl):1 – 91
32. Gertzbein SD, Seligman J, Holtby R, Chan KH, Kapasouri A, Tile M, Cruickshank B (1985) Centrode patterns and segmental instability in degenerative disc disease. Spine 10:257 – 261
33. Grant JP, Oxland TR, Dvorak MF (2001) Mapping the structural properties of the lumbosacral vertebral endplates. Spine 26:889 – 896
34. Grant JP, Oxland TR, Dvorak MF, Fisher CG (2002) The effects of bone density and disc degeneration on the structural property distributions in the lower lumbar vertebral endplates. J Orthop Res 20:1115 – 1120
35. Gregersen GG, Lucas DB (1967) An in vivo study of the axial rotation of the human thoracolumbar spine. J Bone Joint Surg Am 49:247 – 262
36. Grobler LJ, Robertson PA, Novotny JE, Pope MH (1993) Etiology of spondylolisthesis. Assessment of the role played by lumbar facet joint morphology. Spine 18:80 – 91
37. Hasegawa K, Takahashi HE, Koga Y, Kawashima T, Hara T, Tanabe Y, Tanaka S (1993) Mechanical properties of osteopenic vertebral bodies monitored by acoustic emission. Bone 14:737 – 743
38. Hutton WC, Cyron BM, Stott JR (1979) The compressive strength of lumbar vertebrae. J Anat 129:753 – 758
39. Iatridis JC, Setton LA, Foster RJ, Rawlins BA, Weidenbaum M, Mow VC (1998) Degeneration affects the anisotropic and nonlinear behaviors of human anulus fibrosus in compression. J Biomech 31:535 – 544
40. Janevic J, Ashton-Miller JA, Schultz AB (1991) Large compressive preloads decrease lumbar motion segment flexibility. J Orthop Res 9:228 – 236
41. Jemmett RS, Macdonald DA, Agur AM (2004) Anatomical relationships between selected segmental muscles of the lumbar spine in the context of multi-planar segmental motion: a preliminary investigation. Man Ther 9:203 – 210
42. Kettler A, Marin F, Sattelmayer G, Mohr M, Mannel H, Durselen L, Claes L, Wilke HJ (2004) Finite helical axes of motion are a useful tool to describe the three-dimensional in vitro kinematics of the intact, injured and stabilised spine. Eur Spine J 13:553 – 559
43. Kottke FJ, Mundale MO (1959) Range of mobility of the cervical spine. Arch Phys Med Rehabil 40:379 – 382

44. Lavender SA, Tsuang YH, Andersson GBJ (1992) Trunk muscle cocontraction: the effects of moment direction and moment magnitude. J Orthop Res 10:691 – 670
45. Liu YK, Goel VK, Dejong A, Njus G, Nishiyama K, Buckwalter J (1985) Torsional fatigue of the lumbar intervertebral joints. Spine 10:894 – 900
46. Lorenz M, Patwardhan A, Vanderby R, Jr. (1983) Load-bearing characteristics of lumbar facets in normal and surgically altered spinal segments. Spine 8:122 – 130
47. Lumsden RM, Morris JM (1968) An in vivo study of axial rotation and immobilization at the lumbosacral joint. J Bone Joint Surg Am 50:1591 – 1602
48. Macintosh JE, Bogduk N, Pearcy MJ (1993) The effects of flexion on the geometry and actions of the lumbar erector spinae. Spine 18:884 – 893
49. Malko JA, Hutton WC, Fajman WA (2002) An in vivo MRI study of the changes in volume (and fluid content) of the lumbar intervertebral disc after overnight bed rest and during an 8-hour walking protocol. J Spinal Disord Tech 15:157 – 163
50. Marchand F, Ahmed AM (1990) Investigation of the laminate structure of lumbar disc anulus fibrosus. Spine 15:402 – 410
51. Mayer TG, Tencer AF, Kristoferson S, Mooney V (1984) Use of noninvasive techniques for quantification of spinal range-of-motion in normal subjects and chronic low-back dysfunction patients. Spine 9:588 – 595
52. McBroom RJ, Hayes WC, Edwards WT, Goldberg RP, White AA, III (1985) Prediction of vertebral body compressive fracture using quantitative computed tomography. J Bone Joint Surg Am 67:1206 – 1214
53. McGill SM, Santaguida L, Stevens J (1993) Measurement of the trunk musculature from T5 to L5 using MRI scans of 15 young males corrected for muscle fiber orientation. Clin Biomech 8:171 – 178
54. McGlashen KM, Miller JA, Schultz AB, Andersson GB (1987) Load displacement behavior of the human lumbo-sacral joint. J Orthop Res 5:488 – 496
55. McMillan DW, Garbutt G, Adams MA (1996) Effect of sustained loading on the water content of intervertebral discs: implications for disc metabolism. Ann Rheum Dis 55:880 – 887
56. McMillan DW, McNally DS, Garbutt G, Adams MA (1996) Stress distributions inside intervertebral discs: the validity of experimental “stress profilometry”. Proc Inst Mech Eng [H] 210:81 – 87
57. Miller JA, Haderspeck KA, Schultz AB (1983) Posterior element loads in lumbar motion segments. Spine 8:331 – 337
58. Moroney SP, Schultz AB, Miller JA, Andersson GB (1988) Load-displacement properties of lower cervical spine motion segments. J Biomech 21:769 – 779
59. Nachemson A (1966) Electromyographic studies on the vertebral portion of the psoas muscle; with special reference to its stabilizing function of the lumbar spine. Acta Orthop Scand 37:177 – 190
60. Nachemson A, Morris JM (1964) In vivo measurements of intradiscal pressure: discometry, a method for the determination of pressure in the lower lumbar discs. J Bone Joint Surg Am 46:1077 – 1092
61. Nachemson AL (1960) Lumbar intradiscal pressure. Experimental studies on post-mortem material. Acta Orthop Scand 43(Suppl):1 – 104
62. Nachemson AL (1963) The influence of spinal movements on the lumbar intradiscal pressure and on the tensile stresses in the anulus fibrosus. Acta Orthop Scand 33:183 – 207
63. Nachemson AL (1981) Disc pressure measurements. Spine 6:93 – 97
64. Nemeth G, Ohlsen H (1986) Moment arm lengths of trunk muscles to the lumbosacral joint obtained in vivo with computed tomography. Spine 11:158 – 160
65. Nussbaum MA, Chaffin DB, Rechtien CJ (1995) Muscle lines-of-action affect predicted forces in optimization-based spine muscle modeling. J Biomech 28:401 – 409
66. Oxland TR, Panjabi MM (1992) The onset and progression of spinal injury: a demonstration of neutral zone sensitivity. J Biomech 25:1165 – 1172
67. Panjabi MM (1992) The stabilizing system of the spine. Part II. Neutral zone and instability hypothesis. J Spinal Disord 5:390 – 396
68. Panjabi MM, Brand RA, Jr., White AA, III (1976) Mechanical properties of the human thoracic spine as shown by three-dimensional load-displacement curves. J Bone Joint Surg Am 58:642 – 652
69. Panjabi MM, Goel VK, Takata K (1982) Physiologic strains in the lumbar spinal ligaments. An in vitro biomechanical study. 1981 Volvo Award in Biomechanics. Spine 7:192 – 203
70. Panjabi MM, Oxland T, Takata K, Goel V, Duranceau J, Krag M (1993) Articular facets of the human spine. Quantitative three-dimensional anatomy. Spine 18:1298 – 1310
71. Panjabi MM, White AA, III, Johnson RM (1975) Cervical spine mechanics as a function of transection of components. J Biomech 8:327 – 336
72. Pearcy M, Portek I, Shepherd J (1984) Three-dimensional x-ray analysis of normal movement in the lumbar spine. Spine 9:294 – 297
73. Pearcy MJ, Tibrewal SB (1984) Axial rotation and lateral bending in the normal lumbar spine measured by three-dimensional radiography. Spine 9:582 – 587

74. Penning L (2000) Psoas muscle and lumbar spine stability: a concept uniting existing controversies. Critical review and hypothesis. Eur Spine J 9:577 – 585
75. Pope MH, Frymoyer JW, Krag MH (1992) Diagnosing instability. Clin Orthop 279: 60 – 67
76. Portek I, Pearcy MJ, Reader GP, Mowat AG (1983) Correlation between radiographic and clinical measurement of lumbar spine movement. Br J Rheumatol 22:197 – 205
77. Ranu HS (1990) Measurement of pressures in the nucleus and within the anulus of the human spinal disc: due to extreme loading. Proc Inst Mech Eng [H] 204:141 – 146
78. Rohlmann A, Graichen F, Weber U, Bergmann G (2000) 2000 Volvo Award winner in biomechanical studies: Monitoring in vivo implant loads with a telemeterized internal spinal fixation device. Spine 25:2981 – 2986
79. Schultz AB, Warwick DN, Berkson MH, Nachemson AL (1979) Mechanical properties of human lumbar spine motion segments. Part 1: Responses in flexion, extension, lateral bending and torsion. J Biomech Eng 101:46 – 52
80. Seroussi RE, Krag MH, Muller DL, Pope MH (1989) Internal deformations of intact and denucleated human lumbar discs subjected to compression, flexion, and extension loads. J Orthop Res 7:122 – 131
81. Shirazi-Adl A, Ahmed AM, Shrivastava SC (1986) Mechanical response of a lumbar motion segment in axial torque alone and combined with compression. Spine 11:914 – 927
82. Silva MJ, Wang C, Keaveny TM, Hayes WC (1994) Direct and computed tomography thickness measurements of the human, lumbar vertebral shell and endplate. Bone 15:409 – 414
83. Skaggs DL, Weidenbaum M, Iatridis JC, Ratcliffe A, Mow VC (1994) Regional variation in tensile properties and biochemical composition of the human lumbar anulus fibrosus. Spine 19:1310 – 1319
84. Stokes IA (1987) Surface strain on human intervertebral discs. J Orthop Res 5:348 – 355
85. Stokes IA (1988) Bulging of lumbar intervertebral discs: non-contacting measurements of anatomical specimens. J Spinal Disord 1:189 – 193
86. Tencer AF, Ahmed AM (1981) The role of secondary variables in the measurement of the mechanical properties of the lumbar intervertebral joint. J Biomech Eng 103:129 – 137
87. Tencer AF, Ahmed AM, Burke DL (1982) Some static mechanical properties of the lumbar intervertebral joint, intact and injured. J Biomech Eng 104:193 – 201
88. Tkaczuk H (1968) Tensile properties of human lumbar longitudinal ligaments. Acta Orthop Scand 115(Suppl):1
89. Tracy MF, Gibson MJ, Szypryt EP, Rutherford A, Corlett EN (1989) The geometry of the muscles of the lumbar spine determined by magnetic resonance imaging. Spine 14:186 – 193
90. Tsantrizos A, Ito K, Aebi M, Steffen T (2005) Internal strains in healthy and degenerated lumbar intervertebral discs. Spine 30:2129 – 2137
91. Tsuang YH, Novak GJ, Schipplein OD, Hafezi A, Trafimow JH, Andersson GB (1993) Trunk muscle geometry and centroid location when twisting. J Biomech 26:537 – 546
92. Tveit P, Daggfeldt K, Hetland S, Thorstensson A (1994) Erector spinae lever arm length variations with changes in spinal curvature. Spine 19:199 – 204
93. Urban JP, McMullin JF (1985) Swelling pressure of the intervertebral disc: influence of proteoglycan and collagen contents. Biorheology 22:145 – 157
94. van Dieen JH, Hoozemans MJ, Toussaint HM (1999) Stoop or squat: a review of biomechanical studies on lifting technique. Clin Biomech 14:685 – 696
95. Virgin WJ (1951) Experimental investigations into the physical properties of the intervertebral disc. J Bone Joint Surg Br 33-B:607 – 611
96. Vleeming A, Volkers AC, Snijders CJ, Stoeckart R (1990) Relation between form and function in the sacroiliac joint. Part II: Biomechanical aspects. Spine 15:133 – 136
97. Waters RL, Morris JM (1973) An in vitro study of normal and scoliotic interspinous ligaments. J Biomech 6:343 – 348
98. White AA, Panjabi MM (1990) Clinical biomechanics of the spine. In: White AA, III, Panjabi MM, eds. Philadelphia: J.B. Lippincott
99. Wilke HJ, Neef P, Caimi M, Hoogland T, Claes LE (1999) New in vivo measurements of pressures in the intervertebral disc in daily life. Spine 24:755 – 762
100. Yang KH, King AI (1984) Mechanism of facet load transmission as a hypothesis for low-back pain. Spine 9:557 – 565
101. Yoganandan N, Larson SJ, Pintar FA, Gallagher M, Reinartz J, Droese K (1994) Intravertebral pressure changes caused by spinal microtrauma. Neurosurgery 35:415 – 421

# 3 Spinal Instrumentation

Daniel Haschtmann, Stephen J. Ferguson

## Core Messages

- ✔ Spinal instrumentation is usually combined with spinal fusion
- ✔ The type of instrumentation and the surgical approach should follow the degree of instability
- ✔ Consolidated fusion may relieve the implant from stress
- ✔ Implant failure is a result of instant overload or of cyclic loading (fatigue)
- ✔ If fusion is delayed and/or the wrong implants are chosen, instrumentation will ultimately fail
- ✔ Spinal instrumentation should provide early and safe mobilization of the patient
- ✔ For achieving bony fusion sufficient segmental stability and appropriate load sharing are essential
- ✔ Absolute stability may interfere with fracture healing due to stress-shielding of the bone graft
- ✔ Rigid (multi-)segmental instrumentation may cause adjacent segment overload

## Goals of Spinal Instrumentation

Knowledge of biomechanical principles reduces the rate of implant failure and non-union

Spinal instrumentation basically means the implantation of more or less rigid metallic or non-metallic devices which are attached to the spine. These devices function to provide spinal stability and thus facilitate bone healing leading to spinal fusion (spondylodesis). Fundamental **biomechanical knowledge** and its application serves to improve the performance of the individual spine surgeon with respect to the rate of bony fusion, implant failure or degree of deformity correction. However, biomechanics is inherently linked with **(mechano-)biology.** And there is still an incomplete understanding of spinal biomechanics and even more so of the underlying biology. Moreover, apparently advantageous biomechanical concepts do not necessarily lead to a better patient outcome.

While a myriad of spinal stabilization devices and fusion techniques are available to the surgeon today, there are a concise number of underlying fundamental principles. Indeed, whole volumes have been written about the definition and assessment of spinal instability and the biomechanics of spinal stabilization [11, 103]. The reader is encouraged to explore these resources for a more in-depth study of this subject and for an interesting historical perspective of chronological implant development, from the Harrington rod [40] to the first external segmental instrumentation systems by Magerl in 1977 [55], followed by the "*fixateur interne*" which was developed by Kluger and Dick [27], and the CD (Cotrel/Dubousset) system [20]. A milestone in the history of spine research was the introduction of universal concepts for the biomechanical testing of spinal implants by **Manohar M. Panjabi**, taking into consideration three major aspects [65]:

Key properties are material strength, stability and fatigue resistance

- implant **strength** (failure load)
- **fatigue** (longevity under cyclic loading)
- ability to restore spinal **stability**

However, in vitro testing for primary implant stability usually comprises non-destructive testing protocols with only a few cycles, and therefore takes into account neither the effect of repetitive loading (fatigue) nor the biological host reaction.

Adapt implant and instrumentation technique to the individual case

Each spinal pathology which is intended to be treated with a stabilizing surgical procedure has its own unique biomechanical characteristics. For a successful patient outcome it is important that one chooses the **appropriate implant and technique**, considering the specific nature of each case.

Before selecting an instrumentation system to restore or maintain stability of the compromised spine, it is a prerequisite to understand the functions of the respective structures and how the biomechanics are changed by their loss. Thus, the choice of implant is strongly dependent on the indication. For example, the stress on a lumbar **translaminar facet joint screw (TLS)** in a patient treated with instrumented fusion for arthritis-related facet pain and with only minimal residual segmental mobility is relatively low. However, it is not reasonable to stabilize a complete vertebral body burst fracture with a substantially compromised anterior column solely with TLS. In this case, the screws would most likely fail, resulting in a post-traumatic kyphosis, because anterior support was mandatory.

The goals of spinal instrumentation are to stabilize, correct and fuse

With the exception of the recent developments in non-fusion devices such as spinal arthroplasty and posterior dynamic systems, spinal stabilization is a means to achieve the end goal of a solid bony fusion. Beyond this, the **aims of spinal instrumentation** are (Table 1):

**Table 1.** Goals of spinal instrumentation

- to support the spine when its structural integrity is severely compromised (iatrogenic, traumatic, infectious or tumorous)
- to prevent progression or to maintain the achieved profile after correction of spinal deformities (scoliosis, kyphosis, spondylolisthesis)
- to alleviate or eliminate pain originating from various anatomical structures by fusing or stiffening spine segments and thereby diminishing movement

Current implants have a wide "safety zone"

Each region of the spine has its own anatomical, biomechanical and biological properties. Aspects such as kyphotic or lordotic curve, inherent mobility, loading conditions as well as bone healing potential have an influence on the choice of implant and surgical approach. For this reason spinal implants not only differ in size but also follow different preferred **region-specific stabilization principles**. The authors' intention is to outline instrumentation principles based on biomechanical studies rather than to discuss specific implants. For detailed information about individual implants and anatomical regions, the reader is referred to the clinical chapters of this book and the literature cited in the references. Since nowadays it is still only approximately possible to assess the individual case in advance concerning spinal stability, individual constitutional and genetic factors as well as biological responses, e.g., bone healing properties, bone quality, tolerance to foreign materials, the recommendations for instrumentation techniques can only be generalized to a certain extent. The inability to assess **complete** disease entities has also led to therapy principles which are within "**the safety zone**" and implants which are generally sufficient for the majority of cases. But this also implies that instrumented fusion is sometimes overpowered (too rigid) or is sometimes not indicated at all.

Unlike in biomechanical studies, where spine specimens are tested under "extreme" conditions, in reality very often substantial stabilizing structures are preserved and therefore may make the instrumentation partially redundant. This is one reason why suboptimal (in the biomechanical sense) spinal instrumentation methods may still result in excellent patient outcomes. Furthermore, the "**better and the faster the biology**" the less rigidity is likely necessary to ensure healing of the spondylodesis. This is impressively demonstrated by the safe and reliable posterior in-situ fusion (without instrumentation) in lumbar lytic spondylolisthesis in children [87].

The extent of stability necessary to achieve fusion is unclear

Another example of the role of the biological and mechanical environment is the cervical spine: unlike in the lumbar spine, where rigid stabilization is mandatory, the subaxial cervical spine is more tolerant to less rigid instrumentation in terms of bony fusion. Here, for example after discectomy, stand-alone interbody cages or structural autologous bone grafts successfully reestablish physiological stability, which nevertheless results in an approximately 100 % fusion rate [37, 83].

Instrumentation generally aims to exceed physiological segmental stability

## Basic Biomechanics of Spinal Instrumentation

The following sections are intended to provide insights into the biomechanical principles of spinal instrumentation and should also provide background knowledge for the different stabilization techniques treated in the subsequent clinical chapters of this book.

### Loading and Load Sharing Characteristics

Spinal instrumentation and the stabilized spine segment form a mechanical system, a couple, which shares loads and moments. **In-vivo telemetry** has provided valuable insights into the complex three-dimensional loading of internal fixators during daily physiological activity [77]. Several interesting conclusions can be drawn from these studies: mainly muscle forces were influencing fixator loads. Flexion/extension movements as well as wearing braces or harnesses did not significantly affect fixator loads. Sitting and standing exhibited similar loads and erect standing and walking resulted in the highest loads. The forces acting were mainly **compression forces** rather than distraction; moments were mainly **flexion-bending** types. Support of the anterior column reduced fixator loads postoperatively while later healing of the fusion very often did **not**. Thus implant failure such as screw breakage does not necessarily prove pseudarthrosis [76, 78, 79, 81].

Mainly muscle forces have an influence on internal fixator loads while posture is less important

However, telemetric fixator load analysis does not provide any information about the overall force flow and **load sharing**, i.e. how much of the total load is transferred by the implant and how much by the spine. This topic was investigated by Cripton et al. [21] using posteriorly instrumented spine segments. By simultaneously measuring intradiscal pressure and the forces in a modified AO internal fixator during physiological loading, analysis of the load distribution within the instrumented spinal construct was possible. On this basis, it was demonstrated that spinal loads during **flexion and extension** were carried predominantly by equal and opposite forces in the disc and the fixator constituting a force couple. Only a small portion of the total loading was transferred directly by bending of the implant or through the posterior elements. However, for **side bending** the majority of loading was transferred through equal and opposite forces in the fixator rods. For **torsional loading**, the distribution was approximately evenly spread between implant forces, torsional resistance of the disc and

The loading pattern of the implant is critically dependent on the motion

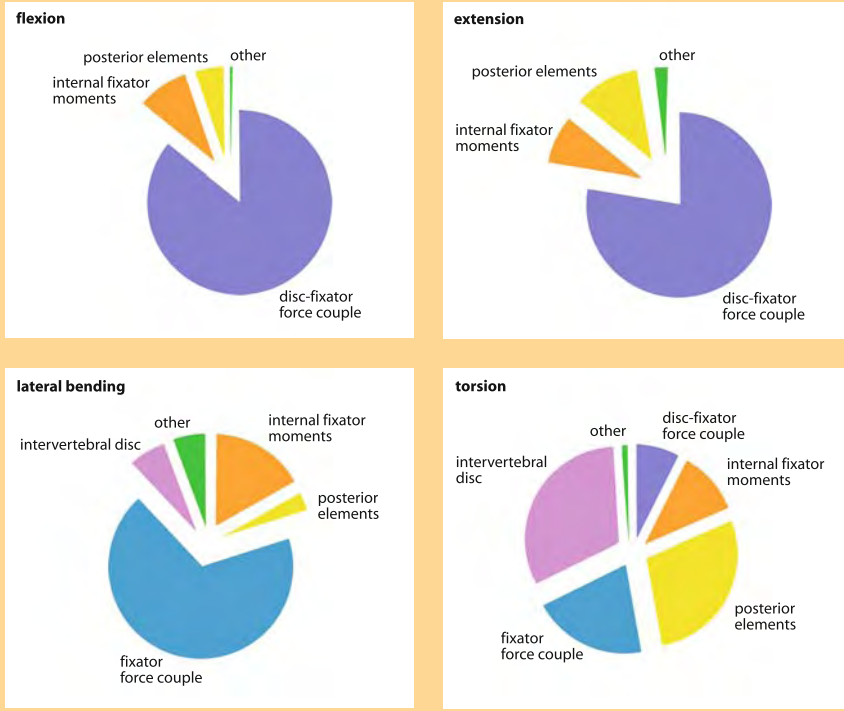


**Figure 1. Load sharing**

Load-sharing between rod/pedicle screw instrumentation and the anatomical structures of the spine during spinal motion. In flexion-extension load is mainly transferred by the disc-fixator force couple through equal and opposite forces. In torsion a great fraction of load is transferred by the disc. Therefore, the integrity of the anterior column is crucial for relieving the implants from load and thus to ensure longevity. In lateral bending load transfer is mainly through the implant.

forces acting on the posterior elements (Fig. 1). But how does the load distribution change with an **insufficient anterior column support**, which may be found in various spinal disorders, e.g. vertebral body burst fractures, spondylitis, metastatic vertebral destruction or after disc ruptures? In case of a compromised anterior column, the implant must carry the majority of the load in lateral bending, flexion, and extension (Fig. 1). Furthermore, after discectomy and the complete removal of the posterior structures the segmental range of motion (ROM) is still sufficiently limited (by 64 %) in flexion and extension, but torsion is only weakly controlled and increases by more than 230 % under these conditions (Fig. 1). Taking this information into consideration, in the clinical setting postoperative lateral bending (and torsion) should be avoided by the patient in any event to minimize fixator loads whereas flexion and extension are mostly unproblematic provided there is a functioning anterior column.

Combining the in-vivo measurements of implant loading taken by Rohlmann et al., and the force flow analysis in the study of Cripton et al., global moments of up to **30 Nm** may act through the spine [21]. If instrumentation devices are exposed to such high moments, the safe limit for many implants may be exceeded. Therefore, in the case of a substantially unstable anterior column, additional anterior support is critical to prevent hardware failure.

Anterior column defects require anterior buttressing

Further work is required to characterize the force and load transfer through intervertebral devices, corpectomy cages and other stabilization constructs.

## Posterior Stabilization Principles

The term "posterior instrumentation" is used for any surgical measure with the implantation of a stabilization device acting on the posterior column (according to F.W. Holdsworth's **two-column concept** [43]). This is commonly carried out via a posterior approach, which can vary depending on the surgeon's preferences. However, it does not necessarily mean that the device itself is exclusively acting on the posterior spinal column. Rod/pedicle screw devices or lateral mass screws, for example, also affect the anterior column. On the other hand, implantation of interbody cages through the spinal canal (**PLIF = posterior lumbar interbody fusion**) is a measure of anterior instrumentation, although it generally makes additional posterior stabilization, e.g. pedicle screws or translaminar screws, necessary due to the iatrogenic destabilization of dorsal structures.

PLIF effectively stabilizes the anterior column by a posterior approach

### Pedicle Screw Technique

The introduction of pedicle screws by Roy-Camille in 1970 [82], the subsequent development of the external fixator by Magerl [55], the following "***fixateur interne***" by Kluger and Dick [27], the angle-stable internal **AO fixator** [4] and the posterior segmental instrumentation systems [20, 51] have all dramatically improved the outcomes of spinal fusion. In contrast to the usage of long rods, now short segment stabilization using pedicle screws and rigid connecting plates or rods has become possible. This technique has been proven to be safe and effective for the surgical treatment of almost all spinal disorders such as congenital, developmental, traumatic, neoplastic and degenerative conditions [2, 3, 13, 34, 51].

Pedicle screw/rod systems are now well established for surgical treatment

The stabilizing properties of pedicle screw/rod spinal fixation systems, such as the **Universal Spine System** (Synthes, USA and Switzerland) [51], are not exceeded by any other posterior systems but are critically dependent on the degree of spinal instability and thus the pathological condition. Various biomechanical studies have been conducted on further implant characterization and to define accurate clinical indications. For example, after **corpectomy** and **bisegmental** instrumentation using a spacer and a cross-linked pedicle screw/rod system, motion is reduced by up to 85 % in flexion, 52 % in extension, 81 % in lateral bending and 51 % in axial rotation [7]. Similar results have been reported by Cripton et al. [21]. This applies also for **monosegmental instability** with destruction of the posterior elements combined with a partial dissection of the intervertebral disc. Here most other posterior instrumentation devices also exceed the physiological stability, but with the short segment fixator being the stiffest [1]. However, after complete removal of the posterior structures combined with a **complete** disruption of the intervertebral disc but with the pedicle screw instrumentation in place, the range of motion for flexion/extension was **increased** by 21 % compared to the intact spine. Furthermore, torsion was only weakly stabilized by rod/pedicle screws in posterior (facet joint) and two-column insufficiency [21].

The stabilizing potential of screw/rod systems depends heavily on extent and location of instability

The stability of pedicle screw systems is derived from the solid anchorage of the screw in the pedicle and the inherent rigidity of the connecting hardware. While the **pullout strength** of pedicle screws is directly related to the bone density [39], it can be increased by choosing **convergent screw trajectories** (Fig. 2). Furthermore, in the presence of anterior column instability, the avoidance of parallel pedicle screw insertion in short segment fixation not only increases the pull-out strength but also prevents an unstable **"four-bar" mechanism**. The same rationale applies for **cross-linking** the rods. Here, diagonal cross-linking is favorable to the horizontal configuration in terms of rotational stability [29, 100] (Fig. 3).

Convergent screw positioning increases pull-out strength

The material, length and diameter of the connecting rods determine their **stiffness**. Compared to 7-mm rods, using 10-mm rods would increase the stiffness 4.1 times and 3-mm rods would have a 30 times lower bending stiffness [80].

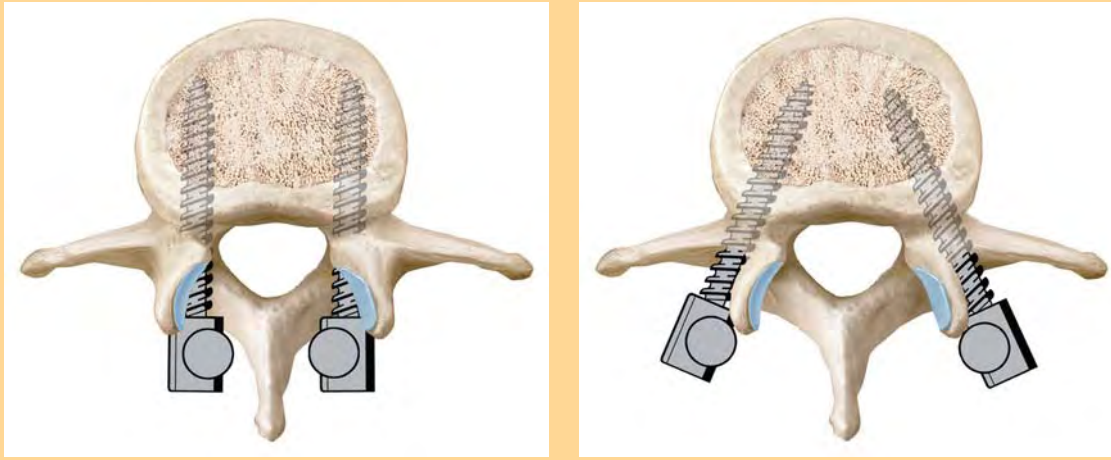

**Figure 2. Pedicle screw positioning**

The use of convergent screw trajectories (*right*) increases the pull-out strength and overall stability of pedicle screw constructs, in comparison with parallel screw insertion (*left*).

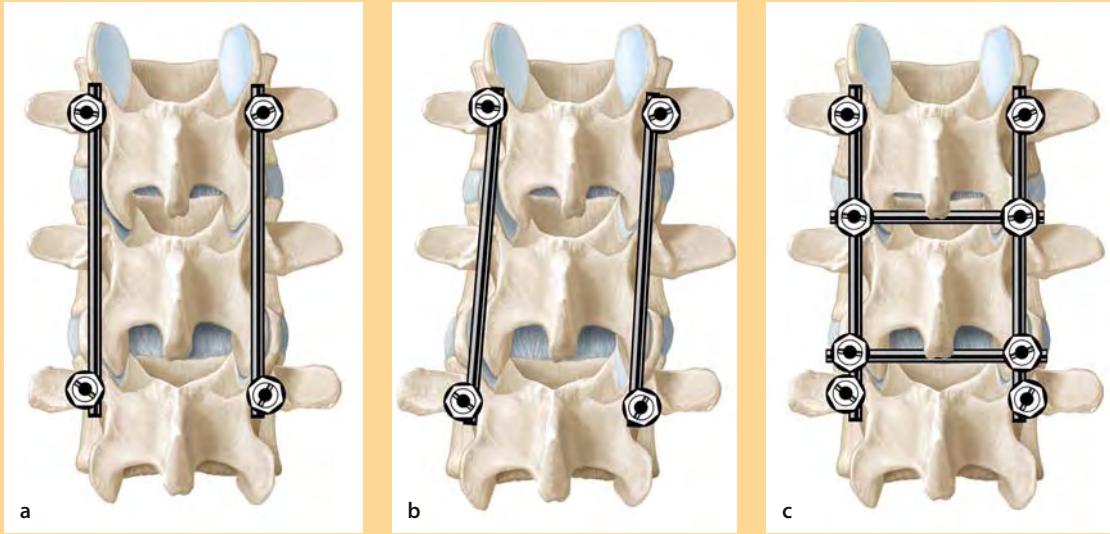


**Figure 3. Screw assembly**

a The use of conventional parallel pedicle screws and rods for spine segments with diminished anterior integrity may be insufficient. b Displacement of the stabilized segment by rotation of the pedicle screws – a so-called "four-bar" mechanism – may result in instability. Further stability can be achieved by the use of convergent screw trajectories and the addition of cross-linking. c Two cross-links or at least one oblique cross-link provides better stability than one horizontal cross-link.

However, greater deformation in smaller rods leads to greater internal stress and may finally result in failure. More rigid rods on the other hand produce higher internal loads in the implant, on the clamping device, and on the pedicle screws, and thus have a higher risk of screw breakage [80]. Therefore, current implant designs are a compromise between an absolutely rigid fixation and a minimal risk of implant failure to provide stable fixation with a proven service life [7].

**Figure 4. Thoracic pedicle screw positioning**

In contrast to the standard intrapedicular screw insertion (*left pedicle*), an extrapedicular screw trajectory (*right pedicle*) allows a greater margin of safety with respect to the spinal canal and offers greater pull-out strength and stability.

Extrapedicular screw placement in the thoracic spine is safe and reliable

While pedicle screws have been accepted as a reliable and safe method for stabilizing the thoracolumbar spine, their use in the mid and upper thoracic spine is more complicated and risky, due to the smaller overall dimensions and greater morphological variation of the thoracic pedicle, and the existing spinal cord at this height. A safer alternative to the standard intrapedicular screw placement in the thoracic spine is the **extrapedicular screw trajectory** (Fig. 4), first described by Dvorak et al. [28]. The **pull out strength** is increased by a greater screw-angulation, longer screw length, and the penetration of additional cortices. Segmental stability has been shown to be equivalent to that of the conventional intrapedicular technique, without a higher risk of material fatigue [59].

Lateral extrapedicular screw positioning is safe and biomechanically advantageous in the thoracic spine

The use of simple **laminar hooks** in the thoracic spine is safe with respect to the damage of neural structures. However, hook disengagement has been reported in scoliosis correction surgery [38]. To achieve a higher resistance to the complex three-dimensional forces, pedicle hooks with additional supporting screws have been developed [4, 51]. Biomechanical pull-out tests have shown that a significant increase in failure load can be achieved with the use of screw-augmented hooks [12].

### Translaminar and Transarticular Screw Technique

Translaminar screws effectively stabilize the spinal segments in conjunction with anterior instrumentation

**Transarticular** screws were first used by D. King in 1948 and later modified by H. Boucher in 1959 [14]. The now widely accepted **translaminar** facet joint screw placement (Fig. 5) was introduced by **F. Magerl** in the 1980s [58]. Translaminar screws (TLS) are setscrews, have a long trajectory in bone and have a favorable direction with reference to the nerve root. TLS are mostly used supplementary to anterior fusion techniques or in concert with posterior/posterolateral fusion measures in degenerative disorders. Here incompetent facet joints frequently allow pathological shear translation (olisthesis) and segmental multiplanar rotation. Biomechanical testing has shown that isolated screw fixation of the facet joints causes a moderate stabilization in all loading directions [72]. Therefore for posterior and posterolateral spondylodesis, the combination with facet fusion is generally recommended as it enhances stability [96].

Stand-alone interbody cages do not sufficiently stabilize the spine in extension and axial rotation

Similarly, as **anterior fusion** (PLIF/ALIF) **with stand-alone** cages is particularly weak in controlling extension and axial rotation [54], an additional fixation is strongly recommended to ensure fusion [72]. In one study TLS were applied complementary to paired threaded interbody cages, thereby achieving a reduced angular motion of 30 % in flexion and 60 % in extension [67].

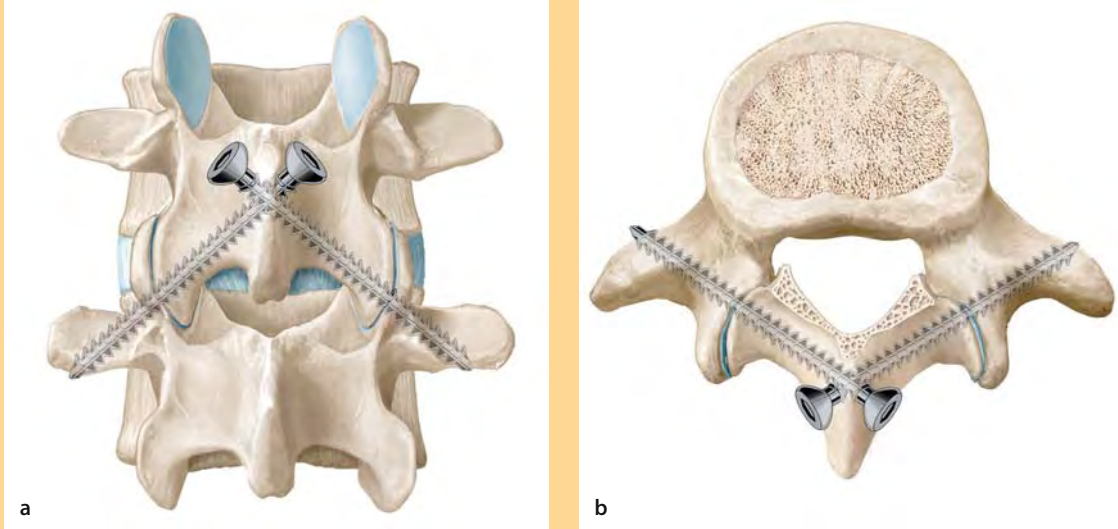


**Figure 5. Translaminar screws**

Translaminar screw positioning in the coronal (a) and the axial view (b).

The degree of stability needed for optimal fusion is still unknown

However, compared to pedicle screws, the stabilizing properties of TLS are fewer, especially in flexion and rotation [49]. Nevertheless, one should emphasize that the **degree of stability** needed to achieve bony fusion is still not known. Furthermore, several studies have shown that solid fusion and clinical outcome are not well correlated [33]. Nevertheless, the goal must be to achieve solid fusion and it is much more likely that a poor clinical outcome and "failed surgery" with pseudarthrosis and implant failure are due to insufficient postoperative spinal stability and improper instrumentation than to excessive stability and thus **stress shielding**. In this context, the related question of "adjacent segment degeneration" is discussed below in detail.

### Occipitocervical Fixation

The evolution of occipitocervical fixation started with pure **in-situ bone grafting**, after which came wire techniques, first without and later with attached steel rods, then followed by plate/screw instrumentation in the 1990s and most recently **modular combined plate-rod/screw instrumentation** [46, 99, 102]. The major advantage of the latter is its greater stability, allowing the abandonment of supplemental external fixation such as halo fixators or Minerva jackets.

Lateral mass and pedicular screw fixation is superior to sublaminar wiring or hooks for cervical fusions

Basically the same principles of posterior fixation as described above apply to the occipitocervical junction. Comparative biomechanical in-vitro studies have demonstrated that lateral mass screws, pedicle screws or transarticular screws (C1–C2) are superior to sublaminar wiring or sublaminar hooks [63]. Stability of occipital fixation depends on whether mono- or bicortical screws are used and the local occipital topography to the side of the screw placement. Cortical thickness is greatest at the midline and the superior and inferior nuchal lines [75].

## Anterior Stabilization Principles

The term "**anterior instrumentation**" is used for any surgical measure for the implantation of a stabilization device acting on the anterior column (according to

F.W. Holdsworth the **two-column concept** [43]). The surgical approach is traditionally more or less from anterior depending on the body region and the neighboring cavity. However, especially for the lumbar spine, other routes are established such as posterior lumbar interbody fusion (PLIF) or transforaminal procedures (**transforaminal lumbar interbody fusion, TLIF**) [60]. Even if in the past anterior lumbar instrumentation has been questionable for some indications in the presence of sound alternatives, in the future and with the advance of disc arthroplasty, anterior surgery will probably gain in popularity. Furthermore anterior fusion will most likely retain its position as a salvage procedure for failed disc arthroplasty.

### Interbody Fusion Technique

The technique of interbody or intercorporal fusion was introduced by Smith and Robertson in 1955 for the neck [91] and much earlier for the lumbar spine for surgically treating spinal deformity and Pott's disease by Hibbs and Albee in 1911 [5, 41] and later by Burns in 1933 for stabilizing spondylolisthesis [15]. As a surgical measure interbody fusion includes an at least partial removal of the intervertebral disc and of the cartilaginous endplates and subsequent filling-up of the disc space with (structured) bone graft or nowadays increasingly with artificial spacers (cages). **Cages** were designed and first used by G. Bagby and D. Kuslich (BAK cage) in the late 1980s; they were initially threaded hollow cylinders filled with bone graft. Nowadays a variety of cage designs are available for implantation using anterior or posterior approaches [97, 98]. Different designs (Fig. 6) are available:

- threaded, cylindrical cages
- ring-shaped cages with and without mesh structure
- box-shaped cages

Load sharing between implant and bone graft is essential for successful healing

Intervertebral cages were **originally proposed as stand-alone devices** for anterior lumbar interbody fusion (ALIF) or PLIF. While the cages retain height and provide support and stability, bony fusion occurs within and/or around the cage. However, the **biomechanical requirements** on these devices are very high: on one hand they should provide enough compressive strength to keep disc space height while stress concentration on the implant-bone interface must be minimized to reduce penetration or subsidence into the underlying cancellous vertebral body. On the other hand, the bone graft around and within the cage must be stressed and strained sufficiently to evoke the biological signals (release of cytokines) for bone formation [17, 84] (Table 2).

In this context it is proposed that extensive **stress-shielding** may lead to delayed or non-union. This conflict is reflected in most current cage geometries and materials, but further work is required to fully understand the underlying mechanobiology [30].

Peripheral endplate buttressing reduces cage subsidence

When implanting interbody devices, the partial removal of the endplate is a prerequisite for proper graft incorporation, but a bleeding cancellous bone bed may also compromise the support of the device, especially if limited contact areas are present. Resistance to implant subsidence critically depends on the quality of underlying trabecular bone [47]. However, the strength of the endplate has been

**Table 2.** Cage features for successful biological incorporation

- adequate compressive strength to maintain disc space height
- minimal stress-concentration on implant bone interface to reduce subsidence
- broad contact area between bone graft and vertebral endplate
- assurance of sufficient load sharing between implant and bone graft

**Figure 6. Cage designs**

a The first cages had a cylindrical design and were screwed into the endplates (Image © Zimmer, Inc. used by permission). b A very simple cage (DePuy Spine, Inc.) was popularized by J. Harms consisting of a ring-shaped titanium mesh. c Last generation cages are box-shaped and better buttress the endplate, which is left intact (Synthes).

shown to be greatest at its periphery in the **posterolateral corners** [53, 64], and therefore removal of the central endplate mostly does not compromise the strength of the cage/bone interface significantly [93]. Based on this information, an effective compromise between the biological and biomechanical requirements for fusion may be achieved by choosing larger implants with more peripheral contact areas, such as the Syncage [97].

Anterior cage positioning provides the best stability

Similar to endplate strength the **overall stiffness** of the stabilized spinal segment increases by a factor of three as an interbody cage is moved within the disc space towards the mechanically more advantageous anterior position [69].

Do not use stand-alone lumbar interbody cages without additional fixation

The indications for anterior fusion of the spine are various and include discitis/spondylitis and vertebral burst fractures but they are still also often controversial, especially for lumbar back pain. If the surgeon decides to remove the disc, the resulting degree of instability must be estimated before choosing the type of implant and extent of surgery. It has to be emphasized that a complete discectomy combined with the dissection of the anterior longitudinal ligament renders the spine substantially unstable for **all loading conditions**. For flexion and lateral bending, interbody devices can restore stability profoundly. However, the major disadvantage of these devices regardless of the approach (PLIF or ALIF) is the **poor control of extension and rotation** [61].

Comparison of the strict anterior with the anterolateral implantation technique has shown that resection of the anterior annulus and anterior longitudinal

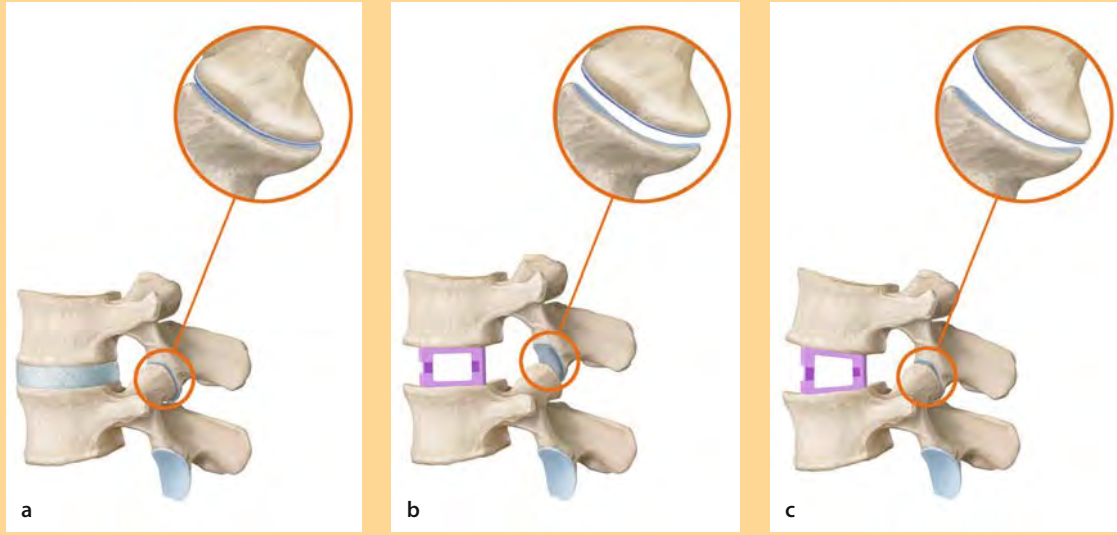


**Figure 7. Cage kinematics**

Stand-alone intervertebral cages for spinal fusion exhibit poor stabilization in extension. a Extension is normally partially limited by the facet joints. b Following the insertion of an interbody cage, the facet joints may be distracted, c thereby increasing segmental mobility.

ligament is **not** responsible for this lack of stability [62]. This has led to the opinion that stand-alone cages and anterior bone grafts cause **segmental distraction** and thereby incongruence of the facet joints (Fig. 7), which may aggravate instability [54]. The originally established concept of **"distraction compression"** by G. Bagby [8] is thus also placed into perspective again. This indicates that, with distraction of the disc space and consequent tensioned anulus fibers, a compressive force on the cage is created. However, due to the viscoelastic anulus material properties, the compressive effect most likely acts only for a short time [50]. Therefore, from the above-mentioned studies it can be concluded that posterior instrumentation with pedicle screws or translaminar screws in addition to the interbody cage must be recommended to establish the appropriate stability.

Overdistraction with a cage results in facet joint incongruency and secondary damage

A potential alternative to the above-mentioned combined instrumentation is the recent development of a novel "stand-alone" device which combines the principle of the interbody cage with **anterior tension band instrumentation** (SynFix, Synthes, USA and Switzerland). Cain et al. have compared the stabilizing properties of this screw-cage construct with conventional 360° instrumentation using cage and pedicle screws or translaminar screws. Motion analysis demonstrated a significant increase in segmental stiffness with the Synfix compared to cage/translaminar screw instrumentation in flexion-extension and rotation [16]. However, testing was non-destructive and included only a few cycles. For a definite judgment the comparative biomechanical behavior under repetitive loading (fatigue) as well as clinical results and fusion rates need to be evaluated.

The combination of anterior tension band instrumentation and a cage is a promising up-and-coming technique

In the **cervical spine** in contrast to the lumber spine, **stand-alone interbody cages** (or structural bone grafts) are used routinely after one level discectomy, exhibiting near 100% fusion rates. In a comparative biomechanical in-vitro study, D. Greene et al. assessed cervical segmental stability after implantation of interbody cages and structural bone grafts. After single-level discectomy physiological segmental stability was reestablished with both techniques, but with the cage tending to result in slightly higher stiffness [37].

Single-level stand-alone cervical cage fixation suffices in selected cases

### Corpectomy Fusion Technique

Spinal instability after single-level or even multiple-level corpectomy or vertebrectomy is a challenging task in the biomechanical sense, especially in the lumbar spine. Indications are theoretically numerous and apply for myelopathy, neoplastic and metastatic tumor growth, chronic spondylitis or severe fracture cases. However, the resulting instability, and thus the demand on the instrumentation, strongly depends on the number of involved levels and the preserved and functioning stabilizers. It is quite obvious that the function of incompetent or compromised anatomical structures has to be compensated.

Severely impaired anterior column integrity requires a combined anterior and posterior instrumentation (360°)

Pure **bisegmental** spinal stability after single-level corpectomy in the lumbar spine can theoretically be restored by pedicle screw systems [7]. However, in the absence of anterior column integrity, the posterior **bridge-construct** bears 100 % of the load and will most likely fail even in the presence of a posterior spondylodesis. This phenomenon is well known from unstable burst fractures lacking anterior support [57]. Furthermore, biomechanical tests have shown that corpectomy cages alone or in combination with an **anterior angle-stable plate fixation** are **not** capable of restoring physiological bisegmental stability. To ensure solid bony fusion it is commonly accepted that normal physiological spinal stability must be exceeded (to what extent is so far unknown). As segmental flexibility with either a stand-alone cage or a cage/anterior plate combination is especially increased in rotation, extension and lateral bending, the addition of pedicle screw fixation must be recommended to ensure a significant increase in overall stiffness [66]. Thus far, from the biomechanical perspective, fundamental anterior instability like that found after corpectomy cannot be treated with anterior or posterior measures alone.

Similarly to the lumbar spine, corpectomy in the **cervical region** is indicated for a variety of spinal pathologies: cervical myelopathy, cervical spine trauma and tumor manifestations. The stability after **single level corpectomy** and cage implantation is comparable to the range of motion (ROM) of the intact spine in all six degrees of freedom [85]. In one study, stability was even increased in all directions but extension [48]. Supplemental instrumentation must therefore also be applied. **Anterior plating** adds significant stability, particularly in rotation, which is only exceeded by posterior systems. Comparing stability of different anterior and posterior systems demonstrated that pedicle screws are more stable than lateral mass screws and constrained posterior systems are superior to unconstrained systems. The highest stability was provided by combined 360° instrumentation [85]. In a two or more level corpectomy, anterior plating may already be insufficient (see tension band technique). In this case posterior instrumentation involving lateral mass or pedicle screws adds significant stability [90].

Anterior cervical plating substantially increases spinal stability after corpectomy

## Anterior Tension Band Technique

Anterior cervical plating bears the risk of **stress-shielding** the bone graft and thus may cause non-union

Anterior cervical plates act as typical **tension bands** during extension but function as **buttress plates** during flexion. They exhibit several characteristics, e.g. excellent visibility with implantation, prevention of graft expulsion and increased fusion rates in multisegmental constructs. Anterior cervical plates are either constrained or unconstrained devices and are available as dynamic plates in various lengths.

**Constrained** cervical systems have a rigid, angle-stable connection between the plate and screws, whereas **unconstrained** systems rely on friction generated by compression of the plate on the anterior cortex. In biomechanical testing, constrained systems have shown a greater rigidity, whereas unconstrained plates can lose a significant amount of their stability over time [92]. The surgeon has the

option of selecting systems with monocortical or bicortical screw fixation, often with the same plate. Pull-out tests have demonstrated that bicortical is more stable than monocortical screw placement [92]. Further improvements in stabilization have been made using monocortical locking expansion screws, their strength being comparable to bicortical screws [74]. But no significant differences in stability were seen on kinematic testing [68]. However, bicortical screw fixation still has specific indications, e.g. for multilevel stabilization, poor bone quality or after correction of deformities, but also bears the risk of spinal cord damage.

A three-level cervical corpectomy requires anterior and posterior instrumented fusion

It has also been shown that the capability of anterior cervical plates to stabilize the spine after **three-level corpectomy** is significantly limited after fatigue loading [45], whereas no difference in stability was noted for **single-level corpectomy**. Another concern regarding the cervical spine, with its inherent mobility and relatively low compressive forces, is delayed or non-union (pseudarthrosis) due to possible **stress shielding** of the graft. This is particularly true for the latest generation of constrained (locking) plates, with which it is more difficult to set the graft under compression.

For this reason **dynamic (semi-constrained) anterior plates** were designed. Reidy et al. have shown in a cadaver corpectomy model that axial load transmission was particularly more directed to the graft with the dynamic cervical plate than with a static plate especially when the graft was **undersized** [73].

The stiffness of anterior tension band instrumentation differs from pedicle screws in all loading directions

Several systems have also been developed for anterior stabilization of the **thoracolumbar spine**, including the Ventrofix (Mathys Medical, Bettlach, Switzerland) and the Kaneda SR (DePuy Spine, Raynham, MA, USA) systems, which are used mostly for reconstruction in trauma, tumor and post-traumatic kyphosis. The load is transferred through a combination of compressive or tensile loading along the length of the implant and bending or torsion. Due to its profile and their position directly on the anterior column, bending forces are much lower than for posterior pedicle screw systems. However, their stabilizing potential is also lower, due to a shorter effective lever arm. The relative effectiveness of anterior, posterior and combined anteroposterior fixation in a corpectomy model has been addressed in a study by Wilke et al. [106]. Compared to pedicle screws, the anterior rod devices were slightly more unstable in flexion and lateral bending. In lateral bending, the implants provided better stabilization when the spine was bending away from the implant side, as the devices act as a tension band. **Double-rod** anterior systems with or without transverse elements are superior to single rod systems, and locking screws increase the stiffness.

Finally, however, in all loading directions, only **combined** anteroposterior fixation can provide complete segmental stabilization.

## Biomechanics of the "Adjacent Segment"

Adjacent segment mobility and intradiscal pressure increase with fusion length

Spondylodesis normally results in an unphysiologically long and stiff spinal segment. It has often been suggested that adjacent segment degeneration is the result of increased biomechanical stress. Shono et al. [89] have shown, in an in-vitro study, that the displacement of the adjacent motion segment is indeed increased after fusion. In these experiments, a fixed **displacement** was applied to the entire spine specimen. To produce the total displacement, the motion at the adjacent segment must increase as the motion of the fused segment decreases due to its stiffness. Increased segmental motion is paired with an **elevated intradiscal pressure**, which correlates with the number of fused levels [19, 42]. Rohlmann et al. have demonstrated, with a simplified finite element model, that

application of a **controlled load** on rigid instrumentation had only a minor influence on stresses in the adjacent discs and endplates [80]. Nevertheless, in another in-vitro study, application of controlled loads resulted in small but significant **increases** in adjacent segment mobility [9].

The cause (mechanical overload or natural history) of adjacent segment degeneration remains unclear

It can be questioned whether "**adjacent segment degeneration**" is a result of altered biomechanical stresses or a natural progression of the disease. This issue depends on whether adjacent segment motion is indeed increased in vivo following fusion. An animal study by Dekutowski et al. provides some support for increased adjacent segment motion [25]. Taken together, to date and despite numerous clinical and biomechanical studies, it still remains unclear whether the changed biomechanics or the progression of the natural history is responsible for adjacent segment degeneration. However, the overall incidence of adjacent segment degeneration would likely be much higher if its cause were purely mechanical. It is well accepted that disc degeneration is a multifactorial disease with genetic and environmental factors [10]. To what **extent** mechanical factors contribute to the disease likely also determines whether or not disc degeneration is initiated or aggravated adjacent to a fused segment.

## Non-Fusion Principles

Non-fusion devices may not be superior to instrumented spinal fusion in low back pain

The aims of non-fusion devices are the stabilization and reestablishment of normal segmental anatomy including the **preservation of segmental motion** and thus without performing a spondylodesis. Several approaches have been described to replacing certain parts of the motion segment or to adding supporting stabilization. Depending on the primary pathology of the mostly multifactorial problem, disc arthroplasty, nucleoplasty or posterior dynamic stabilization is performed. Several different devices for various indications are nowadays on the market, or are currently under way, e.g. facet arthroplasty. All of these have in common that no prospective and controlled clinical trials (class I or II evidence) which comparatively assess the clinical outcomes are available or that the follow-up time is too short for a definitive judgment.

### Disc Arthroplasty

Disc arthroplasty preserves spinal motion, makes bone harvest unnecessary and may abolish or delay adjacent segment disease

Functional disc replacement is a logical progression in the treatment of degenerative disorders of the disc. Arthroplasty in the spine has several potential advantages: preservation of segmental motion, lower rate of adjacent level degeneration and no need for harvesting autologous bone graft.

An excellent review of the field of disc arthroplasty by Szpalski et al. highlights the historical development and the different design concepts to date [95]. The demands on the material properties and function of such devices are substantial. They must not only possess sufficient strength to withstand compressive and shear loads transmitted through the spinal column, but must also respect the complex kinematics of intervertebral motion.

The design concepts of TKA are still evolving

The **design philosophy** of many current disc prostheses reflects the evolution of other total joint prostheses. In total knee arthroplasty (TKA), for example, there has been the tendency towards implants which emulate physiological motion patterns. Unlike in conventional TKA, mobile bearing knee prostheses employ a conforming polyethylene plate which moves on the surface of a highly polished metallic tray which itself is affixed to the tibial plateau. Due to its conformity throughout the full range of motion, stresses transmitted through the polyethylene and into the bone should be lower and thus reduce polymer wear and prosthesis loosening.

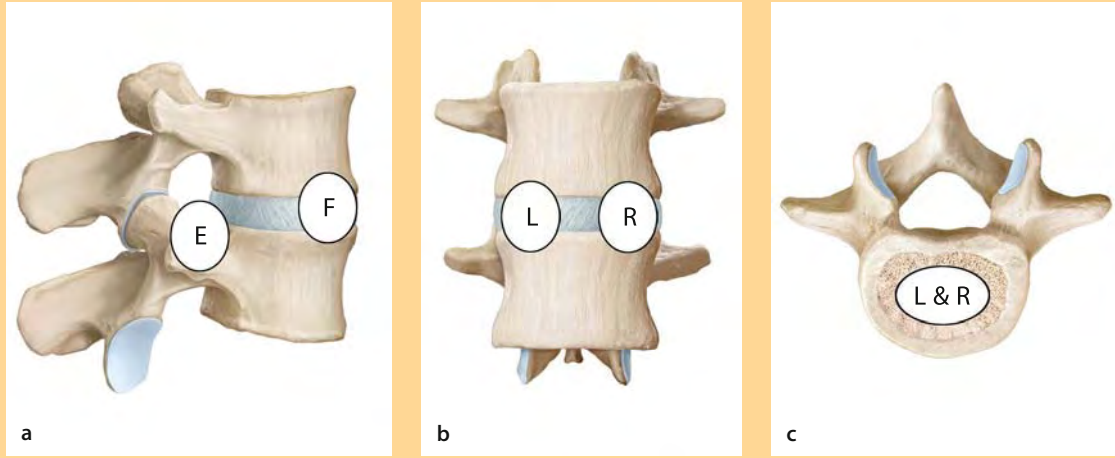


**Figure 8. Center of rotation**

The kinematics of the intervertebral joint is complex. a The center of rotation moves during flexion/extension, b left and right side bending c and left and right torsion. Current designs for intervertebral prostheses or dynamic stabilization systems aim to respect this unique characteristic of spinal motion.

Disc prostheses are confronted with a complex segmental spinal motion pattern

As in the knee, motion of the natural intervertebral joint **cannot** be compared to a simple ball-and-socket joint. Segmental motion in flexion and extension is a combination of sagittal rotation plus translation. This is also referred to as the **helical axis of motion**. Thus, the **instantaneous axis of rotation** constantly changes throughout the full range of motion (Fig. 8).

This principle is reflected in the Bryan Cervical Disc System (Medtronic), which comprises a low friction elastic nucleus located between titanium endplates and a sealing flexible membrane, allowing free rotation and some **translation** in all directions. Similarly the Charité artificial disc (DePuy Spine) consists of cobalt chromium endplates and a floating polyethylene sliding core also enabling translation and rotation. In contrast, the ProDisc (Synthes) and Maverick Artificial Disc (Medtronic) are **constrained** devices with a single articulation, allowing free rotation in all directions around a fixed center of rotation. Unconstrained devices allow a greater range of motion and theoretically prevent excessive facet loads in extreme motion. In contrast constrained disc arthroplasties may reduce shear force on the posterior elements [44]. Only comparative prospective clinical trials can conclusively show if any of these concepts is advantageous for the patient [31]. The Charité and ProDisc were the first protheseses involved in an FDA trial (Fig. 9).

Current disc prostheses almost reestablish a physiological range of motion

As with other total joint prostheses, the stability of the prosthesis and the motion segment likely depends on well balanced ligaments and surrounding soft tissues. Therefore, precise operation technique with **retention of stabilizing tissue** is essential for a good outcome. Wear of prosthesis components, as in other arthroplasties, likely occurs. **Histocompatibility** was tested for titanium and polyethylene particles in animal models, and neither material induced a strong inflammatory host response [6, 18]. Finally, the kinematics of each new device must be verified against representative motion patterns of the normal spine [22]. In one study by DiAngelo et al., spinal kinematics before and after implantation of a cervical disc prosthesis (ProDisc) was compared with spondylodesis. Using a **displacement-controlled** protocol, with the prosthesis in place almost **no alteration in motion patterns** could be recorded compared to the intact state, unlike in the fusion case where the adjacent segments compensated for the fused level to




**Figure 9. Designs of total disc arthroplasty**

Current intervertebral disc prostheses differ in the bearing material used (polyethylene or metal alloys) and have either a fixed (constrained) center of rotation (e.g. **a** Prodisc, Synthes) or follow the segmental helical axis of motion (semi-constrained) as in **b** the Charité prothesis (DuPuy Spine Inc.).

achieve full motion [26]. This is in agreement with Puttlitz et al., who demonstrated an establishment of an approximate physiological kinetics in all six degrees of freedom with cervical disc arthroplasty [70]. In another biomechanical in-vitro study, Cunningham et al. compared the Charité disc prothesis with an interbody fusion device (BAK) with and without posterior instrumentation. Unlike interbody fusion, also in the lumbar spine the disc prosthesis exhibited a near physiological segmental motion pattern in all axes except rotation, which was increased [23].

Only few data exist so far about the lifetime of disc prostheses, preservation of motion and long-term patient satisfaction. Therefore, total disc replacement still has to establish its position against spondylodesis [24, 71, 101].

## Nucleoplasty

Nucleoplasty is an intriguing evolving new surgical technique

In contrast to total disc arthroplasty, replacement of only the degenerated or excised nucleus pulposus is an option offered by the Prosthetic Disc Nucleus (PDN, Raymedica Inc., Minneapolis, USA). The PDN is a hydroactive implant which mimics the natural fluid exchange of the nucleus by swelling when unloaded and expressing water under compressive load. Wilke et al. [105] have shown that the PDN implant can restore disc height and range of motion after nucleotomy to normal values. There is, however, little data on the long-term biomechanical behavior of such implants in the intervertebral disc space, and the overall effectiveness of replacing only the nucleus pulposus in a degenerated disc.

## Posterior Dynamic Stabilization Technique

Indications for dynamic posterior stabilizing devices are difficult to define

Non-rigid posterior stabilization of the spine is another concept for the treatment of various spinal pathologies. In 1992, **H. Graf** introduced the **ligamentoplasty**, a posterior dynamic stabilization system consisting of pedicle screws which were connected via elastic polyester elements [36]. The underlying theory is the maintenance of physiological lordosis while flexion-extension motion is restricted and therefore the respective disc is unloaded and thus "protected". Kinematic in-vitro studies have shown that, after laminectomy and partial

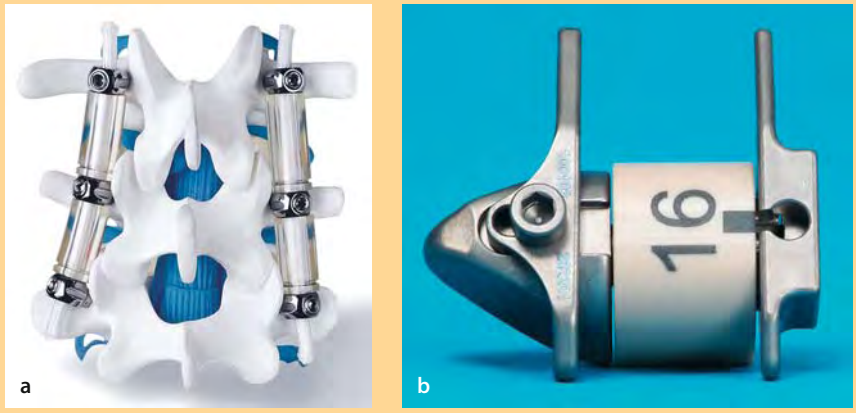


**Figure 10. Non-fusion spinal stabilization devices**

a Dynamic posterior spinal stabilization with Dynesys (Image © Zimmer, Inc. used by permisson. b Interspinous process distraction devices (e.g. X-stop) limit extension motion and unload the facet joints. The aim is to improve functional spinal stenosis by indirect widening of the spinal canal.

removal of the facet joint with Graf ligamentoplasty, flexibility is significantly reduced in all directions compared to the intact state [94]. However, clinical studies report conflicting data about the clinical success [35, 56].

The stabilizing properties of Dynesys largely exceed physiological stability

Nowadays the most often used device is the **dynamic neutralization system (Dynesys)** for the spine (Zimmer, Warsaw, USA). Dynesys (Fig. 10a) is a non-fusion pedicle screw system composed of titanium pedicle screws joined by polycarbonate urethane (PCU) spacers containing pre-tensioned polyethylene terephthalate (PET) cords. With such a system, the affected segments can be distracted and disc height restored and kinematics in all planes are restricted. However, motion is not absolutely prevented, in contrast to solid fusion implants. Schmoelz et al. compared the kinematics of Dynesys stabilized segments with an internal fixator using destabilized cadaver specimens. They demonstrated that Dynesys was able to improve stability in all dimensions. However, axial rotation was poorly controlled while in lateral bending and flexion the system was as stiff as the internal fixator. Only in extension was Dynesys able to restore the physiological state [86].

Posterior dynamic systems are challenged by the required long lift time cycle

Freudiger et al. [32] have demonstrated that the Dynesys limits shear translation and bulging of the posterior anulus in the unstable spine segment under physiological loading. Due to the compliance of the instrumentation, overloading of adjacent segments may be prevented. However, unlike with the spondylodesis the instrumentation must bear certain loads throughout its whole life. Thereby material fatigue and pedicle screw loosening may result in ultimate failure. The efficacy of such a system depends heavily on the condition of the anterior column and no one knows so far how much stability or flexibility is actually needed in each particular case.

## Interspinous Process Distraction Technique

The principle of implanting a spacer between adjacent spinous processes was already used by F. Knowles in the late 1950s to unload the posterior anulus in patients with disc herniation and thereby achieving pain relief [104]. In recent years various systems have entered the market such as the Interspinous "U" (Fixano, Péronnas, France), the Diam (Medtronic, Memphis, USA), the Wallis

(Spine Next, Bordeaux, France) and the X-Stop (St. Francis Medical Technologies, Concord, USA) (Fig. 10b) systems. Only few biomechanical and no high-quality clinical studies are currently available.

Interspinous devices decrease extension and aim to widen the spinal canal

All devices aim to **limit motion in extension**. Biomechanical testing has shown that extension motion is indeed decreased while flexion, axial rotation and lateral bending stay unaffected [52]. Limited extension is thought to reduce narrowing of the spinal canal and flavum buckling [88]. Furthermore, Lindsey et al. demonstrated an **unloading of the facet joint** in an in-vitro cadaver study using pressure sensitive foil [107].

But how far the resulting **increase of segmental kyphosis** is compensated by the adjacent segments and how this may affect the sagittal profile and balance in the long term need to be evaluated in the future. However, for patients with spinal stenosis and neurogenic claudication which improves in flexion, the interspinous device is a feasible option especially with regard to the limited trauma with implantation.

## Recapitulation

**Goals of spinal instrumentation.** The aims of spinal instrumentation are stabilization, achievement and maintenance of curve correction (alignment) and facilitation of bony fusion (spondylodesis). Knowledge of the underlying **fundamental biomechanical principles** helps to prevent material failure and thus improves surgical outcome. Several basic properties of spinal implants have to be considered: **material strength**, the ability to provide **segmental stability** and the **resistance to fatigue** with cyclic loading. Unfortunately it is still unclear how much stability is required in each particular case to ensure spinal fusion. Generally the instrumentation aims to exceed the physiological state, e.g. to make the motion segment stiffer.

**Loading and load sharing characteristics.** Spinal instrumentation and the stabilized spine segment form a system which **shares loads and moments**. In-vivo telemetric measures have given valuable insight into device loading patterns. Forces acting on the implant depend on the **degree of instability**. It has been shown that rod/pedicle screw implants are mainly loaded with compression forces and bending moments. Load sharing between the implant and bone graft is mandatory for successful bone healing. In contrast, extreme **stress-shielding** may result in pseudarthrosis.

**Pedicle screw technique.** Pedicle screw/rod instrumentation has been well established for the surgical treatment of almost all spinal disorders. Unless there is a substantial incompetence of the anterior column, pedicle screw systems **provide excellent stability** in mono- and multisegmental applications. Choosing **convergent screw trajectories** and **cross-linked rods** may enhance stability.

**Translaminar and transarticular screws.** The translaminar route should be favored over the direct transarticular trajectory in degenerative disorders and in conjunction with anterior interbody fusion.

**Occipitocervical fixation.** Modular plate-rod/screw instrumentation is available. **Lateral mass screws**, **transarticular screws** (C1–C2) and **pedicle screws** provide increased stability compared to laminar hooks and wires. Therefore additional external support with halo fixation, etc., has mostly been abandoned.

**Interbody fusion technique.** Lumbar interbody cages are designed to provide sufficient strength to keep disc space height without the necessity for using structural bone grafts. Originally implanted as **stand-alone cages**, which led to noticeable pseudarthrosis rates, they are nowadays routinely **combined with additional instrumentation** (pedicle screws/translaminar screws or anterior tension band) due to the poor control of extension/distraction and rotation. **Meticulous endplate preparation** is mandatory to ensure bony fusion. Anterior cage position is advantageous in terms of stability. Endplate strength is highest in the periphery. In the cervical spine, however, after single level discectomy and "stand-alone" cage implantation near 100 % fusion rates are achieved.

**Corpectomy fusion technique.** Spinal instability after **corpectomy or after vertebrectomy** in the lumbar spine often requires complex reconstructive procedures. The type and degree of instrumentation depend strongly on the number of involved levels and the retained functioning stabilizing structures. Generally, after corpectomy **anterior support is mandatory** and long-term stability cannot be achieved with rod/pedicle screw instrumentation alone. Furthermore, the combination with an anterior tension band device still exhibits a certain instability in extension and rotation. Therefore, from the biomechanical perspective, substantial anterior instability requires **"front and back" instrumentation**. In the cervical spine, however, single-level cage stabilization is sufficiently supported by an anterior tension band device. **Multiple-level cervical corpectomies** are particularly unstable and anterior plating may be insufficient; consequently **additional pedicle/lateral mass screw devices must be considered**.

**Anterior tension band technique.** Anterior rods/plates act as tension bands in extension and function as buttress plates in flexion. For the cervical spine, the latest generation of "**semi-constrained/dynamic**" plates allow locked angle-stable monocortical screw fixation while axial compression of the graft is permitted. This offers increased stability combined with a minimized risk of stress-shielding. In the lumbar spine, **anterior rod/double-rod instrumentation** increases anterior stability after cage or graft implantation especially in extension. In flexion and lateral bending they are still inferior to pedicle screw devices.

**Biomechanics of the "adjacent segment".** Unphysiologically long and stiff spinal segments increase motion and intradiscal pressure in the adjacent segments. However, it is still unclear if adjacent segment degeneration after spinal fusion is resulting from the **changed biomechanics or** exhibits simply the progression of the **natural history**.

**Disc arthroplasty.** Disc arthroplasty offers several advantages such as preservation of segmental motion, potential absence of adjacent segment degeneration and no need for harvesting autologous bone graft. Current prostheses differ in bearing materials (metal or polyethylene) and kinematics principles. **Constrained prostheses** have a fixed center of rotation whereas **unconstrained devices** allow translational movement and thus respect the physiological helical axis of motion. **Kinematics** studies have shown that both types successfully reestablish almost the physiological range of motion. Only a few data exist so far on the long-term radiological and clinical outcome.

**Posterior dynamic stabilization technique.** Improving primary or iatrogenic spinal instability while "unloading/protecting" certain spine elements without performing a spinal fusion are the objectives of posterior dynamic implants. **All systems successfully reduce segmental motion**. However, rotation is poorly controlled while the posterior devices are particularly stiff in flexion. As it is unknown how much stability is needed in which particular entity of spine pathology combined with the partially undefined clinical indications, an assessment of this technique is currently impossible. Finally, only long-term prospective clinical trials will give the necessary evidence for the efficacy of this particular treatment method.

## Key Articles

**Cripton PA, Jain GM, Wittenberg RH, Nolte LP (2000) Load-sharing characteristics of stabilized lumbar spine segments. Spine 25:170 – 179**
Biomechanical cadaver study using pressure sensors, strain gauges and an optoelectronic tracking system. Load-sharing between an internal fixator and anatomical structures was assessed in a sequential injury scenario. Applied loads were mostly supported by equal and opposite forces between disc and fixator. Based on the results, the paper highlights the fact that an anterior column insufficiency may lead to fixator overloads and implant failure.

**Laxer E (1994) A further development in spinal instrumentation. Technical Commission for Spinal Surgery of the ASIF. Eur Spine J 3:347 – 352**
Introduction of the Universal Spine System with a single set of implants and instruments for various spinal disorders and surgical approaches.

**Magerl FP (1984) Stabilization of the lower thoracic and lumbar spine with external skeletal fixation. Clin Orthop Relat Res 125 – 141**
Classic article introducing the concept of a new angle-stable transpedicular fixation device which formed the basis for the development of second generation internal spinal fixation devices.

**Panjabi MM (1988) Biomechanical evaluation of spinal fixation devices: I. A conceptual framework. Spine 13:1129 – 1134**

**Panjabi M, Abumi K, Duranceau J, Crisco J (1988) Biomechanical evaluation of spinal fixation devices: II. Stability provided by eight internal fixation devices. Spine 13:1135 – 1140**

**Abumi K, Panjabi MM, Duranceau J (1989) Biomechanical evaluation of spinal fixation devices. Part III. Stability provided by six spinal fixation devices and interbody bone graft. Spine 14:1249 – 1255**
These three publications are milestone papers as they introduced the basic concepts for testing and evaluation of spinal implants. Guidelines for three categorical biomechanical tests are stated: assessment of strength, fatigue and stability.

**Tsantrizos A, Andreou A, Aebi M, Steffen T (2000) Biomechanical stability of five stand-alone anterior lumbar interbody fusion constructs. Eur Spine J 9:14 – 22**
The authors compared five different stand-alone cages with respect to stabilizing properties (kinematics) and pull-out strength using human specimens. The results demonstrated a general stabilizing effect of all implants but load/displacement curves also suggested micro-instability. Influencing factors of the cage design concerning dimensions, height and wedge angle were pointed out.

## References


1. Abumi K, Panjabi MM, Duranceau J (1989) Biomechanical evaluation of spinal fixation devices. Part III. Stability provided by six spinal fixation devices and interbody bone graft. Spine 14:1249 – 1255
2. Aebi M, Etter C, Kehl T, Thalgott J (1988) The internal skeletal fixation system. A new treatment of thoracolumbar fractures and other spinal disorders. Clin Orthop Relat Res 227: 30 – 43
3. Aebi M, Etter C, Kehl T, Thalgott J (1987) Stabilization of the lower thoracic and lumbar spine with the internal spinal skeletal fixation system. Indications, techniques, and first results of treatment. Spine 12:544 – 551
4. Aebi M, Thalgott JS, Webb JK (1998) AO ASIF principles in spine surgery. Springer-Verlag, Berlin Heidelberg New York
5. Albee FH (1972) The classic. Transplantation of a portion of the tibia into the spine for Pott's disease. A preliminary report. JAMA 57:885, 1911. Clin Orthop Relat Res 87:5 – 8
6. Anderson PA, Rouleau JP, Bryan VE, Carlson CS (2003) Wear analysis of the Bryan cervical disc prosthesis. Spine 28:S186 – 194
7. Arand M, Wilke HJ, Schultheiss M, Hartwig E, Kinzl L, Claes L (2000) Comparative stability of the "Internal Fixator" and the "Universal Spine System" and the effect of cross-linking transfixating systems. A biomechanical in vitro study. Biomed Tech (Berl) 45: 311 – 316
8. Bagby GW (1988) Arthrodesis by the distraction-compression method using a stainless steel implant. Orthopedics 11:931 – 934
9. Bastian L, Lange U, Knop C, Tusch G, Blauth M (2001) Evaluation of the mobility of adjacent segments after posterior thoracolumbar fixation: a biomechanical study. Eur Spine J 10: 295 – 300
10. Battie MC, Videman T, Parent E (2004) Lumbar disc degeneration: epidemiology and genetic influences. Spine 29:2679 – 2690
11. Benzel EC (2001) Biomechanics of spine stabilization, 1st edn. American Association of Neurological Surgeons, Rolling Meadows, IL
12. Berlemann U, Cripton P, Nolte LP, Lippuner K, Schlapfer F (1995) New means in spinal pedicle hook fixation. A biomechanical evaluation. Eur Spine J 4:114 – 122
13. Boos N, Webb JK (1997) Pedicle screw fixation in spinal disorders: a European view. Eur Spine J 6:2 – 18
14. Boucher HH (1959) A method of spinal fusion. J Bone Joint Surg Br 41B:248 – 259
15. Burns BH (1933) An operation for spondylolisthesis. Lancet 224:1233 – 1239

16. Cain CM, Schleicher P, Gerlach R, Pflugmacher R, Scholz M, Kandziora F (2005) A new stand-alone anterior lumbar interbody fusion device: biomechanical comparison with established fixation techniques. Spine 30:2631 – 2636
17. Carlisle E, Fischgrund JS (2005) Bone morphogenetic proteins for spinal fusion. Spine J 5:S240 – 249
18. Chang BS, Brown PR, Sieber A, Valdevit A, Tateno K, Kostuik JP (2004) Evaluation of the biological response of wear debris. Spine J 4:239S–244S
19. Chow DH, Luk KD, Evans JH, Leong JC (1996) Effects of short anterior lumbar interbody fusion on biomechanics of neighboring unfused segments. Spine 21:549 – 555
20. Cotrel Y, Dubousset J (1984) A new technic for segmental spinal osteosynthesis using the posterior approach. Rev Chir Orthop Reparatrice Appar Mot 70:489 – 494
21. Cripton PA, Jain GM, Wittenberg RH, Nolte LP (2000) Load-sharing characteristics of stabilized lumbar spine segments. Spine 25:170 – 179
22. Cunningham BW (2004) Basic scientific considerations in total disc arthroplasty. Spine J 4:219S – 230S
23. Cunningham BW, Gordon JD, Dmitriev AE, Hu N, McAfee PC (2003) Biomechanical evaluation of total disc replacement arthroplasty: an in vitro human cadaveric model. Spine 28: S110 – 117
24. de Kleuver M, Oner FC, Jacobs WC (2003) Total disc replacement for chronic low back pain: background and a systematic review of the literature. Eur Spine J 12:108 – 116
25. Dekutoski MB, Schendel MJ, Ogilvie JW, Olsewski JM, Wallace LJ, Lewis JL (1994) Comparison of in vivo and in vitro adjacent segment motion after lumbar fusion. Spine 19: 1745 – 1751
26. DiAngelo DJ, Foley KT, Morrow BR, Schwab JS, Song J, German JW, Blair E (2004) In vitro biomechanics of cervical disc arthroplasty with the ProDisc-C total disc implant. Neurosurg Focus 17:E7
27. Dick W, Kluger P, Magerl F, Woersdorfer O, Zach G (1985) A new device for internal fixation of thoracolumbar and lumbar spine fractures: the 'fixateur interne'. Paraplegia 23:225 – 232
28. Dvorak M, MacDonald S, Gurr KR, Bailey SI, Haddad RG (1993) An anatomic, radiographic, and biomechanical assessment of extrapedicular screw fixation in the thoracic spine. Spine 18:1689 – 1694
29. Eggli S (1994). Steifigkeitsanalyse von transpedikulären multisegmentalen Fixationssystemen der Wirbelsäule. Medizinische Fakultät, Universität Bern, Bern
30. Epari DR, Kandziora F, Duda GN (2005) Stress shielding in box and cylinder cervical interbody fusion cage designs. Spine 30:908 – 914
31. Ferguson SJ, Tolkmitt F, Nolte L-P (2004) Kinematic analysis of intervertebral disc prostheses. Proceedings of the 14th Conference of the European Society of Biomechanics. 's Hertogenbosch, The Netherlands
32. Freudiger S, Dubois G, Lorrain M (1999) Dynamic neutralisation of the lumbar spine confirmed on a new lumbar spine simulator in vitro. Arch Orthop Trauma Surg 119:127 – 132
33. Fritzell P, Hagg O, Wessberg P, Nordwall A (2002) Chronic low back pain and fusion: a comparison of three surgical techniques: a prospective multicenter randomized study from the Swedish lumbar spine study group. Spine 27:1131 – 1141
34. Gaines RW, Jr. (2000) The use of pedicle-screw internal fixation for the operative treatment of spinal disorders. J Bone Joint Surg Am 82-A:1458 – 1476
35. Gardner A, Pande KC (2002) Graf ligamentoplasty: a 7-year follow-up. Eur Spine J 11 Suppl 2:S157 – 163
36. Graf H (1992) Lumbar instability. Rachis 412:123 – 137
37. Greene DL, Crawford NR, Chamberlain RH, Park SC, Crandall D (2003) Biomechanical comparison of cervical interbody cage versus structural bone graft. Spine J 3:262 – 269
38. Guidera KJ, Hooten J, Weatherly W, Highhouse M, Castellvi A, Ogden JA, Pugh L, Cook S (1993) Cotrel-Dubousset instrumentation. Results in 52 patients. Spine 18:427 – 431
39. Halvorson TL, Kelley LA, Thomas KA, Whitecloud TS, 3rd, Cook SD (1994) Effects of bone mineral density on pedicle screw fixation. Spine 19:2415 – 2420
40. Harrington PR (1962) Treatment of scoliosis. Correction and internal fixation by spine instrumentation. J Bone Joint Surg Am 44-A:591 – 610
41. Hibbs RA (1964) The classic: the original paper appeared in the New York Medical Journal 93:1013, 1911. I. An operation for progressive spinal deformities: a preliminary report of three cases from the service of the orthopaedic hospital. Clin Orthop Relat Res 35:4 – 8
42. Hilibrand AS, Robbins M (2004) Adjacent segment degeneration and adjacent segment disease: the consequences of spinal fusion? Spine J 4:190S–194S
43. Holdsworth FW (1964) Fractures and dislocations of the lower thoracic and lumbar spines, with and without neurological involvement. Curr Pract Orthop Surg 23:61 – 83
44. Huang RC, Girardi FP, Cammisa FP, Jr., Wright TM (2003) The implications of constraint in lumbar total disc replacement. J Spinal Disord Tech 16:412 – 417
45. Isomi T, Panjabi MM, Kato Y, Wang JL (2000) Radiographic parameters for evaluating the neurological spaces in experimental thoracolumbar burst fractures. J Spinal Disord 13: 404 – 411

46. Jeanneret B (1996) Posterior rod system of the cervical spine: a new implant allowing optimal screw insertion. Eur Spine J 5:350 – 356
47. Jost B, Cripton PA, Lund T, Oxland TR, Lippuner K, Jaeger P, Nolte LP (1998) Compressive strength of interbody cages in the lumbar spine: the effect of cage shape, posterior instrumentation and bone density. Eur Spine J 7:132 – 141
48. Kandziora F, Pflugmacher R, Schaefer J, Scholz M, Ludwig K, Schleicher P, Haas NP (2003) Biomechanical comparison of expandable cages for vertebral body replacement in the cervical spine. J Neurosurg 99:91 – 97
49. Kandziora F, Schleicher P, Scholz M, Pflugmacher R, Eindorf T, Haas NP, Pavlov PW (2005) Biomechanical testing of the lumbar facet interference screw. Spine 30:E34 – 39
50. Kettler A, Wilke HJ, Dietl R, Krammer M, Lumenta C, Claes L (2000) Stabilizing effect of posterior lumbar interbody fusion cages before and after cyclic loading. J Neurosurg 92: 87 – 92
51. Laxer E (1994) A further development in spinal instrumentation. Technical Commission for Spinal Surgery of the ASIF. Eur Spine J 3:347 – 352
52. Lindsey DP, Swanson KE, Fuchs P, Hsu KY, Zucherman JF, Yerby SA (2003) The effects of an interspinous implant on the kinematics of the instrumented and adjacent levels in the lumbar spine. Spine 28:2192 – 2197
53. Lowe TG, Hashim S, Wilson LA, O'Brien MF, Smith DA, Diekmann MJ, Trommeter J (2004) A biomechanical study of regional endplate strength and cage morphology as it relates to structural interbody support. Spine 29:2389 – 2394
54. Lund T, Oxland TR, Jost B, Cripton P, Grassmann S, Etter C, Nolte LP (1998) Interbody cage stabilisation in the lumbar spine: biomechanical evaluation of cage design, posterior instrumentation and bone density. J Bone Joint Surg Br 80:351 – 359
55. Magerl FP (1984) Stabilization of the lower thoracic and lumbar spine with external skeletal fixation. Clin Orthop Relat Res 189:125 – 141
56. Markwalder TM, Wenger M (2003) Dynamic stabilization of lumbar motion segments by use of Graf's ligaments: results with an average follow-up of 7.4 years in 39 highly selected, consecutive patients. Acta Neurochir (Wien) 145:209 – 214; discussion 214
57. McLain RF, Sparling E, Benson DR (1993) Early failure of short-segment pedicle instrumentation for thoracolumbar fractures. A preliminary report. J Bone Joint Surg Am 75:162 – 167
58. Montesano PX, Magerl F, Jacobs RR, Jackson RP, Rauschning W (1988) Translaminar facet joint screws. Orthopedics 11:1393 – 1397
59. Morgenstern W, Ferguson SJ, Berey S, Orr TE, Nolte LP (2003) Posterior thoracic extrapedicular fixation: a biomechanical study. Spine 28:1829 – 1835
60. Mummaneni PV, Rodts GE, Jr. (2005) The mini-open transforaminal lumbar interbody fusion. Neurosurgery 57:256 – 261
61. Nibu K, Panjabi MM, Oxland T, Cholewicki J (1997) Multidirectional stabilizing potential of BAK interbody spinal fusion system for anterior surgery. J Spinal Disord 10:357 – 362
62. Nydegger T, Oxland TR, Hoffer Z, Cottle W, Nolte LP (2001) Does anterolateral cage insertion enhance immediate stabilization of the functional spinal unit? A biomechanical investigation. Spine 26:2491 – 2497
63. Oda I, Abumi K, Sell LC, Haggerty CJ, Cunningham BW, McAfee PC (1999) Biomechanical evaluation of five different occipito-atlanto-axial fixation techniques. Spine 24:2377 – 2382
64. Oxland TR, Grant JP, Dvorak MF, Fisher CG (2003) Effects of endplate removal on the structural properties of the lower lumbar vertebral bodies. Spine 28:771 – 777
65. Panjabi MM (1988) Biomechanical evaluation of spinal fixation devices: I. A conceptual framework. Spine 13:1129 – 1134
66. Pflugmacher R, Schleicher P, Schaefer J, Scholz M, Ludwig K, Khodadadyan-Klostermann C, Haas NP, Kandziora F (2004) Biomechanical comparison of expandable cages for vertebral body replacement in the thoracolumbar spine. Spine 29:1413 – 1419
67. Phillips FM, Cunningham B, Carandang G, Ghanayem AJ, Voronov L, Havey RM, Patwardhan AG (2004) Effect of supplemental translaminar facet screw fixation on the stability of stand-alone anterior lumbar interbody fusion cages under physiologic compressive preloads. Spine 29:1731 – 1736
68. Pitzen T, Wilke HJ, Caspar W, Claes L, Steudel WI (1999) Evaluation of a new monocortical screw for anterior cervical fusion and plating by a combined biomechanical and clinical study. Eur Spine J 8:382 – 387
69. Polly DW, Jr., Klemme WR, Cunningham BW, Burnette JB, Haggerty CJ, Oda I (2000) The biomechanical significance of anterior column support in a simulated single-level spinal fusion. J Spinal Disord 13:58 – 62
70. Puttlitz CM, Rousseau MA, Xu Z, Hu S, Tay BK, Lotz JC (2004) Intervertebral disc replacement maintains cervical spine kinetics. Spine 29:2809 – 2814
71. Putzier M, Funk JF, Schneider SV, Gross C, Tohtz SW, Khodadadyan-Klostermann C, Perka C, Kandziora F (2006) Charité total disc replacement – clinical and radiographical results after an average follow-up of 17 years. Eur Spine J 15:183 – 195
72. Rathonyi GC, Oxland TR, Gerich U, Grassmann S, Nolte LP (1998) The role of supplemental

translaminar screws in anterior lumbar interbody fixation: a biomechanical study. Eur Spine J 7:400 – 407
73. Reidy D, Finkelstein J, Nagpurkar A, Mousavi P, Whyne C (2004) Cervical spine loading characteristics in a cadaveric C5 corpectomy model using a static and dynamic plate. J Spinal Disord Tech 17:117 – 122
74. Richter M, Wilke HJ, Kluger P, Claes L, Puhl W (1999) Biomechanical evaluation of a newly developed monocortical expansion screw for use in anterior internal fixation of the cervical spine. In vitro comparison with two established internal fixation systems. Spine 24:207 – 212
75. Roberts DA, Doherty BJ, Heggeness MH (1998) Quantitative anatomy of the occiput and the biomechanics of occipital screw fixation. Spine 23:1100 – 1107; discussion 1107 – 1108
76. Rohlmann A, Bergmann G, Graichen F, Mayer HM (1998) Influence of muscle forces on loads in internal spinal fixation devices. Spine 23:537 – 542
77. Rohlmann A, Bergmann G, Graichen F, Mayer HM (1995) Telemeterized load measurement using instrumented spinal internal fixators in a patient with degenerative instability. Spine 20:2683 – 2689
78. Rohlmann A, Bergmann G, Graichen F, Neff G (1999) Braces do not reduce loads on internal spinal fixation devices. Clin Biomech (Bristol, Avon) 14:97 – 102
79. Rohlmann A, Bergmann G, Graichen F, Weber U (1997) Comparison of loads on internal spinal fixation devices measured in vitro and in vivo. Med Eng Phys 19:539 – 546
80. Rohlmann A, Calisse J, Bergmann G, Weber U (1999) Internal spinal fixator stiffness has only a minor influence on stresses in the adjacent discs. Spine 24:1192 – 1195; discussion 1195 – 1196
81. Rohlmann A, Graichen F, Weber U, Bergmann G (2000) 2000 Volvo Award winner in biomechanical studies: Monitoring in vivo implant loads with a telemeterized internal spinal fixation device. Spine 25:2981 – 2986
82. Roy-Camille R, Roy-Camille M, Demeulenaere C (1970) [Osteosynthesis of dorsal, lumbar, and lumbosacral spine with metallic plates screwed into vertebral pedicles and articular apophyses]. Presse Med 78:1447 – 1448
83. Samartzis D, Shen FH, Lyon C, Phillips M, Goldberg EJ, An HS (2004) Does rigid instrumentation increase the fusion rate in one-level anterior cervical discectomy and fusion? Spine J 4:636 – 643
84. Sato M, Ochi T, Nakase T, Hirota S, Kitamura Y, Nomura S, Yasui N (1999) Mechanical tension-stress induces expression of bone morphogenetic protein (BMP)-2 and BMP-4, but not BMP-6, BMP-7, and GDF-5 mRNA, during distraction osteogenesis. J Bone Miner Res 14:1084 – 1095
85. Schmidt R, Wilke HJ, Claes L, Puhl W, Richter M (2005) Effect of constrained posterior screw and rod systems for primary stability: biomechanical in vitro comparison of various instrumentations in a single-level corpectomy model. Eur Spine J 14:372 – 380
86. Schmoelz W, Huber JF, Nydegger T, Dipl I, Claes L, Wilke HJ (2003) Dynamic stabilization of the lumbar spine and its effects on adjacent segments: an in vitro experiment. J Spinal Disord Tech 16:418 – 423
87. Seitsalo S, Osterman K, Hyvarinen H, Schlenzka D, Poussa M (1990) Severe spondylolisthesis in children and adolescents. A long-term review of fusion in situ. J Bone Joint Surg Br 72:259 – 265
88. Senegas J (2002) Mechanical supplementation by non-rigid fixation in degenerative intervertebral lumbar segments: the Wallis system. Eur Spine J 11 Suppl 2:S164 – 169
89. Shono Y, Kaneda K, Abumi K, McAfee PC, Cunningham BW (1998) Stability of posterior spinal instrumentation and its effects on adjacent motion segments in the lumbosacral spine. Spine 23:1550 – 1558
90. Singh K, Vaccaro AR, Kim J, Lorenz EP, Lim TH, An HS (2003) Biomechanical comparison of cervical spine reconstructive techniques after a multilevel corpectomy of the cervical spine. Spine 28:2352 – 2358; discussion 2358
91. Smith GW, Robinson RA (1958) The treatment of certain cervical-spine disorders by anterior removal of the intervertebral disc and interbody fusion. J Bone Joint Surg Am 40-A:607 – 624
92. Spivak JM, Chen D, Kummer FJ (1999) The effect of locking fixation screws on the stability of anterior cervical plating. Spine 24:334 – 338
93. Steffen T, Tsantrizos A, Aebi M (2000) Effect of implant design and endplate preparation on the compressive strength of interbody fusion constructs. Spine 25:1077 – 1084
94. Strauss PJ, Novotny JE, Wilder DG, Grobler LJ, Pope MH (1994) Multidirectional stability of the Graf system. Spine 19:965 – 972
95. Szpalski M, Gunzburg R, Mayer M (2002) Spine arthroplasty: a historical review. Eur Spine J 11 Suppl 2:S65 – 84
96. Totoribe K, Chosa E, Tajima N (2004) A biomechanical study of lumbar fusion based on a three-dimensional nonlinear finite element method. J Spinal Disord Tech 17:147 – 153
97. Tsantrizos A, Andreou A, Aebi M, Steffen T (2000) Biomechanical stability of five standalone anterior lumbar interbody fusion constructs. Eur Spine J 9:14 – 22

98. Tsantrizos A, Baramki HG, Zeidman S, Steffen T (2000) Segmental stability and compressive strength of posterior lumbar interbody fusion implants. Spine 25:1899 – 1907
99. Vaccaro AR, Lim MR, Lee JY (2005) Indications for surgery and stabilization techniques of the occipito-cervical junction. Injury 36 Suppl 2:B44 – 53
100. Valdevit A, Kambic HE, McLain RF (2005) Torsional stability of cross-link configurations: a biomechanical analysis. Spine J 5:441 – 445
101. van Ooij A, Oner FC, Verbout AJ (2003) Complications of artificial disc replacement: a report of 27 patients with the SB Charite disc. J Spinal Disord Tech 16:369 – 383
102. Vender JR, Rekito AJ, Harrison SJ, McDonnell DE (2004) The evolution of posterior cervical and occipitocervical fusion and instrumentation. Neurosurg Focus 16:E9
103. White AA, Panjabi MM (1990) Clinical biomechanics of the spine, 2nd edn. JB Lippincott Co, Philadelphia
104. Whitesides TE, Jr. (2003) The effect of an interspinous implant on intervertebral disc pressures. Spine 28:1906 – 1907; author reply 1907 – 1908
105. Wilke HJ, Kavanagh S, Neller S, Claes L (2002) [Effect of artificial disk nucleus implant on mobility and intervertebral disk high of an L4/5 segment after nucleotomy]. Orthopade 31:434 – 440
106. Wilke HJ, Kemmerich V, Claes LE, Arand M (2001) Combined anteroposterior spinal fixation provides superior stabilisation to a single anterior or posterior procedure. J Bone Joint Surg Br 83:609 – 617
107. Wiseman CM, Lindsey DP, Fredrick AD, Yerby SA (2005) The effect of an interspinous process implant on facet loading during extension. Spine 30:903 – 907

# 4 Age-Related Changes of the Spine

Atul Sukthankar, Andreas G. Nerlich, Günther Paesold

## Core Messages

- ✔ The spinal column degenerates far earlier than other musculoskeletal tissues
- ✔ Age-related changes of the spine are not synonymous with painful alterations
- ✔ Time course and probability of early disc degeneration are largely determined by genetic disposition
- ✔ The intervertebral disc is the largest avascular structure of the human body resulting in large diffusion distances to allow for disc nutrition
- ✔ Compromised disc nutrition is a key factor for disc degeneration
- ✔ Changes in the matrix components of the intervertebral disc, especially the proteoglycans, determine age-related changes of the disc
- ✔ Orientation and misalignment of the facet joints correlate with development of early osteoarthritis of the joint
- ✔ Changes in bone architecture of the vertebral bodies and formation of osteophytes alter mechanical properties of the spinal column
- ✔ Changes in matrix molecules and fiber orientation in ligaments alter behavior of the ligaments
- ✔ Age-related changes of the three joint complex lead to disc herniation, osseous and ligamentous stenosis

## Epidemiology

Musculoskeletal impairments are prevalent and symptomatic health problems in individuals of middle and old age. Naturally, aging of an individual is accompanied by decreasing strength, pain and restricted movement. As a consequence, increasing age is concomitant with limited abilities for work and leisure activities. Regular physical activities are important to maintain optimal mobility and general health. Age-related changes in the musculoskeletal system occur due to alteration in a multitude of tissues, such as bone and soft tissue including muscles, articular cartilage, intervertebral discs, tendons, ligaments and joint capsules [40]. In addition, a decrease in musculoskeletal function increases probability and severity of soft tissue and skeletal damage due to trauma and also enhances the likelihood of complications during surgery.

Musculoskeletal impairments are a predominant health problem in the aging population

Considering estimations that predict a doubling of the number of people over 65 years of age during the next 25 years, patients suffering from musculoskeletal impairments will increase significantly [79]. In the USA, musculoskeletal and associated conditions in the elderly caused direct costs of US $51 billion in 1992 [158]. These facts impressively underline the impact on healthcare systems that age-related alterations of the musculoskeletal system will have in the future.

The number of people over 65 years will double within 25 years

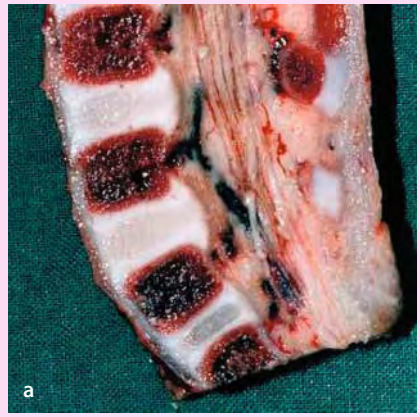


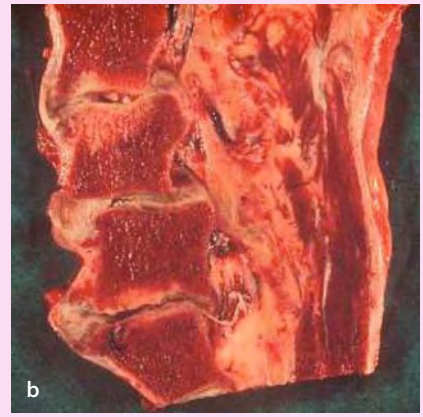


**Case Introduction**

This spinal specimen shows the extreme course of the result of aging on the lumbar spine. A sagittal section through the lumbar spine (L3 – S1) of an 8-year-old individual (a) demonstrates that the nucleus pulposus can be clearly distinguished from the anulus fibrosus. The cartilage endplates are composed of a thick layer of hyaline cartilage. The disc height is somewhat less than the vertebral body height. The vertebral bodies demonstrate rounded edges. On the contrary, the parasagittal section (b) of a 77-year-old individual demonstrates that the disc space has completely collapsed. Anterior or posterior displacement of the vertebral bodies is visible at all levels. The cartilaginous endplates are partially resorbed and exhibit severe sclerotic alterations. The vertebral bodies exhibit severe bridging osteophyte formation. Despite these dramatic changes there is no close link between these alterations and pain.

## General Age-Related Changes

Various mechanisms on a cellular and systemic level have been identified to contribute to age-related changes in the musculoskeletal system [45].
At the **cellular level:**

- **cellular senescence**, leading to a decreasing ability of somatic cells to replicate, repair, and maintain tissue
- **apoptosis** (programmed cell death), leading to decreased cell numbers in the affected tissue
- accumulation of **post-translational modifications** of matrix proteins, leading to altered properties of the extracellular matrix
- increasing generation of **oxidative stress** due to generation of reactive oxygen species (ROS), leading to cell damage
- **genetic predisposition**, leading to premature aging or phenotypic changes in the musculoskeletal system

At the **systemic level:**

Systemic and cellular factors contribute to musculoskeletal age-related changes

- declining levels of **trophic hormones**, leading to altered tissue environment and response of tissue to use and injury
- **general age-related changes**, such as a decrease in reaction time, proprioception, vision, hearing, pulmonary and cardiovascular function, leading to decreased mobility and therefore affecting the musculoskeletal system
- **socioeconomic and psychosocial factors** also contribute, mainly by influencing the individual variation regarding the age-related impairment of mobility

The diversity of contributing factors on cellular and systemic levels underlines the multifactorial nature of age-related changes that will finally lead to alter-

ations of the local environment within the affected tissue. These local alterations can then directly affect the function of the respective tissue. Although the result, i.e. **altered tissue function**, can be observed and analyzed, the exact relationships and interactions between cellular and systemic changes are not yet clear.

The spine is most frequently affected by age-related alterations

Although any part of the musculoskeletal system can be affected by age-related alterations, lower extremities and especially the lumbar spine are the most frequently reported locations of musculoskeletal impairment (Case Introduction). Between 70 % and 85 % of the population in Western industrialized countries will experience back pain at least once during their lives, underlining the impact of age-related alterations to the spine [33, 35, 86, 151, 152]. These episodes of back pain often lead to sickness leave and sometimes to chronic disabilities (approx. 10 %) causing an **enormous socioeconomic burden** on society [80]. In this context, it is important to notice that normal age-related degenerative changes and pathological degeneration leading to back pain have to be distinguished. Several studies have shown that between 7 % and 72 % of individuals that exhibit signs of disc degeneration never experienced relevant low back pain [15, 115, 155].

Degenerative spondylosis is inevitable with aging

Among age-related alterations of the spine, the so-called "**degenerating spondylosis**" or spinal osteoarthritis is the most common and is probably inevitable with increasing age. This alteration is radiologically characterized by osteophytes (bone spurs) arising from the margin of the vertebral body and is usually accompanied by disc space narrowing. The term "**spondylosis**" was historically an effort to distinguish between degenerative changes in the spine and those in synovial joints (osteoarthritis) such as facet joints [145]. However, it has been shown that pathological changes in the spine and osteoarthritis of the synovial joints coexist and in most cases are interrelated [145]. Autopsy studies by Schmorl and Junghanns [64] reported evidence of spondylosis in 60 % of women and 80 % of men by the age of 49 years, and in 95 % of both sexes by the age of 70 years.

## Functional Spine Unit

The motion segment is the functional unit of the spine

The spine is a multi-segmented column, which provides stability and mobility to the body at each segmental level and gives protection to the nerve roots and the spinal cord. The smallest anatomical unit of the spine which exhibits the basic functional characteristics of the entire spine is called the "**motion segment**" or "**functional spine unit**" (Fig. 1). It was first described by Schmorl and Junghanns [64]. Each motion segment consists of two adjacent vertebrae, separated dorsally by the zygapophyseal joints or facet joints and anteriorly by the interposed intervertebral disc. The vertebrae are further connected by spinal ligaments, joint capsules and segmental muscles. The spinal ligament complex consists of the interspinous, supraspinous intertransverse, yellow, anterior and posterior longitudinal ligaments. In contrast to the extrinsic muscles, the intrinsic muscles span over two vertebrae and consist of splenius, erector spinae, transversospinal and segmental muscles. Spine motion, stability and equilibrium are achieved by the antagonist action of the powerful flexor and extensor muscle groups.

The motion segment is a three joint complex

The normal spinal function largely depends on the integrity of these components and their coordinated interplay. Kirkaldy-Willis [71] introduced the term "**the three joint complex**" to highlight the importance of a normal interaction of the three joints in a segment, i.e. the intervertebral disc and the two facet joints. Any alterations in one of these components will result in a disturbance of their interplay with subsequent dysfunction, finally leading to back pain, deformity and neurological compromise.

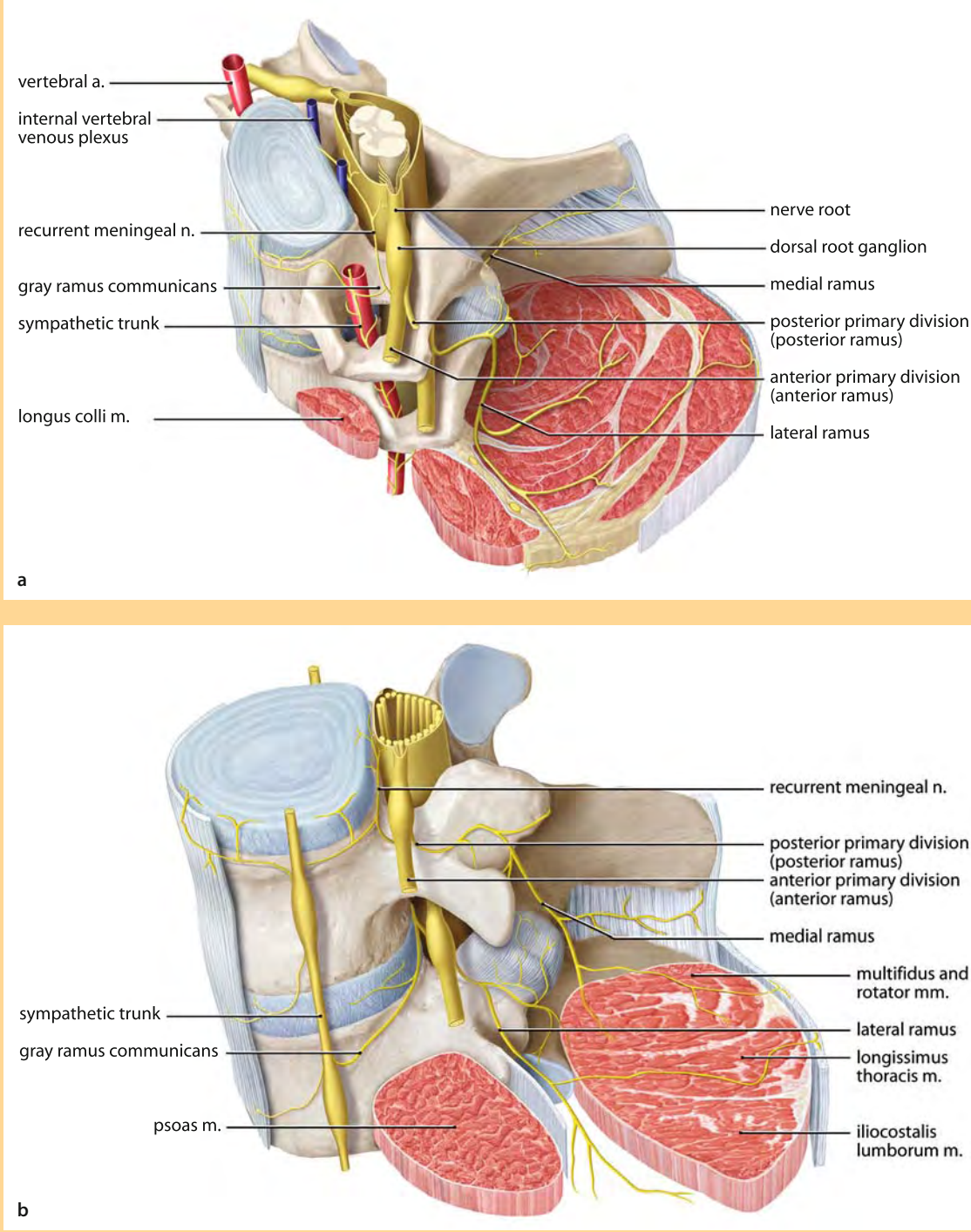


**Figure 1. Functional spinal unit**

Schematic representation of a functional spinal unit (motion segment) in a the cervical and b lumbar spine.

## The Intervertebral Disc and Cartilage Endplate

The intervertebral discs are located between the vertebral bodies. They transmit load arising from body weight and muscle activity through the spinal column and also provide flexibility to the spine by allowing bending, flexion and torsion. The discs of the lumbar spine are approximately 7–10 mm thick and 40 mm in diameter (anterior-posterior), representing one-third of the height of the spine [120, 141]. Generally, the discs consist of three highly specialized structures: the anulus fibrosus, the nucleus pulposus and the cartilage endplate that forms the interface with the adjacent vertebral bodies.

The disc consists of three highly specialized structures

### Intervertebral Disc

Among all the tissue components of the spine, the intervertebral discs exhibit the most striking alterations with age. Because of these dramatic changes, many spine specialists believe that the disc is a **major source of back and neck pain**. The intervertebral disc has attracted much research to unravel the underlying **molecular mechanism of disc degeneration**. Although the intervertebral disc is much better explored than other components of the spine, our understanding of its molecular biology is still in its infancy.

The intervertebral disc undergoes dramatic alterations with aging

#### Normal Anatomy and Biochemical Composition

The anulus fibrosus is made up of 15–25 concentric rings consisting of **parallel collagen fibers**. These rings are termed lamellae and are visible macroscopically in healthy discs. The collagen fibers in each lamella are oriented at approximately 60° to the vertical axis, alternating left and right to the adjacent lamellae (see Chapter 2). **Elastin fibers** intersperse the lamellae and may play an important role in restoration of shape after bending of the spine [161]. The cellular part of the anulus fibrosus consists of thin and elongated **fibroblast-like cells** aligned to the collagen fibers (Fig. 2) [114, 117].

The outer anulus fibrosus consists of concentric rings of collagen fibers

Surrounded by the anulus fibrosus is the nucleus pulposus, the **gelatinous core** of the intervertebral disc. The matrix of the nucleus pulposus consists of randomly organized collagen fibers and radially arranged elastin fibers that are embedded in a highly hydrated aggrecan-containing proteoglycan gel. Interspersed at a low density are rounded chondrocyte-like cells usually located inside a capsule in the surrounding matrix (so-called lacunae) [82].

The nucleus is the gelatinous core of the disc and is rich in proteoglycan

Macroscopically, the boundary between the anulus fibrosus and the gelatinous nucleus pulposus can only be distinguished in young individuals (Fig. 2). The different **mechanical properties** of anulus fibrosus and nucleus pulposus are determined by composition and organization of the respective extracellular matrix. Although the mechanical properties of nucleus pulposus and anulus fibrosus are very different, the **main components** are very similar and consist of:

- water
- proteoglycans
- collagen

**Water** makes up 80% of the wet weight of the nucleus and 70% of the wet weight of the anulus [105, 162]. Collagen and proteoglycans fulfil complementary functions in the tissue.

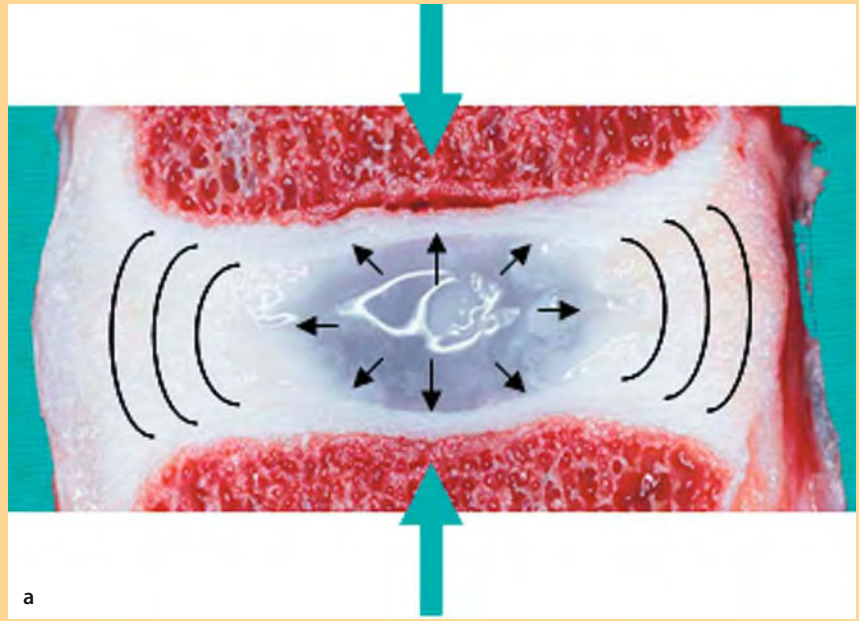


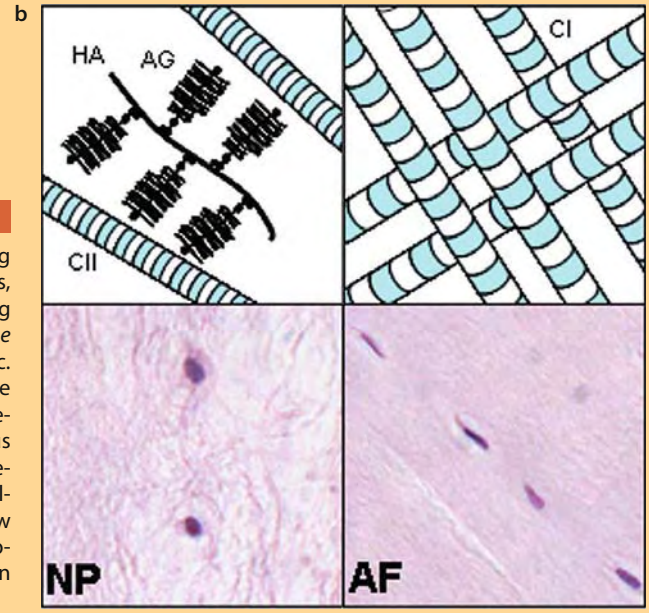


**Figure 2. Normal anatomy and composition**

**a** Mid-sagittal section through a healthy young intervertebral disc. The white cartilage endplates, the gel-like nucleus pulposus and the surrounding anulus fibrosus can easily be distinguished. *Large arrows* show the direction of axial load on the disc. *Small arrows* indicate dissipation of the compressive forces to the anulus fibrosus. **b** *Upper panels:* schematic presentation of the composition of nucleus pulposus (*NP*) and anulus fibrosus (*AF*) (*AG* aggrecan, *HA* hyaluronan, *CII* collagen type II fibers, *CI* collagen type I fibers). *Lower panels:* histological view of the chondrocyte-like cells of the NP and the fibroblast-like cells of the AF (schematic representation of the NP matrix adapted from [121]).

*Collagens*

- are mechanically stable proteins
- provide tensile strength
- are mainly collagen types I and II

*Proteoglycans*

- consist of chondroitin and negatively charged keratan sulfate chains
- are osmotically active due to their negative charge
- maintain hydration of the tissue through osmotic pressure

To meet the different **mechanical needs** of anulus fibrosus and nucleus pulposus, the compositions of the respective extracellular matrices vary substantially. The anulus fibrosus that is responsible for containing the nucleus pulposus and withstanding the resulting tensile forces consists of up to 70% (percent dry weight) of collagen type I and II whereas the nucleus pulposus only contains 20% of collagen [31]. On the other hand, the nucleus pulposus that is responsible for dissipating the compressive forces on the disc by exerting a **hydrostatic pressure** on the anulus fibrosus consists of up to 50% of proteoglycans (percent wet weight), whereas the anulus fibrosus only contains 20% proteoglycans (Fig. 2b). These differences in proteoglycan content are also reflected by the water content of the two tissues (80% in the nucleus pulposus and 70% in the anulus fibrosus).

The anulus resists high tensile forces

Besides these main components, there are **several minor components** including collagen III, V, VI, IX, X, XI, XII and XIV [5, 10, 29, 31, 38, 43, 113] and also small proteoglycans such as lumican, biglycan, decorin and fibromodulin and other non-collagenous proteins like fibronectin (Table 1). The exact role of these additional matrix proteins and glycoproteins is not completely clear [55, 87].

The collagen and proteoglycan interplay influences disc functions

It is important to keep in mind that the disc matrix is not a static but a **dynamic structure**. The components of the matrix are continuously degraded and replaced by newly synthesized molecules. Degradation of matrix components is

In the normal disc, matrix degradation and synthesis are in balance

**Table 1.** Biochemical disc components

| Matrix molecule | Tissue distribution and abundance | Function | References |
|---|---|---|---|
| **Collagens** | | | |
| Type I | dominant component: 70% of the dry weight of the anulus, 20% of the dry weight of the nucleus | | [5, 31] |
| Type II | | | [6, 31] |
| | *collagen I:* major component of anulus fibrosus<br>*collagen II:* major component of nucleus pulposus and cartilage endplate | tensile strength<br>anchors tissue to bone | |
| Type III | minor component of anulus fibrosus | mechanical function | [126] |
| Type V | minor component of anulus fibrosus | mechanical function | [126] |
| Type VI | minor component of anulus fibrosus and cartilage endplate | mechanical function | [126] |
| Type IX | minor component of nucleus pulposus and cartilage endplate | mechanical function: forms crosslinks between collagen fibrils | [126] |
| Type X | minor component of hypertrophic cartilage endplate | mechanical function | [126] |
| Type XI | minor component of the nucleus pulposus | mechanical function | [126] |
| Type XII | minor component | mechanical function | [126] |
| Type XIV | minor component | mechanical function | [126] |
| **Proteoglycans** | | | |
| *Large* | | | |
| Aggrecan | all proteoglycans make 50% of the wet weight of the nucleus and 20% of the anulus | tissue hydration (water retention) | [25, 135] |
| Versican | | | [25] |
| *Small* | | | |
| Biglycan | elevated in deg. disc | tissue hydration<br>regulate formation of matrix | [25, 55, 62, 87, 122] |
| Decorin | | mechanical function<br>regulate formation of matrix | [87, 122] |
| Fibromodulin | | | [87, 134] |
| Lumican | | | [8, 134] |
| **non-collagenous proteins** | | | |
| Fibronectin | minor component | role unclear | [41, 97] |
| Elastin | minor component (2%) | mechanical function | [8] |
| Chondronectin | minor component | role unclear | [57, 76, 81, 127, 157] |

an enzymatic process catalyzed by matrix metalloproteinases (MMPs) and aggrecanases that are synthesized by disc cells [27, 118]. The balance between synthesis, degradation and accumulation of matrix molecules determines the quality and integrity of the disc matrix and is also prerequisite for adaptation/alteration of the matrix properties to changing environmental conditions.

Nutritional supply and waste removal entirely depend on diffusion

The majority of a healthy **adult disc is avascular.** The blood vessels closest to the disc matrix are therefore the capillary beds of the adjacent vertebral bodies and small capillaries in the outermost part of the anulus fibrosus [24, 46]. The blood vessels present in the longitudinal ligaments running adjacent to the disc and in young cartilage endplates (less than 12 months old) are branches of the spinal artery [49, 50, 142]. As a consequence of the avascularity, the **nutrient supply** to the disc cells and **removal of metabolic waste products** is entirely dependent on diffusion mainly from or to the capillary beds of the adjacent vertebrae [49]. Animal experiments indicated that the role of the peripheral small capillaries for the nutrient supply is only of minor importance [102]. The dependency of nutrient supply to the inner parts of the disc on diffusion together with the **poor diffusion capacity** of the disc matrix severely limits nutrient and waste exchange. As a result, a gradient between the inner parts and the peripheral regions of the disc builds up with very low levels of glucose and oxygen and high levels of the waste product lactic acid on the inside [49] (Fig. 3). These gradients are even further aggravated by the disc cells using oxygen and glucose and producing lactic acid [49, 56]. The **restricted nutrient supply** and the increasing **acidic milieu**, due to the accumulation of lactic acid, are considered the main factors limiting cell viability and therefore the integrity of the disc matrix.

### Macroscopic Disc Alterations

Onset and progression of age-related alterations of the disc can be determined with various techniques. MRI allows disc degeneration to be studied in vivo. Applying this technique revealed that early signs of age-related alterations could

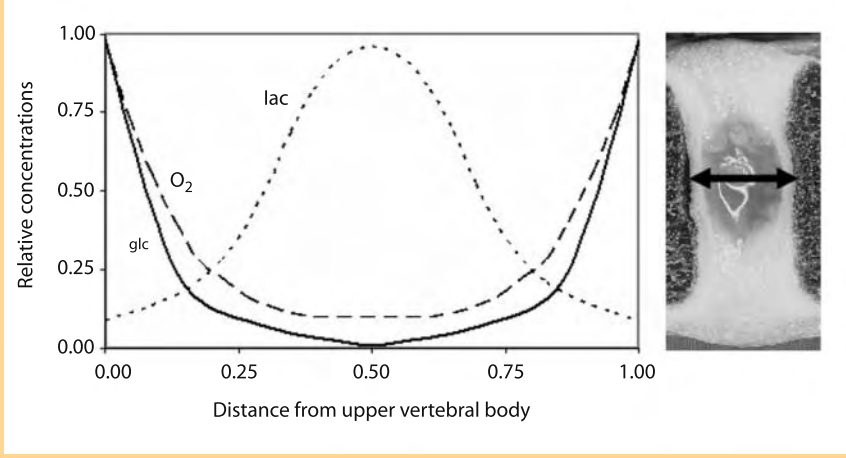


**Figure 3. Disc nutrition**

Glucose and oxygen concentration were found to drop steeply from the endplate towards the inner part of the nucleus pulposus (*glc* glucose, $O_2$ oxygen). Lactate concentration displayed the opposite course, with highest levels in the inner region (*lac* lactate). This profile reflects the nutrient limitations in the inner disc and the lower pH values on the inside due to the acidic waste product lactate. The sagittal section through an intervertebral disc shows the region of the determined concentrations (adapted from [143]).

**Figure 4. Macroscopic age-related disc changes**

**Grade I:** normal juvenile disc

- nucleus pulposus and anulus fibrosus can clearly be distinguished
- the nucleus pulposus has a gel-like appearance and is highly hydrated
- anulus fibrosus consists of discrete fibrous lamellae
- cartilage endplates are uniformly thick and consist of hyaline cartilage

**Grade II:** normal adult disc

- peripheral appearance of white, fibrous tissue in the nucleus pulposus
- mucinous material is found between the lamellae of the anulus fibrosus
- thickness of the cartilage endplate is irregular

**Grade III:** early stage

- consolidated fibrous tissue in the whole nucleus pulposus
- demarcation between nucleus pulposus and anulus fibrosus is lost and extensive mucinous infiltration in the anulus fibrosus is observed
- cartilage endplates show focal defects

**Grade IV:** advanced stage

- clefts in the nucleus pulposus appear, usually parallel to the endplate
- focal disruptions are found in the anulus fibrosus
- hyaline cartilage of the endplate is replaced by fibrocartilage; irregularities and focal sclerosis are found in the subchondral bone

**Grade V:** end stage

- typical disc structure may be lost completely
- clefts extend through nucleus pulposus and anulus fibrosus
- endplates display diffuse sclerosis

**The different stages represent age-related changes which occur during life (modified from [138]).**

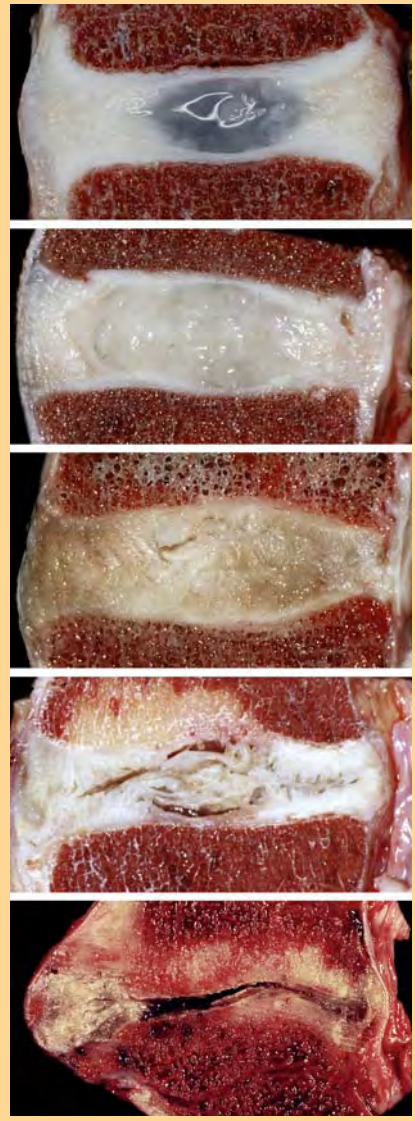

already be observed in the **second decade of life** [47]. However, more detailed information has been gained from macroscopic postmortem analysis of intervertebral disc tissue from individuals of various ages [92]. These studies have led to grading systems that on one hand allow the evaluation of stages of disc degeneration, but also illustrate the process of age-related degeneration. The original grading system was established by Friberg and Hirsch (and propagated by Nachemson) and has been further refined by Thompson et al. [34, 95, 138]. **Thompson's grading system** distinguishes five stages that describe age-related degeneration from healthy young discs leading to old heavily degenerated intervertebral disc (Fig. 4) [138]:

Disc degeneration starts as early as the second decade of life

### Microscopic Alterations of the Disc During Aging

To improve the rather poor resolution of macroscopic approaches to analyzing disc degeneration, Boos et al. established a **histological degeneration score** (HDS) [17]. Studying age-related changes at the microscopic level, several hall-

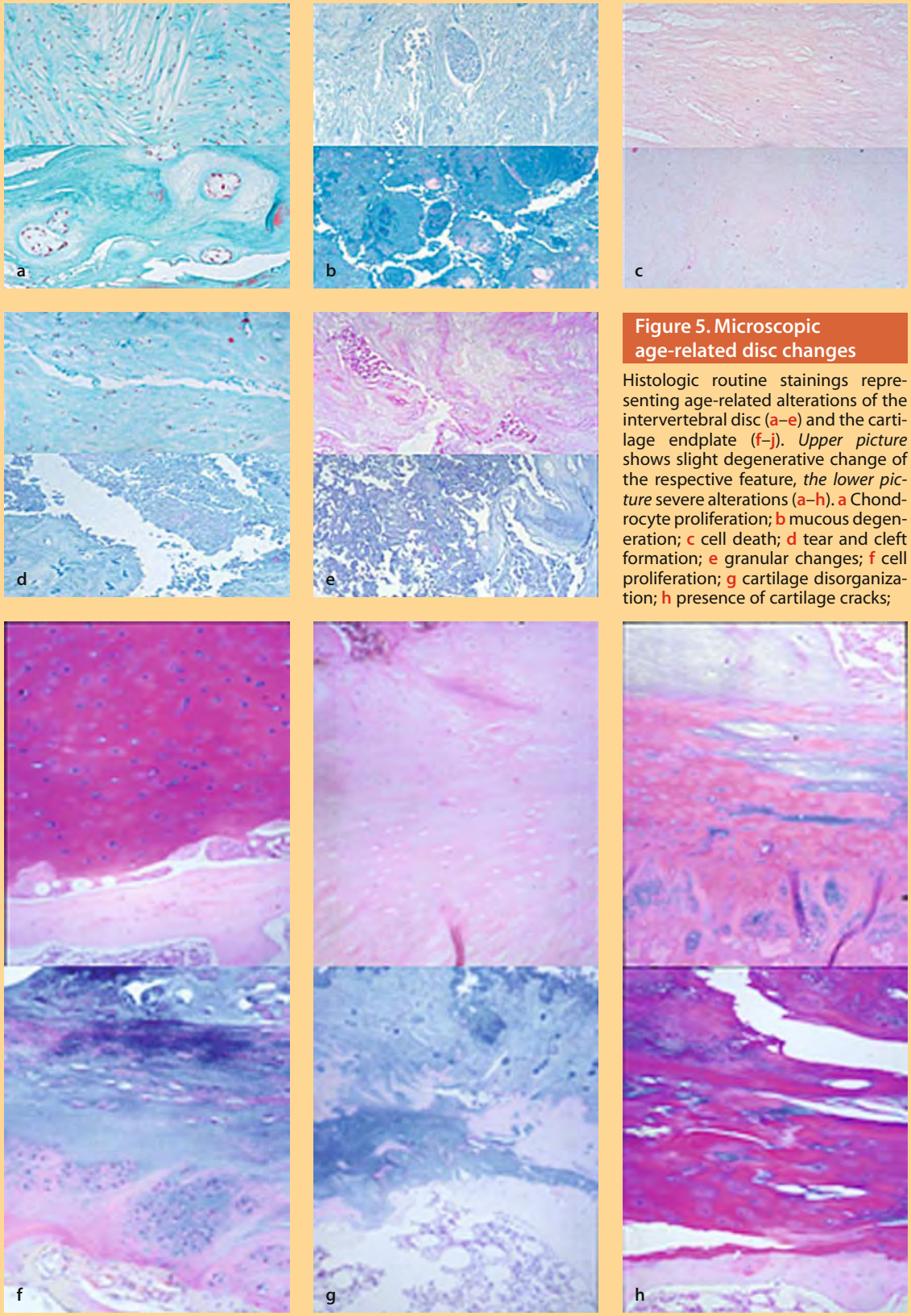


**Figure 5. Microscopic age-related disc changes**

Histologic routine stainings representing age-related alterations of the intervertebral disc (a–e) and the cartilage endplate (f–j). *Upper picture* shows slight degenerative change of the respective feature, *the lower picture* severe alterations (a–h). a Chondrocyte proliferation; b mucous degeneration; c cell death; d tear and cleft formation; e granular changes; f cell proliferation; g cartilage disorganization; h presence of cartilage cracks;

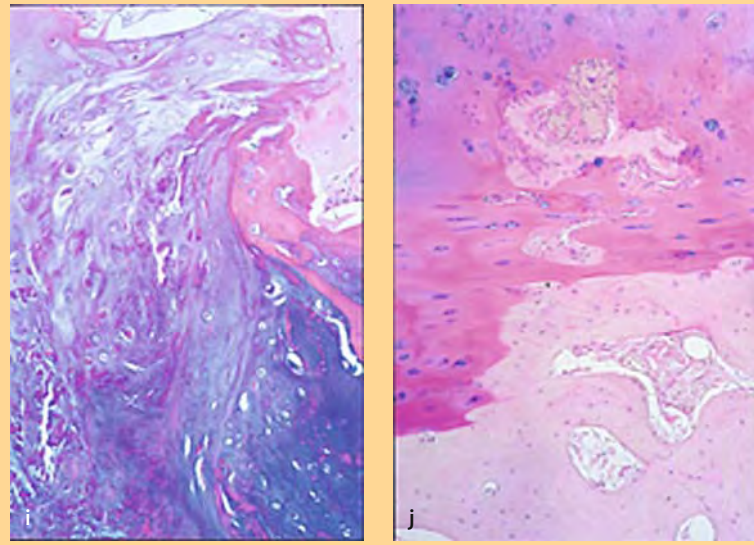


**Figure 5.** (*Cont.*)
i formation of new bone; j bony sclerosis (according to Boos et al. [17]).

marks for degenerative changes were identified for the intervertebral disc and the cartilage endplates (Fig. 5).

### *Intervertebral Disc*

- chondrocyte proliferation (increasing cell clusters due to reactive proliferation)
- mucous degeneration (accumulation of mucous substances)
- cell death
- tear and cleft formation
- granular changes: increasing accumulation of granular tissue

### *Cartilage Endplate*

- cell proliferation
- cartilage disorganization
- presence of cracks in the cartilage
- presence of microfractures
- formation of new bone
- bony sclerosis

Chondrocyte proliferation is the first sign of disc degeneration

First signs of tissue degradation are seen between 10 and 16 years of age when tears in the nucleus pulposus occur along with focal **disc cell proliferation** and **granular matrix transformation** [17]. In parallel, the amount and extent of acidic mucopolysaccharides in the matrix increase. The general structure of the nucleus pulposus and the anulus fibrosus, however, is preserved in this age group.
In the young adult disc (up to approx. 30 years of age), the aforementioned changes of the nucleus pulposus are observed to a considerable extent. The nucleus is accordingly transformed by **multiple large clefts and tears** and the matrix shows significant granular changes. In this age group the first histologic changes occur in the anulus fibrosus.

The adult disc (30–50 years) is characterized by a further increase in the changes with respect to extent. In this age group particularly the anulus fibrosus

Advanced disc degeneration is indicated by a loss of nuclear/annular distinction

is more and more affected, resulting in a loss of the clear distinction between nucleus and anulus. Finally, at advanced age (50–70 years) tissue alterations become most severe. **Huge clusters of proliferating cells** are observed near clefts and tears that are filled with granular material. In individuals older than 70 years, the structural abnormalities change more to scar-like tissue and large tissue defects. At this stage, differentiation of the anatomical regions is no longer possible. Therefore, histological features can hardly be determined and characterize a "**burned-out**" intervertebral disc.

Disc degeneration exhibits a spatial heterogeneity

The histological approach, although it largely parallels the macroscopic classification proposed by Thompson et al. [138], provides a more reliable classification of age-related alterations of the intervertebral disc [17]. Whereas macroscopic and histological approaches concur in the progressive loss of structure in all anatomical regions of the intervertebral disc, the microscopic approach revealed an earlier occurrence of nuclear clefts already in the second decade of life. In addition, the histologic approach revealed the **heterogeneity of the alteration** within the disc, indicating relevant spatial differences with more alterations usually present in the posterolateral aspects of the disc.

In addition, the microscopic approach underlined the importance of **nutritional supply** to the disc cells for the maintenance of a healthy disc and the lack thereof for the onset and progression of disc degeneration. Since vascularization was seen to disappear from the disc during the first decade, nutritional supply to the disc cells becomes severely impaired during the subsequent phase of growth [17].

### Age-Related Changes in Vascularization and Innervation

The disc is the largest avascular structure of the human body

Although there is still some debate over the presence of blood vessels and nerve endings in the inner portions of pathologic discs, there is consensus that the healthy adult disc is the **largest avascular and aneural tissue** in the human body [61, 88]. This absence of significant vascular supply to the intervertebral disc matrix has important consequences for the maintenance of discal structures as discussed above [17, 88].

Vascular changes in the endplate play a key role in the nutritional supply

In fetal and early infantile intervertebral discs blood vessels penetrate both the endplate and the peripheral region of the anulus fibrosus. However, by late childhood the blood vessels disappear, leaving only small capillaries accompanied by lymph vessels that penetrate up to 2 mm into the outer anulus fibrosus [46, 124]. Since the importance of this peripheral vascularization for the nutrient supply of the disc is not known in detail, the consequences of its disappearance are also unknown. More important for the blood supply to the inner regions of the disc and therefore better described is the vascularization of the interface between adjacent vertebral bodies, cartilage endplate and the disc. The vertebral bodies are supplied by different arteries that are either responsible for the outer regions, the mid-anulus region, or the central core [23, 116]. These arteries of the vertebral body feed capillaries that, after penetrating **channels in the subchondral plate**, terminate in loops at the bone-cartilage interface [143]. The channels penetrating the subchondral plate are present in the fetus and infants, but disappear during childhood, compromising the blood supply to the inner disc [22]. Later during aging, sclerosis of the subchondral plate is observed and the cartilage endplates undergo calcification followed by resorption and finally replacement by bone [14, 28]. These age-related changes at the bone-disc interface restrict blood supply to the disc even further, finally cutting off nutrient supply to the inner parts of the disc [13, 96]. So far, it is not entirely clear whether calcification of the endplates causes disc degeneration or if age-related changes during degeneration in the environment of the endplates lead to **calcification**. However, it is thought that the impairment of the already critical supply of the disc cells with nutrients might be a major cause of disc degeneration.

Calcification of the endplates and occlusion of the vascular channels are detrimental to the disc

**Distribution of nerve fibers** is very similar to the occurrence of blood vessels, as they are only, if at all, detectable in the outermost zone of the anulus fibrosus of healthy adult discs. In contrast, fetal and infantile discs contain small nerve structures adjacent to vessels also in central portions of the disc, i.e. the transition zone between nucleus pulposus and anulus fibrosus. Concomitant with the closure of the vessels, neural structures also disappear.

In contrast to fetal discs, the adult disc is aneural

From adult age on, the intervertebral disc remains avascular and aneural until advanced age. Only in those rare cases where the disc is completely destroyed and fibrously transformed may the **ingrowth of blood vessels** be associated with innervation of this fibrous tissue. Accordingly, this pattern is restricted to those cases where the original disc structure is completely lost.

### Molecular Changes of the Extracellular Matrix During Aging

The structure and composition of the extracellular matrix are of fundamental significance for the **biomechanical properties** of the intervertebral disc. Collagen represents the main structural component of the discal extracellular matrix with variable compositions of isoforms seen in the different anatomic subsettings. Collagen types I, III, V and VI are components of the normal anulus fibrosus, and the normal nucleus pulposus contains collagen types II, IX and XI. While the overall collagen content in the nucleus pulposus remains fairly constant over the years, that of the anulus fibrosus decreases with advancing age.

Collagens I and II are the main structural disc components

In addition to these quantitative changes, there are significant qualitative changes in the distribution of disc collagens during aging:

#### *Nucleus Pulposus*

- appearance and increasing amount of collagen type I
- appearance of collagen type X in individuals older than 60 years
- increasing amounts of collagen type III and VI

#### *Anulus Fibrosus*

- decreasing expression of collagen type IX
- appearance of collagen type X in individuals older than 60 years in the inner anulus fibrosus

  Besides collagens, **aggrecan**, a proteoglycan, is a major component of the disc matrix. In a healthy intervertebral disc, aggrecan is present in the nucleus pulposus as large aggregates with hyaluronan. During degeneration aggrecan molecules are increasingly subjected to proteolytic cleavage.

Age-related changes of collagen are predominantly qualitative

**Cleavage of aggrecan** has severe consequences for the healthy disc:

- smaller aggrecan fragments are generated that diffuse more easily from the disc matrix
- loss of aggrecan resulting in decreasing osmotic pressure
- dehydration of the disc matrix
- increased outflow of matrix molecules
- increased inflow of mediators such as growth factor complexes and cytokines

Taken together, changes in the composition of the disc matrix often result in a loss of disc height. This rapid loss of disc height puts the apophyseal joints to abnormal loads, predisposing to osteoarthritic changes. Loss of disc height also allows the ligamentum flavum to thicken, leading to a narrowing of the spinal canal.

Aggrecan loss significantly compromises biomechanical properties

The observed changes in the molecular composition of the disc matrix are mainly due to degradation of the existing matrix components and synthesis of new matrix components. During degeneration the **balance between degradation and synthesis** is disturbed, leading to increased degradation and therefore resulting in loss of tissue from the disc. This loss of tissue due to proteolytic destruction of the matrix components goes along with the occurrence of clefts and tears, which in turn leads to biomechanical instability and thus to a loss of functional properties of the disc. Therefore, the proteolytic matrix destruction holds a central role in disc degeneration [98].

Disc collagens are degraded by various matrix metalloproteinases

The most important proteolytic enzymes during matrix degradation are the **matrix metalloproteinases** (MMPs). The members of the MMP family differ in their specificity for collagen types (Table 2).

**Table 2.** Matrix degrading enzymes and their inhibitors

| Enzyme | Synonym | Function | References |
|---|---|---|---|
| **Degrading enzymes** | | | |
| MMP1 | collagenase I | degradation of collagen I, II, III, VII, X | [9, 154] |
| MMP3 | stromelysin I | degradation of gelatin I, III, IV, collagen III, IV, X, fibronectin, proteoglycans | [154] |
| MMP9 | gelatinase B | degradation of gelatin I, V, collagen IV, V | [154] |
| MMP 13 | collagenase III | degradation of collagen I | [154] |
| ADAMTS4 | aggrecanase I | degradation of aggrecan | |
| **Inhibitors** | | | |
| TIMP1 | | MMP inhibitor | [140] |
| TIMP2 | | MMP inhibitor | [140] |
| TIMP3 | | aggrecanase inhibitor | [140] |

MMP = **M**atrix **M**etalloproteinases, TIMP = **T**issue **I**nhibitors of MMPs, ADAMTS = **A D**isintegrin and **M**etalloproteinase with **T**hrombo**s**pondin **M**otif

While infantile and juvenile discs contain only very small amounts of various MMPs, the MMP expression in areas of degenerative changes is significantly upregulated [154]. Additionally, there is evidence that increased activity of proteolytic enzymes has to be noted in regions of clefting and tissue disruption. MMP activity is tightly regulated on many levels: at transcriptional level by cytokines, growth factors, cell-cell and cell-extracellular matrix interaction. At post-translational level, regulation consists of proteolytic activation. After activation, MMPs are modulated in their function by **tissue inhibitors of matrix metalloproteinases** (TIMPs), which are increasingly found in degenerated and herniated discs [140].

Aggrecan is degraded by specific proteinases (aggrecanases)

Besides the MMPs, aggrecan-specific proteinases, the so-called aggrecanases, also play a major role in matrix degradation. Although far less characterized compared to the MMPs, two aggrecanases have been identified, ADAMTS-4 [139] and ADAMTS-5 [1] (**A Disintegrin And Metalloproteinase with Thrombospondin Motif** [75]). These aggrecanases differ in their specificity for parts of the aggrecan molecule. Whereas ADAMTS-4 was detected in increasing levels with increasing degeneration, ADAMTS-5 was so far only detected in in vitro model systems for disc degeneration [77, 128].

The combined action of various proteinases and the ratio between these degradative processes and the synthesis of new matrix components are responsible for the remodeling of the disc matrix during degeneration.

### Modulation of Cells and Matrix by Cytokines and Growth Factors

Cytokines and growth factors modulate disc matrix

Many studies have analyzed the ability of disc cells to either produce or respond to **cytokines and growth factors** (Table 3). There is more and more evidence that

**Table 3.** Major cytokines of the intervertebral disc

| Enzyme | Function | References |
|---|---|---|
| TNF-α | Proinflammatory cytokine, proapoptic | [7, 9, 20, 93] |
| IL-1αs | Proinflammatory cytokine, chemokine | [18, 58, 123] |
| IL-1β | Proinflammatory cytokine, chemokine | [60, 132] |
| IL-6 | Proinflammatory cytokine, chemokine | [7, 132] |
| IL-8 | Proinflammatory cytokine, chemokine | [7, 132] |
| IL-10 | Inhibition of pro-inflammatory cytokine, chemokine | [132] |
| GM-CSF | Proinflammatory cytokine | [7, 21] |
| $PGE_2$ | Tissue degradation, inflammation, angiogenesis | [7, 21] |
| TGF-β | Growth factors for proteoglycan synthesis | [7, 74] |
| PLA-2 | Biosynthesis of prostaglandins | |
| COX2 | Biosynthesis of prostaglandins | [93] |

cytokines and growth factors are responsible for the alterations of the disc matrix described above [7, 20, 93]. However, for most factors it is difficult to distinguish if they are part of the normal, age-related degeneration process or mainly important during pathological changes of the disc. Therefore, the mechanism of cytokine action is of major importance for the understanding of disc degeneration and also represents a potential target for therapeutic interventions. Despite this importance, only little is known about the age-related changes in cytokine and growth factor expression patterns.

IL-1, TNF-α and TGF-β are upregulated in disc degeneration

Among the factors that have been identified to be either produced by disc cells or that can be recognized by disc cells, two major groups can be distinguished: **proinflammatory cytokines** with mostly catabolic activity (represented by interleukins and TNF-α) and growth factors with mostly anabolic effects (such as TGF-β) [7]. Recent studies provide evidence that factors of both classes are induced during age-related degeneration. Weiler et al. demonstrated that TNF-α was found in an increasing proportion of cells with increasing age in non-symptomatic intervertebral discs [153]. Among the adult disc specimens, increasing levels of TNF-α were found with increasing degeneration. In addition, members of the interleukin-1 (IL-1) family were found to be produced in non-degenerated and degenerated intervertebral discs and displayed an increasing amount with increasing disc degeneration [78]. **Expression and secretion** of these two main cytokines has several consequences:

*TNF-α*

- probably inducing MMP synthesis
- increased prostaglandin $E_2$ ($PGE_2$) production

*IL-1*

- enhancing proteoglycan catabolism
- inducing production of $PGE_2$ and nitric oxide (NO)
- inducing production of MMPs (MMP-3 and MMP-13)
- stimulation of phospholipase $A_2$ ($PLA_2$) production

Proinflammatory cytokines may diffuse out of the disc through tears and clefts and cause peridiscal inflammation

Interestingly, the induction of interleukins and TNF-α may initiate a **local inflammatory reaction**, but – by rapid diffusion through nuclear and annular clefts and tears – may also induce inflammation in the peridiscal space, which is very well innervated. This hypothesis has been supported by the observation that TNF-α applied to the dorsal root ganglion caused pain behavior in animal studies [94]. Thereby, TNF-α might be the linking factor between degenerative processes and the induction of **discogenic pain**.

**TGF**-β is a cytokine with matrix-inducing activity (**anabolic effect**) that is synthesized in increased amounts in the degenerated disc [97]. Since TGF-β is a potent stimulator for the synthesis of various matrix components, its enhanced expression during degeneration might indicate a rearrangement of the matrix. This may consequently be responsible for the matrix disarrangement, including the formation of granulation tissue, characterized by changes to collagen and proteoglycan synthesis and also changes to the collagen composition of the matrix. Although the synthesis of TGF-β has been shown in disc cells, the mechanism of TGF-β induction remains unknown.

Disc degeneration is characterized by an imbalance of matrix synthesis and degradation

Taken together, alterations to the expression of **catabolic and anabolic factors** during degeneration might disturb the delicate balance between matrix synthesis and degradation that is essential for the maintenance of a healthy disc matrix. Once this balance is disturbed, degeneration progresses together with matrix degradation or alteration.

### Etiology of Disc Degeneration

Although the etiology of disc degeneration is far from being understood, there is consensus that not a single factor can be held responsible for the complex phenomenon of disc degeneration. Rather a multitude of exogenous and endogenous factors, each contributing individually, might influence the progress of degenerative changes of the discs. These factors can be divided into three main groups:

- nutritional effects
- genetic predisposition
- mechanical load

**Insufficient nutritional supply** of the disc cells is thought to be a major problem contributing to disc degeneration. Since the intervertebral disc is the largest avascular tissue in the human body, its cells are facing the precarious situation of having to maintain a huge extracellular matrix with a "fragile" supply of nutrients that is easily disturbed. Whereas the cells in the outer anulus fibrosus may be supplied with nutrients from blood vessels in the adjacent longitudinal ligaments, the supply of the nucleus pulposus cells is almost completely dependent on the **capillary network in the vertebral bodies**. Due to the size of the intervertebral disc, the nutrients need to diffuse from the capillaries through the endplate and the disc matrix to the cells in the nucleus of the disc. With the originally cartilaginous endplates becoming calcified when degeneration progresses, the supply of disc cells with nutrients will become even more restricted. This will consequently lead to:

Failure of disc nutrient supply primarily causes disc degeneration

- **limited nutrient supply** (glucose and oxygen) particularly in the disc center
- **accumulation of waste products** (e.g. lactic acid) with decreasing pH

This was verified by measurements demonstrating that oxygen concentrations were very low in the nucleus and increased towards the disc surface, whereas the lactic acid concentration showed the reverse profile [51]. Since **lactic acid** is not only the major waste product of disc cells but also an acid, its accumulation results in a lowered pH inside the disc. In vitro experiments have shown that low oxygen concentrations and acidic pH significantly affect the synthetic activity and especially **proteoglycan synthesis** rates of disc cells, which might lead to a fall in proteoglycan content and therefore to disc degeneration in vivo (Fig. 4).

The accumulation of lactic acid is detrimental to the disc

Genetic predisposition has a major impact on disc degeneration

The timeframe for these alterations (i.e. early or late) appears to be predetermined by genetic predisposition. Several recent studies have reported a strong

familial predisposition for disc degeneration and herniation [48, 83, 84, 144]. Heritability for disc herniation exceeded 60 % [11]. **Genetic predisposition** has been confirmed by recent findings of associations between disc degeneration and **polymorphisms in various classes of genes:**

#### *Genes Encoding for Matrix Components*

- aggrecan [70]
- collagen type IX [59, 67, 68, 100, 131]
- collagen type I [112]
- cartilage intermediate layer protein (CILP) [129]

#### *Genes Encoding for Cytokines*

- interleukin-1 (IL-1) [130]
- interleukin-6 (IL-6) [101]

#### *Genes Encoding for Proteinases*

- matrix metalloproteinase-3 (MMP-3) [136]

#### *Genes Encoding for Miscellaneous Proteins*

- vitamin D receptor [63, 69, 147, 148]

All polymorphisms identified so far affect genes that are involved in the maintenance of integrity or functionality of the disc matrix, suggesting that the genetic background plays a major role in the integrity of a healthy disc. If mutations in these genes occur, normally innocuous conditions or forces might lead to accelerated or enhanced degenerative changes, suggesting that disc degeneration may be explained primarily by genetic influences and that **environmental factors** have only modest effects. However, it is important to keep in mind that despite the dominating role of genetic predisposition, injuries can occur when normal forces are applied to abnormally weak tissues, or when abnormally high forces are applied to normal tissues [2].

Environmental factors have only modest effects on disc degeneration

Considering the influences of the genetic predisposition discussed above, the impact of mechanical forces on disc degeneration is only minor. Therefore, it is not surprising that several studies carried out in humans did not provide a strong causal link between occupational exposures and disc degeneration [146]. Even well-controlled animal experiments did not provide a conclusive connection between mechanical load and degeneration. However, it is conceivable that **abnormal loads** might cause damage to the adjacent vertebral bodies, especially the bony endplates, which in turn might contribute to the initiation of disc degeneration [3].

Abnormal mechanical loads contribute secondarily to disc degeneration

## The Cartilage Endplate

### Normal Anatomy and Composition

A morphological distinction of the disc and bone interface is the thin cartilage endplate. This **thin layer of hyaline cartilage** interfaces the disc and the vertebral body. The collagen fibers within it run horizontal and parallel to the vertebral bodies along with the fibers continuing into the disc [120]. At birth, the human cartilage endplates make up approximately 50 % of the intervertebral space

Cartilage endplates are mechanically important and influence nutritional pathways and growth

(compared with approximately 5 % in the adult) and have large vascular channels running through them. Soon after birth, the **vascular channels** of the cartilage endplate fill in with extracellular matrix such that no channels remain by the end of the first life decade. The cartilage endplate in humans functions in early life as a **growth plate** for the adjacent vertebral body; its structure is typical of that seen in the epiphyseal growth plate of long bones. This structure is lost during skeletal maturity. By adulthood, the cartilage endplate is a layer of hyaline cartilage (approximately 0.6 mm thick) with calcified cartilage adjoining the bone. The endplate occupies the central 90 % of the interface between the disc and the vertebral body, encompassed by a ring of bone that forms via the epiphysis fusing with the vertebral body in the rim region. The **endplate is totally avascular and aneural** in a healthy adult. Biomechanical properties of the cartilage include collagen types II, III, V, VI, IX, and X, which alter by age [99]. Functionally, the endplate is involved in **two important mechanical functions** [19]:

The endplate is important for the mechanical support and nutritional supply of the disc

- preventing the nucleus pulposus from bulging into the vertebral bodies
- partially absorbing the hydrostatic pressure dissipated by the nucleus pulposus under loading

Similar to the disc, the ability of the endplate to withstand mechanical forces depends on the structural integrity of the matrix.

### Age-Related Changes

Roberts et al. [119, 120] identified **changes in the endplate** that are becoming more frequent in the third decade of life:

- fissure formation
- fractures
- horizontal cleft formation
- death of chondrocytes
- increased vascular penetration
- extension of calcification and ossification

A study of cadaveric human vertebrae demonstrated that the number of vascular channels perforating the osseous vertebral endplate diminishes drastically between 6 and 30 months of age [30]. Analyses on the microscopic level revealed that the abundance of obliterated blood vessels in the endplate gradually increases between 1 month and 16 years of age. The **decrease in blood vessels** [17] is paralleled by:

- an increase in cartilage disorganization
- a decrease in endplate cell density
- cartilage cracks
- microfractures

Endplate calcification/ossification obstructs nutritional pathways

These changes, especially the loss of blood vessels, can cause nutritional consequences for the intervertebral disc. With advanced degeneration and markedly reduced disc height, further changes of the endplate are induced resulting in:

- complete endplate disarrangement
- dense sclerosis of the adjacent vertebral bodies

## The Facet Joints

### Normal Anatomy

The facet joints, also called **zygapophyseal joints**, are paired diarthrodial articulations between the posterior elements of adjacent vertebrae (Fig. 2). The joints exhibit the features of typical **synovial joints** and are an essential part of the posterior support structures of the spine consisting of:

- pedicles
- lamina
- spinous and transverse processes

Anatomically, the facet joints are responsible for restraining excessive mobility and for distributing axial load over a broad area. Adams and Hutton have found that the facet joints resist most of the intervertebral **shear force** [4]. The posterior anulus is protected in torsion by the facet surfaces and in flexion by the capsular ligaments. The posterior elements also serve as anchors for the spinal muscles. The earlier described "**menisci**" in the joints were found to be rudimentary fibrous invaginations of the dorsal and ventral capsule. They are basically fat-filled synovial reflections, some of which contain fibrous tissue probably as a result of mechanical stress. At the posterolateral aspect of the facet joint, a **fibrous capsule** composed of several layers of fibrous tissue and a synovial membrane is present. It has been shown that the synovial lining (small C-type pain fibers) and the capsules are **richly innervated** [16, 133]. This suggests that the facet joints dispose of the sensory apparatus to transmit inceptive and nociceptive information [16].

The facet joints resist most of the shear forces

The facet joint capsules are richly innervated

### Age-Related Changes

As seen in large synovial joints, a strong correlation has been found between orientation and misalignment of the joints as a **predisposing factor** for development of osteoarthritis. In contrast to osteoarthritic large synovial joints, the covering of the articular surfaces with hyaline cartilage is frequently retained in posterior intervertebral joints [137, 145]. This was observed even in the presence of large osteophytes and dense sclerosis of the subchondral bone. Preservation of articular cartilage is thought to be a sequela of changing joint surfaces. Late stages of **facet joint osteoarthritis** (OA) also demonstrate the **classic features** of synovial joint disease:

Facet malorientation and malalignment predispose for osteoarthritis

Osteoarthritis of large synovial and facet joints share common features

- complete loss of articular cartilage
- cysts and pseudocysts in the bone
- dense bone sclerosis
- large osteophyte formation

At this stage endplate fractures can occur which resemble breaches in the subchondral bone plate with protrusion of a portion of the articular cartilage into the subarticular bone. **Spontaneous fusion** of the facet joints **is very rare** in the absence of ankylosing spondylitis or ankylosing hyperostosis.

Spontaneous ankylosis of the facet joints is rare

Several authors [42, 137] have investigated the changes of zygapophyseal joints in relation to their biomechanical function. Changes in subchondral bone and articular cartilage in particular areas of the facets were corresponding to loading and shear forces imposed on them. Damage on the inferior surfaces lends some support to the hypothesis that their apices impact the laminae of the vertebra inferior to them as a result of degeneration and narrowing of the associated intervertebral disc. Fujiwara et al. [36] were able to show that **subchondral**

Subchondral sclerosis is an early sign of facet joint OA

**sclerosis** significantly decreased the motion and that severity of osteophytes had no significant association with the segmental motion.

According to **Kirkaldy-Willis' concept** (see Chapter 19), progressive degenerative changes in the posterior joint lead to marked destruction and instability [71]. Similar changes in the disc can result in herniation, internal disruption and resorption. Combined changes in the posterior joint and disc sometimes produce entrapment of a spinal nerve in the lateral recess, central stenosis at one level, or both of these conditions. Changes at one level often lead, over a period of years, to **multilevel spondylosis** and/or stenosis [72, 159]. Developmental stenosis is an enhancing factor in the presence of a small herniation leading to degenerative stenosis. Although several studies have provided some evidence that disc degeneration usually precedes facet joint osteoarthritis, the grade of disc degeneration did not correlate with those of the facet joint. The effect of muscle function remains controversial and will be discussed later.

Disc degeneration often precedes facet joint OA

## Vertebral Bodies

### Normal Anatomy and Composition

The bony components of the spine are responsible for the static stability of the spinal column. The microscopic (biochemical, cellular) and macroscopic architecture of the bone is well known and will not be repeated in this chapter.

### Age-Related Changes

Aging decreases vertebral strength and predisposes to fractures

Aging of the vertebral bodies is generally characterized by a decreased structural strength, mainly due to osteoporosis. **Decreased structural strength** is a result of changes to the:

- bone mineral density (BMD)
- bone architecture
- bone remodeling rate
- bone repair rate

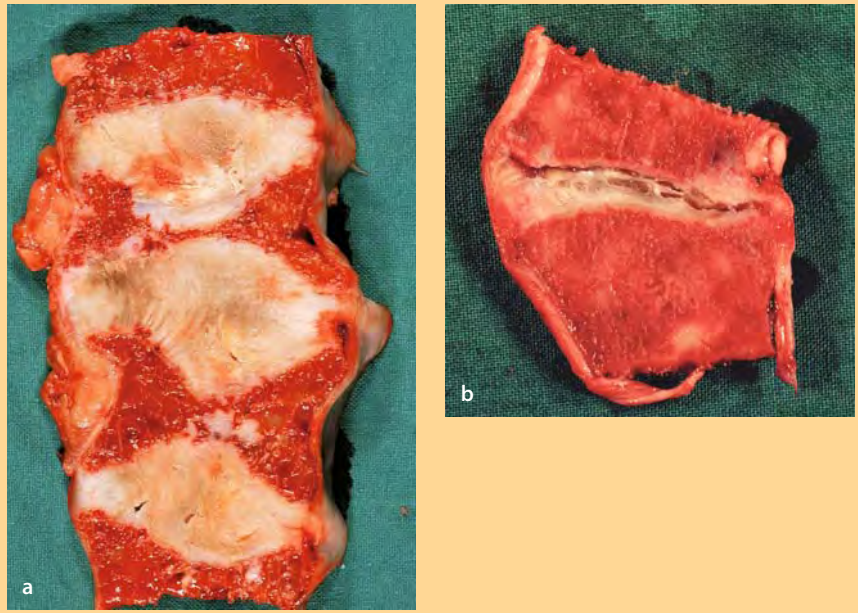


**Figure 6. Age-related changes of the vertebral bodies**

a A decline of structural strength due to osteoporosis can lead to a collapse of the vertebral body resulting in severe bulging of the intervertebral disc into the vertebral body. b Alternatively, age-related alterations to the vertebral bodies often lead to osteophyte formation, sclerosis and parallel collapse of the intervertebral disc.

The increased bone fragility induces **osteoporotic fractures** which lead to a bulging of the disc into the vertebral bodies (Fig. 6a), kyphotic vertebral deformities and sagittal imbalance (see Chapter 32). There is always some degree of osteophyte formation at the peripheral margins of the vertebral bodies, seen more anterolaterally than posteriorly. Bony ankylosis is seen only rarely since intervertebral disc tissue is usually found between the edges of the osteophytes. Most interestingly, not all individuals follow this course. There appears to be a different course which is characterized by a **severe sclerosis of the endplate** with complete collapse of the intervertebral discs (Fig. 6b). In these cases, ankylosing of vertebra may occur and vertebral compression fracture appears less likely. Due to a complete disc collapse, osteophyte formation and narrowing of the spinal canal and and foramen can result in compression of the cauda equina and nerve roots (see Chapter 19) [32].

## Spinal Ligaments

### Normal Anatomy and Composition

Ligaments surrounding the spine provide intrinsic stability to the spine and limit motion in all planes. The microscopic (biochemical, cellular) and macroscopic architecture of the ligaments is well known and will not be repeated in this chapter. The **spinal ligament complex** includes:

- interspinous ligaments
- supraspinous ligaments
- intertransverse ligaments
- yellow ligaments (ligamentum flavum)
- anterior and posterior longitudinal ligaments

High amounts of oriented fibrillar collagen provide tensile properties and are present in all ligaments [107, 149]. As an exception, the ligamentum flavum contains a high percentage of elastin [52].

### Age-Related Changes

With aging, as in other tissues, ligaments undergo macroscopic and biochemical changes:

- collagen and water concentration declines
- reducible collagen cross-links decrease
- non-reducible cross-links increase
- collagen fibrils become disorganized

Aging decreases ligamentous stabilization and can contribute to spinal stenosis

These changes affect the biomechanical behavior of the spinal ligaments [103, 104]. Cadaver studies have demonstrated that elastic modules and ultimate tensile stress of tendons as well as their restraining energy to failure were two to three times greater in young specimens (16–25 years) than in older specimens (48–68 years). Especially, the increase in elastin with age leads to decreased tensile properties, therefore affecting stabilization of the spine by the longitudinal ligaments.

Yellow ligament hypertrophy contributes to spinal stenosis

During aging, a hypertrophy of the ligamentum flavum is often observed [12, 72, 125, 156, 160]. This thickening together with a loss of disc height during degeneration causes bulging of the ligamentum flavum and therefore contributes to the narrowing of the spinal canal. All these changes will alter the biomechanics of the spine and can contribute to a compression of neural structures (spinal stenosis) [37, 54].

## Spinal Muscles

### Normal Anatomy and Structure

Skeletal muscles provide active movement of the articulated skeleton and maintenance of its posture. The basic property of the skeletal muscle is the contractility of its protoplasm (sarcoplasm).

The basic structure of the skeletal muscle is the muscle fiber, which is a fusion of many cells. This multinucleated cell can vary in size depending on the function of the muscle. An anterior horn cell in the myelon, its axon, the myoneural junction and the individual muscle fiber is called a **"motor unit". Two types of skeletal muscle fiber** can be distinguished by structure and function:

- slow twitch muscle fibers (ST)
- fast twitch muscle fibers (FT)

The properties of the two fiber types are summarized in Table 4.

Paraspinal muscles significantly contribute to spinal stability

The muscles of the trunk and pelvis have a major role in motion as well as dynamic and static stabilization of the spine (see Chapter 2). Postural dorsal (intrinsic) and abdominal muscles (extrinsic) are constantly active in a standing position. In motion, both muscle groups permit equilibrium and control of stability through antagonistic action to each other. Although the effect of intrinsic and extrinsic actions of the muscles was not included in the model of Kirkaldy-Willis, Goel et al. were able to show that muscles imparted stability to the motion segment [39]. The presence of muscles also led to decrease in stresses in the vertebral body, the intradiscal space and other mechanical parameters of importance. In an animal model by Kaigle et al. [66], paraspinal lumbar muscles were less efficient in providing stability during flexion-extension when chronic lesions were made in the intervertebral disc and facet joints. This observation provided evidence for a neuromuscular feedback system that is compromised by degenerated motion segments. Therefore, trunk muscles not only stabilize the spine but are also affected by degenerative alterations of the spine.

### Age-Related Changes

Age-related muscle degeneration is characterized by:

- decrease in size (loss of muscle mass)
- fatty infiltration
- deposits of connective tissue

**Loss of muscle mass** resulting from a decrease in the number and size of muscle cells appears to be the major cause of this change. Starting at the age of 25 years, skeletal muscle mass declines at a rate of 3–8% per decade until the age of 50 years; thereafter the rate of decrease increases to 10% per decade [89, 90]. Loss of muscle mass is evident in the considerable decrease in strength. Between the

**Table 4.** Fiber types present in skeletal muscles

| | Slow twitch fibers (ST) | Fast twitch fibers (FT) |
|---|---|---|
| Type | Type I | Type II |
| Endurance | long term | short term |
| Contraction velocity | slow | fast |
| Glycolytic capacity | low | high |
| Oxidative capacity | high | low |
| Resistance to fatigue | high | low |
| Activity | aerobic | anaerobic |

ages of 30 and 80 the strength of the muscle groups in the upper and lower extremities and the back decreases by as much as 60 % [73]. This age-related loss of muscle mass, also called sarcopenia, is thought to be caused by **immunological and hormonal changes** that occur with increasing age [150]. Interestingly, the factors found to be involved in sarcopenia vary between genders. In women sarcopenia is associated with estrogen, vitamin D levels and low IL-6 levels, whereas in men testosterone, physical performance and TNF-α were found responsible [53, 110, 111].

Age-related loss of muscle mass is caused by hormonal and immunological changes

Investigations applying imaging techniques such as CT and MRI demonstrated that the loss of muscle mass during aging is accompanied by the presence of deposits of fat and connective tissue in the muscles [85, 108]. Interestingly, Parkkola et al. demonstrated that **fat deposits** were only found in paraspinal muscles but not in psoas muscles and that the amount of fat in the paraspinal muscles increased with age [108]. Although several studies found a correlation between fat deposits in paraspinal muscles and the occurrence of low back pain, it is not yet clear if **muscle atrophy**, determined by higher amounts of fat, causes low back pain, or if muscle atrophy is a sequela to muscle disuse due to chronic low back pain [65, 91, 109].

Muscle atrophy is not closely linked to LBP

This age-related loss of muscle mass might compromise the stabilization of the spine by disrupting the balanced antagonist action of extensor and flexor muscles. The resulting imbalance, together with age-related alterations in other parts of the spine, might cause conditions such as degenerative scoliosis and may be a starting point for progressive disorganization of the spine [106].

One example of destabilization of the spine due to muscle loss is known as progressive lumbar kyphosis. This condition is believed to be caused by a non-specific myopathy of the paraspinal muscles resulting in a forward flexion of the trunk. Delisle et al. identified the muscular changes as type 2 muscle fiber atrophy in the multifidus muscle, the innermost and shortest of the paraspinal muscles [26].

In this context, Haig et al. were able to show that paraspinal denervation of the muscles was most pronounced in patients suffering from low back pain [44]. Although denervation was also seen in asymptomatic controls, the authors suggest that paraspinal denervation might play a role as a cause or exacerbator of the **degenerative cascade** described by Kirkaldy-Willis (see Chapter 19).

Age-related muscle loss causes destabilization and aggravates degenerative changes

However, often the musculoskeletal system is able to compensate for muscular degeneration and restore stabilization of the spine. Parkkola et al. [109] demonstrated an age-related atrophic phenomenon of the trunk muscles in patients with back pain in comparison with an asymptomatic control group. In this study, no correlation was found between isometric strength of the muscles and their cross-sectional area. Symptomatic patients with muscle degeneration did show better strength testing than asymptotic patients with an identical degree of muscle degeneration. The authors concluded that atrophic muscles secondary to pain restrictions are able to use the remaining muscle mass more efficiently than those whose atrophy is related to a sedentary lifestyle without clinical symptoms [109].

On the whole, degeneration of muscles, especially the paraspinal muscles, causes a disturbed equilibrium between the two antagonists, leading to decreased motion stability inducing a kyphotic attitude in the lumbar spine or scoliotic deformations.

## Recapitulation

In the next 25 years, a doubling of the number of people over the age 65 years can be expected. A significant increase in patients suffering from **musculoskeletal impairments** will result. In the musculoskeletal system, the spine with its **three joint complex** is subjected to earlier and more often age-related alterations than the other parts. Alterations to components of the spine can lead to chronic disabilities with **enormous socioeconomic impact**.

**Intervertebral disc.** During aging, the disc matrix undergoes major alterations including the degradation of its main matrix components collagen and proteoglycans, especially aggrecan. The **loss of aggrecan** from the nucleus pulposus is a major hallmark in disc degeneration leading to a decrease of osmotic pressure in the disc with consecutive loss of water and fibrotic transformation of the tissue. **Loss of water** results in changes of the mechanical behavior, causing **cleft and tear formation**, loss of disc height and herniation. Molecular changes to the disc cells results in increased expression of matrix degrading proteinases that are modulated by **cytokines and/or growth factors**. Although disc degeneration is influenced by a complex network of factors, the main contributions are the limited, diffusion-dependent nutritional supply to the disc cells due to the avascular nature of the disc and the genetic predisposition.

**Cartilage endplate.** The cartilage endplates form the interface between the well-vascularized vertebral bodies and the intervertebral disc. Age-related changes include fissure formation, fractures, horizontal cleft formation, death of chondrocytes, extension of calcification and ossification. Especially **calcification and ossification** decrease the permeability of the endplate, inhibiting the diffusion of nutrients to the inner parts of the disc contributing to the limited **nutritional supply** of the disc cells.

**Facet joints.** The facet joints are responsible for **restraining excessive mobility** of the spine and for **distributing axial load**. A correlation was found between orientation and misalignment of the joints and development of **osteoarthritis**. Generally it is accepted that **disc degeneration** with segmental instability and height loss **precedes facet joint degeneration**. Changes in subchondral bone and articular cartilage correspond to loading and shear forces imposed on them. Consecutive instability of the posterior joints results in **degenerative spondylolisthesis**, **spinal stenosis** through osteophyte formation and increased load on the intervertebral disc.

**Vertebral body.** The vertebral bodies are responsible for providing **static stability** to the spinal column. Aging of these bony structures, especially osteoporosis, leads to **decreased structural strength** mainly due to decreased bone mineral density and remodeling of the bone architecture. Together with repetitive torsional load, altered biomechanical properties can result in rotational deformities mostly due to **fractures**. Secondary pathologies include sclerosis and bone formation of the endplate, restricted blood supply to the disc and formation of osteophytes, ending up in spinal deformities. These changes can, together with changes in the posterior joints and spinal ligaments, cause spinal stenosis.

**Ligaments.** The ligaments of the spine **provide intrinsic stability and limit motion in all planes**. Age-related alterations to the composition of the ligaments affect collagen and elastin content, fiber organization and fiber cross-linking and lead to changes in the mechanical behavior of the ligaments. The reduced tensile strength results in destabilization of the spine. Consecutive **ligament hypertrophy**, especially of the ligamentum flavum, contributes to compression of neural structures.

**Muscles.** Age-related muscle degeneration is characterized by **loss of muscle mass**, **fatty infiltration** and deposits of connective tissue. Loss of muscle mass is due to gender-specific age-related immunological and hormonal changes. Consequently, the reduced strength of paraspinal and trunk muscles results in destabilization of the spine and might cause or exacerbate degenerative changes to the spine.

## Key Articles

**Kirkaldy-Willis WH, Wedge JH, Yong-Hing K, Reilly J (1978) Pathology and pathogenesis of lumbar spondylosis and stenosis. Spine 3(4):319–28**
In this study, autopsy specimens of lumbar spines were used to define the degenerative cascade of the spine. Progressive degenerative changes in the posterior joints lead to destruction and instability. Similar changes in the disc result in herniation, internal disruption, and resorption. Combined changes in posterior joint and disc can produce entrapment of a spinal nerve in the lateral recess and/or central stenosis. Changes at one level often lead, over a period of years, to multilevel spondylosis and/or stenosis.

**Miller JA, Schmatz C, Schultz AB (1988) Lumbar disc degeneration: correlation with age, sex, and spine level in 600 autopsy specimens. Spine 13(2):173–8**
This meta-analysis is based on data from 16 published reports. Macroscopic disc degeneration grades were correlated with age, sex, and level in 600 lumbar discs from 273 cadavers (0–96 years of age). Male discs were significantly more degenerated than female discs in the second, and fifth to seventh life decades. L4/L5 and L3/L4 level discs showed more degeneration than other levels. Higher mechanical stress, perhaps combined with longer nutritional pathways, may be responsible for the earlier degeneration of male discs.

**Boos N, Weissbach S, Rohrbach H, Weiler C, Spratt KF, Nerlich AG (2002) 2002 Volvo Award in Basic Science: Classification of age-related changes in lumbar intervertebral discs. Spine 27(23):2631–44**
This paper provides a systematic semiquantitative assessment of age-related morphologic changes in the intervertebral disc and cartilaginous endplate which is based on 20 250 histologic variables. The study revealed significant temporospatial variations with regard to presence and abundance of histologic disc alterations across levels, regions, macroscopic degeneration grades and age groups. The detailed analysis resulted in a practicable and reliable histologic classification system for lumbar discs which can serve as a morphologic reference framework. The article provides clear histologic evidence for the detrimental effect of a diminished blood supply to the intervertebral disc that appears to initiate disc tissue breakdown beginning in the first half of the second life decade.

**Horner HA, Phil M, Urban JPG (2001) 2001 Volvo Award Winner in Basic Science: Effect of nutrient supply on the viability of cells from the nucleus pulposus of the intervertebral disc. Spine 26(23):2543–49**
Nucleus pulposus cells were cultivated in a system where nutrient supply was dependent on diffusion, therefore simulating the situation in the intervertebral disc. It was found that the cell density was dependent on nutrient supply and was inversely related to disc thickness. Oxygen supply was not necessary for cell viability but was needed for proteoglycan production. Lack of glucose or low pH led to cell death suggesting nutrient restrictions contribute to disc degeneration.

**Roberts S, Urban JPG, Evans H, Eisenstein SM (1996) Transport properties of the human cartilage endplate in relation to its composition and calcification. Spine 21(4):415–20**
Transport properties of solutes of different sizes and shapes were correlated with the composition of the cartilage matrix. The more hydrated the matrix, the easier solutes were found to move. Increasing contents of proteoglycan, collagen or calcification resulted in greater restriction of solute movement. This finding confirmed that calcification of the cartilage endplate might have consequences for the nutrient supply to the disc and therefore for the onset of disc degeneration.

**Weiler C, Nerlich AG, Zipperer J, Bachmeier BE, Boos N (2002) 2002 SSE Award in Basic Science: Expression of major matrix metalloproteinases is associated with intervertebral disc degradation and resorption. Eur Spine J 11(4):308–20**
The role of matrix metalloproteinases (MMPs) in matrix degradation leading to disc degeneration was investigated in 30 cross-sections of lumbar intervertebral discs from cadavers (0–86 years of age). Expression of major MMPs was found to correlate with age and the occurrence of signs of degeneration, i.e. clefts and tears. These data indicated that major MMPs play an important role in matrix degradation that might lead to disc degeneration and possibly to the induction of low back pain.

**Battie MC, Videman T, Gibbons LE, Fisher LD, Manninen H, Gill K (1995) 1995 Volvo Award in Clinical Sciences. Determinants of lumbar disc degeneration. A study relating lifetime exposures and magnetic resonance findings in identical twins. Spine 20(24):2601 – 12**
Effects of lifetime exposure of 115 twin pairs to commonly suspected risk factors on disc degeneration were assessed by magnetic resonance imaging and their influence was compared to age and familial aggregation, reflecting genetic and shared environmental influences. The results of this study suggested that disc degeneration may be primarily explained by genetic influences, with environmental factors, widely suspected of accelerating disc degeneration, only having very modest effects.

**Adams MA, Freeman BJC, Morrison HP, Nelson IW, Dolan P (2000) Mechanical initiation of intervertebral disc degeneration. Spine 25(13):1625 – 36**
It was investigated whether minor damage to a vertebral body can lead to progressive disruption of the adjacent intervertebral disc. After cadaveric lumbar motion segments were subjected to complex loading patterns to simulate typical activities, compressive damage to the bony endplates was observed, altering the compressive stress distribution on the adjacent disc. Further loading cycles resulted in progressive structural changes and deterioration of the adjacent discs.

## References


1. Abbaszade I, Liu RQ, Yang F, Rosenfeld SA, Ross OH, Link JR, Ellis DM, Tortorella MD, Pratta MA, Hollis JM, Wynn R, Duke JL, George HJ, Hillman MC, Jr, Murphy K, Wiswall BH, Copeland RA, Decicco CP, Bruckner R, Nagase H, Itoh Y, Newton RC, Magolda RL, Trzaskos JM, Burn TC, et al. (1999) Cloning and characterization of ADAMTS11, an aggrecanase from the ADAMTS family. J Biol Chem 274:23443 – 23450
2. Adams MA, Dolan P (2005) Spine biomechanics. J Biomech 38:1972 – 1983
3. Adams MA, Freeman BJ, Morrison HP, Nelson IW, Dolan P (2000) Mechanical initiation of intervertebral disc degeneration. Spine 25:1625 – 1636
4. Adams MA, Hutton WC (1980) The effect of posture on the role of the apophysial joints in resisting intervertebral compressive forces. J Bone Joint Surg Br 62:358 – 362
5. Adams P, Eyre DR, Muir H (1977) Biochemical aspects of development and ageing of human lumbar intervertebral discs. Rheumatol Rehabil 16:22 – 29
6. Adams P, Muir H (1976) Qualitative changes with age of proteoglycans of human lumbar discs. Ann Rheum Dis 35:289 – 296
7. Ahn SH, Cho YW, Ahn MW, Jang SH, Sohn YK, Kim HS (2002) mRNA expression of cytokines and chemokines in herniated lumbar intervertebral discs. Spine 27:911 – 917
8. Akhtar S, Davies JR, Caterson B (2005) Ultrastructural immunolocalization of alpha-elastin and keratan sulfate proteoglycan in normal and scoliotic lumbar disc. Spine 30:1762 – 1769
9. Anderson DG, Izzo MW, Hall DJ, Vaccaro AR, Hilibrand A, Arnold W, Tuan RS, Albert TJ (2002) Comparative gene expression profiling of normal and degenerative discs: analysis of a rabbit annular laceration model. Spine 27:1291 – 1296
10. Antoniou J, Steffen T, Nelson F, Winterbottom N, Hollander AP, Poole RA, Aebi M, Alini M (1996) The human lumbar intervertebral disc: evidence for changes in the biosynthesis and denaturation of the extracellular matrix with growth, maturation, ageing, and degeneration. J Clin Invest 98:996 – 1003
11. Battie MC, Videman T, Gibbons LE, Fisher LD, Manninen H, Gill K (1995) 1995 Volvo Award in clinical sciences. Determinants of lumbar disc degeneration. A study relating lifetime exposures and magnetic resonance imaging findings in identical twins. Spine 20:2601 – 2612
12. Beamer YB, Garner JT, Shelden CH (1973) Hypertrophied ligamentum flavum. Clinical and surgical significance. Arch Surg 106:289 – 292
13. Benneker LM, Heini PF, Alini M, Anderson SE, Ito K (2005) 2004 Young Investigator Award Winner: vertebral endplate marrow contact channel occlusions and intervertebral disc degeneration. Spine 30:167 – 173
14. Bernick S, Cailliet R (1982) Vertebral end-plate changes with aging of human vertebrae. Spine 7:97 – 102
15. Boden SD, Davis DO, Dina TS, Patronas NJ, Wiesel SW (1990) Abnormal magnetic-resonance scans of the lumbar spine in asymptomatic subjects. A prospective investigation. J Bone Joint Surg Am 72:403 – 408
16. Bogduk N (1983) The innervation of the lumbar spine. Spine 8:286 – 293
17. Boos N, Weissbach S, Rohrbach H, Weiler C, Spratt KF, Nerlich AG (2002) Classification of age-related changes in lumbar intervertebral discs: 2002 Volvo Award in basic science. Spine 27:2631 – 2644

18. Braly WG, Tullos HS (1985) A modification of the Bristow procedure for recurrent anterior shoulder dislocation and subluxation. Am J Sports Med 13:81 – 86
19. Broberg KB (1983) On the mechanical behaviour of intervertebral discs. Spine 8:151 – 165
20. Burke JG, Watson RWG, Conhyea D, McCormack D, Dowling FE, Walsh MG, Fitzpatrick JM (2003) Human nucleus pulposis can respond to a pro-inflammatory stimulus. Spine 28: 2685 – 2693
21. Burke JG, Watson RW, McCormack D, Dowling FE, Walsh MG, Fitzpatrick JM (2002) Intervertebral discs which cause low back pain secrete high levels of proinflammatory mediators. J Bone Joint Surg Br 84:196 – 201
22. Chandraraj S, Briggs CA, Opeskin K (1998) Disc herniations in the young and end-plate vascularity. Clin Anat 11:171 – 176
23. Crock HV, Goldwasser M (1984) Anatomic studies of the circulation in the region of the vertebral end-plate in adult Greyhound dogs. Spine 9:702 – 706
24. Crock HV, Yoshizawa H (1976) The blood supply of the lumbar vertebral column. Clin Orthop Relat Res:6 – 21
25. Cs-Szabo G, Ragasa-San Juan D, Turumella V, Masuda K, Thonar EJ, An HS (2002) Changes in mRNA and protein levels of proteoglycans of the anulus fibrosus and nucleus pulposus during intervertebral disc degeneration. Spine 27:2212 – 2219
26. Delisle MB, Laroche M, Dupont H, Rochaix P, Rumeau JL (1993) Morphological analyses of paraspinal muscles: comparison of progressive lumbar kyphosis (camptocormia) and narrowing of lumbar canal by disc protrusions. Neuromuscul Disord 3:579 – 582
27. Doita M, Kanatani T, Ozaki T, Matsui N, Kurosaka M, Yoshiya S (2001) Influence of macrophage infiltration of herniated disc tissue on the production of matrix metalloproteinases leading to disc resorption. Spine 26:1522 – 1527
28. Donisch EW, Trapp W (1971) The cartilage endplates of the human vertebral column (some considerations of postnatal development). Anat Rec 169:705 – 716
29. Duance VC, Crean JK, Sims TJ, Avery N, Smith S, Menage J, Eisenstein SM, Roberts S (1998) Changes in collagen cross-linking in degenerative disc disease and scoliosis. Spine 23: 2545 – 2551
30. Edelson JG, Nathan H (1988) Stages in the natural history of the vertebral end-plates. Spine 13:21 – 26
31. Eyre DR, Muir H (1977) Quantitative analysis of types I and II collagens in human intervertebral discs at various ages. Biochim Biophys Acta 492:29 – 42
32. Farfan HF (1980) The pathological anatomy of degenerative spondylolisthesis. A cadaver study. Spine 5:412 – 418
33. Fischgrund JS, Montgomery DM (1993) Diagnosis and treatment of discogenic low back pain. Orthop Rev 22:311 – 318
34. Friberg S, Hirsch C (1949) Anatomical and clinical studies on lumbar disc degeneration. Acta Orthop Scand 19:222 – 242, illust
35. Frymoyer JW, Cats-Baril WL (1991) An overview of the incidences and costs of low back pain. Orthop Clin North Am 22:263 – 271
36. Fujiwara A, Lim TH, An HS, Tanaka N, Jeon CH, Andersson GB, Haughton VM (2000) The effect of disc degeneration and facet joint osteoarthritis on the segmental flexibility of the lumbar spine. Spine 25:3036 – 3044
37. Fukuyama S, Nakamura T, Ikeda T, Takagi K (1995) The effect of mechanical stress on hypertrophy of the lumbar ligamentum flavum. J Spinal Disord 8:126 – 130
38. Ghosh P, Taylor TK, Braund KG, Larsen LH (1976) The collagenous and non-collagenous protein of the canine intervertebral disc and their variation with age, spinal level and breed. Gerontology 22:124 – 134
39. Goel VK, Kong W, Han JS, Weinstein JN, Gilbertson LG (1993) A combined finite element and optimization investigation of lumbar spine mechanics with and without muscles. Spine 18:1531 – 1541
40. Grecula MJ, Caban ME (2005) Common orthopaedic problems in the elderly patient. J Am Coll Surg 200:774 – 783
41. Greg Anderson D, Li X, Tannoury T, Beck G, Balian G (2003) A fibronectin fragment stimulates intervertebral disc degeneration in vivo. Spine 28:2338 – 2345
42. Gries NC, Berlemann U, Moore RJ, Vernon-Roberts B (2000) Early histologic changes in lower lumbar discs and facet joints and their correlation. Eur Spine J 9:23 – 29
43. Gruber HE, Hanley EN, Jr (1998) Analysis of aging and degeneration of the human intervertebral disc. Comparison of surgical specimens with normal controls. Spine 23:751 – 757
44. Haig AJ (2002) Paraspinal denervation and the spinal degenerative cascade. Spine J 2: 372 – 380
45. Hamerman D (1997) Aging and the musculoskeletal system. Ann Rheum Dis 56:578 – 585
46. Hassler O (1969) The human intervertebral disc. A micro-angiographical study on its vascular supply at various ages. Acta Orthop Scand 40:765 – 772
47. Haughton V (2006) Imaging intervertebral disc degeneration. J Bone Joint Surg Am 88 Suppl 2:15 – 20
48. Heikkila JK, Koskenvuo M, Heliovaara M, Kurppa K, Riihimaki H, Heikkila K, Rita H, Vide-

man T (1989) Genetic and environmental factors in sciatica. Evidence from a nationwide panel of 9 365 adult twin pairs. Ann Med 21:393 – 398
49. Holm S, Maroudas A, Urban JP, Selstam G, Nachemson A (1981) Nutrition of the intervertebral disc: solute transport and metabolism. Connect Tissue Res 8:101 – 119
50. Holm S, Nachemson A (1988) Nutrition of the intervertebral disc: acute effects of cigarette smoking. An experimental animal study. Ups J Med Sci 93:91 – 99
51. Horner HA, Urban JP (2001) 2001 Volvo Award Winner in Basic Science Studies: Effect of nutrient supply on the viability of cells from the nucleus pulposus of the intervertebral disc. Spine 26:2543 – 2549
52. Hukins DW, Kirby MC, Sikoryn TA, Aspden RM, Cox AJ (1990) Comparison of structure, mechanical properties, and functions of lumbar spinal ligaments. Spine 15:787 – 795
53. Iannuzzi-Sucich M, Prestwood KM, Kenny AM (2002) Prevalence of sarcopenia and predictors of skeletal muscle mass in healthy, older men and women. J Gerontol A Biol Sci Med Sci 57:M772 – 777
54. Iida T, Abumi K, Kotani Y, Kaneda K (2002) Effects of aging and spinal degeneration on mechanical properties of lumbar supraspinous and interspinous ligaments. Spine J 2: 95 – 100
55. Inkinen RI, Lammi MJ, Lehmonen S, Puustjarvi K, Kaapa E, Tammi MI (1998) Relative increase of biglycan and decorin and altered chondroitin sulfate epitopes in the degenerating human intervertebral disc. J Rheumatol 25:506 – 514
56. Ishihara H, Urban JP (1999) Effects of low oxygen concentrations and metabolic inhibitors on proteoglycan and protein synthesis rates in the intervertebral disc. J Orthop Res 17: 829 – 835
57. Ito M, Abumi K, Takeda N, Satoh S, Hasegawa K, Kaneda K (1998) Pathologic features of spinal disorders in patients treated with long-term hemodialysis. Spine 23:2127 – 2133
58. Itoi E, Tabata S (1992) Conservative treatment of rotator cuff tears. Clin Orthop:165 – 173
59. Jim JJ, Noponen-Hietala N, Cheung KM, Ott J, Karppinen J, Sahraravand A, Luk KD, Yip SP, Sham PC, Song YQ, Leong JC, Cheah KS, Ala-Kokko L, Chan D (2005) The TRP2 allele of COL9A2 is an age-dependent risk factor for the development and severity of intervertebral disc degeneration. Spine 30:2735 – 2742
60. Jimbo K, Park JS, Yokosuka K, Sato K, Nagata K (2005) Positive feedback loop of interleukin-1beta upregulating production of inflammatory mediators in human intervertebral disc cells in vitro. J Neurosurg Spine 2:589 – 595
61. Johnson WE, Evans H, Menage J, Eisenstein SM, El Haj A, Roberts S (2001) Immunohistochemical detection of Schwann cells in innervated and vascularized human intervertebral discs. Spine 26:2550 – 2557
62. Johnstone B, Markopoulos M, Neame P, Caterson B (1993) Identification and characterization of glycanated and non-glycanated forms of biglycan and decorin in the human intervertebral disc. Biochem J 292(3):661 – 666
63. Jones G, White C, Sambrook P, Eisman J (1998) Allelic variation in the vitamin D receptor, lifestyle factors and lumbar spinal degenerative disease. Ann Rheum Dis 57:94 – 99
64. Junghanns SA (1971) The human spine in health and disease. Grune and Stratton, New York London
65. Kader DF, Wardlaw D, Smith FW (2000) Correlation between the MRI changes in the lumbar multifidus muscles and leg pain. Clin Radiol 55:145 – 149
66. Kaigle AM, Wessberg P, Hansson TH (1998) Muscular and kinematic behavior of the lumbar spine during flexion-extension. J Spinal Disord 11:163 – 174
67. Karppinen J, Paakko E, Paassilta P, Lohiniva J, Kurunlahti M, Tervonen O, Nieminen P, Goring HH, Malmivaara A, Vanharanta H, Ala-Kokko L (2003) Radiologic phenotypes in lumbar MR imaging for a gene defect in the COL9A3 gene of type IX collagen. Radiology 227: 143 – 148
68. Karppinen J, Paakko E, Raina S, Tervonen O, Kurunlahti M, Nieminen P, Ala-Kokko L, Malmivaara A, Vanharanta H (2002) Magnetic resonance imaging findings in relation to the COL9A2 tryptophan allele among patients with sciatica. Spine 27:78 – 83
69. Kawaguchi Y, Kanamori M, Ishihara H, Ohmori K, Matsui H, Kimura T (2002) The association of lumbar disc disease with vitamin-D receptor gene polymorphism. J Bone Joint Surg Am 84-A:2022 – 2028
70. Kawaguchi Y, Osada R, Kanamori M, Ishihara H, Ohmori K, Matsui H, Kimura T (1999) Association between an aggrecan gene polymorphism and lumbar disc degeneration. Spine 24:2456 – 2460
71. Kirkaldy-Willis WH (1984) The relationship of structural pathology to the nerve root. Spine 9:49 – 52
72. Kirkaldy-Willis WH, Wedge JH, Yong-Hing K, Reilly J (1978) Pathology and pathogenesis of lumbar spondylosis and stenosis. Spine 3:319 – 328
73. Kirkendall DT, Garrett WE, Jr (1998) The effects of aging and training on skeletal muscle. Am J Sports Med 26:598 – 602
74. Konttinen YT, Kemppinen P, Li TF, Waris E, Pihlajamaki H, Sorsa T, Takagi M, Santavirta S,

Schultz GS, Humphreys-Beher MG (1999) Transforming and epidermal growth factors in degenerated intervertebral discs. J Bone Joint Surg Br 81:1058 – 1063
75. Kuno K, Kanada N, Nakashima E, Fujiki F, Ichimura F, Matsushima K (1997) Molecular cloning of a gene encoding a new type of metalloproteinase-disintegrin family protein with thrombospondin motifs as an inflammation associated gene. J Biol Chem 272:556 – 562
76. Ladefoged C (1985) Amyloid in intervertebral discs. A histopathological investigation of intervertebral discs from 30 randomly selected autopsies. Appl Pathol 3:96 – 104
77. Le Maitre CL, Freemont AJ, Hoyland JA (2004) Localization of degradative enzymes and their inhibitors in the degenerate human intervertebral disc. J Pathol 204:47 – 54
78. Le Maitre CL, Freemont AJ, Hoyland JA (2005) The role of interleukin-1 in the pathogenesis of human intervertebral disc degeneration. Arthritis Res Ther 7:R732 – 745
79. Leveille SG (2004) Musculoskeletal aging. Curr Opin Rheumatol 16:114 – 118
80. Maniadakis N, Gray A (2000) The economic burden of back pain in the UK. Pain 84:95 – 103
81. Marcelli C, Perennou D, Cyteval C, Leray H, Lamarque JL, Mion C, Simon L (1996) Amyloidosis-related cauda equina compression in long-term hemodialysis patients. Three case reports. Spine 21:381 – 385
82. Marchand F, Ahmed AM (1990) Investigation of the laminate structure of lumbar disc anulus fibrosus. Spine 15:402 – 410
83. Matsui H, Kanamori M, Ishihara H, Yudoh K, Naruse Y, Tsuji H (1998) Familial predisposition for lumbar degenerative disc disease. A case-control study. Spine 23:1029 – 1034
84. Matsui H, Terahata N, Tsuji H, Hirano N, Naruse Y (1992) Familial predisposition and clustering for juvenile lumbar disc herniation. Spine 17:1323 – 1328
85. McLoughlin RF, D'Arcy EM, Brittain MM, Fitzgerald O, Masterson JB (1994) The significance of fat and muscle areas in the lumbar paraspinal space: a CT study. J Comput Assist Tomogr 18:275 – 278
86. McMeeken J, Tully E, Stillman B, Nattrass C, Bygott IL, Story I (2001) The experience of back pain in young Australians. Man Ther 6:213 – 220
87. Melrose J, Ghosh P, Taylor TK (2001) A comparative analysis of the differential spatial and temporal distributions of the large (aggrecan, versican) and small (decorin, biglycan, fibromodulin) proteoglycans of the intervertebral disc. J Anat 198:3 – 15
88. Melrose J, Roberts S, Smith S, Menage J, Ghosh P (2002) Increased nerve and blood vessel ingrowth associated with proteoglycan depletion in an ovine anular lesion model of experimental disc degeneration. Spine 27:1278 – 1285
89. Melton LJ, 3rd, Khosla S, Crowson CS, O'Connor MK, O'Fallon WM, Riggs BL (2000) Epidemiology of sarcopenia. J Am Geriatr Soc 48:625 – 630
90. Melton LJ, 3rd, Khosla S, Riggs BL (2000) Epidemiology of sarcopenia. Mayo Clin Proc 75 Suppl:S10 – 12; discussion S12 – 13
91. Mengiardi B, Schmid MR, Boos N, Pfirrmann CW, Brunner F, Elfering A, Hodler J (2006) Fat content of lumbar paraspinal muscles in patients with chronic low back pain and in asymptomatic volunteers: quantification with MR spectroscopy. Radiology 240:786 – 792
92. Miller JA, Schmatz C, Schultz AB (1988) Lumbar disc degeneration: correlation with age, sex, and spine level in 600 autopsy specimens. Spine 13:173 – 178
93. Miyamoto H, Saura R, Harada T, Doita M, Mizuno K (2000) The role of cyclooxygenase-2 and inflammatory cytokines in pain induction of herniated lumbar intervertebral disc. Kobe J Med Sci 46:13 – 28
94. Murata Y, Onda A, Rydevik B, Takahashi I, Takahashi K, Olmarker K (2006) Changes in pain behavior and histologic changes caused by application of tumor necrosis factor-alpha to the dorsal root ganglion in rats. Spine 31:530 – 535
95. Nachemson A (1960) Lumbar intradiscal pressure. Experimental studies on post-mortem material. Acta Orthop Scand Suppl 43:1 – 104
96. Nachemson A, Lewin T, Maroudas A, Freeman MA (1970) In vitro diffusion of dye through the end-plates and the annulus fibrosus of human lumbar intervertebral discs. Acta Orthop Scand 41:589 – 607
97. Nerlich AG, Bachmeier BE, Boos N (2005) Expression of fibronectin and TGF-beta1 mRNA and protein suggest altered regulation of extracellular matrix in degenerated disc tissue. Eur Spine J 14:17 – 26
98. Nerlich AG, Boos N, Wiest I, Aebi M (1998) Immunolocalization of major interstitial collagen types in human lumbar intervertebral discs of various ages. Virchows Arch 432:67 – 76
99. Nerlich AG, Schleicher ED, Boos N (1997) 1997 Volvo Award winner in basic science studies. Immunohistologic markers for age-related changes of human lumbar intervertebral discs. Spine 22:2781 – 2795
100. Noponen-Hietala N, Kyllonen E, Mannikko M, Ilkko E, Karppinen J, Ott J, Ala-Kokko L (2003) Sequence variations in the collagen IX and XI genes are associated with degenerative lumbar spinal stenosis. Ann Rheum Dis 62:1208 – 1214
101. Noponen-Hietala N, Virtanen I, Karttunen R, Schwenke S, Jakkula E, Li H, Merikivi R, Baral S, Ott J, Karppinen J, Ala-Kokko L (2005) Genetic variations in IL6 associate with intervertebral disc disease characterized by sciatica. Pain 114:186 – 194

102. Ogata K, Whiteside LA (1981) 1980 Volvo award winner in basic science. Nutritional pathways of the intervertebral disc. An experimental study using hydrogen washout technique. Spine 6:211 – 216
103. Okuda T, Baba I, Fujimoto Y, Tanaka N, Sumida T, Manabe H, Hayashi Y, Ochi M (2004) The pathology of ligamentum flavum in degenerative lumbar disease. Spine 29:1689 – 1697
104. Okuda T, Fujimoto Y, Tanaka N, Ishida O, Baba I, Ochi M (2005) Morphological changes of the ligamentum flavum as a cause of nerve root compression. Eur Spine J 14:277 – 286
105. Panagiotacopulos ND, Knauss WG, Bloch R (1979) On the mechanical properties of human intervertebral disc material. Biorheology 16:317 – 330
106. Panjabi M, Abumi K, Duranceau J, Oxland T (1989) Spinal stability and intersegmental muscle forces. A biomechanical model. Spine 14:194 – 200
107. Panjabi MM, Goel VK, Takata K (1982) Physiologic strains in the lumbar spinal ligaments. An in vitro biomechanical study 1981 Volvo Award in Biomechanics. Spine 7:192 – 203
108. Parkkola R, Kormano M (1992) Lumbar disc and back muscle degeneration on MRI: correlation to age and body mass. J Spinal Disord 5:86 – 92
109. Parkkola R, Rytokoski U, Kormano M (1993) Magnetic resonance imaging of the discs and trunk muscles in patients with chronic low back pain and healthy control subjects. Spine 18:830 – 836
110. Payette H, Roubenoff R, Jacques PF, Dinarello CA, Wilson PW, Abad LW, Harris T (2003) Insulin-like growth factor-1 and interleukin 6 predict sarcopenia in very old community-living men and women: the Framingham Heart Study. J Am Geriatr Soc 51:1237 – 1243
111. Pedersen M, Bruunsgaard H, Weis N, Hendel HW, Andreassen BU, Eldrup E, Dela F, Pedersen BK (2003) Circulating levels of TNF-alpha and IL-6-relation to truncal fat mass and muscle mass in healthy elderly individuals and in patients with type-2 diabetes. Mech Ageing Dev 124:495 – 502
112. Pluijm SM, van Essen HW, Bravenboer N, Uitterlinden AG, Smit JH, Pols HA, Lips P (2004) Collagen type I alpha1 Sp1 polymorphism, osteoporosis, and intervertebral disc degeneration in older men and women. Ann Rheum Dis 63:71 – 77
113. Pokharna HK, Phillips FM (1998) Collagen crosslinks in human lumbar intervertebral disc aging. Spine 23:1645 – 1648
114. Postacchini F, Bellocci M, Massobrio M (1984) Morphologic changes in annulus fibrosus during aging. An ultrastructural study in rats. Spine 9:596 – 603
115. Powell MC, Wilson M, Szypryt P, Symonds EM, Worthington BS (1986) Prevalence of lumbar disc degeneration observed by magnetic resonance in symptomless women. Lancet 2:1366 – 1367
116. Ratcliffe JF (1980) The arterial anatomy of the adult human lumbar vertebral body: a microarteriographic study. J Anat 131:57 – 79
117. Roberts S (2002) Disc morphology in health and disease. Biochem Soc Trans 30:864 – 869
118. Roberts S, Caterson B, Menage J, Evans EH, Jaffray DC, Eisenstein SM (2000) Matrix metalloproteinases and aggrecanase: their role in disorders of the human intervertebral disc. Spine 25:3005 – 3013
119. Roberts S, Menage J, Duance V, Wotton S, Ayad S (1991) 1991 Volvo Award in basic sciences. Collagen types around the cells of the intervertebral disc and cartilage end plate: an immunolocalization study. Spine 16:1030 – 1038
120. Roberts S, Menage J, Urban JP (1989) Biochemical and structural properties of the cartilage end-plate and its relation to the intervertebral disc. Spine 14:166 – 174
121. Roughley PJ (2004) Biology of intervertebral disc aging and degeneration: involvement of the extracellular matrix. Spine 29:2691 – 2699
122. Roughley PJ, White RJ, Magny MC, Liu J, Pearce RH, Mort JS (1993) Non-proteoglycan forms of biglycan increase with age in human articular cartilage. Biochem J 295(2): 421 – 426
123. Roukis TS, Jacobs PM, Dawson DM, Erdmann BB, Ringstrom JB (2002) A prospective comparison of clinical, radiographic, and intraoperative features of hallux rigidus: short-term follow-up and analysis. J Foot Ankle Surg 41:158 – 165
124. Rudert M, Tillmann B (1993) Detection of lymph and blood vessels in the human intervertebral disc by histochemical and immunohistochemical methods. Ann Anat 175:237 – 242
125. Schrader PK, Grob D, Rahn BA, Cordey J, Dvorak J (1999) Histology of the ligamentum flavum in patients with degenerative lumbar spinal stenosis. Eur Spine J 8:323 – 328
126. Scott JE, Bosworth TR, Cribb AM, Taylor JR (1994) The chemical morphology of age-related changes in human intervertebral disc glycosaminoglycans from cervical, thoracic and lumbar nucleus pulposus and annulus fibrosus. J Anat 184(1):73 – 82
127. Sebert JL, Fardellone P, Deramond H, Marie A, Lansaman J, Bardin T, Lambrey G, Gheerbrant JD, Legars D, Galibert P, et al. (1986) [Destructive spondylarthropathy with amyloid deposits in 3 patients on chronic hemodialysis]. Rev Rhum Mal Osteoartic 53:459 – 465
128. Seguin CA, Bojarski M, Pilliar RM, Roughley PJ, Kandel RA (2006) Differential regulation of matrix degrading enzymes in a TNFalpha-induced model of nucleus pulposus tissue degeneration. Matrix Biol 25:409 – 418

129. Seki S, Kawaguchi Y, Chiba K, Mikami Y, Kizawa H, Oya T, Mio F, Mori M, Miyamoto Y, Masuda I, Tsunoda T, Kamata M, Kubo T, Toyama Y, Kimura T, Nakamura Y, Ikegawa S (2005) A functional SNP in CILP, encoding cartilage intermediate layer protein, is associated with susceptibility to lumbar disc disease. Nat Genet 37:607 – 612
130. Solovieva S, Kouhia S, Leino-Arjas P, Ala-Kokko L, Luoma K, Raininko R, Saarela J, Riihimaki H (2004) Interleukin 1 polymorphisms and intervertebral disc degeneration. Epidemiology 15:626 – 633
131. Solovieva S, Lohiniva J, Leino-Arjas P, Raininko R, Luoma K, Ala-Kokko L, Riihimaki H (2002) COL9A3 gene polymorphism and obesity in intervertebral disc degeneration of the lumbar spine: evidence of gene-environment interaction. Spine 27:2691 – 2696
132. Specchia N, Pagnotta A, Toesca A, Greco F (2002) Cytokines and growth factors in the protruded intervertebral disc of the lumbar spine. Eur Spine J 11:145 – 151
133. Suseki K, Takahashi Y, Takahashi K, Chiba T, Tanaka K, Morinaga T, Nakamura S, Moriya H (1997) Innervation of the lumbar facet joints. Origins and functions. Spine 22:477 – 485
134. Sztrolovics R, Alini M, Mort JS, Roughley PJ (1999) Age-related changes in fibromodulin and lumican in human intervertebral discs. Spine 24:1765 – 1771
135. Sztrolovics R, Alini M, Roughley PJ, Mort JS (1997) Aggrecan degradation in human intervertebral disc and articular cartilage. Biochem J 326(1):235 – 241
136. Takahashi M, Haro H, Wakabayashi Y, Kawauchi T, Komori H, Shinomiya K (2001) The association of degeneration of the intervertebral disc with 5a/6a polymorphism in the promoter of the human matrix metalloproteinase-3 gene. J Bone Joint Surg Br 83:491 – 495
137. Taylor JR, Twomey LT (1986) Age changes in lumbar zygapophyseal joints. Observations on structure and function. Spine 11:739 – 745
138. Thompson JP, Pearce RH, Schechter MT, Adams ME, Tsang IK, Bishop PB (1990) Preliminary evaluation of a scheme for grading the gross morphology of the human intervertebral disc. Spine 15:411 – 415
139. Tortorella MD, Burn TC, Pratta MA, Abbaszade I, Hollis JM, Liu R, Rosenfeld SA, Copeland RA, Decicco CP, Wynn R, Rockwell A, Yang F, Duke JL, Solomon K, George H, Bruckner R, Nagase H, Itoh Y, Ellis DM, Ross H, Wiswall BH, Murphy K, Hillman MC, Jr, Hollis GF, Newton RC, Magolda RL, Trzaskos JM, Arner EC (1999) Purification and cloning of aggrecanase-1: a member of the ADAMTS family of proteins. Science 284:1664 – 1666
140. Tsuru M, Nagata K, Ueno T, Jimi A, Irie K, Yamada A, Nishida T, Sata M (2001) Electron microscopic observation of established chondrocytes derived from human intervertebral disc hernia (KTN-1) and role of macrophages in spontaneous regression of degenerated tissues. Spine J 1:422 – 431
141. Twomey LT, Taylor JR (1987) Age changes in lumbar vertebrae and intervertebral discs. Clin Orthop Relat Res:97 – 104
142. Urban JP, Holm S, Maroudas A, Nachemson A (1977) Nutrition of the intervertebral disk. An in vivo study of solute transport. Clin Orthop Relat Res:101 – 114
143. Urban JP, Smith S, Fairbank JC (2004) Nutrition of the intervertebral disc. Spine 29: 2700 – 2709
144. Varlotta GP, Brown MD, Kelsey JL, Golden AL (1991) Familial predisposition for herniation of a lumbar disc in patients who are less than twenty-one years old. J Bone Joint Surg Am 73:124 – 128
145. Vernon-Roberts B, Pirie CJ (1977) Degenerative changes in the intervertebral discs of the lumbar spine and their sequelae. Rheumatol Rehabil 16:13 – 21
146. Videman T, Battie MC (1999) The influence of occupation on lumbar degeneration. Spine 24:1164 – 1168
147. Videman T, Gibbons LE, Battie MC, Maravilla K, Vanninen E, Leppavuori J, Kaprio J, Peltonen L (2001) The relative roles of intragenic polymorphisms of the vitamin D receptor gene in lumbar spine degeneration and bone density. Spine 26:E7–E12
148. Videman T, Leppavuori J, Kaprio J, Battie MC, Gibbons LE, Peltonen L, Koskenvuo M (1998) Intragenic polymorphisms of the vitamin D receptor gene associated with intervertebral disc degeneration. Spine 23:2477 – 2485
149. Viejo-Fuertes D, Liguoro D, Rivel J, Midy D, Guerin J (1998) Morphologic and histologic study of the ligamentum flavum in the thoraco-lumbar region. Surg Radiol Anat 20: 171 – 176
150. Volpi E, Nazemi R, Fujita S (2004) Muscle tissue changes with aging. Curr Opin Clin Nutr Metab Care 7:405 – 410
151. Waddell G (1991) Low back disability. A syndrome of Western civilization. Neurosurg Clin N Am 2:719 – 738
152. Waddell G (1996) Low back pain: a twentieth century health care enigma. Spine 21: 2820 – 2825
153. Weiler C, Nerlich AG, Bachmeier BE, Boos N (2005) Expression and distribution of tumor necrosis factor alpha in human lumbar intervertebral discs: a study in surgical specimen and autopsy controls. Spine 30:44 – 53; discussion 54
154. Weiler C, Nerlich AG, Zipperer J, Bachmeier BE, Boos N (2002) 2002 SSE Award Competi-

tion in Basic Science: expression of major matrix metalloproteinases is associated with intervertebral disc degradation and resorption. Eur Spine J 11:308 – 320
155. Weishaupt D, Zanetti M, Hodler J, Boos N (1998) MR imaging of the lumbar spine: prevalence of intervertebral disk extrusion and sequestration, nerve root compression, end plate abnormalities, and osteoarthritis of the facet joints in asymptomatic volunteers. Radiology 209:661 – 666
156. Yahia LH, Garzon S, Strykowski H, Rivard CH (1990) Ultrastructure of the human interspinous ligament and ligamentum flavum. A preliminary study. Spine 15:262 – 268
157. Yasuma T, Arai K, Suzuki F (1992) Age-related phenomena in the lumbar intervertebral discs. Lipofuscin and amyloid deposition. Spine 17:1194 – 1198
158. Yelin E, Callahan LF (1995) The economic cost and social and psychological impact of musculoskeletal conditions. National Arthritis Data Work Groups. Arthritis Rheum 38: 1351 – 1362
159. Yong-Hing K, Kirkaldy-Willis WH (1983) The pathophysiology of degenerative disease of the lumbar spine. Orthop Clin North Am 14:491 – 504
160. Yoshida M, Shima K, Taniguchi Y, Tamaki T, Tanaka T (1992) Hypertrophied ligamentum flavum in lumbar spinal canal stenosis. Pathogenesis and morphologic and immunohistochemical observation. Spine 17:1353 – 1360
161. Yu J, Winlove PC, Roberts S, Urban JP (2002) Elastic fibre organization in the intervertebral discs of the bovine tail. J Anat 201:465 – 475
162. Ziv I, Moskowitz RW, Kraise I, Adler JH, Maroudas A (1992) Physicochemical properties of the aging and diabetic sand rat intervertebral disc. J Orthop Res 10:205 – 210

# 5 Pathways of Spinal Pain

Heike E. Künzel, Norbert Boos

## Core Messages

- ✔ Chronic (persistent) pain has a high prevalence in the general population and is predominately felt as musculoskeletal pain
- ✔ A temporal classification of pain (i.e. acute, subacute, chronic) is arbitrary and does not reflect the underlying mechanisms of pain
- ✔ Pain is better differentiated into nociceptive, inflammatory, and neuropathic pain
- ✔ Neuropathic pain has lost its protective role and is maladaptive
- ✔ The physiologic processes involved in pain can be differentiated into transduction, conduction, transmission, modulation, projection and perception
- ✔ Nociceptive signals are modulated by various excitatory and inhibitory mechanisms on their pathways to the brain
- ✔ Genetic predisposition and biopsychosocial factors have a significant influence on pain perception
- ✔ Pain pathways can undergo distinct alterations as a result of peripheral tissue damage and neural injuries (neuroplasticity)
- ✔ The neuroplasticity of the pain pathways can be described in terms of peripheral sensitization, transcriptional changes in the dorsal root ganglion, central sensitization and disinhibition
- ✔ Persistent pain is not prolonged acute pain but follows distinct alterations in the pain pathways
- ✔ Neuropathic pain is different from nociceptive pain and results from primary damage or disease of the peripheral or central nervous system
- ✔ Not all persistent pain is neuropathic. The clinical differentiation of persistent inflammatory and neuropathic pain, however, remains a challenge
- ✔ Treatment of acute pain should be aggressive, multimodal and preemptive to avoid pain persistence
- ✔ Adjuvant drugs (e.g. antidepressants, anticonvulsants, anxiolytics) enhance the central effect of analgesics and should be included for an adequate treatment of moderate to severe pain
- ✔ The scientific evidence for a long-term effectiveness of surgical treatment of persistent spinal pain is lacking

## Historical Background

### Precartesian Theories

Pain remained enigmatic in ancient times

Early civilizations provided a wide variety of explanations for pain and attributed it to factors such as religious influences of gods, the intrusion of magical fluids, the frustration of desires and deficiency or excess in the circulation of Qi [70]. The relief of pain therefore was the task of shamans or priests, who used herbs, rites, and ceremonies to alleviate pain. The early Greeks gave more specific explanations for pain [70]. According to Plato (427–347 A.D.), the heart and the liver were the centers of appreciation of all the sensations, and pain arose not only from peripheral sensation but as an emotional response in the soul, which was located in the heart [70]. Hippocrates assumed a wrong mixture of fluids to be the cause of pain. However, Galen of Pergamon (130–200 A.D.) made the first observations on the nervous system and the spine but still believed the so-called "**fluid doctrine**" of Hippocrates (see Chapter 1).

## Cartesian Theory

Descartes first suggested a pathway which transmits noxious stimulus directly to the brain

The French philosopher **René Descartes** (1596 – 1650) presented a **dualistic view** of the **human body and soul**, i.e. he assumed a separation of the mind and the body. The body was seen as a machine working according to the laws of nature and the "rational soul" was the "conductor of the orchestra" [70]. With the suggested separation of the soul from the human body, an endless controversy arose about the mind-body relation which has been plaguing and intriguing philosophers and neuroscientists ever since [7]. Descartes also proposed a simple pathway of the transmission of a noxious stimulus to the brain [22]. However, Descartes' theory was only published after his death in the *Traité de l'Homme* [7]. Descartes gave a purely mechanical view of the involuntary withdrawal of a foot that comes into contact with a noxious stimulus: "the small rapidly moving particle of fire moves the skin of the affected spot causing a thin thread to be pulled. This opens a small valve in the brain and through it animal spirits are sent down to the muscles which withdraw the foot" [22]. After that it was believed for a long time that there was a one-to-one relationship between the amount of damage and the perceived pain. The theory of Descartes implies that a **specific pain pathway** carries the message from a pain receptor in the skin to a pain center in the brain. However, it has become apparently clear that pain cannot be alleviated by simply cutting this pathway. On the contrary, a dissection of this pathway can even exacerbate the pain [22].

## Gate Control Theory

Neural "gates" transmit or block nociceptive transmission to the CNS

Major progress in our understanding of pain and its mechanisms followed the introduction of a new theory by Melzack and Wall in 1965 [77]. The authors suggested a gate control system which modulates sensory input from the skin before it evokes pain perception and response. Accordingly, the substantia gelatinosa in the dorsal horn functions as a gate control system that modulates the afferent patterns before they influence the central transmission cells. The afferent pattern in the dorsal column system acts as a central control trigger which activates selective brain processes that influence the modulation properties of the gate control system. The transmission cells activate neural mechanisms which compromise the action system responsible for response and perception [77]. This theory underwent multiple modifications and extensions throughout the following years. Although it has been shown that specific elements of the gate control theory are invalid or too simplistic, the fundamental model remains. Gates in the dorsal horn consisting of interneurons balance the level of sensory fiber activity and are influenced by descending brain signals. This concept explains how pain can be felt with and without tissue damage and how psychological factors can influence pain [84].

## Modern Pain Theories

Since the introduction of Melzack and Wall's theory, most of the research has focused on two general processes that can control the pain gate [19], i.e.:

- the inhibitory mechanism
- the exhibitory mechanism

Pain has a morphological and molecular correlate

Inhibitory neuronal circuits control nociceptive transmission in the spinal cord and act as gatekeepers suppressing undesirable inputs [19], while increased excitation can occur as a result of neural plasticity [130]. In the last decade, intriguing progress has been made in dissecting out the molecular and cellular mechanisms

that operate in sensory pathways to generate those neural signals that we ultimately interpreted as pain [9, 18, 55, 112].

## Epidemiology of Chronic Pain

Chronic pain is very common

Epidemiological studies show a prevalence of **chronic pain** from **24 % to 46 %** in the general population [31, 102]. Elliott et al. [31] showed that about 15 % of patients suffer from the worst degree of pain. The most frequently reported forms of pain in this study are back pain and arthritic pain. In a 1-year follow-up study, 79 % of patients reporting chronic pain at the baseline investigation still suffered from pain at the end of the study [31]. During this period the average annual incidence was about 8.3 %, whereas the recovery rate was about 5.4 % [31]. **Chronic pain** is localized in **90 %** of patients to the **musculoskeletal system**.

Axial pain is very frequent (85 %) and strongly tends to chronify

The incidence of musculoskeletal pain is reported to vary from 21 % for shoulder pain up to 85 % for low back pain in the industrialized nations [3, 10, 24, 42]. The reported lifetime prevalence of back pain is 84 % [15] and that of neck pain 67 % [20]. Dorsal (thoracic) pain is much less frequent. The 1-year prevalence of dorsal pain was 17 % compared to 64 % for neck and 67 % for low back pain in a Finnish study [85]. In a primary care setting, most patients improve considerably during the first 4 weeks after seeking treatment. Sixty-six to 75 % continue to experience at least mild back pain 1 month after seeking care. At 1 month, approximately 33 % report continuing pain of at least moderate intensity, whereas 20 – 25 % report substantial activity limitations. After more than 1 year, approximately 33 % of patients report intermittent or persistent pain of at least moderate intensity, 14 % continue to report back pain of severe intensity, and 20 % report substantial activity limitations [118]. The patient population suffering from chronic back pain has been found to be responsible for an enormous part of the cost of the health care system (intake of analgesics, medical consultations, hospitalizations, requirement for diagnostic and therapeutic procedures) [82] (see also Chapter 6).

## Definition and Classification

The manifestation of pain is largely variable but we define all sensations that hurt or are unpleasant as pain. The **Taxonomy Committee of the International Association for the Study of Pain** (IASP) [50] has provided a definition, which is widely used today (Table 1).

**Table 1.** Definition of pain

| |
|---|
| "Pain is an unpleasant sensory and emotional experience associated with actual or potential tissue damage, or described in terms of such damage". |

Pain is always subjective

The IASP task force [50] stresses the fact that the inability to communicate verbally does not exclude that an individual is experiencing pain and requires appropriate pain-relieving treatment. Furthermore, the task force highlights that pain is **always subjective**. Each individual learns the application of the word through experiences related to injury in early life. Accordingly, pain is that experience we associate with actual or potential tissue damage. It is also **always unpleasant** and therefore has an **emotional** experience. However, many people report pain in the absence of tissue damage or any likely pathophysiological cause. This latter pain cannot be differentiated from pain due to tissue damage if

we consider the subjective report. If these individuals regard their experience as pain and if they report it in the same ways as pain caused by tissue damage, it should be accepted as pain [50].

## Temporal Course

From a temporal perspective [50, 101], pain can be differentiated as:

- acute pain (< 4 weeks)
- subacute pain (4 weeks to 3 months)
- chronic pain (> 3–6 months)

Chronic pain induces molecular and cellular changes in the nervous system

**Acute pain** is caused by an adequate stimulation of **nociceptive** neurons. This pain typically results from soft tissue injury or inflammation and has a protective role by enabling healing and tissue repair [81, 122]. **Subacute pain** is often less intense and follows the acute phase. It is regarded as organic pain from tissue healing and remodeling. It usually lasts up to 12 weeks but usually not longer. In contrast, **chronic pain** has lost its protective role. In retrospect, it is often difficult to identify the noxious stimulus or tissue damage in patients presenting with chronic pain which originally causes the pain. Chronic pain induces biochemical and phenotypic changes in the nervous system that escalate and alter sensory inputs, resulting in physiologic, metabolic and immunologic alterations that threaten homeostasis and contribute to illness and death [81].

## Contemporary Pain Classification

A timely distinction of pain is given by **Clifford Woolf** [106, 123], who suggests differentiating (Fig. 1):

- nociceptive pain
- inflammatory pain
- neuropathic pain
- functional pain

### Nociceptive Pain

Nociceptive pain is a vital physiologic sensation which occurs in situations like trauma or surgery [123]. **Acute nociceptive pain** is elicited by noxious stimulation of normal tissue sufficiently intense to damage tissue. It has the important function of protecting tissue from further damage by, e.g. eliciting withdrawal reflexes.

### Inflammatory Pain

Adaptive pain is a physiologic protection mechanism

In the case of tissue damage that occurs despite an intact nociceptive defensive system, the role of the nociceptive system switches from preventing noxious stimulation to promoting healing of the injured tissue. Inflammatory pain is characterized by an **increased sensitivity to stimuli**, which does not cause pain under normal conditions. This protects the individual from further damage to the injured part until the healing and repair process is completed. Inflammatory pain normally decreases during the healing process. An exception is inflammatory pain states due to surgery or chronic diseases such as rheumatoid arthritis. In these cases, pain management has to be conceptualized that decreases or normalizes pain sensitivity without impairing the warning system of nociceptive pain [59, 61, 106, 123, 125, 126].

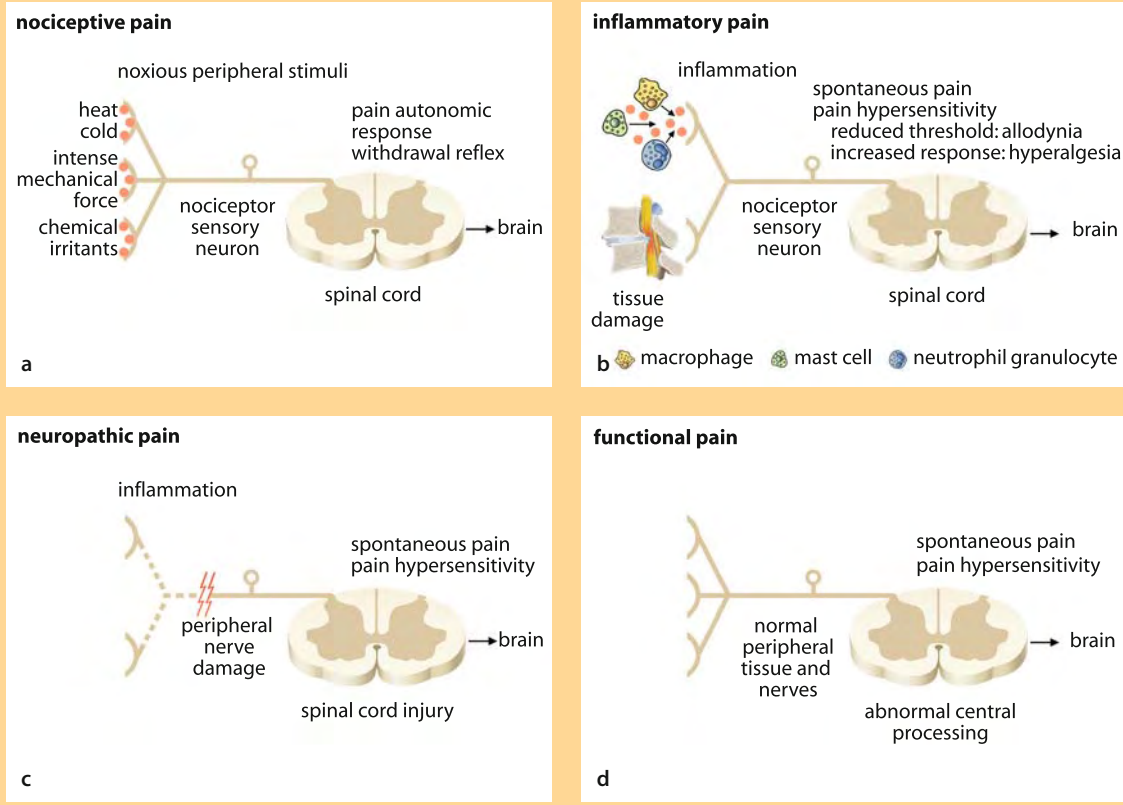


**Figure 1. Classification of pain**

Redrawn from Woolf [123] (with permission from ACP).

## Neuropathic Pain

In contrast to nociceptive pain, which is provoked by noxious stimulation of the sensory endings in the tissue, **neuropathic pain** is the result of a direct damage or disease of neurons in the periphery or central nervous system and seems not to have any beneficial effect. Therefore, peripheral neuropathic pain syndromes are differentiated from central pain. Neuropathic pain normally is felt as abnormal, because it is not related primarily to a signal of tissue damage. It often occurs spontaneously in a continuous or episodic form and is associated with other sensory abnormalities. Neuropathic pain often has a burning or electrical character and might be combined with **allodynia and/or hyperalgesia**. This type of pain often shows a chronic course and in most cases is difficult to treat. Neuropathic pain can have a **variety of causes**, e.g. [27, 106, 123, 128, 134]:

Neuropathic pain is the result of direct damage or disease of neurons

Allodynia and hyperalgesia are found in neuropathic pain

- nerve root injury (traumatic, compression syndrome)
- spinal cord injury
- brain lesions
- diabetic polyneuropathy
- AIDS polyneuropathy
- postherpetic

### Functional Pain

No morphological correlate can be found in functional pain

This form of pain occurs due to an **abnormal responsiveness or function** of the nervous system. In the clinical examination, no neurological or peripheral abnormalities can be found. The physiological basis of functional pain is an increased sensitivity or hyperresponsiveness of the sensory system that amplifies symptoms. **Syndromes** which belong to this class of pain are, e.g. [106, 123]:

- fibromyalgia
- irritable bowel syndrome
- non-cardiac chest pain
- tension headache

## Pathways of Pain

The physiologic processes [61, 81, 123] involved in pain sensation include (Fig. 2):

- **transduction** of noxious stimuli (thermal, mechanical and chemical) into electrical activity at the peripheral terminal of nociceptor sensory fibers
- **conduction** of the resulting sensory input to the central terminal of nociceptors
- **transmission** and **modulation** of the sensory input from one neuron to another
- **projection** to the brain stem, thalamus and cortex
- **perception** of the sensory input at the somatosensory cortex.

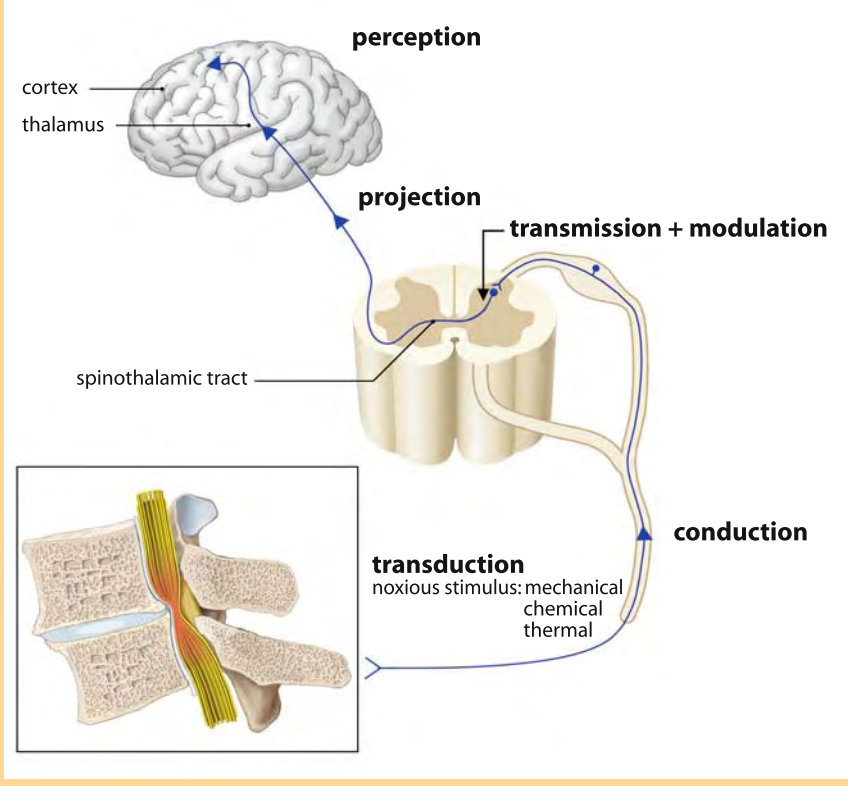


Figure 2. Pathways of pain

## Transduction

Nociception can be defined as the detection of noxious stimuli and the subsequent transfer of encoded information to the brain while pain is a perceptual process that arises in response to such activity [61]. Nociception is mediated by activation of peripheral sensory-nerve terminals located in, e.g. the skin, deep fascias, muscles, and joints. These terminals are called primary sensory neurons or nociceptors. We can differentiate **three types of noxious stimuli** which are targeted by the receptor of nociceptors, i.e.:

There are three types of nociceptor: mechanical, thermal, and chemical

- mechanical (pressure and mechanical stress)
- thermal (hot/cold)
- chemical

**Primary sensory neurons** can be excited by noxious heat, intense pressure or irritant chemicals, but not by innocuous stimuli such as warm or light touch [55]. The conversion of a noxious thermal, mechanical, or chemical stimulus into electrical activity in the peripheral terminals of nociceptor sensory fibers is described as **transduction** [123].

**Mechanical stress** resulting from direct pressure, tissue deformation or osmolarity changes can activate nociceptors allowing for the detection of touch, deep pressure, distension of a visceral organ, destruction of bone or swelling [55] (Fig. 3a). These stimuli are mediated by **mechanosensory transducers** such as ion channels of the degenerin family (mammalian degenerin, MDEG) or acid-sensing ion channel 2 (ASIC2) [39, 55]. Mechanical stimulation can release ATP from the cell activating G-protein-coupled ATP receptors (P2Y) or ATP-gated ion channels (P2X) [55, 83]. **Noxious heat** can be detected by the **vanilloid receptor** (TRPV1, formerly also called VR1) and the **vanilloid receptor-like** (TRPV2, formerly called VRL-1) **channel**, which belong to the larger family of **transient receptor potential** (TRP) **channels.** The core membrane structure of the receptors resembles that of voltage-gated potassium or cyclic nucleotide-gated channels [55, 83]. The TRPM8 receptor, a distant relative of TRPV1, has been identified as detecting noxious cold [75, 88]. Nociceptors uniquely express two voltage-

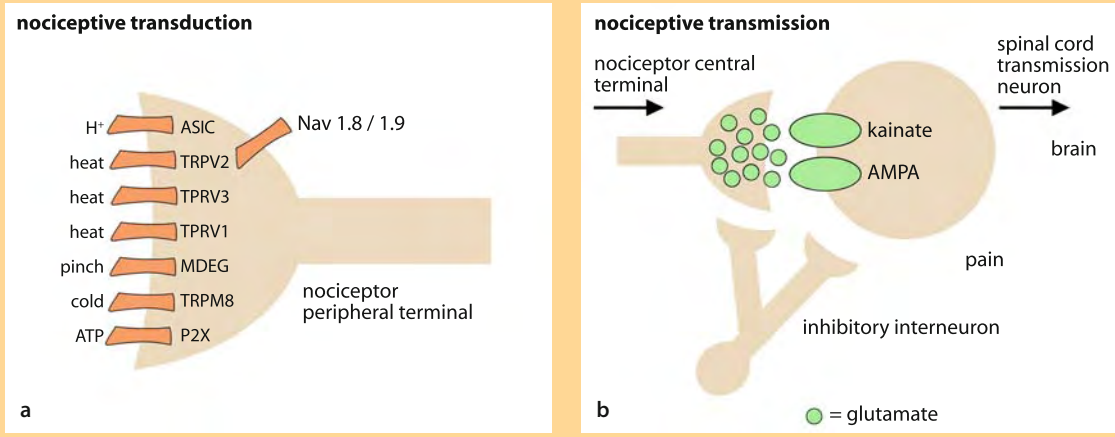


**Figure 3. Nociceptive transduction and transmission**

a **Nociceptive transduction** (*ASIC* acid sensitizing ion channel, *TRP* transient receptor potential channels, *MDEG* mammalian degenerin channel, *P2X* ATP-gated ion channel). b **Nociceptive transmission** (*AMPA* α-amino-3-hydroxy-5-methyl-4-isoxazolepropionic acid receptors). Redrawn from Woolf [123] (with permission from ACP).

gated sodium channels ($Na_v1.8$ and $Na_v1.9$), which could become the target for selective anesthetics blocking only pain but leaving innocuous sensation, motor and autonomic output intact [123].

## Conduction

Conduction is the action potential passage from the peripheral to the central nociceptor terminal

Conduction is the passage of action potentials from the peripheral terminal along axons to the central terminal of nociceptors in the spinal cord [123]. Dorsal root ganglion (DRG) cell bodies give rise to three different fiber types [55, 61]:

- C type fibers
- Aδ fibers
- Aβ fibers

**C type fibers** are **unmyelinated fibers** ranging in diameter from 0.4 to 1.2 µm and have a velocity of 0.5 – 2.0 m/s. These fibers present the thermosensitive receptors reacting to temperature (heat/cold), mechanoreceptors of low threshold and specific receptors for algogenic substances [2, 55, 78].

**Aδ fibers** are **lightly myelinated** ranging in diameter from 2.0 to 6.0 µm and have a velocity of 12 – 30 m/s. These fibers are classified into two subgroups. **Type I** presents high-threshold mechanoreceptors and they respond weakly to chemical and thermal stimuli. **Type II** corresponds mainly to mechanothermal receptors for high temperatures and intense cold [2, 55, 78].

**Aβ fibers** are **myelinated** with a diameter of more than 10 µm and a velocity of 30 – 100 m/s. These fibers mediate the sensations of touch and mild pressure, as well as the sensation of joint positions (proprioception) and vibration [2, 55, 78]. Their activation contributes to mechanisms of segmental suppression in the spinal cord.

Activation of C type fibers and Aδ fibers leads to burning sensations and twinges. Under pathological conditions, signs of neuropathic pain, e.g. dysesthesia and paresthesia, can result from activation of Aβ fibers. Pathologic pain sensation can manifest as hyperalgesia mediated by C fibers and Aδ fibers. Under pathologic conditions, activation of low threshold mechanoreceptors (Aβ fibers) can evoke allodynia (touch evoked pain) [2, 55, 78].

## Transmission and Modulation

Transmission is the first synaptic transfer
The sensory input is modulated in the dorsal horn

Transmission is the synaptic transfer of sensory input from one neuron to another [123].

The primary sensory neurons terminate in the dorsal horn in a highly organized fashion, innervating both intrinsic dorsal horn interneurons and projection neurons. The dorsal horn is the first site of synaptic transmission (or integration) in the nociceptive pathway and is subject to considerable local and descending modulation [18].

### Dorsal Horn Cytoarchitecture

The dorsal horn exhibits a distinct cytoarchitecture

The gray matter of the spinal cord can be divided into **ten laminae**. Of these, laminae I (marginal layer), II (substantia gelatinosa), III, IV (nucleus propius), V and VI (deep layers) comprise the dorsal horn [78]. The laminae form columns extending along the spinal cord [81, 99]. Within the columns, a large number of second-order excitatory and inhibitory interneurons receive multiple inputs from surrounding columns and send outputs to the brain and to the anterior horn [81]. The **neuronal network** of the dorsal horn hence serves as a gate controlling propagation of nociceptive signals to higher brain areas [132].

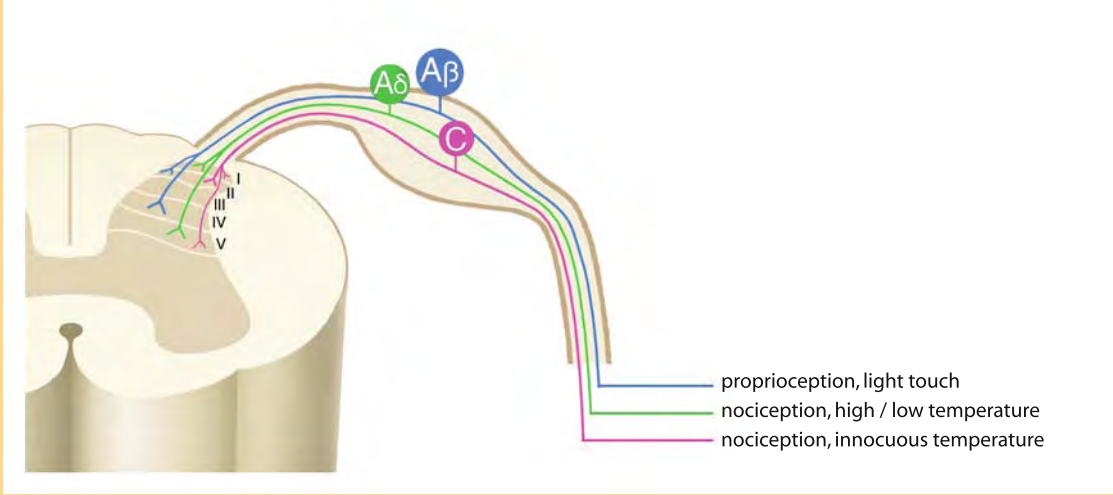


Figure 4. Cytoarchitecture of the dorsal horn

The cytoarchitecture of the dorsal horn is very complex [2, 78, 81, 99, 127]. Simplified, large myelinated low-threshold Aβ afferents terminate in laminae III and IV, lightly myelinated high-threshold Aδ fibers synapse at laminae I and V, and non-myelinated high-threshold C fibers terminate in lamina II but also terminate with some fibers in laminae I and V [111, 127] (Fig. 4).

Within the dorsal horn **three distinct types of neurons** can be identified according to the type of afferents and their response pattern to nociceptive input [78]:

There are three distinct neuron types within the dorsal horn

- nociceptive-specific (SN) neurons
- multireceptorial or wide-dynamic range (WDR) neurons
- non-nociceptive neurons

**Nociceptive-specific (NS) neurons** are located in the substantia gelatinosa but can also occur in layers (laminae V and VI) under physiologic conditions. They are exclusively activated by high intensity noxious stimuli mediated by C and Aδ fibers [78].

**Multireceptorial or wide-dynamic range (WDR) neurons** respond to thermal, mechanical and chemical stimuli via C, Aδ and Aβ fibers. These neurons are found to a lesser degree in the ventral horn (VH). WDR neurons present a considerable convergence from cutaneous, muscle and visceral input. This type of neuron is the major type of neuron that encodes stimulus intensity [26]. Additionally, these neurons participate mainly in the C-fiber-mediated processes of sensitization and amplification of prolonged pain [78].

**Non-nociceptive (N-NOC) neurons** are activated by innocuous stimuli such as low intensity mechanical, thermal and proprioceptive stimuli, mediated by Aδ and Aβ fibers. They are found predominately in laminae II, III and IV [78]. These neurons act indirectly in segmental suppression mechanisms [2]. The different types of neurons are connected via second order excitatory and inhibitory interneurons. These interneurons receive multiple inputs from other columns and send information and impulses to the brain [81]. After modulation and modification of the nociceptive stimulus within the dorsal horn, the information is transmitted to the CNS. Afferents of the spinal cord dorsal horn neurons form so called spinal tracts that transmit nociceptive informations to the CNS.

Plasticity or modifiability of synaptic transfer in the dorsal horn is a key feature of its function and integral to the generation of pain and pain hypersensitivity [18].

The **major synapses** responsible for transmission are located in the dorsal horn of the spinal cord in lamina I (marginal zone) and lamina II (substantia gelatinosa). These impulses are conveyed to the thalamus, the main region for the integration of brain input [37]. The transfer of nociceptive stimuli is mediated by direct monosynaptic contact or through multiple excitatory or inhibitory interneurons. Transmission of nociceptive stimulus is inhibited by descending pathways of the brain stem and midbrain and collateral influences within the dorsal horn [37, 106].

### Modulation of Sensory Inputs

Transmission of the peripheral nociceptive signals to the brain undergoes various modulatory influences in the dorsal horn by descending pathways [9, 37, 78]. Many neurotransmitters have been identified which mediate this modulation [9, 37] (Table 2).

The sensory input is modulated by inhibitory and excitatory mechanisms

**Modulation** can be described as the process in which pain transmission is modified or altered – "gated" – before being transmitted to the CNS. Nociceptive impulses are modulated in two ways, i.e. by:

- excitatory (facilitatory) mechanisms
- inhibitory mechanisms

#### *Inhibitory Mechanisms*

The majority of the inhibitory mechanism is GABA-dependent

Inhibitory mechanisms can originate from local (segmental) inhibitory interneurons or from descending antinociceptive pathways. The majority of local inhibitory neurons in the spinal cord release glycine and/or γ-aminobutyric acid (**GABA**). The descending inhibition pathways originate at the level of the cortex and thalamus, and descend via the brain stem (periaqueductal gray) and the dorsal columns to terminate at the dorsal horn of the spinal cord. These descending pathways modulate nociceptive transmission through the release of serotonin (5-HT) and/or norepinephrine [37, 78]. Inhibition can be postsynaptic or presynaptic. Postsynaptic inhibition results from a hyperpolarization of the cell membrane and/or from the activation of a shunting conductance, which impairs prop-

**Table 2.** Neurotransmitters

| Peptides | Non-peptides |
|---|---|
| *Opioid peptides*<br>• β-endorphin<br>• enkephalins<br>• dynorphins | *Monoamines*<br>• norepinephrine<br>• serotonin (5-HT) |
| *Non-opioid peptides*<br>• substance P<br>• somatostatin<br>• neurotensin<br>• cytokines (IL-1β, IL-6, TNF-α)<br>• calcitonin gene related peptide (CGRP)<br>• galanin<br>• neuropeptides Y<br>• nerve growth factor (NGF)<br>• cholecystokinin (CCK)<br>• purines<br>• nociceptin | *Amino acids*<br>• inhibitory amino acids (GABA, glycine)<br>• excitatory amino acids (aspartate, glutamate)<br>*Nitric oxide (NO)* |

agation of excitatory postsynaptic potentials along the dendrite of neurons [132]. Presynaptic inhibition occurs at axoaxonic synapses of GABAergic neurons with primary sensory nerve terminals [37].

### *Excitatory Mechanisms*

Glutamate plays a pivotal role as an excitatory transmitter

The excitatory transmitter **glutamate** is released by primary afferent fibers and plays a pivotal role in the spinal mechanisms of nociceptive transmission [9]. Synaptically released glutamate acts on **kainate** and **AMPA** (α-amino-3-hydroxy-5-methyl-4-isoxazolepropionic acid) receptors, being responsible for a fast synaptic transmission at the first synapse in the dorsal horn (Fig. 3b). Transient and non-injurious noxious stimuli result in stable AMPA receptor-mediated synaptic signals which are finally perceived as a transient localized pain [123]. Glutamate can also act on *N*-methyl-D-aspartate (**NMDA**) receptors, but this receptor is blocked under resting conditions by extracellular magnesium ions [81]. Depolarization of the postsynaptic neuron, e.g. through intense AMPA receptor activation, removes this magnesium block. In addition, activators of protein kinase C can reduce the sensitivity of NMDA receptors to magnesium, possibly contributing to spinal hypersensitivity and amplification of peripheral inputs. The activation of the NMDA receptors also leads to an entry of calcium, which is a key event in the generation of long lasting potentiation of synaptic transmission (LTP). In addition, calcium activates various enzymes such as nitric oxide (NO) synthase and phospholipases [9], which can also augment pain sensitivity.

Wind-up is an activity-dependent phenomenon responsible for increasing pain in response to repeated stimuli

Closely timed repeated stimulation of C fibers results in an increased response even though the amplitude of the input signal remains unchanged. This **activity-dependent phenomenon** known as **wind-up** is responsible for the increasing pain experienced in response to closely repeated stimulation of the skin by noxious heat [72, 123].

## Pain Projection

Nociceptive information is projected to supraspinal structures via afferent bundles

Subsequent to pain transmission and modulation within the dorsal horn, nociceptive information is projected to the supraspinal structures via afferent bundles (Fig. 5). These bundles can be differentiated into several tracts with special functions [2]:

- **spinothalamic tract** involved in sensory-discriminative components and motivational-affective aspects of pain as well as the affective components of painful experience
- **spinoreticular tract** involved in the motivational-affective aspects and neurovegetative responses to pain
- **spinomesencephalic tract** involved in somatosensory processing, activation of descending analgesia, inducing aversive behaviors in response to nociceptive stimuli as well as autonomic, cardiovascular, motivational and affective responses
- **spinoparabrachial tract** involved in autonomic, motivational, affective regulation and in the neuroendocrine responses to pain
- **spinohypothalamic tract** involved in neuroendocrine autonomic, motivational, affective and alert responses of somatic and visceral pain
- **spinocervical tract** involved in the sensory-discriminative components and motivational-affective and autonomic responses of pain, and plays a role in sensory integration and modulation of afferent inputs
- **postsynaptic pathways** of spinal column involved in the sensory-discriminative components and motivational-affective aspects of pain

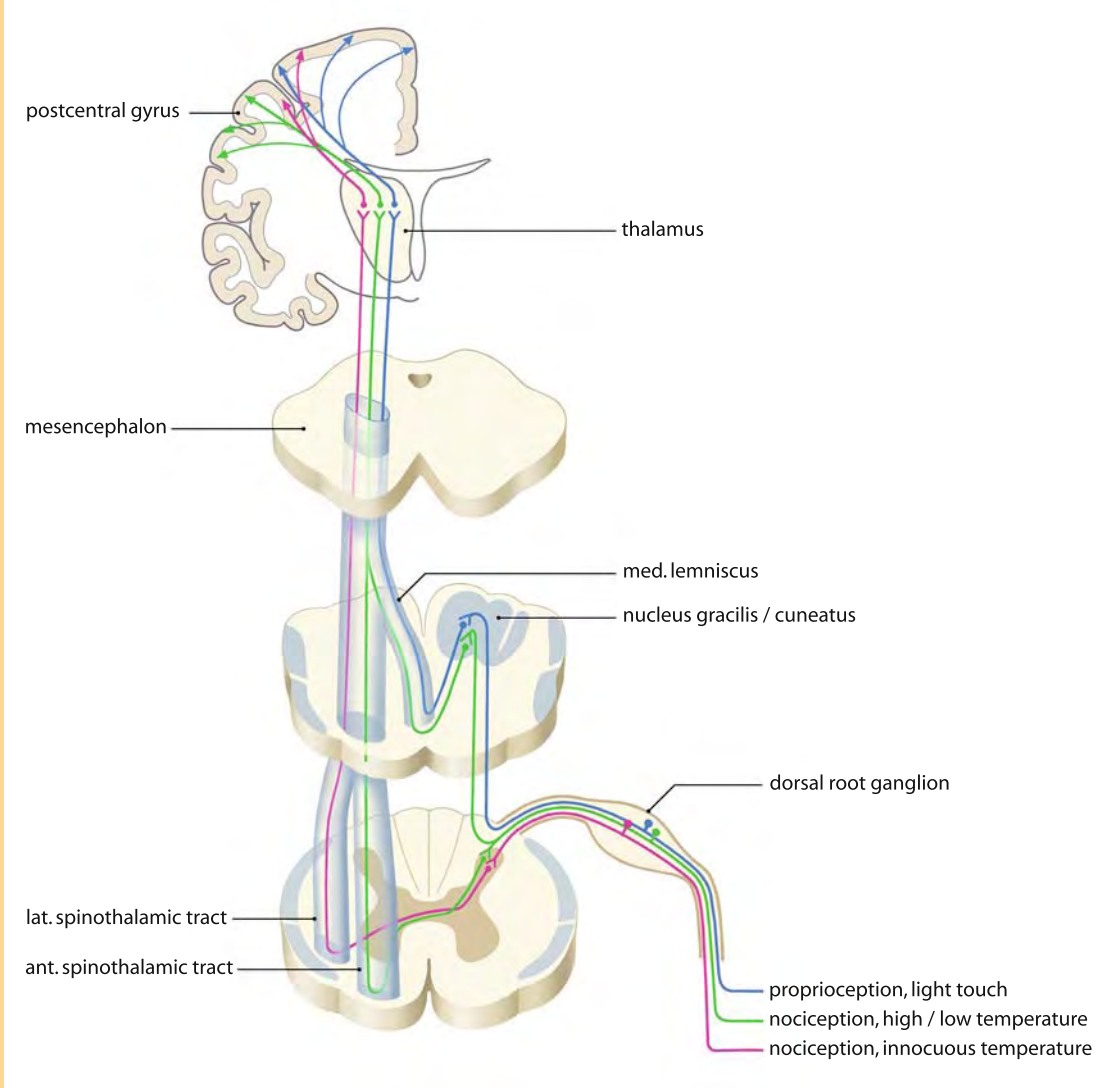


Figure 5. Afferent pathways

## Pain Perception

Thalamus and somatosensory cortex are the main structures of pain perception

The **spinal projection pathways** project to the reticular formation of the brain stem and surrounding nuclei before converging in the **thalamus**, the main structure for reception, integration and nociceptive transfer of nociceptive stimuli before transmission to the somatosensory cortex. However, only a small proportion of all the sensory input from the spinal cord arrives at the thalamus because of local processing, modulation, and controlling [123]. The somatosensory cortex in turn projects to adjoining cortical association areas, predominately the limbic system. The **limbic system** includes [81]:

- cingulate gyrus (behavior and emotion)
- amygdala (conditioned fear and anxiety)
- hippocampus (memory)
- hypothalamus (sympathetic autonomic activity)

- locus ceruleus (arousal, vigilance, behavior)
- parts of the periaqueductal gray (fight and flight response, stress-induced analgesia)

Projections from the periaqueductal gray play a role in controlling anti-nociceptive and autonomic responses to nociceptive stimuli [81].

## Neuroplasticity

Persistent pain is not just a simple prolongation of acute (nociceptive) pain but results from **distinct alterations in the pain pathways**. Peripheral tissue damage or nerve injury can result in a pathological state in which there is a reduction in pain threshold (allodynia), an increased response to noxious stimuli (hyperalgesia), an increase in the duration of response to brief stimulation (persistent pain) and a spread of pain and hyperalgesia to uninjured tissue (referred pain and secondary hyperalgesia) [17]. These alterations in the pain pathways are usually referred to as **neuroplasticity**.

Alterations in the pain pathways characterize neuroplasticity

### Peripheral Sensitization

**Tissue damage** results in the release of **inflammatory mediators** including ions ($H^+$, $K^+$), bradykinin, histamine, 5-hydroxytryptamine (5-HT), ATP and nitric oxide (NO). The tissue injury activates the arachidonic acid pathway, which results in the production of prostanoids and leukotrienes [60]. Inflammatory mediators are also released from attracted cells such as mast cells, fibroblasts, neutrophils and platelets [55]. Tissue damage and inflammation leads to **low pH**, which enhances painful sensations by sensitizing and activating the vanilloid receptor 1 (TRPV1) [49]. Inflammatory mediators, e.g. prostaglandin $E_2$, brady-

Tissue damage results in inflammatory mediator release

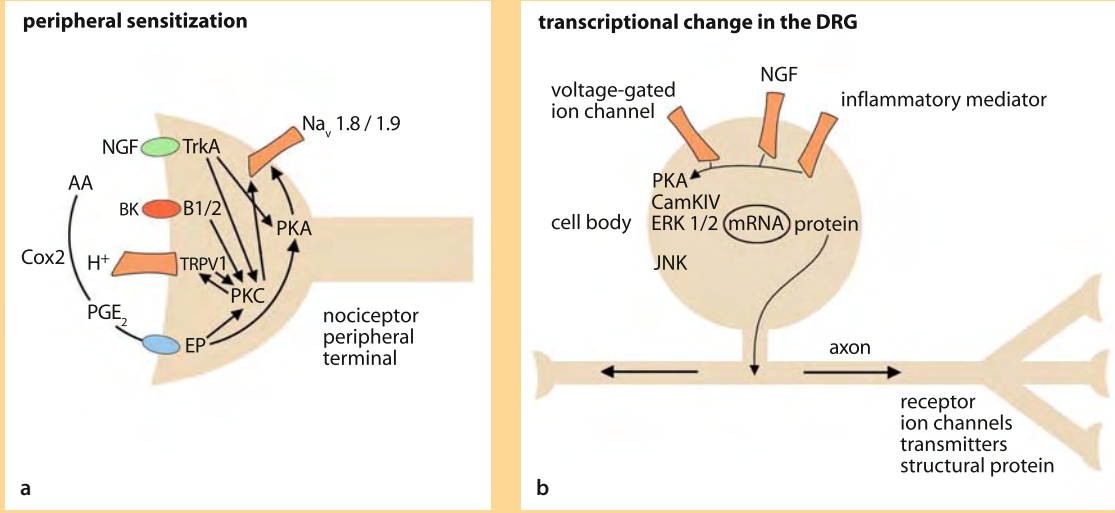


**Figure 6. Neuroplasticity of the nociceptor**

a **Peripheral sensitization** (*NGF* nerve growth factor, *BK* bradykinin, *TRPV1* transient receptor potential vanilloid 1 channel, *EP* prostaglandin E receptor, *PK* protein kinases, *AA* arachidonic acid, *PGE$_2$* prostaglandin, *TrkA* tyrosine kinase A receptor, *Cox2* cyclooxygenase 2). b **Transcriptional change in the DRG** (*PKA* protein kinase A, *CamKIV* camkinase IV, *JNK* jun kinase, *ERK* extracellular signal-regulated kinase). Redrawn from Woolf [123] (with permission from ACP).

kinin and nerve growth factor (NGF) [108], activate intracellular protein kinases A and C in the peripheral terminal that phosphorylate TRPV1 and tetrodotoxin-resistant (TTXr) sodium channels ($Na_v1.8$, $Na_v1.9$) to increase excitability [123, 125, 130]. These mechanisms (Fig. 6a) contribute to the sensitization of the peripheral terminal leading to pain hypersensitivity [130].

## Transcriptional DRG Changes

NGF and inflammatory mediators modulate DRG gene expression

In damaged tissue, **nerve growth factor** (NGF) and **inflammatory mediators** are expressed and transported from the periphery to the cell body of peripheral neurons [123]. Within the DRG, signal transduction cascades are activated involving protein kinase, CaM kinase IV, extracellular signal-regulated kinase (ERK), mitogen-activated protein kinase (MAPK) p38, and jun kinase [52, 53, 71, 86, 123]. These cascades control the transcription factors that **modulate gene expression**, leading to changes in the levels of receptors, ion channels, and other structural proteins [86, 123] (Fig. 6b).

## Central Sensitization

The early phase results in pain hypersensitivity

Central sensitization is the form of **synaptic plasticity** that amplifies and facilitates the synaptic transfer from the nociceptor central terminal to dorsal horn neurons [59, 123]. During nociception the release of glutamate predominately acts on kainate and AMPA receptors within the dorsal horn. The intense stimulation of nociceptors (e.g. by spinal injuries) releases transmitters [brain-derived neurotrophic factor (BDNF), substance P, glutamate], which act on multiple dorsal horn receptors, e.g. AMPA, NMDA, NK1 and TrkB [64, 125, 135]. In this **early phase** (Fig. 7a) of central sensitization, intracellular kinases are also activated which phosphorylate receptor ion channels. This effect also increases the responsiveness to glutamate by removal of the $Mg^{2+}$ block of the NMDA channel leading to **spinal hypersensitivity** and **amplification of peripheral inputs** [110, 123, 124, 131].

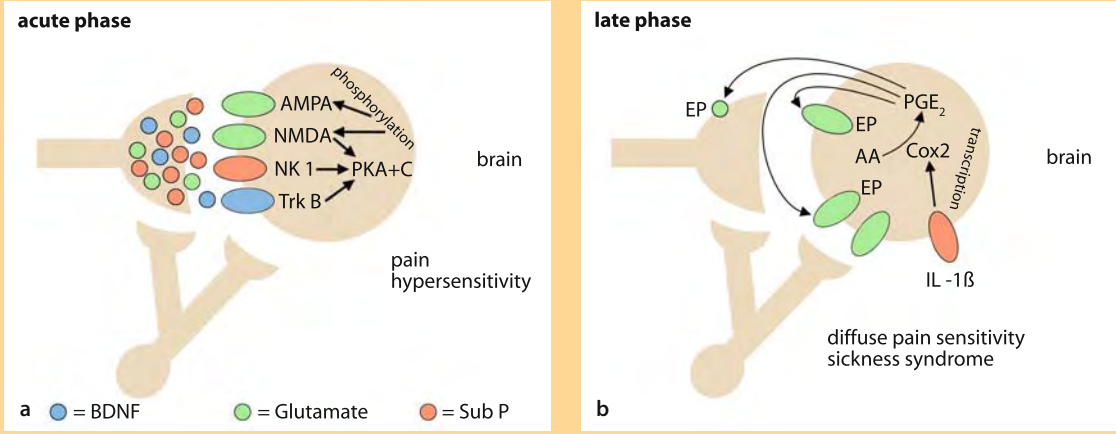


**Figure 7. Central sensitization**

**a Acute phase** (*AMPA* α-amino-3-hydroxy-5-methyl-4-isoxazolepropionic acid receptors, *NMDA N*-methyl-D-aspartate, *EP* prostaglandin E receptor, *NK1* neurokinin 1 receptor, *TrkA* tyrosine kinase B receptor, *PK* protein kinases). **b Late phase** (*EP* prostaglandin E receptor, *AA* arachidonic acid, $PGE_2$ prostaglandin, *Il-1β* interleukin-1β, *Cox2* cyclooxygenase 2). Redrawn from Woolf [123] (with permission from ACP).

Prostaglandins not only sensitize the nociceptive system at the level of the primary nociceptor but also centrally at the level of the dorsal horn [133]. In the **late phase** (Fig. 7b) of central sensitization, $PGE_2$ is produced by COX-2 in the dorsal horn, which is induced by proinflammatory cytokines such as interleukin-1β [103, 123, 133]. This expression of $PGE_2$ appears to be a key factor responsible for central pain sensitization [1, 98]. These **mechanisms of central sensitization** are responsible for the well known clinical symptoms such as **allodynia**, **hyperalgesia**, and **secondary hyperalgesia**.

The late phase results in diffuse pain hypersensitivity

## Disinhibition

Afferent nociceptive signals from the periphery to the brain are modulated by a well balanced interplay of excitatory and inhibitory neurons [123]. The loss of inhibition, i.e. **disinhibition of dorsal horn neurons**, is a key element in persistent inflammatory and neuropathic pain [132]. Inhibitory mechanisms within the spinal cord are mediated by the neurotransmitters glycine and GABA. The expression of $PGE_2$ during inflammation leads to a protein kinase A-dependent phosphorylation which inhibits the glycine receptors. Dorsal horn neurons are relieved from the glycinergic neurotransmission [1, 46]. Furthermore, partial nerve injury has been shown to decrease dorsal horn levels of the GABA synthesizing enzyme glutamic acid decarboxylase (GAD) and induce neuronal apoptosis. Both of these mechanisms could reduce presynaptic GABA levels and promote a functional loss of GABAergic transmission in the superficial dorsal horn [79]. However, significant loss of GABAergic or glycinergic neurons is not necessary for the development of thermal hyperalgesia in the chronic constriction injury (CCI) model of neuropathic pain [92].

Disinhibition is a key factor in persistent pain

Additional mechanisms involved in the neuroplasticity leading to pathologic pain processing include **spinal cord glial changes** and **medullary descending facilitation**. Similar to immune cells responding to viruses and bacteria, spinal cord glia (microglia and astrocytes) can amplify pain by expressing proinflammatory cytokines [119]. These spinal cord glia also become activated by certain sensory signals arriving from the periphery, e.g. as a result of a nerve root injury [54, 119]. **Nerve root injury** and inflammation can result in persistent input of pain signals and lead to sustained activation of descending modulatory pathways that facilitate pain transmission [93, 123].

## Endogenous and Environmental Influences on Pain Perception

There is an increasing plethora of studies indicating a strong influence of endogenous and environmental factors on pain perception and processing (see Chapters 6, 7). It is common knowledge that the identical noxious stimulus does not lead to an equal pain perception neither on the intraindividual nor on the interindividual level. Similarly, it is well known that not every patient with severe injury to the nervous system develops chronic/neuropathic pain [87]. With the advance of molecular biological techniques, research has focused on exploring the **genetic predisposition** for these interindividual differences. The genetic predisposition for disc degeneration but not necessarily pain has been established in several studies [6]. Tegeder et al. [112] recently reported that a haplotype of the GTP cyclohydrolase gene was significantly associated with less pain following discectomy for persistent radicular leg pain. GTP cyclohydrolase (GCH1) is the responsible enzyme for tetrahydrobiopterin (BH4) synthesis. BH4 is an essential cofactor for catecholamine, serotonin and nitric oxide production and thus a key modulator of peripheral neuropathic and inflammatory pain. Healthy individu-

Genetic factors influence pain perception

als homozygous for this haplotype exhibited reduced experimental pain sensitivity, and forskolin-stimulated immortalized leukocytes from haplotype carriers upregulated GCH1 less than did normal controls [112]. Considering the complexity of persistent pain, it appears very likely that many genes are involved and we are only at the beginning of unraveling the molecular background of individual differences in pain perception.

Biopsychosocial factors have a strong influence on persistent pain

Additionally to biological mechanisms, there are several established predisposing **biopsychosocial risk factors** for the development of persistent pain:

- gender [34, 100]
- age [38]
- ethnicity [28, 47]
- affective-emotional behavioral pattern [16, 69]
- psychosocial factors [11, 58, 115]
- previous pain states [94, 109, 113]
- personality traits [69, 90]

Although various studies show that gender, age, ethnicity, personality traits, etc., play a role in pain perception and pain processing, there is no evidence for a specific pain-prone personality that reliably predicts the development of a persistent pain syndrome [69, 91].

## Clinical Assessment of Pain

Nociceptive pain is an **important warning sign** to prevent the individual from injury, whereas neuropathic pain has lost this role and presents as a disease by itself. Nociceptive spinal pain occurs due to circumscribed actual or impending tissue damage. Patients suffering from nociceptive spinal pain present specific clinical signs corresponding to the affected tissue. In contrast to nociceptive spinal pain, neuropathic spinal pain occurs as consequence of a direct injury or affection of the nervous system. Severe nerve root and spinal cord injuries are the most common causes of the neuropathic form of spinal pain. Clinical experience and rather discouraging research mainly related to the treatment of chronic pain has demonstrated that a strategy directed at examining, classifying and treating pain on the basis of anatomy or underlying disease is of limited help [51]. **Clifford Woolf** has first advocated that a **mechanism-based approach** to pain is more reasonable and has direct implications on present and future pain treatment [129].

A mechanism-based approach is recommended for clinical assessment

### Differentiating Inflammatory and Neuropathic Pain

Differentiating inflammatory and neuropathic pain is challenging clinically

While the diagnosis and assessment of nociceptive and acute inflammatory pain is straightforward, the clinical differentiation of persistent inflammatory and neuropathic pain often remains a **diagnostic challenge** for several reasons [51]:

- lack of a single diagnostic test which can confirm/reject the putative diagnosis
- perception of neuropathic pain is purely subjective
- various diseases (e.g. low back pain) exhibit a variable degree of neuropathic component
- pain is not static but changes in a dynamic way
- signs and symptoms may change during the course of the disease
- lack of a commonly agreed definition of neuropathic pain

Not all persistent pain is neuropathic

It is most important to stress that not all persistent pain is neuropathic. This diagnosis should only be made in the presence of positive findings [40]. However, the

**Table 3.** Criteria for classifying neuropathic pain

| Definite | Possible | Unlikely |
|---|---|---|
| Pain located in a neuroanatomical area and fulfilling at least two of the following:<br>• decreased sensibility in all/part of the painful area<br>• present or former disease known to cause nerve lesion relevant for the pain<br>• nerve lesion confirmed by neurophysiology, surgery or neuroimaging | Pain located in a neuroanatomical area and fulfilling at least two of the following:<br>• decreased sensibility in all/part of the painful area<br>• unknown etiology<br>• present or former disease known to cause either nociceptive or neuropathic pain<br>• radiation pain or paroxysms | Pain fulfilling at least the following:<br>• pain located in a non-neuroanatomical area<br>• presence of former disease known to cause nociceptive pain in the painful area<br>• no sensory loss |

According to Rasmussen et al. [97]

**Table 4.** Differentiating nociceptive and neuropathic pain

| Nociceptive pain | Neuropathic pain |
|---|---|
| • sharp, aching or throbbing quality<br>• well localized<br>• transient<br>• good response to analgesic treatment | • burning, tingling, numbness, shooting, stabbing quality, or electric-like sensation<br>• spontaneous or evoked<br>• persistent or paroxysmal pain<br>• resistance to non-steroidal anti-inflammatory drugs and limited or no response to opioids |

According to Jensen and Baron [51]

scope of the diagnosis is largely variable. Rasmussen et al. [97] provided criteria facilitating the diagnosis of neuropathic pain (Table 3).

The diagnosis of neuropathic pain requires a thorough work-up

The **diagnostic work-up** of patients with neuropathic pain should include:

- medical history
- sophisticated quantitative sensory testing
- neurophysiological studies
- imaging studies
- pharmacological tests

### Medical History

A thorough history and physical examination (see Chapter 8) including a detailed neurologic assessment (see Chapter 11) is the prerequisite for a mechanism based diagnosis and effective pain treatment. A detailed history of persistent pain should **include the following aspects:**

- beginning
- localization
- intensity
- quality
- temporal pattern
- pain aggravating and relieving factors
- autonomic changes
- confounding biopsychosocial risk factors

A pain drawing can be helpful in differentiating anatomic and non-anatomic pain distribution

A **pain drawing** can be used to graphically document the pain distribution [73, 96]. The graphic depiction of the subjective pain perception often instantaneously shows a non-anatomic distribution which argues against neuropathic pain. However, the general discriminative power of the pain drawing to assess psychological disturbance is limited [44]. Pain can further be differentiated according to its **character.** Melzack [76] has developed a questionnaire which distinguishes sensory and affective pain descriptors, which can be helpful in the assessment of the pain character (see Chapter 8). The history sometimes allows a differentiation of nociceptive and neuropathic pain (Table 4).

### Clinical Examination

Negative and positive sensory symptoms and signs need to be assessed

The examination should include the assessment of negative and positive sensory symptoms and signs (Table 5). Currently there is no consensus about what, where and how to measure and what to compare with [51]. Although the mirror side can serve as an internal control, the assessment can be influenced by contralateral segmental changes [51].

Screening tools and questionnaires (e.g. LANSS, NPQ, DN4, painDETECT) have been developed and are recommended to supplement the assessment for neuropathic pain [8].

### Neurophysiological Studies

Recent advances in neurophysiology have become a valuable diagnostic tool in identifying the extent of neurologic disturbance in neuropathic pain [25, 63].

### Imaging Modalities

fMRI is an intriguing imaging modality

The primary objective of imaging studies in the evaluation of neuropathic pain is to identify a structural abnormality or damage to neural tissue, which is a prerequisite in making a definite diagnosis. However, imaging studies can go beyond a pure anatomical appraisal. Functional imaging such as positron emission tomography (PET), magnetic resonance spectroscopy and **functional MRI** (fMRI) allow the identification of local cerebral blood flow changes which reflect local synaptic activity, thereby revealing the cortical representation of pain [12, 13, 43, 68, 95, 107].

### Pharmacological Testing

Pharmacological tests in a controlled manner with either different drugs or different administration forms of the same substance allow for an examination of the location of the pain generator and the molecular mechanisms involved in pain [40, 51].

**Table 5.** Clinical testing

| | |
|---|---|
| **Negative sensory symptoms/signs** | **Bedside examination** |
| • reduced touch | • touch skin with cotton wool |
| • reduced pin prick | • prick skin with a pin single stimulus |
| • reduced cold/warm | • thermal response to cold, 20° and 45° |
| • reduced vibration | • tuning fork on malleoli/interphalangeal joints |
| **Positive sensory symptoms/signs** | |
| *Spontaneous* | **Bedside examination** |
| • paresthesia | • grade (1 – 10) |
| • dysesthesia | • grade (1 – 10) |
| • paroxysms | • number/grade (1 – 10) |
| • superficial burning pain | • grade (1 – 10) |
| • deep pain | • grade (1 – 10) |
| *Evoked* | **Bedside examination** |
| • touch evoked hyperalgesia | • stroking skin with painter's brush |
| • static hyperalgesia | • gentle mechanical pressure |
| • punctuate repetitive hyperalgesia (wind-up) | • pricking skin with pin 2/s for 30 s |
| • aftersensation | • measure pain duration after stimulation |
| • cold hyperalgesia | • stimulate skin with cool metal roller |
| • heat hyperalgesia | • stimulate skin with warm metal roller |
| • chemical hyperalgesia | • topical capsaicin |
| • sympathetic maintained pain | • none |

According to Jensen and Baron [51]

## General Concepts of Pain Treatment

### Pharmacological Treatment

Current acute pain treatment is aggressive, multimodal and preemptive

A systemic pharmacological treatment remains the cornerstone of the management of acute or persistent pain [67]. The **three-step pain relief ladder** developed by the WHO [120] originally for the treatment of cancer pain in 1986 also applies for other pain disorders such as spinal pain. The pain relief ladder (Fig. 8) suggests starting with a weak analgesic and stepwise increasing the potency of the medication until pain relief is felt [29]. In cases of severe pain, it may be necessary to immediately start with step 3 opiate analgesics (**stratified therapy**) [57]. There is increasing evidence that acute painful experiences can lead to longer-term painful consequences, even when tissue healing has occurred [41]. The increasing understanding of the neurobiology of pain has prompted an aggressive, multimodal, preemptive approach to the treatment of acute pain to prevent pain persistence [30, 41].

#### Drug Types

A detailed discussion of the various drug types and their application is far beyond the scope of this chapter and the reader is referred to the literature [4, 5, 30, 56, 62, 66, 105].

##### *Non-opioid Analgesics*

Although **paracetamol** (acetaminophen) has been known for a century, the exact mechanisms of its antinociceptive effect are still controversial. Paracetamol

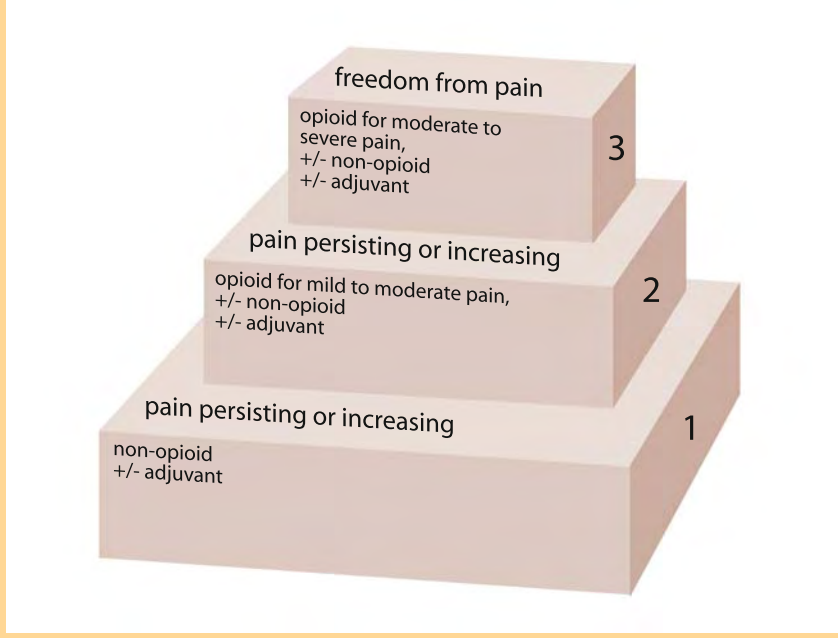


**Figure 8. Pain relief ladder**

Non-opioids (paracetamol, NSAIDs, tramadol), adjuvants (tricyclic antidepressants, anticonvulsants, anxiolytic agents, neuroleptics). According to WHO [120].

Paracetamol and tramadol are the most frequently used non-opioid analgesics

appears to cause a weak peripheral cyclooxygenase (COX) inhibition but also inhibits COX centrally [66]. The analgesic effect of paracetamol is thought to be related to an increasing pain threshold by means of central prostaglandin inhibition [30]. **Tramadol** is a synthetic analog of codeine. It has a central acting analgesic effect and inhibits norepinephrine and serotonin uptake [30].

**NMDA antagonists** are potent analgesics which interfere with the transmission in primary afferent pain pathways at the NMDA receptor. The prototype of NMDA antagonists is ketamine, which is effective in neuropathic and other chronic pain conditions.

### *Non-steroidal Anti-inflammatory Drugs*

NSAIDs are a cornerstone for inflammatory pain treatment

The primary mechanism of action of non-steroidal anti-inflammatory drugs (**NSAIDs**) is the inhibition of prostaglandin synthesis by **blocking cyclooxygenase (COX)**, which catalyzes the biotransformation of arachidonic acid to prostaglandins [62]. In most tissues, COX-1 is constitutively expressed, while COX-2 is induced in many cell types as a result of inflammation [62]. The products of COX-1 and COX-2, particularly prostaglandin $E_2$ and $I_2$, induce inflammatory alterations and act directly on sensory nerve endings [104]. Non-selective COX inhibitors (e.g. aspirin, ibuprofen, naproxen, diclofenac, piroxicam) inhibit both isoforms of COX. The inhibition of COX-1 has the disadvantage that it also prevents the synthesis of PGs that act to protect the tissue [66]. Subsequent to the discovery of COX isoenzymes, selective COX-2 inhibitors have been developed. However, selective COX-2 inhibitors (e.g. celecoxib, rofecoxib, valdecoxib) have recently been scrutinized because of the report of potential serious side effects [21, 48, 74].

### *Opioids*

Opioids are the mainstay of severe acute pain treatment

Opioids include all the endogenous and exogenous compounds that possess morphine-like analgesic properties [30]. Among the most commonly used opioids are morphine, hydromorphone, methadone, oxycodone, oxymorphone and fentanyl. These drugs remain the mainstay for the treatment of severe acute pain. Controversy exists about their effectiveness and safety with long-term use. A recent systematic review indicates that the short-term use of opioids is good in both neuropathic and musculoskeletal pain [56]. However, conclusions on tolerance and addiction were not possible because of the small numbers of patients with long-term opioid medication, not allowing conclusions to be drawn regarding the treatment of chronic pain [56].

### *Adjuvants*

The WHO has recommended adding adjuvant drugs to relieve pain associated fears and anxiety [120] and enhance the central effect on pain relief. Several **categories of adjuvant medications** can be differentiated:

- antidepressants
- anticonvulsants
- anxiolytics
- muscle relaxants
- sleep-promoting medications

Tricyclic **antidepressants** (e.g. amitriptyline, desipramine, nortriptyline) have a long history of use in neuropathic pain syndrome and act primarily by enhancing adrenergic $\alpha_2$-adrenoreceptor stimulation. Some also possess NMDA receptor-

blocking activity [66]. The rationale for their use in chronic low-back pain (LBP) is based on the frequent coexistence of pain and depression, their sedating effect (improving sleep) and supposed analgesic effect in lower doses [116]. However, there is contradictory evidence that antidepressants are effective for low back pain in the short to intermediate term [80, 116]. **Anticonvulsants** are extremely useful for neuropathic pain [89]. The effectiveness of the anticonvulsant drugs in the treatment of neuropathic and central pain states lies in their action as non-selective $Na^+$-channel-blocking agents [66]. Until recently, the first generation of anticonvulsants (e.g. phenytoin, carbamazepine and valproic acid) were used to treat neuropathic pain [36]. However, the newer antiepileptic agents including gabapentin and pregabalin are rapidly becoming the initial medications of choice to treat neuropathic pain [89]. **Selective serotonin reuptake inhibitors** (e.g. fluoxetine, paroxetine) are frequently used for the treatment of anxiety disorders. However, the therapeutic effects are not seen immediately because of a slow onset of action (2 – 4 weeks). Benzodiazepines are used to treat acute anxiety states and serve as a pre-medication before a surgical intervention to reduce stress and muscle spasm [89]. **Muscle relaxants** have a central action on the nervous system rather than a direct peripheral effect on muscle spasm. Benzodiazepines (e.g. diazepam) are sedative and exhibit an addictive potential as well as a withdrawal syndrome [89]. Baclofen centrally facilitates $GABA_B$ receptor-mediated transmission while tizanidine is a centrally acting $\alpha_2$-adrenergic agonist and reduces the release of excitatory neurotransmitters and inhibits spinal reflexes [89]. There is strong evidence that oral non-benzodiazepines are more effective than placebo for patients with acute LBP on short-term pain relief, global efficacy and improvement of physical outcomes. However, there is only moderate evidence for the short-term effectiveness in chronic LBP [116]. **Sleep-promoting medications** are helpful as adjuvant medication because of the high correlation of insomnia, depression and pain [121]. Appropriate pain treatment therefore also improves insomnia. Traditionally, antidepressants have been used because of their sedative effect. Benzodiazepines should only be used for short-term management of insomnia because of the well known side effects such as oversedation ("morning hangover"), addiction, dependence and withdrawal syndrome. Newer omega-1 receptor agonists (e.g. zolpidem, zaleplon) minimize morning hangover and withdrawal symptoms and have a shorter half-life [89].

Adjuvant drugs relieve pain associated fear and anxiety

## Non-pharmacological Treatment of Spinal Pain

It is well established that **bed rest** of more than 3 days for acute back pain is ill-advised [45, 116]. There is conflicting evidence on the effectiveness of **back schools** for patients with chronic LBP. While there also is conflicting evidence for the effect of **exercise therapy** for acute LBP, exercise is at least as (in-)effective as other conservative interventions for chronic LBP [116]. **Spinal manipulation** is not more effective in the short and long term compared with other conventionally advocated therapies such as general practice care, physical or exercise therapy, and back school [116].

## Biopsychosocial Interventions

Since Melzack and Wall's introduction on the gate control theory [77], our understanding of how psychosocial factors can modulate the pain signal has substantially increased. Furthermore, our understanding of pain has been shaped by another landmark paper. In the late 1970s, Engel [32] realized that the dominant biomedical model left no room within its framework for the social, psychological, and behavioral dimensions of illness. He therefore proposed a biopsychosocial

Biopsychosocial interventions are effective in chronic musculoskeletal pain

model which included physiologic as well as psychological and social factors, allowing for a more comprehensive understanding of pain. These two theoretical advances resulted in the development of various new treatment approaches, e.g. behavioral [33] and **cognitive-behavioral treatments** [114] that went beyond the biomedical dimension [84]. The rationale for this approach is that of altering the range of physical, psychological and social components of pain [84].

Chronic LBP patients should stay as active as possible

In persistent pain disorders, the actual tissue damage has almost always disappeared and rest is no longer required to promote healing. Therefore the advice to stay as active as possible is the most important advice which should be given to patients. There is evidence that this advice improves pain and function at least in the short term [116]. **Fordyce** and coworkers [35, 65] also indicated that pain **does not hurt so much if you have something to do**.

Cognitive-behavioral treatment is effective in chronic LBP in the short term

Although cognitive-respondent treatment and intensive multidisciplinary treatment have been shown to be effective for short-term improvement of pain and function in chronic LBP, there is still no evidence that any of these interventions provides long-term effects on low back pain and function [116].

## Surgical Treatment

The surgical treatment of chronic spinal pain continues to be very controversial [23]. So far, convincing evidence for the mid- and long-term superiority of spinal fusion over cognitive behavioral treatment and exercise is still lacking. Similarly, there is a lack of other invasive interventions (e.g. spinal injection, spinal cord stimulation, intrathecal pumps) to treat chronic low back pain other than disc herniation, spinal stenosis and spondylolisthesis [14, 117].

Surgery for persistent non-specific pain is not evidence-based

## Recapitulation

**Epidemiology.** The incidence of **chronic pain** ranges from **24% to 46%** in the general population. In 90% of chronic pain patients the pain is located in the musculoskeletal system. The natural history of chronic pain is poor due to a strong risk of pain persistence often regardless of treatment.

**Classification.** Pain may be differentiated into **acute pain** (1–4 weeks) caused by an adequate stimulation of **nociceptive** neurons. **Chronic pain** (>6 months) can occur spontaneously or can be provoked by a normally non-noxious stimulus. However, the temporal classification of pain does not reflect the underlying pain mechanism. A mechanism-based classification of pain is more reasonable. A contemporary definition of pain differentiates **adaptive (nociceptive and inflammatory) pain** protecting the individual from further damage and **maladaptive (neuropathic and functional) pain** that has lost this protective function and can be considered as a disease by itself.

**Pain pathways.** The physiologic processes involved in pain can be differentiated into transduction, conduction, transmission, modulation, projection and perception. **Transduction** is the conversion of noxious stimuli (thermal, mechanical and chemical) into electrical activity at the peripheral terminal of nociceptor sensory fibers. The DRG cell bodies give rise to three different fiber types (**Aβ, Aδ and C fibers**) responsible for nociception. The resulting sensory input to the central terminal of nociceptors is described as **conduction**. **Transmission** is the synaptic transfer and modulation of sensory input from one neuron to another. The peripheral nociceptive signals to the brain undergo various **modulations** by **excitatory (facilitatory)** and **inhibitory mechanisms** in the dorsal horn of the spinal cord. This modulation provides a framework to explain how pain can be felt even without tissue damage and how psychosocial factors can influence pain. After pain transmission and modulation, nociceptive information is transferred to the supraspinal structures via afferent bundles, which is known as **projection**. The spinal pathways project to the reticular formation of the brain stem before converging in the **thalamus**, the main structure for reception, integration and nociceptive transfer of noci-

ceptive stimuli before transmission to the somatosensory cortex (**perception**).

**Neuroplasticity.** Alterations in the physiological function of pain pathways as a result of tissue damage or neural injury are referred to as **neuroplasticity**. Injured tissue can release inflammatory mediators which activate and sensitize receptor channels in the peripheral terminal of the nociceptor. High-threshold and silent nociceptors are activated by a decrease in their threshold and show an increase in the responsiveness (**peripheral sensitization**). Tissue damage may also result in transcriptional changes in the dorsal root ganglion. Similarly, pain transmission is facilitated and inhibitory influences are attenuated by distinct neurobiological alterations of the receptor channels in the dorsal horn (**central sensitization**). Afferent nociceptive signals from the periphery to the brain are modulated by a well balanced interplay of excitatory and inhibitory neurons which can be disturbed as a result of an injury. **Disinhibition** is the disturbance of this balance with relief from inhibitory neuronal mechanisms. **Genetic predisposition** and **biopsychosocial factors** have a significant influence on the modulation of the afferent sensory input.

**Clinical assessment.** The clinical assessment of pain encompasses a detailed medical history, sophisticated quantitative sensory testing, neurophysiological studies, imaging studies, and pharmacological tests. The clinical differentiation of persistent inflammatory pain and neuropathic pain remains difficult because of the lack of an objective test for neuropathic pain (the missing gold standard). It is important to note that not all persistent pain is neuropathic. The diagnosis of **neuropathic pain** should be based on the **presence of negative and positive sensory symptoms and signs**.

**General treatment concepts.** The pharmacological treatment of acute pain must be aggressive, multimodal and preemptive to reduce the likelihood of pain persistence. The **WHO three-step pain relief ladder** indicates one should start with a weak analgesic and stepwise increase the potency of the medication until pain relief is felt. Analgesics can be differentiated into **non-opioid analgesics** (e.g. paracetamol, tramadol, ketamine), **NSAIDs**, and **opioids**. Opioids include all the endogenous and exogenous compounds that possess morphine-like analgesic properties. **Adjuvant drugs** (e.g. antidepressants, anticonvulsants, anxiolytics) are useful adjunct medications because they enhance the central effect of analgesics and target associated depression, fear or anxiety. **Non-pharmacological treatments** of chronic back pain such as back school, exercise therapy, or spinal manipulation have not passed the test of mid- and long-term clinical effectiveness. **Cognitive-behavioral treatment** is effective in chronic LBP only in the short term. Surgical treatment of chronic pain syndromes particularly chronic LBP has not been proven to be effective in the long term.

## Key Articles

**Melzack R, Wall PD (1965) Pain mechanism: A new theory. Science 150:971 – 979**
This paper introduced the gate control theory and substantially contributed to our increasing understanding of the pain signal.

**Engel GL (1977) The need for a new medical model: a challenge for biomedicine. Science 196:129 – 36**
The previous dominant model of disease in the late 1970s was biomedical, and it left no room within its framework for the social, psychological, and behavioral dimensions of illness. Therefore, Engel proposed a biopsychosocial model that closed the gap between the mind and the body.

**Woolf CJ (1983) Evidence for a central component of post-injury pain hypersensitivity. Nature 306:686 – 8**
This landmark paper introduces the phenomenon of central sensitization demonstrating that the long-term consequences of noxious stimuli result from central as well as from peripheral changes.

**Review Articles (recommended for further reading)**
Besson JM (1999) The neurobiology of pain. Lancet 353:1610 – 5

Furst S (1999) Transmitters involved in antinociception in the spinal cord. Brain Res Bull 48:129 – 41
Julius D, Basbaum AI (2001) Molecular mechanisms of nociception. Nature 413:203 – 10
Scholz J, Woolf CJ (2002) Can we conquer pain? Nat Neurosci 5 Suppl:1062 – 7
Jensen TS, Baron R (2003) Translation of symptoms and signs into mechanisms in neuropathic pain. Pain 102:1 – 8
Woolf CJ (2004) Pain: moving from symptom control toward mechanism-specific pharmacologic management. Ann Intern Med 140:441 – 51
Almeida TF, Roizenblatt S, Tufik S (2004) Afferent pain pathways: a neuroanatomical review. Brain Res 1000:40 – 56
Kehlet H, Jensen TS, Woolf CJ (2006) Persistent postsurgical pain: risk factors and prevention. Lancet 367:1618 – 25

**Appendix:** IASP Pain Terminology (www.iasp-pain.org)

| | |
|---|---|
| allodynia | • pain due to a stimulus that does not normally provoke pain |
| analgesia | • absence of pain in response to stimulation that would normally be painful |
| anesthesia dolorosa | • pain in an area or region that is anesthetic |
| causalgia | • a syndrome of sustained burning pain, allodynia, and hyperpathia after a traumatic nerve lesion, often combined with vasomotor and sudomotor dysfunction and later trophic changes |
| dysesthesia | • an unpleasant abnormal sensation, whether spontaneous or evoked |
| hyperalgesia | • an increased response to a stimulus that is normally painful |
| hyperesthesia | • increased sensitivity to stimulation, excluding special senses |
| hyperpathia | • a painful syndrome, characterized by increased reaction to a stimulus, especially a repetitive stimulus, as well as an increased threshold |
| hypoalgesia | • diminished sensitivity to noxious stimulation |
| hypoesthesia | • diminished sensitivity to stimulation, excluding special senses |
| neuralgia | • pain in distribution of nerve or nerves |
| neuritis | • inflammation of a nerve or nerves |
| neurogenic pain | • pain initiated by a primary lesion, dysfunction, or transitory perturbation in the peripheral or central nervous system |
| neuropathic pain | • any pain syndrome in which the predominating mechanism is a site of aberrant somatosensory processing in the peripheral or central nervous system |
| neuropathy | • a disturbance of function or pathologic change in a nerve; in one nerve, mononeuropathy; in several nerves, mononeuropathy multiplex; if symmetrical and bilateral, polyneuropathy |
| nociceptor | • a receptor preferentially sensitive to a noxious stimulus or to a stimulus that would become noxious if prolonged |
| noxious stimulus | • a noxious stimulus is one that is potentially or actually damaging to body tissue |
| pain | • an unpleasant sensory and emotional experience associated with actual or potential tissue damage, or described in terms of such damage |
| pain threshold | • the least experience of pain that a subject can recognize |
| pain tolerance level | • the greatest level of pain that a subject is prepared to tolerate |
| paresthesia | • an abnormal sensation, whether spontaneous or evoked |

## References

1. Ahmadi S, Lippross S, Neuhuber WL, Zeilhofer HU (2002) PGE(2) selectively blocks inhibitory glycinergic neurotransmission onto rat superficial dorsal horn neurons. Nat Neurosci 5:34 – 40
2. Almeida TF, Roizenblatt S, Tufik S (2004) Afferent pain pathways: a neuroanatomical review. Brain Res 1000:40 – 56
3. Andersson HI, Ejlertsson G, Leden I, Rosenberg C (1993) Chronic pain in a geographically defined general population: studies of differences in age, gender, social class, and pain localization. Clin J Pain 9:174 – 82
4. Anonymous (1997) Practice guidelines for chronic pain management. A report by the American Society of Anesthesiologists Task Force on Pain Management, Chronic Pain Section. Anesthesiology 86:995 – 1004

5. Anonymous (2004) Practice guidelines for acute pain management in the perioperative setting: an updated report by the American Society of Anesthesiologists Task Force on Acute Pain Management. Anesthesiology 100:1573 – 81
6. Battie MC, Videman T (2006) Lumbar disc degeneration: epidemiology and genetics. J Bone Joint Surg Am 88 Suppl 2:3 – 9
7. Benini A, DeLeo JA (1999) Rene Descartes' physiology of pain. Spine 24:2115 – 9
8. Bennett MI, Attal N, Backonja MM, Baron R, Bouhassira D, Freynhagen R, Scholz J, Tolle TR, Wittchen HU, Jensen TS (2007) Using screening tools to identify neuropathic pain. Pain 127:199 – 203
9. Besson JM (1999) The neurobiology of pain. Lancet 353:1610 – 5
10. Bingefors K, Isacson D (2004) Epidemiology, co-morbidity, and impact on health-related quality of life of self-reported headache and musculoskeletal pain – a gender perspective. Eur J Pain 8:435 – 50
11. Blyth FM, Macfarlane GJ, Nicholas MK (2007) The contribution of psychosocial factors to the development of chronic pain: the key to better outcomes for patients? Pain 129:8 – 11
12. Brooks J, Tracey I (2005) From nociception to pain perception: imaging the spinal and supraspinal pathways. J Anat 207:19 – 33
13. Buffington AL, Hanlon CA, McKeown MJ (2005) Acute and persistent pain modulation of attention-related anterior cingulate fMRI activations. Pain 113:172 – 84
14. Carter ML (2004) Spinal cord stimulation in chronic pain: a review of the evidence. Anaesth Intensive Care 32:11 – 21
15. Cassidy JD, Carroll LJ, Cote P (1998) The Saskatchewan health and back pain survey. The prevalence of low back pain and related disability in Saskatchewan adults. Spine 23:1860 – 6; discussion 1867
16. Clark MR, Treisman GJ (2004) Perspectives on pain and depression. Adv Psychosom Med 25:1 – 27
17. Coderre TJ, Katz J, Vaccarino AL, Melzack R (1993) Contribution of central neuroplasticity to pathological pain: review of clinical and experimental evidence. Pain 52:259 – 85
18. Costigan M, Woolf CJ (2000) Pain: molecular mechanisms. J Pain 1:35 – 44
19. Costigan M, Woolf CJ (2002) No DREAM, No pain. Closing the spinal gate. Cell 108:297 – 300
20. Cote P, Cassidy JD, Carroll L (1998) The Saskatchewan Health and Back Pain Survey. The prevalence of neck pain and related disability in Saskatchewan adults. Spine 23: 1689 – 98
21. Crofford LJ, Breyer MD, Strand CV, Rushitzka F, Brune K, Farkouh ME, Simon LS (2006) Cardiovascular effects of selective COX-2 inhibition: is there a class effect? The International COX-2 Study Group. J Rheumatol 33:1403 – 8
22. DeLeo JA (2006) Basic science of pain. J Bone Joint Surg Am 88 Suppl 2:58 – 62
23. Deyo RA, Nachemson A, Mirza SK (2004) Spinal-fusion surgery – the case for restraint. N Engl J Med 350:722 – 6
24. Dionne CE, Von Korff M, Koepsell TD, Deyo RA, Barlow WE, Checkoway H (1999) A comparison of pain, functional limitations, and work status indices as outcome measures in back pain research. Spine 24:2339 – 45
25. Dotson RM (1997) Clinical neurophysiology laboratory tests to assess the nociceptive system in humans. J Clin Neurophysiol 14:32 – 45
26. Dubner R, Hargreaves KM (1989) The neurobiology of pain and its modulation. Clin J Pain 5 Suppl 2:S1 – 4; discussion S4 – 6
27. Dworkin RH, Backonja M, Rowbotham MC, Allen RR, Argoff CR, Bennett GJ, Bushnell MC, Farrar JT, Galer BS, Haythornthwaite JA, Hewitt DJ, Loeser JD, Max MB, Saltarelli M, Schmader KE, Stein C, Thompson D, Turk DC, Wallace MS, Watkins LR, Weinstein SM (2003) Advances in neuropathic pain: diagnosis, mechanisms, and treatment recommendations. Arch Neurol 60:1524 – 34
28. Edwards RR, Doleys DM, Fillingim RB, Lowery D (2001) Ethnic differences in pain tolerance: clinical implications in a chronic pain population. Psychosom Med 63:316 – 23
29. Ehrlich GE (2003) Low back pain. Bull WHO 81:671 – 676
30. Ekman EF, Koman LA (2005) Acute pain following musculoskeletal injuries and orthopaedic surgery: mechanisms and management. Instr Course Lect 54:21 – 33
31. Elliott AM, Smith BH, Hannaford PC, Smith WC, Chambers WA (2002) The course of chronic pain in the community: results of a 4-year follow-up study. Pain 99:299 – 307
32. Engel GL (1977) The need for a new medical model: a challenge for biomedicine. Science 196:129 – 36
33. Fey SG, Fordyce WE (1983) Behavioral rehabilitation of the chronic pain patient. Annu Rev Rehabil 3:32 – 63
34. Fillingim RB, Hastie BA, Ness TJ, Glover TL, Campbell CM, Staud R (2005) Sex-related psychological predictors of baseline pain perception and analgesic responses to pentazocine. Biol Psychol 69:97 – 112
35. Fordyce WE (1991) Behavioral factors in pain. Neurosurg Clin N Am 2:749 – 59
36. Freeman R (2005) The treatment of neuropathic pain. CNS Spectr 10:698 – 706

37. Furst S (1999) Transmitters involved in antinociception in the spinal cord. Brain Res Bull 48:129 – 41
38. Gagliese L, Melzack R (1997) Chronic pain in elderly people. Pain 70:3 – 14
39. Gillespie PG, Walker RG (2001) Molecular basis of mechanosensory transduction. Nature 413:194 – 202
40. Gorman DJ, Kam PA, Brisby H, Diwan AD (2004) When is spinal pain "neuropathic"? Orthop Clin North Am 35:73 – 84
41. Gottschalk A, Wu CL, Ochroch EA (2002) Current treatment options for acute pain. Expert Opin Pharmacother 3:1599 – 611
42. Goubert L, Crombez G, De Bourdeaudhuij I (2004) Low back pain, disability and back pain myths in a community sample: prevalence and interrelationships. Eur J Pain 8:385 – 94
43. Grachev ID, Fredrickson BE, Apkarian AV (2000) Abnormal brain chemistry in chronic back pain: an in vivo proton magnetic resonance spectroscopy study. Pain 89:7 – 18
44. Greenough CG, Fraser RD (1991) Comparison of eight psychometric instruments in unselected patients with back pain. Spine 16:1068 – 74
45. Hagen KB, Hilde G, Jamtvedt G, Winnem MF (2000) The Cochrane Review of Bed Rest for Acute Low Back Pain and Sciatica. Spine 25:2932 – 2939
46. Harvey RJ, Depner UB, Wassle H, Ahmadi S, Heindl C, Reinold H, Smart TG, Harvey K, Schutz B, Abo-Salem OM, Zimmer A, Poisbeau P, Welzl H, Wolfer DP, Betz H, Zeilhofer HU, Muller U (2004) GlyR alpha3: an essential target for spinal PGE2-mediated inflammatory pain sensitization. Science 304:884 – 7
47. Hastie BA, Riley JL, 3rd, Fillingim RB (2004) Ethnic differences in pain coping: factor structure of the coping strategies questionnaire and coping strategies questionnaire-revised. J Pain 5:304 – 16
48. Heim HK, Broich K (2006) Selective COX-2 inhibitors and risk of thromboembolic events – regulatory aspects. Thromb Haemost 96:423 – 32
49. Hellwig N, Plant TD, Janson W, Schafer M, Schultz G, Schaefer M (2004) TRPV1 acts as proton channel to induce acidification in nociceptive neurons. J Biol Chem 279:34553 – 61
50. IASP Task Force on Taxonomy (1994) Classification of chronic pain. In: Merskey H, Bogduk N, eds. Seattle: IASP Press, 209 – 214
51. Jensen TS, Baron R (2003) Translation of symptoms and signs into mechanisms in neuropathic pain. Pain 102:1 – 8
52. Ji RR, Baba H, Brenner GJ, Woolf CJ (1999) Nociceptive-specific activation of ERK in spinal neurons contributes to pain hypersensitivity. Nat Neurosci 2:1114 – 9
53. Ji RR, Befort K, Brenner GJ, Woolf CJ (2002) ERK MAP kinase activation in superficial spinal cord neurons induces prodynorphin and NK-1 upregulation and contributes to persistent inflammatory pain hypersensitivity. J Neurosci 22:478 – 85
54. Jin SX, Zhuang ZY, Woolf CJ, Ji RR (2003) p38 mitogen-activated protein kinase is activated after a spinal nerve ligation in spinal cord microglia and dorsal root ganglion neurons and contributes to the generation of neuropathic pain. J Neurosci 23:4017 – 22
55. Julius D, Basbaum AI (2001) Molecular mechanisms of nociception. Nature 413:203 – 10
56. Kalso E, Edwards JE, Moore RA, McQuay HJ (2004) Opioids in chronic non-cancer pain: systematic review of efficacy and safety. Pain 112:372 – 80
57. Karani R, Meier DE (2004) Systemic pharmacologic postoperative pain management in the geriatric orthopaedic patient. Clin Orthop Relat Res:26 – 34
58. Keefe FJ, Rumble ME, Scipio CD, Giordano LA, Perri LM (2004) Psychological aspects of persistent pain: current state of the science. J Pain 5:195 – 211
59. Kehlet H, Jensen TS, Woolf CJ (2006) Persistent postsurgical pain: risk factors and prevention. Lancet 367:1618 – 25
60. Kidd BL (1999) What are the mechanisms of regional musculoskeletal pain? Baillieres Best Pract Res Clin Rheumatol 13:217 – 30
61. Kidd BL, Urban LA (2001) Mechanisms of inflammatory pain. Br J Anaesth 87:3 – 11
62. Kiefer W, Dannhardt G (2002) COX-2 inhibition and the control of pain. Curr Opin Investig Drugs 3:1348 – 58
63. Konen A (2000) Measurement of nerve dysfunction in neuropathic pain. Curr Rev Pain 4:388 – 94
64. Lin SY, Wu K, Levine ES, Mount HT, Suen PC, Black IB (1998) BDNF acutely increases tyrosine phosphorylation of the NMDA receptor subunit 2B in cortical and hippocampal postsynaptic densities. Brain Res Mol Brain Res 55:20 – 7
65. Lindstrom I, Ohlund C, Eek C, Wallin L, Peterson LE, Fordyce WE, Nachemson AL (1992) The effect of graded activity on patients with subacute low back pain: a randomized prospective clinical study with an operant-conditioning behavioral approach. Phys Ther 72:279 – 90; discussion 291 – 3
66. MacPherson RD (2000) The pharmacological basis of contemporary pain management. Pharmacol Ther 88:163 – 85
67. MacPherson RD (2002) New directions in pain management. Drugs Today (Barc) 38: 135 – 45

68. Maihofner C, Handwerker HO, Birklein F (2006) Functional imaging of allodynia in complex regional pain syndrome. Neurology 66:711 – 7
69. Main CJ, Spanswick CC (1991) Pain: psychological and psychiatric factors. Br Med Bull 47:732 – 42
70. Main CJ, Spanswick CC (2000) Models of pain. In: Main CJ, Spanswick CC, eds. Pain management. An interdisciplinary approach. Edinburgh: Churchill Livingstone, 3 – 18
71. Mannion RJ, Costigan M, Decosterd I, Amaya F, Ma QP, Holstege JC, Ji RR, Acheson A, Lindsay RM, Wilkinson GA, Woolf CJ (1999) Neurotrophins: peripherally and centrally acting modulators of tactile stimulus-induced inflammatory pain hypersensitivity. Proc Natl Acad Sci U S A 96:9385 – 90
72. Mannion RJ, Woolf CJ (2000) Pain mechanisms and management: a central perspective. Clin J Pain 16:S144 – 56
73. Margolis RB, Tait RC, Krause SJ (1986) A rating system for use with patient pain drawings. Pain 24:57 – 65
74. Maxwell SR, Payne RA, Murray GD, Webb DJ (2006) Selectivity of NSAIDs for COX-2 and cardiovascular outcome. Br J Clin Pharmacol 62:243 – 5
75. McKemy DD (2005) How cold is it? TRPM8 and TRPA1 in the molecular logic of cold sensation. Mol Pain 1:16
76. Melzack R (1987) The short-form McGill Pain Questionnaire. Pain 30:191 – 7
77. Melzack R, Wall PD (1965) Pain mechanism: A new theory. Science 150:971 – 979
78. Millan MJ (1999) The induction of pain: an integrative review. Prog Neurobiol 57:1 – 164
79. Moore KA, Kohno T, Karchewski LA, Scholz J, Baba H, Woolf CJ (2002) Partial peripheral nerve injury promotes a selective loss of GABAergic inhibition in the superficial dorsal horn of the spinal cord. J Neurosci 22:6724 – 31
80. Moulin DE (2001) Systemic drug treatment for chronic musculoskeletal pain. Clin J Pain 17:S86 – 93
81. Muir WW, 3rd, Woolf CJ (2001) Mechanisms of pain and their therapeutic implications. J Am Vet Med Assoc 219:1346 – 56
82. Nachemson AL (1992) Newest knowledge of low back pain. A critical look. Clin Orthop Relat Res:8 – 20
83. Nakamura F, Strittmatter SM (1996) P2Y1 purinergic receptors in sensory neurons: contribution to touch-induced impulse generation. Proc Natl Acad Sci U S A 93:10465 – 70
84. Nielson WR, Weir R (2001) Biopsychosocial approaches to the treatment of chronic pain. Clin J Pain 17:S114 – 27
85. Niemelainen R, Videman T, Battie MC (2006) Prevalence and characteristics of upper or mid-back pain in Finnish men. Spine 31:1846 – 9
86. Obata K, Noguchi K (2004) MAPK activation in nociceptive neurons and pain hypersensitivity. Life Sci 74:2643 – 53
87. Pasternak GW, Inturrisi CE (2006) Feeling pain? Who's your daddy. Nat Med 12:1243 – 4
88. Peier AM, Moqrich A, Hergarden AC, Reeve AJ, Andersson DA, Story GM, Earley TJ, Dragoni I, McIntyre P, Bevan S, Patapoutian A (2002) A TRP channel that senses cold stimuli and menthol. Cell 108:705 – 15
89. Polatin PB, Dersh J (2004) Psychotropic medication in chronic spinal disorders. Spine J 4:436 – 50
90. Polatin PB, Gatchel RJ, Barnes D, Mayer H, Arens C, Mayer TG (1989) A psychosociomedical prediction model of response to treatment by chronically disabled workers with low-back pain. Spine 14:956 – 961
91. Polatin PB, Kinney RK, Gatchel RJ, Lillo E, Mayer TG (1993) Psychiatric illness and chronic low-back pain. The mind and the spine – which goes first? Spine 18:66 – 71
92. Polgar E, Hughes DI, Riddell JS, Maxwell DJ, Puskar Z, Todd AJ (2003) Selective loss of spinal GABAergic or glycinergic neurons is not necessary for development of thermal hyperalgesia in the chronic constriction injury model of neuropathic pain. Pain 104:229 – 39
93. Porreca F, Ossipov MH, Gebhart GF (2002) Chronic pain and medullary descending facilitation. Trends Neurosci 25:319 – 25
94. Poyhia R, Da Costa D, Fitzcharles MA (2001) Previous pain experience in women with fibromyalgia and inflammatory arthritis and nonpainful controls. J Rheumatol 28: 1888 – 91
95. Price DD, Craggs J, Verne GN, Perlstein WM, Robinson ME (2007) Placebo analgesia is accompanied by large reductions in pain-related brain activity in irritable bowel syndrome patients. Pain 127:63 – 72
96. Ransford A, Cairns D, Mooney V (1976) The pain drawing as an aid to the psychologic evaluation of patients with low-back pain. Spine 1:127 – 134
97. Rasmussen PV, Sindrup SH, Jensen TS, Bach FW (2004) Symptoms and signs in patients with suspected neuropathic pain. Pain 110:461 – 9
98. Reinold H, Ahmadi S, Depner UB, Layh B, Heindl C, Hamza M, Pahl A, Brune K, Narumiya S, Muller U, Zeilhofer HU (2005) Spinal inflammatory hyperalgesia is mediated by prostaglandin E receptors of the EP2 subtype. J Clin Invest 115:673 – 9
99. Rexed B (1954) A cytoarchitectonic atlas of the spinal cord in the cat. J Comp Neurol 100:297 – 379

100. Robinson ME, Riley JL, 3rd, Myers CD, Papas RK, Wise EA, Waxenberg LB, Fillingim RB (2001) Gender role expectations of pain: relationship to sex differences in pain. J Pain 2:251 – 7
101. Russo CM, Brose WG (1998) Chronic pain. Annu Rev Med 49:123 – 33
102. Rustoen T, Wahl AK, Hanestad BR, Lerdal A, Paul S, Miaskowski C (2004) Prevalence and characteristics of chronic pain in the general Norwegian population. Eur J Pain 8:555 – 65
103. Samad TA, Moore KA, Sapirstein A, Billet S, Allchorne A, Poole S, Bonventre JV, Woolf CJ (2001) Interleukin-1beta-mediated induction of Cox-2 in the CNS contributes to inflammatory pain hypersensitivity. Nature 410:471 – 5
104. Schaible HG, Vanegas H (2000) How do we manage chronic pain? Baillieres Best Pract Res Clin Rheumatol 14:797 – 811
105. Schofferman J (1999) Long-term opioid analgesic therapy for severe refractory lumbar spine pain. Clin J Pain 15:136 – 40
106. Scholz J, Woolf CJ (2002) Can we conquer pain? Nat Neurosci 5 Suppl:1062 – 7
107. Schweinhardt P, Glynn C, Brooks J, McQuay H, Jack T, Chessell I, Bountra C, Tracey I (2006) An fMRI study of cerebral processing of brush-evoked allodynia in neuropathic pain patients. Neuroimage 32:256 – 65
108. Shu X, Mendell LM (1999) Nerve growth factor acutely sensitizes the response of adult rat sensory neurons to capsaicin. Neurosci Lett 274:159 – 62
109. Smedley J, Egger P, Cooper C, Coggon D (1997) Prospective cohort study of predictors of incident low back pain in nurses. BMJ 314:1225 – 8
110. Suen PC, Wu K, Xu JL, Lin SY, Levine ES, Black IB (1998) NMDA receptor subunits in the postsynaptic density of rat brain: expression and phosphorylation by endogenous protein kinases. Brain Res Mol Brain Res 59:215 – 28
111. Swett JE, Woolf CJ (1985) The somatotopic organization of primary afferent terminals in the superficial laminae of the dorsal horn of the rat spinal cord. J Comp Neurol 231: 66 – 77
112. Tegeder I, Costigan M, Griffin RS, Abele A, Belfer I, Schmidt H, Ehnert C, Nejim J, Marian C, Scholz J, Wu T, Allchorne A, Diatchenko L, Binshtok AM, Goldman D, Adolph J, Sama S, Atlas SJ, Carlezon WA, Parsegian A, Lotsch J, Fillingim RB, Maixner W, Geisslinger G, Max MB, Woolf CJ (2006) GTP cyclohydrolase and tetrahydrobiopterin regulate pain sensitivity and persistence. Nat Med 12:1269 – 77
113. Thomas E, Silman AJ, Croft PR, Papageorgiou AC, Jayson MI, Macfarlane GJ (1999) Predicting who develops chronic low back pain in primary care: a prospective study. BMJ 318:1662 – 7
114. Turk DC, Kerns RD (1983) Conceptual issues in the assessment of clinical pain. Int J Psychiatry Med 13:57 – 68
115. Turk DC, Okifuji A (2002) Psychological factors in chronic pain: evolution and revolution. J Consult Clin Psychol 70:678 – 90
116. van Tulder MW, Koes B, Malmivaara A (2006) Outcome of non-invasive treatment modalities on back pain: an evidence-based review. Eur Spine J 15 Suppl 1:S64 – 81
117. van Tulder MW, Koes B, Seitsalo S, Malmivaara A (2006) Outcome of invasive treatment modalities on back pain and sciatica: an evidence-based review. Eur Spine J 15 Suppl 1:S82 – 92
118. Von Korff M, Saunders K (1996) The course of back pain in primary care. Spine 21:2833 – 7; discussion 2838 – 9
119. Watkins LR, Milligan ED, Maier SF (2001) Glial activation: a driving force for pathological pain. Trends Neurosci 24:450 – 5
120. WHO. http://www.who.int/cancer/palliative/painladder/en/, 2007.
121. Wilson KG, Eriksson MY, D'Eon JL, Mikail SF, Emery PC (2002) Major depression and insomnia in chronic pain. Clin J Pain 18:77 – 83
122. Woolf CJ (1995) Somatic pain – pathogenesis and prevention. Br J Anaesth 75:169 – 76
123. Woolf CJ (2004) Pain: moving from symptom control toward mechanism-specific pharmacologic management. Ann Intern Med 140:441 – 51
124. Woolf CJ (2007) Central sensitization: uncovering the relation between pain and plasticity. Anesthesiology 106:864 – 7
125. Woolf CJ, Costigan M (1999) Transcriptional and posttranslational plasticity and the generation of inflammatory pain. Proc Natl Acad Sci U S A 96:7723 – 30
126. Woolf CJ, Decosterd I (1999) Implications of recent advances in the understanding of pain pathophysiology for the assessment of pain in patients. Pain Suppl 6:S141 – 7
127. Woolf CJ, Fitzgerald M (1986) Somatotopic organization of cutaneous afferent terminals and dorsal horn neuronal receptive fields in the superficial and deep laminae of the rat lumbar spinal cord. J Comp Neurol 251:517 – 31
128. Woolf CJ, Mannion RJ (1999) Neuropathic pain: aetiology, symptoms, mechanisms, and management. Lancet 353:1959 – 64
129. Woolf CJ, Max MB (2001) Mechanism-based pain diagnosis: issues for analgesic drug development. Anesthesiology 95:241 – 9

130. Woolf CJ, Salter MW (2000) Neuronal plasticity: increasing the gain in pain. Science 288:1765 – 9
131. Yu XM, Askalan R, Keil GJ, 2nd, Salter MW (1997) NMDA channel regulation by channel-associated protein tyrosine kinase Src. Science 275:674 – 8
132. Zeilhofer HU (2005) The glycinergic control of spinal pain processing. Cell Mol Life Sci 62:2027 – 35
133. Zeilhofer HU, Brune K (2006) Analgesic strategies beyond the inhibition of cyclooxygenases. Trends Pharmacol Sci 27:467 – 74
134. Zimmermann M (2001) Pathobiology of neuropathic pain. Eur J Pharmacol 429:23 – 37
135. Zirrgiebel U, Ohga Y, Carter B, Berninger B, Inagaki N, Thoenen H, Lindholm D (1995) Characterization of TrkB receptor-mediated signaling pathways in rat cerebellar granule neurons: involvement of protein kinase C in neuronal survival. J Neurochem 65:2241 – 50

# 6 Epidemiology and Risk Factors of Spinal Disorders

Achim Elfering, Anne F. Mannion

## Core Messages

- ✔ In 85 % of patients with a spinal disorder the etiology is unclear
- ✔ In non-specific spinal disorders, axial pain (i.e. cervical, thoracic, lumbar pain without radiation into the extremities) is the main symptom
- ✔ Back pain in non-specific spinal disorders is a symptom, not a disease
- ✔ With a 12-month prevalence of 15–45 %, a 12-month incidence of up to 20 %, and a yearly recurrence rate of up to 60 %, low back pain (LBP) is a major health problem.
- ✔ The prevalence and incidence rates for neck pain are only slightly lower
- ✔ For the majority of people with an acute episode of LBP (80–90 %), the prognosis is good: within 1 month, marked improvements in pain and disability occur, and work can be resumed
- ✔ Work-related disability from non-specific spinal disorders has become epidemic in industrialized countries
- ✔ Only a minority of patients are chronically disabled, but such cases cause most of the costs
- ✔ Over 50 % of the costs of spinal disorders are related to indirect societal costs
- ✔ The best predictor of future episodes of back pain is previous back pain
- ✔ Models of back pain are multifactorial, and include genetic, biological, physical, psychological, sociological, and health policy factors
- ✔ Occupational psychosocial variables are clearly linked to the transition from acute to chronic neck and back pain, work disability, recovery, and return to work

## General Scope

Epidemiology is **research on the frequency and causes of diseases or syndromes** in different populations. The baseline idea of epidemiology is that disease and causal factors are not distributed at random in human populations. Individuals who develop a disease are expected to be exposed to antecedent risk factors to a greater degree or for a longer time than are individuals who stay healthy. It is important to bear in mind that epidemiology estimates the association between risk factors and diseases in statistical terms.

Epidemiology estimates the association between risk factors and diseases in statistical terms

A second significant **goal of epidemiology** therefore is to rule out alternative sources of association, e.g. confounding factors, study bias, and chance. Epidemiological knowledge contributes to the planning and evaluation of primary prevention. Epidemiological data also serve as a guide to the management of patients in whom disease has already developed. The number of individuals that suffer from a disease or a syndrome is expressed in terms of prevalence rates, and the number of new cases is expressed in incidence rates.

**Prevalence.** Prevalence refers to the percentage of a population that is affected with a particular disease at a given time or for a given period. Frequently used time periods are the whole adult **lifetime** until the establishing diagnosis (life-

time prevalence), or 1, 6, or 12 months before the interview-establishing diagnosis (1-, 6-, or 12-month prevalence rates; also called **current prevalence rates**). **Point prevalence** indicates the percentage of those reporting pain on the day of the interview.

**Incidence.** Incidence refers to the number or rate of new cases of the disorder per persons at risk (usually 100 or 1 000) during a specified period of time (usually one year). To determine the incidence rate, individuals who were healthy at the beginning of the observation period and who become affected during the observation period are counted. From this definition it follows that incidence rates are hard to estimate when conditions are widespread or often reoccur and therefore lack clear information on first onset. Incidence rates tend to be higher when comparably weak criteria are used to define health at the beginning ("no symptoms during 2 months before"), and are lower when criteria are stricter ("never experienced symptoms before").

**Persistence and Recurrence.** Because of the high prevalence and incidence rates, the burden of back pain in adult populations is better estimated with measures of the persistence ("**duration of pain episodes**") and recurrence ("**number of recurrent episodes**"). Persistence and recurrence are also captured by measuring the total number of days with pain in the last year. For instance, work disability is longer in recurrent compared with first episodes to low back pain [107].

**Severity.** The intensity of pain and functional disability represent the main focus in attempts to devise a grading system indicating the severity of disorders [78, 97].

## Objectives in Spinal Disorders

The **specific objectives of epidemiology** in the management of spinal disorders are to [77]:

- pinpoint the problem
- estimate the societal and economic burden of spinal disorders
- forecast the problem in future
- describe and differentiate spinal disorders
- classify and grade symptoms within spinal disorders
- describe the natural history (assisting decision making)
- identify preceding risk factors and estimate their impact (alone or combined)
- identify protective resource factors preventing disease or promoting healing
- evaluate primary and secondary prevention efforts
- provide guidance for health care planning

Epidemiology helps to classify spinal disorders, identify risk factors, predict natural history and estimate costs

Epidemiology contributes to the standardization of terminology, a matter that is still unsatisfactory in spinal disorders. For instance it was shown recently that different definitions of back pain are systematically related to differences in prevalence rates [68].

Risk and resource factors comprise demographic, genetic, and other individual factors, and occupational, societal and even non-identified cultural characteristics [52]. Epidemiology is often a source for methodological development that helps to crystallize evidence from a data pool. Finally, epidemiology helps to evaluate primary and secondary prevention efforts and offers important guidance for planning health policy [77].

## Classification of Spinal Disorders

Spinal disorders are a wide and heterogeneous variety of diseases affecting the vertebrae, intervertebral discs, facet joints, tendons and ligaments, muscles, spinal cord and nerve roots of the spine (Table 1).

### Etiology

Spinal disorders comprise a variety of disorders that all involve the spinal column

We can differentiate spinal disorders according to their etiology. We differentiate on the basis of whether a specific cause can be found which conclusively explains the patient's symptoms:

**Specific spinal disorders** have an unambiguous etiology and can be diagnosed on the basis of specific structural pathologies that are consistent with the clinical picture.

**Non-specific spinal disorders** are not diseases per se but more of a syndrome. In the vast majority of patients (85–90%) presenting with a spinal disorder it is not possible to identify a pathomorphological source of the problem despite a thorough diagnostic work-up [66]. There are many potential causative and aggravating factors associated with non-specific spinal disorders but no structural pathology can, with certainty, be held responsible for the symptoms. It is not easy to differentiate between specific and non-specific spinal disorders by early symptoms, because the primary manifestation of most spinal disorders is pain involving the neck and back.

For pain which is not radiating into the extremities the term **axial pain** is often used. We can differentiate between:

- axial neck pain
- axial dorsal pain
- axial back pain

### Time Course

Spinal disorders can be further classified according to the **time course** of symptoms:

- acute – duration less than 1 month
- subacute – duration up to 3 months
- chronic – duration more than 3 months

Neck and back pain are the most common symptoms in non-specific spinal disorders

Spinal disorders are labeled as **acute** if persisting for a short time period (less than 1 month) with a sudden onset. Symptoms are classified as **subacute** if they occur after a prolonged period (6 months) without pain and with a retrospective duration of less than 3 months. A **chronic** stage is reached if symptoms occur epi-

**Table 1.** Classification of spinal disorders

| Specific spinal disorders | Non-specific spinal disorders |
|---|---|
| **With** clearly identifiable pathomorphological correlate (10–15%) such as:<br>• congenital<br>• developmental<br>• traumatic<br>• infectious<br>• tumorous<br>• metabolic<br>• degenerative (depending on the disorder) | **Without** clearly identifiable pathomorphological correlate (85–90%):<br>• non-specific axial neck pain<br>• non-specific axial dorsal pain<br>• non-specific axial back pain |

sodically within a 6-month period or last for more than 3 months [47]. Back and neck pain within non-specific spinal disorders are frequently accompanied by other types of musculoskeletal pain, bodily complaints, psychological distress and, especially in chronic cases, amplified dysfunctional cognition (e.g. catastrophizing) and pain behavior [81]. It is important to keep in mind that LBP of less than 7 days' duration is not a disease. However, a complaint can turn into a complex syndrome.

## Low Back Pain

Low back pain is common and appears as pain, muscle tension, or stiffness localized below the costal margin and above the inferior gluteal folds, with or without leg pain (sciatica) [54].

With respect to the cause of back pain the so-called "**diagnostic triage**" [99, 100] classification has become standard. It divides low back pain into **three categories**:

- specific spinal pathology
- nerve root pain/radicular pain
- non-specific low back pain

Back pain often is divided into three large groups with respect to its location, aggravating factors, and temporal nature: **referred** pain, **axial** pain, and **radicular** pain.

- **axial** or **mechanical pain** (neck, dorsal, back) is restricted to the lower back area and gets worse with certain activities or positions.
- **referred** pain comes and goes and varies in intensity. It starts in the low back area and commonly spreads into the groin, buttocks and upper thighs.
- **radicular** pain is deep and usually constant. It radiates down the leg according to the dermatone and is accompanied by numbness or tingling and muscle weakness. This type of pain is caused by injury to a spinal nerve. Some of the possible causes are a disc herniation or foraminal stenosis.

The lifetime prevalence of LBP ranges between 75 % and 85 %

About 75 – 85 % of all individuals will experience LBP at some time during their life (**lifetime prevalence**). Most epidemiological studies do not differentiate between types of pain [66]. The lifetime prevalence for associated leg pain seems to be about half that of back pain in general, and the lifetime prevalence of sciatic pain is estimated to be much lower, approximately 3 – 5 % [40].

The yearly prevalence of back pain is estimated to range from 15 % to 20 % in the US and from 25 % to 45 % in Europe. The natural history of LBP is usually favorable and most individuals recover within 2 – 4 weeks; of the remainder, more than 90 % resolve within 12 weeks [3]. A complete view of back-related work absence in Jersey/the UK showed that 3 % of those starting absence in 1994 and who were out of work for 6 months or more caused 33 % of social benefit costs [108]. This population based study also showed that recurrent episodes are associated with longer work absences, and that more specific diagnoses are associated with longer absences than non-specific back pain and back injuries [108]. In a review of 36 studies, Hestbaek and colleagues reported that, after a first episode of low back pain, the proportion of patients who report recurrent episodes after 12 months was on average 62 %, and the percentage who had relapses of work absence was 33 % [42]. Pengel and colleagues showed that 73 % of patients had at least one recurrence within 12 months [71]. Return to work in the first month after an initial episode of LBP is high (82 % of those initially off work), and some further improvement appears in the subsequent 3 months. Thereafter levels for

pain, and disability, and return to work remain almost constant [71]. There is increasing evidence that non-specific back pain in adults shows a fluctuating, recurrent and intermittent course that may ultimately lead to a chronic phase [19]. The unstable and episodic nature of LBP and the uncertainty of onset of any episode make estimation of the incidence of LBP difficult. The figures of up to 36 % for the 12-month incidence may overestimate the "true" incidence of real first time episodes of pain [19].

## Neck Pain

Neck pain located by a mannequin drawing is most often defined as pain occurring in the area from the occiput to the third thoracic vertebra [21, 22]. Neck pain seems to be less common than low back pain, but there is limited epidemiological data on neck pain compared with low back pain [66]. Many studies examine shoulder pain together with neck pain, reporting prevalence numbers for **neck and shoulder disorders** (NSD) to be high in industrialized countries [66]. Recently Fejer and coworkers showed in their review of 56 epidemiological studies that neck pain is common in many areas of the world and numbers did not differ systematically with most definitions of neck pain (i.e. pain, ache, troublesome, soreness) [35]. However, numbers are higher when definitions like stiffness are used, and numbers are lower when neck pain of longer duration or high severity is assessed. Numbers did not differ systematically depending on whether the shoulder region was included or not, nor was the quality of studies systematically related to prevalence rates. Point prevalence rates ranged between 5.9 % and 22.2 % in adult populations with a mean point prevalence of 7.6 %. Mean week-prevalence was slightly higher (12.5 %), and increased with the period of time captured in prevalence data (23.3 % in 1-month prevalence, 29.8 % in 6-month prevalence, 37.2 % in 1-year prevalence, and 48.5 % in lifetime prevalence) [35].

Neck and shoulder pain are often associated

The so-called **whiplash associated disorder** denominates injury-related neck pain and subsequent associated disorders (see Chapter 30). It was first specifically defined as an **acceleration-deceleration injury** (usually related to accidents in vehicles), but later on the term whiplash syndrome was adopted for all types of neck injuries [66]; nonetheless, the causal link to trauma is not well documented. Although neck pain following trauma is common, few studies to date have included a control group in order to compare neck pain after injury with prevalence and incidence rates to be expected in the absence of a trauma [66]. According to Schrader and coworkers [82], the period prevalence of neck pain after trauma of around 35 % equaled the prevalence in a control group.

Whiplash associated disorders may result from cervical sprain (frequently rear-end collision)

Compared with low back pain, there is less knowledge about the incidence and course of neck pain. In the **Saskatchewan Health and Back Pain Survey**, a population-based cohort study of Saskatchewan adults, the incidences of neck pain and back pain were assessed [18, 19, 22]. The age and gender standardized annual incidence of neck pain was 14.6 % (back pain: 18.6 %). The annual rate of resolution of neck pain was 36.6 % (back pain: 26.8 %). Contrary to the popular belief of many clinicians, most individuals with neck pain do not experience complete resolution of their symptoms and disability.

Incidence and course of neck pain is less well documented compared with LBP

## Pain, Impairment and Disability

**Impairment** defines an abnormality in structure or functioning of the body that may include pain, and **disability** defines the reduction in the performance of activities. Because in non-specific spinal disorders the etiology is uncertain, the establishment of impairment in these disorders is often less clear-cut than that of

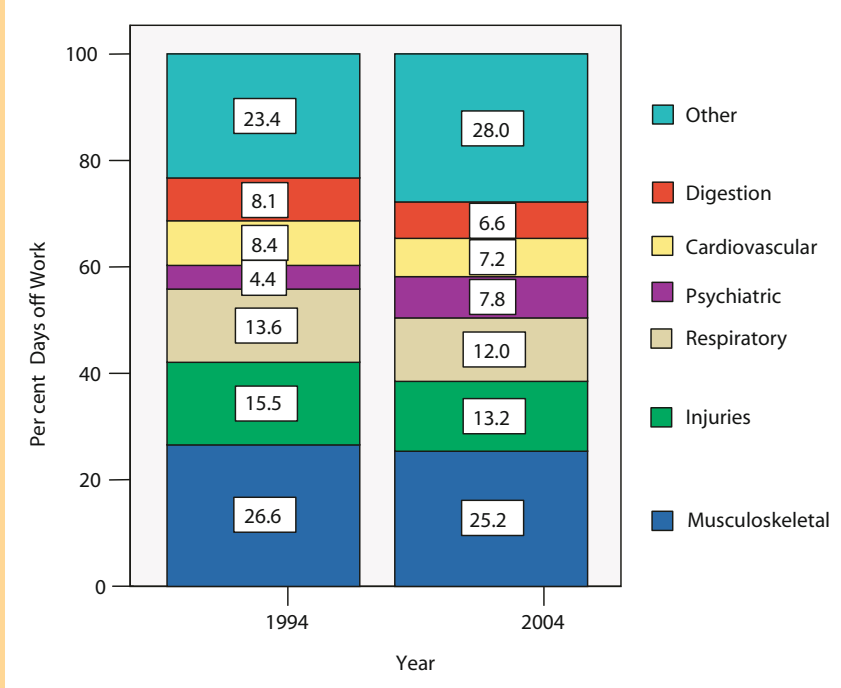


**Figure 1**

Work disability caused by disorders in Germany in 1994 and in 2004 [94]. Note: Within musculoskeletal disorders in 2004, the most frequent diagnosis was back pain ICD-10 M54 (7.7% days off work).

disability. Disability at work and in one's private life includes restrictions in the individual's major role and limitations in social and recreational activities. Individual functional losses include subcategories of functional capacity, such as mobility (part of the activities of daily living, transportation, leisure activities, sexual activities and other social role handicaps – occupation and household). It is also important to make a distinction between **pain** and **disability**. Pain and disability differ in their risk factors, prevalence and incidence, and they have developed very differently in their prevalence rates over time. An historical review [2] has indicated that people have always suffered from back pain, but back pain disability shows a trend for a steady increase over time. For example, Donald [27] reported a 208.5% increase in back pain disability in the UK between 1978 and 1992 compared with a 54.6% increase in other types of disability. In Germany, in 2003, musculoskeletal complaints (ICD XIII) caused 24.9% of days of work absence [94]. The mean number of absence days per LBP episode was among the highest (18.2 days), with only psychiatric disorders (ICD V) causing longer spells (28.5 days) [94]. In Germany and some other countries, however, the trend for an increase in absence days in recent decades has stopped and numbers seem to have leveled off [94].

Pain and disability must be differentiated

Disability causes great loss of productivity at home and at work, and the economic burden of chronic disability has become enormous in both the developing and industrialized countries [26].

Risk factors and obstacles to recovery potentially can differ for pain and disability

The Glasgow Illness Model is an operational clinical model of low back disability [99, 104] that includes physical, psychological, and social elements (Fig. 2). It assumes that most back and neck pain starts with a physical problem, which causes nociception, at least initially. Psychological distress may significantly amplify the subjective pain experience and lead to abnormal illness behavior.

**Figure 2**

Glasgow Illness Model of Disability [99]. This operational model of low back disability describes the development from a physical problem causing nociception to illness behavior and an alteration of the social role.

High levels of pain and illness behavior alter social function, and the individual may adopt a "sick role". A small minority of patients persist in the sick role, experiencing high levels of pain, even though the initial cause of nociception should have ceased and healing should have occurred.

## Burden of Spinal Disorders

Back pain related heath care utilization is common [55]. Musculoskeletal complaints account for about 10–20% of primary care visits and are the second most common reason for consulting a doctor [76].

Papageorgiou and Rigby [70] characterized the back pain related contact with medical services by applying a **one-in-five rule of thumb**: One in five of the population experience back pain at any one period of time; of these, one in five consult their GP; and one in five of those consulting are referred to a specialist. One in five of those attending outpatients are admitted to hospital, and one in five of those admitted undergo surgery for back pain.

Low back pain has a severe impact on the individual, families, and society

Musculoskeletal complaints are second only to respiratory disorders as a cause of short-term sick leave [87], and are the leading cause of long-term absence from work (>2 weeks) in many countries [11]. Furthermore, musculoskeletal complaints are among the leading causes of long-term disability [94, 102]. Individual disability includes subcategories of functional capacity, such as mobility (part of the activities of daily living, transportation, leisure activities, sexual activities and other social role handicaps – occupation and household). As such, non-specific back pain is often accompanied by psychological distress (depression or anxiety), impaired cognition and dysfunctional pain behavior.

## Economic Costs

The estimation of costs depends largely on the perspective that is chosen, such as the societal perspective, the patient's perspective, the health insurance perspective, the health care provider perspective or the perspective of companies. Whether results are comparable depends largely on the chosen perspective. Economic evaluations usually refer to a societal perspective. In that case, all relevant outcomes and costs are measured, regardless of who is responsible for the costs and who benefits from the effects. Since spinal disorders result in high costs to society, there have been an increasing number of economic evaluations. Van

**Table 2.** Direct costs of musculoskeletal disorders

| ICD 10 | Diagnosis | 1994 direct costs for treatment (%) | 1997 direct costs for treatment (billions DM) |
|---|---|---|---|
| XIII | Musculoskeletal disorders | 12.6 | 48.8 |
| X | Respiratory disorders | 5.2 | 20.1 |
| XIX | Injuries, poisonings | 7.8 | 30.2 |
| V | Psychiatric disorders | 10.9 | 42.2 |
| | Others | 63.5 | 245.7 |
| | Total | 100 | 387 |

Cost estimates according to Thiehoff [89]

**Table 3.** Lost work days and lost productivity due to musculoskeletal disorders in 2003

| ICD 10 | Diagnosis | Lost work days (millions) | % | Lost productivity (billions EUR) | In % GNP |
|---|---|---|---|---|---|
| XIII | Musculoskeletal disorders | 116.50 | 24.9 | 10.60 | 0.50 |
| X | Respiratory disorders | 66.05 | 14.1 | 6.01 | 0.28 |
| XIX | Injuries, poisonings | 61.04 | 13.0 | 5.55 | 0.26 |
| V | Psychiatric disorders | 45.54 | 9.7 | 4.14 | 0.20 |

According to Deutsches Bundesministerium für Wirtschaft und Arbeit (2003) Bericht der Bundesregierung: Sicherheit und Gesundheit bei der Arbeit. http://de.osha.eu.int/statistics

Roer, Boos and van Tulder recently gave an introduction to cost analysis [91]. The economic burden of spinal disorders includes:

- direct,
- indirect, and
- intangible costs

**Direct costs** concern medical expenditure, such as the cost of prevention, detection, treatment, rehabilitation, and long-term care. Direct costs of spinal disorders are estimated to be high. For instance back pain was estimated to cost the National Health Service in Britain £480 million in 1994 and accounted for £1.4 billion in social security costs [20].

The total costs of low back pain are enormous, and are predominantly caused by disability

**Indirect costs** consist of lost work output attributable to a reduced capacity for activity, and result from lost productivity, lost earnings, lost opportunities for family members, lost earnings of family members, and lost tax revenue. In Germany, musculoskeletal disorders are the most expensive form of work disability for companies and cause almost 27% of all production downtime due to sick leave from work. Estimates of direct and indirect annual costs of musculoskeletal disorders add up to approximately 24.5 billion euros for the labor force and approximately 38 billion euros for the total population [89]. However, working with spinal disorders produces additional loss as recently shown by Hagberg, Tornqvist, and Toomingas [37] in employees working at video display units. Participants in this study rated their loss in productivity due to musculoskeletal problems in the last month compared with the previous month. Among those with no sick leave in the last month, 6.1% of women and 8.3% of men reported a loss of productivity as a result of musculoskeletal disorders.

**Finally, intangible costs** are the most difficult to estimate. Intangible costs include psychosocial burdens resulting in reduced quality of life, such as job stress, economic stress, family stress, and suffering.

Reports dealing with direct and indirect costs from different countries have recently been reviewed and discussed [36, 56, 59].

The direct and indirect costs are considerable and their management utilizes a significant part of the gross national product of many countries. However, as

with prevalence rates, estimates of costs differ considerably due to the use of varying definitions and cost methodologies [59].

## Risk Factors

LBP is multifactorial in origin

In non-specific low back and neck pain there is no clear etiology; in these disorders, pain is a **symptom** rather than an illness. There are individual characteristics as well as conditions of work and lifestyle factors that relate to the reporting of symptoms. Four important points should be made here:

- Non-specific low back and neck pain cannot be understood when looking at single factors alone. **Multiple factors** are involved.
- Risk factors contribute differently with respect to predicting **development**, **persistence**, and **recurrence** of symptoms.
- Risk factors differ for **pain reporting**, **disability**, and **pain behavior**. In addition, risk factors differ for morphological alterations such as disc herniation and disc degeneration.
- The association of risk factors with non-specific low back and neck pain is **probabilistic** not deterministic, i.e. an individual showing a risk factor has an increased likelihood of developing symptoms in the future, but it is not inevitable, and the individual may instead remain symptom free.

Risk factors can be categorized into **several domains**:

- individual factors
- morphological factors
- general psychosocial factors
- occupational physical factors
- occupational psychological factors

### Individual Risk Factors

By far the most strongly predictive risk factor for neck pain and low back pain is **previous neck pain and low back pain** [41, 81]. Recent studies have indicated that some of the strongest predictors of disc degeneration and LBP are genetic factors [6, 69]. Research in adult monozygotic twins who differ in their history of work-related and other risk factors showed that a considerable amount of disc degeneration is due to heredity [6]. The **genetic influence** in disc degeneration was considerably higher than the influence of work-related factors, which were previously thought to be most strongly related to disc degeneration. The genetic influence on neck and back pain is less clear [34, 39] and seems to depend on age [39]. Genetic influences on back and neck pain might therefore be indirect via morphological factors, or via factors that influence the reporting of neck and back pain, i.e. there might be a genetically determined tendency for psychological distress, as was recently found in a study on adult female monozygotic and dizygotic twins [60]. Besides the influence of genetic factors on spine morphology, there are also various factors such as birth weight and smoking during pregnancy that can affect the development of the vertebral canal [49]. Other individual characteristics affecting **susceptibility to spinal disorders** include:

Age, gender, and body weight are established risk factors

- age > 50 years [100], most likely linked to pain via degenerative diseases
- gender, with females being more likely to report neck and back pain, and men being more likely to have a higher number of days absent from work [67, 94], and diagnosed hernia [67]
- obesity

- general health status and comorbidity
- smoking
- sedentary lifestyle [44]

Recent reviews show that the evidence for body weight, smoking and physical inactivity as risk factors is comparably small [81]. Among various individual characteristics of children (including gender, body height, body weight, trunk asymmetry, thoracic kyphosis and lumbar lordosis), it was shown that being female and having a short stature at 11 years of age predicted the incidence of neck pain [74].

Evidence is increasing that genetic factors are related to disorders that involve discs

With respect to physical activity during leisure time, there is not much evidence for a general association of sports and musculoskeletal symptoms, but a sedentary lifestyle is associated with a higher prevalence of LBP and sick leave [44]. There appears to be a weak positive association between increased body height and disc herniation. Obesity, regardless of height, is associated with disc degeneration and LBP [38, 45]. Low income and lower social class are risk factors, but analyses including multiple risk factors show more specific factors to be behind these categories [81].

## Morphological Risk Factors

Morphological factors are poorly correlated with pain

**Disc herniation** and **disc degeneration** are often present in asymptomatic individuals, a finding that confirms that low back pain symptoms, pathology and radiological findings are not strongly interrelated [8, 16, 30, 50]. Vertebral fractures are not necessarily related to pain [51]. In a recent review, van Tulder and coworkers reported that degeneration, defined by the presence of disc space narrowing, osteophytes, and sclerosis, *was* associated with non-specific low back pain, although the associations were only moderate [92]. **Spina bifida**, **transitional vertebrae**, **spondylosis** and **Scheuermann's disease** did not appear to be associated with low back pain [92]. Patients reporting back pain in spondylolysis and spondylolisthesis are often classified as having non-specific low back pain because a considerable proportion of patients with such anatomical abnormalities are asymptomatic [85, 92]. The anatomical incidence is about 5% [111].

Among patients reporting back pain, MRI findings of mild to moderate compression of spinal nerves, disc degeneration or bulging, and central stenosis were not found to correlate closely with the severity of symptoms [8, 48].

In one large epidemiological study, the one-year incidence of cervical radiculopathy was 83/100 000 [75]; the incidence of lumbar radiculopathy is probably much higher.

## Psychosocial Factors

In accordance with the Glasgow Illness Model, epidemiological research indicates that psychosocial factors are an integral part of the pain disability process. Evidence is increasing that psychosocial factors have more impact on low-back pain disability than do biomechanical factors [66].

Depression and anxiety are the best explored risk factors

There is strong evidence that psychosocial variables are associated with the reporting of back and neck pain [105]. Inappropriate attitudes and beliefs about back pain (for example, the belief that back pain is harmful or potentially severely disabling, or high expectations of passive treatments rather than a belief that active participation will help), inappropriate pain behavior (for example, fear-avoidance behavior and reduced activity levels), low work satisfaction, and emotional problems (such as depression, anxiety, stress, tendency to low mood and withdrawal from social interaction) are strongly linked to the transition from acute to chronic pain and disability [66, 93].

## Occupational Physical Risk Factors

Heavy physical work is associated with LBP

There is evidence that there is a moderate association between the incidence (onset) of back pain and heavy physical work [100]. With regard to disc herniation in males, higher incidence rates are found in the wholesale trade industry (10.7/10 000), manufacturing (8.9/10 000), and construction (8.4/10 000) than in the service sector (2.8/10 000) and finance and insurance (2.2/10 000) [67]. When national health statistics include the nature of injury or illness by major events or exposure, nearly 95 % of exposures labeled as "**overexertion**" and "**repetitive motion**" include musculoskeletal complaints [67]. Within private industry in the US, more than half of the cases of illness and injury that mention "overexertion" refer to frequent lifting. Cases filed in connection with overexertion and repetitive motion mostly refer to the region of the back (52 %) and upper extremities (26 %), but rarely to the neck [67]. Interestingly, although the proportion of people involved in heavy work has decreased in industrialized countries, there has been a concomitant increase in the number of people with work disability [99]. Furthermore, the rate of musculoskeletal disorders of the back is higher in many non-manufacturing industries than in manufacturing industries [67]. These discordant trends for heavy physical work and LBP disability suggest that while heavy work may be a contributory factor in the onset of non-specific back pain it is not a cause in many cases of work disability. There is some evidence, however, that the physical demands of work may influence the ease of return after an episode of pain [29].

**Physical risk factors** for the development of occupational back pain include:

- heavy physical work related to overexertion [39]
- manual materials handling including repetitive motion [39, 100, 101]
- twisting and bending [100, 101]
- frequent lifting [100, 101]
- awkward postures [100, 101]
- whole body vibration [57]

For the **cervical spine** the most consistently identified physical risk factors include [66]:

- exposure to repetitive movement of arms or neck and arm
- static load on the neck region
- segmental vibration exposure through hand-held tools
- rapid acceleration deceleration movements (whiplash)

## Occupational Psychological Risk Factors

Psychosocial work factors are associated with disability and return to work

There is increasing evidence that the work factors leading to chronic disability are more psychosocial than biomechanical [9]. Musculoskeletal disorders are closely connected with occupational health psychology not only via biomechanical and environmental strains, but also through occupational variables such as task related and social stressors, control at work, job satisfaction, and support from supervisors and coworkers. The evidence for psychosocial risk factors in back pain [46] and neck pain [4] has been the subject of recent reviews.

**Work-related psychosocial factors** associated with spinal disorders are [29]:

- a rapid work rate
- monotonous work
- low job satisfaction
- low social support
- low decision latitude
- job stress

The way an individual copes with work factors, and how people attribute symptoms as being related to work factors, also influences the course of the disorder, especially in relation to return to work after treatment [86].

## Absence of Evidence for Certain Risk Factors

Remember: Absence of evidence is not evidence of absence

Epidemiology contributes to the search for evidence for various risk factors in the development of LBP. However, also of importance is the **absence of evidence** for other factors. Non-evidence has now accumulated for various factors of importance to our understanding of the development, diagnosis and treatment of LBP:

- limited diagnostic and prognostic value of medical imaging in non-specific back pain [8, 10]
- no positive effect but negative effect of bed rest [25, 98, 103]
- no negative but positive effects of early return to work [17]
- LBP in children and adolescents more common than previously thought [88]
- no seasonal impact [43]

The contribution of medical imaging in predicting the development of future LBP in non-symptomatic individuals is limited [10]. Prolonged bed rest for sciatica is not beneficial [25, 98]. Bed rest may be instead a risk factor for poor recovery in acute LBP [103]. Early return to work after an episode of pain, and even return to work with a moderate level of prevailing pain, is not a risk factor for recurrent pain episodes but may in contrast be beneficial in preventing recurrent episodes [17]. For many years, LBP in children and adolescents was considered to be rare and an indication of serious disease [1]. More recent epidemiological studies have shown that the prevalence of non-specific LBP in children is high, reaching that of adults by the end of the growth period, and psychological factors such as beliefs about general health also seem to predict the first reports of pain episodes [88]. Contrary to widespread belief in practitioners and patients, the empirical evidence for seasonal variation in the prevalence of neck and back pain is minimal [43].

## Geographical Variation

The reporting of back and neck pain exhibits substantial geographical variations

Epidemiological knowledge about prevalence of neck and back pain in developing countries is relatively small. Recently Fejer, Kyvik, and Hartvigsen included 56 studies on prevalence rates in their study on neck pain in the world population [35]. Almost half the studies (46 %) were from Scandinavia, 23 % from the rest of Europe, 16 % from Asia, and 11 % from North America. Two papers were from Australia and one was from Israel. The mean one-year prevalence rates were higher in Scandinavian countries (36 %) compared with the rest of Europe (26 %) and Asia (13 %), but the differences were not statistically significant. Two studies from the Tokelau Islands (small islands in the South Pacific Ocean) reported lifetime prevalence rates for neck pain that were very low [109] or close to zero [110]. Violinn [95] also reported lower prevalence rates for low back pain in farmers living in Nigeria, southern China, Indonesia, and the Philippines. Of note was the finding that low back pain was more common among inhabitants of these countries who lived in cities. A recent comparison of chronic pain among 15 countries of the EU and Israel showed that self-reports of herniated or degenerated intervertebral discs were more common in Belgium, Austria, and Switzerland compared with Norway, Sweden, Finland and Denmark [13]. Prevalence rates also differ within countries, e.g. in the UK [106] and Germany [81]. Not surprisingly, the use of surgery for low back pain varies widely across regions and between counties [64]. In the United States there are reports of large regional differences in the like-

lihood of being offered spine surgery for a given disorder [7]. The interpretation of geographical data regarding prevalence rates always remains tentative because so many other differences between countries are left unconsidered. Therefore, Deyo characterized geographical comparison as a more "hypothesis generating" approach than "hypothesis testing" [24].

Unfortunately, important epidemiological data are not available for large areas of the world, and as such the natural course of non-specific spinal disorders and factors influencing their development and cost cannot be fully determined for these regions.

Some **important future research considerations** include the collection of:

- epidemiological data from different countries in a more uniform manner to facilitate comparative research and to render results comparable [96]
- more data sets in eastern Europe and the developing countries [95]

## Flag System for the Risk Factors

The Flag System is very useful for the assessment of risk factors

Consultation with a surgeon is recommended for conditions with "**red flags**". Red flags are symptoms and findings that may indicate tumor, fracture, infection, or cauda equinal compression. **Obstacles to recovery** and **return to work** (the so-called **yellow and blue flags**) are likely to involve more complex clinical and psychosocial issues, requiring more detailed, individual assessment [14, 15, 63]. Finally, black flags indicate factors that are the same for many individuals and relate to the social security and health care system of a country.

A distinction should be made, however, between individual perceived obstacles to return-to-work (**blue flags**) and organizational policies regarding sickness, over which the individual has no control [14, 61]. Dealing with obstacles should include work-focused interventions and individually adapted interventions to meet the needs of individual clients. Altogether, yellow, blue and black flags should contribute to:

- better screening of individuals at risk of developing a chronic problem
- better interventions to increase return to work
- prevention of recurrent episodes of disability

Flags are therefore included in occupational policy guidelines for the management of non-specific spinal disorders, particularly occupational LBP.

### Red Flags

Red flags are indicators of **serious spinal pathology** (e.g. cauda equina syndrome, which requires urgent surgical decompression). They represent potentially significant physiological risk factors for developing chronic LBP if not appropriately assessed. Red flags indicating neoplasm, infection, and cauda equina syndromes are extremely rare [16].

**Red flags** comprise:

- 🚩 thoracic pain
- 🚩 fever and unexplained weight loss
- 🚩 bladder and bowel dysfunction
- 🚩 history of carcinoma
- 🚩 ill health or presence of other medical illness
- 🚩 progressive neurological deficit
- 🚩 disturbed gait, saddle anesthesia

## Yellow Flags

Yellow, blue, and black "flags" address factors that should be taken into account to prevent long-term disability

Yellow flags are individual cognitive, emotional, and behavioral risk factors for developing chronic LBP, including individual attitudes and beliefs towards one's own LBP and its management [53, 58]. Yellow flags **indicate psychosocial obstacles to recovery**, and have been integrated into a systems approach for the management of acute and subacute LBP [53] that recognizes the importance of both clinical and occupational perspectives in the management of LBP at work. **Yellow flags** comprise:

- distress/depression (depression, anxiety, distress, and related emotions are related to pain and disability) [101]
- preexisting chronic pain, either in the back or elsewhere [84]
- fear-avoidance (attitudes, cognitive style, and fear-avoidance beliefs are related to the development of pain and disability) [63, 86]
- coping (passive coping is related to neck and back pain and disability) [65]
- pain cognitions (e.g. catastrophizing, which is related to pain and disability) [72]
- poor self-rated health (self-perceived poor health is related to chronic pain and disability and development of new chronic back pain [84])
- kinesiophobia [72]
- expectation of passive treatments(s) rather than a belief that active participation will help [100]

## Blue Flags

Research into occupational health has identified certain work characteristics, such as time pressure and low job satisfaction, that represent risk factors for the development of complaints [83] including LBP [31]. Blue flags are individually perceived occupational factors that impede recovery from prevailing non-specific musculoskeletal pain and disability and increase the risk of prolonged symptoms or recurrence of episodes [23, 29, 73, 101]. **Work-related psychosocial risk factors** include:

- high job demands (time pressure, uncertainty, frequent interruptions, etc.) [83]
- low job control (influence on methods and time, e.g. the ability to independently plan and organize one's own work, and influence on work pace and schedule, autonomy, decision latitude, participation in planning) [31]
- low or inadequate social support from supervisors and colleagues [33]
- low appreciation of efforts (income, social recognition, non-monetary rewards, career progression) [29]
- unfavorable team climate [29]
- low job satisfaction [29]
- attributing the cause of pain to work [86]
- being sceptical about the further management of work tasks and about return to work at all [29]

## Black Flags

Black flags relate to **occupational and societal factors** that are the same for many workers. These may initially lead to the onset of LBP ("occupational injury risk"), and may promote disability once the acute episode has occurred ("vocational education system", "sickness policy", "social benefit system", "compensation claims", "micro- and macroeconomic situation", "security obligations"). For instance, the influence of societal factors on work disability due to spinal disorders is shown in

comparing the prevalence of work disability in the former East and West Germany [81]. After unification, the western health and social benefit system was adopted in East Germany. In the first few years after unification, work disability was lower in East than in West Germany. However, the difference in prevalence rates between the two regions decreased continuously in subsequent years, and the figures for East Germany now approach those of West Germany [81].

**Black flags** are:

- adverse sickness policy [66]
- ongoing disability claim (results in little involvement in rehabilitation efforts) [5]
- disability compensation at the time of vocational rehabilitation (corresponds to less participation and poorer outcome) [28]
- unemployment (causes physical, psychological, and social effects that interact to aggravate pain and disability) [20, 90, 106]
- legal aspects and the insurance system (e.g. whiplash syndrome is not common in Lithuania, where insurance does not cover compensation for neck pain after traffic accidents) [82]

## Direction for Future Epidemiological Research

Improved classifications of spinal disorders are required that are standardized, reliable and valid

Studies should use more standardized classification procedures, which necessitates greater agreement on definitions, classification and staging [112]. In addition to a population based registry approach [79, 80], a greater standardization of the assessment of risk, treatment and outcomes [62, 94] and a more standardized costing methodology are also urgently needed, to help estimate the long-term economic consequences of treatment [59]. There is also a need to distinguish prognostic risk factor analyses with reference to "new", "persistent", and "recovered" courses of symptoms over time, as preliminary evidence shows differences between persistent and "new" chronic back pain in their predictors and associations [84]. Analysis of time-bound cumulative exposure to risk factors might allow new insights into the reversibility of developments [32]. Transition phases into and out of a "chronic pain status" should also be the focus of future research endeavors. Specific types of psychosocial risk variables may relate to distinct developmental time frames, implying that assessment and intervention need to reflect these variables [58]. In addressing such issues, epidemiology may help to screen those workers who are at risk of developing chronic, non-specific spinal disorders [102].

### Recapitulation

**General scope.** Epidemiology helps clinical decision-making by providing evidence-based information with respect to the classification of disorders, the **natural course of disease**, the **frequency** and **development** of the disease in a population, and the burden of costs.

**Classification.** Most spinal disorders are **non-specific** and within non-specific spinal disorders neck pain and low back pain are the most common symptoms. Non-specific neck pain and non-specific low back pain show high 1-year **prevalence rates**, and their **lifetime incidences** indicate that nearly everyone will experience neck and back pain at some time in their life. There are also **high recurrence rates**. It is the persistence of symptoms in some individuals that causes the **enormous costs** to society.

**Risk factors.** The etiology of non-specific spinal disorders is unclear. **Genetic factors** associated with the vulnerability of the intervertebral disc to de-

generative change seem to be involved. By far the best predictor of future back/neck pain episodes is previous back/neck pain. According to the **Glasgow Illness Model**, biological, psychological and sociological factors contribute to the persistence and recurrence of disability. Epidemiological evidence shows that psychological, sociological, and health policy factors are more strongly related to chronic pain and disability than are morphological factors and biomechanical load.

**Flag system for risk factors.** Epidemiological knowledge of risk factors provides the foundation for the flag categorization approach, and this should contribute to better screening of those at risk of long-term disability. Among other yellow flags, **inappropriate beliefs** – such as the belief that back pain is due to (progressive) pathology, that back pain is harmful or disabling, that activity avoidance will aid recovery, and that passive treatments rather than active self-management will help – play a major role in the **persistence of disability**.

## Key Articles

**Breivik H, Collett B, Ventafridda V, Cohen R, Gallacher D (2006) Survey of chronic pain in Europe: Prevalence, impact of daily life, and treatment. Eur J Pain 10:287 – 333**
This article provides recent (2003) estimates of the prevalence of pain in 15 European countries and Israel.

**Brauer C, Thomsen JF, Loft IP, Mikkelsen S (2003) Can we rely on retrospective pain assessments? Am J Epidemiol 2003 157:552 – 557**
Recall bias in the assessment of pain can have a critical influence on estimates of the prevalence and incidence of spinal disorders. This paper describes an empirical approach to the problem in which 12 consecutive weekly pain recordings were compared with the final retrospective judgment of the 3-month period. The results showed that workers were able to accurately recall and rate the severity of pain or discomfort for a period of 3 months.

**Carragee EJ (2005) Clinical practice. Persistent low back pain. N Engl J Med 352(18): 1891 – 1898**
This excellent overview article begins with a case vignette highlighting a common clinical problem and presents current knowledge on persistent low back pain from a clinical point of view.

**Nachemson AL, Waddell G, Norlund AI (2000) Epidemiology of neck and low back pain. In: Nachemson AL, Jonsson E (2000) Neck and back pain. Philadelphia: Williams & Wilkins, pp 165 – 188**
This chapter summarizes current evidence from the view of some of the most revered researchers in the field.

**Raspe H (2002) How epidemiology contributes to the management of spinal disorders. Best Practice Res Clin Rheumatol 18:9 – 21**
A carefully written overview with special reference to a research agenda of topics that are most important to address in further research.

**WHO Scientific Group (2003) The Burden of Musculoskeletal Conditions at the Start of the New Millennium. WHO Technical Report Series, 919.** http://www.emro.who.int/ncd/publications/musculoskeletalconditions.pdf
Over the last couple of years, a WHO scientific group of experts has been working in collaboration with the Bone and Joint Decade 2000 – 2010 to map out the burden of the most prominent musculoskeletal conditions. The long-term aim of the work is to help prepare nations for the impending increase in disability brought about by such conditions. The group has gathered data on the incidence and prevalence of spinal disorders and considered the severity and course of spinal disorders, along with their economic impact. The group has also made suggestions for a more standardized approach in the measurement of pain, disability, etc.

**Waddell G, Burton AK (2001) Occupational health guidelines for the management of low back pain at work: evidence review. Occup Med 51:124 – 35**
The article is probably the best evidence-based review of occupational LBP and continuous updates are planned.

## References


1. Afshani E, Kuhn JP (1991) Common causes of low back pain in children. Radiographics 11:269 – 91
2. Allan D, Waddell G (1989) An historical perspective on low back pain and disability. Acta Orthopaedica Scandinavica. Supplementum 234:1 – 23
3. Andersson GBJ (1998) Epidemiology of the low back pain. Acta Ortho Scand 69:Suppl 281 28 – 31
4. Ariëns GAM, van Mechelen W, Bongers PM, Bouter LM, van der Wal G (2001) Psychosocial risk factors for neck pain: A systematic review. Am J Ind Med 39:180 – 194
5. Atlas SJ, Wasiak R, van den Ancker M, Webster B, Pransky G (2004) Primary care involvement and outcomes of care in patients with a workers' compensation claim for back pain. Spine 29:1041 – 1048
6. Battie MC, Videman T, Parent E (2004) Lumbar disc degeneration: Epidemiology and genetic influences. Spine 29:2679 – 90
7. Birkmeyer NJ, Weinstein JN (1999) Medical versus surgical treatment for low back pain: evidence and clinical practice. Eff Clin Pract 2:218 – 27
8. Boden SD, Davis DO, Dina TS, Patronas NJ, Wiesel SW (1990) Abnormal magnetic-resonance scans of the lumbar spine in asymptomatic subjects. A prospective investigation. J Bone Joint Surg Am 72(3):403 – 8
9. Bongers, PM, de Winter CR, Kompier MAJ, Hildebrandt VH (1993) Psychosocial factors at work and musculoskeletal disease. Scand J Work Environ Health 19:297 – 312
10. Boos N, Semmer NK, Elfering A, Schade V, Gal I, Zanetti M, Kissling R, Buchegger N, Hodler J, Main C (2000) Natural history of individuals with asymptomatic disc abnormalities in magnetic resonance imaging: Predictors of low back pain-related medical consultation and work incapacity. Spine 25:1484 – 92
11. Brage S, Nygard JF, Tellnes G (1998) The gender gap in musculoskeletal-related long-term sickness absence in Norway. Scand J Soc Med 26:34 – 43
12. Brauer C, Thomsen JF, Loft IP, Mikkelsen S (2003) Can we rely on retrospective pain assessments? Am J Epidemiol 157:552 – 557
13. Breivik H, Collett B, Ventafridda V, Cohen R, Gallacher D (2006) Survey of chronic pain in Europe: Prevalence, impact of daily life, and treatment. Eur J Pain 10:287 – 333
14. Burton AK, Main CJ (2000) Obstacles to recovery from work-related musculoskeletal disorders. In: Karwowski W, ed. International encyclopedia of ergonomics and human factors. London: Taylor & Francis, 1542 – 44
15. Carragee EJ (2005) Clinical practice. Persistent low back pain. N Engl J Med 352(18): 1891 – 1898
16. Carragee EJ, Hannibal M (2004) Diagnostic evaluation of low back pain. Orthop Clin North Am 35(1):7 – 16
17. Carter JT, Birrell LN (2000) Occupational health guidelines for the management of low back pain at work – principal recommendations. London: Faculty of Occupational Medicine
18. Cassidy JD, Carroll LJ, Cote P (1998) The Saskatchewan health and back survey. The prevalence of low back pain and related disability in Saskatchewan adults. Spine 23:1860 – 1867
19. Cassidy JD, Cote P, Carroll LJ, Kristman V (2005) Incidence and course of low back pain episodes in the general population. Spine 30:2817 – 2823
20. Clinical Standards Advisory Group (CSAG) (1994) Back pain. London: HMSO
21. Cote P, Cassidy JD, Carroll L (1998) The Saskatchewan Health and Back Pain Survey. The prevalence of neck pain and related disability in Saskatchewan adults. Spine 23:1689 – 98
22. Cote P, Cassidy JD, Carroll LJ, Kristman V (2004) The annual incidence and course of neck pain in the general population: a population-based cohort study. Pain 112:267 – 73
23. Cox T, Randall R, Griffiths A (2002) Interventions to control stress at work in hospital staff. CRR 435: HSE Books
24. Deyo, RA (1997) Point of view: The epidemiology of low back pain in the rest of the world: A review of surveys in low- and middle-income countries. Spine 22:1754
25. Deyo RA, Diehl AK, Rosenthal M (1986) How many days of bed rest for acute low back pain? A randomized clinical trial. NEJM 315:1064 – 70

26. Deyo RA, Weinstein JN (2001) Low back pain. NEJM 344:363 – 70
27. Donald SM (2000) Rehabilitation of low back pain. CPD Rheumatology 1104 – 112
28. Drew DMA, Drebing CE, Van Ormer A, Losardo MSPA, Krebs C, Penk W, Rosenheck RA (2001) Effects of disability compensation on participation in and outcomes of vocational rehabilitation. Psychiatric Services 52:1479 – 1484
29. Elfering A (2006) Work-related outcome assessment instruments. Eur Spine J 15:S32–S43
30. Elfering A, Semmer NK, Birkhofer D, Zannetti M, Hodler J, Boos N (2002) Risk factors for lumbar disc degeneration: A five-year prospective MR study in asymptomatic individuals. Spine 27:125 – 134
31. Elfering A, Grebner S, Semmer NK, Gerber H (2002) Time control, catecholamines, and back pain among young nurses. Scand J Work Environ Health 28:386 – 93
32. Elfering A, Semmer NK, Kälin W (2004) Beyond risk factor intensity: Length of risk factor exposure in prognostic studies. Paper presented at Annual SSE Meeting Porto, Portugal, May 30–June 4
33. Elfering A, Semmer NK, Schade V, Grund S, Boos N (2002) Supportive colleague, unsupportive supervisor: The role of provider-specific constellations of social support at work in the development of low back pain. J Occup Health Psychol 7:130 – 40
34. Fejer R, Hartvigsen J, Kyvik KO (2006) Heritability of neck pain: A population-based study of 33 794 Danish twins. Rheumatology (Oxford) 45:589 – 94
35. Fejer R, Kyvik KO, Hartvigsen J (2006) The prevalence of neck pain in the world population: a systematic critical review of the literature. Eur Spine J 15:834 – 48
36. Göbel H (2001) Epidemiologie und Kosten chronischer Schmerzen. Spezifische und unspezifische Rückenschmerzen. Schmerz 15:92 – 98
37. Hagberg M, Tornqvist EW, Toomingas A (2002) Self-reported reduced productivity due to musculoskeletal symptoms: Associations with workplace and individual factors among white-collar computer users. J Occup Rehabil 12:151 – 62
38. Hartvigsen J, Frederiksen H, Christensen K (2006) Back and neck pain in seniors – prevalence and impact. Eur Spine J 15:802 – 6
39. Hestbaek L, Iachine IA, Leboeuf-Yde C, Kyvik KO, Manniche C (2004) Heredity of low back pain in a young population: A classical twin study. Twin Research 7:16 – 26
40. Heliövaara M, Impivaara O, Sievers K et al. (1987) Lumbar disc syndrome in Finland. J Epidemiol Commun Health 41:251 – 258
41. Hellsing AL, Bryngelsson IL (2000) Predictors of musculoskeletal pain in men. A twenty-year follow-up from examination at enlistment. Spine 23:3080 – 86
42. Hestbaek L, Leboeuf-Yde C, Manniche C (2003) Low back pain: what is the longterm course? A review of studies of general patient populations. Eur Spine J 12(2):149 – 65
43. Hildebrandt VH, Bongers PM, van Dijk FJM, Kemper HCG, Dul J (2002) The influence of climatic factors on non-specific back and neck-shoulder disease. Ergonomics 45:32 – 48
44. Hildebrandt VH, Bongers PM, Dul J, van Dijk FJH, Kemper HCG (2000) The relationship between leisure time, physical activities and musculoskeletal symptoms and disability in worker populations. Int Arch Occup Environ Health 73:507 – 18
45. Hildebrandt J, Ursin H, Mannion AF, Airaksinen O, Brox JI, Cedraschi C, Klaber-Moffett J, Kovacs F, Reis S, Staal B, Zanoli G, Broos L, Jensen I, Krismer M, Leboeuf-Yde C, Niebling W, Vlaeyen JW (2005) European guidelines for the management of chronic non-specific low back pain. European Co-operation in the field of Scientific and Technical Research (COST). Available at: http://www.backpaineurope.org/web/files/WG2_Guidelines.pdf.
46. Hoogendoorn WE, van Poppel MNM, Bongers PM, Koes BW, Bouter LM (2000) Psychosocial factors at work and in the personal situation as risk for back pain. Spine 25:2114 – 2125
47. International Association for the Study of Pain (1986) Classification of chronic pain. Pain 3(Suppl):1 – 225
48. Jarvik JJ, Hollingworth W, Heagerty P, Haynor DR, Deyo RA (2001) The Longitudinal Assessment of Imaging and Disability of the Back (LAIDBack) Study: baseline data. Spine 26(10):1158 – 66
49. Jeffrey JE, Campbell DM, Golden MHN, Smith FW, Porter RW (2003) Antenatal factors in the development of the lumbar vertebral canal: A magnetic resonance imaging study. Spine 28:1418 – 1423
50. Jensen MC, Brant-Zawadzki MN, Obuchowski N, Modic MT, Malkasian D, Ross JS (1994) Magnetic resonance imaging of the lumbar spine in people without back pain. N Engl J Med 331(2):69 – 73
51. Kado DM, Duong T, Stone KL, Ensrud KE, Nevitt MC, Greendale GA, Cummings SR (2003) Incident vertebral fractures and mortality in older women: a prospective study. Osteoporos Int 14:589 – 94
52. Keel P (2001) Low back pain and foreign workers: Does culture play an important role? In: Yilmaz AT, Weiss MG, Riecher-Rössler A eds. Cultural Psychiatry: Euro-International Perspectives. Bib Psychiatr Basel: Karger, 117 – 25
53. Kendall NAS, Linton SJ, Main CJ (1997) Guide to assessing psychosocial yellow flags in acute low back pain: risk factors for long term disability and work loss. Wellington: Accident

Rehabilitation and Compensation Insurance Corporation of New Zealand and the National Health Committee
54. Kuorinka I, Jonsson B, Kilbom Å, Vinterberg H, Biering-Sorensen F, Andersson G, Jorgensen K (1987) Standardised Nordic questionnaires for the analysis of musculoskeletal symptoms. Appl Ergon 18:233 – 273
55. Lim K-L, Jacobs P, Klarenbach S (2006) A population-based analysis of healthcare utilization of persons with back disorders. Spine 31:212 – 218
56. Lindgren B (1998) The economic impact of musculoskeletal disorders. Acta Orthopaedica Scandinavica Suppl 281:58 – 60
57. Lings S, Leboeuf-Yde C (2000) Whole body vibration and low back pain: a systematic, critical review of the epidemiological literature 1992 – 1999. Int Arch Occup Environ Health 73:290 – 97
58. Linton S (2000) A review of psychological risk factors in back and neck pain. Spine 25:1148 – 56
59. Maetzel A, Li L (2002) The economic burden of low back pain: a review of studies published between 1996 and 2001. Best Practice & Research Clinical Rheumatology 16:23 – 30
60. MacGregor AJ, Andrew T, Sambrook PN, Spector TD (2004) Structural, psychological, and genetic influences on low back and neck pain: A study of adult female twins. Arthritis & Rheumatism 51:160 – 167
61. Main CJ, Spanswick CC (2000) Pain management: An interdisciplinary approach. Edinburgh: Churchill Livingstone
62. Mannion AF, Elfering A, Staerkle R, Junge A, Grob D, Semmer NK, Jacobshagen N, Dvorak J, Boos N (2005) Outcome assessment in low back pain: how low can you go? Eur Spine J 14:1014 – 1026
63. Marhold C, Linton SJ, Melin L (2002) Identification of obstacles for chronic pain patients to return to work: evaluation of a questionnaire. J Occup Rehabil 12:65 – 75
64. McIntosh G, Hall M, Melles T (1998) The incidence of spinal surgery in Canada. Can J Surh 41:59 – 66
65. Mercado AC, Carroll LJ, Cassidy JD, Côte P (2005) Passive coping as a risk factor for disabling neck or low back pain. Pain 117:51 – 57
66. Nachemson AL, Jonsson E (2000) Neck and back pain. Philadelphia: Williams & Wilkins
67. NIOSH 2001. Look at data from the Bureau of Labor statistics worker health by industry and occupation: musculoskeletal disorders, anxiety, disorders, dermatitis, hernia. US Department of Health and Human Services, the Center for Disease Control and Prevention. Available at http://www.cdc.gov/niosh/pdfs/2001 – 120.pdf
68. Ozguler A, Leclerc A, Landre MF, Pietri-Taleb F, Niedhammer I (2000) Individual and occupational determinants of low back pain according to various definitions of low back pain. J Epidemiol Community Health 54:215 – 220
69. Paassilta P, Lohiniva J, Göring HHH, Perälä M, Räinä SS, Karppinen J, Hakala M, Palm T, Kröger H, Kaitila I, Vanharanta H, Ott J, Ala-Kokko L (2001) Identification of a novel common genetic risk factor for lumbar disk disease. JAMA 285:1843 – 9
70. Papageorgiou AC, Rigby AS (1991) Review of UK data on the rheumatic diseases – 7. Low back pain. Br J Rheumatol 30:50 – 53
71. Pengel LH, Herbert RD, Maher CG, Refshauge KM (2003) Acute low back pain: systematic review of its prognosis. BMJ 327(7410):323
72. Picavet HSJ, Vlaeyen JWS, Schouten JSAG (2002) Pain catastrophizing and kinesiophobia: Predictors of chronic low back pain. Am J Epidemiol 156:1028 – 34
73. Pincus T, Burton AK, Vogel S, Field AP (2002) A systematic review of psychological factors as predictors of chronicity/disability in prospective cohorts of low back pain. Spine 27:E109 – 20
74. Poussa MS, Heliovaara MM, Seitsamo JT, Kononen MH, Hurmerinta KA, Nissinen MJ (2005) Anthropometric measurements and growth as predictors of low-back pain: a cohort study of children followed up from the age of 11 to 22 years. Eur Spine J 14:595 – 598
75. Radhakrishnan K, Litchy WJ, O'Fallon WM, Kurland LT (1994) Epidemiology of cervical radiculopathy. A population-based study from Rochester, Minnesota, 1976 through 1990. Brain 117(2):325 – 35
76. Rasker JJ (1995) Rheumatology in general practice. Br J Gen Pract 34:494 – 7
77. Raspe H (2002) How epidemiology contributes to the management of spinal disorders. Best Practice Res Clin Rheumatol 18:9 – 21
78. Raspe H (2001) Back pain. In: Silman A, Hochberg A (eds) Epidemiology of the rheumatic diseases. Oxford University Press, Oxford, 309 – 338
79. Röder C, Chavanne A, Mannion AF, Grob D, Aebi M (2005) SSE Spine Tango – content, workflow, set-up. Eur Spine J 14:920 – 924
80. Röder C, Müller U, Aebi M (2006) The rationale for a spine registry. Eur Spine J 15:S52–S56
81. Schmidt CO, Kohlmann T (2005) What do we know about back pain? Epidemiological results on prevalence, incidence, course, and risk factors. Z Orthop 143:292 – 298
82. Schrader H, Obeline D, Bovim G et al. (1996) Natural evolution of late whiplash syndrome outside the medicolegal context. Lancet 347:1207 – 1211

83. Semmer NK, Zapf D, Dunckel H (1995) Assessing stress at work: a framework and an instrument. In: Svane O, Johansen C (eds) Work and health – scientific basis of progress in the working environment. Office for Official Publications of the European Communities, Luxembourg, pp 105 – 113
84. Smith BH, Elliott AM, Hannaford PC, Chambers WA, Smith WC (2004) Factors related to the onset and persistence of chronic back pain in the community: results from a general population follow-up study. Spine 29:1032 – 40
85. Soler T, Calderon C (2000) The prevalence of spondylolysis in the Spanish elite athlete. Am J Sports Med 28(1):57 – 62
86. Staerkle R, Mannion A, Elfering A, Junge A, Semmer NK, Jacobshagen N, Grob D, Dvorak J, Boos N (2004) Longitudinal validation of the Fear-Avoidance Beliefs Questionnaire (FABQ) in a Swiss-German sample of low back pain. Eur Spine J 13:332 – 40
87. Stansfeld SA, North FM, White I, Marmot MG (1995) Work characteristics and psychiatric disorder in civil servants in London. J Epidemiol Community Health 49:48 – 53
88. Szpalski M, Gunzburg R, Balague F, Nordin M, Melot C (2002) A 2-year prospective longitudinal study on low back pain in primary school children. Eur Spine J 11:459 – 64
89. Thiehoff R (2002) Economic significance of work disability caused by musculoskeletal disorders. Orthopäde 31:949 – 56
90. Underwood MR (1998) Crisis: What crisis? Eur Spine J 7:2 – 5
91. van der Roer N, Boos N, van Tulder MW (2006) Economic evaluations: a new avenue of outcome assessment in spinal disorders. Eur Spine J 15:S109–S117
92. van Tulder MW, Assendelft WJ, Koes BW, Bouter LM (1997) Spinal radiographic findings and nonspecific low back pain. A systematic review of observational studies. Spine 22: 427 – 34
93. van Tulder MW, Becker A, Bekkering T, Breen A, Gil del Real MT, Hutchinson A, Koes BW, Laerum E, Malmivaara A, Nachemson AL, Niehus W, Roux E, Rozenberg S (2005) European guidelines for the management of acute nonspecific low back pain in primary care. European Co-operation in the field of Scientific and Technical Research (COST). Available at: http://www.backpaineurope.org/web/files/WG1_Guidelines.pdf. Accessed February 25, 2006
94. Vetter C, Kuesgens I, Bonkass F (2006) Krankheitsbedingte Fehlzeiten in der deutschen Wirtschaft. In: Badura B, Schellschmidt H, Vetter C (eds) Fehlzeiten-Report 2005 Arbeitsplatzunsicherheit und Gesundheit Zahlen, Daten, Analysen aus allen Branchen der Wirtschaft. Springer, Berlin Heidelberg New York, pp 243 – 458
95. Volinn E (1997) The epidemiology of low back pain in the rest of the world: A review of surveys in low- and middle-income countries. Spine 22:1747 – 54
96. Von Korff M (2001) Epidemiologic and survey methods. In: Turk DC, Melzack R, eds. Handbook of pain assessment. New York: Guilford Press, 603 – 18
97. Von Korff M, Ormel J, Keefe F, Dworkin SF (1992) Grading the severity of chronic pain. Pain 50:133 – 149
98. Vroomen PCAJ, de Krom MCTFM, Wilmink JT, Kester ADM, Knottnerus JA (1999) Lack of effectiveness of bed rest for sciatica. N Engl J Med 340:418 – 423
99. Waddell G (1987) 1987 Volvo award in clinical sciences. A new clinical model for the treatment of low-back pain. Spine 12:632 – 44
100. Waddell G, Burton AK (2000) Occupational Health Guidelines for the Management of Low Back Pain at Work – Evidence Review. London: Faculty of Occupational Medicine
101. Waddell G, Burton AK (2001) Occupational health guidelines for the management of low back pain at work: evidence review. Occup Med 51:124 – 35
102. Waddell G, Burton AK, Main CJ (2003) Screening to identify people at risk of long-term incapacity for work. A Conceptual and Scientific Review. London: Royal Society of Medicine Press
103. Waddell G, Feder G, Lewis M (1997) Systematic reviews of bed rest and advice to stay active for acute low back pain. Br J Gen Pract 47:647 – 52
104. Waddell G, Main CJ, Morris EW (1984) Chronic low back pain, psychological distress and illness behavior. Spine 9:209 – 213
105. Waddell G, Waddell H (2000) A review of social influences on neck and back pain and disability. In: Nachemson A, Jonsson E, eds. Neck and back pain: The scientific evidence of causes, diagnosis and treatment. Philadelphia: Lippincott, Williams & Wilkins, 13 – 55
106. Walsh K, Cruddas M, Coggan D (1992) Low back pain in eight areas of Britain. J Epidemiol Community Health 46:227 – 230
107. Wasiak R, Kim JY, Pransky G (2006) Work disability and costs caused by recurrence of low back pain: longer and more costly than in first episodes. Spine 31:219 – 225
108. Watson PJ, Main CJ, Waddell G, Gales TF, Percell-Jones G (1998) Medically certified work loss, recurrence and costs of wage compensation for back pain: A follow-up study on the working population of Jersey. Br J Rheum 37:82 – 6
109. Wigley RD, Prior IA, Salmond C, Stanley D, Pinfold B (1987) Rheumatic complaints in Tokelau. I. Migrants resident in New Zealand. The Tokelau Island migrant study. Rheumatol Int 7:53 – 59

110. Wigley RD, Prior IA, Salmond C, Stanley D, Pinfold B (1987) Rheumatic complaints in Tokelau. II. A comparison of migrants in New Zealand and non-migrants. The Tokelau Island migrant study. Rheumatol Int 7:61–65
111. Wiltse LL, Newman PH, Macnab I (1976) Classification of spondylosis and spondylolisthesis. Clin Orthop 117:23–9
112. World Health Organization (2003) The burden of musculoskeletal conditions at the start of the new millennium. Report of a WHO scientific group. WHO Technical Report Series Number 919

# 7 Predictors of Surgical Outcome

Anne F. Mannion, Achim Elfering

## Core Messages

- ✔ A substantial proportion (20–40%) of patients will have a poor outcome regardless of the technical success of the surgical procedure
- ✔ The proportion of "successful" patients, as well as the factors that determine a good outcome, depends on how success is defined
- ✔ Outcomes tend to be less good for contentious indications (e.g. chronic low back pain, instability)
- ✔ The most robust information on predictors of outcome is delivered by prospective studies in which a large number of patients and many putative risk factors are examined
- ✔ Consistent risk factors for a poor outcome include: a long duration of symptoms; severity of morphological alteration (for disc herniation) comorbidity; psychological distress (especially in chronic pain); social support encouraging passive behavior (especially in chronic pain); smoking (especially for fusion); job dissatisfaction; worker's compensation; long-term sick-leave
- ✔ Risk factors should be assessed before surgery and modified to improve the likely outcome and/or discussed with the patient to set realistic expectations
- ✔ The accurate identification of a surgically treatable lesion is instrumental in determining outcome

## Epidemiology

A not inconsiderable proportion of patients operated on for spinal disorders will have a **poor result** (Table 1), regardless of the apparent technical success of the operative procedure itself. In a large randomized controlled trial of fusion methods for chronic low back pain (posterolateral vs posterolateral with screws and internal fixation vs posterolateral with screws and interbody fusion), the proportions of patients achieving solid fusion were 72%, 87% and 91% in each group respectively; however, these were unrelated to the patients' ratings of global outcome and changes in pain and function, which were highly comparable between the groups [25]. **Patient-orientated** and **radiological outcomes** were similarly uncorrelated in a large study of the long-term results of patients undergoing posterior spondylodesis for spondylolysis and spondylolisthesis [52]. In a study of 78 patients with adolescent idiopathic scoliosis who had undergone surgery with Harrington instrumentation 20 years previously, the overall long-term clinical outcome (assessed with the Scoliosis Research Society questionnaire) showed no correlation with the radiological outcome [39]. Finally, in a large follow-up study of patients with lumbar spinal stenosis, successful or unsuccessful surgical decompression (judged by the postoperative observation of stenosis on CT) did not correlate with patients' subjective disability, walking capacity or severity of pain [40].

Clinical outcome poorly correlates with the radiological result

**Table 1.** Summary of recent prospective studies of predictors of outcome of spinal surgery, grouped according to outcome measure used (global score, back function, pain, return to work). See text for details

| Reference | L/C | Surgery, indication | No. pts. | FU | Outcome | | Demographic/ biological | | | | Work variables | | | | | | | Psychosocial | | | | | | Medical | | | | | | R2 |
|---|---|---|---|---|---|---|---|---|---|---|---|---|---|---|---|---|---|---|---|---|---|---|---|---|---|---|---|---|---|---|
| | | | | | | | More aged | Male gender | Smoking | High BMI/weight | Low income | Low education | Low job level | Worker's comp./ disability | Heavy job | Long sick leave/ unemployment | Job satis./stress/ resignation | MMPI scales | Depression/psych. distress | Family reinforcement | Pain drawings/ pain behavior/ somatic sympt. | Coping strategies | Neuroticism | No. affected levels | Long duration symptoms | Severity, clinical | Severity, imaging | Comorbidity/self-rated low health | Previous ops. | % Variance accounted for |
| Block et al. 2001 [6] | L | laminect./discect.; fusion (cLBP) | 204/259 | >6 mo | global score† | 24% good, 42% fair | | | | – | | | | – | – | | | – | | – | | – | | | | | | | | – |
| Carragee et al. 2003 [12] | L | discectomy, herniation | 180/187 | >2 y | global score# (& function, reop. rate) | mean 73% improvement | 0 | 0 | | | | | | – | 0 | 0 | | | | | | | | | 0 | | + | | | – |
| Junge et al. 1995 [45] | L | disc surgery (herniation/ other) | 328/381 | 1 y | global score (SC*) | 52% good | 0 | 0 | | | | | – | – | | – | | | 0 | – | 0 | | | | – | mix | 0 | | | |
| Kohlboeck et al. 2004 [50] | L | discectomy, herniation | 48/58 | 6 mo | global score§ | 56% good | | | | | | | | | | | | | – | | | 0 | | | | + | | | | – |
| Nygaard et al. 2000 [68] | L | microdiscectomy, herniation | 132 | 1 y | global score° | – | 0 | 0 | | | | | | | | – | | | | | | | | | – | | | | | 21% |
| Hagg et al. 2003 [38] | L | fusion, degen. cLBP | 201/232 | 2 y | global category | 63% improved | 0 | 0 | 0 | | | | | 0 | 0 | 0 | | 0 | 0 | | 0 | | – | 0 | 0 | 0 | mix | 0 | | – |
| Schade et al. 1999 [73] | L | discectomy, herniation | 42/46 | 2 y | global score (SC*) | 74% exc./ good | | | | 0 | | | | | | | 0 | | – | 0 | | | | | 0 | 0 | + | | | 58% |
| Spratt et al. 2004 [76] | L | decompression, stenosis | 36/40 | 1 y | global score‡ | 58% successful | | | | | | | | | | | | | | | – | | | 0 | | | | 0 | | – |
| Carragee and Kim 1997 [13] | L | discectomy, herniation | 48/51 | >2 y | global score# | 75% exc./ good | 0 | + | 0 | 0 | | | | – | | | | | | | | | | | 0 | 0 | + | – | | 75% |
| Hagg 2003a, b [37, 38] | L | fusion, cLBP | 201/232 | 2 y | function (ODI) | 25% improvement | 0 | 0 | 0 | | | | | 0 | 0 | 0 | | – | 0 | | – | | – | 0 | 0 | 0 | mix | 0 | | – |
| McGregor and Hughes 2002 [63, 64] | L | decompression, stenosis | 65/84 | 1 y | function (ODI) | 20% improvement | 0 | 0 | 0 | | | | | | | | | | | | | | | | 0 | | | | 0 | 11–50% |
| Ng and Sell 2004 [66] | L | discectomy, herniated disc | 103/113 | 1 y | function (ODI) | 77% clin. rel. improvement | | | 0 | | | | | | | 0 | | | | | | | | | – | | + | | | – |
| Peolsson et al. 2003 [71] | C | decompression & fusion, degen. cNP | 74/103 | >12 mo | function (NDI) | 30% NDI score 20% | 0 | 0 | – | | | | | | | | | | | | | | | | | mix | 0 | | | 23% |

**Table 1.** (*Cont.*)

| Reference | L/C | Surgery, indication | No. pts. | FU | Outcome | | Demographic/ biological | | | | Work variables | | | | | | | Psychosocial | | | | | | Medical | | | | | | R2 |
|---|---|---|---|---|---|---|---|---|---|---|---|---|---|---|---|---|---|---|---|---|---|---|---|---|---|---|---|---|---|---|
| | | | | | | | More aged | Male gender | Smoking | High BMI/weight | Low income | Low education | Low job level | Worker's comp./ disability | Heavy job | Long sick leave/ unemployment | Job satis./stress/ resignation | MMPI scales | Depression/psych. distress | Family reinforcement | Pain drawings/ pain behavior/ somatic sympt. | Coping strategies | Neuroticism | No. affected levels | Long duration symptoms | Severity, clinical | Severity, imaging | Comorbidity/self-rated low health | Previous ops. | % Variance accounted for |
| Schade et al. 1999 [73] | L | discectomy, herniation | 42/46 | 2 y | function (RM) | – | | | | 0 | | | | | | | + | | 0 | 0 | | | | | 0 | 0 | + | | | 46 % |
| Solberg et al. 2005 [74] | L | microdiscectomy, herniated disc | 180/228 | > 1 y | function (ODI) & pain | mean improvement 69 % | | | | | | | | | | – | | | 0 | | | | | | | | | | | 27 % |
| Trief et al. 2000 [84] | L | 67 % fusion, 30 % decomp.; cLBP | 102/150 | 6 & 12 mo | function (DPQ) | – | 0 | 0 | | | | 0 | | 0 | | 0 | | | – | | | | | | – | | | | | 36 – 41 % |
| Woertgen et al. 1999 [90] | L | discectomy, herniation | 98/121 | 3, 12, 28 mo | function (LBOS) | 66 % successful* | 0 | 0 | 0 | | | – | | | 0 | | | | | | | | | | – | mix | | | | – |
| Katz et al. 1999 [48] | L | decompression, stenosis | 199/272 | 2 y | pain, symptoms, satis., walk | 37 % mild/ no pain; 73 % satisfied | 0 | 0 | | | – | 0 | | | | | | | 0 | | | | | 0 | | 0 | 0 | – | | 22 – 33 % |
| McGregor and Hughes 2002 [63] | L | decompression, stenosis | 65/84 | 1 y | pain | mean decrease 30 % | 0 | 0 | 0 | | | | | | | | | | 0 | | | | | | 0 | | | | – | 11 – 50 % |
| Ng and Sell 2004 [66] | L | discectomy, herniated disc | 103/113 | 1 y | pain | mean decrease 60 % | | | 0 | | | | | | | 0 | | | | | | | | | 0 | | | | | – |
| Peolsson et al. 2003 [71] | C | decompression & fusion, degen. cNP | 74/103 | > 1 y | pain | 30 % patients pain 10 (0 – 100 scale) | + | + | – | | | | | | | | | | | | | | | | | mix | + | | | 30 % |
| Schade et al. 1999 [73] | L | discectomy, herniation | 42/46 | 2 y | pain | 83 % complete relief leg pain | | | | 0 | | | | | | | 0 | | 0 | – | | | | | 0 | 0 | + | | | 30 % |
| Trief et al. 2000 [84] | L | 67 % fusion, 30 % decomp.; cLBP | 102/150 | 6 & 12 mo | pain | 59 – 65 % better | 0 | 0 | | | | 0 | | 0 | | 0 | | | – | | | | | | 0 | | | | | – |
| Hagg et al. 2003 [36] | L | fusion, degen. cLBP | 201/232 | 2y | RTW | 38 % working | – | 0 | 0 | | | | | 0 | 0 | – | | 0 | 0 | | 0 | | | 0 | 0 | 0 | mix | 0 | | – |
| Kaptain et al. 1999 [47] | C | discectomy, herniation | 269/269 | > 10 mo | RTW | 84 % working | 0 | 0 | | | | | – | | | | | | | | | | | – | | | | | – | – |
| Schade et al. 1999 [73] | L | discectomy, herniation | 42/46 | 2 y | RTW | 81 % working full time | | | | 0 | | | | | | | – | | – | 0 | | | | | 0 | 0 | 0 | | | 31 % |

**Table 1. (*Cont.*)**

| Reference | L/C | Surgery, indication | No. pts. | FU | Outcome | | Demographic/ biological | | | | Work variables | | | | | | | Psychosocial | | | | | | Medical | | | | | | R2 |
|---|---|---|---|---|---|---|---|---|---|---|---|---|---|---|---|---|---|---|---|---|---|---|---|---|---|---|---|---|---|---|
| | | | | | | | More aged | Male gender | Smoking | High BMI/weight | Low income | Low education | Low job level | Worker's comp./ disability | Heavy job | Long sick leave/ unemployment | Job satis./stress/ resignation | MMPI scales | Depression/psych. distress | Family reinforce-ment | Pain drawings/ pain behavior/ somatic sympt. | Coping strategies | Neuroticism | No. affected levels | Long duration symptoms | Severity, clinical | Severity, imaging | Comorbidity/self-rated low health | Previous ops. | % Variance accounted for |
| Trief et al. 2000 [84] | L | 67 % fusion, 30 % decomp.; cLBP | 102/150 | 6 & 12 mo | RTW | 51 % working | 0 | 0 | | | | 0 | | – | | – | | | – | | | | | | 0 | | | | | – |
| Young et al. 1997 [91] | L | microdiscect., DH | 348 | > 10 mo | RTW | 75 % working | | + | | | – | | | | | | | | | | | | | | | | | | | – |
| Ng and Sell 2004 [66] | L | discectomy | 103/113 | 1 y | satisfaction | 65 % exc./ good | | | 0 | | | | | | | 0 | | | | | | | | | – | | | | | – |
| Peolsson et al. 2004 [70] | C | decompres-sion & fusion | 74/103 | > 1 y | fusion | 27 % pseu-darthr. | 0 | + | 0 | | | | | | | | | | | | | | | – | | 0 | 0 | | | 14 % |

+ = positive effect on outcome; "–" = negative effect on outcome; **0** = no effect on outcome; "**mix**" = some positive, some negative, some no effect

L/C: L lumbar, C cervical; No. patients = number of patients followed-up out of original group; FU: follow-up duration; RTW: return to work; ODI: Oswestry Disability Index; RM: Roland Morris Disability scale; SC: Stauffer-Coventry (pain, working, medication/physician visits); DPQ: Dallas Pain Questionnaire; LBOS: low back outcome score; PROLO: Prolo Score; R2 = % variance accounted for by all listed predictors in the final multiple regression model

[†]pain, function, medication use; [#]pain, function, satisfaction, medication use; [‡]pain, function, claudication; [$]pain, function, RTW, quality of life; [°]pain, clinical examination, function, medication

*results differed slightly at different FU times, as did the predictors (only stable ones mentioned here)

The discrepancy between a good surgical outcome and a poor subjective result has prompted the search for "risk factors" in an attempt to better identify individuals who are less likely to benefit from surgery. It has also encouraged the development of "**pre-screening**" tools, to assist with the patient selection procedure and the promotion of realistic expectations on behalf of the patient [55, 64].

Some patients will have a poor outcome even after a technically successful operation

Over the last 10 – 15 years, numerous studies have sought to identify predictors of surgical outcome (see Table 1). The **various factors** that **may influence** the (at times discrepant) findings from these studies include:

- the **design of the study** and the **statistical methods** used to identify predictors
- the **outcome measures** employed and the means by which a "successful outcome" is defined
- the **proportion of patients** in the investigated group that typically achieve a successful outcome
- the **number and type of predictor factors** subjected to examination, and their prevalence within the group under investigation
- the **specific pathology** or **surgical procedure** under investigation and the defining characteristics of the patients with that pathology

These issues must be considered carefully, in order that the reader may appreciate the somewhat complicated nature of the topic and may develop the critical thinking required to interpret the results of the existing and future studies of predictors. A more comprehensive review of this topic can be found in two recent reviews [41, 58].

## Outcome Measures

The **proportion of positive outcomes** after spinal surgery [43] and the factors that predict outcome [36, 73] depend to a large extent on the manner in which outcome is assessed. There is no single, universally accepted method for assessing the outcome of spinal surgery. In the past, many clinicians developed their own simple rating scales, using categories such as "excellent, good, moderate and poor", which they themselves used to judge the outcome, predominantly from a surgical or clinical perspective. The **technical success of the operation** also lent itself to evaluation in terms of, for example, the accuracy of screw placement or the degree of fusion/extent of decompression achieved, as monitored by appropriate imaging modalities at follow-up. In an effort to achieve further objectivity, these measures were in the past supplemented with physiological measures such as range of motion or muscle strength [18]. However, in many cases, these measures proved to be only weakly associated with outcomes of relevance to the patients and to society. There is now increasing awareness that the outcome should be (at least also) assessed by the patient himself/herself.

The patient is the best judge of the outcome

The previously popular surgical outcome measures have been superseded by a diverse range of **patient-orientated questionnaires** that assess factors of importance to the patient, such as symptoms, disability, quality of life, and ability to work. However, the emergence of many new instruments in each of these domains, some of which have not been fully validated [92], and the lack of their standardized use, has compromised meaningful comparison among different diagnostic groups, treatment procedures and clinical studies. In recognition of this problem, a standardized set of outcome measures for use with back pain patients was proposed in 1998 by a multinational group of experts [18]. There was general consensus that the most **appropriate core outcome measures** should

Core outcome measures are pain, function, generic well-being, disability, and satisfaction

include the following domains: pain, back specific function, generic health status (well-being), work disability, and patient satisfaction [7, 18]. Recent studies have shown that these measures, while related, are not interchangeable as outcome measures [19]. **Deyo** et al. [18] developed a **core set of just six questions** that would cover all of these domains yet be brief enough to be practical for routine clinical use, quality management and possibly also more formal research studies. The psychometric characteristics of this questionnaire were recently examined in both surgical and conservative back pain patients and the reliability, validity and sensitivity to change of the individual core questions and of a "multidimensional sum-score" was established [59]. The authors added another single question to the core-set to assess "overall quality of life" (taken from the **WHO-QoL BREV questionnaire**), as this domain appeared to be delivering different information to the (symptom-specific) "overall well-being" question in the original core-set. It has been shown that it is feasible to implement this questionnaire on a prospective basis for all patients being operated on within a busy orthopedic Spine Unit performing approximately 1 000 spine operations per year [62]. For more extensive or in-depth clinical trials, it has been suggested that researchers may wish to administer an expanded set of instruments, depending on the particular focus of the study, e.g. **Roland Morris or Oswestry Disability Index** for back specific function, and SF36 for generic health status [7, 18], and perhaps other validated questionnaires to assess, for example, beliefs, fears, or psychosocial factors.

Short, valid and reliable outcome questionnaires were recently developed

In addition to the information delivered by these above questionnaires, a single question enquiring about the patient's rating of the overall effects of treatment ("**global outcome**") is often used as an outcome measure. This can be useful for retrospective studies in which no patient-orientated baseline data is otherwise available or for studies of predictors in which outcome categories are to be compared. Recent work has shown that global assessment represents a valid, unbiased and responsive descriptor of overall effect in randomized controlled trials [35, 57]. Criticisms of global assessment usually include the difficulties in comparing different disease entities, and the dependence of the measures on the baseline characteristics of the groups to be compared [35]; however, both of these can be overcome in observational predictor studies if cases and control groups are well matched.

Global outcome assessment is desirable

## What Constitutes a "Successful Outcome"

How "success" is defined governs not only the proportion of patients with a good outcome but also the factors that predict it

The proportion of patients that can be considered a success after surgery, as well as the factors that might predict a good outcome, depend on how success is defined [3, 73]. The **success of outcome** is likely best considered in relation to the predominant aim of the surgery. Hence, for decompression surgery for a herniated disc or spinal stenosis, the most important outcome may be the reduction of leg pain or sensory disturbances and/or walking capacity, whereas for "chronic degenerative low back pain", the relief of low back pain will primarily govern the degree of success. For all of these conditions, the ability to regain normal function in activities of daily living will also be of importance, although this typically follows with time, once the main symptoms have resolved. In the case of deformity surgery, pain or disability may not be an issue, and factors other than symptoms (such as cosmetic appearance, prevention of progressive worsening and associated systemic complications) may determine the "success" of surgery. The success may also depend on the age group and working status of the group under investigation, as well as the answer to the question "**who's asking?**" – when viewed from the economic point of view, outcomes concerned with work capacity may be of greatest importance for younger patients of working age.

As mentioned above, global assessment scores often give the most direct answer to the question "**did the operation help?**" and allow for the patient to interpret the question in relation to his or her own particular pre-surgical problems and expectations of surgery. For the purposes of predictor studies, multiple response categories for this question (commonly between three and seven responses, ranging from "the surgery helped a lot" through to "the surgery made things worse", or "excellent result" through to "bad result") are often collapsed to dichotomize the data into "good" and "poor" outcome groups. Some authors consider that all responses greater than a "neutral" outcome (i.e. no change) should be considered as a positive result, while others argue that for elective surgical procedures a notable improvement should be required (i.e. more than "helped a little" or "fair result") to consider the operation a success [33].

Multiple response categories are favored for outcome assessment

In predictor studies in which continuous variables, such as the **Roland Morris score**, **Oswestry Disability Index**, or **pain visual analogue scales**, are used as the primary outcome measure, some indication of the cut-off value corresponding to a "good outcome" is required, i.e. the value of the minimal clinically relevant change-score. To determine the value of such cut-off scores, the method of **Receiver Operating Characteristics** (ROC) is commonly used. The ROC curve

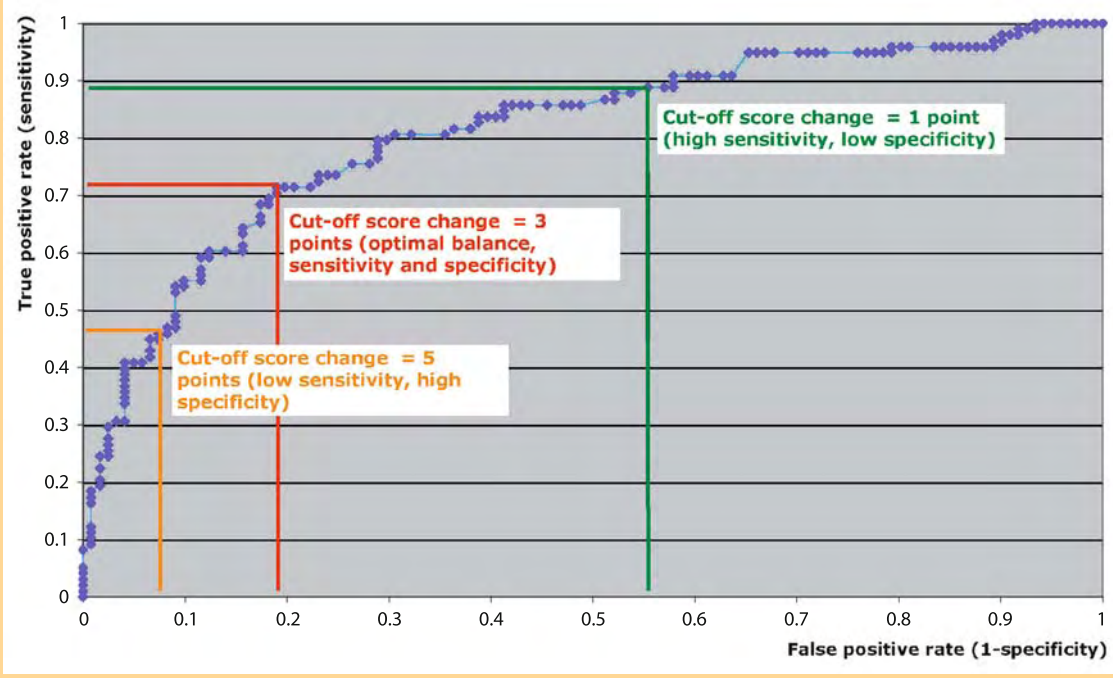


**Figure 1. Receiver operating characteristics (ROC) curve**

This curve is used for determining the minimal clinically relevant change-score of a 0–10 outcome scale. The curve shows the "true-positive rate" (sensitivity) versus "false-positive rate" (1 – specificity) for detecting a "good global outcome" for each of several cut-off points for the change score. The cut-off score with the optimal balance between true-positive (71%) and false-positive (19%) rates (*red line*) yields the clinically relevant change score (in this case, a 3-point reduction). A cut-off of 1-point reduction (*green line*) would be very sensitive (89%) (since most patients with a good outcome have at least a 1-point change in score) but would also have a high false-positive rate (55%) (since many poor outcome patients may show a 1-point change due to measurement error or for non-specific reasons). A cut-off of 5-points change (*orange line*) would be less sensitive (46%) (since many patients with a good outcome would not change by as much as 5 points) but more specific (only 7% false-positive rate) (since few patients with a poor outcome would have such a large score change).

Receiver operating characteristics allow the predictive power of diagnostic tests to be evaluated

synthesizes information on sensitivity and specificity for detecting improvement (according to some dichotomized, external criterion) for each of several possible cut-off points in change score [17] (Fig. 1). Thus, sensitivity and specificity can be calculated for a change score of one point, two points, and so on. This method is analogous to evaluating the predictive power of a diagnostic test, in which the instrument (questionnaire) change-score is the diagnostic test and the global outcome (dichotomized as described above) is used to represent the gold standard [17]. Using such methods, it has been shown that the cut-off for a "**good outcome**" for the 0–100 **Oswestry Disability Index** is a change score of approximately 10 points [38] or an 18% reduction of the pre-surgery score [61]; for the pain visual analogue scale, it is approximately 20 points (on a 100-point scale) [38]; for the 0–24 point **Roland Morris disability score**, approximately 4 points [8, 61]; and for the Multidimensional Short Core Measures, approximately 3 points (on a 0–10 scale) [59]. The minimal clinically relevant changes for generic health scales, such as the SF36, and other secondary outcome measures, such as psychological distress, have been less well investigated. However, these tend to be less responsive to surgery [7, 38] and often the minimal clinically relevant change borders on the value for the minimal detectable difference (i.e. 95% confidence intervals for the measurement error) for these instruments [38], rendering difficult the identification of "real change" as opposed to "random error" in a given individual.

## The Outcome of Common Spine Surgical Procedures

The proportion of patients reporting a "good outcome" after surgery depends to a large extent on how outcome is assessed (see also Table 1). Hence, one must be wary when attempting to make comparisons of different surgical procedures between studies, as some of the variation may simply be attributable to the specific outcome measure used. Few studies (e.g. [5]) have examined the relative success of different procedures or different indications within the same study and using a given outcome measure, and even fewer (e.g. [79–81]) have done this on a prospective basis.

Probably the most comprehensive data reported to date comes from the publications of the authors responsible for the **Swedish Spine Registry**, based on their material collected in 1999 [79–81]. They report the outcome in relation to 2553 patients treated surgically for the most common degenerative lumbar spine disorders. The greatest proportion of patients were diagnosed with **disc herniation** (50%), followed by **central spinal stenosis** (28%), **lateral spinal stenosis** (8%), **segmental pain** (8%) and **spondylolisthesis** (6%). Pain intensity was examined prospectively, using visual analogue scales, and pain relief compared with the situation before the operation was enquired about using **Likert-like responses**. Patients rated their global satisfaction with the procedure as either "satisfied" "uncertain" or "dissatisfied". For disc herniation patients, 75% reported complete or almost complete pain relief 4 months postoperatively. This compared with 59% for central spinal stenosis, 52% for lateral spinal stenosis, 66% for segmental pain and 65% for spondylolisthesis. These values remained relatively stable up to 12 months postoperatively, except in the case of segmental pain (which reduced to 45% patients with complete/almost complete pain relief at 12 months) and spondylolisthesis (reduced to 50% at 12 months). Twelve months postoperatively, the ratings of patient satisfaction among the diagnostic categories generally followed the same pattern as those for pain relief, with the disc herniation group having the greatest proportion of satisfied patients (75%), and segmental pain the lowest (55%).

The best outcome is achieved for disc herniations and stenosis

The results demonstrate that, for certain indications, there is certainly room for improvement. Interestingly, there appears to be a negative relationship between the "soundness" (or generally accepted validity) of the diagnosis and the postsurgical outcome: e.g. for herniated disc, the cause of the symptoms can be diagnosed with relative certainty based on the history, clinical examination and imaging; in contrast, the reliability and accuracy of the procedures used to establish instability/segmental pain have long been the subject of controversy. In most cases, instability is neither clearly defined nor measurable and its strongest link to the pain is determined from subjective interpretations of "**mechanical" back pain**, provocative discography or response to rigid bracing [24]. This indicates that the problem may lie, at least in part, in the patient selection procedure (see later).

The more contentious the indication, the worse the postsurgical outcome

## Predictors of Outcome of Spinal Surgery

The literature reveals a plethora of studies in which predictor factors have been assessed. Recent imaging modalities and operative techniques have advanced so much since the 1980s that negative explorations are now quite rare and the clinical presentation is more straightforward [12]; hence, studies using diagnostic techniques and/or operative methods that are no longer state-of-the-art may identify predictors that are of little relevance today. The primary aim of many studies is simply to report the outcomes for a given procedure, and the factors associated with a good or bad outcome are considered as incidental or supplementary information. The latter (often retrospective studies) tend to be less robust in terms of their scientific quality [58]. Other studies specifically set out to examine prospectively the **predictors of outcome** for a given spinal disorder or surgical technique, and it is the results of these studies that are most helpful in identifying the variables that consistently emerge as predictors. Some of the recent key studies (Table 1) prospectively examined multiple predictor variables, used valid outcome instruments and employed multivariate analyses.

The interplay of the various outcome predictors is complex and requires multivariate analyses

The **most commonly examined predictors** of surgical outcome can be loosely categorized into the following groups:

- medical factors
- biological and demographic factors
- health behavioral and lifestyle factors
- psychological factors
- sociological factors
- work-related factors

In addition to these, and increasing in popularity as a relatively unexplored avenue for explaining some of the variance in outcomes, is the notion of "**patient expectations of surgery**" [55, 60, 64]. One must bear in mind a number of factors when examining the agreement between studies for the variables identified as "**predictors**". Firstly, predictors can only be found among the variables that are examined in the first place; and, secondly, the failure to evaluate potentially important predictor variables in some studies can lead to overestimation of the importance of the variables that *are* examined, or to emphasis being placed on different, but closely related variables carrying similar information. Further, in studies of very small groups of patients, the **sample sizes** for different outcome groups may be too small (especially in relation to the size of the "**poor outcome**" group, which tends to contain just a minority of patients) to sufficiently power the study and allow it to identify potentially relevant, real differences.

Sample size often limits the comprehensive assessment of outcome predictors

## Medical Factors

### Diagnosis-Specific Clinical Factors

Clinical tests are poor predictors of outcome

Few studies have been able to identify **clinical variables** that are predictive of outcome after spinal surgery. Hagg et al. [36] reported no significant predictive effect on outcome after fusion of various baseline pain-provocation (flexion/extension), trunk flexibility, and neurological tests, with the exception of abnormal motor function, which was associated with a poorer outcome. One study has shown that preoperative sensory deficit is associated with a good outcome (in terms of back-specific function), but the relationship was only evident at 28 months after surgery and not at the 3- or 12-month follow-ups [90], suggesting it may have been a spurious finding. In the same study, the presence of a positive SLR test at < 30 degrees was associated with an unfavorable outcome at each time point, and significantly so at 12 months. In contrast, Kohlboeck et al. [50] showed that, preoperatively, the **Lasègue sign** was a good indicator of a successful outcome. Junge et al. considered the deficiency of reflexes to be predictive of a better outcome in their pre-screening instrument developed for disc surgery patients [45].

The Lasègue sign is a good clinical outcome predictor

### Imaging

The recent widespread use of the **MRI** scan in the assessment of spinal disorders has considerably improved the ability of surgeons to understand spinal pathology, especially in relation to disc herniation [11]. In two studies, Carragee and colleagues showed that, in patients with sciatica, the anteroposterior length of the herniated disc material and the ratio of disc area to canal area seen on MRI [13], as well as the degree of annular competence and type of herniation seen intraoperatively [12], had a stronger association with surgical outcome (pain, function, medication use, satisfaction) than did any clinical or demographic variables. Other studies have shown that patients with an uncontained herniated disc had a better functional outcome one year after surgery than did those with a contained herniation [66]. Using multiple regression analysis of a range of medical variables (including MRI findings) and psychosocial variables, Schade et al. [73] reported that **MRI-identified nerve root compromise** and the **extent of herniation** were the strongest independent predictors of global surgical outcome 2 years after surgery in patients undergoing lumbar discectomy. In contrast, return-to-work could not be predicted by any clinical or imaging variables and was instead determined by various psychosocial factors.

Nerve root compromise is the single best outcome predictor for discectomy

Sun et al. [82] retrospectively compared the outcome after adjacent two-level lumbar discectomy in patients with radicular pain attributable to nerve-root impingement either with or without concomitant osseous **degenerative changes** at the same level. The proportion of patients with an excellent/good global outcome (MacNab classification) was significantly higher in the group with only a herniated disc (86 %) compared with the group in which osseous changes were also present (57 %).

One large study showed that low disc height (less than 50 %) was one of the most significant positive predictors of outcome (back-specific function) in patients with degenerative chronic low back pain undergoing spinal fusion [36]. In contrast, Peolsson et al. [70, 71] found that **disc space narrowing** was without any prognostic significance for functional outcome. In patients undergoing lumbar fusion, a surgical diagnostic severity score, based on presurgical imaging, had no predictive power for either disability status, global outcome, or physical or social functioning subscales of the SF20 [16].

Degenerative alterations of the motion segment are poor outcome predictors

In the study of Peolsson et al. [70, 71], preoperative segmental kyphosis at the level to be operated on was the strongest predictor of pain and disability 2 years

after cervical decompression with fusion, although the proportion of explained variance was low.

### Pain History

Symptom duration is a strong predictor of outcome

A consistent predictor of poor outcome for various different diagnoses and types of outcome is the duration of symptoms prior to the operation (Table 1). In studies that failed to identify this association, closely related variables (e.g. long-term sick leave, work-disability claim) were often chosen for inclusion in the multivariate model, especially in **predicting return to work** [36, 84].

Prior operations on the spine have been identified as a risk factor for poor outcome in a couple of studies [47, 63] although, interestingly, satisfaction with repeat operations is purportedly higher when there is a history of good results from previous operations and no epidural scarring requiring surgical lysis [67].

The number of affected levels is inversely related to outcome

The **number of affected (or operated) levels** is often assumed to be negatively associated with outcome, although only few (mostly retrospective) studies have actually demonstrated such a relationship with regard to disability status after fusion [16, 24, 47], the long-term clinical outcome after laminectomy [44] or the risk of requiring subsequent fusion after discectomy [82]. This relationship is believed by some to be related to resulting postoperative spinal instability [44]. A number of other studies, on various diagnostic groups, have been unable to confirm this association at all [1, 34, 70, 76]. Again, identifying the correct surgically treatable lesion(s) may be of greater importance; if this is not done, then increasingly poor results can obviously be expected as increasingly more levels are wrongly operated on.

### General Medical

Significant comorbidity leads to worse outcomes

Many studies have shown that, especially in older populations of patients, poor general health in terms of other joint problems or systemic diseases (**comorbidity**) appears to have a significant negative influence on the outcome of spinal surgery [11, 45, 48]. However, some studies have failed to find any clear association [36, 76]. Perhaps the poor patient-rated outcomes in comorbid patients reflect, in part, cross-contamination of the outcome instruments (especially those assessing function [65]), leading to overestimation of the true back-specific disability. Either way, it is important to make patients with comorbidity aware that the operation is being carried out for the specific spinal lesion identified and that it will not serve as a panacea for all their ongoing medical problems.

### Surgery-Related Factors

Indications for surgery must always be critically assessed

All the factors assessed so far for their role in determining the outcome of surgery are somewhat "extrinsic" to the surgical procedure itself. The assumption tends to be that the surgeon him- or herself is infallible and that the only reason for failure relates to inherent characteristics of the patient him- or herself. Certainly **surgical skill** is an aspect that is difficult to examine within the context of clinical trials, but we must concede that a certain proportion of failures are attributable not to the patient but to failure of the technique used, or the hardware, and surgical complications. Furthermore, it is incumbent upon the surgeon to perform an accurate diagnostic work-up and to critically assess the indications for surgery; any shortcomings in this respect will naturally increase the potential for an unsatisfactory result. A recent study, in which the rates of surgery for herniated disc and spinal stenosis were compared across different spine service areas in the State of Maine (USA), found that the rates varied up to fourfold among the

Surgical skill is an important but less studied outcome predictor

areas examined [49]. Interestingly, the outcomes for patients in the area with the lowest surgery-rate were significantly superior to those in the high surgery-rate areas (79% vs 60% with marked/complete pain relief respectively) [49]. The patients in the higher-rate areas generally had less severe symptoms at baseline than did those in the lowest-rate area. The authors concluded that the variability may have been related to differences in **physicians' preferences or thresholds** for severity with regard to recommending an operation and their criteria for the selection of patients. Waddell and colleagues have argued that distress may increase the pressure for surgery and that inappropriate symptoms and signs may obscure the physical assessment, leading to a mistaken diagnosis of a surgically treatable lesion [88]. In this instance, psychological factors may affect the outcome of surgery indirectly if inappropriate illness behavior leads to inappropriate surgery [88].

Achieving solid arthrodesis does not assure a good patient-orientated outcome

As far as **technical success** is concerned, one of the most commonly assessed surgical outcomes is the **achievement of arthrodesis** after fusion surgery, although it has long been a matter of debate whether the presence of pseudarthrosis has any influence on the subsequent patient-orientated outcome. Some studies have shown that pain relief in particular is greater when solid fusion is achieved [10, 70, 89], although it explains only a small proportion of the variance in pain outcome (4% [70]). In one recent study of interbody cage lumbar fusion, although 84% patients achieved solid fusion, only approximately 40–50% patients demonstrated a successful outcome in terms of pain, quality of life, global outcome and work-disability status [51]. Other retrospective studies have indicated that the presence of radiological arthrodesis has no influence on either back function [30, 69] or work disability status [24] after fusion.

## Biological and Demographic Variables

Gender and age are often "marker" variables for other more important predictors

Numerous retrospective studies have shown a negative association between the patient's age at surgery and outcome, although most of the prospective studies have shown no influence of **age** (Table 1) or have even found improved outcomes in older patients (cervical spine) [71]. In part, the role of age may be explained by the outcome measure being investigated: where work issues are concerned, then it is more likely that older age at operation will result in less positive results with regard to return to work. It is also unclear in many studies (especially when bivariate analyses were used) whether the duration of symptoms was controlled for. The latter is one of the strongest predictors of a poor outcome (see earlier), and especially in chronic disorders tends to show a correlation with age. Hence, age may be acting in part as a marker for symptom duration, where the latter has not been simultaneously accounted for.

**Gender** is also highlighted by many retrospective studies as a potential predictor of outcome, although most prospective studies have failed to find such an association. Those that do, tend to show that men have a better outcome than women (see Table 1). An association with "maleness" is difficult to explain: postulated mechanisms include the notion of gender acting as an indirect marker for various (negative) psychological factors [87], biological differences in the healing potential of men and women, or (with respect to fusion) gender-related differences in the mechanical loading/muscle compressive forces promoting new bone growth [70].

**Body weight** has rarely been found to be a predictor of outcome; many studies show no influence (Table 1) although one recent study showed obesity to have a negative effect on outcome [6].

## Health Behavioral and Lifestyle Factors

Health behavioral and lifestyle factors are important but less studied

Few studies have examined "**health behavioral**" or "**lifestyle**" factors as predictors of outcome, although it is conceivable that these could be important in determining an individual's response to major surgery. Intuitively, one might imagine that a higher level of pre-surgical physical fitness would allow a more rapid return to normal functioning after surgery. To the authors' knowledge, fitness or the participation in regular exercise has been examined in only one retrospective study [4] and was not found to be associated with outcome after percutaneous lumbar discectomy. Results from the authors' own studies suggest that the regular participation in exercise/physical activity for many years prior to the operation (but not necessarily exercise habits at the time of the intervention) – i.e. exercise as a "**lifetime habit**" – is associated with a more positive outcome after decompression surgery (unpublished observations).

Smoking may be a marker for negative health behavior in predicting outcome

Smoking is a relatively frequently examined predictor factor, especially in relation to the outcome after spinal fusion. In some studies it has been shown to have a negative impact on outcome whereas in many others it has had no effect (Table 1). It has been suggested that tobacco use must be examined as a dose-response relationship in order to reveal associations that can be obscured by expressing it as a dichotomous variable (yes/no to a smoking habit) [51].

Fusion is inhibited by nicotine

While the inhibitory effects of nicotine on fusion itself have been established [2, 26], it is also possible that **smoking** may simply reflect other factors – such as negative health behavior (low physical activity levels, alcohol use), lower education/social level, manual job – and thereby act as a marker for these in determining outcome. Interestingly, even in a subgroup of patients with no signs of pseudarthrosis, smoking still predicted clinical outcome and return to work in patients undergoing fusion [26].

## Psychological Factors

Psychological factors are one of the mostly commonly investigated predictors of surgical outcome, although their overall importance still remains equivocal and may be dependent on the spinal disorder in question [11].

The MMPI was developed for psychiatric disorders and is less suited for spinal disorders

Some of the early studies carried out in the 1980s showed slight to moderate associations between certain scales on the **Minnesota Multiphasic Personality Inventory** (MMPI) (most commonly hypochondriasis, hysteria, depression, and admission of symptoms scales) and outcome after disc surgery/fusion. These studies encouraged the development of scoring systems, that included MMPI measures, to assist in predicting surgical outcome from various baseline indicators [6, 75, 85]. In view of the various psychometric and practical problems associated with use of the MMPI in pain patients [56], new or modified methods of assessing psychological characteristics have been introduced, which focus primarily on the measurement of depression, anxiety and/or heightened somatic awareness. More recently, other psychological characteristics have become of interest as potential predictor factors, such as coping strategies [6, 28], **fear-avoidance beliefs** (about work and physical activity) [77] and **various workplace psychological factors** (stress, satisfaction, "resigned" attitude, etc.) [73]. Overall, these have led to mixed results, in terms of their ability to reliably predict outcome.

Fear-avoidance beliefs and workplace factors are strong outcome predictors

Using **pain drawings** and **inappropriate signs**, Greenough and coworkers [31, 32] reported in two retrospective studies that psychological distress was predictive of a poor outcome after anterior fusion. Van Susante and coworkers [87] used a "psychogenic back pain score" to examine prospectively the outcome after lumbosacral fusion of three types of patient group: organic, uncertain, and psychogenic. It was shown that the "organic" group had a much better outcome in

terms of pain, disability and medication use than did the "psychogenic" group. In patients undergoing discectomy, depression was found to be a significant predictor of global outcome [50, 73] and return to work [73]. A recent prospective study by Trief et al. [84] investigated the influence of baseline depression, state anxiety, somatic anxiety and hostility on outcome after lumbar spine surgery [mostly fusion (68 %) and decompressive laminectomy (30 %)]. In multivariate analyses, the **Distress and Risk Assessment Method (DRAM)**, which classifies patients as either "normal", "at-risk" of developing psychological problems, or "distressed", was found to be a significant predictor of outcome in terms of work status, change in back pain and leg pain, and the "daily activities" and "work-leisure activities" scales of the Dallas Pain index. Nonetheless, in each of these cases, the psychological factors appeared to explain only a very small proportion of the overall variance in outcome.

Distress is a significant predictor of outcome

Junge et al. [45] found that certain aspects of pain behavior (search for social support) were significantly associated with a poor global outcome in patients undergoing disc surgery; although depression did not show a significant association, there was a tendency for higher baseline values in patients with a poor outcome and depression was therefore included in the pre-screening tool developed by the group. In prospectively studying patients undergoing discectomy [42] or fusion [83], two studies failed to reproduce the findings of Trief et al. [84], in that DRAM scores were found to have no predictive power in relation to back function (Oswestry Disability Index). Similarly, neither depression [36] nor pain drawings [37] were able to predict outcome (any domain) after fusion for chronic LBP (Table 1). Greenough et al. [30] were also unable to reproduce their earlier findings [31] in a later retrospective study on patients undergoing posterolateral surgery. Notably, in all these studies, psychological disturbance was improved after surgery in patients with a good outcome. No association between depression and outcome could be found in studies on spinal stenosis patients undergoing decompression [48, 63].

In a large group of patients followed up 6 months after spinal surgery (for mixed diagnoses), Staerkle et al. [77] showed that Fear Avoidance Beliefs were a significant predictor of work loss in the preceding month, although the amount of variance explained was extremely low.

Psychological factors often predict outcome in patients with chronic pain

It has been suggested that the poor results of surgery reported in psychologically disturbed patients may reflect intervention in patients who did not have surgically remediable pathology [88], and this appears to have been verified by the many recent studies of Carragee et al. (see [11]). This group has shown that patients with acute and subacute sciatica in association with a clearly identifiable, severe disc herniation have a very high chance of dramatic and lasting improvement with surgery and that standard psychometric tests in these patients fail to predict outcome. Even severe emotional distress in patients coming to early, appropriate surgical intervention did not correlate with adverse outcomes, although the same psychometric profile in patients with chronic sciatic pain and disability did predict worse outcomes compared with less emotionally distressed patients with the same level of chronicity. It was concluded that, with **prolonged pain** and **emotional distress**, adverse and possibly **self-perpetuating psychological** and **social changes** may significantly decrease the impact of disc surgery [11].

Psychological treatment before and after surgery may improve outcomes in distressed patients

All in all, and in view of the conflicting evidence, it would not appear prudent to recommend that patients be denied surgery simply on the basis of their preoperative psychological status. Nonetheless, it may be a useful strategy to identify patients with **long-lasting symptoms** and a **high level of distress** who might benefit from an additional psychological treatment, before and/or accompanying surgical treatment; decreased levels of distress may then increase the impact of surgical treatment.

## Sociological Factors

**Low social functioning** (as measured with quality of life instruments) was identified as a significant negative predictor of reoperation rate in a retrospective study on fusion patients [27], and of global outcome, pain, and quality of life in a mixed group of spine-surgery patients [78]. In some studies, a low **education level** and/or **low income** have been shown to predict a negative surgical outcome in terms of either the total costs associated with workers' compensation [15], return to work [91] or global outcome/function [45, 54, 90]. It has been suggested that because individuals with a better education, a higher income, and at a higher level on the job ladder tend to have greater responsibilities, personal investment may override the discomfort caused by any residual postoperative symptoms and encourage a return to work [47].

Low education and income level are negative outcome predictors

**Social support** from the spouse [73], search for social support (as a pain behavior) [45] and family reinforcement of pain [6] have all been associated with a more negative outcome after surgery. It is suggested that this kind of "support" – in which relatives take over the patient's jobs or responsibilities, encourage rest and provide more attention when the pain appears greatest [22] – serves to reinforce the illness status and thereby encourages the adoption of "passive" behavior [22, 73].

Family reinforcement of pain behavior negatively influences outcome

## Work-Related Factors

Work-related predictors include such variables as worker's compensation, disability pension, work status before surgery, duration of sick leave, and heaviness of job.

The majority of studies that have examined the effect on outcome of the involvement in **disability pension claims** or **worker's compensation issues** have confirmed that these have a negative impact on the result of surgery, especially in relation to return to work or "global outcomes" (Table 1) [16, 20, 31, 32, 51, 53, 86]. In one large high quality study, however, workers' compensation showed no effect on outcome in multivariate models [36]. The authors suggested that the strength of such an association may in part depend on the social insurance system in the given country [36]. One large retrospective study showed that while compensation status was predictive of the 2-year outcome after fusion, it no longer had any influence (in terms of back-specific function scores) after 10 years [69].

Although rarely examined in prospective studies, retrospective studies have shown that the **involvement of a lawyer** in compensation claims has a consistent negative predictive value for various outcomes after spinal fusion [15, 16, 51]. Cynics may interpret this finding as evidence for the premeditated instruction to magnify symptoms for the purposes of secondary gain; some studies have even shown that lawyers may advise their clients how to respond to psychological assessments in order to better their chances of success with their disability claims (see discussion in [51]). Others have suggested that litigious patients experience an increased somatic sensitivity to pain as a consequence of financial incentives and social-contextual variables [22].

Lawyer involvement in compensation claims is predictive of a negative outcome

**Long preoperative sick leave** is a consistent negative predictor of return to work [36, 68, 84] and of global outcome, overall satisfaction or back-specific function [45, 74]. This highlights the importance of providing timely intervention, once a clear-cut diagnosis that can be remedied by surgery has been made (see later).

**Job heaviness** (physically strenuous work) has been examined as an independent predictor in only a few studies, and the results appear to be somewhat con-

Heavy manual work is a negative outcome predictor

flicting: in one retrospective study on herniated disc patients, **heavy manual work** was a negative predictor of overall outcome and postoperative work status 10 years after lumbar discectomy [54]. A prospective study of patients with chronic degenerative low back pain revealed a similarly negative relationship in relation to outcome measured with a combined global score [6], whereas a further study on fusion patients [36] and two others on discectomy patients showed no influence of heavy work on outcome [12, 90]. Intuitively, it may be expected that, while work status may not necessarily govern the degree of pain and disability reported after surgery, it may well influence an individual's chances of returning to a job requiring the performance of heavy manual duties.

In patients undergoing lumbar disc surgery, **job level** was found to be a significant predictor of combined global outcome [45]. An interesting study on military personnel undergoing cervical disc surgery showed that both position (rank) and duration of the individual's military career (but not economic forms of secondary gain, per se) were significant predictors of return to active duty [47].

Occupational mental stress and job-related resignation are strongly correlated with a poor outcome

**Occupational mental stress** and **job-related resignation** have been shown to be negatively associated with return to work and postoperative pain relief/disability respectively [73]. Job-related resignation reflects a "resigned" attitude to work-related troubles, job continuation despite dissatisfaction, the notion that the current situation must be accepted because things might otherwise be worse, and that expectations are limited as an employee [73]. The significance of the impact of job satisfaction on return to work is well documented in the back-pain literature [14, 18].

## Risk Factor Assessment in Clinical Practice

It is extremely **difficult to identify unequivocal predictor factors** that can be used in clinical practice to accurately predict the outcome of surgery. Many risk factors are contentious, or are at least very specific to the patient profile, the diagnosis, the surgical technique and the length and type of follow-up. These factors appear to play such a decisive role that it becomes almost impossible to provide a simple recipe for predicting the outcome of surgery with any certainty on an individual basis. Furthermore, a lack of adequate resources and support often makes it difficult for the clinician to perform a systematic and comprehensive assessment of all the factors that might influence outcome [29]. Many of the questionnaires necessary for assessing psychological and work-related factors are long, have complicated scoring schemes with poorly defined cut-offs for indicating risk, and are not all available in languages other than English (see Elfering and Mannion, Chapter 6 [21]). Some simple predictor models or screening tools have been developed [6, 36, 45, 75], but few [46] have been investigated in a different patient group or under conditions that differ from those in which they were originally developed, limiting their applicability for general use. Moreover, the proportion of variance in outcome explained by even a combination of the strongest predictors is usually relatively low, suggesting that we have a long way to go before being able to rest easily having withheld surgical treatment on the basis of unfavorable baseline characteristics.

Preoperative assessment of outcome predictors in a clinical practice setting is a challenge

The knowledge of the role of the various predictors is important when advising patients for surgery

In reality, the best that science can offer is a series of factors that can be considered to "influence" (rather than predict) the outcome of surgery, which should be considered together with the patient's diagnosis, the proposed operative technique and the characteristics of the patient, in order to discuss with the patient reasons that might cause his or her outcome to deviate from "optimal" (Table 2).

**Table 2.** Generally consistent predictors of poor outcome (see also Table 1 for more details)

**Medical factors**
- severity of pathology on MRI (for disc herniation only)
- long duration of symptoms
- comorbidity/other joint problems/poor general health
- unclear indication

**Biological and demographic factors**
- none

**Health behavioral and lifestyle factors**
- smoking (especially for fusion)

**Psychological factors**
- psychological distress (e.g. depression, anxiety), especially in patients with chronic pain

**Sociological factors**
- family reinforcement of pain, especially in patients with chronic pain

**Work-related factors**
- job dissatisfaction/resignation
- worker's compensation
- long-term sick-leave/work disability

This is of utmost **importance in elective surgery.** The opportunity (time), encouragement (education and positive messages), support and resources (referral to appropriate supporting services) to modify risk factors that are indeed modifiable can be offered, and realistic expectations can be discussed with the patient before the decision to operate is made. Such approaches have already proven worthwhile, with respect to such factors as smoking cessation prior to fusion surgery [26]. Since clear risk factors for a poor work-related outcome are long-term sick-leave/receipt of disability benefit, every effort should be made to keep the individual in the workforce despite ongoing symptoms and plans for surgery. In patients with a particularly heavy job, consultation with occupational physicians to implement ergonomic change, or provide job re-training to allow lighter duties, might later ease the way back into the workplace. Especially patients with a degenerative condition, and/or concomitant systemic or joint disease, should be counselled that their condition is unlikely to return to normal and that only a small percentage of them will have complete pain relief or a complete return to premorbid function. Patients with long-lasting symptoms and a high level of distress may benefit from an additional psychological treatment, before and/or accompanying the surgical treatment.

It is important to keep the individual in the workforce despite symptoms

These modifications, per se, might ultimately result in a greater satisfaction with surgery. Most spinal surgery is carried out for disorders that are not life-threatening, and while time may be of the essence for disorders with a very clear-cut diagnosis [66, 68, 72], there are also many that do not require immediate surgical treatment. This is not to suggest that a simple wait and see policy be adopted without further intervention: instead, active measures to minimize risk factors should be taken in order to best prepare the patient for a potential future surgical procedure, and evidence-based conservative treatments should be persevered with in the meantime. Recent studies suggest that many of the latter are as good as surgery for some of the more contentious indications (e.g. chronic LBP due to degenerative changes) commonly dealt with by spinal fusion [9, 23], and these treatments may be worth considering as an alternative in patients for whom the outcome of surgery is uncertain.

## Recapitulation

**Epidemiology.** **Twenty to 40%** of patients operated on for spinal disorders will have a **poor result** after spinal surgery, regardless of the apparent technical success of the operative procedure itself.

**Outcome measures.** The proportion of positive outcomes after spinal surgery and the factors that predict success depend to a large extent on the manner in which outcome is determined. Outcome is best assessed in terms of the **core measures** of importance to the patient, such as symptoms, function, disability, quality of life, ability to work and satisfaction. Clinically relevant changes have been determined for many of the common outcome instruments: for the Oswestry Disability Index, this is an approximately 20% reduction on the baseline score; for 0–10 pain intensity VAS, it is around 2 points; for the Roland Disability Score, it is about 4 points; and for the multidimensional Core Measures (0–10 scale) it is around 3 points. Spine surgical registries deliver the best information on the relative success of different types of surgery: herniated disc generally proves most successful followed by central stenosis, lateral stenosis, segmental pain, and spondylolisthesis.

**Predictors of outcome of spinal surgery.** The strongest evidence for predictors of outcome is obtained from large-scale prospective studies in which multivariate analyses were used. Many **methodological factors** influence the precise predictors identified in any given study. The most commonly examined predictors of surgical outcome can be loosely categorized into the following groups: medical factors, biological and demographic factors, health behavioral and lifestyle factors, psychological factors, sociological factors, work-related factors

**Medical factors.** Of the medical factors, **clinical tests** are poor predictors of outcome. The severity of morphological alterations seen on MRI predicts the outcome of surgery for herniated disc. The duration of symptoms prior to the operation is a significant predictor of poor outcome for various different diagnoses and types of outcome measure. A number of studies show that **poor general health**, in terms of other joint problems or systemic diseases (**comorbidity**), has a significant negative influence on the outcome of spinal surgery. The strength of the indication for surgery has an important role to play in governing the likely outcome. In contrast, the **technical success** of the operation itself (e.g. the achievement of solid fusion after arthrodesis, the extent of decompression of a stenotic segment) appears to be less critical.

**Biological or demographic variables.** None of these variables has been shown to have a consistent influence on outcome; where such an effect has been observed, it is not clear whether these variables are simply acting as markers for other closely related but more powerful predictors.

**Health behavioral and lifestyle factors** have not been well studied. **Smoking** is the most commonly investigated variable. Studies have confirmed that nicotine lowers the rate of fusion, but the finding that smoking also predicts clinical outcome in patients with no pseudarthrosis suggests that it may mediate its effects by reflecting various aspects of "**negative health behavior**".

**Psychological factors** are one of the most commonly investigated predictors of surgical outcome, although their overall importance still remains equivocal and may be dependent on the spinal disorder in question. The general consensus is that, with **prolonged pain** and **emotional distress**, adverse and possibly self-perpetuating psychological and social changes may significantly decrease the impact of surgery. It may be a useful strategy to identify patients with long-lasting symptoms and a high level of distress who would benefit from an additional psychological treatment, before and/or accompanying surgical treatment.

**Sociological factors.** The sociological factors that are most strongly related to outcome involve "inappropriate" **social support** from the family, i.e. the kind of "support" that involves relatives taking over the patient's jobs or responsibilities, encouraging rest and providing more attention when the pain appears greatest.

**Work-related predictors.** Significant work-related predictors include the receipt of **worker's compensation** or a **disability pension**, work status before surgery, **duration of sick leave** and **low work satisfaction**.

**Risk factor assessment in clinical practice.** In clinical practice, it is extremely difficult to identify and assess unequivocal risk factors that can be used to

accurately predict the outcome of surgery. The practical work involved is time-consuming and resource-intensive, and the science is inexact. **There is insufficient evidence to exclude patients from surgery on the grounds of specific risk factors.** Nonetheless, in the presence of the factors listed above, the case for elective surgery should be considered very carefully, together with the patient. Possibly, surgery should be delayed until attempts have been made to modify risk factors that are amenable to change and all possible conservative means of treatment have been exhausted.

## Key Articles

**Block AR, Gatchel RJ, Deardorff WW, Guyer RD (2003) The psychology of spine surgery. American Psychological Association, Washington DC, pp 29 – 261**
Gives a thorough overview of the means of assessment and the role of putative psychological risk factors.

**Boos N (Guest Editor) (2006) Outcome assessment and documentation. Eur Spine J 15: Suppl 1, pp S1 – S123**
Contains a wealth of up-to-date information covering all aspects of outcome (methodology, assessment in practice, prediction, evidence-based outcome, etc.) compiled by leading experts in the field.

**Carragee EJ (2001) Psychological screening in the surgical treatment of lumbar disc herniation. Clin J Pain 17 3:215 – 219**
This is an extremely well written review paper which clearly puts the role of psychological risk factors and modern imaging (MRI) into perspective in relation to outcome after lumbar discectomy. Its key messages are also appropriate to other indications.

**Deyo RA, Battie M, Beurskens AJHM, Bombardier C, Croft P, Koes B, Malmivaara A, Roland M, Von Korff M, Waddell G (1998) Outcome measures for low back pain research. A proposal for standardized use. Spine 23 18:2003 – 2013**
This consensus paper comes from an international group of back pain experts and reports their recommendations for the use of standardized measures in clinical outcomes research. Since the identification of predictors of surgical success depends heavily on the outcome measure used, it is important to be aware of the most relevant outcomes and their means of assessment.

**Hagg O, Fritzell P, Ekselius L, Nordwall A (2003) Predictors of outcome in fusion surgery for chronic low back pain. A report from the Swedish Lumbar Spine Study. Eur Spine J 12 1:22 – 33**
This is a large study from the Swedish Lumbar Spine Study Group reporting the predictors identified in their randomized clinical trial of spinal fusion vs conservative treatment in chronic LBP. It may be of additional interest to readers keen to learn about predictors of outcome after non-surgical treatment. It also represents a good example of the appropriate statistical methods to use in predictor studies (with simple explanations of their interpretation).

**Schade V, Semmer N, Main CJ, Hora J, Boos N (1999) The impact of clinical, morphological, psychosocial and work-related factors on the outcome of lumbar discectomy. Pain 80 1 – 2:239 – 249**
A small study from the point of view of identifying predictors, but an excellent paper for demonstrating the statistical methodology that should be applied in carrying out predictor analysis.

**Waddell G, Morris EW, Di Paola MP, Bircher M, Finlayson D (1986) A concept of illness tested as an improved basis for surgical decisions in low-back disorders. Spine 11 7:712 – 719**
This paper is a little older than those otherwise considered in this review, but it confronts an extremely important aspect of decision-making in surgery and its message is still true today. In describing the results of a large study to analyze how physical and psychological factors interact to affect outcome, it emphasizes the importance of accurate diagnosis of a surgically treatable lesion, and warns against the perils of letting inappropriate illness behavior lead to inappropriate surgery.

## References


1. Amundsen T, Weber H, Nordal HJ, Magnaes B, Abdelnoor M, Lilleas F (2000) Lumbar spinal stenosis: conservative or surgical management? A prospective 10-year study. Spine 25 11:1424 – 1435; discussion 1435 – 1426
2. Andersen T, Christensen FB, Laursen M, Hoy K, Hansen ES, Bunger C (2001) Smoking as a predictor of negative outcome in lumbar spinal fusion. Spine 26 23:2623 – 2628
3. Asch HL, Lewis PJ, Moreland DB, Egnatchik JG, Yu YJ, Clabeaux DE, Hyland AH (2002) Prospective multiple outcomes study of outpatient lumbar microdiscectomy: should 75 to 80 % success rates be the norm? J Neurosurg Spine 96 (1 Suppl):34 – 44
4. Bernd L, Schiltenwolf M, Mau H, Schindele S (1997) No indications for percutaneous lumbar discectomy? Int Orthop 21 3:164 – 168
5. Birkmeyer NJ, Weinstein JN, Tosteson AN, Tosteson TD, Skinner JS, Lurie JD, Deyo R, Wennberg JE (2002) Design of the Spine Patient Outcomes Research Trial (SPORT). Spine 27 12:1361 – 1372
6. Block AR, Ohnmeiss DD, Guyer RD, Rashbaum RF, Hochschuler SH (2001) The use of presurgical psychological screening to predict the outcome of spine surgery. Spine J 1 4: 274 – 282
7. Bombardier C (2000) Outcome assessments in the evaluation of treatment of spinal disorders. Spine 25 24:3100 – 3103
8. Bombardier C, Hayden J, Beaton DE (2001) Minimal Clinically Important Difference. Low Back Pain: Outcome Measures. Pain 28:431 – 438
9. Brox JI, Sorensen R, Friis A, Nygaard O, Indahl A, Keller A, Ingebrigtsen T, Eriksen HR, Holm I, Koller AK, Riise R, Reikeras O (2003) Randomized clinical trial of lumbar instrumented fusion and cognitive intervention and exercises in patients with chronic low back pain and disc degeneration. Spine 28 17:1913 – 1921
10. Buttermann GR, Garvey TA, Hunt AF, Transfeldt EE, Bradford DS, Boachie-Adjei O, Ogilvie JW (1998) Lumbar fusion results related to diagnosis. Spine 23 1:116 – 127
11. Carragee EJ (2001) Psychological screening in the surgical treatment of lumbar disc herniation. Clin J Pain 17 3:215 – 219
12. Carragee EJ, Han MY, Suen PW, Kim D (2003) Clinical outcomes after lumbar discectomy for sciatica: the effects of fragment type and anular competence. J Bone Joint Surg Am 85-A 1:102 – 108
13. Carragee EJ, Kim DH (1997) A prospective analysis of magnetic resonance imaging findings in patients with sciatica and lumbar disc herniation. Correlation of outcomes with disc fragment and canal morphology. Spine 22 14:1650 – 1660
14. Coste J, Delecoeuillerie G, Cohen de Lara A, Le Parc JM, Paolaggi JB (1994) Clinical course and prognostic factors in acute low back pain: an inception cohort study in primary care practice. BMJ 308:577 – 580
15. DeBerard MS, Masters KS, Colledge AL, Holmes EB (2003) Presurgical biopsychosocial variables predict medical and compensation costs of lumbar fusion in Utah workers' compensation patients. Spine J 3 6:420 – 429
16. DeBerard MS, Masters KS, Colledge AL, Schleusener RL, Schlegel JD (2001) Outcomes of posterolateral lumbar fusion in Utah patients receiving workers' compensation: a retrospective cohort study. Spine 26 7:738 – 746; discussion 747
17. Deyo R, Centor RM (1986) Assessing the responsiveness of functional scales to clinical change: an analogy to diagnostic test performance. J Chron Dis 11:897 – 906
18. Deyo RA, Battie M, Beurskens AJHM, Bombardier C, Croft P, Koes B, Malmivaara A, Roland M, Von Korff M, Waddell G (1998) Outcome measures for low back pain research. A proposal for standardized use. Spine 23 18:2003 – 2013
19. Dionne CE, Von Korff M, Koepsell TD, Deyo RA, Barlow WE, Checkoway H (1999) A comparison of pain, functional limitations, and work status indices as outcome measures in back pain research. Spine 24 22:2339 – 2345
20. Elfering A (2006) Work-related outcome assessment instruments. Eur Spine J 15 Suppl 1:S32 – 43
21. Elfering A, Mannion AF (2006) Epidemiology and risk factors for spinal disorders. Chapter 6, this volume
22. Epker J, Block AR (2001) Presurgical psychological screening in back pain patients: a review. Clin J Pain 17 3:200 – 205
23. Fairbank J, Frost H, Wilson-MacDonald J, Yu LM, Barker KL, Collins R (2005) A randomised controlled trial to compare surgical stabilisation of the lumbar spine with an intensive rehabilitation programme for patients with chronic low back pain: the MRC spine stabilisation trial. BMJ 330:1233
24. Franklin GM, Haug J, Heyer NJ, McKeefrey SP, Picciano JF (1994) Outcome of lumbar fusion in Washington State workers' compensation. Spine 19 17:1897 – 1903; discussion 1904
25. Fritzell P, Hägg O, Wessberg P, Nordwall A (2002) Chronic low back pain and fusion: a com-

parison of three surgical techniques: a prospective multicenter randomized study from the Swedish lumbar spine study group. Spine 27 11:1131 – 1141
26. Glassman SD, Anagnost SC, Parker A, Burke D, Johnson JR, Dimar JR (2000) The effect of cigarette smoking and smoking cessation on spinal fusion. Spine 25 20:2608 – 2615
27. Glassman SD, Dimar JR, Johnson JR, Minkow R (1998) Preoperative SF-36 responses as a predictor of reoperation following lumbar fusion. Orthopedics 21 11:1201 – 1203
28. Grebner M, Breme K, Rothoerl R, Woertgen C, Hartmann A, Thome C (1999) [Coping and convalescence course after lumbar disk operations]. Schmerz 13 1:19 – 30
29. Greenough CG (2006) Outcome assessment: recommendations for daily practice. Eur Spine J 15 Suppl 1:S118 – 123
30. Greenough CG, Peterson MD, Hadlow S, Fraser RD (1998) Instrumented posterolateral lumbar fusion. Results and comparison with anterior interbody fusion. Spine 23 4:479 – 486
31. Greenough CG, Taylor LJ, Fraser RD (1994) Anterior lumbar fusion. A comparison of non-compensation patients with compensation patients. Clin Orthop 300:30 – 37
32. Greenough CG, Taylor LJ, Fraser RD (1994) Anterior lumbar fusion: results, assessment techniques and prognostic factors. Eur Spine J 3 4:225 – 230
33. Grob D, Benini A, Junge A, Mannion AF (2005) Clinical experience with the Dynesys semi-rigid fixation system for the lumbar spine: surgical and patient-orientated outcome in 50 cases after an average of 2 years. Spine 30 3:324 – 331
34. Gunzburg R, Keller TS, Szpalski M, Vandeputte K, Spratt KF (2003) Clinical and psycho-functional measures of conservative decompression surgery for lumbar spinal stenosis: a prospective cohort study. Eur Spine J 12 2:197 – 204
35. Hagg A, Fritzell P, Oden A, Nordwall A (2002) Simplifying outcome measurement: evaluation of instruments for measuring outcome after fusion surgery for chronic low back pain. Spine 27 11:1213 – 1222
36. Hagg O, Fritzell P, Ekselius L, Nordwall A (2003) Predictors of outcome in fusion surgery for chronic low back pain. A report from the Swedish Lumbar Spine Study. Eur Spine J 12 1:22 – 33
37. Hagg O, Fritzell P, Hedlund R, Moller H, Ekselius L, Nordwall A (2003) Pain-drawing does not predict the outcome of fusion surgery for chronic low-back pain: a report from the Swedish Lumbar Spine Study. Eur Spine J 12 1:2 – 11
38. Hagg O, Fritzell P, Nordwall A, Group SLSS (2003) The clinical importance of changes in outcome scores after treatment for chronic low back pain. Eur Spine J 12 1:12 – 20
39. Helenius I, Remes V, Yrjonen T, Ylikoski M, Schlenzka D, Helenius M, Poussa M (2002) Comparison of long-term functional and radiologic outcomes after Harrington instrumentation and spondylodesis in adolescent idiopathic scoliosis: a review of 78 patients. Spine 27 2:176 – 180
40. Herno A (1995) Surgical results of lumbar spinal stenosis. Ann Chir Gynaecol Suppl 210: 1 – 969
41. Hiebert R, Nordin M (2006) Methodological aspects of outcomes research. Eur Spine J 15 Suppl 1:S4 – 16
42. Hobby JL, Lutchman LN, Powell JM, Sharp DJ (2001) The distress and risk assessment method (DRAM). J Bone Joint Surg Br 83 1:19 – 21
43. Howe J, Frymoyer JW (1985) The effects of questionnaire design on the determination of end results in lumbar spinal surgery. Spine 10 9:804 – 805
44. Iguchi T, Kurihara A, Nakayama J, Sato K, Kurosaka M, Yamasaki K (2000) Minimum 10-year outcome of decompressive laminectomy for degenerative lumbar spinal stenosis. Spine 25 14:1754 – 1759
45. Junge A, Dvorak J, Ahrens S (1995) Predictors of bad and good outcomes of lumbar disc surgery. A prospective clinical study with recommendations for screening to avoid bad outcomes. Spine 20 4:460 – 468
46. Junge A, Frohlich M, Ahrens S, Hasenbring M, Sandler A, Grob D, Dvorak J (1996) Predictors of bad and good outcome of lumbar spine surgery. A prospective clinical study with 2 years' follow up. Spine 21 9:1056 – 1064; discussion 1064 – 1055
47. Kaptain GJ, Shaffrey CI, Alden TD, Young JN, Laws ER, Jr., Whitehill R (1999) Secondary gain influences the outcome of lumbar but not cervical disc surgery. Surg Neurol 52 3: 217 – 223; discussion 223 – 215
48. Katz JN, Stucki G, Lipson SJ, Fossel AH, Grobler LJ, Weinstein JN (1999) Predictors of surgical outcome in degenerative lumbar spinal stenosis. Spine 24 21:2229 – 2233
49. Keller RB, Atlas SJ, Soule DN, Singer DE, Deyo RA (1999) Relationship between rates and outcomes of operative treatment for lumbar disc herniation and spinal stenosis. J Bone Joint Surg Am 81 6:752 – 762
50. Kohlboeck G, Greimel KV, Piotrowski WP, Leibetseder M, Krombholz-Reindl M, Neuhofer R, Schmid A, Klinger R (2004) Prognosis of multifactorial outcome in lumbar discectomy: a prospective longitudinal study investigating patients with disc prolapse. Clin J Pain 20 6:455 – 461
51. Lacaille RA, Deberard MS, Masters KS, Colledge AL, Bacon W (2005) Presurgical biopsy-

chosocial factors predict multidimensional patient: outcomes of interbody cage lumbar fusion. Spine J 5 1:71 – 78
52. Lamberg TS, Remes VM, Helenius IJ, Schlenzka DK, Yrjonen TA, Osterman KE, Tervahartiala PO, Seitsalo SK, Poussa MS (2005) Long-term clinical, functional and radiological outcome 21 years after posterior or posterolateral fusion in childhood and adolescence isthmic spondylolisthesis. Eur Spine J 14 7:639 – 644
53. Little DG, MacDonald D (1994) The use of the percentage change in Oswestry Disability Index score as an outcome measure in lumbar spinal surgery. Spine 19 19:2139 – 2143
54. Loupasis GA, Stamos K, Katonis PG, Sapkas G, Korres DS, Hartofilakidis G (1999) Seven- to 20-year outcome of lumbar discectomy. Spine 24 22:2313 – 2317
55. Lutz GK, Butzlaff ME, Atlas SJ, Keller RB, Singer DE, Deyo RA (1999) The relation between expectations and outcomes in surgery for sciatica. J Gen Intern Med 14 12:740 – 744
56. Main CJ, Spanswick CC (1995) Personality assessment and the Minnesota Multiphasic Personality Inventory. 50 years on: do we still need our security blanket? Pain Forum 4:90 – 96
57. Mannion AF, Dvorak J, Junge A, Porchet F, Grob D (2004) Do retrospective ratings of "global outcome" reflect prospective changes in pain and self-rated disability after spine surgery? 64. Jahreskongress der schweizerischen Gesellschaft für Orthopädie. Lausanne, Switzerland
58. Mannion AF, Elfering A (2006) Predictors of surgical outcome and their assessment. Eur Spine J 15 Suppl 1:S93 – 108
59. Mannion AF, Elfering A, Staerkle R, Junge A, Grob D, Semmer NK, Jacobshagen N, Dvorak J, Boos N (2005) Outcome assessment in low back pain: how low can you go? Eur Spine J 14 10:1014 – 1026
60. Mannion AF, Junge A, Dvorak J, Porchet F, Müntener M, Grob D (2005) Does how well you do depend on how well you think you'll do? A prospective study of expectations in patients undergoing spinal decompression surgery. Spine Society of Europe. Barcelona, Spain 14:S17
61. Mannion AF, Junge A, Grob D, Dvorak J, Fairbank JCT (2006) Development of a German version of the Oswestry Low Back Index. Part 2: sensitivity to change after spinal surgery. Eur Spine J 15:66 – 73
62. Mannion AF, Junge A, Porchet F, Jeszenszky D, Bartanusz V, Kleinstück F, Dvorak J, Grob D (2005) Responsiveness of a short set of core outcome measures in spinal surgery patients: a prospective study. International Society for the Study of the Lumbar Spine. New York, USA
63. McGregor AH, Hughes SP (2002) The evaluation of the surgical management of nerve root compression in patients with low back pain: Part 1: the assessment of outcome. Spine 27 13:1465 – 1470
64. McGregor AH, Hughes SP (2002) The evaluation of the surgical management of nerve root compression in patients with low back pain: Part 2: patient expectations and satisfaction. Spine 27 13:1471 – 1476; discussion 1476 – 1477
65. Muller U, Roeder C, Dubs L, Duetz MS, Greenough CG (2004) Condition-specific outcome measures for low back pain. Part II: Scale construction. Eur Spine J 13:314 – 324
66. Ng LC, Sell P (2004) Predictive value of the duration of sciatica for lumbar discectomy. A prospective cohort study. J Bone Joint Surg Br 86 4:546 – 549
67. North RB, Campbell JN, James CS, Conover-Walker MK, Wang H, Piantadosi S, Rybock JD, Long DM (1991) Failed back surgery syndrome: 5-year follow-up in 102 patients undergoing repeated operation. Neurosurgery 28 5:685 – 690; discussion 690 – 681
68. Nygaard OP, Kloster R, Solberg T (2000) Duration of leg pain as a predictor of outcome after surgery for lumbar disc herniation: a prospective cohort study with 1-year follow up. J Neurosurg Spine 92:131 – 134
69. Penta M, Fraser RD (1997) Anterior lumbar interbody fusion. A minimum 10-year follow-up. Spine 22 20:2429 – 2434
70. Peolsson A, Hedlund R, Vavruch L (2004) Prediction of fusion and importance of radiological variables for the outcome of anterior cervical decompression and fusion. Eur Spine J 13 3:229 – 234
71. Peolsson A, Hedlund R, Vavruch L, Oberg B (2003) Predictive factors for the outcome of anterior cervical decompression and fusion. Eur Spine J 12 3:274 – 280
72. Rothoerl RD, Woertgen C, Brawanski A (2002) When should conservative treatment for lumbar disc herniation be ceased and surgery considered? Neurosurg Rev 25 3:162 – 165
73. Schade V, Semmer N, Main CJ, Hora J, Boos N (1999) The impact of clinical, morphological, psychosocial and work-related factors on the outcome of lumbar discectomy. Pain 80 1 – 2:239 – 249
74. Solberg TK, Nygaard OP, Sjaavik K, Hofoss D, Ingebrigtsen T (2005) The risk of "getting worse" after lumbar microdiscectomy. Eur Spine J 14 1:49-54
75. Spengler DM, Ouellette EA, Battie M, Zeh J (1990) Elective discectomy for herniation of a lumbar disc. Additional experience with an objective method. J Bone Joint Surg Am 72 2:230 – 237
76. Spratt KF, Keller TS, Szpalski M, Vandeputte K, Gunzburg R (2004) A predictive model for outcome after conservative decompression surgery for lumbar spinal stenosis. Eur Spine J 13 1:14 – 21

77. Staerkle R, Mannion AF, Elfering A, Junge A, Semmer NK, Jacobshagen N, Grob D, Dvorak J, Boos N (2004) Longitudinal validation of the fear-avoidance beliefs questionnaire (FABQ) in a Swiss-German sample of low back pain patients. Eur Spine J 13 4:332 – 340
78. Stärkle R, Mannion AF, Junge A, Elfering A, Grob D, Dvorak J, Boos N (2002) The influence of baseline psychological factors on outcome after spine surgery. SIROT. San Diego, USA
79. Stromqvist B (2002) Evidence-based lumbar spine surgery. The role of national registration. Acta Orthop Scand Suppl 73 305:34 – 39
80. Stromqvist B, Fritzell P, Hagg O, Jonsson B (2005) One-year report from the Swedish National Spine Register. Swedish Society of Spinal Surgeons. Acta Orthop Suppl 76 319:1 – 24
81. Stromqvist B, Jonsson B, Fritzell P, Hagg O, Larsson BE, Lind B (2001) The Swedish National Register for lumbar spine surgery: Swedish Society for Spinal Surgery. Acta Orthop Scand 72 2:99 – 106
82. Sun EC, Wang JC, Endow K, Delamarter RB (2004) Adjacent two-level lumbar discectomy: outcome and SF-36 functional assessment. Spine 29 2:E22 – 27
83. Tandon V, Campbell F, Ross ER (1999) Posterior lumbar interbody fusion. Association between disability and psychological disturbance in noncompensation patients. Spine 24 17:1833 – 1838
84. Trief PM, Grant W, Fredrickson B (2000) A prospective study of psychological predictors of lumbar surgery outcome. Spine 25 20:2616 – 2621
85. Uomoto JM, Turner JA, Herron LD (1988) Use of the MMPI and MCMI in predicting outcome of lumbar laminectomy. J Clin Psychol 44 2:191 – 197
86. Vaccaro AR, Ring D, Scuderi G, Cohen DS, Garfin SR (1997) Predictors of outcome in patients with chronic back pain and low-grade spondylolisthesis. Spine 22 17:2030 – 2034; discussion 2035
87. Van Susante J, Van de Schaaf D, Pavlov P (1998) Psychological distress deteriorates the subjective outcome of lumbosacral fusion. A prospective study. Acta Orthop Belg 64 4:371 – 377
88. Waddell G, Morris EW, Di Paola MP, Bircher M, Finlayson D (1986) A concept of illness tested as an improved basis for surgical decisions in low-back disorders. Spine 11 7:712 – 719
89. Wetzel FT, McCracken L, Robbins RA, Lahey DM, Carnegie M, Phillips FM (2001) Temporal stability of the Minnesota Multiphasic Personality Inventory (MMPI) in patients undergoing lumbar fusion: a poor predictor of surgical outcome. Am J Orthop 30 6:469 – 474
90. Woertgen C, Rothoerl RD, Breme K, Altmeppen J, Holzschuh M, Brawanski A (1999) Variability of outcome after lumbar disc surgery. Spine 24 8:807 – 811
91. Young JN, Shaffrey CI, Laws ER, Jr., Lovell LR (1997) Lumbar disc surgery in a fixed compensation population: a model for influence of secondary gain on surgical outcome. Surg Neurol 48 6:552 – 558; discussion 558 – 559
92. Zanoli G, Stromqvist B, Padua R, Romanini E (2000) Lessons learned searching for a HRQoL instrument to assess the results of treatment in persons with lumbar disorders. Spine 25 24:3178 – 3185

# 8 History and Physical Examination

Clément M.L. Werner, Norbert Boos

## Core Messages

- ✔ Back pain is one of the most common causes for a medical consultation
- ✔ Up to 85 % of individuals will experience back pain at least once in their lifetime
- ✔ The high rate of benign back/neck pain increases the risk of overlooking serious spinal disorders
- ✔ Findings (red flags) suggesting serious pathology are: features of cauda equina syndrome, severe night pain, significant trauma, fever, unexplained weight loss, history of cancer, patient over 50 years of age, and use of intravenous drugs or steroids
- ✔ Back pain getting worse during the night may indicate a tumor or infection
- ✔ Tumors, discitis/spondylodiscitis, acute fractures, relevant pareses, or conus/cauda equina syndromes need immediate further diagnostic work-up in a specialized spine unit
- ✔ Spinal disorders can be classified as specific (with morphological correlates) vs. non-specific (without structural findings)
- ✔ Central (axial) pain should be differentiated from peripheral (radicular) pain
- ✔ The physical examination is facilitated when a certain sequence of different examining positions are used, i.e. walking, standing, sitting, lying supine, lying on the left/right side, lying prone
- ✔ The most important aspects of the clinical examination are the spinal balance and the neurological assessment
- ✔ The sagittal profile (lordosis/kyphosis) varies to a large extent
- ✔ In the flexed neck position, rotation of the upper cervical spine and in the extended position rotation of the lower cervical spine is assessed
- ✔ The Lasègue test is positive if radicular leg pain is provoked during lifting of the ipsilateral leg
- ✔ Abnormal illness behavior should caution one to consider a spinal intervention
- ✔ The reproducibility of the patient's history and examination is limited

## Epidemiology

Generally, spinal pain is common, benign, and self-limiting

Back and neck pain are a very common medical problem and a predominant cause for visits and medical consultations [15]. The reported **lifetime prevalence** of back pain ranges up to 84 % [5] and that of neck pain to 67 % [6]. Dorsal (thoracic) pain is much less frequent. The 1-year prevalence of dorsal pain was 17 % compared to 64 % for neck and 67 % for low-back pain in a Finnish study [25]. More than 90 % of patients initially presenting with back pain can be managed non-operatively with physical therapy and analgetic medication and will return to an acceptable pain level within 3 weeks, and even to normal within 3 months [10]. These figures indicate that spinal pain is a benign and self-limiting disorder (see Chapter 6).

About 85 % of patients can be classified as having **non-specific back pain** (see Chapter 21), i.e. no morphological correlate can be detected which would satisfactorily explain the pain [10, 30]. The **diagnostic challenge** in patients with spinal disorders is a result of the very high rate of benign spinal pain which poses a

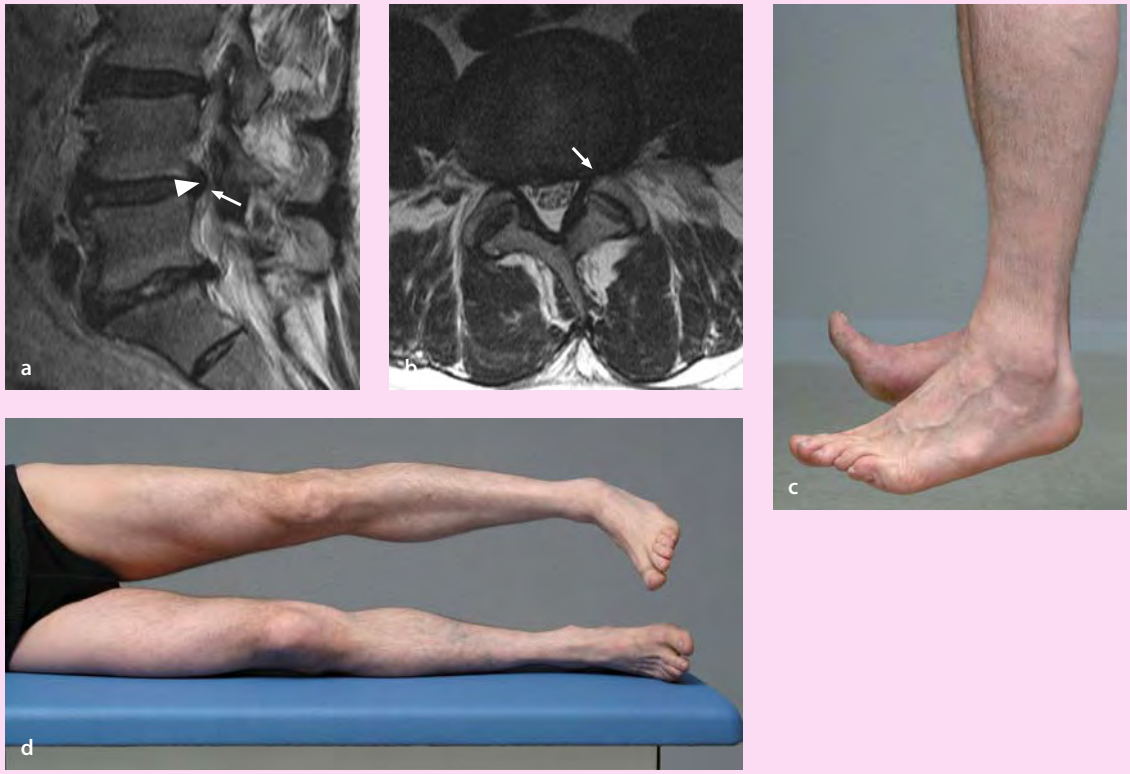


## Case Introduction

A 46-year-old male was referred for an imaging study of the lumbar spine and possible surgical treatment of an acute foot drop. The clinical history revealed a sudden onset (about 6 h), paresis of the left foot (long extensors of the greater toe and foot) with relevant muscle weakness (M1 – 2). However, the patient did not report any significant back pain and only mild pain in the lower limb. An MRI investigation was prompted because of the sudden onset of the paresis. **a** The sagittal T2 W image showed a minor disc protrusion (*arrowhead*) with contact to the nerve root L5 (*arrow*). **b** In the axial view, only a small foraminal disc protrusion is seen without clear neural compromise. The MRI could not satisfactorily explain the severe foot drop and the patient was reassessed clinically. **c** The patient was unable to extend his left foot while sitting on the examination table. **d** However, he was able to lift his left leg in a right sided position indicating normal muscle force for the hip abductors (L5). This discrepancy was indicative of a peripheral paresis of the peroneal muscles which was later documented by neurophysiology. Completion of the patient's history revealed that he was kneeling for several hours repairing a floor in his house the day before the onset of the foot drop.

Rule out specific causes of spinal pain

great risk of overlooking a serious pathology. Therefore, the most important aspect of the diagnostic work-up is to **rule out:**

- relevant paresis (<MRC Grade 3)
- bowel and bladder dysfunction
- tumor/metastasis
- infection
- inflammatory diseases
- occult (osteoporotic) fractures

A thorough and standardized clinical assessment allows for an effective triage and further diagnostic work-up of patients with suspected specific causes of back pain.

## History

History contributes most to a clinical diagnosis

Due to the broad range of clinical entities that may present with back, dorsal and neck pain, a systematic and logical approach, a skillful interpretation, and a careful analysis of history data should be performed prior to the physical examination [8, 9]. In many cases a highly probable diagnosis can be made from the patient's history alone. Back and neck pain has a strong tendency to become chronic (see Chapter 6). Therefore, a rapid, pathomorphology-oriented diagnostic work-up and initiation of treatment is mandatory.

The **major goal of the clinical assessment** is to differentiate:

- specific spinal disorders, i.e. **with** a pathomorphological correlate
- non-specific spinal disorders, i.e. **without** an evident pathomorphological correlate

The diagnosis of non-specific neck/back pain is made by exclusion

In **specific spinal disorders** a pathomorphological (structural) correlate can be found which is consistent with the clinical presentation. Accordingly, in **non-specific spinal disorders** no such correlate can be detected. It is obvious that patients are classified in the latter group by exclusion. Unfortunately, the sources of patients' complaints remain unclear in the vast majority of cases (85–90%) despite a thorough clinical and diagnostic work-up [30]. However, in the individual case it can be difficult to differentiate specific and non-specific disorders and a final conclusion is only reached after a thorough further diagnostic work-up.

The most **devastating failure** of the clinical assessment is to overlook the presence of a tumor, infection, or a spinal compression syndrome. This can be avoided in most cases, if the examiner considers possible specific causes during history taking and physical examination. If suspicion is raised, the proper diagnostic work-up is prompted. The importance of this triage has led to the suggestion of a so-called **flag system** (see Chapter 6). The **red flags** are of particular relevance because they help to detect serious spinal disorders [1]:

- 🚩 features of cauda equina syndrome
- 🚩 severe and worsening pain (especially at night or when lying down)
- 🚩 significant trauma
- 🚩 fever
- 🚩 unexplained weight loss
- 🚩 history of cancer
- 🚩 patient over 50 years of age
- 🚩 use of intravenous drugs or steroids

Features of cauda equina syndrome include urinary retention, fecal incontinence, widespread neurological symptoms and signs in the lower limb, including gait abnormality, saddle area numbness and a lax anal sphincter [1]. A **relevant paresis** can be defined as the inability of the patient to move the extremity against gravity. It is particularly important to recognize a **progressive weakness** because emergency exploration and treatment is necessary. It is always astonishing that patients do not spontaneously report a disturbance of their **bowel and bladder** function because they do not suspect a correlation with a spinal problem. Other color (i.e. yellow, blue, black) flags indicate **obstacles to recovery** from an acute episode (Chapters 6, 21).

After red flags are explored, the clinical assessment focuses on the **three major complaints** which lead the patients to seek medical advice:

- pain
- functional impairment
- spinal deformity

Of these three complaints, pain is by far the most common aspect.

## Pain

Although pain is the most common complaint in patients with spinal disorders, our understanding of the pathophysiology of pain is still scarce. However, molecular biology has recently unraveled some basic mechanisms of pain generation and persistence which help to better understand patients presenting with spinal pain (Chapter 5 is strongly recommended for further reading).

### Differentiation of Pain

The most obvious differentiation of spinal pain syndromes is based on the **region** of the pain, i.e.:

- neck pain
- dorsal pain
- low-back pain

More important than the regional differentiation is the distinction with regard to pain **radiation**, i.e.:

- radicular pain
- referred pain
- axial pain

**Radicular pain** is a nerve mediated pain which follows a dermatomal distribution (Fig. 1). It can even occur without back or neck pain, e.g. in case of a disc herniation. A differential diagnosis of the segmental and peripheral innervation [11] is obvious and mandatory (Fig. 2). **Referred pain** usually originates from the back or neck but radiates into the extremities. It is musculoskeletal in origin and rarely radiates below the elbow or knee. However, knowledge of the so-called sclerotomes [7] is helpful in understanding otherwise unexplained musculoskeletal pain (Fig. 3). In the case of a L5 radiculopathy, for example, patients most frequently experience pain in the greater trochanter region (L5 sclerotome). **Axial pain** is defined as a locally confined pain in the axis of the spine without radiation. In this context, the most important questions are (Table 1):

**Table 1.** Important triage questions

- How much of your pain is in your arm(s)/hand(s) and how much in your neck?
- How much of your pain is in your legs(s)/(foot, feet) and how much in your lower back?

Pain which is exclusively or predominantly in the arms/hands is indicative of a radicular syndrome (disc herniation, spondylotic radiculopathy or myelopathy). Pain which is exclusively or predominantly in the legs/feet indicates a **radicular syndrome** (disc herniation, foraminal stenosis) or spinal claudication. A differentiation of axial pain is less straightforward and it remains difficult to relate a specific pathomorphological alteration to this pain.

**Table 2.** Pain descriptors

| Sensory dimension | | Affective dimension |
|---|---|---|
| • throbbing | • hot-burning | • tiring-exhausting |
| • shooting | • aching | • sickening |
| • stabbing | • heavy | • fearful |
| • sharp | • tender | • punishing-cruel |
| • cramping | • splitting | |
| • gnawing | | |

According to Melzack [21]

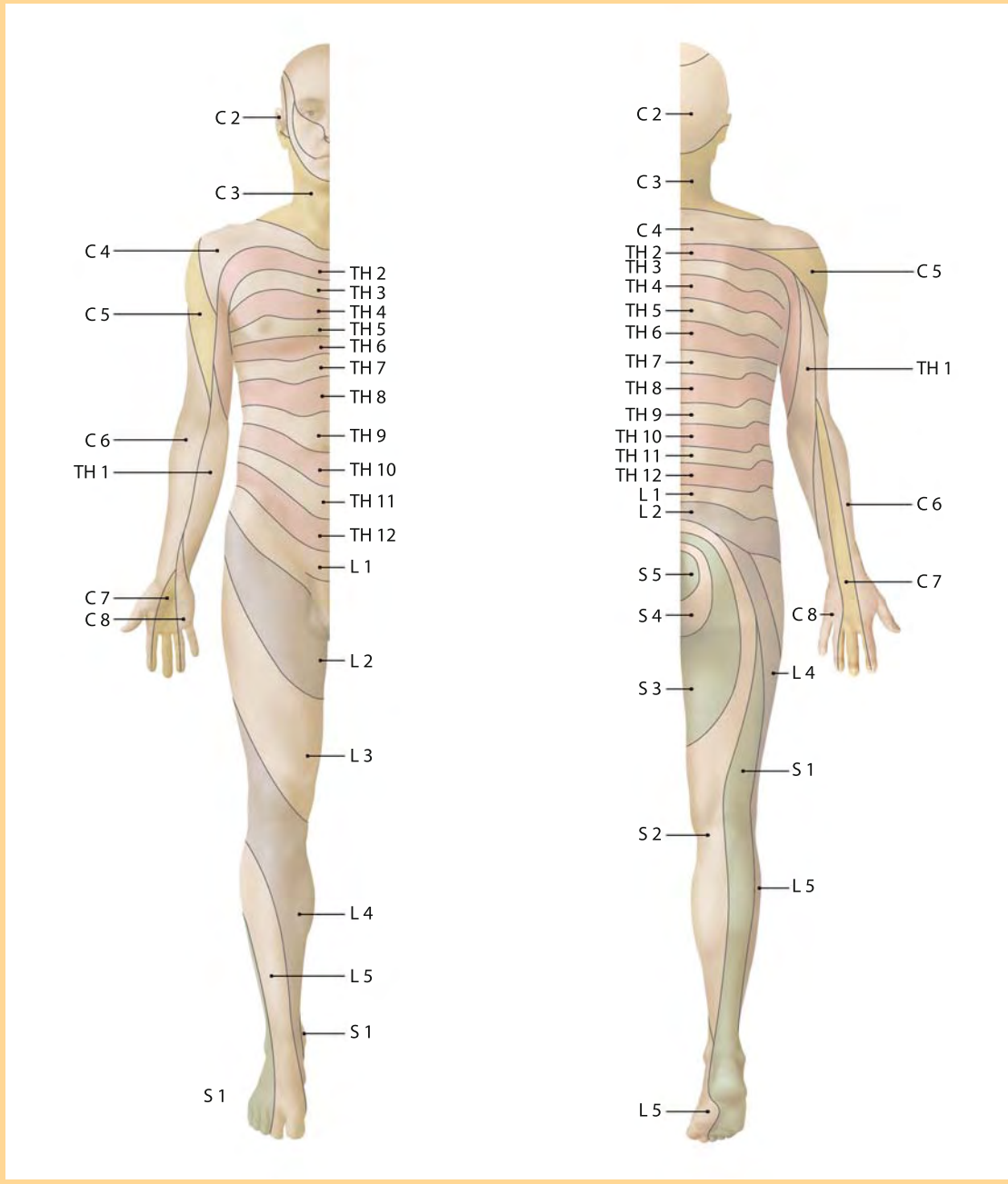


Figure 1. Segmental innervation of the skin

Pain can be further differentiated according to its **character**. Melzack [21] has developed a questionnaire which distinguishes **sensory** and **affective pain descriptors** (Table 2) which can be helpful in the assessment of the pain character.

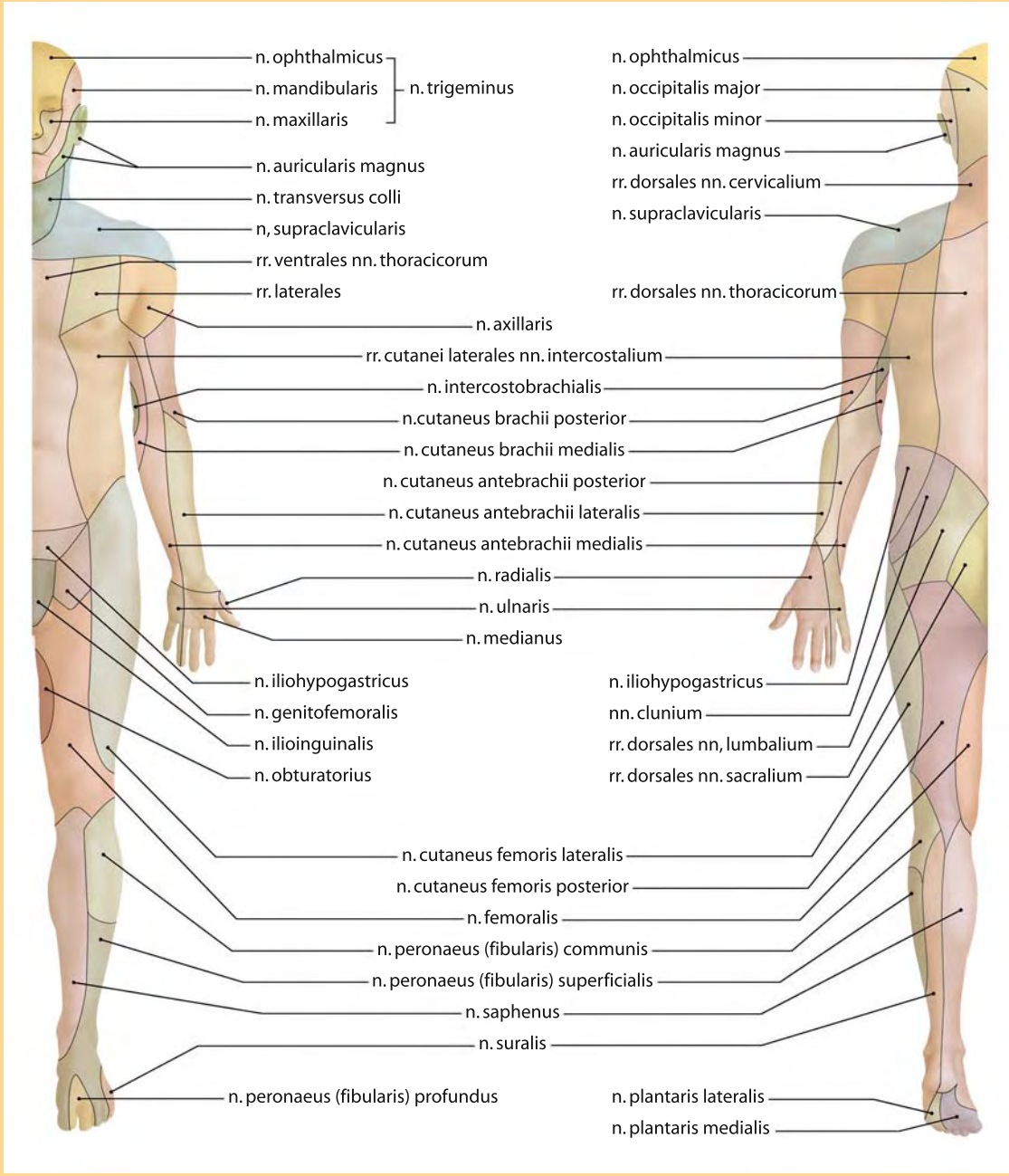


**Figure 2. Peripheral innervation of the skin**

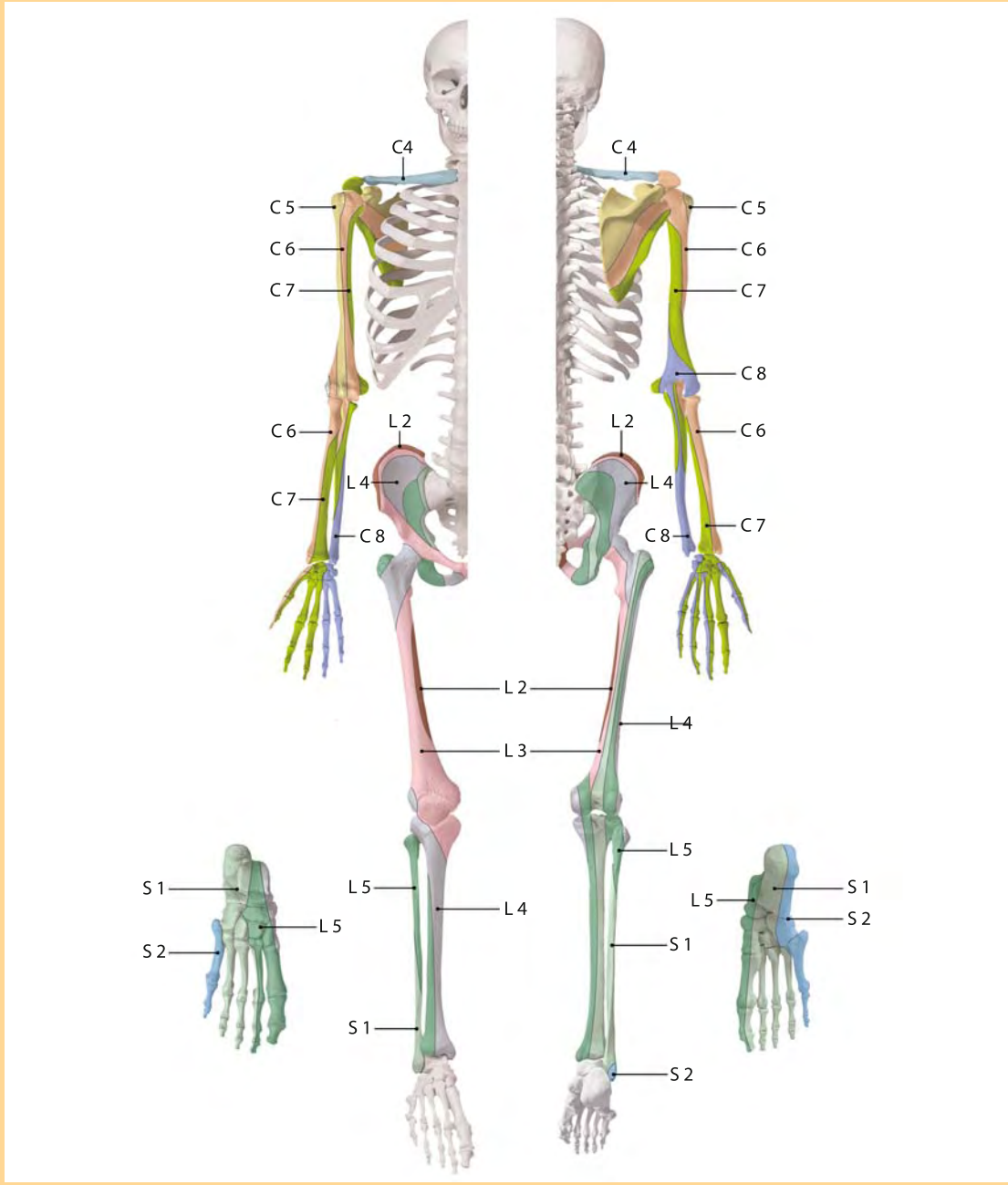


Figure 3. Segmental innervation of the bones

A classic differentiation of pain is often based on the **temporal course**, i.e.:

- acute – duration less than 1 month
- subacute – duration up to 3 months
- chronic – duration more than 3–6 months

Chronic pain is not simply prolonged acute pain

However, as outlined in Chapter 5, this differentiation is arbitrary and does not reflect the underlying pathomechanism. Chronic pain is not simply a prolonged acute pain but undergoes distinct alterations in the pain pathways.

### Pain Intensity

Pain intensity is best assessed with a visual analogue scale

Based on the definition of the International Association for the Study of Pain (IASP), pain is always subjective [16]. An objective assessment of pain intensity is therefore very difficult. Today, **visual analogue scales** (VAS) have become a standard tool in assessing pain intensity. Pain intensity should routinely be assessed with regard to outcome assessment of a future treatment (see Chapter 40).

Excruciating pain may indicate neural compression or severe instability

Pain intensity is rarely a guide to the underlying pathology. However, acute **excruciating pain** should raise the suspicion of a neural compression or a severe instability. Myelopathic or radicular pain can sometimes be so severe that it is difficult to control it by analgesics.

### Pain Onset

Slowly progressive pain worsening during the night is indicative of tumor/infection

The onset of pain can be helpful in inferring the underlying pathology. It is reasonable to explore whether the pain onset followed a **specific incident** or not:

- incident with immediate pain onset
- incident with delayed pain onset
- no incident, slowly progressive pain

It is most obvious in patients who sustained an **injury** (e.g. fall, motor vehicle accident) which immediately initiated the pain. In these cases, a fracture or fracture dislocation must be ruled out. Some elderly patients report a loud crack in their back as the onset of pain which is indicative of an acute osteoporotic fracture. Rear-end collision accidents typically result in a **delayed pain onset** (whiplash-associated disorders). More frequent and difficult to interpret is a situation in which the patient has sustained a minor incident (e.g. lifting accident, uncomfortable movement) with delayed pain onset. An acute onset of back pain which subsequently radiates into an extremity is indicative of a radiculopathy caused by a disc herniation. The vast majority of patients with spinal disorders do not report an incident but a **slowly progressive pain** and discomfort which initially is unrecognized. In the case of a slowly progressive pain which worsens during the night or rest, the examiner should suspect a tumor or infection.

Slowly progressive pain indicates degenerative disorders, but do not overlook tumor or infection

### Pain Modulators

The assessment of modulators of pain is helpful for the diagnosis of specific pain syndromes and can guide the examiner to the underlying pathology. It is important to stress that the significance of these pain modulators is often not based on scientific evidence. Therefore, caution is prompted when interpreting pain modulating factors. The most helpful **positional and activity modulators** of spinal pain are listed in Table 3.

Besides these positional and activity modulators of pain, the **diurnal variation** is helpful in discriminating spinal pain syndromes (Table 4).

**Table 3.** Positional and activity modulators of pain

| Modulator | Possible interpretation |
|---|---|
| forward bending | • increases pressure within the intervertebral disc<br>• relieves the facet joints<br>• widens the spinal canal |
| backward bending | • stresses the facet joints<br>• narrows the spinal canal |
| sideward bending | • increases pressure within the intervertebral disc |
| side rotation | • stresses the facet joints |
| sitting | • increases pressure within the intervertebral disc<br>• relieves claudication symptoms |
| standing | • stresses of the facet joints |
| rest | • improves pain related to segmental instability<br>• worsens tumor/infection related pain<br>• worsens arthritic facet joint pain |
| activity | • worsens pain related to segmental instability<br>• improves arthritic facet joint pain |
| walking uphill | • increases pressure within the intervertebral disc<br>• decreases claudication symptoms |
| walking downhill | • stresses the facet joints<br>• increases claudication symptoms |
| climbing stairs | • increases pressure in the disc |
| descending stairs | • stresses the facet joints |
| vibration (e.g. riding a train, driving on uneven road) | • worsens pain related to segmental instability |
| walking | • initiates claudication symptoms<br>• worsens pain related to segmental instability |
| lying prone | • relieves claudication symptoms<br>• improves pain related to segmental instability |
| coughing, sneezing<br>rotating the head (e.g. backwards while driving) | • aggravates radicular pain<br>• stresses the cervical facet joint |
| working above arm level | • stresses the cervical facet joint (extension) |

**Table 4.** Diurnal pain variation

| Pain modulator | Possible interpretation |
|---|---|
| night pain | • tumor/infection related pain<br>• arthritic facet joint pain |
| early morning pain | • arthritic facet joint pain<br>• spondylarthropathy (ankylosing spondylitis) |
| pain relief after getting up | • arthritic facet joint pain |
| pain increase during the day | • pain related to segmental instability |

## Pain Medication

The assessment of the effect of medication on the pain is seldom indicative of the underlying pathology. However, myelopathic and radicular pain can be very severe and require strong narcotics. In the rare cases of an osteoid osteoma, non-steroidal anti-inflammatory drugs (**NSAIDs**) and particularly acetylsalicylate relieves symptoms and therefore may be diagnostic. On the other hand, non-specific chronic back pain does not respond well to pain medication. The **type and frequency** of pain medication should be noted as a future outcome parameter.

Non-specific back pain does not respond well to pain medications

## Function

Assessment of the back/neck related function of the patient is important because many patients with spinal disorders are severely limited [35, 37]. However, Mooney outlined that the definition of the terms impairment, disability and handicap is not so straightforward and is often overlapping [23]. **Physical impairment** is an anatomical, physiological, or psychological abnormality leading to loss of normal bodily ability while **disability** is the resulting diminished capacity for everyday activities and gainful employment or the limitation of a patient's performance compared to a fit person of the same age and sex [23, 34]. **Handicap** can be seen as a product of an interaction of a person with impairment and disability and the environment [2] and thus resembles a loss or limitation of opportunities to take part in community life on an equal level compared to healthy persons.

Functional limitations including **activities of daily living** should be assessed with regard to:

- sitting (time)
- standing (time)
- self-care
- walking (distance, time)
- sleeping (time)
- weight lifting (maximum weight, position)
- driving
- reading
- working above head/shoulder level
- writing
- working with computer
- fine motor skills
- sex life
- social contacts (family, friends)
- work status

Functional impairment is best assessed with a standardized questionnaire

The functional impairment should best be assessed using a **standardized questionnaire** [12, 27], which allows for an evaluation of the treatment outcome (see Chapter 40).

## Spinal Deformity

The assessment of spinal deformities requires some specific additional information from the patient (or parents). The patients should be explored with respect to:

- family history regarding spinal deformities
- course of pregnancy
- course of delivery
- developmental milestones (onset of walking, speaking, etc.)
- fine motor skills
- tendency to fall (clumsiness)
- onset of menses
- growth of beard
- growth spurt
- breaking of the voice
- evidence for metabolic or neuromuscular disorders

## Physical Examination

In contrast to major joints of the extremities, which allow a passive examination even in the presence of severe painful pathology, the physical assessment of the spine is often hampered by strong muscle spasm. The patient with a spinal disorder is usually in pain and the examination often aggravates this pain. The physical examination should therefore be as short and effective as possible. In concordance with Fairbank and Hall [13], we suggest an **algorithm** which does not focus on the classic examination approach (i.e. inspection, palpation, functional testing) but on a succession of body positions which allow for a time-effective examination. The **different examination positions** consist of:

The examination should be done using a distinct succession of body positions

- walking
- standing
- sitting
- lying supine
- lying on the left/right side
- lying prone

The examination of the spine should **include the whole spine** and not only the affected part(s) because the spine is an organ which extends from the occiput down to the coccyx. Although as simple as it is obvious, it is important to stress that **patients should be examined undressed** (down to their underwear). The examination room should have enough space to allow free movement of the patient and contain an examination table (Table 5).

### Walking

The physical assessment begins as soon as the patient enters the examination room with an inspection of the gait. It is noted whether the patient is able to walk unsupported or with support (e.g. by an accompanying person, crutches, or wheelchair). After the completion of history taking, the patient is asked to walk back and forth in the room. Any causes of limping must be differentiated, i.e.:

- pain
- muscle insufficiency
- paralysis
- ankylosis
- leg length discrepancy

Differentiate the cause of limping

The patient should walk on their tiptoes (S1) and heels (L4, L5) to assess muscle weakness in the lower limbs. Any evidence of atactic gait should be noted and further explored (Rhomberg's test, walking along a line; see Chapter 11).

### Standing

Body height and weight should be assessed at least at the first clinical visit. For follow-up examination of patients with spinal deformities the assessment of body height (sitting and standing) is compulsory. The undressed patient should be inspected for any presence of **spinal stigmata** such as café-au-lait spots (neurofibromatosis), hairy patches (spina bifida occulta), and foot size differences (tethered cord). Any **scarring** must be noted and particular attention should be paid to previous spinal or thoracic surgery (putative secondary spinal deformity).

**Table 5.** Physical examination algorithm

**Walking**
*Inspection for:*
- limping (pain, muscle insufficiency, paresis, leg length discrepancy, ankylosis)
- weakness while walking on tiptoes (S1) and heels (L4, L5)
- difficulty walking along a line (atactic gait)

**Standing**
*Assessment of:*
- body height and weight

*Inspection for:*
- spinal stigmata
- sagittal and coronal spinal balance
- sagittal profile (hypo-/hyperkyphosis/lordosis)
- muscle atrophies
- level of shoulders
- waist asymmetries and pelvic rotation
- level of pelvis (in standing and flexed position)
- rib/lumbar hump (in standing and flexion)
- spinous process step-off

*Functional testing of:*
- finger floor distance/Schober and Ott test
- Trendelenburg test
- left/right side bending and rotation
- repetitive forward bending
- repetitive backward bending and rotation
- repetitive tiptoe standing (McNab's test)
- repetitive stool climbing
- jumping on one leg

**Sitting**
*Palpation of the cervical spine:*
- spinous processes, facet joints, transverse process of C2, mastoid
- tender points in paraspinal muscle

*Functional testing of cervical spine:*
- chin-sternum distance
- active forward/backward bending, left/right side rotation (neutral position)
- active left/right side rotation in flexion
- active flexion/extension/side rotation against resistance
- passive motion testing
- Spurling's test
- Roos and Adson's tests

*Neurological assessment of:*
- sensory qualities (light touch, pin prick, proprioception)
- muscle force (M0–5)
- muscle tendon reflexes

**Lying supine**
*Assessment of:*
- muscle strength for foot extension, eversion, inversion and leg lifting
- pathological reflexes (Babinski group, Trömner, Hofmann, and abdominal reflexes)
- spasticity (arms/legs)
- Lhermitte's sign
- straight leg raising test (Lasègue sign)
- hip mobility
- Patrick test, sacroiliac joint compression/distraction test
- peripheral pulses

**Lying on left/right side**
*Assessment of:*
- hip abduction force
- Mennell's test (sacroiliac joint)
- perianal sensitivity and sphincter tonus

**Lying prone**
*Palpation of:*
- spinous processes, paravertebral muscles, posterior superior iliac spine
- femoral stretch test (reversed Lasègue sign)

In the standing position, the **most important aspects** to observe are:

- coronal balance
- sagittal balance
- sagittal profile
- muscle atrophies

Search for sagittal and coronal imbalance

While the diagnosis of a coronal imbalance is easy to make with the plumbline deviated off the intergluteal groove, the assessment of the sagittal profile is not as obvious. A normal sagittal balance is present if the plumbline runs from the external acoustic meatus down to the acromion, greater trochanter, lateral condyle of the knee and the lateral malleolus. More difficult is the definition of the sagittal profile because of the high individual variability [3]. A thoracic kyphosis of 20–60 degrees is usually regarded as normal [3]. The definition of normal lumbar or cervical lordosis is even more controversial. The normal range in the literature for cervical lordosis (C2–7) ranges from 20 to 35 degrees [14]. However, Grob et al. [14] did not find a significant difference between patients with neck pain compared to healthy individuals with regard to the global curvature, the segmental angles, or the incidence of straight-spine or kyphotic deformity. In a recent study, the lumbar lordosis of young adult volunteers ranged from 26 to 76 degrees with an average of 46 degrees [31]. The sagittal profile should be noted but the **sagittal balance** is more important (Fig. 4). In particular, an anterior imbalance can only be compensated poorly. The spinal muscles must counteract this imbalance and thereby fatigue, which often results in severe pain. It is important to explore the sagittal imbalance in more detail and separate a global trunk imbalance from a head protraction (anterior shifting of the cervical spine). The anterior imbalance has a great impact because it increases the risk of progressive thoracic kyphosis (e.g. in patients with multiple osteoporotic fractures). Similarly, a severe double major scoliosis which is in balance is much less a clinical problem than a decompensated moderate size thoracic curve.

Sagittal disbalance is a frequent cause of back pain

A coronal dysbalance can cause pain in idiopathic scoliosis

The importance of a systematic inspection for **muscle atrophies** is self-evident. Furthermore, the presence of the following **deformity relevant aspects** should be noted during inspection:

- shoulder and pelvis level
- pelvic rotation
- thoracic asymmetry
- waist asymmetry
- rib and lumbar hump (during standing and forward flexion)
- trunk shift (disc herniation)
- spinous process step-off (spondylolisthesis)

In the forward flexed position, any asymmetries of the back contour and leg length discrepancy become more obvious. **Rib hump and lumbar hump** should be assessed either in millimeters or degrees. Leg length discrepancy with consecutive imbalance of the pelvis can be leveled with a wooden board of known height under the foot of the shorter leg to determine the amount.

The finger-floor distance is independent of lumbar mobility

The **finger floor distance** is not a measure of the mobility of the lumbar spine but of the hips and limited by the hamstring muscles. Tight hamstrings in an adolescent with a recent onset of back pain may indicate a spondylolysis/spondylolisthesis.

Sagittal spinal range of motion can be assessed with the Schober and Ott tests

The range of lumbar motion can be assessed during forward flexion with the so-called **Schober test**. A skin mark is made over the spinous process of S1 and 10 cm above. A normal lumbar range is present when the distance between the upper and lower skin mark increases from 10 to over 15 cm (documented as 10/15 cm) during forward flexion. The **Ott test** or thoracic Schober test is an equiva-

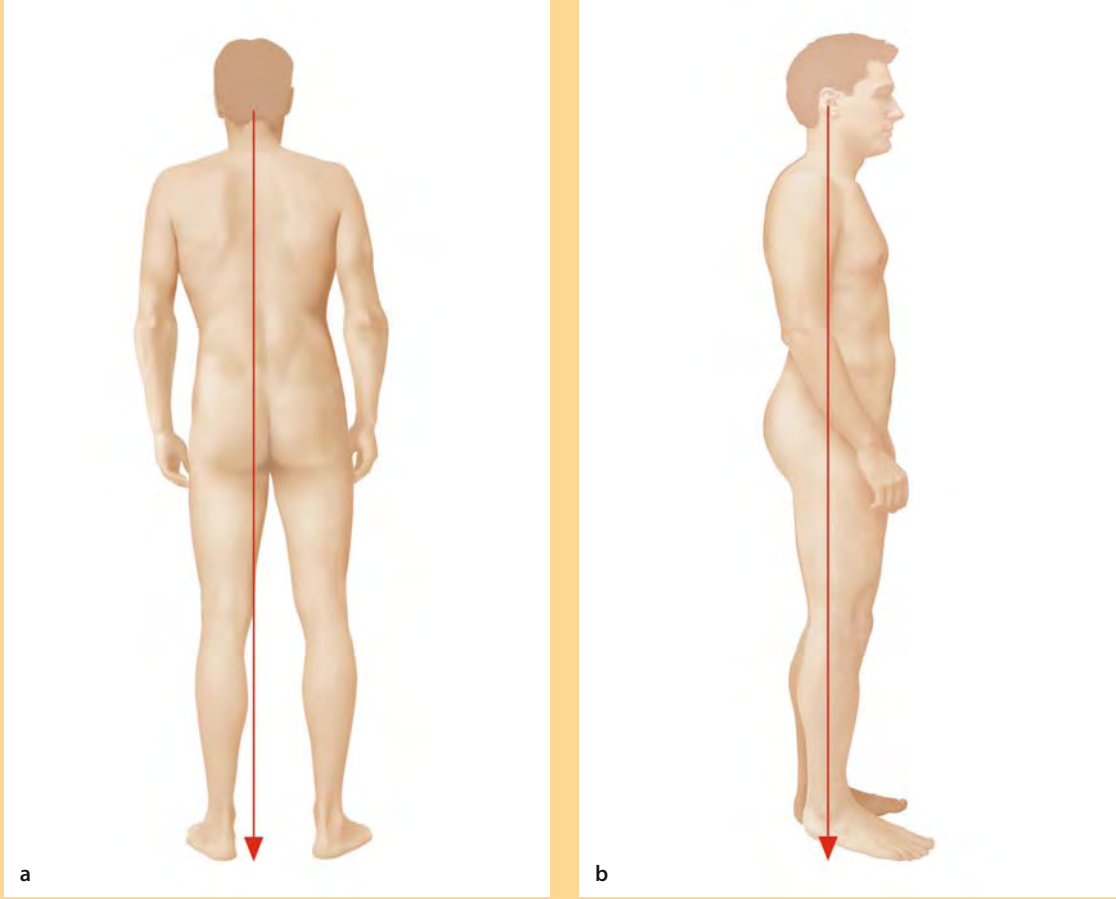


**Figure 4. Coronal and sagittal balance**

a In the coronal plane the gravity line should fall in the rima ani and between both feet. b In the sagittal plane the gravity originating from the external auditory canal should run along the acromion, greater trochanter, lateral knee condyle and lateral malleolus.

lent test for thoracic spine mobility. A skin mark is made at the spinous process of C7 and a second mark 30 cm below. The distance should range up to 38 cm (documented as 30/38 cm). However, both reproducibility and diagnostic value remain debatable. An important observation is to document an abnormal spinal motion pattern when the patient becomes erect from the forward flexed position. Some patients need the support of their hands on the thigh to straighten up again. This may indicate an underlying segmental instability.

The **motion of the lumbar spine** is best tested with hands crossed behind the neck (Fig. 5). The following **movements** should be tested:

- side bending
- side rotation
- backward bending
- backward bending with rotation

Repetitive motions can provoke typical symptoms

A precise and reproducible assessment is not possible. Therefore, we prefer to semiquantitatively estimate how much these movements are limited (reduced by a quarter, half, etc.). More important than the range of motion is the provocation of symptoms. Side rotation and backward bending stresses more the facet joints,

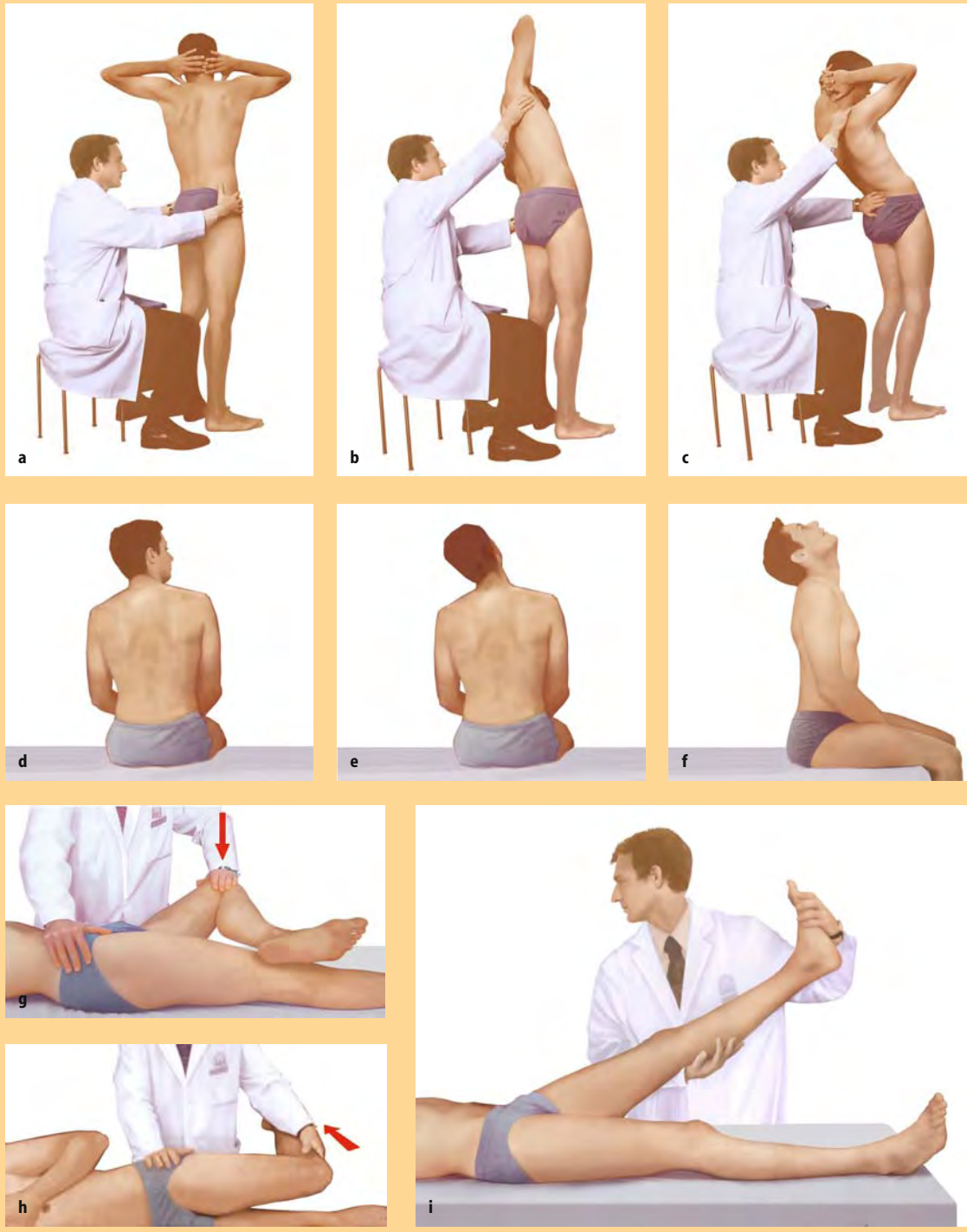


**Figure 5. Physical assessments**

a Lumbar spine: a left/right side rotation; b left/right side bending; c backward bending. Cervical spine: d left/right side rotation; e left/right side bending; f backward bending. g Patrick test; h Mennel test; i Lasègue test

while side and forward bending stresses more the intervertebral discs. Pain provocation during these movements may therefore be indicative of an underlying pathology of these structures. **Repetitive tests** may be useful in this context. In patients with disc herniation, side rotation and backward bending is likely to increase the pain because this test narrows the lumbar foramen.

Repetitive testing may disclose a subtle muscle weakness

A **global functional test** of the motor force of the lower extremities is applied when the patient is asked to jump on one leg. This ability excludes a relevant paresis of the lower extremities because all muscle groups are activated. Patients frequently present with only subtle motor weakness, which is often not detected during routine examination. A subtle weakness of the gastrocnemius muscle (S1) can be detected by standing on one leg with repetitive (e.g. 10 times on each side) tiptoe standing (**McNab's test**). A similar test for the quadriceps muscle (L3 – 4) is repetitive stool climbing. A subtle weakness will present with an earlier fatigue.

Repetitive tiptoe standing can reveal a subtle weakness

## Sitting

The cervical spine is best examined when the patient is sitting on an examination table with their lower limbs and feet freely moving. In contrast to the lumbar spine, **palpation** of bony landmarks is easier in the cervical spine. The examiner should palpate:

- spinous processes C2 – 7
- transverse process of C1
- mastoid process
- facet joints

Always palpate where it is most painful mainly for psychological reasons

The palpation of the paravertebral muscles or osseous processus is seldom of diagnostic value but reasonable from a psychological point of view. If the examiner does not palpate the often painful muscles and provoke pain, the patient may get the impression that they are not being thoroughly examined. Palpation must include the supraclavicular fossae (enlarged lymph nodes, tumor, cervical rib) and the anterior structures (including the thyroid gland).

**Functional testing** of the cervical spine begins with the measurement of the chin sternum distance. This measure is useful to document the clinical course but not so much as an objective parameter. The **assessment of the mobility** of the cervical spine consists of:

- flexion/extension (chin-sternum distance: documentation, e.g. 2/18 cm)
- left/right rotation (normal: 60° – 0 – 60°) in neutral position
- left/right rotation (normal: 30° – 0 – 30°) in flexed position
- left/right rotation (normal: 40° – 0 – 40°) in extended position
- left/side bedding (normal: 40° – 0 – 40°)

Cervical spine motion is examined with active and passive motion and against resistance

In flexion, rotation only occurs at the upper cervical spine because the facet joints of the lower cervical spine are flexed and there the facet joint capsules are stretched resisting rotation. In extension the upper cervical spine joints are blocked only permitting rotation in the lower cervical spine. Differences in pain provocation in the flexed and extended position may indicate the level of pathology. In the case of limitation of active movements, the examination is repeated with **passive motion** to differentiate between a soft (muscle, pain) and a hard (bony) stop. Beside the assessment of the motion, the provocation of pain is recommended. This can be enhanced by examining the cervical spine **against resistance** and stresses the intervertebral discs (flexion, side bending) or facet joints (rotation, extension), respectively.

If a **cervical radiculopathy** is suspected, the following tests can be carried out to provoke the patients' radicular symptoms (Fig. 6):

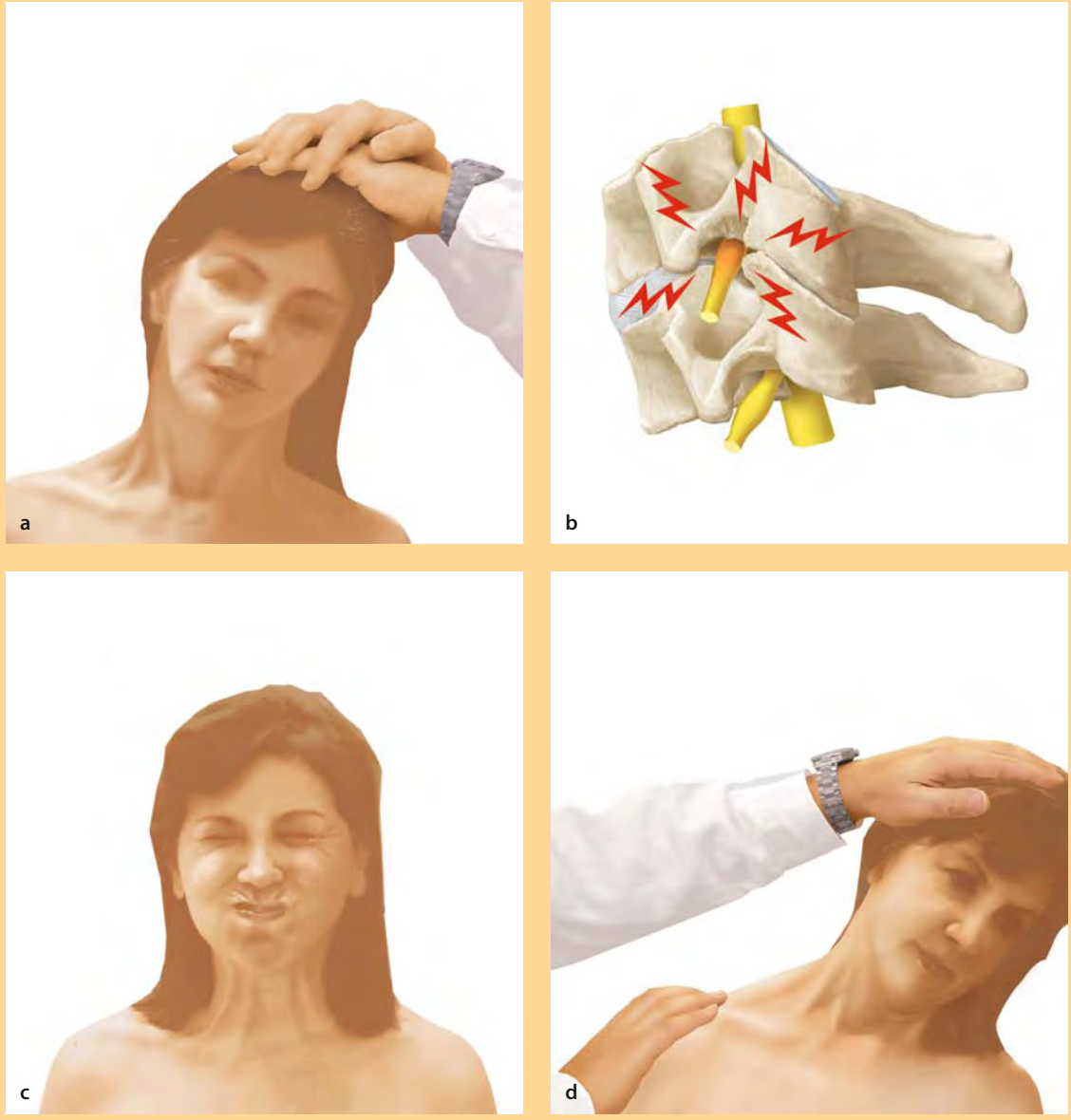


**Figure 6. Provocation tests for cervical radicular pain**

a **Spurling's test**: continuous (30–60 s) pressure is applied in different head positions (left/right side bending or rotation in neutral position, flexion and extension). b Depending on the target level the different rotation positions further narrow the spinal foramen and may elicit typical radicular pain. c **Valsalva maneuver**: this test may elicit pain by increasing the intradural pressure. d **Shoulder depression test**: this test stretches an affected nerve root and may cause radicular arm pain.

- Spurling's test
- Valsalva maneuver
- shoulder depression test

Consider thoracic outlet syndrome in the case of arm pain

In the case of a potential differential diagnosis of **thoracic outlet syndrome**, Adson's and the Roos tests can be carried out. **Adson's test** consists of hyperextending the neck and turning the head to the affected side while holding breath. The maneuver leads to a decrease of the radial pulse and tingling in the hand. The **Roos test** is carried out with both arms 90 degrees abducted and externally

rotated. The individual rapidly opens and closes the hand for 3 min. The test is positive if the hand becomes pale or blue and the maneuver provokes the typical symptoms.

A thorough neurological examination is compulsory

The **neurological assessment** can be best performed with the patient either in the supine or the seated position. We prefer the latter position because it allows for a better testing of muscle force (e.g. shoulder abduction, hip flexion, knee extension). A prerequisite for a thorough neurological assessment is a profound knowledge of the dermatomal (Fig. 1) and peripheral (Fig. 2) skin innervation. Multiple sensory qualities (heat–cold, pain, touch, pressure, static and dynamic two-point discrimination, vibration sensation) can be distinguished. The most important examinations are:

- light touch
- pin prick
- proprioception

**Light touch** can still be preserved in the presence of nerve root compression when pin prick is already decreased (see Chapter 11). The cross-over innervation for pain is much less pronounced than for the sensory quality of light touch. The assessment of proprioception (vibration) is important in the differential diagnosis of radiculopathy and peripheral neuropathy. Each dermatome must be systematically assessed in order to allow for a differential diagnosis of a radicular vs. a peripheral neuropathy.

The assessment of each **key muscle** and **tendon reflex** (Table 6) can easily be done in the seated position. A differential diagnosis of peripheral nerve palsies is necessary and diagnosis can be done clinically in many cases (Fig. 7). However, the differential diagnosis can sometimes be very difficult and require

**Table 6.** Motor innervation and muscle tendon reflexes

| Nerve root | Muscle | Reflex | Differential diagnosis for peripheral neuropathy |
|---|---|---|---|
| C3/4 | diaphragm<br>deltoid muscle | deltoid reflex (inconsistent) | phrenic nerve (tumor) |
| C5 | deltoid muscle, biceps muscle | biceps reflex | axillary nerve<br>musculocutaneous nerve (normal innervation of the brachioradialis muscle, normal sensation of the thumb) |
| C6 | biceps muscle extensor carpi muscle | biceps reflex, brachioradial reflex | musculocutaneous nerve<br>radial nerve |
| C7 | triceps, wrist flexors, finger extensors | triceps reflex | median nerve (carpal tunnel syndrome, disturbed sweat secretion) |
| C8 | abductor digiti minimi muscle<br>interossei muscles | – | ulnar nerve (sharp sensory deficit of the ulnar half of the ring finger) |
| L2 | iliopsoas muscle (hip flexion) | adductor reflex (inconsistent) | obturator nerve |
| L3 | quadriceps muscle | patellar tendon reflex | lateral cutaneous nerve (meralgia paresthetica – normal motor function) |
| L4 | tibialis anterior | patellar tendon reflex | femoral nerve (intact innervation of the saphenous nerve) |
| L5 | extensor hallucis longus muscle, gluteus medial muscle | tibialis posterior reflex (inconsistent) | peroneal nerve (intact hip abduction) |
| S1 | peroneus brevis, triceps muscle | Achilles | tibial nerve (extensor hallucis longus weakness) |

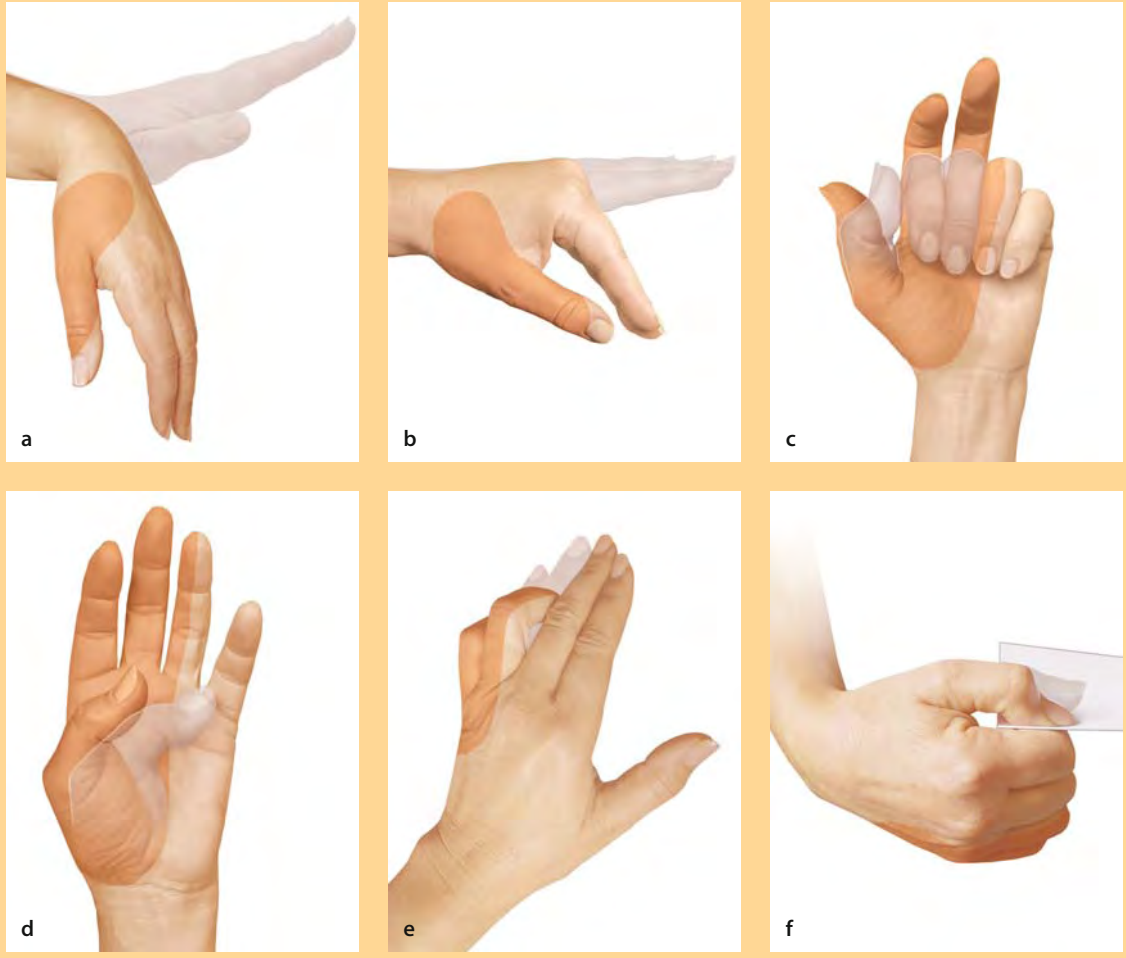


**Figure 7. Peripheral nerve palsies**

a, b **Radial nerve palsy**: The patient is unable to extend a his wrist and b fingers in the metacarpophalangeal joints. c **Median nerve palsy**: inability to close the hand to a fist to firmly grip a bottle and d to oppose the thumb and fingertips. e **Ulnar nerve palsy**: hyperextension of the metacarpophalangeal joints of the ring and little finger indicates a paralysis of the intrinsic muscles and f inability to adduct the thumb without flexion of the interphalangeal joints (Froment's sign). Note the autonomic regions of innervation for the respective nerves (darker color).

**Table 7.** Clinical motor strength grading

| Motor grade | Findings |
|---|---|
| 5 | full movement against full resistance |
| 4 | full movement against reduced resistance |
| 3 | full movement against gravity alone |
| 2 | full movement only if gravity eliminated |
| 1 | evidence of muscular contractions or fasciculations |
| 0 | no contractions or fasciculations |

detailed neurological assessments and neurophysiological studies for further differentiation (see Chapters 11, 12). The muscle force should be assessed according to a standardized protocol either following the guidelines of the British Medical Research Council (Table 7) or as modified by the ASIA Standards (see Chapter 11).

## Lying Supine

In the supine position, the **neurological examination** can be completed with regard to the assessment of:

- muscle strength [dorsiflexion of the foot (L4) and greater toe (L5)]
- muscle strength for inversion (L5) and eversion (S1) of the foot
- long tract signs (Babinski, Gordon, Oppenheimer, Rossolimo, see Chapter 11)
- abdominal reflexes (see Chapter 11)
- presence of any spasticity of the lower extremities (see Chapter 11)
- Lhermitte sign
- Straight leg raising test

Radicular pain provocation is the key aspect of the Lasègue sign

The **Lhermitte sign** is provoked by forceful flexion of the head. The test is positive if the patient has a sensation of electrical shocks in the body and lower extremities. This sign is indicative of a severe spinal cord compression. There is a plethora of descriptions of the **Lasègue sign** (test). We regard the test as positive in the presence of radicular leg pain. It is important to precisely ask the patient what they are experiencing while the straight leg is raised. We always note the elevation degree when radicular pain is experienced. Any other sensation than radicular pain is not regarded as a true Lasègue sign and can be described as a **pseudolasègue sign**. The latter sign does not exclude the presence of a radiculopathy but is often caused by a severe muscle spasm. Most frequently, the patient is just experiencing tension in the popliteal fossa as a result of tight hamstrings. A **cross-over sign** is present when the patient experiences radicular pain in the affected leg while raising the contralateral leg and is highly predictive of a large median disc herniation [18].

Do not overlook a hip joint disorder

While the patient is in the supine position, the hips should be examined so as not to overlook a **hip pathology**, which is frequent in elderly patients. The diagnosis of an affection of the **sacroiliac joint** is very difficult clinically because this joint is not easily accessible. It is possible to compress or distract the sacroiliac joint and provoke pain in the case of an affection. However, we can also use the femur as a lever to move the sacroiliac joint. The so-called **Patrick test** is performed by flexing the ipsilateral hip and knee and placing the external malleolus of the ankle over the patella of the opposite leg. The examiner gently pushes the ipsilateral knee down until a hard resistance is felt. At this point, the examiner gives a short impulse on the ipsilateral knee, i.e. pushing it towards the examination table. The test is positive if the patient feels the usual buttock pain (Fig. 5).

The examination in the supine position is completed by assessing the arterial pulses with regard to an important differential diagnosis of neurogenic claudication.

## Lying on Left/Right Side

Hip abduction differentiates L5 radiculopathy and peroneal nerve palsy

The patient is asked to lie on their left and right side, respectively. In this position, the **hip abduction** is tested with the lower knee flexed and the upper knee extended. Normal hip abduction force (L5) in the presence of a foot drop is indicative of a paresis of the peroneal nerve (Case Introduction).

In this position, a further test for sacroiliac joint affection can be done (**Mennell test**). The upper hip is extended and the knee flexed. The examiner places one hand on the ipsilateral hip and with the other hand extends the hips gently until a hard stop is felt. At this point the examiner gives a short impulse by pulling the leg in more extension. The test is positive if the patient feels the usual buttock pain.

In the lateral position, the perianal sensitivity and sphincter tone can be tested to rule out a cauda equina syndrome.

## Lying Prone

In this position, the **reversed Lasègue sign** or femoral stretch test can assess lumbar disc herniations at higher levels (L2–4). The test is positive if extension of the straight leg is causing anterior thigh pain. It is important to perform the test with the leg straight, because flexion of the knee stretches the quadriceps muscle, which makes it difficult to separate neural and muscular pain.

The reversed Lasègue sign is tested with the leg extended

Finally, the spinous processes, paraspinal muscles and the posterior superior iliac spine can be palpated. Although this examination seldom provides a clue for the underlying pathology, it is psychologically important as outlined above.

Palpation is rarely diagnostic

## Abnormal Illness Behavior

If there is some doubt regarding the severity or genuineness of the patient's complaints, not only the patient's pain drawing [26] will show frank exaggeration or non-anatomic pain patterns [38], but several tests might also be useful in this setting. Waddell [36, 39] described **five signs** to help reveal functional overlay in back pain patients.

Positive Waddell signs suggest non-organic causes of symptoms

- presence of widespread superficial tenderness
- pain on axial loading or simulated rotation
- postural differences in straight leg raising test
- regional non-anatomic sensory/motor disturbances
- overreaction (crying out, facial expression, sweating, collapsing)

Vertical compression on the head in the standing position is not translated to the lumbar spine. When the patient is standing and presses their arms firmly against the greater trochanters, the first 30 degrees of rotation occur in the hip joints. Both tests therefore should not cause low-back pain unless psychological overlay is present. Large differences (< 20 degrees) of the straight leg raising test between sitting and lying cannot be explained pathoanatomically and are indicative of abnormal illness behavior.

## Reproducibility

It is important to note that findings during history taking and physical assessment are hampered by a poor or only modest reproducibility. This has to be borne in mind when using this data for outcome evaluation and scientific projects [4, 20, 24, 28, 32, 33, 40]. The reproducibility of history of having ever experienced back pain has been reported to be around 80% [4, 40]. The same has been found for **pain drawings** made by patients [19]. Retrospective data obtained by means of subjective patient statements should be handled with great caution. With regard to physical signs, only a few studies have addressed the issue of reproducibility [4, 20, 22, 24, 29]. McCombe found that reliable signs consisted of measurements of lordosis and flexion range, determination of pain on flexion and lateral bend, nearly all measurements associated with the straight leg raising test, determination of pain location in the thigh and legs, and determination of sensory changes in the leg [20].

The reproducibility of history and physical findings is limited

## Differential Diagnosis of Spinal Pain Syndromes

The differential diagnosis of spinal disorders in general and low-back pain particularly is far reaching. The differential diagnosis of spinal pain syndromes includes neoplasia, infection, inflammatory disease, as well as pelvic organ disorders, and renal and gastrointestinal disorders. Jarvik and Deyo differentiate non-mechanical spinal conditions and visceral disease (Table 8) from mechanical low-back pain in the differential diagnosis of low-back pain [8, 17].

**Table 8.** Differential diagnosis of low-back pain

| Non-mechanical spinal conditions (1 %) | Visceral disease (2 %) |
|---|---|
| *Neoplasia (0.7 %)*<br>• multiple myeloma<br>• metastatic carcinoma<br>• lymphoma and leukemia<br>• spinal cord tumors<br>• retroperitoneal tumors<br>• primary vertebral tumors | *Pelvic organ involvement*<br>• prostatitis<br>• endometriosis<br>• chronic inflammatory disease<br>• chronic pelvic inflammatory disease |
| *Infection (0.01 %)*<br>• osteomyelitis<br>• septic discitis<br>• paraspinous abscess<br>• epidural abscess | *Renal involvement*<br>• nephrolithiasis<br>• pyelonephritis<br>• perinephric abscess |
| *Inflammatory arthritis (0.3 %)*<br>• ankylosing spondylitis<br>• psoriatic spondylitis<br>• Reiter syndrome<br>• inflammatory bowel disease | *Gastrointestinal involvement*<br>• pancreatitis<br>• cholecystitis<br>• penetrating ulcer |
| *Paget disease* | *Aortic aneurysm* |

Figures in parenthesis indicate estimated percentage of patients with these conditions among all adult patients with signs and symptoms of low-back pain according to Jarvik and Deyo [17]

### Recapitulation

**History.** The high rate of benign self-limiting low-back and neck pain can disguise serious underlying causes of spinal pain. The most important task of the clinical assessment is to **rule out serious illness** indicated by the so-called **red flags**, i.e., features of cauda equina syndrome, severe worsening pain (especially at night or when lying down), significant trauma, fever, unexplained weight loss, history of cancer, patient over 50 years of age, and use of intravenous drugs or steroids. Tumors and infections must be ruled out. Furthermore, a **relevant paresis** (motion of the extremity against gravity impossible) must be detected early and treated. After red flags are ruled out, the clinical assessment focuses on the three major complaints which lead patients to seek medical help, i.e. pain, functional impairment, and spinal deformity. The most important differentiation of pain is the distribution between central (back/neck) and peripheral pain (leg/arm). **Radicular pain** must be distinguished from **axial** (central) pain. Radicular pain is usually attributable to a pathomorphological correlate. Pain intensity should be assessed with a visual analogue scale. The assessment of **positional** and **activity modulators of spinal pain** is very helpful for further differential diagnosis of the pain syndrome. Physical impairment should be differentiated from disability and handicap. The history of patients with **spinal deformity** should include the assessment of spinal deformities requiring some specific additional information from the patient (or parents). The patients should be explored with respect to: family history, course of pregnancy and delivery, developmental milestones (onset of walking, speaking,

etc.), fine motor skills, tendency to fall (clumsiness), onset of menses, and evidence of metabolic or neuromuscular disorders.

**Examination.** The physical examination is performed with the patient in different positions, i.e. walking, standing, sitting, lying supine, lying on the left/right side, lying prone. During **walking** the presence of a limp, ataxia, and muscle force (walking on hips/tiptoes) is assessed. The most important aspect for the examination in the **standing position** is the assessment of the sagittal and coronal balance. The sagittal profile (lordosis/kyphosis) is largely variable. **Finger floor distance** is an assessment of the hip flexion and muscle stretch. Repetitive testing of a motion (tiptoe standing, stepping up on a stool) may disclose a subtle muscle weakness. In the **seated position**, the examination for sensory deficits, muscle weaknesses and tendon reflexes is facilitated. Similarly, the examination of the cervical spine is best performed with the patient in this position. Rotation in flexion examines the upper cervical spine and rotation in extension of the lower cervical spine. In the seated position **radicular provocation tests** (Spurling's test, Valsalva maneuver, and shoulder depression test) can be performed to provoke typical radicular pain. In the supine position, the straight leg raising test (Lasègue sign) is performed. The most important read-out of this test is the provocation of radicular pain, which is pathologically independent of the degree of hip flexion. Elicited non-radicular pain can be classified as a pseudolasègue sign. The assessment of hip and sacroiliac joint function as well as vascular status should not be forgotten. In the **left/right side position**, assessment of the hip abduction force is important for a differential diagnosis of L5 radiculopathy and peroneal nerve palsy. In this position, the perianal sensitivity and sphincter tonus are best assessed. In the **prone position**, the reversed Lasègue sign (for nerve root compromise, L2 – 4) can be tested. The palpation of the dorsal and lumbar spine is hardly ever diagnostic but should not be discarded for psychological reasons. The assessment of abnormal **illness behavior** is mandatory. In general, the reproducibility of history taking and physical examination is limited. The differential diagnosis of spinal pain syndromes includes cancer, infection, inflammatory disease, as well as pelvic organ disorders, and renal and gastrointestinal disorders.

## Key Articles

**Biering-Sorensen F, Hilden J (1984) Reproducibility of the history of low-back trouble. Spine 9:280 – 6**
This paper reports on the reproducibility of auto-anamnestic information concerning low back trouble. The authors found that within a year, only 84 % of people recall ever having had back pain, which the authors explained by forgetfulness. They made the statement that data obtained by means of subjective statements should be handled with caution.

**Deyo RA, Rainville J, Kent DL (1992) What can the history and physical examination tell us about low back pain? JAMA 268:760 – 5**
Excellent overview article on important findings during history taking and physical assessment.

**Vroomen PC, de Krom MC, Wilmink JT, Kester AD, Knottnerus JA (2002) Diagnostic value of history and physical examination in patients suspected of lumbosacral nerve root compression. J Neurol Neurosurg Psychiatry 72:630 – 4**
This paper deals with patient characteristics, symptoms, and examination findings in the clinical diagnosis of lumbosacral nerve root compression. Various clinical findings were found to be associated with nerve root compression on MR imaging, i.e. the tests tended to have a lower sensitivity and specificity than previously reported. The straight leg raise test was not predictive. Most of the diagnostic information revealed by physical examination findings had already been revealed by the history items.

**Spratt KF, Lehmann TR, Weinstein JN, Sayre HA (1990) A new approach to the low-back physical examination. Behavioral assessment of mechanical signs. Spine 15:96 – 102**
This study systematically explores the test-retest reliability, a low-back physical examination tool. Patients' reports of pain location were quite stable across time but reports of

pain aggravation were generally less consistent across time than were later observed pain behaviors.

**Waddell G, McCulloch JA, Kummel E, Venner RM (1980) Nonorganic physical signs in low-back pain. Spine 5:117 – 25**
Landmark article on the clinical significance of non-organic signs in low-back pain.

## References


1. Anonymous (2004) New Zealand Acute Low Back Pain Guide. In: ACC Accident Compensation Corporation, ed. Wellington, New Zealand
2. Badley EM (1995) The genesis of handicap: definition, models of disablement, and role of external factors. Disabil Rehabil 17:53 – 62
3. Bernhardt M, Bridwell KH (1989) Segmental analysis of the sagittal plane alignment of the normal thoracic and lumbar spines and thoracolumbar junction. Spine 14:717 – 21
4. Biering-Sorensen F, Hilden J (1984) Reproducibility of the history of low-back trouble. Spine 9:280 – 6
5. Cassidy JD, Carroll LJ, Cote P (1998) The Saskatchewan health and back pain survey. The prevalence of low back pain and related disability in Saskatchewan adults. Spine 23:1860 – 6; discussion 1867
6. Cote P, Cassidy JD, Carroll L (1998) The Saskatchewan Health and Back Pain Survey. The prevalence of neck pain and related disability in Saskatchewan adults. Spine 23:1689 – 98
7. Déjerine (1914) Sémiologie du Système Nerveux. Paris: Masson
8. Deyo RA (1986) Early diagnostic evaluation of low back pain. J Gen Intern Med 1:328 – 38
9. Deyo RA, Rainville J, Kent DL (1992) What can the history and physical examination tell us about low back pain? JAMA 268:760 – 5
10. Deyo RA, Weinstein JN (2001) Low back pain. N Engl J Med 344:363 – 70
11. Duus P, Bähr M, Frotscher M (2005) Topical diagnosis in neurology. Anatomy, physiology, signs, symptoms. Stuttgart: Thieme
12. Fairbank JC, Couper J, Davies JB, O'Brien JP (1980) The Oswestry Low Back Pain Disability Questionnaire. Physiotherapy 66:271 – 3
13. Fairbank JC, Hall H (1990) History taking and physical examination: Identification of syndromes of back pain. In: Weinstein JN, Wiesel SW, eds. The lumbar spine. Philadelphia: Saunders Company, 88 – 106
14. Grob D, Frauenfelder H, Mannion AF (2007) The association between cervical spine curvature and neck pain. Eur Spine J 16:669 – 678
15. Hart LG, Deyo RA, Cherkin DC (1995) Physician office visits for low back pain. Frequency, clinical evaluation, and treatment patterns from a U.S. national survey. Spine 20:11 – 9
16. IASP Task Force on Taxonomy (1994) Classification of chronic pain. In: Merskey H, Bogduk N, eds. Seattle: IASP Press, 209 – 214
17. Jarvik JG, Deyo RA (2002) Diagnostic evaluation of low back pain with emphasis on imaging. Ann Intern Med 137:586 – 97
18. Kosteljanetz M, Bang F, Schmidt-Olsen S (1988) The clinical significance of straight-leg raising (Lasegue's sign) in the diagnosis of prolapsed lumbar disc. Interobserver variation and correlation with surgical finding. Spine 13:393 – 5
19. Margolis RB, Tait RC, Krause SJ (1986) A rating system for use with patient pain drawings. Pain 24:57 – 65
20. McCombe PF, Fairbank JC, Cockersole BC, Pynsent PB (1989) 1989 Volvo Award in clinical sciences. Reproducibility of physical signs in low-back pain. Spine 14:908 – 18
21. Melzack R (1987) The short-form McGill Pain Questionnaire. Pain 30:191 – 7
22. Million R, Hall W, Nilsen KH, Baker RD, Jayson MI (1982) Assessment of the progress of the back-pain patient 1981 Volvo Award in Clinical Science. Spine 7:204 – 12
23. Mooney V (1987) Impairment, disability, and handicap. Clin Orthop Relat Res:14 – 25
24. Nelson MA, Allen P, Clamp SE, de Dombal FT (1979) Reliability and reproducibility of clinical findings in low-back pain. Spine 4:97 – 101
25. Niemelainen R, Videman T, Battie MC (2006) Prevalence and characteristics of upper or mid-back pain in Finnish men. Spine 31:1846 – 9
26. Ransford A, Cairns D, Mooney V (1976) The pain drawing as an aid to the psychologic evaluation of patients with low-back pain. Spine 1:127 – 134
27. Roland M, Morris R (1983) A study of the natural history of back pain. Part I: development of a reliable and sensitive measure of disability in low-back pain. Spine 8:141 – 4
28. Spratt KF, Lehmann TR, Weinstein JN, Sayre HA (1990) A new approach to the low-back physical examination. Behavioral assessment of mechanical signs. Spine 15:96 – 102

29. Strender LE, Sjoblom A, Sundell K, Ludwig R, Taube A (1997) Interexaminer reliability in physical examination of patients with low back pain. Spine 22:814 – 20
30. van Tulder M, Becker A, Bekkering T, Breen A, del Real MT, Hutchinson A, Koes B, Laerum E, Malmivaara A (2006) Chapter 3. European guidelines for the management of acute nonspecific low back pain in primary care. Eur Spine J 15 Suppl 2:S169 – 91
31. Vaz G, Roussouly P, Berthonnaud E, Dimnet J (2002) Sagittal morphology and equilibrium of pelvis and spine. Eur Spine J 11:80 – 7
32. Viikari-Juntura E, Takala EP, Riihimaki H, Malmivaara A, Martikainen R, Jappinen P (1998) Standardized physical examination protocol for low back disorders: feasibility of use and validity of symptoms and signs. J Clin Epidemiol 51:245 – 55
33. Vroomen PC, de Krom MC, Wilmink JT, Kester AD, Knottnerus JA (2002) Diagnostic value of history and physical examination in patients suspected of lumbosacral nerve root compression. J Neurol Neurosurg Psychiatry 72:630 – 4
34. Waddell G (1987) Clinical assessment of lumbar impairment. Clin Orthop Relat Res:110 – 20
35. Waddell G, Allan DB, Newton M (1991) Clinical evaluation of disability in back pain. In: Frymoyer JW, ed. The adult spine: principles and practice. New York: Raven Press, 155 – 168
36. Waddell G, Bircher M, Finlayson D, Main CJ (1984) Symptoms and signs: physical disease or illness behaviour? Br Med J (Clin Res Ed) 289:739 – 41
37. Waddell G, Main CJ (1984) Assessment of severity in low-back disorders. Spine 9:204 – 8
38. Waddell G, Main CJ, Morris EW, Di Paola M, Gray IC (1984) Chronic low-back pain, psychologic distress, and illness behavior. Spine 9:209 – 13
39. Waddell G, McCulloch JA, Kummel E, Venner RM (1980) Nonorganic physical signs in low-back pain. Spine 5:117 – 25
40. Walsh K, Coggon D (1991) Reproducibility of histories of low-back pain obtained by self-administered questionnaire. Spine 16:1075 – 7

# 9 Imaging Studies

Marius R. Schmid, Jürg Hodler

## Core Messages

- ✔ Standard radiographs obtained with the patient in the upright position represent the basis of imaging
- ✔ In standard radiography, the role of special views is decreasing because CT and MR imaging more easily provide relevant additional information
- ✔ MR imaging is the most commonly used advanced imaging method and is the method of choice in suspected disc abnormalities, tumors, infection, abnormalities of the spinal cord and other abnormalities
- ✔ MR imaging may occasionally be misleading because it demonstrates findings that are also found in asymptomatic individuals and – therefore – may not be clinically relevant
- ✔ Intravenous contrast administration is useful in MR imaging of infection, systemic inflammation, neoplasm, and vascular malformation and in postoperative imaging
- ✔ Advances can still be expected in MR imaging including fast whole-spine imaging, improved spatial resolution, spectroscopy, and functional imaging of the spinal cord
- ✔ CT retains an important role in assessment of trauma but may not reliably demonstrate disco-ligamentous injuries
- ✔ Ultrasonography has a limited role in imaging of the spine but may occasionally be indicated, such as for demonstration of paravertebral soft tissue abnormalities, vessels adjacent to the spine and for image guided interventions
- ✔ Bone scans are still useful for the assessment of bone abnormalities (activity of disease, staging for widespread disease, follow-up studies). The role of PET, PET-CT and SPECT-CT remains to be determined

## Imaging Methods

### Standard Radiographs

Digital systems can reduce radiation dose and retakes

Standard radiographs still represent the basis of spinal imaging. They can be obtained with a number of techniques: Conventional film/screen combination is an analogue technique which is still widely used in small hospitals and practitioners' offices. Most radiology institutions, however, use digital systems, i.e.,

- computed radiology (CR) systems or
- digital radiography (DR) systems

**CR systems** are based on phosphor plates which are sensitive to X-ray beams. They are placed in cassettes which are similar in design and size to the cassettes used for the old film-screen systems. After exposure, the cassette is transferred to a digitizer which reads the latent information contained within the phosphor plate and provides a digital image in the widely used **DICOM** 3 format (DICOM stands for Digital Imaging and Communications in Medicine). DICOM standardizes the handling, storing and transmitting the information of medical images.

DICOM images can be printed on hard copies or paper, or they can be distributed by a digital **PACS** (Picture Archiving and Communication System).

Digital systems are becoming the new standard

**DR systems** use flat panel detectors, which replace the cassettes used in film-screen and CR systems. They can be placed on existing classical radiographic tables, may be mounted on dedicated equipment or are available as portable devices. They directly acquire a digital image of high resolution after exposure. The image appears on a screen installed in the examination room and is visible within a few seconds while the patient is still available in the room for any repeat exposures. The images can then directly be sent to a **PACS system**, or alternatively they can be printed on film or paper. Because no cassettes have to be transferred, this system is much faster than film-screen or CR equipment. Similarly to CR, DR is less sensitive with regard to exposure errors than film-screen systems. Although the originally expected reduction in X-ray exposure has not been completely achieved, the digital systems allow some reduction of dose and reduce the number of repeat examinations.

Patient positioning, beam angulation, film-focus and object-film distances are identical for all three methods.

## Lumbar Spine

Standard radiographs (anteroposterior, lateral) remain the basic imaging studies

Upright anteroposterior and lateral radiographs represent the basis of imaging of the lumbar spine. Film-focus distance typically is 115 cm for over-couch tubes with grid tables and 150 cm for vertical stands. The beam is centered 2 cm above the iliac crest. Additional radiographs are not routinely acquired because they have been replaced by magnetic resonance (MR) imaging or computed tomography (CT). The so-called **Barsony projection** has not been consistently described but typically consists of a radiograph centered at the sacrum (with a 15° to 20° caudocranial angulation of the beam (in order to be approximately perpendicular to the sacrum and sacroiliac joints). Anteroposterior **oblique radiographs** with the entire patient rotated by 45° to both sides used to be employed for the demonstration of spondylolysis but are at least in part replaced by CT ("reversed angle" technique or sagittal reformatted images from thin sectioned axial source images). MR imaging may also be used for this purpose.

Positional radiographs do not reliably demonstrate spinal instability

**Positional radiographs** are typically obtained in the lateral projection with the spine in flexion and extension. For flexion radiographs, the patient is asked to bend forward with the pelvis in the center or slightly posterior to the center of the cassette. For extension radiographs, a back support is useful in order to allow the patient to lean backwards. The pelvis is located slightly anterior to the center of the film in extension radiographs. Lateral bending anteroposterior views are less commonly employed but may be useful for certain indications such as surgical planning in scoliosis. The role of positional radiographs in assessing instability has been debated due to a lack of consistent criteria for this diagnosis.

## Thoracic Spine

In the thoracic spine, anteroposterior and lateral radiographs are most commonly employed. They are centered at the middle of the thoracic spine with the superior border of the image at C7 level. Such radiographs are obtained with the patient in the upright position if possible. **Deep inspiration** during exposure of the lateral projection is recommended in order to render the density of the chest more even. Anteroposterior radiographs are exposed in expiration. If additional imaging is required, radiographs centered at the thoracolumbar transition may be helpful. For the lateral view of the thoracolumbar transition, **expiration** is recommended.

Imaging the thoracolumbar junction often requires a centered image

### Cervical Spine

As for the other radiographs of the spine, anteroposterior and lateral images are typically employed. For lateral radiographs, weights (up to 10 kg on each side) may be placed in each hand of the patient in order to move the shoulders downwards. Shoulder soft tissue overlap is most pronounced in heavy patients. The **lateral swimmer's view** with the shoulders rotated out of the X-ray beam may assist in the assessment of the cervicothoracic spine. This view is of importance in the evaluation of a traumatized patient in whom the cervicothoracic junction cannot be visualized by conventional views and in cases for which CT is not readily available. **Anteroposterior oblique images** better demonstrate the intervertebral foramina and sometimes the facet joints. **Anteroposterior transbuccal radiographs** centered at the odontoid process are included in many standard imaging protocols at least after trauma and in patients with rheumatoid arthritis. **Lateral positional radiographs** are commonly obtained in flexion and extension in order to assess atlantodental instability.

Specialized views can be diagnostic for cervical spine

The swimmer's view demonstrates the cervicothoracic junction

### Whole Spine Radiographs

Whole spine radiographs are mainly employed for the diagnosis, follow-up and surgical planning of spinal deformity, particularly **scoliosis**. They are typically obtained with a film-focus distance of at least 2 m. This distance may be increased to up to 3 m. Radiation doses for this type of radiograph are relatively high with a mean effective dose of between 0.23 and 1.09 mSv per radiograph [16]. A lower effective dose for the anteroposterior view compared to the lateral view and a lower effective dose in male patients has been demonstrated [16]. The posteroanterior exposure supposedly results in a smaller dose to the sensitive breast tissue than an anteroposterior exposure.

Whole spine and lateral bending radiographs are associated with a relatively high radiation dose

**Lateral bending radiographs** may be required for assessment of stiffness of the scoliotic spine. For comparison, mean effective doses for cervical spine radiographs are 0.18 mSv (anteroposterior) and 0.27 mSv (lateral); for thoracic spine radiographs they are 0.51 mSv (anteroposterior) and 0.80 mSv (lateral); and for lumbar spine radiographs they are 0.77 mSv (anteroposterior) and 1.7 mSv (lateral), respectively [43].

Lateral bending films are helpful in the assessment of scoliotic curve rigidity

## Magnetic Resonance Imaging

### MR Systems

MR imaging is the second most commonly employed imaging method in assessing spinal disorders. In Europe and the United States, 1.5-Tesla scanners with tunnel-shaped, superconducting magnets are typically employed. Mid-field scanners with field strengths of 0.5 and 1.0 T are less commonly offered by the major manufacturers. On the other hand, high field scanners with 3.0 T or higher field strengths are increasingly being installed. A higher field strength has the advantage of a higher spatial resolution, a better signal-to-noise ratio and a shorter acquisition time. It is also advantageous in specialized imaging, including MR angiography, and functional imaging of the spinal cord. **Disadvantages** include increased **susceptibility and flow artifacts**. Susceptibility artifacts relate to local disturbances of the magnetic field and are more pronounced in high field scanners. They are most commonly encountered after surgery with metallic implants. Flow artifacts may be prominent in the vicinity of large vessels. Additionally, patients in high field units are exposed to higher energy deposition (SAR: specific absorption rate). In order not to exceed acceptable SAR values,

3T scanners have several advantages including potentially superior image quality

3T scanners have the disadvantage of increased susceptibility and flow artifacts

sequence parameters may have to be adapted, which may offset the physically possible shorter acquisition time [35].

Open MR systems allow claustrophobic patients to be imaged

So-called **open MR systems**, usually based on permanent magnets, have relatively low field strength with typical values of 0.2–0.6 T, although lower and higher values are available. These magnets are open in the sense that the patients are not lying in a closed tunnel but rather between two horizontal plates which leave space on both sides of the patient as well as in the cranial and caudal direction. The plate on top may be closer to the patient, however, than the top of the tunnel-like magnets. Permanent magnet systems are generally less expensive to purchase and operate than superconducting magnets but have disadvantages. Image quality and selection of specialized sequences tend to be inferior to those with mid to high field scanners. In addition, the magnet weight in such systems is higher than for superconducting systems, and open MR units are more susceptible to external sources influencing the magnetic field such as tramways and suburban trains.

For adequate imaging, dedicated coils have to be employed for detection of MR signals

For adequate imaging of the spine, **dedicated coils** have to be employed for detection of MR signals. A number of different designs are available which are placed underneath the body. With increasing distance from these surface coils, signal and image quality decrease. Therefore, these standard coils may not be sufficient for homogeneous images. Advanced designs which include both a dorsal and a ventral element adapted to the body form are sometimes necessary and are routinely used for examinations of the cervical spine.

## MR Protocol for Spinal Imaging

Various imaging protocols are used depending on the institution and the scanner type. No general recommendation can be given. However, the imaging parameters used at our center are given in Table 1.

**Table 1.** MR imaging parameters

| Sequence | | Slice (mm) | TR (ms) | TE (ms) | Flip angle | Matrix | FOV (mm) | ETL | NEX | Time (min:s) |
|---|---|---|---|---|---|---|---|---|---|---|
| **Cervical spine** | | | | | | | | | | |
| T1 sagittal | TSE | 4 | 300–600 | <20 | – | 384×384 | 220–360 | 3 | 2 | 2:53 |
| T2 sagittal | TSE | 2.5 | 3500–6000 | >100 | – | 512×512 | 220–360 | 23 | 2 | 3:41 |
| T2* axial | GE Ci3d | 2 | 9.3 | 4.7 | 70° | 512×512 | 180 | – | 1 | 2:50 |
| **Thoracic and lumbar spine** | | | | | | | | | | |
| T1 sagittal | TSE | 4 | 300–600 | <20 | – | 384×384 | 220–360 | 3 | 3 | 4:02 |
| T2 sagittal | TSE | 4 | 3500–6000 | >100 | – | 512×512 | 220–360 | 21 | 2 | 3:12 |
| T2 axial | TSE | 4 | 3500–6000 | >100 | – | 512×512 | 220 | 15 | 2 | 3:32 |
| STIR sagittal | TSE | 4 | 3800 | TE 79 TI 170 | – | 256×256 | 220–360 | 9 | 1 | 3:42 |
| **Sacroiliac joint** | | | | | | | | | | |
| T1 coronal | TSE | 4 | 450 | 12 | – | 512×512 | 280 | 3 | 2 | 2:37 |
| STIR coronal | TSE | 4 | 4950 | 69 | – | 256×256 | 280 | 9 | 1 | 4:23 |
| T1 axial fs. Gd. | TSE | 5 | 570 | 10 | – | 384×384 | 250 | 3 | 2 | 3:44 |
| STIR sagittal | TSE | 4 | 3500 | TR 70 TI 150 | - | 384×384 | 360 | 9 | 1 | 3:14 |

The above sequences are the routine spine MR protocols of Balgrist University Hospital, Zürich, Switzerland, acquired with a 1.5T MR unit (Avanto, Siemens, Medical Solutions, Erlangen, Germany)
TSE = turbo spin-echo, GE = gradient-echo, Ci3d = 3D CISS sequence, Me2d = 2D MEDIC sequence, STIR = short tau inversion-recovery, TR = repetition time, TE = echo time, TI = inversion time, FOV = field of view, ETL = echo train length, NEX = number of excitations, fs. = fat saturated, Gd. = after i.v. injection of MR contrast agent (gadolinium)

## Routinely Used MR Sequences for the Assessment of the Spine

Standard MR sequences are sufficient for most indications

Standard T1 (**weighted = W**) and T2 W spin-echo sequences are the basis of imaging in the spine (Fig. 1). T1 W and T2 W sagittal sequences, as well as axial T2 W sequences, provide a basis for the MR imaging of all spine regions. Some surgeons and radiologists prefer axial T1 W images, which render the dural sac relatively hypointense and the epidural fat hyperintense. In most cases, this protocol (two sagittal sequences and one axial sequence) is sufficient to make all the relevant diagnoses.

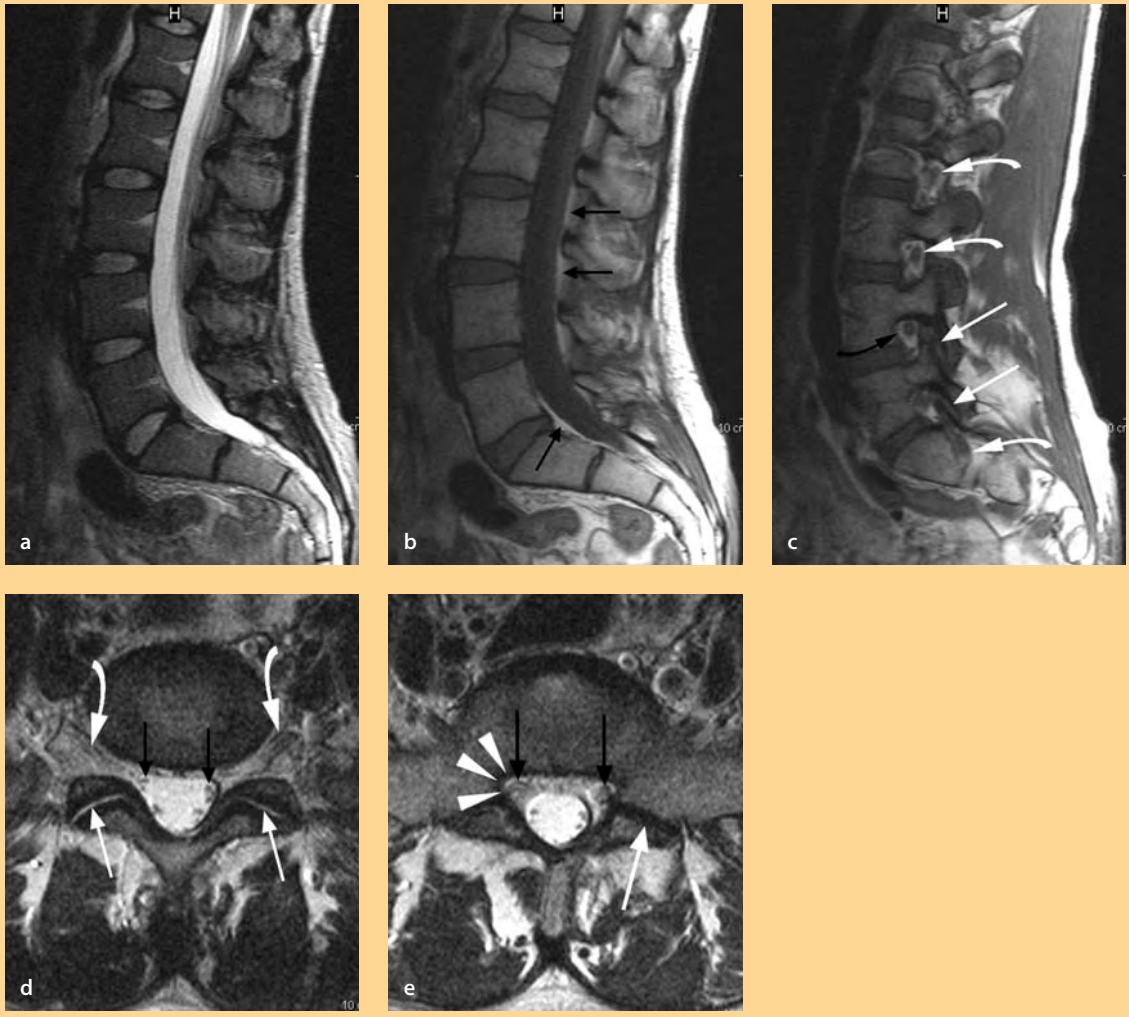


**Figure 1. Normal lumbar MR anatomy**

a, b Midsagittal T2 W (W = weighted) and T1 W, c parasagittal T1 W, and d axial T2 W MR images of a normal lumbar spine. a, b In non-degenerated discs, the structure of the disc is homogeneous in T2 W images, with a bright hyperintense white signal intensity and a normal disc height. c Parasagittal T1 W image through the intervertebral foramen shows lumbar nerve isointense (*curved arrows* point to L3, L4 and S1 nerve roots) and hyperintense perineural fat tissue. d Axial T2 W images at the level of the intervertebral disc L5/S1 and e of the pedicles of S1 (*white arrowheads*) show nerve roots L5 (*curved arrows*) and S1 (*straight black arrows*). Caused by chemical shift artifact, the dura can be seen more clearly on the left side while the border between the dural sac and epidural fat on the right is less distinct anteriorly. In a normal facet joint (*straight white arrows*) cartilage should be seen as a bright thin line with adjacent dark thin and regular subchondral cortical bone.

**T2 W images** best demonstrate:

- disc degeneration [30] (Fig. 2)
- annular tears [39] (Fig. 3)
- disc herniation [22] (Fig. 4)
- intraspinal tumors (Fig. 5)

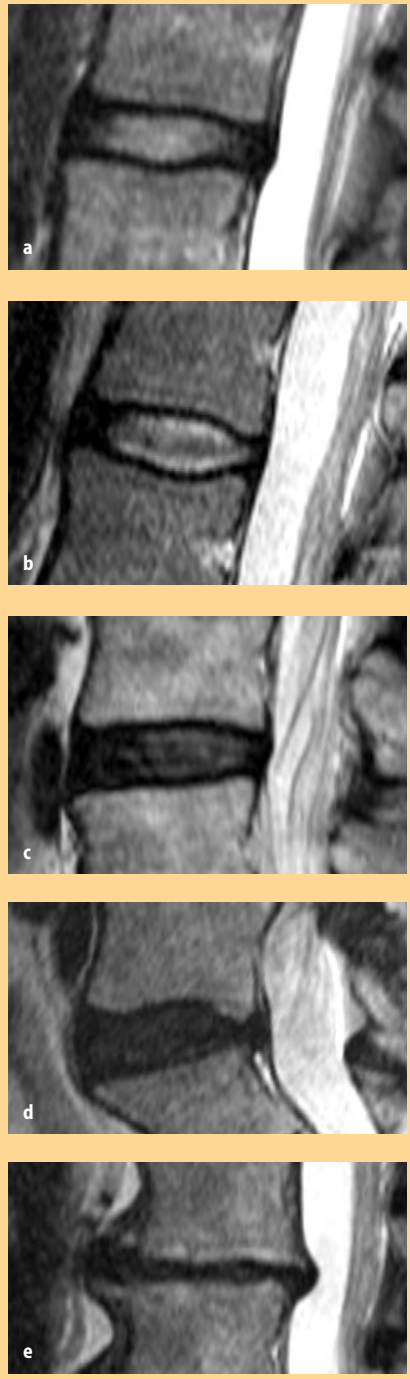


**Grade I:** Normal adolescent disc. The structure of the disc is homogeneous with a bright hyperintense signal intensity of the nucleus and normal disc height.

**Grade II:** Normal adult disc. The structure of the disc is inhomogeneous, with a hyperintense white signal. The distinction between nucleus and anulus is clear, and the disc height is normal, with or without horizontal gray bands.

**Grade III:** The structure of the disc is inhomogeneous, with an intermediate gray signal intensity. The distinction between nucleus and anulus is unclear, and the disc height is normal or slightly decreased.

**Grade IV:** The structure of the disc is inhomogeneous, with a hypointense dark gray signal intensity. The distinction between nucleus and anulus is lost, and the disc height is normal or moderately decreased.

**Grade V:** The structure of the disc is inhomogeneous, with a hypointense black signal intensity. The distinction between nucleus and anulus is lost, and the disc space is collapsed.

**Figure 2. Grading of disc degeneration**

The grading is performed on T2 W midsagittal fast spin-echo images according to Pfirrmann et al. [29].

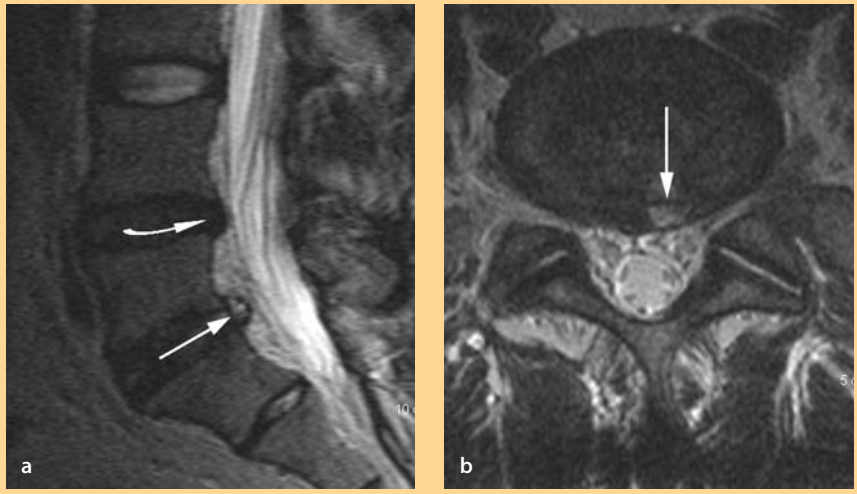


**Figure 3. Annular tear**

a Sagittal and b axial T2-weighted MR images show the high intensity zone (annular tear) of the L5/S1 disc (*straight arrow*). Disc protrusion is shown in the L4/5 segment (*curved arrow*).

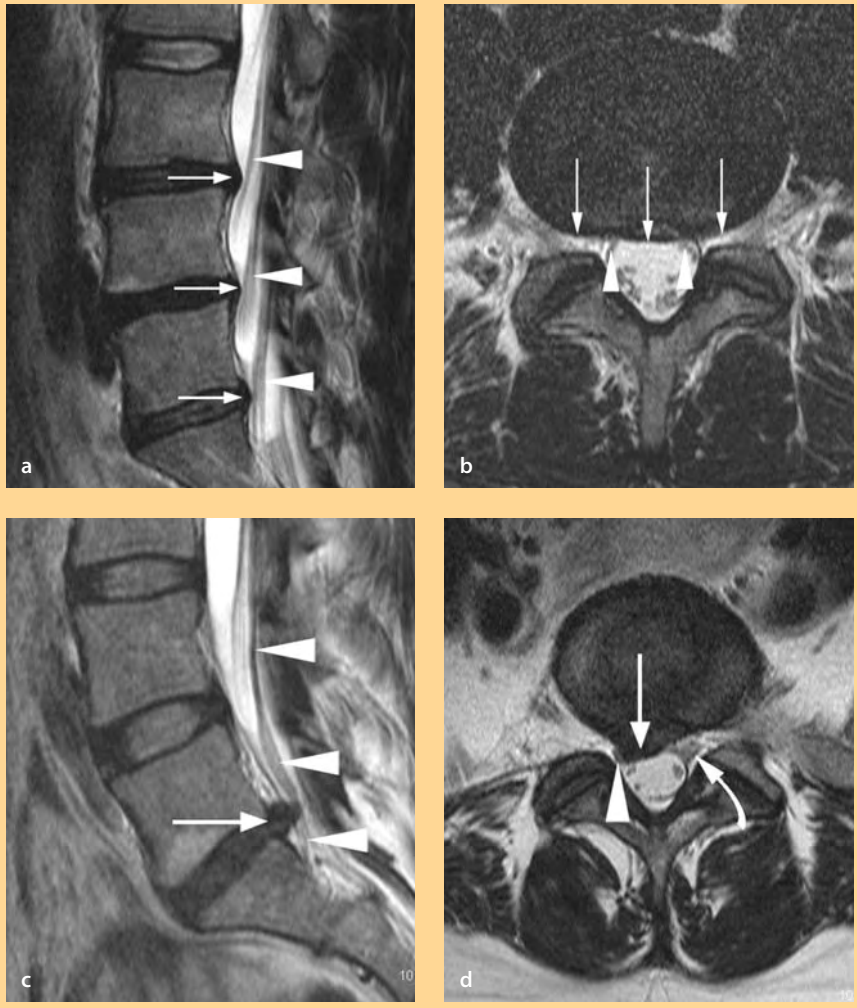


**Figure 4. Disc protrusion and extrusion**

a, b Disc protrusion. Sagittal T2 W MR image shows disc protrusions in the L3/4, L4/5, and L5/S1 segments (*arrows*) with contact to the L4, L5, and S1 nerve roots (*arrowheads*). The axial T2 W MR image shows diffuse protrusion of the L4/5 disc (*arrows*) with contact to the L5 nerve roots (*arrowheads*). c, d Disc extrusion. Sagittal T2 W and axial T2 W images in a different patient show disc extrusion (*arrows*) with compression of the L5 nerve root (*arrowheads*) between the L4/5 disc and the ligamentum flavum.

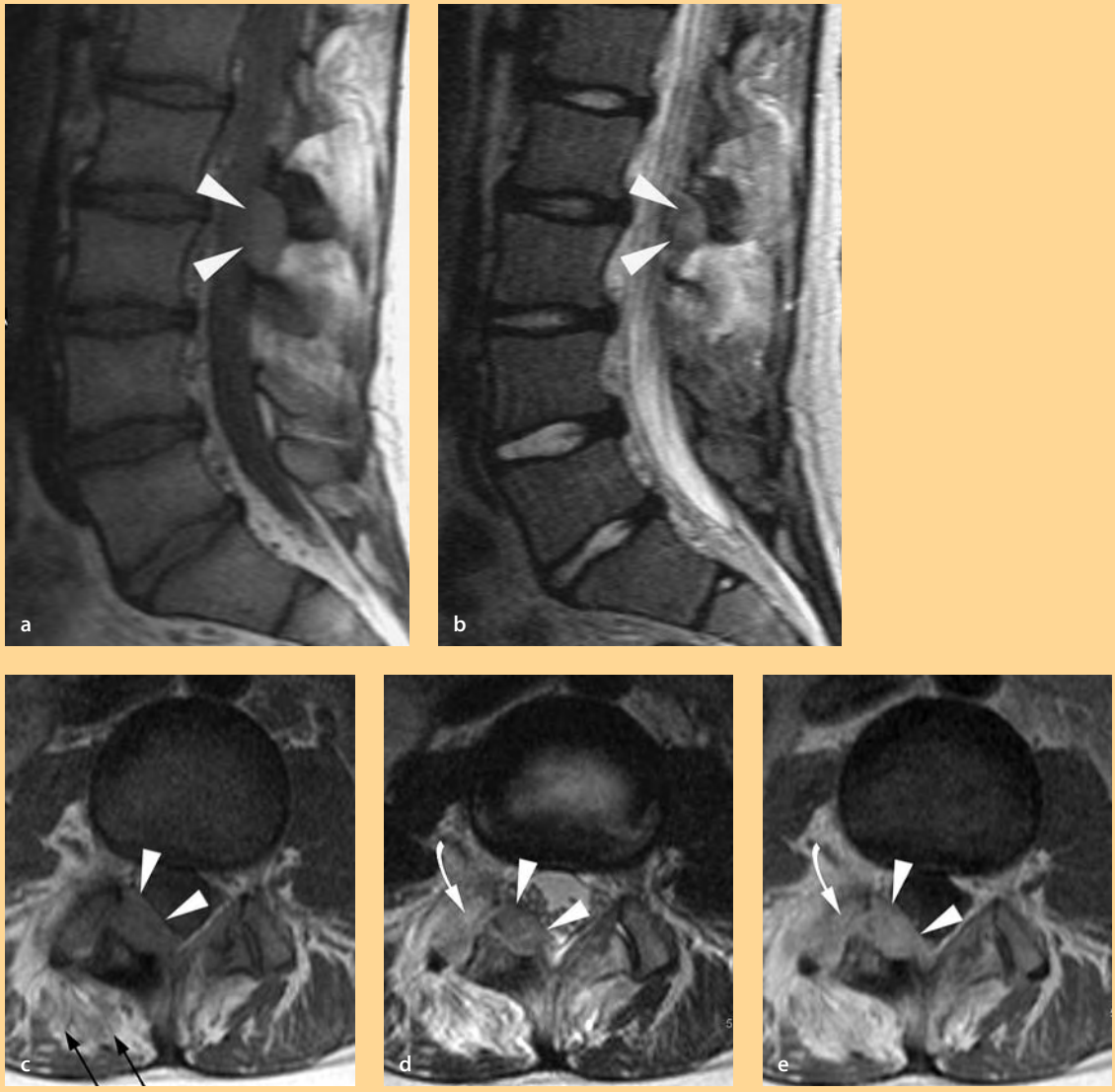


**Figure 5. Intraspinal tumor**

a Sagittal T1 W, b T2 W and c axial T1 W, d T2 W, and e contrast enhanced T1 W fat suppressed images. There is a contrast enhancing epidural mass (*arrowheads*) arising from the subperiosteal bone of the lamina of L2 with impression of the dural sac. T1 W image shows fatty degeneration (*straight black arrows*) of the adjacent multifidus and longissimus muscles. There is a bone marrow signal change in the joint facet with hyperintensity in T2 and contrast enhancement in T1 (*curved arrow*). The imaging findings are suggestive of an osteoblastoma.

**T1 W sequences are** important to show:

- fat, e.g., within vertebral body hemangiomas or for detection of epidural fat (Fig. 6)
- acute bleeding (Fig. 7)
- endplate changes [23] (Fig. 8)

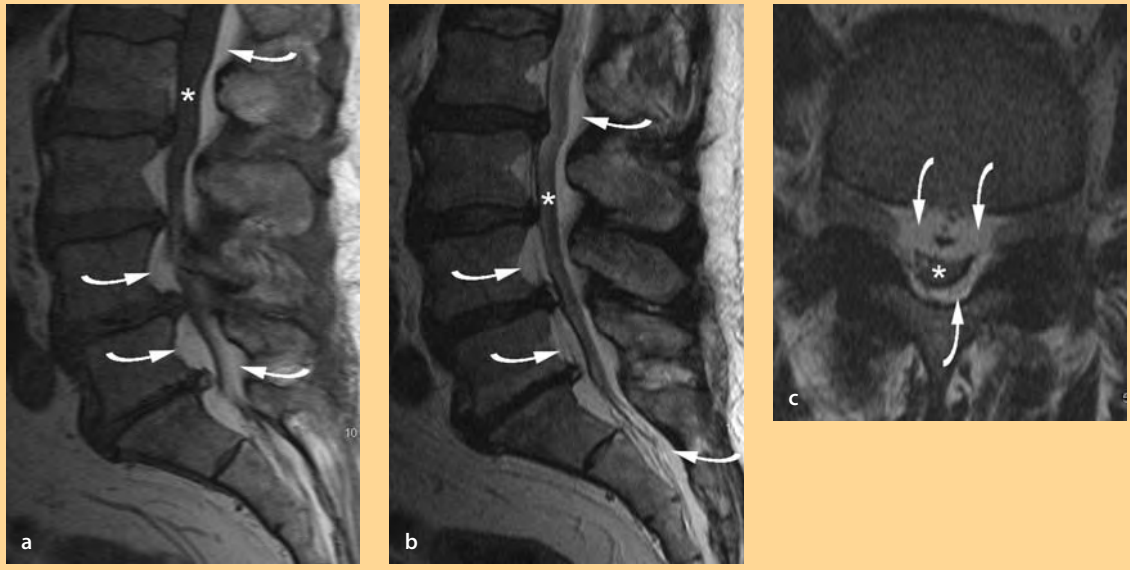


**Figure 6. Epidural lipomatosis**

**a** Sagittal T1-weighted, **b** sagittal T2 W, and **c** axial T2 W images (at the L4/5 level) demonstrate an increased amount of epidural fat (*curved arrows*) as hyperintense tissue in all three sequences. The dural sac (*asterisk*) is narrowed with deformation and flattening in the axial image.

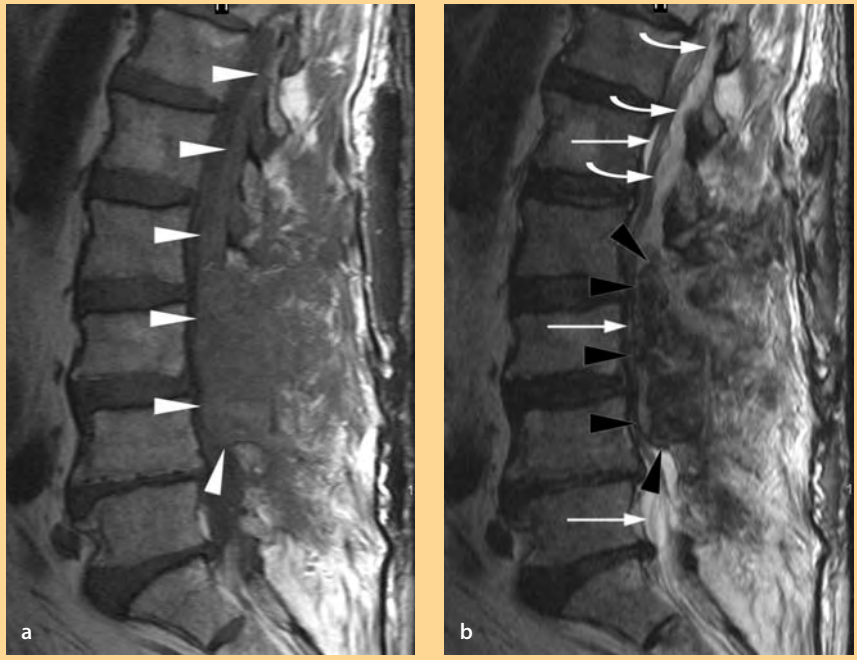


**Figure 7. Acute postoperative epidural bleeding**

**a** Sagittal T1 W and **b** T2 W, as well as **c** axial T2 W images at the L2 and **d** L4 levels, show postoperative epidural bleeding after decompression surgery. In the T1 W image, the bleeding (*white arrowheads*) is slightly hyperintense compared to the cerebrospinal fluid. T2 W images show different stages of bleeding with in part T2-hyperintense hyperacute bleeding (*curved arrows*) and T2-hypointense acute bleeding (*black arrowheads*).

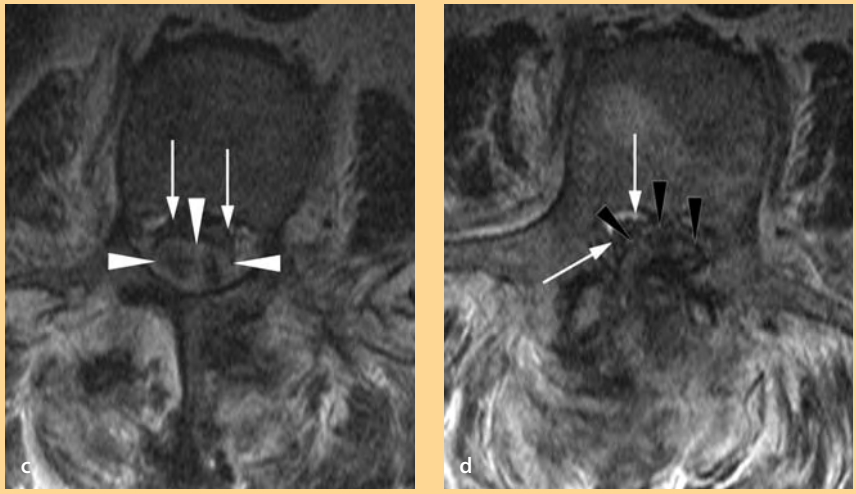


**Figure 7.** (*Cont.*)

The dural sac (*arrows*) is dislocated anteriorly and compressed. **c** At the L2 level, the dural sac (*arrows*) is displaced anteriorly and flattened caused by hyperacute bleeding (*white arrowheads*). **d** At the L4 level, the dural sac (*arrows*) is compressed and dislocated to the right because of the T2-hypointense acute bleeding (*black arrowheads*)

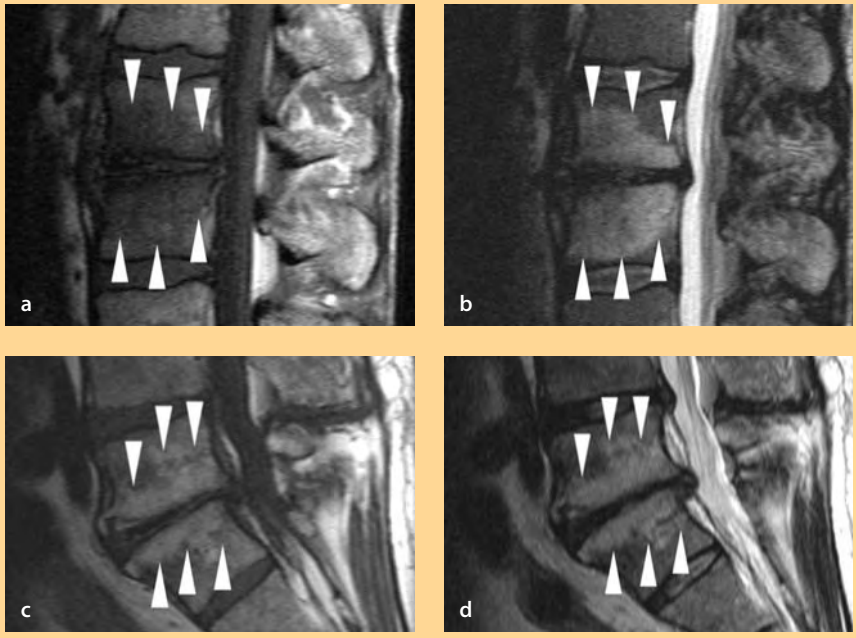


**Figure 8. Endplate changes**

Endplate changes have been classified by Modic [23] as Type I–III. **a** T1 W and **b** T2-weighted images demonstrate **Type I endplate changes** (*arrowheads*) with high signal in T2 W and low signal in T1 W images. **c** T1 W and **d** T2 W images demonstrate **Type II endplate changes** (*arrowheads*) with high signal in T1 W and T2 W images which corresponds to a higher amount of fat within these regions.

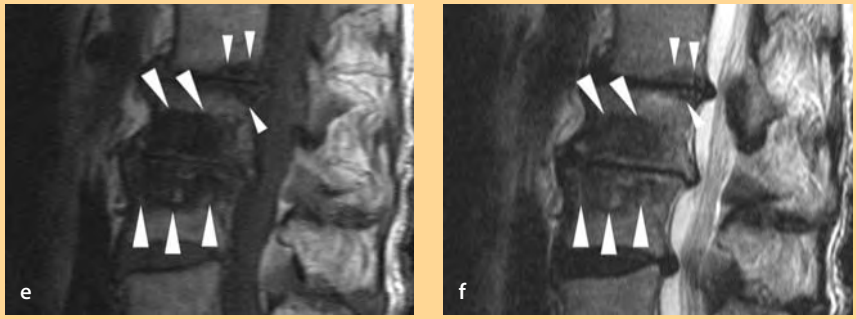


**Figure 8.** (*Cont.*)

e T1 W and f T2 W images demonstrate **Type III endplate changes** (*arrowheads*) in two segments with low signal in T1 W and T2 W images, which corresponds to bony sclerosis within these regions.

## Contrast Enhanced MR Imaging of the Spine

Contrast agents shorten T1 relaxation times

Occasionally, intravenous (i.v.) injection of MR **contrast agents** is necessary. Such agents are virtually always gadolinium chelates, which predominantly shorten T1 relaxation times. This means that there is increased signal on T1 W sequences wherever the contrast agent is accumulated (typically within vessels, hyperemic tissue, and joint spaces). Brand and generic names of these contrast agents include Magnevist (gadopentetate dimeglumine, Gd-DTPA), Dotarem (gadoterate meglumine, Gd-DOTA), Omniscan (gadodiamide, Gd-DTPA-BMA), and Prohance (gadoteridol, Gd-HP-DO3A). Most MR contrast agents have a gadolinium (Gd) concentration of 0.5 mmol/ml. A higher Gd concentration (1 mmol/ml) is occasionally used for MR angiography and brain imaging.

The **use of MR contrast agents** [14, 17, 24, 25, 31] is recommended in:

- suspected **tumors** [paravertebral, vertebral, epidural, intradural-extramedullary, and intramedullary tumors (Fig. 5)]
- suspected **demyelination** within the spinal cord
- suspected **infection** [spondylitis, spondylodiscitis (Fig. 9), or soft tissue infection]
- spontaneous intraspinal **hemorrhage** for demonstration of vascular malformations
- inflammatory **rheumatological disorders** [ankylosing spondylitis, rheumatoid arthritis, seronegative spondyloarthritis, and **SAPHO** (i.e., synovitis, acne, pustulosis, hyperostosis, osteitis) syndrome with spondylitis]
- **postoperative spine**

Fat-suppressed images are helpful because fat may disguise the underlying pathology

In order to increase lesion conspicuity, the contrast enhanced T1 W sequences may be combined with fat suppression. **Fat** (fatty bone marrow, subcutaneous and retroperitoneal fat) and MR contrast agents are both hyperintense (increased signal) on standard T1 W images, which may obscure abnormalities. On fat-suppressed images, only the signal originating from the injected contrast medium remains. **Enhanced, fat-suppressed T1 W** images are most useful [17, 25, 31] in suspected cases of:

- spondylodiscitis
- epidural abscess or soft tissue infection
- neoplasm
- ankylosing spondylitis or other inflammatory rheumatologic disorders

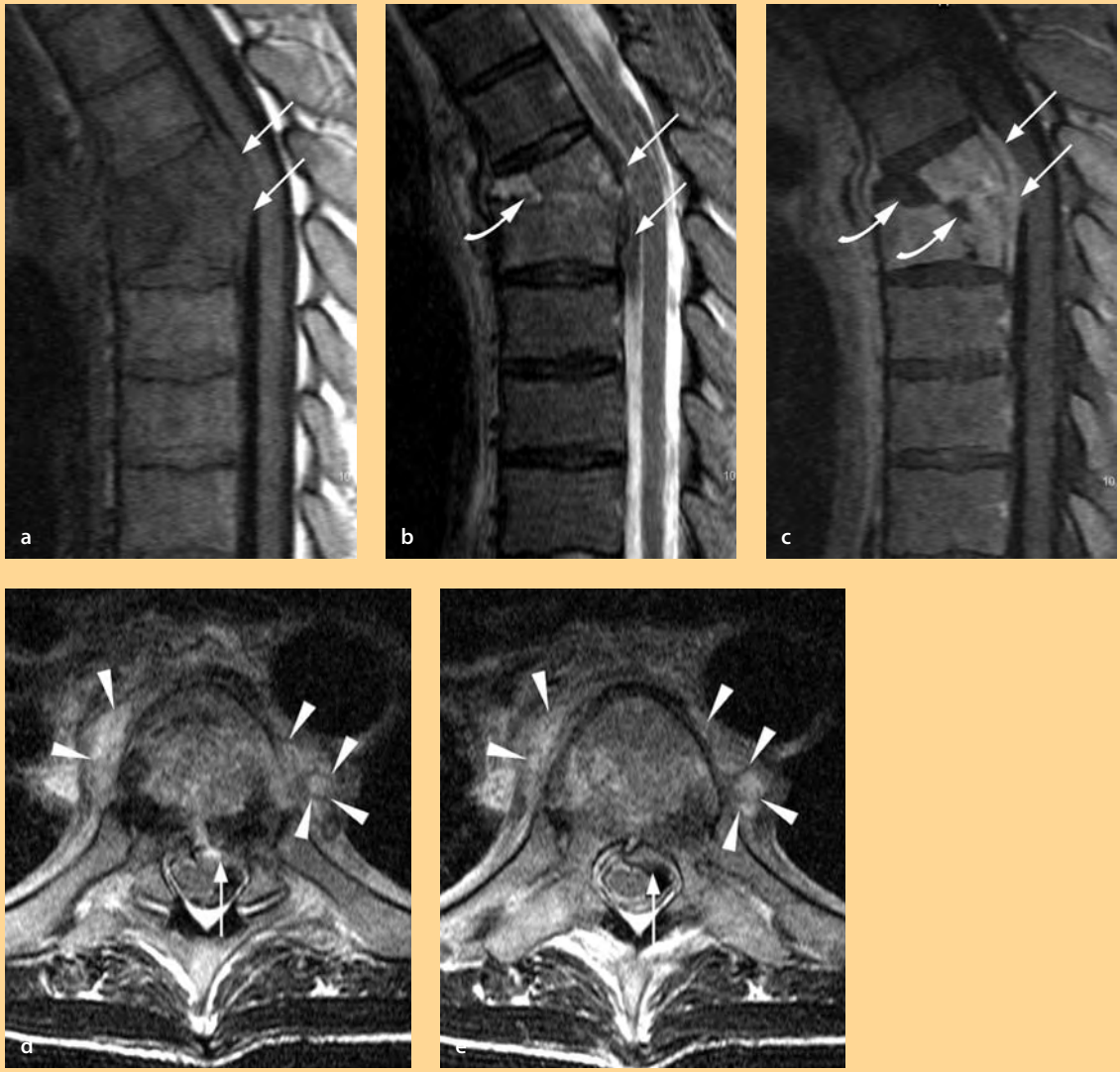


**Figure 9. Spinal infection**

**a** Sagittal T1 W, **b** T2 W and **c** contrast enhanced T1 W fat suppressed images as well as **d** axial T1 W fat suppressed and **e** T2 W images in spondylodiscitis of the thoracic spine. There is collapse of one vertebral body and of the intervertebral disc (*white curved arrow*) and contrast enhancement within both vertebral bodies and within an epidural mass (*arrows*) with slight deformation of the dural sac. Inflammatory changes with abscess formation (*arrowheads*) can be seen in the paravertebral space.

## Additional Sequences

Gradient-echo and fat-suppressed T2 W sequences are the two most commonly employed additional sequences. Both types of sequences are available on all types of scanners.

T2*W gradient-echo sequences reduce CSF pulsation artifacts

Axial **T2*W gradient-echo sequences** are commonly used in the cervical spine instead of T2 W fast spin-echo sequences. The "*" in T2*W is employed because the signal on these sequences is not only determined by T2 relaxation times but also by additional factors. The main reason to use such sequences is the reduction of **pulsation artifacts** within cerebrospinal fluid commonly present on T2 W images. These artifacts consist of hypointense regions which may obscure or imi-

tate abnormalities. They may for instance interfere with the diagnosis of vascular malformations and other filling defects within the subarachnoidal space. **Gradient-echo images** tend to provide excellent contrast between the cerebrospinal fluid on one hand and the spinal cord or discs on the other hand. With regard to intramedullary abnormalities their contrast behavior tends to be inferior to T2 W spin-echo images. Gradient-echo sequences additionally have disadvantages such as marked susceptibility artifacts in the presence of metallic implants and fragments [33]. There are many different types of gradient echo sequences, depending on the manufacturer. Commonly the manufacturers try to abbreviate the complicated names of the gradient echo techniques with acronyms such as MEDIC, DESS, CISS, FFE, SPGR and many others.

Gradient-echo sequences allow for an excellent contrast between CSF and spinal cord

So-called fluid sensitive sequences such as **T2 W fat-suppressed** or **short tau inversion-recovery (STIR) sequences** may be used in addition to the routine sequences. In these sequences, fluid (in a wide sense of the word) is hyperintense. Such fluid may be present in:

The STIR sequence differentiates acute from chronic fractures

- **soft tissue** (circumscribed: e.g., hematomas or abscesses; diffuse: e.g., edema)
- **bone marrow** (edema, granulation tissue, abscess formation, tumor)
- **cerebrospinal fluid**

All other structures including normal bone marrow, soft tissue and fat are hypointense. These sequences are commonly used for screening in suspected abnormalities not seen on the standard sequences. **Typical indications** include:

- primary bone tumors and metastases
- acute or subacute fractures [4]
- bone and soft tissue infection
- soft tissue tumors
- soft tissue trauma (ligament disruption, soft tissue bleeding) [51]

**Diffusion imaging** is based on the ability of the protons to move during application of an MR gradient. Such motion is most pronounced in fluid (cerebrospinal fluid, seroma). In normal cellular tissue such as the spinal cord or bone marrow motion is restricted. Under pathologic conditions, different types of diffusion pattern can be observed. Diffusion imaging is most commonly applied to the brain for the assessment of ischemia. In the early phase, motion may be more restricted than in the surrounding tissue but increases with development of necrosis. In the spine, diffusion imaging has mainly been applied to bone, such as the differentiation of traumatic and pathologic (mainly tumor-related) fractures [52].

Diffusion imaging and spectroscopy are still evolving

**Proton ($^1$H)-spectroscopy** provides spectra of the many different compounds of the examined volume including the protons contained in water and body fat. These two large peaks are commonly suppressed because they interfere with measurement of the much smaller peaks associated with compounds relating to metabolic changes found in tumors and other abnormalities. In $^1$H-spectroscopy, proton-containing compounds such as *N*-acetyl aspartate, creatine, and choline can be identified [8]. $^1$H-spectroscopy cannot be considered to be a routine imaging method. Spectroscopy is not limited to $^1$H but may also be performed with other types of nuclei including phosphorus, sodium and others. Special equipment is required for such types of spectroscopy.

MR spectroscopy is not yet in routine use for the assessment of spinal disorders

### Contraindications, Artifacts, Side Effects

The contraindications for imaging of the spine are the same as for MR imaging in general. They mainly include electronic devices which may malfunction, may be

MR imaging is contraindicated in the presence of cardiac pacemakers and neurostimulators

displaced or may increase in temperature. The list of such devices typically includes:

- cardiac pacemakers
- neurostimulators
- insulin pumps
- inner ear implants
- metallic fragments

Metallic spinal implants are not a contraindication for MRI

The **metallic implants** used in spine surgery including pedicular screws are not contraindications for imaging from the point of view of patient safety. However, they tend to produce so-called **susceptibility artifacts** (Fig. 10). These artifacts are caused by local distortion of the magnetic field by the metallic objects and appear as hypointense regions surrounding the implant. Pure titanium implants are less prone to susceptibility artifacts than steel alloy implants. Other parameters influencing the extent of susceptibility artifacts are the size of the implant and a number of MR parameters which may sometimes be successfully manipulated (including readout direction, type of sequence, sequence design). Generally, spin-echo sequences cause fewer artifacts than gradient-echo sequences [26].

Pure titanium implants exhibit fewer artifacts than stainless steel

A considerable number of patients feel uncomfortable within the MR system. **Claustrophobia** is the most commonly encountered problem. One possibility is the use of prism glasses, which allow the patient to observe the magnet opening. In severely claustrophobic patients, sedation by intravenous (2–5 mg), oral (7.5 mg) or intranasal administration of midazolam is necessary. Pain is another commonly encountered problem in MR imaging. Patients with severe back pain

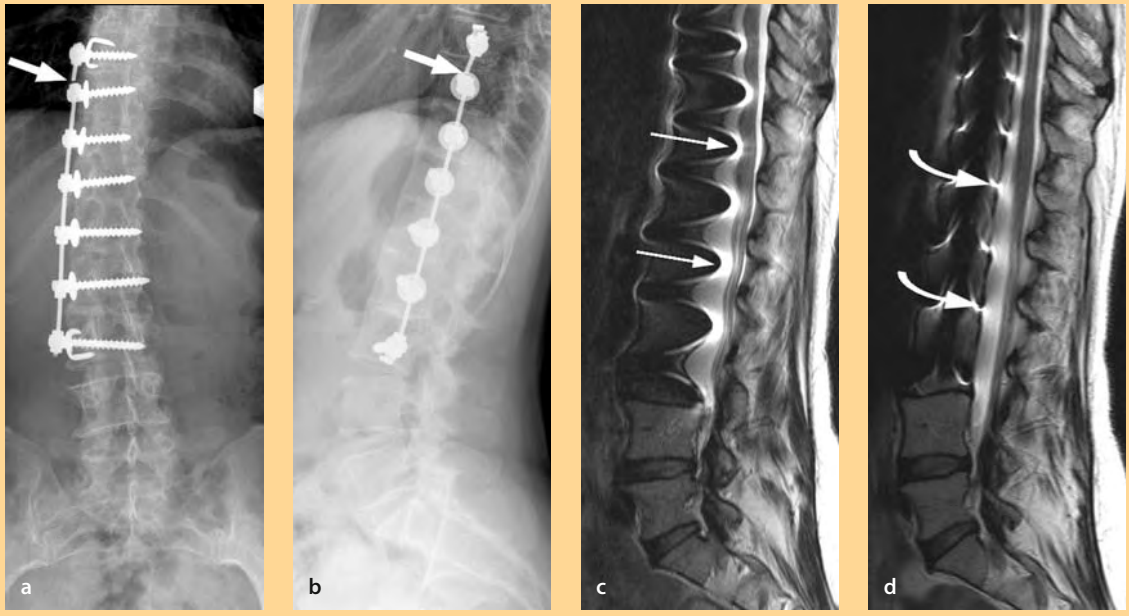


**Figure 10. Susceptibility artifact and artifact reduction**

a Conventional anteroposterior and b lateral radiographs of a 43-year-old female patient several years after scoliosis surgery in Th9 to L3 with implant rupture (*bold arrow*) in the level Th9/10. c Sagittal T2 W MR image of the lumbar spine shows considerable susceptibility artifacts caused by the metallic implants, which obscure the spinal cord partially (*thin arrows*). d After optimization of the imaging parameters (different phase direction and special sequence design), visibility of the spinal canal (*curved arrows*) and spinal cord is far better than before.

are often unable to stay motionless for the 20 min required for a standard examination. Hip flexion, which might relieve the patient's pain, is only possible to a limited degree in most magnet designs. Proper analgesic medication prior to the MR examination may be required in order to reduce patient discomfort and pain-related motion artifacts.

## Computed Tomography

CT is the modality of choice for imaging of bone

CT has developed with amazing speed during the last few years. **Spiral CT** with continuous data acquisition appeared in routine work in the mid-1990s, and multi-detector row CT at the end of the 1990s. Initially, four detector rows were employed which were quickly followed by 16, 40 and 64 detector rows. At the time of writing, this development has not yet come to an end. Compared to MR imaging, CT has several advantages. CT shows bony details with a high spatial resolution.

In plane **spatial resolution of CT** (pixel size) is approximately 0.25 – 0.5 mm (depending on the system geometry and on the reconstruction kernel selected by the user) and is therefore better than in typical MR protocols. CT does not interfere with the function of pacemakers and other electronic devices. The metal-related artifacts present in CT are related to so-called beam-hardening, which depends on the amount/size of implants and the atomic number of the implant. Such artifacts may be less pronounced or in a different place when compared to MR imaging. Examinations in **emergency room** and **intensive care patients** are preferably performed using CT because imaging times are shorter, patient access is easier and no specialized (non-ferromagnetic, shielded) intensive care equipment is necessary as for MR imaging.

CT is the imaging modality of choice in an emergency situation

Contrast resolution is inferior to MRI

On the other hand, the **contrast resolution of CT** is much inferior to MR imaging in important structures such as the intervertebral discs, cerebrospinal fluid and soft tissue. The radiation dose is considerable in CT, e.g., 28 % of the medical radiation dose in Switzerland is generated by CT examinations [46]. CT examinations of the lumbar spine (8.2 mSv) and of the sacroiliac joints (7.0 mSv) result in a higher effective radiation dose compared to CT examinations of the cervical (3.4 mSv) spine.

CT fluoroscopy allows for interventional procedures

**CT fluoroscopy** allows real-time imaging of **interventional procedures**. During these procedures, the radiologist activates intermittent or continuous image acquisition with a foot pedal. If necessary, the patient can be moved in the craniocaudal axis using a joystick, placed within the reach of the radiologist's elbow or hand. In order to protect the patient and the radiologist from high radiation doses, low-dose imaging (lower mAs) is usually performed. In addition, a reduced number of pixels (reduced spatial resolution) and near-real-time image reconstruction algorithms are commonly used in order to reduce acquisition time [42]. CT fluoroscopy allows imaging of a needle or other radiopaque devices in real-time fashion during insertion. This method is typically employed for CT guided nerve root blocks, facet joint blocks, CT discography, injections into the sacroiliac joints, sympathetic trunk blocks, vertebral body biopsy, and soft tissue biopsy.

DEXA is used for the determination of bone mineral density

CT is one of the many available tools for bone density measurement. Bone density within the vertebral body can be directly measured by simultaneously scanning the vertebral body and phantoms with defined densities [15]. This method is not commonly employed, however, for a number of reasons. The most commonly employed method is **dual energy X-ray absorptiometry (DEXA)**, which reduces radiation dose and cost when compared to CT. On the other hand, this method is a projectional method and may overestimate bone density in the presence of spondylophytes. Dedicated small CT scanners have

pQCT allows fast losers to be detected

been used for **peripheral quantitative computed tomography (pQCT)** measurements [9]. Such scanners are less expensive than standard CT scanners and provide highly reproducible results which may be used for early detection of fast losers and for monitoring the effects of medication therapy. Other methods mainly used for peripheral measurements (with variable predictive value for spinal fractures) are broadband ultrasonic attenuation (BUA) [44] and high-resolution MR imaging measurement of the trabecular bone volume fraction [47].

### Imaging Protocol

Multi-detector CT has improved resolution and shortened imaging time

When a single slice CT unit is used, the examination needs to be restricted to a few spinal segments. Typically, the cervical spine is imaged with thinner slices compared to the thoracic and lumbar spine. **Multi-detector CT** (MDCT) units allow the acquisition of a large number of segments with thin slice thickness, within the same period of time. Sagittal and coronal multiplanar reformations (MPRs) are more easily obtained and are of better quality based on such data sets. Typical imaging protocols in the cervical, thoracic, and lumbar, spine, as well as for the sacroiliac joints, are shown in Table 2.

**Table 2.** Imaging parameters for computed tomography[a]

| | Single-slice CT | 16-row MDCT | 64-row MDCT |
|---|---|---|---|
| **Cervical spine** | | | |
| Plane | Axial | axial | axial |
| Slice thickness | *C0 – C3* 1 mm<br>*C4 – C7* 2 mm | 16×16.75 mm | 64×64.6 mm |
| Pitch | *C0 – C3* 1.3<br>*C4 – C7* 1.25 | – | – |
| Recon. interval | *C0 – C3* 2 mm<br>*C4 – C7* 2 mm | 0.6 mm | 0.7 mm |
| Kernel soft | AH 50 | B 30 | B 30 |
| Kernel bone | AH 91 | B 50 | B 50 |
| Window soft (C/W) | 250/50 | 280/60 | 360/70 |
| Window bone (C/W) | 1 800/450 | 1 500/400 | 1 500/400 |
| **Thoracic and lumbar spine** | | | |
| Plane | axial | axial | axial |
| Slice thickness | 2 – 3 mm | 16×16.75 mm | 64×64.6 mm |
| Pitch | 1.25 – 1.5 | – | – |
| Recon. interval | 3 – 4 mm | 0.6 mm | 0.7 mm |
| Kernel soft | AB 50 | B 30 | B 30 |
| Kernel bone | AH 82 | B 50 | B 50 |
| Window soft (C/W) | 250/50 | 360/70 | 360/70 |
| Window bone (C/W) | 1 800/450 | 1 500/400 | 1 500/400 |
| **Sacroiliac joints** | | | |
| Plane | coronal | axial | axial |
| Slice thickness | 2 mm | 16×16.75 mm | 64×64.6 mm |
| Pitch | 1.25 | – | – |
| Recon. interval | 3 mm | 0.6 mm | 0.7 mm |
| Kernel soft | AB 50 | B 30 | B 30 |
| Kernel bone | AH 82 | B 50 | B 50 |
| Window soft (C/W) | 250/50 | 360/70 | 360/70 |
| Window bone (C/W) | 1 800/450 | 1 500/400 | 1 500/400 |

[a] As used in our institution
Kernel soft = image reconstruction algorithm for soft tissue; Kernel bone = image reconstruction algorithm for bone; C = center, W = width. The above algorithms are only for Siemens CT units; differences with other manufacturers are likely

## Indications

Generally, MR imaging is the advanced modality of choice in imaging of the spine. As a screening, CT can be applied to diagnose or rule out disc herniation particularly when an ossified herniation is suspected (Fig. 11). However, there are clinical situations where CT is superior to MRI. CT should be preferred to MRI when the bony structures have to be analyzed such as fracture of the spine (Fig. 12) or in cases of MRI contraindications.

CT is superior to MR imaging in the evaluation of bone abnormalities

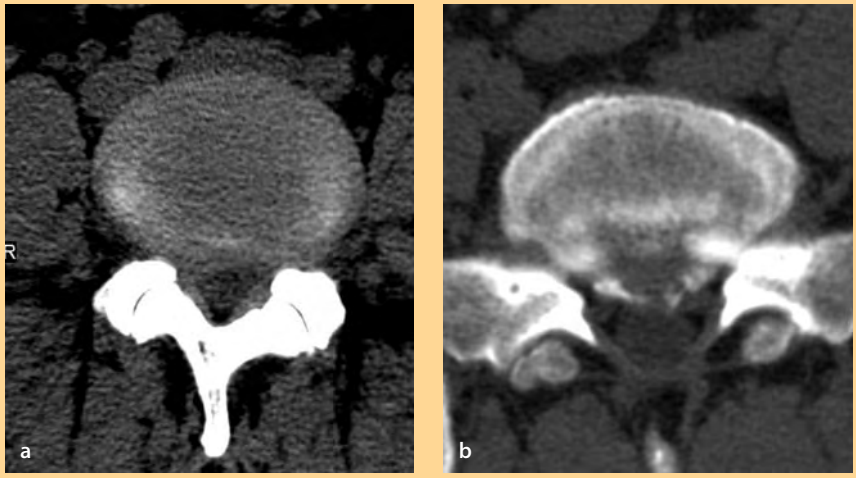


**Figure 11. CT diagnosis of disc herniation**

a CT scan at the L4/5 level (soft tissue window) demonstrating a right-sided mediolateral disc herniation. b CT scan at the L5/S1 level (soft tissue window) is superior to MRI, showing a calcified, broad-based median disc herniation.

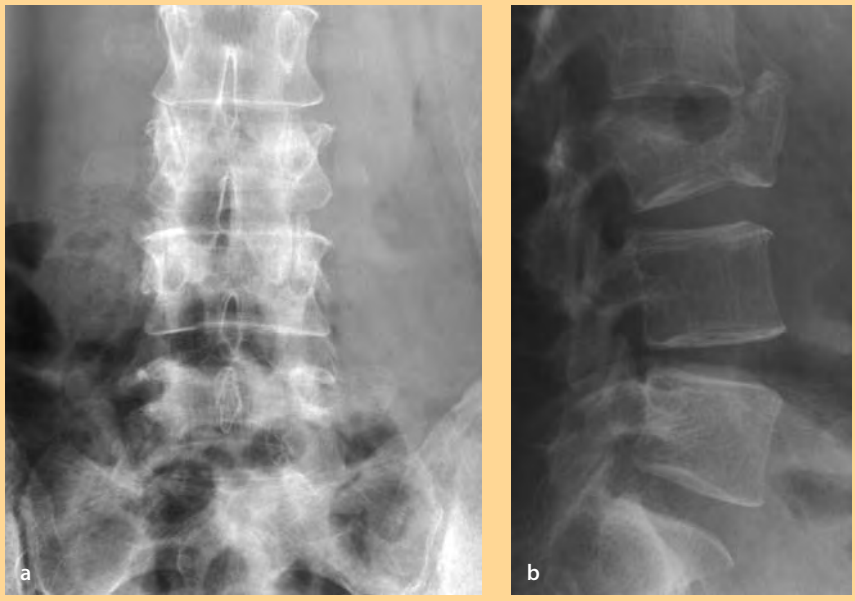


**Figure 12. CT diagnosis of spinal fractures**

a, b Standard radiographs demonstrate loss of height, widening of interpedicular distance and probable dorsally extruded fragment.

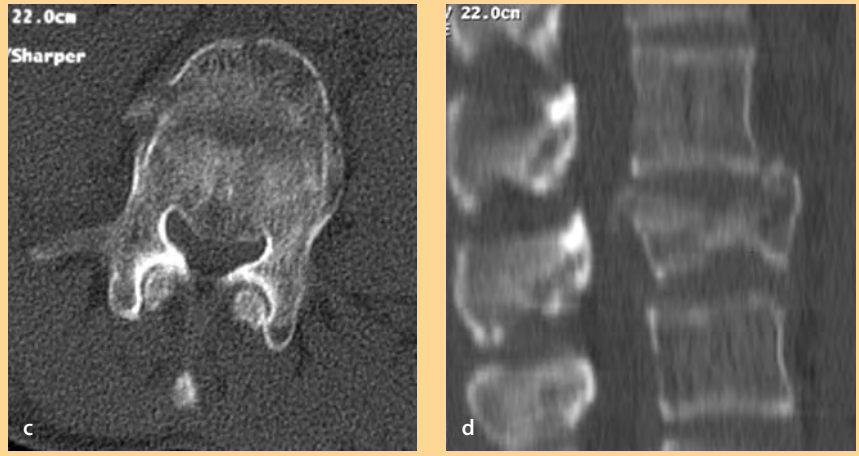


**Figure 12.** (*Cont.*)
c, d This is confirmed by a CT scan with image reformation.

Such **indications** include:

- acute spinal trauma
- evaluation of spinal fusion
- planning of complex surgical procedures (e.g., osteotomies)
- spondylolysis
- complex vertebral deformities
- claustrophobia and contraindications to MRI

### Contraindications, Artifacts, Side Effects

CT is relatively contraindicated during pregnancy. Especially in pregnancy, but also in all other instances, the indications for CT should be considered carefully.

**Beam hardening artifacts** are most commonly caused by metallic implants. These artifacts depend on the volume, orientation and atomic number of the implant. The artifacts are limited to the CT slices which include the metallic implants. These artifacts are accentuated in the longitudinal direction of screws. They appear as one or multiple thick lines which may be oriented in a sunbeam-like fashion and may cover large parts of the field of view. **Typical causes** of beam hardening artifacts are extensive dental implants, screws, cages, intervertebral disc prostheses, shoulder and hip prostheses, as well as pacemakers or drug pumps. In the vicinity of implants, beam hardening artifacts tend to be less pronounced compared to susceptibility artifacts seen on MR imaging. On the other hand, implants located far away from the spine (for example dental implants) may be more disturbing on CT images while MR images are not degraded in a clinically relevant fashion.

CT exhibits fewer artifacts than MRI in the presence of implants

## Additional Imaging Methods

### Bone Scintigraphy

Bone scans are surpassed by MR imaging and PET

$^{99m}$Technetium polyphosphonate scintigraphy, such as $^{99m}$Tc-methyl diphosphonate (MDP) scintigraphy, has been used in an almost unchanged fashion for many years [41]. For this examination, 500 – 800 MBq of $^{99m}$Tc is injected intravenously and images are obtained 2 – 3 h after injection. The $^{99m}$Tc distribution at that time shows the activity of the osteoblasts and thus demonstrates bony turnover activity. Images acquired within a few minutes after the injection demon-

strate the vascularity of the tissue. Bone scintigraphy is mainly used as a **screening tool** because it demonstrates the entire skeleton in a single examination. Bone scintigraphy may also be useful in assessment of disease activity. For local diagnosis, however, bone scintigraphy has mainly been replaced by MR imaging, which provides similar information regarding disease activity but adds anatomical details. The role of specialized scintigraphic methods such as $^{111}$In, $^{67}$Ga, or anti-granulocyte antibody scintigraphy has declined due to the increasing use of MR imaging, the advent of **positron emission tomography** (PET) and also because some of the methods do not perform in the spine as well as in peripheral bones due to the relatively large proportion of cell-rich hematopoietic bone marrow. This interferes with the detection of abnormalities such as infection and neoplasm which are also characterized by a large number of cells. Independently of this discussion, bone scintigraphy has a limited role in detecting Langerhans' cell histiocytosis and multiple myeloma [21], which both tend to be inconspicuous on $^{99m}$Tc bone scintigraphy.

Bone scan remains a skeletal screening modality for tumors or infections

### Positron Emission Tomography

Imaging with PET requires expensive equipment, especially if combined with a CT scanner (PET-CT). The tracers required for PET have short half-life periods of between a few minutes ($^{15}$O: $t^{1/2}$ = 2.1 min) and approximately 2 h ($^{18}$F: $t^{1/2}$ = 110 min). Therefore, the cyclotron generating the tracers has to be within an adequate distance of the PET scanner. A large number of different tracers are available. However, PET is typically performed with $^{18}$FDG ($^{18}$fluorodeoxyglucose). Doses of between 200 and 600 MBq of $^{18}$FDG are intravenously injected. Scanning starts after a delay of 30 – 40 min [40]. This method demonstrates areas of increased glucose metabolism which typically are present in tumors and infection. PET can provide images of large parts of the body within a single examination and is increasingly used for staging of tumors but also for the assessment of infection. Its role is not limited to bone but may be even more important for imaging of soft tissue, lymph nodes and abdominal organs.

PET is increasingly used for staging of tumors and for the assessment of infection

### Myelography

For lumbar myelography the injection of contrast is typically performed at the L2/3 level with a thin (22G) needle. Rounded needles have been advocated in order to reduce traumatizing of the dura and nerve roots but are not universally used. Application of 2.5 – 4.5 g iodine (8 – 15 ml of a contrast agent containing 300 mg/ml iodine) results in a sufficient intrathecal contrast [18]. **Water-soluble, non-ionic, iso-osmolar** types of contrast agent produce the fewest side effects. Side effects mainly include pain, which may be similar or different from the pain usually experienced. Pain is most commonly found in patients with severe stenosis of the spinal canal. Severe side effects of myelography such as seizures are infrequent [38]. However, the injection of ionic contrast media is strictly contraindicated because a severe form of seizure called "ascending tonic-clonic seizure" has been reported after inadvertent intrathecal injection of such ionic contrast agents [5, 38]. Prolonged side effects are most often related to the puncture itself. **Liquor leakage** through the dural puncture site can cause severe headache, which can last for several days or even weeks. Blood patches with approximately 8 ml of the patient's own blood have been suggested for treatment of prolonged symptoms.

Myelography can be associated with serious side effects

Immediately after intrathecal contrast administration, radiographs are obtained with the patient in the prone and lateral decubitus position as well as prone oblique radiographs (approximately 15°/30°, commonly positioned under

**Figure 13. Myelography and CT myelography**

Positional radiographs in a flexion and b extension, demonstrating segmental stenosis of the spinal canal, most pronounced at the L3/4 level. c CT at the L3/4 level, confirming stenosis of the spinal canal. Gas within degenerated disc.

Functional examination rarely has a diagnostic or therapeutic impact

fluoroscopic control, in order to better demonstrate the entire course of nerve roots). **Functional examination** in flexion and extension does not appear to have an impact on the diagnostic and therapeutic decision-making in the presence of an MRI examination and is not routinely done in our center [36, 48, 50]. Myelography is commonly combined with CT of the spine (CT myelography) (Fig. 13). The acquisition parameters are similar to those for standard CT (see CT chapter). Compared to standard CT, intrathecal contrast medium outlines the intradural space and any filling defects within this space or abnormalities impinging on the dural sac. Stenosis of the spinal canal or the lateral recesses as well as the influence of disc herniation on intradural structures may even be more clearly demonstrated than by MR imaging.

Direct cervical myelography with craniocervical injections has largely been replaced by MR imaging or CT myelography obtained after lumbar injection.

Indications for myelography or CT myelography in the era of MRI are very rare and are restricted to the following conditions:

- postoperative spine with marked susceptibility artifacts in MRI
- unclear conditions with suspected functional stenosis

In all other cases MRI should provide enough information about foraminal or spinal canal stenosis. Only in a few cases is additional CT without intrathecal contrast administration necessary to distinguish between osteophyte formation and disc protrusion within the intervertebral foramen, mainly in the cervical spine.

The diagnostic value of MR myelography is questionable

**MR myelography** (MR imaging performed after intrathecal injection of MR contrast media) has rarely been employed but appears to be feasible. No adverse reactions other than those known from conventional myelography were found in these patients. However, the technique of intrathecal administration of gadopentetate and related contrast media has so far not been approved by the responsible state agencies and the additional diagnostic effect is questionable.

### Image Guided Injections

Image guided injections such as nerve root blocks or facet joint injections are discussed in Chapter 10. Fluoroscopy and CT (possibly CT fluoroscopy) are most commonly employed as guiding methods for such procedures although MR imaging has also been suggested for this purpose.

### Ultrasonography

Sonography has a limited role in imaging of the spine

Ultrasonography does not play an important role in imaging of the spine. Retroperitoneal abnormalities are commonly examined from ventrally with a transducer suitable for abdominal imaging (commonly a curved array transducer with a frequency of 3.5–5 MHz). The evaluation of the contents of the spinal canal cannot easily be performed sonographically. The bony surfaces surrounding the relevant structures prevent a consistent evaluation.

Sonography has been used to guide periradicular injections in the lumbar spine [13] and it has also been used as guidance for lumbar sympathetic trunk blocks [20]. There may be a role for intraoperative sonography in spinal cord tumors or malformations but probably not typically for the evaluation of degenerative disc disorders and other common spine abnormalities [12].

Sonography is routinely used for the assessment of cervical arteries

Duplex sonography and color Doppler sonography are excellent tools for evaluation of the vertebral and carotid arteries [3]. The vertebral arteries can be injured in different types of spinal trauma (such as vertebral artery dissection in cervical fractures extending into the transverse foramen). Alternatively, MR imaging (loss of the flow void within the artery), MR angiography with intravenous injection of MR contrast media or CT angiography after injection of iodine containing contrast media can be obtained to demonstrate abnormalities of the vertebral arteries [45].

## Indications for Spinal Imaging

There are no universally accepted and standardized indications for the application of imaging modalities in spinal disorders. However, the following imaging algorithms are enhanced by evidence from the literature and resemble a "best practice" approach as used in our spine center.

### Acute Low Back Pain Without Radicular Symptoms, Without Trauma

In acute non-specific low back pain, imaging is usually not necessary

In acute low back pain, imaging is **not recommended during the first 6 weeks** of a pain episode if:

- spinal infection or
- tumor

can be excluded.

Standard radiographs demonstrate transitional anomalies which may be overlooked on MRI

**Upright anteroposterior** and **lateral radiographs** of the lumbar spine are the basis of imaging. Radiographs give an overview and demonstrate bony details and indirect signs of disc degeneration including reduced disc height, sclerosis of the vertebral endplates, spondylophytes as well as osteoarthritis of the facet joints. In cases of **anomalies of the transition** between the lumbar spine and the sacrum, conventional radiographs are important for definition of the lumbar segments. **Calcifications** are easily recognizable on standard radiographs. Standard radiographs are obtained with the patient in the upright position, which is only possible with very few MR scanners. In addition, degenerative or inflammatory findings of the sacroiliac joints are often recognized on these standard examinations.

**Specific MR imaging questions** are related to the presence of:

- disc degeneration
- disc herniation
- nerve root compromise
- facet joint osteoarthritis
- spinal canal stenosis
- spondylodiscitis
- rare findings (e.g., intra- and extradural tumors)

Sacroiliac disorders may be overlooked using standard MRI protocols

Suspected abnormalities of the **sacroiliac joint** should be specifically mentioned in the request for the MR examination because the imaging protocol has to be adapted. (Angled) coronal or axial images covering the entire sacroiliac joint as well as sequences able to recognize inflammatory disease such as STIR (short TI inversion recovery) or contrast-enhanced T1 W fat-suppressed sequences are added in this situation.

The use of MR imaging without standard radiographs may be considered when abnormalities are suspected which are not typically associated with bone abnormalities.

CT and myelography are not relevant in acute low back pain. Imaging guided nerve root blocks or facet joint blocks may be useful for obtaining more precise topographical diagnostic information, for determination of the relevance of MR abnormalities and for therapeutic purposes (see Chapter 10).

## Acute Low Back Pain With Radicular Symptoms

MR imaging is superior to CT for the assessment of radiculopathy

Imaging considerations are similar to those described above. The difference is in timing. Imaging is performed at the beginning of the diagnostic work-up. In the presence of motor weakness (M3 and worse) imaging is performed as an emergency examination. MR imaging usually represents the method of choice because it demonstrates the location and extent of nerve root compromise. Standard radiographs are not necessary for the initial analysis but should be obtained prior to surgery.

There are several **disc herniation classification systems** (see Chapter 18) currently in use [6, 7, 22]. Today, the most frequently used system is the one suggested by Modic and coworkers [22]:

- **normal:** no disc extension beyond interspace (DEBIT)
- **bulging:** circumferential, symmetric DEBIT around the endplate
- **protrusion:** focal or asymmetric DEBIT into the canal, the base against the parent disc is broader than any other diameter of the protrusion
- **extrusion:** focal, obvious DEBIT, the base against the parent disc is narrower than the diameter of the extruding material itself
- **sequestration:** the extruded material has lost its connection to the parent disc

Often more important than the description of the shape of the intervertebral disc is its influence and relation to the adjacent nerve roots, which is crucially dependent on the width of the spinal canal [10]. Pfirrmann et al. [29] showed good interobserver reliability in following the **nerve root compromise** classification system (see Chapter 18):

- **no compromise:** normal epidural fat layer visible between nerve root and disc
- **contact** to nerve root: no epidural fat layer visible between nerve root and disc; nerve root is in normal position and is not dorsally deviated
- **deviation** of nerve root: nerve root is displaced dorsally by disc
- **compression** of nerve root: nerve root is compressed between disc and the wall of the spinal canal; it may appear flattened or be indistinguishable from disc material

CT is inferior to MRI in this situation and is only indicated in the case of contraindications for MRI. Imaging guided treatment such as nerve root blocks or facet joint blocks may be employed for therapeutic rather than diagnostic purposes.

## Spinal Cord and Cauda Compression Syndromes

A suspected spinal cord and cauda equina compression syndrome is an emergency situation requiring immediate MR imaging. If no clear diagnosis such as a large disc herniation or intraspinal hemorrhage can be made, a tumor within the spinal cord has to be excluded. In such cases, **contrast enhanced MRI** should be obtained and imaging should be extended to include the thoracic and cervical spine.

Spinal cord and cauda equina compression represent an emergency indication for MR imaging

### Acute Trauma

Imaging starts with standard radiographs in two planes. If conventional radiographs lead one to suspect vertebral fracture or if they are equivocal, CT with multiplanar reformations is employed. Increasingly, CT is even used as a primary examination, especially in polytraumatized patients. If a multidetector CT (MDCT) is available, the acquired data sets can be used for reconstruction of the spine with adequate image quality [32]. MR imaging can be necessary for identification of radiologically occult fractures (Figs. 14–16) and bone contusions. MRI reveals additional information regarding:

Trauma is typically imaged with standard radiographs and CT

- herniated disc material
- epidural or intramedullary hematoma (Fig. 15)
- post-traumatic myelopathy
- spinal cord transsection (Fig. 15)
- injury to the posterior support structures

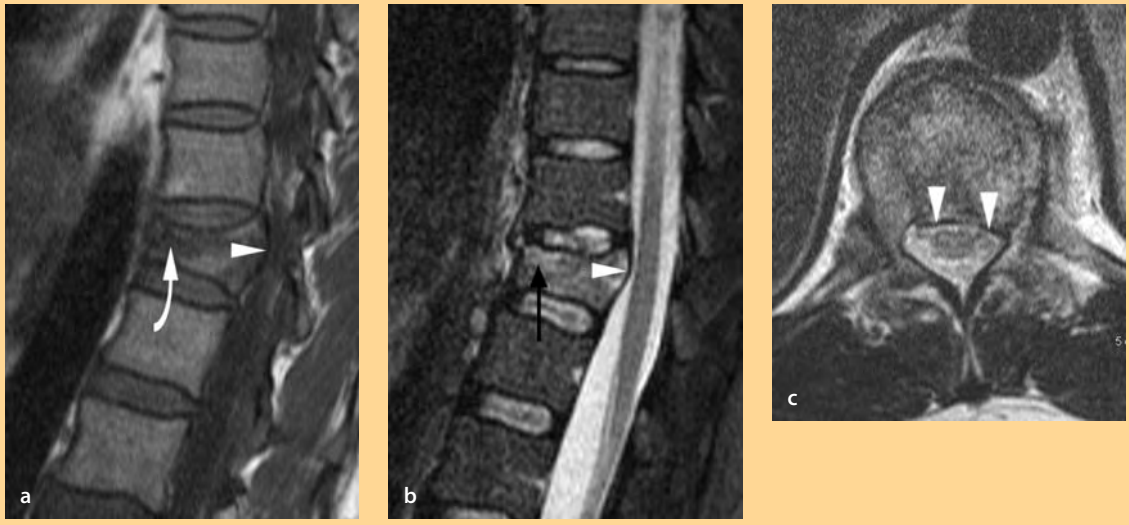


**Figure 14. Acute trauma**

a Sagittal T1 W and b sagittal STIR sequences as well as c axial T2 W sequence of a patient with an acute trauma of the thoracic spine. Anterior collapse of the vertebral body is visible in all sagittal sequences and posterior dislocation of a broad-based fragment into the spinal canal (*arrowheads*). Caused by edema and hemorrhage, there is low signal within the bone marrow in the T1 W (*curved arrow*) image. In the fluid-sensitive STIR sequence, edema is much more conspicuous (*black arrow*).

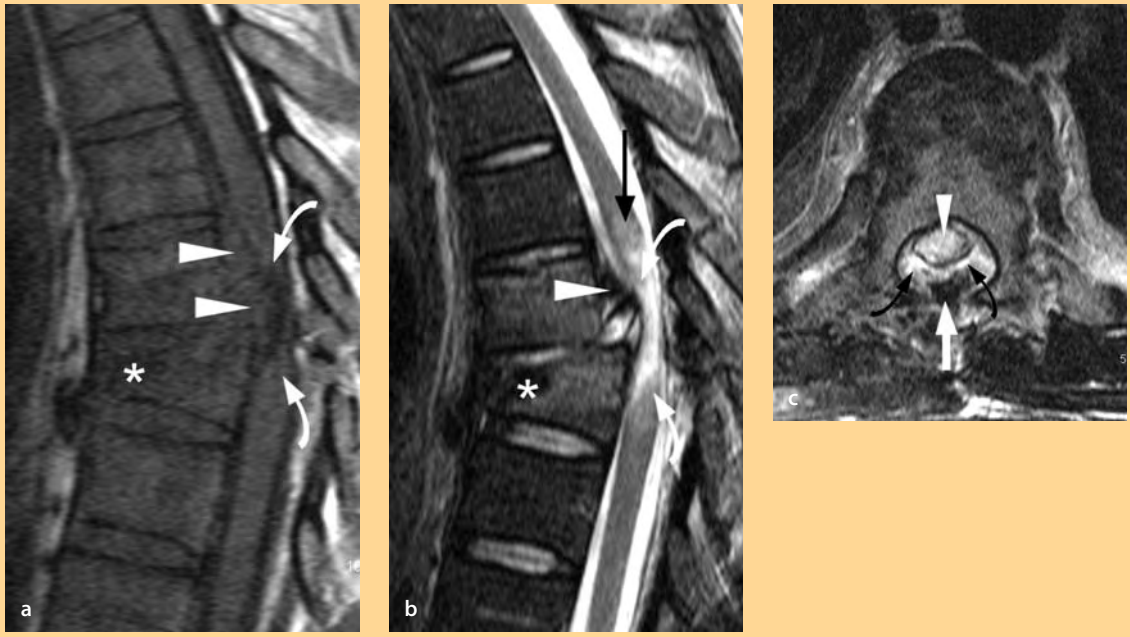


**Figure 15. Spinal cord lesion**

a Sagittal T1 W and b T2 W sequences as well as c axial T2 W sequence of the thoracic spine after a car accident. Anterior collapse of the vertebral body and bone marrow edema is visible in both sagittal sequences (*asterisk*). There is disruption of the spinal cord and dislocation (*curved white arrows*). There is hemorrhage and myelopathy within the spinal cord (*straight black arrow*). Hemorrhage can be seen in the anterior epidural space (*arrowheads*) and also in the posterior epidural space (*straight white arrow*). The dural sac is compressed (*curved black arrows*).

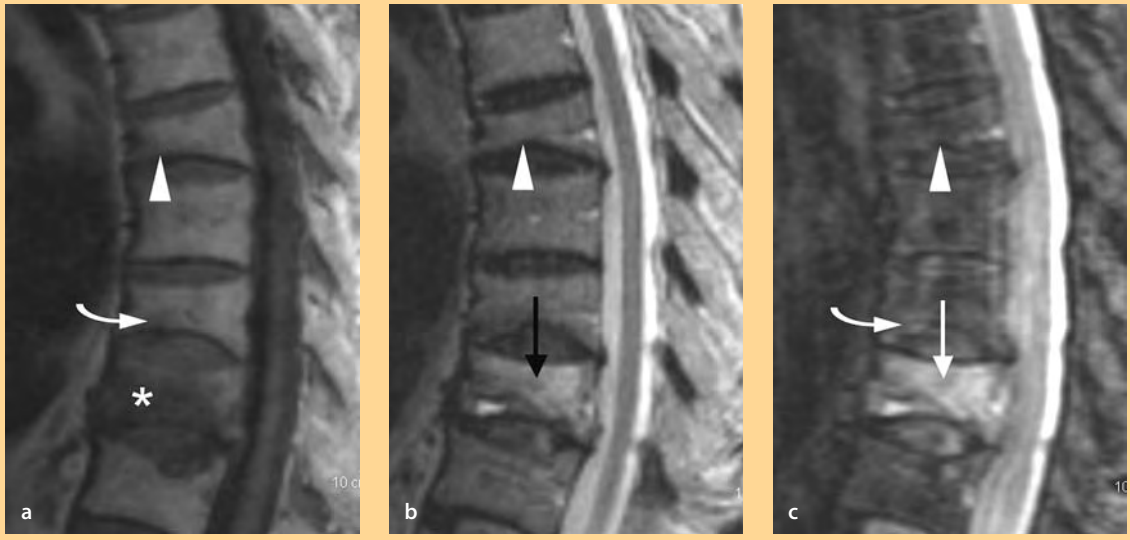


**Figure 16. MRI in acute and old osteoporotic vertebral fractures**

a Sagittal T1 W and b T2 W sequences as well as c sagittal STIR sequence of the thoracic spine in an osteoporotic patient. There is collapse of three different vertebral bodies. The acute fracture (*asterisk*) of one vertebral body can be identified by the low signal in the T1 W (*asterisk*) sequence and high signal within the bone marrow in T2 W (*black arrow*) and STIR (*white arrow*) sequences. Only a slight signal increase near the endplate of the adjacent vertebral body is visible in the STIR sequence (*curved arrow*), which can be caused by degeneration or some minor infraction. There is also an old vertebral body fracture (*arrowhead*) visible without bone marrow signal alterations.

The **appearance of spinal cord lesions** on MR imaging provides prognostic information regarding the likely extent of recovery of neurologic function [11, 19]. Magnetic resonance angiography can reliably demonstrate vertebral artery injuries not uncommonly associated with cervical spine subluxation or dislocation and fractures crossing the transverse foramen [45].

## Chronic Low Back Pain

In chronic low back pain, standard radiographs and MR imaging are the most useful imaging methods

Standard radiographs in the anteroposterior and lateral planes are typically obtained initially although they are usually not very helpful. However, they can occasionally demonstrate unexpected lesions, such as:

- spinal deformities
- previous fractures
- previous infection or other inflammatory diseases
- tumors (later stage)

For additional imaging in most instances, **MRI is preferable** to CT. It is superior to CT for evaluation of:

- disc degeneration
- endplate changes
- disc herniation
- annular tears
- spinal canal and foraminal stenosis

**Endplate changes** are classified according to **Modic** [23] into three grades (Fig. 8):

- **Grade I:** decreased signal on T1 W images and increased signal on T2 W images
- **Grade II:** increased signal on T1 W and T2 W images
- **Grade III:** decreased signal on T1 W and T2 W images

MRI is not inferior to CT for the evaluation of facet joint alterations

Even for evaluation of the **facet joints**, MR imaging does not provide less information than CT [49].

In **suspected osteoporotic fractures**, MR imaging is preferable to CT because signal alterations within the fractured vertebral body allow the determination of whether a fracture is acute (up to a few weeks old) or old (Fig. 16). Such information, for instance, is important in a medicolegal context and it represents a predictor for the success of percutaneous vertebroplasty [1].

## Postoperative Imaging

In postoperative imaging, CT best assesses implants and bony fusion

Standard radiography demonstrates spinal deformity, the position and signs of loosening of implants as well as degeneration in segments adjacent to spinal fusion. CT better demonstrates problems associated with **metallic implants** than competing standard radiographs and MR imaging, including the localization of implants, bone resorption associated with loosening as well as fusion of bone fragments, facet joints or implanted bone (Fig. 17). It is the imaging modality of choice for the **assessment of spinal fusion**.

MR imaging is used for soft tissue abnormalities in the postoperative spine

If non-osseous structures are of primary interest, MR imaging is more useful than CT in the evaluation of the postoperative spine. Typical diagnoses made by MR imaging include:

- recurrent disc herniation
- differentiation between disc herniation and postoperative epidural scar
- intradural hematoma
- epidural or soft tissue abscess
- dural fistula

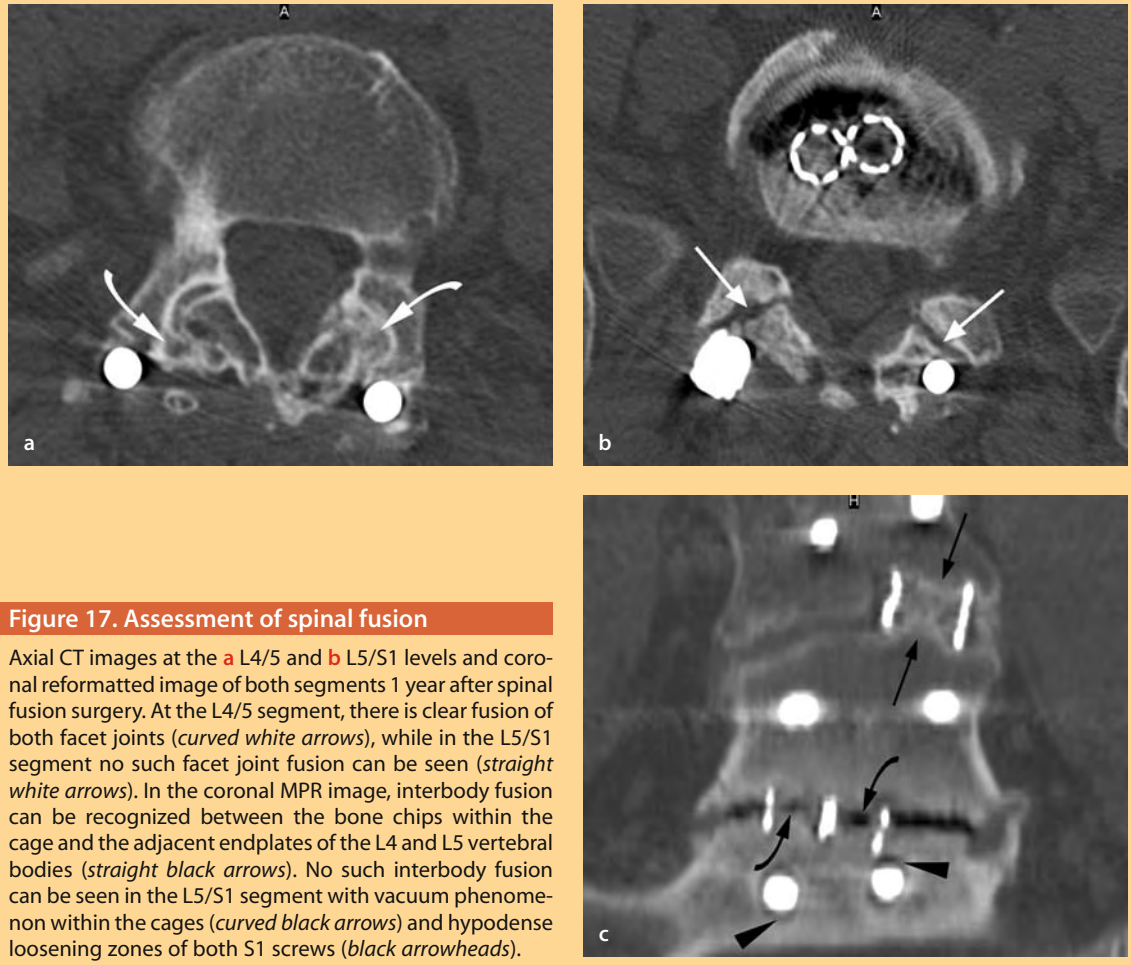


**Figure 17. Assessment of spinal fusion**

Axial CT images at the **a** L4/5 and **b** L5/S1 levels and coronal reformatted image of both segments 1 year after spinal fusion surgery. At the L4/5 segment, there is clear fusion of both facet joints (*curved white arrows*), while in the L5/S1 segment no such facet joint fusion can be seen (*straight white arrows*). In the coronal MPR image, interbody fusion can be recognized between the bone chips within the cage and the adjacent endplates of the L4 and L5 vertebral bodies (*straight black arrows*). No such interbody fusion can be seen in the L5/S1 segment with vacuum phenomenon within the cages (*curved black arrows*) and hypodense loosening zones of both S1 screws (*black arrowheads*).

Contrast enhancement facilitates the differentiation of scar and recurrent herniation

Intravenous contrast is commonly injected in the postoperative situation in order to better differentiate fluid-filled structures from solid ones. It may also assist in the differentiation between **postoperative scar** and granulation tissue from **recurrent disc herniation**, although the value of contrast is not as well documented as it was for CT, which was employed for this purpose before the advent of MR imaging (Fig. 18).

**Imaging guided injections** may be useful for the differentiation of the source of pain or for non-invasive treatment. Ultrasonography is a quick and reliable imaging method for detection of fluid collections in the periverterbral soft tissues. Bone scintigraphy may be used for detection of infection.

## Whiplash-Associated Disorders

In WADs a multidisciplinary work-up is recommended

According to the Quebec Task Force on Whiplash-Associated Disorders, acute whiplash-associated disorders (WADs) should be classified initially by conventional radiographs. If fractures are visible on the initial radiograph, CT has to evaluate the stability of the fracture. If no fracture is seen on the initial radiograph, multidisciplinary work-up should follow after 6 weeks of pain persistence [37]. At that time, MR imaging is still able to identify bone marrow signal alterations caused by occult fractures or residual changes of soft tissue hematoma. In

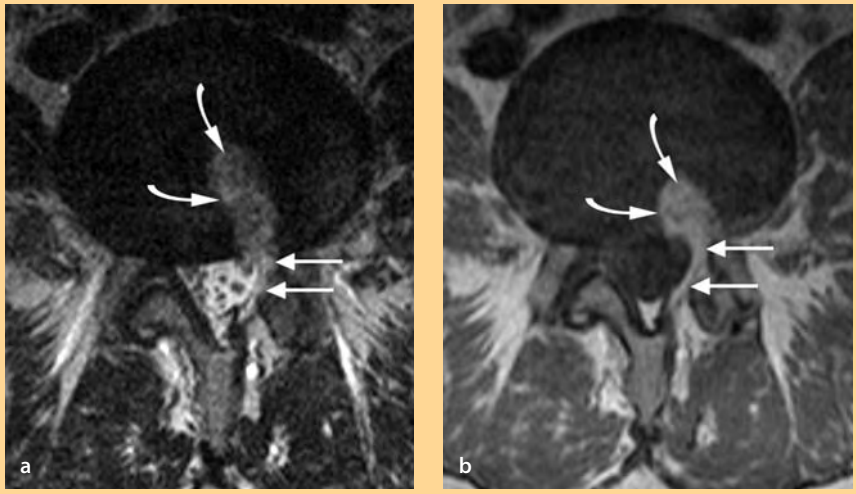


**Figure 18. Differential diagnosis scar versus recurrent herniation**

a Axial T2 W and b T1 W contrast enhanced images at the level of the L4/5 disc a few months after surgery of a disc extrusion. a The T2 W image shows left sided laminotomy and some signal alteration within the epidural space (*straight white arrows*) and in the disc (*curved white arrows*). b After contrast injection there is intense contrast enhancement within the granulation/scar tissue in the epidural space (*straight white arrows*) as well as within the disc (*curved white arrows*). No recurrent herniation is seen.

addition, MR imaging can then identify other reasons for pain persistence such as disc protrusion and extrusion or other degenerative changes of the cervical spine.

In WADs, the role of imaging is to exclude a structural pathology

In chronic whiplash-associated disorders, almost all radiological tools fail to identify a distinct morphological abnormality. Tears of the alar ligaments have been related to the complaints in these patients. Unfortunately, the morphologic variability of the alar ligaments is considerable in asymptomatic volunteers with asymmetry in length and thickness, as well as ill-defined borders in many instances [28]. Some authors have proposed rotational CT measurements of the craniocervical junction as a radiological tool to identify **alar ligament abnormalities** [2]. In asymptomatic volunteers, identical differences between **left-sided and right-sided rotation** of the cervical spine were found [27]. Therefore, rotational CT or MR imaging may have been overestimated in chronic whiplash-associated disorders. MR imaging may be performed to exclude other reasons for the patient's complaints, such as degenerative changes of the facet joints or disc protrusion. Pain relief has been described in some cases of chronic whiplash-associated disorders and associated facet joint degeneration after radiofrequency medial branch neurotomy [34].

In WADs, alar ligament alterations and atlantoaxial rotational abnormalities are of questionable relevance

## Pain Relating to the Sacroiliac Joint

MRI is superior to CT in the demonstration of inflammatory disease of the SIJ

Standard radiographs of the pelvis may not demonstrate subtle disease of the sacroiliac joints (SIJs) for projectional reasons and because bowel gas may overlap with the sacroiliac joints. Barsony's view assists in the evaluation of the sacroiliac joints but may still miss early or subtle diseases. CT is useful in the assessment of bony abnormalities such as intra-articular bone bridging in ankylosing spondylitis or after surgical fusion. CT is also the best method for the demonstration of too extensive bone harvesting at the posterior iliac crest, with bone defects reaching the sacroiliac joint.

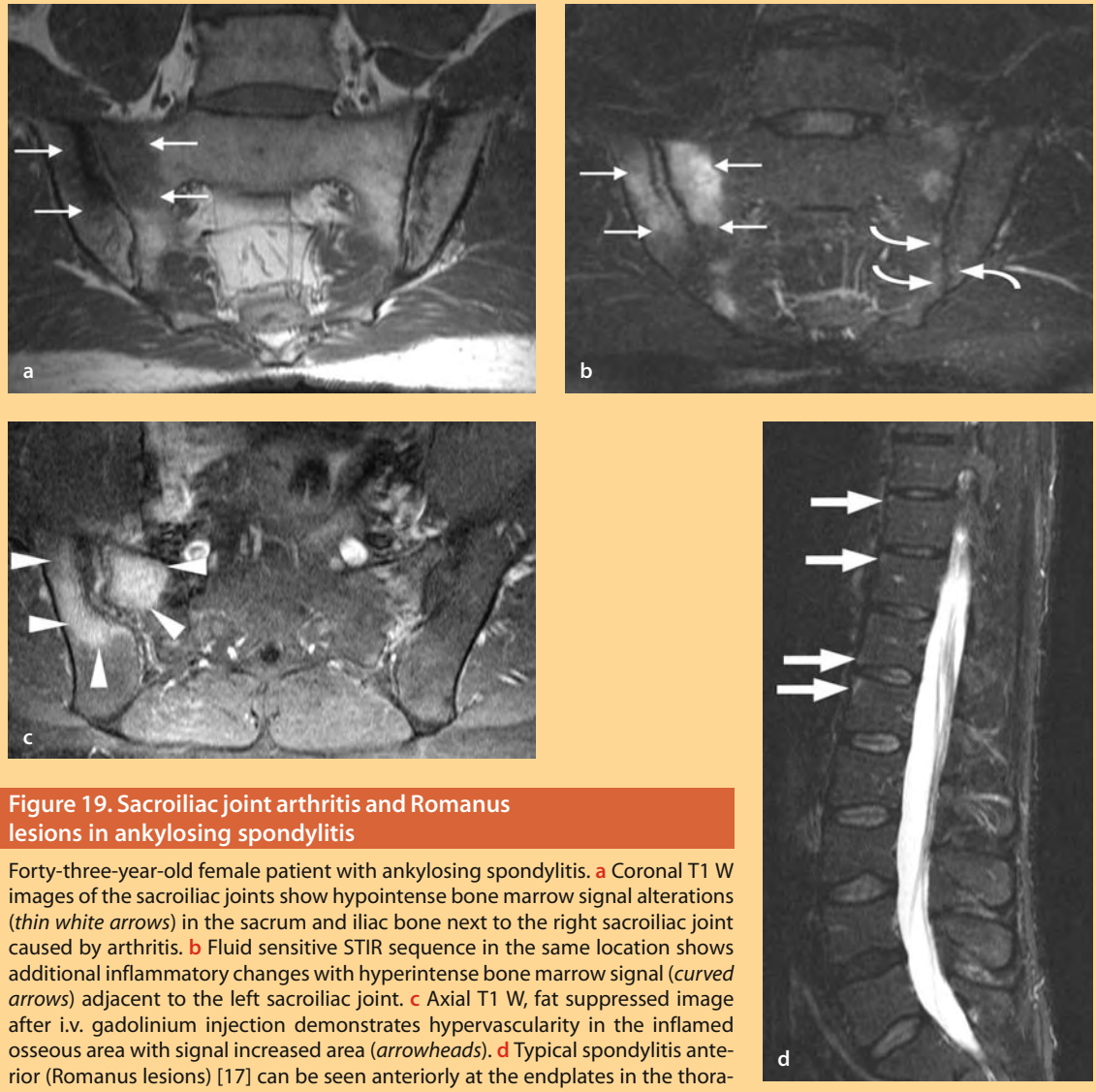


**Figure 19. Sacroiliac joint arthritis and Romanus lesions in ankylosing spondylitis**

Forty-three-year-old female patient with ankylosing spondylitis. **a** Coronal T1 W images of the sacroiliac joints show hypointense bone marrow signal alterations (*thin white arrows*) in the sacrum and iliac bone next to the right sacroiliac joint caused by arthritis. **b** Fluid sensitive STIR sequence in the same location shows additional inflammatory changes with hyperintense bone marrow signal (*curved arrows*) adjacent to the left sacroiliac joint. **c** Axial T1 W, fat suppressed image after i.v. gadolinium injection demonstrates hypervascularity in the inflamed osseous area with signal increased area (*arrowheads*). **d** Typical spondylitis anterior (Romanus lesions) [17] can be seen anteriorly at the endplates in the thoracolumbar junction (*bold white arrows*).

For detection of the **acute phase of spondarthropathies** with involvement of the sacroiliac joints, MR imaging is increasingly used, with or without intravenous contrast media (Fig. 19). Commonly, the examination is combined with a sagittal screening series of the lumbar and lower thoracic spine or even in combination with whole body imaging for staging of systemic inflammatory disease.

Bone scintigraphy is less commonly used in sacroiliac joint inflammation. Even normal sacroiliac joints demonstrate increased activity, which may obscure additional activity caused by inflammatory disease.

In suspected septic arthritis, image guided biopsy can be obtained, which is most commonly performed under CT control. In spondarthropathy, the same technique may be used for local application of steroids. In degenerative disease, local anesthetics with or without steroids can be applied for differentiation of pain sources and for treatment.

## Disease of the Spinal Cord

In spinal cord disease, MR imaging is by far the most important diagnostic tool

Standard radiographs and CT do not provide detailed information about the spinal cord although they may demonstrate bone abnormalities associated with spinal cord disease, such as posterior defects. CT myelography only depicts the contour of the spinal cord but provides little information about the spinal cord substance. MR imaging is clearly the method of choice for demonstration of spinal cord abnormalities such as:

- syringomyelia or hydromyelia
- ischemic changes
- myelopathy associated with multiple sclerosis
- spinal cord tumors

The imaging protocol typically includes the **intravenous injection of contrast media**. The imaging protocol is adapted to the spinal cord, which commonly means the addition of more imaging planes. In order to cover larger regions, slice thickness in the axial plane may be increased in comparison to the protocols aimed at imaging of disc disease. On the other hand, slice thickness in the sagittal plane may be reduced for reduction of partial volume artifacts at the borders of the spinal cord.

### Recapitulation

**Standard radiographs.** These represent the basis of spinal imaging. Conventional film/screen combinations are increasingly being replaced by digital systems. Computed radiology (CR) systems use cassettes with X-ray-sensitive phosphor plates and **digital radiography** (DR) systems use flat panels, directly transforming X-ray energy into digital signals. Upright anteroposterior and lateral radiographs are the basis of imaging. Additional projections (including oblique radiography, Barsony's view) have lost their importance due to the increasing role of cross-sectional imaging. Lateral **positional radiographs** in flexion and extension may be used for assessing instability but are rarely diagnostic. **Whole spine radiographs** should only be used after careful consideration of the indication (mainly in scoliosis) due to the involved radiation dose.

**MR imaging.** This is the second most commonly employed imaging method in assessing spinal disorders. 1.5-Tesla scanners with tunnel-shaped magnets are typically employed. High-field scanners with 3.0 T or higher field strengths are increasingly available. They provide higher **spatial resolution**, better signal-to-noise ratio and shorter acquisition times. For adequate imaging of the spine, dedicated coils have to be employed. A number of different designs are available which are placed underneath the body. With increasing distance from these surface coils, signal and image quality decreases. Therefore, designs with both dorsal and ventral elements are available. **Standard T1 W** and **T2 W sagittal sequences**, as well as **axial T2 W sequences**, provide a basis for MR imaging of the spine. In the cervical spine, gradient-echo sequences may be preferable in the axial plane because they produce fewer flow-related artifacts. Occasionally, **intravenous injection of MR contrast** agents is necessary. They typically produce increased signal on T1 W sequences and are most commonly used in suspected tumors, demyelination, infection (spondylitis, spondylodiscitis or soft tissue infection), spontaneous intraspinal hemorrhage for demonstration of vascular malformations, and inflammatory rheumatological disorders; and for assessing the postoperative spine. MR imaging is contraindicated in the presence of cardiac pacemakers, neurostimulators, insulin pumps, inner ear implants and certain metallic fragments. Implants used for spinal surgery do not represent contraindications for MR imaging, however, although image quality may be degraded due to susceptibility artifacts.

**Computed tomography.** CT demonstrates **bony details** with a high spatial resolution. In plane resolution of CT (pixel size) is approximately 0.25–0.5 mm, which is superior to MR imaging. In addition, CT does not interfere with pacemakers

and other electronic devices. CT suffers from artifacts different from those in MR imaging, the so-called beam-hardening artifacts. However, CT is no longer competitive with regard to soft tissue abnormalities and is also associated with quite impressive radiation to the patient.

**Additional imaging studies.** Myelography has few remaining indications such as the presence of metallic implants interfering with both MR imaging and CT. **Ultrasonography** may occasionally be employed for assessment of paravertebral soft tissue and vessels. **Nuclear medicine studies** are useful for the determination of activity and location of bone abnormalities.

**Choice of imaging methods for the most common indications.** In **acute low back pain**, imaging is **not recommended during the first 6 weeks** unless infection or tumor is suspected and unless radicular symptoms are present. After 6 weeks, standard radiographs are performed, which answer questions such as degeneration of disc space and facet joints and congenital abnormalities. Typically, MR imaging is required for further diagnosis (disc degeneration, nerve root compromise, facet joint osteoarthritis, spinal canal stenosis, spondylodiscitis and tumors). **Suspected spinal cord and cauda equina compression** require immediate MR imaging. In **acute trauma**, imaging starts with standard radiographs. If they demonstrate a fracture or are equivocal, **CT with multiplanar reformations** is employed. CT has even been suggested as a primary examination, especially in polytraumatized patients. MR imaging is useful in demonstrating herniated disc material and other soft tissue abnormalities. **In chronic low back pain**, standard radiographs are typically obtained initially, followed by MR imaging, which is mainly used for disc degeneration, endplate changes and spinal canal and foraminal stenosis and even for facet joints. In **postoperative imaging,** standard radiographs demonstrate spinal deformity, the position and signs of loosening of implants as well as degeneration in segments adjacent to spinal fusion. CT more precisely demonstrates metallic implants and **bony fusion**. MR imaging is most useful in suspected recurrent disc herniation, epidural scars, intradural hematoma, epidural or soft tissue abscess and dural fistula. In the so-called **"whiplash injury"** standard radiographs are obtained initially. In the case of fractures, CT is performed. Otherwise, a multidisciplinary work-up starting within 6 weeks has been recommended. In pain relating to the **sacroiliac joint** standard radiographs are useful in advanced stages of disease. CT best demonstrates intra-articular bone bridging in ankylosing spondylitis. In systemic inflammatory disease, MR imaging is increasingly being used. In **spinal cord abnormalities** MR imaging is clearly the method of choice, typically with intravenous injection of contrast media.

## Key Articles

**Modic MT, Steinberg PM, Ross JS, Masaryk TJ, Carter JR (1988) Degenerative disk disease: assessment of changes in vertebral body marrow with MR imaging. Radiology 166:193 – 199**

This article describes three different types of endplate alterations. In all cases of endplate changes there is evidence of associated degenerative disc disease at the level of involvement. Histopathologic sections in type 1 change demonstrated disruption and fissuring of the endplates and vascularized fibrous tissue, while in type 2 change they demonstrated yellow marrow replacement.

**Stumpe KD, Zanetti M, Weishaupt D, Hodler J, Boos N, Von Schulthess GK (2002) FDG positron emission tomography for differentiation of degenerative and infectious endplate abnormalities in the lumbar spine detected on MR imaging. Am J Roentgenol 179:1151 – 1157**

FDG PET may be useful for differentiation of degenerative and infectious endplate abnormalities detected on MR imaging. Even in active (Modic type I) degenerative endplate abnormalities, PET did not show increased FDG uptake.

**Weishaupt D, Zanetti M, Boos N, Hodler J (1999) MR imaging and CT in osteoarthritis of the lumbar facet joints. Skeletal Radiol 28:215 – 219**

There is moderate to good agreement between MR imaging and CT in the evaluation of osteoarthritis of the lumbar facet joints. When differences of one grade are disregarded,

Key Articles

agreement is even excellent. In the presence of an MR examination additional CT is not required for the assessment of facet joint degeneration.

**Pfirrmann CW, Dora C, Schmid MR, Zanetti M, Hodler J, Boos N (2004) MR image-based grading of lumbar nerve root compromise due to disk herniation: reliability study with surgical correlation. Radiology 230:583 – 588**
The MR image-based grading system used in this study enables discrimination between grades of nerve root compromise in the lumbar spine with sufficient reliability for both research and clinical purposes.

**Pfirrmann CW, Metzdorf A, Zanetti M, Hodler J, Boos N (2001) Magnetic resonance classification of lumbar intervertebral disc degeneration. Spine 26:1873 – 1878**
Disc degeneration can be graded reliably on routine T2 W magnetic resonance images using the grading system and algorithm presented in this investigation.

**Brant-Zawadzki MN, Jensen MC, Obuchowski N, Ross JS, Modic MT (1995) Interobserver and intraobserver variability in interpretation of lumbar disc abnormalities. A comparison of two nomenclatures. Spine 20:1257 – 1263**
The most common disagreement was for normal versus bulge. Herniation was read in 23 % of the asymptomatic subjects. Experienced readers using standardized nomenclature showed moderate to substantial agreement with interpreting disc extension beyond the interspace on magnetic resonance imaging.

**Mullin WJ, Heithoff KB, Gilbert TJ Jr, Renfrew DL (2000) Magnetic resonance evaluation of recurrent disc herniation: is gadolinium necessary. Spine 25:1493 – 1499**
In nine interpretations wherein the readers thought that a contrast-enhanced examination might provide useful additional information, they did not change their interpretations in three cases, improved their interpretations in two, and made their interpretations worse in four on the basis of the addition of the enhanced images.
Routine use of contrast-enhanced examinations in patients who have had prior lumbar surgery probably adds little diagnostic value and may be confusing.

## References


1. Alvarez L, Perez-Higueras A, Granizo JJ, de Miguel I, Quinones D, Rossi RE (2005) Predictors of outcomes of percutaneous vertebroplasty for osteoporotic vertebral fractures. Spine 30:87 – 92
2. Antinnes J, Dvorak J, Hayek J, Panjabi M, Grob D (1994) The value of functional computed tomography in the valuation of soft-tissue injury in the upper cervical spine. Eur Spine J 3:98 – 101
3. Bartels E, Flugel KA (1996) Evaluation of extracranial vertebral artery dissection with duplex color-flow imaging. Stroke 27:290 – 5
4. Baur A, Stabler A, Arbogast S, Duerr HR, Bartl R, Reiser M (2002) Acute osteoporotic and neoplastic vertebral compression fractures: fluid sign at MR imaging. Radiology 225:730 – 5
5. Bohn HP, Reich L, Suljaga-Petchel K (1992) Inadvertent intrathecal use of ionic contrast media for myelography. AJNR Am J Neuroradiol 13:1515 – 9
6. Brant-Zawadzki M, Jensen M (1995) Spinal nomenclature. Spine 20:388 – 90
7. Brant-Zawadzki MN, Jensen MC, Obuchowski N, Ross JS, Modic MT (1995) Interobserver and intraobserver variability in interpretation of lumbar disc abnormalities. A comparison of two nomenclatures. Spine 20:1257 – 63; discussion 1264
8. Cooke FJ, Blamire AM, Manners DN, Styles P, Rajagopalan B (2004) Quantitative proton magnetic resonance spectroscopy of the cervical spinal cord. Magn Reson Med 51:1122 – 8
9. de Bruin ED, Vanwanseele B, Dambacher MA, Dietz V, Stussi E (2005) Long-term changes in the tibia and radius bone mineral density following spinal cord injury. Spinal Cord 43:96 – 101
10. Dora C, Walchli B, Elfering A, Gal I, Weishaupt D, Boos N (2002) The significance of spinal canal dimensions in discriminating symptomatic from asymptomatic disc herniations. Eur Spine J 11:575 – 81
11. Flanders AE, Spettell CM, Tartaglino LM, Friedman DP, Herbison GJ (1996) Forecasting motor recovery after cervical spinal cord injury: value of MR imaging. Radiology 201:649 – 55
12. Fritz T, Klein A, Krieglstein C, Mattern R, Kallieris D, Meeder PJ (2000) Teaching model for intraoperative spinal sonography in spinal fractures. An experimental study. Arch Orthop Trauma Surg 120:183 – 7

13. Galiano K, Obwegeser AA, Bodner G, Freund MC, Gruber H, Maurer H, Schatzer R, Ploner F (2005) Ultrasound-guided periradicular injections in the middle to lower cervical spine: an imaging study of a new approach. Reg Anesth Pain Med 30:391 – 6
14. Georgy BA, Hesselink JR, Middleton MS (1995) Fat-suppression contrast-enhanced MRI in the failed back surgery syndrome: a prospective study. Neuroradiology 37:51 – 7
15. Grampp S, Jergas M, Lang P, Steiner E, Fuerst T, Gluer CC, Mathur A, Genant HK (1996) Quantitative CT assessment of the lumbar spine and radius in patients with osteoporosis. AJR Am J Roentgenol 167:133 – 40
16. Hansen J, Jurik AG, Fiirgaard B, Egund N (2003) Optimisation of scoliosis examinations in children. Pediatr Radiol 33:752 – 65
17. Jevtic V, Kos-Golja M, Rozman B, McCall I (2000) Marginal erosive discovertebral "Romanus" lesions in ankylosing spondylitis demonstrated by contrast enhanced Gd-DTPA magnetic resonance imaging. Skeletal Radiol 29:27 – 33
18. Katayama H, Heneine N, van Gessel R, Taroni P, Spinazzi A (2001) Clinical experience with iomeprol in myelography and myelo-CT: clinical pharmacology and double-blind comparisons with iopamidol, iohexol, and iotrolan. Invest Radiol 36:22 – 32
19. Katzberg RW, Benedetti PF, Drake CM, Ivanovic M, Levine RA, Beatty CS, Nemzek WR, McFall RA, Ontell FK, Bishop DM, Poirier VC, Chong BW (1999) Acute cervical spine injuries: prospective MR imaging assessment at a level 1 trauma center. Radiology 213:203 – 12
20. Kirvela O, Svedstrom E, Lundbom N (1992) Ultrasonic guidance of lumbar sympathetic and celiac plexus block: a new technique. Reg Anesth 17:43 – 6
21. Ludwig H, Fruhwald F, Tscholakoff D, Rasoul S, Neuhold A, Fritz E (1987) Magnetic resonance imaging of the spine in multiple myeloma. Lancet 2:364 – 6
22. Masaryk TJ, Ross JS, Modic MT, Boumphrey F, Bohlman H, Wilber G (1988) High-resolution MR imaging of sequestered lumbar intervertebral disks. AJR Am J Roentgenol 150:1155 – 62
23. Modic MT, Steinberg PM, Ross JS, Masaryk TJ, Carter JR (1988) Degenerative disk disease: assessment of changes in vertebral body marrow with MR imaging. Radiology 166:193 – 9
24. Mullin WJ, Heithoff KB, Gilbert TJ, Jr., Renfrew DL (2000) Magnetic resonance evaluation of recurrent disc herniation: is gadolinium necessary? Spine 25:1493 – 9
25. Parizel PM, Baleriaux D, Rodesch G, Segebarth C, Lalmand B, Christophe C, Lemort M, Haesendonck P, Niendorf HP, Flament-Durand J, et al. (1989) Gd-DTPA-enhanced MR imaging of spinal tumors. AJR Am J Roentgenol 152:1087 – 96
26. Peh WC, Chan JH (2001) Artifacts in musculoskeletal magnetic resonance imaging: identification and correction. Skeletal Radiol 30:179 – 91
27. Pfirrmann CW, Binkert CA, Zanetti M, Boos N, Hodler J (2000) Functional MR imaging of the craniocervical junction. Correlation with alar ligaments and occipito-atlantoaxial joint morphology: a study in 50 asymptomatic subjects. Schweiz Med Wochenschr 130:645 – 51
28. Pfirrmann CW, Binkert CA, Zanetti M, Boos N, Hodler J (2001) MR morphology of alar ligaments and occipitoatlantoaxial joints: study in 50 asymptomatic subjects. Radiology 218:133 – 7
29. Pfirrmann CW, Dora C, Schmid MR, Zanetti M, Hodler J, Boos N (2004) MR image-based grading of lumbar nerve root compromise due to disk herniation: reliability study with surgical correlation. Radiology 230:583 – 8
30. Pfirrmann CW, Metzdorf A, Zanetti M, Hodler J, Boos N (2001) Magnetic resonance classification of lumbar intervertebral disc degeneration. Spine 26:1873 – 8
31. Post MJ, Sze G, Quencer RM, Eismont FJ, Green BA, Gahbauer H (1990) Gadolinium-enhanced MR in spinal infection. J Comput Assist Tomogr 14:721 – 9
32. Roos JE, Hilfiker P, Platz A, Desbiolles L, Boehm T, Marincek B, Weishaupt D (2004) MDCT in emergency radiology: is a standardized chest or abdominal protocol sufficient for evaluation of thoracic and lumbar spine trauma? AJR Am J Roentgenol 183:959 – 68
33. Rudisch A, Kremser C, Peer S, Kathrein A, Judmaier W, Daniaux H (1998) Metallic artifacts in magnetic resonance imaging of patients with spinal fusion. A comparison of implant materials and imaging sequences. Spine 23:692 – 9
34. Sapir DA, Gorup JM (2001) Radiofrequency medial branch neurotomy in litigant and nonlitigant patients with cervical whiplash: a prospective study. Spine 26:E268 – 73
35. Saupe N, Prussmann KP, Luechinger R, Bosiger P, Marincek B, Weishaupt D (2005) MR imaging of the wrist: comparison between 1.5- and 3-T MR imaging – preliminary experience. Radiology 234:256 – 64
36. Schmid MR, Stucki G, Duewell S, Wildermuth S, Romanowski B, Hodler J (1999) Changes in cross-sectional measurements of the spinal canal and intervertebral foramina as a function of body position: in vivo studies on an open-configuration MR system. AJR Am J Roentgenol 172:1095 – 102
37. Spitzer WO, Skovron ML, Salmi LR, Cassidy JD, Duranceau J, Suissa S, Zeiss E (1995) Scientific monograph of the Quebec Task Force on Whiplash-Associated Disorders: redefining "whiplash" and its management. Spine 20:1S–73S
38. Spring DB, Bettmann MA, Barkan HE (1997) Nonfatal adverse reactions to iodinated contrast media: spontaneous reporting to the U.S. Food and Drug Administration, 1978 – 1994. Radiology 204:325 – 32

39. Stadnik TW, Lee RR, Coen HL, Neirynck EC, Buisseret TS, Osteaux MJ (1998) Annular tears and disk herniation: prevalence and contrast enhancement on MR images in the absence of low back pain or sciatica. Radiology 206:49 – 55
40. Stumpe KD, Zanetti M, Weishaupt D, Hodler J, Boos N, Von Schulthess GK (2002) FDG positron emission tomography for differentiation of degenerative and infectious endplate abnormalities in the lumbar spine detected on MR imaging. AJR Am J Roentgenol 179: 1151 – 7
41. Subramanian G, McAfee JG, Bell EG, Blair RJ, O'Mara RE, Ralston PH (1972) 99m Tc-labeled polyphosphate as a skeletal imaging agent. Radiology 102:701 – 4
42. Teeuwisse WM, Geleijns J, Broerse JJ, Obermann WR, van Persijn van Meerten EL (2001) Patient and staff dose during CT guided biopsy, drainage and coagulation. Br J Radiol 74:720 – 6
43. Trueb P (2001) Kompendium für aerztliche Strahlenschutz-Sachverstaendige. Verlag Paul Haupt, Berne
44. Turner CH, Peacock M, Timmerman L, Neal JM, Johnson CC, Jr. (1995) Calcaneal ultrasonic measurements discriminate hip fracture independently of bone mass. Osteoporos Int 5:130 – 5
45. Veras LM, Pedraza-Gutierrez S, Castellanos J, Capellades J, Casamitjana J, Rovira-Canellas A (2000) Vertebral artery occlusion after acute cervical spine trauma. Spine 25:1171 – 7
46. Vock P, Valley J (2004) Medizinische Strahlenexposition in der Schweiz. Teil 1: Frequenzen, Dosen, Konsequenzen. Schweiz Med Forum 4:845 – 50
47. Wehrli FW, Hilaire L, Fernandez-Seara M, Gomberg BR, Song HK, Zemel B, Loh L, Snyder PJ (2002) Quantitative magnetic resonance imaging in the calcaneus and femur of women with varying degrees of osteopenia and vertebral deformity status. J Bone Miner Res 17:2265 – 73
48. Weishaupt D, Schmid MR, Zanetti M, Boos N, Romanowski B, Kissling RO, Dvorak J, Hodler J (2000) Positional MR imaging of the lumbar spine: does it demonstrate nerve root compromise not visible at conventional MR imaging? Radiology 215:247 – 53
49. Weishaupt D, Zanetti M, Boos N, Hodler J (1999) MR imaging and CT in osteoarthritis of the lumbar facet joints. Skeletal Radiol 28:215 – 9
50. Wildermuth S, Zanetti M, Duewell S, Schmid MR, Romanowski B, Benini A, Boni T, Hodler J (1998) Lumbar spine: quantitative and qualitative assessment of positional (upright flexion and extension) MR imaging and myelography. Radiology 207:391 – 8
51. Williams RL, Hardman JA, Lyons K (1998) MR imaging of suspected acute spinal instability. Injury 29:109 – 13
52. Zhou XJ, Leeds NE, McKinnon GC, Kumar AJ (2002) Characterization of benign and metastatic vertebral compression fractures with quantitative diffusion MR imaging. AJNR Am J Neuroradiol 23:165 – 70

# 10 Spinal Injections

Massimo Leonardi, Christian W. Pfirrmann

## Core Messages

- ✔ Morphological alterations in imaging studies of the spine are very common and it is difficult to differentiate symptomatic and asymptomatic alterations
- ✔ Spinal injections are used for diagnostic management of spinal pain to determine which morphological alteration could be a source of pain
- ✔ Spinal injection techniques are used for treatment of various spinal disorders as an adjunct to non-operative care
- ✔ Discography may be helpful in distinguishing asymptomatic from symptomatic disc degeneration (discogenic pain)
- ✔ Facet joint blocks are used as a diagnostic tool to differentiate symptomatic from asymptomatic facet joint alterations and as a therapeutic means to eliminate pain presumably arising from the facet joints (facet syndrome)
- ✔ Cervical and lumbar nerve root blocks as a diagnostic tool are helpful to verify the site and cause of the radiculopathy
- ✔ Cervical and lumbar nerve root blocks as a therapeutic tool are an effective treatment for the management of painful radiculopathy
- ✔ In cases of multilevel involvement or non-specific leg pain, epidural blocks may be used for pain alleviation
- ✔ Sacroiliac joint infiltration represents a diagnostic means to identify this joint as a source of buttock pain

## Rationale for Spinal Injections

Local spinal pain and radiculopathy are very common conditions which affect most of the population worldwide at some time in their lives. The lifetime prevalence ranges from 60 % to 90 % [26]. An initial treatment program consists of rest, oral medication with analgetic-anti-inflammatory agents, and physical therapy. But, in 10 – 20 % of these patients pain persists or recurs and quality of life is impaired, requiring further treatment. At this point evaluation for an anatomical etiology of pain is considered; the imaging studies of choice are usually plain radiographs and MRI.

Morphological alterations are common findings in asymptomatic individuals

The results of these tests must be correlated to the clinical investigation, because there is a **high prevalence of morphological alterations** in the spine in **asymptomatic individuals**, indicating that the correlation between pain and structural abnormality is weak [12].

There are only a few structural abnormalities which do not often occur in asymptomatic individuals [128], i.e.:

- nerve root compression
- large disc extrusion and sequestration
- moderate to severe facet joint alterations
- moderate to severe endplate changes

The diagnostic accuracy of imaging studies is limited in neck and back pain

However, the vast majority of patients with back and neck pain present with no or only minor structural alterations (e.g. disc protrusion, minor nerve root compression and mild facet joint osteoarthritis). The same alterations can be found with high prevalence in an asymptomatic population [5, 6, 12, 56]. The predictive value of MRI in diagnosing symptomatic disc alterations is therefore limited [12]. Spinal injection studies have been advocated to differentiate a symptomatic from an asymptomatic lesion because of the low positive predictive value of imaging studies [56, 74, 110].

The **rationale for spinal injections** is therefore either to:

- provoke spinal pain or
- eliminate spinal pain

The rationale of injection studies is to eliminate or provoke the patient's pain

which is presumably related to the target spinal structure. A large number of studies have accumulated in the literature which describe application, techniques and potential benefits. However, the lack of a clear understanding of the pain pathogenesis and therefore a missing gold standard makes it difficult to decide on the diagnostic impact of these injections [11, 96].

Injection studies can have a therapeutic effect

The frequent use of spinal injections as a **diagnostic tool** has indicated that these injections may also have a therapeutic value. The second rationale is to use spinal injections to **support non-operative treatment** in patients suffering from nerve root compromise, spinal stenosis, or facet joint osteoarthritis. However, debate continues whether the rationale for the use of spinal injections is evidence based [80, 119, 124]. Despite the widespread use of these spinal injections, their application is widely based on anecdotal experience and at best is evidence enhanced but definitely is not evidence based.

## Lumbar and Cervical Nerve Root Blocks

**Selective nerve root blocks** (SNRBs) were first described by Macnab [67] and coworkers in 1971 as a diagnostic test for the evaluation of patients with negative imaging studies and clinical findings of nerve root irritation.

Radiculopathy is caused by a combination of mechanical compression and inflammation

The high prevalence of asymptomatic disc herniations [6, 12, 13, 56] is often a prompt for a verification of the morphological correlate for equivocal radicular pain. **Pain pathogenesis** in cases with nerve root compromise is caused not only by a mechanical compression but also by a chemical irritation due to proinflammatory cytokines [17, 18, 83–85]. The rationale for nerve root blocks is therefore to tackle the **inflammatory component** of the nerve root compromise [83–85]. The peri-radicular foraminal nerve root block is always performed under image intensifier control, allowing for a direct application of the anti-inflammatory agent to the target nerve root [87]. The objective of a therapeutic selective nerve root block is not to cure the patient by interfering with pathogenetic factors that are responsible for sciatica but rather to provide temporary relief from peak pain during the time required for spontaneous resolution of radiculopathy.

Nerve root blocks tackle the inflammatory component of radiculopathy

### Indications

Indications for selective nerve root blocks are applied for a diagnostic as well as a therapeutic purpose (Table 1).

**Table 1.** Indications for selective nerve root blocks

**Diagnostic indications**
- equivocal radicular leg or arm pain
- discrepancy between the morphological alterations and the patient's symptoms
- multiple nerve root involvement
- abnormalities related to a failed back surgery syndrome

**Therapeutic indications**
- acute radicular leg or arm pain in the absence of major neurological deficits
- subacute radiculopathy not responsive to non-operative care
- mild to moderate foraminal stenosis

## Technique

Perineural infiltrations are performed at the foraminal exit

It must be stressed that injections into the nerve root must be avoided because of the potential risk of permanent nerve root damage. The injection which is recommended is a perineural infiltration. The treatment agent used for this procedure varies between studies. Most authors use a mixture of 2 ml 0.25 % bupivacaine and 40 mg methylprednisolone [57, 81, 91]. Others have used 1.5 ml 2 % lidocaine with 9 mg betamethasone acetate [65]. There is no study to suggest which is best in terms of treatment outcome. We report here the techniques which work best in our hands.

### Lumbar Nerve Root Blocks

Lumbar nerve root blocks are done under fluoroscopy control

The standard technique is an **outpatient procedure** without premedication which can be done either in a radiology suite or an operating theater. The patients lie prone, with the injected side elevated approximately at a 30° angle. The final degree of rotation is determined with **fluoroscopy**. The goal of positioning is to allow for a perpendicular needle tract towards the classic injection site underneath the pedicle. The so-called **safe triangle** is defined by the pedicle superiorly, the lateral border of the vertebral body laterally, and the outer margin of the spinal nerve medially (Fig. 1). After skin disinfection, a local anesthetic is administered using a 25-gauge needle. With fluoroscopic guidance, a 22-gauge needle is then advanced through a shorter 18-gauge needle to the region of the safe triangle. For accessing the L5 and S1 nerve root the standardized technique is adapted slightly. For the L5 root, the needle usually has to be tilted in a craniocaudal direction in order to bypass the iliac wing. The **S1 infiltration** is performed through the dorsal S1 foramen. The needle position is checked with biplanar fluoroscopy, followed by an injection of 0.3 ml of contrast material. Anteroposterior spot radiographs are obtained for the documentation of the contrast material distribution. Two milliliters of 0.2 % ropivacaine and 40 mg of triamcinolone are slowly injected.

Pain and neurology must be assessed prior to and after the block

After the procedure, the subjective perception of **numbness** in the dermatome is regarded as a quality control for a correct injection and should be noted. Sometimes **muscle weakness** occurs in accordance with the innervation pattern. **Pain relief** should be assessed prior to and 15 – 30 min after the injection using a visual analogue scale.

### Cervical Nerve Root Blocks

Cervical nerve root blocks should be done under CT fluoroscopic guidance

We recommend performing cervical foraminal injections with CT fluoroscopic guidance to improve safety (Fig. 2). Misplacement of the needle can have deleterious consequences. The patient lies supine, with the head turned to the contralateral side. After skin disinfection and administration of local anesthetics, a

**Figure 1. Lumbar nerve root block**

The needle is positioned in the so-called "safe triangle" directly underneath the pedicle but superior and lateral to the existing nerve root. The image shows correct needle placement and an indirect radiculography.

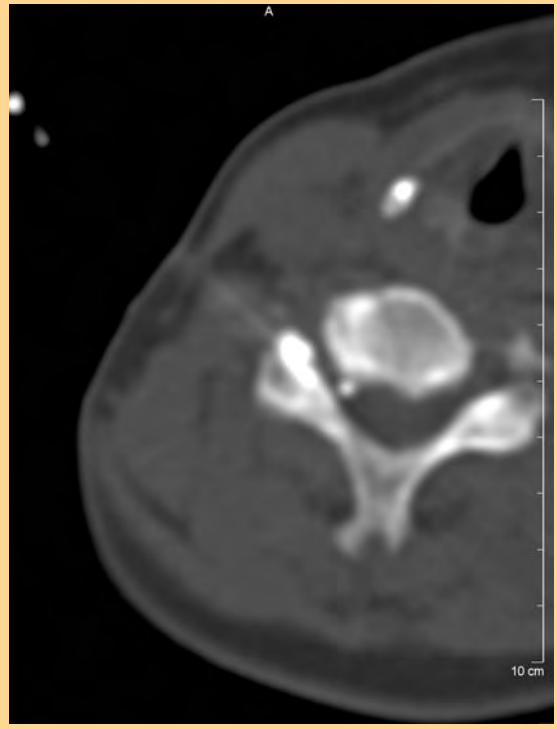


**Figure 2. Cervical nerve root block**

CT guidance for cervical facet nerve root blocks is preferred because of the spatial relationships to the spinal cord to avoid neurological damage. The image shows a CT-guided nerve root block after application of contrast medium at the foramen intervertebrale C5/6.

22-gauge needle is introduced under fluoroscopic guidance by using a lateral or slightly anterolateral approach dorsal to the large cervical vessels. The needle is aimed at the posterior border of the neural foramen, dorsal to the vertebral artery. Initially, 0.3 ml of iopamidol is injected to verify the correct position of the needle tip. The intraforaminal distribution of the contrast material is documented with a single CT-fluoroscopic scan. A maximum of 40 mg of crystalloid corticosteroid suspension-triamcinolone plus 1 ml of 0.2 % ropivacaine is slowly injected. Pain relief should be assessed prior to and 15 – 30 min after the injection using a visual analogue scale.

## Complications

Complications associated with nerve root blocks are rare. However, the following **complications** have been reported [14, 52]:

Complications are rare after lumbar nerve root blocks

- transient non-positional headache (3.1 %)
- increased backache (2.4 %)
- increased leg pain (0.6 %)
- facial flushing (1.2 %)
- vasovagal reaction (0.3 %)
- hypertension (0.3 %)
- increased blood sugar (0.3 %)
- dural puncture

Houten et al. [51] presented three cases with persisting paraparesis and paraplegia which occurred immediately after administration of a **lumbar nerve root block**. In each instance, penetration of the dura was not thought to have occurred. The sudden onset of neurological deficit and the imaging changes pointed to a vascular causation. A devastating complication reported by Rozin et al. [95] described a case of a death associated with a C7 **cervical nerve root block** performed in a 44-year-old female. The patient died of massive cerebral edema secondary to the dissection of the left vertebral artery and subsequent thrombosis due to the perforation of that artery by a 25-gauge spinal needle. Brouwers et al. [15] described a case of a 48-year-old man who underwent diagnostic C6 nerve root blockade. Immediately following the uneventful procedure he developed an MRI-proven fatal cervical spinal cord infarction. The authors suggest that the infarction resulted from an impaired perfusion of the major feeding anterior radicular artery of the spinal cord.

Cervical nerve root blocks may result in spinal cord injury

## Diagnostic and Therapeutic Efficacy

Selective nerve root blocks are useful tools in the diagnosis of radicular pain in atypical presentation, especially when the clinical presentation does not correlate with imaging study. This can be the case when the root is compressed only under load. Diagnostic help is also provided in cases of multilevel disease. The therapeutic effect lies mainly in an **immediate pain reduction** (Table 2). If there is an inflammatory component, pain resolution will last for a few weeks and could be permanent because of the benign natural course of this disease.

Nerve root blocks allow for a rapid pain reduction

### Lumbar Nerve Root Blocks

Selective lumbar nerve root blocks were originally used with contrast agent and lidocaine and aimed to differentiate different sources of leg pain in an equivocal clinical situation [67]. Frequently, it is not possible to localize exactly the compromised nerve root either by clinical neurological examination or by imaging

**Table 2.** Therapeutic efficacy of nerve root injections

| Author/year | Study design | Technique | Patients | Indication | Follow-up | Outcome |
|---|---|---|---|---|---|---|
| Weiner et al. 1997 [126] | cohort prospective single blinded, uncontrolled | lumbar foraminal injection | 30 | lumbar radiculopathy | 3, 4 y | 78.5 % improved at 3, 4 y |
| Lutz et al. 1998 [65] | open study prospective blinded, uncontrolled | lumbar transforaminal | 69 | sciatica due to disc herniation | 80 w | 75 % positive outcome |
| Riew et al. 2000 [91] | prospective, randomized, double blind | nerve root injection bupivacaine with/without betamethasone | 28 vs 27 | lumbar radicular pain | 13 – 28 m | 20 improved vs 9, 8 vs 18 had operation (significant difference) |
| Kolsi et al. 2000 [60] | prospective, controlled double blind | transforaminal vs interspinous | 17 vs 13 | sciatica | 7 and 28 d | significant benefit in both, mean pain score fell from 70 to 26 vs 63 to 23, no differences |
| Pfirrmann et al. 2001 [86] | cohort, prospective | lumbar SNRB | 36 | sciatica | 2 w | pain relief in 86 % |
| Karppinen et al. 2001 [57] | randomized, double blind | lumbar periradicular steroid infiltration vs saline | 160 | unilateral sciatic pain for 1 – 6 months | 2 w, 3 and 6 m, 1 y | after 2 w significant benefit for leg pain, spinal mobility and patient satisfaction in steroid group, 65 % improvement in both groups late |
| Narozny et al. 2001 [79] | cohort, retrospective | lumbar, periradicular steroid + bupivacaine | 30 | monoradicular leg pain with unequivocal morphological correlate | immediate (1 – 4 d), 2 – 3 w, and mean 16 m | 87 % rapid pain regression, 60 % permanent pain resolution |
| Vad et al. 2002 [119] | prospective, randomized not blinded | transforaminal vs trigger points with saline | 25 vs 23 | lumbosacral radiculopathy due to HNP | 16 m | 84 % improvement (mean Roland Morris score, VAS, finger floor distance, patient satisfaction) in transforaminal vs 48 % in trigger points |
| Thomas et al. 2003 [117] | randomized, double blind | transforaminal vs interspinous epidural | 16 vs 15 | discal radicular pain | 6 and 30 d, 6 m | significantly better pain relief on Dallas pain scale in the transforaminal group at all end points |
| Ng et al. 2004 [81] | cohort, prospective | lumbar selective nerve root block | 55 LDH, 62 stenosis | unilateral radicular pain | 6 and 12 w | no statistical difference in VAS improvement 57 % vs 37 %, statistically better outcome in functional outcome for LDH |

Note: d = day, w = week, m = months

Postinjection pain relief is indicative of the involvement of the target nerve root

studies. This is particularly valid for multilevel nerve root compromise shown by MRI. Numerous studies [28, 36, 112, 122, 126, 132] have shown that nerve root blocks are helpful in cases where this close correlation is lacking. In the case of a positive response (i.e. resolution of leg pain), the nerve root block allows the diagnosis of the affected nerve root with a sensitivity of 100 % in cases with disc protrusions and with a positive predictive value of 75 – 95 % in cases of foraminal stenosis [28, 122]. Only a few controlled studies analyzing the therapeutic efficacy of selective nerve root blocks have been published (Table 2).

### Cervical Nerve Root Blocks

Similarly to the lumbar spine, cervical disc herniation or spondylosis can cause discogenic or foraminal osseous nerve root compression, resulting in cervical radiculopathy with or without neurological compromise. However, there are only a few studies regarding selective cervical nerve root blocks. In 60 patients with cervical radiculopathy, Strobel et al. [114] investigated whether magnetic resonance imaging findings can predict pain relief after CT-guided cervical root nerve block. The mean percentage of pain reduction (VAS) was 46 %. Patients with foraminal disc herniation, **foraminal nerve root compromise**, and no spinal canal stenosis appear to have the best pain relief after this procedure.

Patients with foraminal compromise appear to have the best outcome

Berger et al. [4] performed CT-guided foraminal injections and reported effective long term pain relief in 11 of 18 patients with cervical radiculopathy (61 %). In a retrospective study, Slipman et al. [107] investigated fluoroscopically guided cervical nerve root block in 20 patients with cervical spondylotic radicular pain. An overall good or excellent result was observed in 12 (60 %) patients. The authors concluded that there is a role for SNRB in the treatment of atraumatic cervical spondylotic radicular pain.

In a prospective cohort study presented by Vallee et al. [121], 30 patients with cervical radicular pain of more than 2 months duration due to foraminal stenosis were given transforaminal injection of steroids. After 3 months, 29 % of patients had complete pain resolution. They observed complete or more than 75 % pain relief in 53 % of patients at 6 months. After 12 months 20 % had complete pain relief.

## Epidural and Caudal Blocks

Treatment of cervical and lumbar pain syndromes via an epidural injection of corticosteroids was first described in 1952 [92]. Cervical epidural corticosteroid injection was first mentioned in 1972 by Winnie [133] but has not found widespread application, probably because of the fear of complications. The rationale for epidural injections is comparable to those for nerve root blocks and aims to diminish the inflammatory component of a neural compromise. Epidural injections include a variety of injection techniques such as caudal (sacral), interlaminar lumbar and cervicothoracic. In contrast to the selective nerve root blocks, epidural steroid injections have the **drawback** that the pharmacological agent has to diffuse to the site of inflammation and there is no guarantee that it does so.

Multisegmental neural compromise may be treated with epidural blocks

The spatial pharmacological effect is difficult to control

### Indications

In cases with multilevel involvement or non-specific leg pain the epidural route has some advantages compared to selective nerve root blocks (Table 3).

**Table 3.** Indications for epidural/caudal steroid injections

- multilevel nerve root compromise
- equivocal cases with abnormal radicular leg pain
- central spinal stenosis

## Technique

### Lumbar Blocks

Steroid injections are possible via the epidural as well as the sacral route

The preferred level is one level above the target level. Other authors favor the level which corresponds to the segment of origin of the patient's symptoms. One or two percent anesthetic agent is injected to anesthetize the needle track. Using an interlaminar approach, a 22- or 25-gauge spinal needle is advanced between the spinous processes of the target level. Aiming at the upper edge of the lower lamina, the needle is inserted into the posterior epidural space with or without fluoroscopic control depending on one's personal experience with this technique. The location is confirmed using a small amount of contrast material.

### Caudal Epidural Blocks

The correct needle position should be documented by contrast agent administration

Alternatively a caudal approach placing the needle into the sacral hiatus is used. This technique is relatively easy to perform. However, as the sacral epidural space must be filled before solutions can be delivered into the target region, large volumes are required. Furthermore, it has been shown that the sacral epidural space can be blocked in a considerable proportion of patients [33]. It is strongly recommended to use a small amount of contrast medium to ensure that the steroid is applied in the epidural space. Employing **contrast agents**, the specialist may document whether the drug has reached the potential pain generator. Patients are asked to rate their pain before and after the procedure on a visual analogue scale. However, the steroid injection may take several days to be effective. Therefore, the assessment of the pain level directly after the injection is unreasonable.

### Cervicothoracic Blocks

Do not inject anesthetic agents in cervical blocks

The patient is placed prone and the skin is draped in sterile fashion. The C-arm fluoroscopic axis is angled 10° to 15° off midline and caudal for this alignment. The entry point is 1–2 cm from the midline, slightly caudal to the interlaminar gap, normally at C7/T1 or C6/7. After local anesthesia of the skin a spinal needle (22 or 25 gauge) is advanced with cephalad angulation into the dorsal midline epidural space. After confirmation of the right position the steroid injection is performed. Anesthetic agent is not injected into the cervicothoracic space to avoid the risk of a high cervical anesthesia.

## Complications

Although complications are possible with any invasive procedure, reports on series of thousands of lumbosacral epidural steroid injections reveal that they are relatively safe. However, **serious complications** such as epidural abscess, arachnoiditis, epidural hematoma, cerebrospinal fluid fistula, paraparesis and death have been reported [14, 15, 30, 51, 131].

## Therapeutic Efficacy

The therapeutic effect is often only short term

Most reports in the literature are of uncontrolled, retrospective observational studies (Table 4). Despite major methodological flaws the average success rate of epidural injections is in the order of 70% [59]. The **efficacy of epidural steroid blocks** is **short term** and minor in comparison to selective infiltration due to lack of a determined target.

**Table 4.** Therapeutic efficacy of epidural injections

| Author/ year | Study design | Technique | Indication | Patients | Follow-up | Outcome |
|---|---|---|---|---|---|---|
| Beliveau 1971 [3] | controlled, randomized | epidural caudal procaine + steroid vs procaine | sciatica | 24 vs 24 | 1 w, 3 m | no significant improvement 18 vs 16 patients |
| Dilke et al. 1973 [35] | controlled, prospective randomized, double blind | lumbar translaminar saline + steroid vs saline alone | unilateral sciatica | 44 vs 38 | 3 m | significantly less pain in steroid group (40 improved vs 28) |
| Snoek et al. 1977 [111] | controlled, prospective randomized, double blind | lumbar translaminar steroid vs saline | sciatica due to nerve root compression | 27 vs 24 | 3 d | no difference LBP (33 vs 25 %), radicular pain (26 vs 13 %), sciatic nerve stretch (36 vs 25 %) |
| Yates 1978 [135] | randomized, double-blind, patient acted as his own control | steroid with/without lignocaine vs saline with/without lignocaine, each patient 4 injections | low back pain, sciatica | 150 injections, analysis of 49 injections in 20 consecutive patients | immediately, after 30 min | steroid groups better than without steroid in straight leg raising |
| Klenerman et al. 1985 [58] | controlled, prospective randomized, double blind | lumbar translaminar saline + steroid vs saline/bupivacaine | sciatica | 19 vs 16 | 2 m | benefit 15 vs 11 pts., no significant difference |
| Cuckler et al. 1985 [34] | controlled, prospective randomized, double blind | lumbar translaminar steroid + procaine vs saline + procaine | clinical and radiographic nerve root compression | 42 vs 31 | 1 d and 13 – 30 m | early improvement 42 % vs 44 %, no significant difference in both groups |
| Matthews et al. 1987 [71] | controlled, prospective randomized, double blind | epidural caudal steroid + bupivacaine vs lignocaine subcutaneous | sciatica | 23 vs 34 | 1, 3 m, 1 y | after 1 m no significant difference (67 vs 56 %), after 3 m steroid group significantly better |
| Ridley et al. 1988 [90] | controlled, prospective randomized, double blind | lumbar translaminar saline + steroid vs saline | low back pain + sciatica | 19 vs 16 | 2 w, 6 m | after 2 w significant pain relief in steroid group (90 % vs 19), late none |
| Glynn et al. 1988 [45] | randomized, double blind | epidural bupivacaine + morphine vs bupivacaine + clonidine | low back pain | 10 vs 10 | 3 h | no statistical difference |
| Rocco et al. 1989 [93] | randomized, double blind | epidural translaminar lignocaine + steroid vs lignocaine + steroid + morphine, vs lignocaine + morphine | low back pain | 8 vs 7 vs 7 | 1, 6 m | after 1 m mean VAS improvement 0.6 vs –0.6 vs 0.4, after 6 m improved 1 pt. vs 0 vs 0 |
| Bush et al. 1991 [19] | prospective randomized, double blind | caudal epidural steroid + procaine vs saline | lumbar nerve root compromise | 12 vs 11 | 4 w, 1 y | significant pain relief and better mobility after 4 w, at 1 y no benefit |
| Serrao et al. 1992 [105] | randomized, double blind | epidural interlaminar saline + steroid + dextrose vs saline + midazolam + dextrose | mechanical low back pain | 14 vs 14 | < 2 w, 2 m | early benefit 3 vs 10, after 2 m 5 vs 7, significantly less medication in control group |
| Carette et al. 1997 [20] | prospective randomized, double blind | lumbal translaminar | low back pain, radicular pain | 78 vs 80 | 6 w, 3 m | early benefit = better spinal mobility, less radicular pain, lower sensitivity dysfunction, at 3 m no difference |

**Table 4.** *(Cont.)*

| Author/ year | Study design | Technique | Indication | Patients | Follow-up | Outcome |
|---|---|---|---|---|---|---|
| Fukusaki et al. 1998 [43] | randomized, single blind | epidural translaminar saline vs anesthetic vs anesthetic + steroid | uni- or bilateral pseudoclaudication due to stenosis | 16 vs 18 vs 19 | 1 w, 1 m, 3 m | early benefit with anesthetic alone, steroids no effect |
| Buchner et al. 2000 [16] | prospective randomized, double blind | lumbar epidural methylprenisolone + bupivacaine vs nothing | sciatica due to LDH | 17 vs 19 | 2 w, 6 w, 6 m | after 2 w VAS, straight leg raising, functional status better in the steroid group, no difference after 6 w and 6 m |
| McGregor et al. 2001 [73] | prospective randomized | interlaminar vs caudal route | low back pain and leg pain | 19 vs 17 | 6 m | no benefit |
| Valat et al. 2003 [120] | randomized, double blind | translaminar epidural, steroid vs saline | sciatica | 42 vs 43 | 20 d, 35 d | after d 20: improvement 51 % vs 36 % (not significant), after d 35: 49 % vs 48 % success |

Note: d = day, w = week, m = months

### Lumbar Epidural Blocks

The therapeutic effect is not well based on scientific evidence

Koes et al. [59] reviewed 12 randomized clinical trials on the efficacy of **lumbar epidurally steroid injections** for low back pain and sciatica. Of the four methodologically better studies, two reported positive outcomes and two reported negative results. Overall, only six studies indicated that the epidural steroid injection was more effective than the reference treatment and six reported there was no better or worse efficacy than the reference treatment. The author concluded that the benefits of epidural steroid injections, if any, seem to be of short duration only [59]. Watts et al. [125] performed a meta-analysis of 11 placebo-controlled trials on the efficacy of epidural steroid injections in the treatment of sciatica. The methodological quality of the trials was considered generally to be good for the five studies that scored the maximum number of points. Improvement of at least 75 % or reduction in pain was considered to be a clinically useful response. Watts et al. [125] concluded that epidural steroid injections are effective in the management of patients with sciatica [125].

The controversy regarding the efficacy of **epidural steroid injections** is partly due to the methodological and technical flaws [59, 65]. According to Cluff et al. [32], there is no consensus as to the ideal method to perform epidural injection of steroids. No recommendations can be based on the literature in terms of the ideal dose and type of steroid [32].

### Cervical Epidural Blocks

The few clinical outcome studies for cervical epidural steroid injection showed similar success rates and exhibit similar methodological flaws to the publications that focused on lumbar regions [27, 29, 40, 69, 94]. Stojanovic et al. [113] analyzed the role of fluoroscopy in cervical epidural steroid injections. In 38 epidurograms of 31 patients the loss of resistance technique was found to be false positive in 53 %. They concluded that the **loss of resistance technique** may not be an adequate method for accurate needle placement in blindly performed cervical epidural injections. Rowlingson and Kirschenbaum found that patients with cervical radiculopathy who exhibited a dermatomal pattern of sensory loss were very likely to benefit [94]. In a study of 58 patients, Cicala et al. [31] reported 41 % excellent and 21 % good results after 6 months. In the absence of controlled ran-

The "loss of resistance" technique does not suffice for a correct needle placement

domized studies on cervical epidural steroid blocks, the value of this procedure remains undetermined.

## Provocative Discography

Provocative discography distinguishes symptomatic and asymptomatic disc degeneration

In the pre-MRI era, discography provided an excellent assessment of the intradiscal structure which was not possible with any other imaging modality at that time (Fig. 3). Discography has been used as the basis of the diagnosis of discogenic pain. Today, the role of discography lies not so much in an assessment of the disc structure but rather in the possibility of **provoking pain** which can be compared to the patients' symptoms. The mechanism of pain provocation during discography is largely unknown. It is hypothesized that pathological metabolites such as neuropeptides or cytokines are expelled from the disc during discography and cause nociception at the outer annular nerve fibers that are innervated, resulting in pain [17, 127]. So far, discography remains the only method to differentiate symptomatic and asymptomatic disc degeneration.

Discography remains controversial

However, debate continues on the diagnostic value of discography because of a lack of understanding of pain pathogenesis [22–24, 78, 123].

### Indications

In our service, patients are only selected for provocative discography if they are potential candidates for surgery, i.e. the diagnostic test will influence treatment strategy. Provocative discography is indicated to differentiate symptomatic from asymptomatic disc alterations and less frequently in cases with equivocal neural compression caused by a minor disc protrusion or in the presence of annular tears (Table 5).

**Figure 3. Provocative discography**

Image showing a "normal" disc at level L4/5 (Adams I) and severe disc degeneration with contrast medium in the spinal canal of L5/S1 (Adams V).

**Table 5.** Indications for provocative discography

| Differentiation of symptomatic and asymptomatic disc alterations |
|---|
| • Disc degeneration |
| • Annular tears (high intensity zones) |
| • Endplate changes (modic changes) |
| • Minor disc protrusions with questionable nerve root compromise |

## Technique

Inject an MRI normal disc as a negative control

Discography should be performed by a spine specialist or a dedicated radiologist with experience of the diagnostic assessment of spinal disorders. It is mandatory that the patient is awake during the procedure to allow for communication about the injection response. However, mild sedation is helpful during the procedure.

### Lumbar Discography

In lumbar discography the posterolateral approach is widely accepted as the technique of choice. A double needle technique (with a short 18-gauge external and an internal 22-gauge needle) is widely recommended [48, 116]. In patients with unilateral pain, the needle is introduced from the contralateral side to distinguish between iatrogenic and genuine pain. The needle position is verified under fluoroscopy in two planes. After accurate needle positioning, contrast medium containing an iodine concentration of 300 mg/ml is injected into each disc by using a 5-ml syringe. The amount of contrast agent injectable before leakage usually ranges from 0.8 ml to 3.0 ml before leakage [10]. Non-ionic contrast agent is injected with a 5-ml syringe until firm resistance to the injection is felt, until severe pain is provoked, or until contrast medium is seen to leak out of the disc into the spinal canal. During discography, the patient is asked to grade the pain provoked on a visual analogue scale. The type of pain should be graded according to the **Dallas Discogram Description** [97] as follows:

Pain provocation should be graded as concordant or non-concordant

- no sensation
- pressure
- dissimilar pain
- similar pain, or
- exact pain reproduction

Discogenic pain is based on the provocation of concordant pain

Pain sensation occurring during discography is defined as concordant if the patient had exact pain reproduction or felt similar pain. Accordingly, non-concordant pain is defined as pressure, dissimilar pain sensation, or no pain provocation. Evaluation of disc morphological characteristics is performed with conventional radiographs by using the classification of **Adams** et al. [1]. The classification includes five stages of disc degeneration distinguished by their morphological **appearance on discograms**:

- cotton ball (Type I)
- lobular type (Type II)
- irregular (Type III)
- fissured (Type IV)
- ruptured (Type V)

Types I and II are interpreted as non-degenerative discs and Types III–V as degenerative discs.

It has been very helpful to include an MRI normal disc as an internal control. In our practice, we only regard concordant pain predictive of discogenic pain when the injection of the control level does not provoke pain [129].

### Thoracic Discography

Thoracic discography is performed under **CT guidance** on an outpatient basis. The patient is placed in a prone position on the CT table. Following a scout film of the thoracic spine the level of interest is scanned with a section thickness of 3 mm. After choosing the target thoracic disc, the CT-table position is adjusted. The side opposite, if present, is chosen as the injection side, so as not to provoke patient pain while advancing the needle. Under CT guidance a 25-gauge needle is advanced into the target disc. After positioning of the needle in the center of the disc, contrast medium (iopamidol, 1.5 cc) is injected and a CT discogram scan performed. The patient is questioned about the pain provoked during injection as mentioned above.

Thoracic discography should only be done under CT guidance

### Cervical Discography

For this procedure, the patient lies supine with the neck in slight extension. The neck is draped in a sterile fashion. By using a 22-gauge needle, through an anteromedial approach (medial to the m. sternocleidomastoideus), the needle is advanced to the center of the disc under **biplanar fluoroscopic control**. The trachea and esophagus remain medially and the carotid artery is palpated and displaced laterally. The amount of contrast agent injected usually ranges from 0.3 ml to 1.0 ml. The pain response is assessed similarly to the lumbar procedure.

## Complications

Any needle technique carries with it the risk of infection, which appears to be most relevant in cases of cervical and lumbar discography. The reported rate for discitis after **lumbar discography** is in the order of magnitude of 0.25 % [130]. Further complications are reported such as retroperitoneal hemorrhage, allergic reaction, subarachnoidal bleeding, nerve root sheath injuries, or annular or endplate injections due to incorrect needle placement. Of 807 injected cervical discs, Grubb et al. [47] had a rate of discitis of 0.37 % corresponding to 1.7 % patients with discitis treated. In Zeidmann's [136] review of 4 400 diagnostic cervical discography cases, discitis occurred in 7 cases (0.16 %).

The rate of post-discography discitis ranges between 0.16 % and 0.37 %

## Diagnostic Efficacy

In 1948 Lindblom [50] introduced discography as a morphological test to replace or add information to myelography. Today the role of discography is related to a pain provocation test. The assessment of the **diagnostic accuracy** of provocative discography for discogenic LBP is problematic since no gold standard is available. A reasonable practical approach is to include an adjacent normal disc level as internal control [129]. Thus, a positive pain response would include an exact pain reproduction at the target level and no pain provocation or only pressure at the normal disc level. However, careful interpretation of the findings is still mandatory with reference to the clinical presentation.

Diagnostic accuracy is difficult to determine because a gold standard is lacking

### Lumbar Discography

In a prospective, controlled study, Walsh et al. [123] studied ten asymptomatic volunteers and seven symptomatic patients with low back pain by lumbar discography. In the asymptomatic individuals, the injection produced minimum pain in 5 (17 %) of the 30 discs and in 3 moderate to bad pain. The false-positive rate

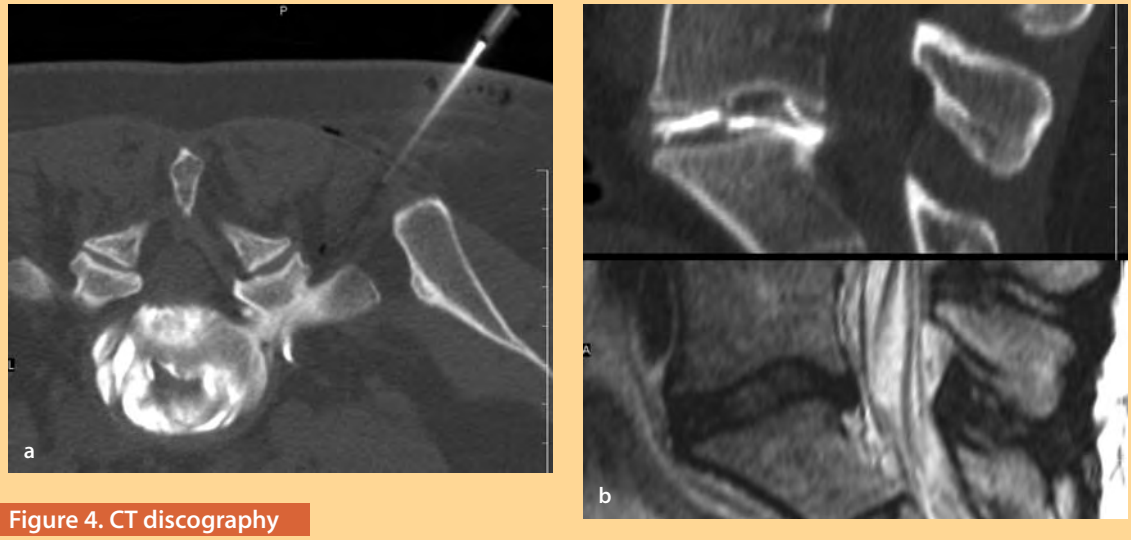


**Figure 4. CT discography**

Axial CT discogram showing contrast medium distribution within the intervertebral disc. **a** Sagittal view of CT/discogram showing contrast medium extension to the margin of the disc. **b** Corresponding MRI of the disc

The diagnostic value of discography remains a matter of debate

of 0 % and a specificity of 100 % led the authors to conclude that discography is a highly reliable and specific diagnostic test for the evaluation of low back pain disorders [123]. In 1999, Caragee et al. [24] reported on patients with no history of low back pain, who underwent posterior iliac crest bone graft. These patients often experienced concordant pain on lumbar discography. However, this study can be criticized because asymptomatic patients cannot perceive concordant discogenic pain. In 2000, Carragee repeated provocative discography in 26 older subjects without history of low back pain [23]. They concluded that the rate of false-positive discography may be low in subjects with normal psychological testing and without chronic pain. Furthermore, Caragee and colleagues [23] performed provocative discography in 20 asymptomatic patients who underwent single level discectomy for sciatica. Forty percent injections were positive in discs that had previous surgery.

Patients with low back pain who had lumbar fusion surgery based on positive discograms have been shown to have only moderate results. Complete pain relief was achieved only in a few cases. Successful clinical results ranged between 86.1 % and 46 %. This indicates that confounding factors other than morphological alterations may play a more important role in predicting surgical outcome (see Chapter 7).

CT discography (Fig. 4) represents a further step in the application of discography and evaluation of the structure of the disc. The debate as to whether CT/discography is superior to MRI because there is a theoretical advantage of CT/discography over MRI in demonstrating the internal architecture of the disc has not been conclusively answered. But, CT discography was found to have a higher accuracy than pain provocation and plain discography, 87 % vs 64 % vs 58 % respectively [54, 55].

### Thoracic Discography

Thoracic discography performed by experienced radiologists with CT guidance is quite safe with a very low rate of complications. Similar to lumbar discography,

it seems to be accurate in distinguishing painful symptomatic discs from asymptomatic discs. Wood et al. performed four-level thoracic discography in ten asymptomatic volunteers and compared the discograms with MRI studies. Three of the 40 discs were reported as intensely painful, all exhibiting prominent endplate infractions typical of Scheuermann's disease. Of the 40 discs studied, only 13 were judged to be normal morphologically on discography versus 20 on MRI. The remaining 27 discs were abnormal, exhibiting endplate irregularities, annular tears, and/or herniations. Wood et al. studied concomitantly thoracic discograms of ten adults with chronic thoracic pain. In this group 48 discs were analyzed, of which 24 were concordantly painful and 17 had non-concordant pain or pressure. On MRI, 21 of the 48 discs appeared normal, whereas on discography only 10 were judged as normal. The authors concluded that thoracic discography detects pathologies which may not be seen on MRI [134].

### Cervical Discography

Results of cervical discography must be interpreted carefully

Ohnmeiss et al. [82] studied 269 discs in patients with neck, shoulder and arm pain by cervical discography. Comparing the pain responses during disc injection with radiological images, they found positive pain provocation in 234 radiographically abnormal discs (77.8 %). They pointed out that it is important not just to assess pain intensity but to interpret the provoked pain in terms of its similarity to clinical symptoms. Grubb et al. [47] reviewed their 12-year experience with 807 injected cervical discs and found a 50 % concordant pain response rate. They concluded that cervical discography provokes concordant pain in multiple discs and conclusions about which disc should be treated must be drawn cautiously.

So far, provocative discography appears to be the only diagnostic test available to differentiate symptomatic and asymptomatic disc degeneration allowing for a direct relation of a radiological image to the patient's pain [49, 129].

## Facet Joint Blocks

Neck pain and low back pain may be caused by osteoarthritis of the facet joints

Since the first report by Ghormley [44], facet joints have been recognized as a predominant source of back pain. Their prevalence as a cause of low back pain has been reported to vary greatly and to range from 7.7 % to 75 % depending on the diagnostic criteria [21, 37, 53, 75–77, 99–104, 106]. Mooney and Robertson [75] demonstrated that low back pain and referred pain could be provoked by injection of hypertonic saline into the facet joints. Many authors today believe that the diagnosis of a facet joint syndrome can be based on pain relief by an intra-articular facet joint injection of an anesthetic or pain provocation by hypertonic saline injection [25, 64, 70, 76].

Today, facet joint blocks are used as a diagnostic and/or therapeutic means to eliminate pain presumably arising from the facet joints.

### Indications

Similarly to disc degeneration, a differentiation of a symptomatic and asymptomatic facet joint osteoarthritis based on imaging studies alone is not possible. Therefore, facet joint blocks alleviating the patient's symptoms presumably resulting from alteration of the facet joints are the only modality to differentiate symptomatic from asymptomatic states (Table 6).

**Table 6.** Indications for facet joint blocks

- differentiating symptomatic from asymptomatic facet joint alterations
- short- to medium-term relief of back pain in patients with previous positive diagnostic blocks

## Technique

### Lumbar Facet Joint Blocks

The blocks are performed under **fluoroscopic guidance** with the patient lying prone. In order to visualize the lumbar joints either the patient is rotated and supported in an oblique prone position or the X-ray beam is tilted accordingly. The angulation is usually between 30° and 40°. After disinfection the skin over the target joint is anesthetized with 2–3 ml of lidocaine. A spinal needle (22 gauge) is then inserted in a lateromedial direction (parallel to the X-ray beam) towards the joint. In obese patients, a double-needle technique is employed where a 22-gauge needle is passed through a shorter 18-gauge needle. Depending on the specific situation, either the mid point or rather the cranial or caudal part of the joint is targeted. A minimal quantity of contrast medium (<0.3 ml) is then injected under fluoroscopy to confirm the correct needle position (Fig. 5). If an intra-articular application is not possible, a periarticular injection is performed. **Needle placement** and **contrast distribution** are documented by standard radiographs. Subsequently, 1.0 ml of a mixture of local anesthetics (Carbostesin or bupivacaine and steroids, e.g. 40 mg triamcinolone) is injected. The patients are kept under surveillance for at least 15 min. All patients should be asked to assess the amount of pain prior to and 15–30 min after the injection using a visual analogue scale. Further follow-up information on the course of pain relief is helpful in interpreting the results.

Correct needle placement should be documented by contrast agent injections

### Spondylolysis Block

A special type of lumbar facet joint block is injection into the spondylolysis. This can be accomplished by injecting the facet joint located superior to the spondylolysis using the same technique as outlined above. Since the **facet capsule is often connected to the spondylolysis zone**, a filling can be observed which can extend to the inferior facet joint (Fig. 6).

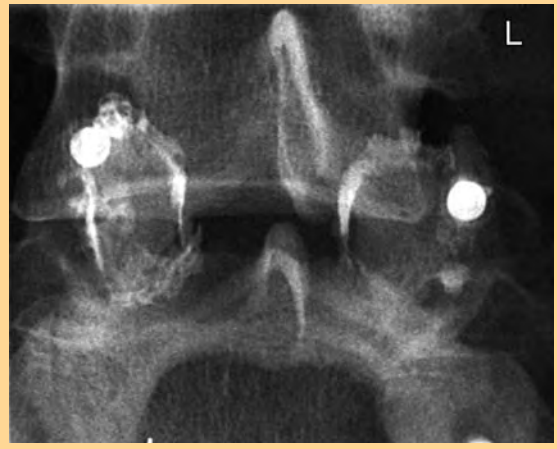


**Figure 5. Lumbar facet joint infiltration**

Fluoroscopically guided lumbar facet infiltration documenting the right position of the needles with correct arthrography of the joint.

**Figure 6. Spondylolysis block**

A correct spondylosis block is performed by injecting the facet joints at the level of L4/5. Contrast medium is extending through the lysis into the facet joint L5/S1.

### Cervical Facet Joint Blocks

We prefer the posterior approach for the cervical facet joints C3/4 to C6/7. The entry point lies two segments below the target joint. The patient is positioned prone on the fluoroscopic table. A spinal needle (22 gauge) is passed through the posterior neck muscles until it strikes the back of the target joint. For safety reasons, the **CT guided fluoroscopy** can be used (Fig. 7). The accurate placement of the needle is confirmed by injection of 1 ml of contrast medium. Thereafter, the steroid and anesthetic agent can be injected. Similarly to the lumbar spine, pain relief is recorded prior to and 15–30 min after the injection using a visual analogue scale.

CT guided cervical facet blocks are relatively safe

## Complications

Although complications are possible with any invasive procedure, reports on series of thousands of facet joint injections reveal that they are relatively safe [68]. Any needle technique carries with it the risk of infection, which appears to be of little relevance in cases of cervical and lumbar facet blocks. Complications are reported such as retroperitoneal hemorrhage, allergic reaction, and nerve root sheath injuries. There were some adverse effects like headache, nausea and paresthesiae, which are transient [70]. Obviously, side effects related to the pharmacology of the anesthetic agent and corticosteroids are possible.

Complications of facet joint blocks are rare

**Figure 7. CT-guided facet block**

CT guidance for cervical facet joint blocks is preferred because of the spatial relationships to the spinal cord to avoid neurological damage. Image showing correct needle placement at the level of C5/6. Note the correct arthrography on both sides.

## Diagnostic and Therapeutic Efficacy

### Lumbar Facet Joint Blocks

Facet joint blocks tackle symptomatic facet joint osteoarthritis

Some authors suggest that a facet joint syndrome can be diagnosed based on pain relief by an intra-articular anesthetic injection or provocation of the pain by hypertonic saline injection followed by subsequent pain relief after injection of anesthetics [25, 64, 70, 76]. Jackson et al. [53] investigated clinical predictors indicative of the injection response but had to conclude that there were no clear clinical findings. Similarly, Revel et al. [89] did not find any difference in the frequency of the 90 variables examined between the responder and non-responder groups. **Uncontrolled diagnostic facet joint blocks** are reported with a false-positive rate of 38 % and a positive predictive value of 31 % [100]. It therefore is mandatory to perform repetitive infiltrations to improve the diagnostic accuracy, e.g. with two different local anesthetics as suggested by Schwarzer et al. [100]. Dreyfuss [37] has concluded that there are no convincing pathognomonic, non-invasive radiographic, historical, or physical examination findings that allow one to definitively identify lumbar facet joints as a source of low back pain and referred lower extremity pain.

Facet joints are innervated polysegmentally making interpretation of the pain response difficult

According to a randomized double blind study by Marks et al. [70], intra-articular blocks are as effective as blocks of the medial branch of the dorsal ramus. One problem of interpreting the response to a facet joint block is related to the finding that facet joints are innervated by two to three segmental posterior branches, making a diagnosis of the affected joint difficult. The evaluation of the diagnostic accuracy of joint injections to diagnose a symptomatic facet joint is difficult in the absence of a true gold standard.

Even less information is available on the therapeutic efficacy of facet joint blocks in relieving pain attributed to facet joints [21]. Carette et al. [21] selected 110 out of 190 patients who experienced pain relief of more than 50 % after an intra-articular facet joint block with 2 ml lidocaine for a double blinded randomized control trial comparing methylprednisolone versus isotonic saline injection. They showed an immediate average pain reduction in the study group of 76 % vs 79 % in the placebo group. At 6 months follow-up, however, the patients in the study group reported a significantly higher pain relief (46 % vs 15 %).

**Table 7.** Therapeutic efficacy of facet joint blocks

| Author/year | Study design | Technique | Indication | Patients | Follow-up | Outcome |
|---|---|---|---|---|---|---|
| Carette et al. 1991 [21] | randomized double-blind | intra-articular lumbar facet block saline vs steroid | low back pain | 49 vs 48 | 1, 3 and 6 m | early benefit 42% vs 33%, after 6 months 46% vs 15% |
| Marks et al. 1992 [70] | randomized, double blind | facet joint vs facet nerve | lumbar or lumbosacral pain | 42 vs 44 | 1 and 3 m | no significant difference |
| Lilius et al. 1989 and 1990 [62, 63] | randomized, not blinded | (1) intracapsular steroid + bupivacaine, (2) pericapsular steroid + bupivacaine, (3) intracapsular saline | low back pain | 28 vs 39 vs 42 | 60 min, 3 m | 64% benefit in all groups, 36% at 3 months, no significant differences between groups |
| Lynch 1986 [66] | controlled, not randomized | 2 levels intra-/extracapsular vs extracapsular | low back pain | 50 vs 15 | 6 m | positive effect in all treated patients |
| Revel et al. 1998 [88] | randomized, double blind | intra-articular lidocaine vs saline | low back pain with 7 inclusion criteria | 43 vs 37 | 30 min | significantly greater pain relief in lidocaine group, 92% of responders to facet injection had 5 out of 7 facet criteria |
| Gorbach et al. 2005 [46] | cohort, prospective | intra-articular steroid + bupivacaine or mepivacaine | low back pain | 1 level: 29<br>2 levels: 13 | 15–30 min = immediate<br>>1 w = short term<br>>3 m = medium term | 74% immediate pos. effect (>50%) pain relief, 57% short term pos. effect, 33% medium term pos. effect |

Note: w = weeks, m = months

### Spondylolysis Block

There are no reports on the therapeutic value of pars infiltration. But, clinicians who use pars infiltration preoperatively for patient selection have described that patients with pain relief are more likely to be pain free after lumbar fusion. Patients without pain relief after pars infiltration could have other sources of pain. Suh et al. reported that patients selected with positive pars infiltration were more likely to have pain relief, to be functional, and to return to work [115].

### Cervical Facet Joint Block

So far, the accuracy and reliability of cervical facet blocks has not been demonstrated.

The result of facet joint blocks is difficult to predict

Few data also exist about the therapeutic efficacy of therapeutic cervical facet joint injections. One observational study found no benefit of cervical intracapsular steroid injections in patients with chronic pain after whiplash injury [2].

## Sacroiliac Joint Blocks

The sacroiliac joints are helpful in the diagnosis of a symptomatic sacroiliac joint

Alterations of the sacroiliac (SI) joints remain a **diagnostic and therapeutic obstacle**. Every joint can cause pain; therefore it is highly likely that pain can also result from the SI joint [98]. Pain from the SI joint has been referred to the region medial to the posterior superior iliac spine called the sacral sulcus. The pain can also radiate into the groin, abdomen and thigh, which makes it difficult to distinguish SI joint pain from disc disease or facet arthropathy [41, 42]. The clinical diagnosis is difficult to make since none of the clinical signs and tests has proven to be predictive. Imaging is not very helpful in diagnosing painful SI joint arthropathy in patients without inflammatory sacroiliitis [118]. A diagnostic anesthetic block of the sacroiliac joint is a possibility for identifying this structure as a relevant source of pain [96]. Slipman et al. [109] suggested that the painful sacroiliac joint is caused by a mild synovial irritation, which is not detectable on imaging. Other researchers assume that there is a chemical irritation of the nerves innervating the joint by mediators from the joint fluid [41].

Therefore, the rationale for SI joint blocks is to support the clinical diagnosis of an SI joint pathology.

### Indications

Indications for sacroiliac joint blocks include the **diagnostic work-up** for patients with low back and buttock pain radiating into the posterior thigh. **Therapeutic infiltrations** have not been reported to be of long-lasting success and are therefore not very helpful.

### Technique

This joint is for most of its extent inaccessible to needles due to the rough corrugated interosseous surfaces of the sacrum and the ileum. However, Bogduk et al. [7] have described puncturing the joint from its inferior end where the joint appears below the interosseous ligament and reaches the dorsal surface of the sacrum deep to the gluteus muscles. The accurate method of sacroiliac joint injection usually requires fluoroscopy or computed tomographic control [38, 39, 50, 108].

CT fluoroscopy facilitates correct needle placement

We describe here the technique which has been helpful in our service. With the patient lying prone the entry point of the joint lies at the lower end of the joint and is identified with fluoroscopic aid. **CT guidance** is necessary in patients with a complex orientation of the sacroiliac joint (Fig. 8). In some patients even the intra-articular access can be impossible, also due to fusion of the joint. After sterile skin preparation and draping, a 25-gauge needle (22 gauge) is introduced through the skin directed to the posterolateral aspect of the sacrum and then readjusted to enter the slit of the joint above the inferior edge. Once the needle is in position, contrast medium is injected to confirm the correct position. Subsequently steroids and anesthetic agents can be injected for diagnostic and therapeutic purposes.

### Complications

Complications due to **sacroiliac joint injections** are rare. Extravasation of anesthetic agent around the sciatic nerve can cause temporary numbness in up to 5 % of patients. If the needle is advanced too inferiorly, contact with the sciatic nerve is possible [118].

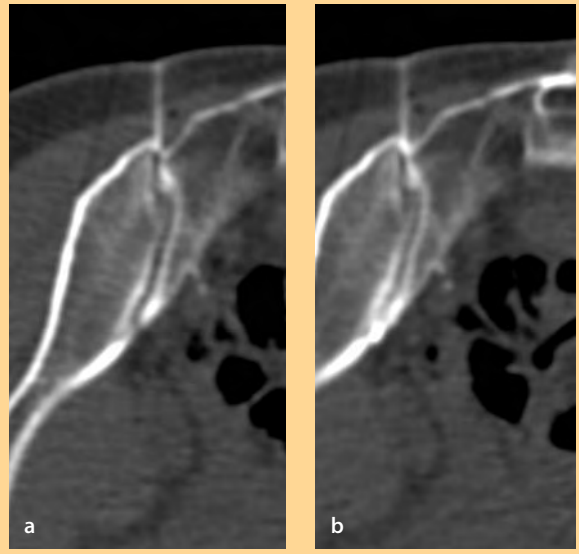


**Figure 8. Sacroiliac joint block**

Images showing correct needle placement (a) and arthrography of the sacroiliac joint (b).

## Diagnostic Efficacy

Sacroiliac joint infiltration allows for the diagnosis of a painful joint

Literature on sacroiliac joint injections and their impact on diagnosis and impact is sparse [98]. No prospective or controlled evaluation of the technique has been published. A few retrospective studies exist on the efficacy of sacroiliac joint injections.

In the report by Maugurs et al. [72], 86 % of patients had good pain relief after sacroiliac joint injection after 1 month, which decreased to 58 % after 6 months. In the study by Bollow et al. [8], 92 % of the 66 investigated patients had pain relief. In Fortin's study, 88 % of 16 patients with non-inflammatory sacroiliac joint syndrome had a decrease in pain after injection of anesthetic agent [41]. Slipman et al. [108] selected 31 patients with pain in the sacral sulcus, positive stress test and relief of pain after a first sacroiliac injection with anesthetic agent. After a second injection with an additional steroid mixture the patients had a significant decrease in pain scores and improved functional status after a follow-up of 94 weeks.

Today low back pain from the sacroiliac joint is best diagnosed when there is relief of pain after injection of anesthetic agent. There is no gold standard for verifying the presence of sacroiliac joint pain to which the results of sacroiliac diagnostic block can be compared. Thus, there are no reliable data on the sensitivity and specificity of this test [96].

## Contraindications for Spinal Injections

There are few contraindications for spinal injections, which must be considered before performing an infiltration. Alteration of the normal anatomy, e.g. pronounced degenerative abnormalities, or after major surgery to the spinal canal, where the positioning of the needle could be technically impossible, is per se not a contraindication.

However, it is apparent that such injections can only be performed in patients with normal hemostasis and without known allergic reactions. History taking on potential allergic reactions is mandatory and laboratory screening strongly rec-

ommended prior to the injections. Injections should not be performed in patients with:

- bleeding diathesis
- full anticoagulation, whereas medication with acetylsalicylic acid does not represent a contraindication
- infections or immunodeficiency syndromes
- allergic reaction to anesthetic agents or steroids

## Algorithm for Spinal Injections

The clinical investigation and patient history is of the utmost importance and should allow the clinician to differentiate between a local pain syndrome (neck pain, lumbar pain, dorsal pain, sacroiliac syndrome) and radicular pain, neurogenic claudication, segmental instability and discogenic pain. Despite the dilemma of unproven diagnostic and therapeutic efficacy of spinal injections [61], a practical approach appears to be justifiable until more conclusive data is provided in the literature. We therefore want to summarize an evidence-enhanced approach as currently used in our center. However, we want to stress that this approach is subjective and predominately anecdotal but appears to work in our hands (Fig. 9).

The evidence for the diagnostic value of injection studies remains controversial

Persistence (for more than 3 months) of non-radicular local pain which is not alleviated by conservative therapy should be investigated with radiographs and MRI. For radicular pain without or with minor neurological deficit these tests should be done after 3 weeks. Every pain syndrome with major neurological deficit and in cases which are suspicious for tumor or infection of the spine requires

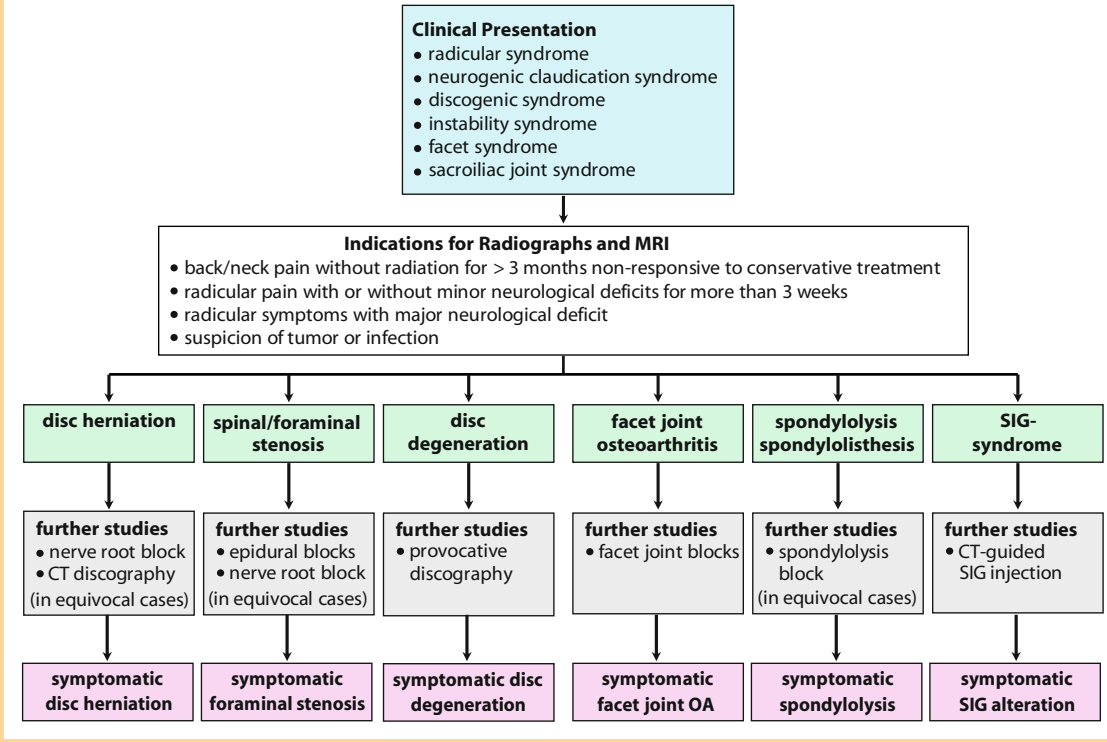


Figure 9. Algorithm for diagnostic spinal injection studies

immediate MRI investigation. If no clear correlation between clinical examination and radiological findings can be established, spinal injections are recommended.

In patients with disc herniation and unequivocal root compression, **selective nerve root block**s may support conservative treatment [86, 114]. In selected cases, nerve root blocks can substantially reduce the proportion of patients requiring a surgical intervention for the treatment of a radiculopathy often allowing for immediate pain relief [79, 91]. **Selective nerve root blocks** are helpful in cases with equivocal morphological findings to confirm the diagnosis. If the patient's pain is alleviated for the duration of the anesthetic effect, involvement of the target nerve root in the pain pathogenesis is very likely. Similarly, nerve root compression due to foraminal stenosis is an indication for nerve root block. Patients with spinal stenosis who are not candidates for surgery and have multisegmental alterations may benefit from **epidural blocks**. However, our anecdotal experience indicates that these injections are less effective than nerve root blocks.

We regard **discography** as the only means to differentiate symptomatic from asymptomatic disc degeneration since the morphological appearance can be identical [9, 12]. Our interpretation for a symptomatic disc degeneration is based on an exact pain provocation in the absence of pain provocation in an adjacent MR normal disc [129]. However, we only perform discography in patients who we would select for surgery in case of an exact pain provocation. In our center, we do not use discography for a pure diagnostic work-up.

Debate continues on the clinical significance of facet joint osteoarthritis as a source of back pain. So far, a definition of a facet syndrome has widely failed. Nevertheless, one-third of patients presenting with symptoms suggestive of a symptomatic facet joint arthropathy can benefit from a **facet joint block** for a short period of time (3–6 months) [46]. We recommend facet joint blocks in elderly patients who prefer non-surgical treatment as an adjunct therapy in the presence of moderate to severe facet joint osteoarthritis. However, we are ambivalent about the diagnostic accuracy of **facet joint and spondylolysis blocks** to support the indication for surgery or selection of fusion levels.

The diagnosis of SI joint alterations as a source of back pain remains unsatisfactory. We regard **SI joint blocks** as the only means to diagnose the involvement of the target joint. However, these injections are not very helpful in alleviating the patient's pain on a medium to long term.

## Recapitulation

**Rationale.** Although injection studies aim to **provoke or eliminate pain** and therefore focus on the source of the problem, there is as yet insufficient evidence to prove clinical efficacy as a diagnostic tool.

**Selective nerve root.** Selective nerve root blocks are used in cases with **equivocal radicular pain** and morphological findings to confirm the diagnosis. If the patient's pain is elevated for the duration of the anesthetic effect, involvement of the target nerve root in the pain pathogenesis is very likely. Selective nerve root blocks are also very helpful in supporting non-operative care in patients presenting with cervical and lumbar radiculopathy. In selected cases, nerve root blocks can substantially reduce the proportion of patients requiring a surgical intervention for the treatment of a radiculopathy often allowing for immediate pain relief.

**Epidural and caudal blocks.** Epidural and caudal application of steroids is used to treat **inflammation** due to compression of one or multiple nerve roots. Whereas low back pain, e.g. discogenic pain, seems not to be a good indication for epidural or caudal blocks, patients with neurogenic claudication may benefit from this injection. However, it seems that epidural blocks are **less effective than nerve root blocks**.

**Provocative discography.** Discography is the **only means** to differentiate symptomatic from asymptomatic disc degeneration since the morphological appearance can be identical. Interpretation for symptomatic disc degeneration is based on an exact pain provocation in the absence of pain provocation in an adjacent MR normal disc. However, discography should be performed in patients who we would **select for surgery** in the case of an exact pain provocation.

**Facet joint blocks.** Debate continues on the clinical significance of facet joint osteoarthritis as a source of back pain. While it would be unreasonable to assume that **facet joint osteoarthritis** is painless, the clinical presentation of facet joint alterations is variable. So far, a definition of facet syndrome has widely failed. However, the diagnostic accuracy of facet joint blocks to support the indication for surgery or selection of fusion levels should be interpreted with caution.

**Sacroiliac joint blocks.** The diagnosis of SI joint alterations as a source of back pain remains unsatisfactory. SI joint blocks are the only means to diagnose the affection of the target joint. However, these injections are not very helpful in alleviating the patient's pain on a medium to long term.

## Key Articles

**Revel M, Poiraudeau S, Auleley GR et al. (1998) Capacity of the clinical picture to characterize low back pain relieved by facet joint anesthesia: proposed criteria to identify patients with painful facet joints. Spine 23:1972–1976**
In this article patients with low back pain were prospectively randomized into two groups with and without clinical criteria predictive of facet joint osteoarthrosis. After facet joint blocks, greater pain relief was observed in the back pain group. The presence of age greater than 65 years and pain that was not exacerbated by coughing, not worsened by hyperextension, not worsened by forward flexion, not worsened when rising from flexion, not worsened by extension-rotation, and well relieved by recumbency distinguished 92 % of patients responding to lidocaine injection and 80 % of those not responding in the lidocaine group. The authors conclude that five clinical characteristics can be used to select lower back pain that will be well relieved by facet joint anesthesia.

**Carragee EJ, Alamin TF (2001) Discography: a review. The Spine Journal 1:364–372**
This paper describes the indication and technique of discography. Further, articles that are relevant to discography are systematically reviewed. Especially the interpretation of the results and conclusion are discussed. The authors state that the specificity of discography is dramatically affected by psychosocial characteristics of the patient. The ability of a patient to determine reliably the concordancy of pain provoked by discography is poor. The authors concluded that clinicians who use discography need to critically examine the validity of the test.

**Karppinen J, Malmivaara A, Kurunlahti M et al. (2001) Periradicular infiltration for sciatica: a randomized controlled trial. Spine 26:1059–1067**
In this randomized, double blind trial the efficacy of periradicular corticosteroid injection for sciatica was tested. One-hundred and sixty patients were randomized for double blind injection with methylprednisolone/bupivacaine combination or saline. Recovery rate was better in the steroid group at 2 weeks for leg pain, straight leg raising, lumbar flexion, and patient satisfaction. Back pain and leg pain were significantly lower in the saline group at 6 months. By 1 year, 18 patients in the steroid group and 15 in the saline group underwent surgery. The authors concluded that improvement was found in both groups and the combination of methylprednisolone and bupivacaine seems to have a short-term effect, but at 3 and 6 months the steroid group seems to experience a rebound phenomenon.

**Vad V, Bhat A, Lutz G, Cammisa F (2002) Transforaminal epidural steroid injections in lumbosacral radiculopathy: a prospective randomized study. Spine 27:11–15**
In this randomized study of 48 patients with radiculopathy secondary to a herniated nucleus pulposus, one group received a transforaminal steroid injection and the other saline trigger-point injection. After an average follow-up period of 1.4 years, the group

receiving transforaminal steroid injections had a success rate of 84 %, as compared with 48 % for the group receiving trigger-point injections.

**Slipman CW, Bhat AL, Gilchrist RV, et al. (2003) A critical review of the evidence for the use of zygapophysial injections and radiofrequency denervation in the treatment of low back pain. Spine J 3:310 – 316**
A database search of Medline, Embase and the Cochrane database was conducted to perform a critical review of studies that analyze the treatment of lumbar facet joints with intra-articular injections and radiofrequency denervation. The authors concluded that current studies give sparse evidence to support the use of interventional techniques in the treatment of lumbar zygapophyseal joint-mediated low back pain.

**Koes BW, Scholten RJPM, Mens JMA, Bouter LM (1995) Efficacy of epidural steroid injections for low-back pain and sciatica: a systematic review of randomized clinical trials. Pain 63:279 – 288**
Twelve randomized clinical trials evaluating epidural steroid injections were analyzed. In this analysis six studies indicated that the epidural steroid injection was more effective than the reference treatment and six reported it to be no better or worse than the reference treatment. The authors concluded that the efficacy of epidural steroid injections has not yet been established and the benefits of epidural steroid injections, if any, seem to be of short duration only.

**Bollow M, Braun J, Taupitz M, et al. (1996) CT-guided intraarticular corticosteroid injection into the sacroiliac joints in patients with spondyloarthropathy: indication and follow-up with contrast-enhanced MRI. J Comput Assist Tomograph 20:512 – 521**
This article prospectively analyzes the therapeutic efficacy of CT-guided intra-articular corticosteroid instillation of inflamed sacroiliac joints in patients with spondyloarthropathies. The role of MRI as a test for indication and follow-up was evaluated. Sixty-one of 66 patients who underwent instillation of corticosteroid showed a statistically significant reduction of subjective complaints. Also the percentage of contrast enhancement on dynamic MRI showed a significant reduction.

## References


1. Adams MA, Dolan P, Hutton WC (1986) The stages of disc degeneration as revealed by discograms. J Bone Joint Surg Br 68:36 – 41
2. Barnsley L, Lord SM, Wallis BJ, Bogduk N (1994) Lack of effect of intraarticular corticosteroids for chronic pain in the cervical zygapophyseal joints. N Engl J Med 330:1047 – 50
3. Beliveau P (1971) A comparison between epidural anaesthesia with and without corticosteroid in the treatment of sciatica. Rheumatol Phys Med 11:40 – 3
4. Berger O, Dousset V, Delmer O, Pointillart V, Vital JM, Caille JM (1999) [Evaluation of the efficacy of foraminal infusions of corticosteroids guided by computed tomography in the treatment of radicular pain by foraminal injection]. J Radiol 80:917 – 25
5. Boden SD, Davis DO, Dina TS, Patronas NJ, Wiesel SW (1990) Abnormal magnetic-resonance scans of the lumbar spine in asymptomatic subjects: a prospective investigation. J Bone Joint Surg 72 A:403 – 408
6. Boden SD, McCowin PR, Davis DO, Dina TS, Mark AS, Wiesel S (1990) Abnormal magnetic-resonance scans of the cervical spine in asymptomatic subjects. A prospective investigation. J Bone Joint Surg Am 72:1178 – 84
7. Bogduk N, Aprill CN, Derby R (1995) Diagnostic block of spinal synovial joints. In: White AH, Schofferman JA, eds. Spine care. Diagnosis and conservative treatment. St. Louis: Mosby-Year Book, Inc., 298 – 321
8. Bollow M, Braun J, Taupitz M, Haberle J, Reibhauer BH, Paris S, Mutze S, Seyrekbasan F, Wolf KJ, Hamm B (1996) CT-guided intraarticular corticosteroid injection into the sacroiliac joints in patients with spondyloarthropathy: indication and follow-up with contrast-enhanced MRI. J Comput Assist Tomogr 20:512 – 21
9. Boos N, Dreier D, Hilfiker E, Schade V, Kreis R, Hora J, Aebi M, Boesch C (1997) Tissue characterization of symptomatic and asymptomatic disc herniations by quantitative magnetic resonance imaging. J Orthop Res 15:141 – 149
10. Boos N, Isotalo M, Witschger P, Angst M, Aebi M (1993) Discomanometry in lumbar intervertebral discs: An experimental study. Eur Spine J 2:215 – 222

11. Boos N, Lander PH (1996) Clinical efficacy of imaging modalities in the diagnosis of low-back pain disorders. Eur Spine J 5:2 – 22
12. Boos N, Rieder R, Schade V, Spratt KF, Semmer N, Aebi M (1995) 1995 Volvo Award in clinical sciences. The diagnostic accuracy of magnetic resonance imaging, work perception, and psychosocial factors in identifying symptomatic disc herniations. Spine 20:2613 – 25
13. Boos N, Semmer N, Elfering A, Schade V, Gal I, Zanetti M, Kissling R, Buchegger N, Hodler J, Main CJ (2000) Natural history of individuals with asymptomatic disc abnormalities in magnetic resonance imaging: predictors of low back pain-related medical consultation and work incapacity. Spine 25:1484 – 92
14. Botwin KP, Castellanos R, Rao S, Hanna AF, Torres-Ramos FM, Gruber RD, Bouchlas CG, Fuoco GS (2003) Complications of fluoroscopically guided interlaminar cervical epidural injections. Arch Phys Med Rehabil 84:627 – 33
15. Brouwers PJ, Kottink EJ, Simon MA, Prevo RL (2001) A cervical anterior spinal artery syndrome after diagnostic blockade of the right C6-nerve root. Pain 91:397 – 9
16. Buchner M, Zeifang F, Brocai DR, Schiltenwolf M (2000) Epidural corticosteroid injection in the conservative management of sciatica. Clin Orthop:149 – 56
17. Burke JG, Watson RW, Conhyea D, McCormack D, Dowling FE, Walsh MG, Fitzpatrick JM (2003) Human nucleus pulposis can respond to a pro-inflammatory stimulus. Spine 28: 2685 – 93
18. Burke JG, Watson RW, McCormack D, Dowling FE, Walsh MG, Fitzpatrick JM (2002) Intervertebral discs which cause low back pain secrete high levels of proinflammatory mediators. J Bone Joint Surg Br 84:196 – 201
19. Bush K, Hillier S (1991) A controlled study of caudal epidural injections of triamcinolone plus procaine for the management of intractable sciatica. Spine 16:572 – 5
20. Carette S, Leclaire R, Marcoux S, Morin F, Blaise GA, St-Pierre A, Truchon R, Parent F, Levesque J, Bergeron V, Montminy P, Blanchette C (1997) Epidural corticosteroid injections for sciatica due to herniated nucleus pulposus. N Engl J Med 336:1634 – 40
21. Carette S, Marcoux S, Truchon R, Grondin C, Gagnon J, Allard Y, Latulippe M (1991) A controlled trial of corticosteroid injections into facet joints for chronic low back pain. N Engl J Med 325:1002 – 7
22. Carragee EJ, Chen Y, Tanner CM, Truong T, Lau E, Brito JL (2000) Provocative discography in patients after limited lumbar discectomy: A controlled, randomized study of pain response in symptomatic and asymptomatic subjects. Spine 25:3065 – 71
23. Carragee EJ, Tanner CM, Khurana S, Hayward C, Welsh J, Date E, Truong T, Rossi M, Hagle C (2000) The rates of false-positive lumbar discography in select patients without low back symptoms. Spine 25:1373 – 80; discussion 1381
24. Carragee EJ, Tanner CM, Yang B, Brito JL, Truong T (1999) False-positive findings on lumbar discography. Reliability of subjective concordance assessment during provocative disc injection. Spine 24:2542 – 7
25. Carrera GF (1980) Lumbar facet joint injection in low back pain and sciatica: preliminary results. Radiology 137:665 – 7
26. Cassidy JD, Carroll LJ, Cote P (1998) The Saskatchewan health and back survey. The prevalence of low back pain and related disability in Saskatchewan adults. Spine 23:1860 – 1867
27. Castagnera L, Maurette P, Pointillart V, Vital JM, Erny P, Senegas J (1994) Long-term results of cervical epidural steroid injection with and without morphine in chronic cervical radicular pain. Pain 58:239 – 43
28. Castro WH, van Akkerveeken PF (1991) Der diagnostische Wert der selektiven lumbalen Nervenwurzelblockade. Z Orthop Ihre Grenzgeb 129:374 – 9
29. Catchlove RF, Braha R (1984) The use of cervical epidural nerve blocks in the management of chronic head and neck pain. Can Anaesth Soc J 31:188 – 91
30. Chan ST, Leung S (1989) Spinal epidural abscess following steroid injection for sciatica. Case report. Spine 14:106 – 8
31. Cicala RS, Thoni K, Angel JJ (1989) Long-term results of cervical epidural steroid injections. Clin J Pain 5:143 – 5
32. Cluff R, Mehio AK, Cohen SP, Chang Y, Sang CN, Stojanovic MP (2002) The technical aspects of epidural steroid injections: a national survey. Anesth Analg 95:403 – 8, table of contents
33. Crighton IM, Barry BP, Hobbs GJ (1997) A study of the anatomy of the caudal space using magnetic resonance imaging. Br J Anaesth 78:391 – 5
34. Cuckler JM, Bernini PA, Wiesel SW, Booth RE, Jr., Rothman RH, Pickens GT (1985) The use of epidural steroids in the treatment of lumbar radicular pain. A prospective, randomized, double-blind study. J Bone Joint Surg Am 67:63 – 6
35. Dilke TF, Burry HC, Grahame R (1973) Extradural corticosteroid injection in management of lumbar nerve root compression. Br Med J 2:635 – 7
36. Dooley JF, McBroom RJ, Taguchi T, Macnab I (1988) Nerve root infiltration in the diagnosis of radicular pain. Spine 13:79 – 83
37. Dreyfuss PH, Dreyer SJ, Herring SA (1995) Lumbar zygapophysial (facet) joint injections. Spine 20:2040 – 7

38. Dussault RG, Kaplan PA, Anderson MW (2000) Fluoroscopy-guided sacroiliac joint injections. Radiology 214:273 – 7
39. Elgafy H, Semaan HB, Ebraheim NA, Coombs RJ (2001) Computed tomography findings in patients with sacroiliac pain. Clin Orthop:112 – 8
40. Ferrante FM, Wilson SP, Iacobo C, Orav EJ, Rocco AG, Lipson S (1993) Clinical classification as a predictor of therapeutic outcome after cervical epidural steroid injection. Spine 18: 730 – 6
41. Fortin JD, Aprill CN, Ponthieux B, Pier J (1994) Sacroiliac joint: pain referral maps upon applying a new injection/arthrography technique. Part II: Clinical evaluation. Spine 19: 1483 – 9
42. Fortin JD, Dwyer AP, West S, Pier J (1994) Sacroiliac joint: pain referral maps upon applying a new injection/arthrography technique. Part I: Asymptomatic volunteers. Spine 19: 1475 – 82
43. Fukusaki M, Kobayashi I, Hara T, Sumikawa K (1998) Symptoms of spinal stenosis do not improve after epidural steroid injection. Clin J Pain 14:148 – 51
44. Ghormley RK (1933) Low back pain. With special reference to the articular facets, with presentation of an operative procedure. JAMA 101:1773 – 1777
45. Glynn C, Dawson D, Sanders R (1988) A double-blind comparison between epidural morphine and epidural clonidine in patients with chronic non-cancer pain. Pain 34:123 – 8
46. Gorbach C, Schmid M, Elfering A, Hodler J, Boos N (2006) Therapeutic efficacy of facet joint blocks. AJR Am J Roentgenol 186:1228 – 1233
47. Grubb SA, Kelly CK (2000) Cervical discography: clinical implications from 12 years of experience. Spine 25:1382 – 9
48. Guyer RD, Ohnmeiss DD (1995) Contemporary concepts in spine care: lumbar discography. Position statement from the North American Spine Society Diagnostic and Therapeutic Committee. Spine 20:2048 – 2059
49. Guyer RD, Ohnmeiss DD (1995) Lumbar discography. Position statement from the North American Spine Society Diagnostic and Therapeutic Committee. Spine 20:2048 – 59
50. Hanly JG, Mitchell M, MacMillan L, Mosher D, Sutton E (2000) Efficacy of sacroiliac corticosteroid injections in patients with inflammatory spondyloarthropathy: results of a 6 month controlled study. J Rheumatol 27:719 – 22
51. Houten JK, Errico TJ (2002) Paraplegia after lumbosacral nerve root block: report of three cases. Spine J 2:70 – 5
52. Huston CW, Slipman CW, Garvin C (2005) Complications and side effects of cervical and lumbosacral selective nerve root injections. Arch Phys Med Rehabil 86:277 – 83
53. Jackson RP (1992) The facet syndrome. Myth or reality? Clin Orthop:110 – 21
54. Jackson RP, Becker GJ, Jacobs RR, Montesano PX, Cooper BR, McManus GE (1989) The neuroradiographic diagnosis of lumbar herniated nucleus pulposus: I. A comparison of computed tomography (CT), myelography, CT-myelography, discography, and CT-discography. Spine 14:1356 – 61
55. Jackson RP, Cain JE, Jr., Jacobs RR, Cooper BR, McManus GE (1989) The neuroradiographic diagnosis of lumbar herniated nucleus pulposus: II. A comparison of computed tomography (CT), myelography, CT-myelography, and magnetic resonance imaging. Spine 14:1362 – 7
56. Jensen MC, Brant-Zawadzki MN, Obuchowski N, Modic MT, Malkasian D, Ross JS (1994) Magnetic resonance imaging of the lumbar spine in people without back pain. N Engl J Med 331:69 – 73
57. Karppinen J, Malmivaara A, Kurunlahti M, Kyllonen E, Pienimaki T, Nieminen P, Ohinmaa A, Tervonen O, Vanharanta H (2001) Periradicular infiltration for sciatica: a randomized controlled trial. Spine 26:1059 – 67
58. Klenerman L, Greenwood R, Davenport HT, White DC, Peskett S (1984) Lumbar epidural injections in the treatment of sciatica. Br J Rheumatol 23:35 – 8
59. Koes BW, Scholten RJ, Mens JM, Bouter LM (1995) Efficacy of epidural steroid injections for low-back pain and sciatica: a systematic review of randomized clinical trials. Pain 63: 279 – 88
60. Kolsi I, Delecrin J, Berthelot JM, Thomas L, Prost A, Maugars Y (2000) Efficacy of nerve root versus interspinous injections of glucocorticoids in the treatment of disk-related sciatica. A pilot, prospective, randomized, double-blind study. Joint Bone Spine 67:113 – 8
61. Leonardi M, Pfirrmann CW, Boos N (2006) Injection studies in spinal disorders. Clin Orthop Relat Res 443:168 – 82
62. Lilius G, Harilainen A, Laasonen EM, Myllynen P (1990) Chronic unilateral low-back pain. Predictors of outcome of facet joint injections. Spine 15:780 – 2
63. Lilius G, Laasonen EM, Myllynen P, Harilainen A, Gronlund G (1989) Lumbar facet joint syndrome. A randomised clinical trial. J Bone Joint Surg Br 71:681 – 4
64. Lippitt AB (1984) The facet joint and its role in spine pain. Management with facet joint injections. Spine 9:746 – 50
65. Lutz GE, Vad VB, Wisneski RJ (1998) Fluoroscopic transforaminal lumbar epidural steroids: an outcome study. Arch Phys Med Rehabil 79:1362 – 6

66. Lynch MC, Taylor JF (1986) Facet joint injection for low back pain. A clinical study. J Bone Joint Surg Br 68:138 – 41
67. Macnab I (1971) Negative disc exploration. An analysis of the causes of nerve-root involvement in sixty-eight patients. J Bone Joint Surg Am 53:891 – 903
68. Manchikanti L (1999) Facet joint pain and the role of neural blockade in its management. Curr Rev Pain 3:348 – 358
69. Mangar D, Thomas PS (1991) Epidural steroid injections in the treatment of cervical and lumbar pain syndromes. Reg Anesth 16:246
70. Marks RC, Houston T, Thulbourne T (1992) Facet joint injection and facet nerve block: a randomised comparison in 86 patients with chronic low back pain. Pain 49:325 – 8
71. Mathews JA, Mills SB, Jenkins VM, Grimes SM, Morkel MJ, Mathews W, Scott CM, Sittampalam Y (1987) Back pain and sciatica: controlled trials of manipulation, traction, sclerosant and epidural injections. Br J Rheumatol 26:416 – 23
72. Maugars Y, Mathis C, Vilon P, Prost A (1992) Corticosteroid injection of the sacroiliac joint in patients with seronegative spondyloarthropathy. Arthritis Rheum 35:564 – 8
73. McGregor AH, Anjarwalla NK, Stambach T (2001) Does the method of injection alter the outcome of epidural injections? J Spinal Disord 14:507 – 10
74. Milette PC, Fontaine S, Lepanto L, Cardinal E, Breton G (1999) Differentiating lumbar disc protrusions, disc bulges, and discs with normal contour but abnormal signal intensity. Magnetic resonance imaging with discographic correlations. Spine 24:44 – 53
75. Mooney V, Robertson J (1976) The facet syndrome. Clin Orthop:149 – 56
76. Moran R, O'Connell D, Walsh MG (1988) The diagnostic value of facet joint injections. Spine 13:1407 – 10
77. Murtagh FR, Arrington JA (1992) Computer tomographically guided discography as a determinant of normal disc level before fusion. Spine 17:826 – 30
78. Nachemson A (1989) Lumbar discography – Where are we today? Spine 14:555 – 556
79. Narozny M, Zanetti M, Boos N (2001) Therapeutic efficacy of selective nerve root blocks in the treatment of lumbar radicular leg pain. SMW 131:75 – 80
80. Nelemans PJ, deBie RA, deVet HC, Sturmans F (2001) Injection therapy for subacute and chronic benign low back pain. Spine 26:501 – 15
81. Ng LC, Sell P (2004) Outcomes of a prospective cohort study on peri-radicular infiltration for radicular pain in patients with lumbar disc herniation and spinal stenosis. Eur Spine J 13:325 – 9
82. Ohnmeiss DD, Guyer RD, Mason SL (2000) The relation between cervical discographic pain responses and radiographic images. Clin J Pain 16:1 – 5
83. Olmarker K, Blomquist J, Stromberg J, Nannmark U, Thomsen P, Rydevik B (1995) Inflammatogenic properties of nucleus pulposus. Spine 20:665 – 9
84. Olmarker K, Rydevik B (1991) Pathophysiology of sciatica. Orthop Clin North Am 22:223 – 34
85. Olmarker K, Rydevik B, Nordborg C (1993) Autologous nucleus pulposus induces neurophysiologic and histologic changes in porcine cauda equina nerve roots. Spine 18:1425 – 32
86. Pfirrmann CW, Oberholzer PA, Zanetti M, Boos N, Trudell DJ, Resnick D, Hodler J (2001) Selective nerve root blocks for the treatment of sciatica: evaluation of injection site and effectiveness – a study with patients and cadavers. Radiology 221:704 – 11
87. Rathmell JP, Aprill C, Bogduk N (2004) Cervical transforaminal injection of steroids. Anesthesiology 100:1595 – 600
88. Revel M, Poiraudeau S, Auleley GR, Payan C, Denke A, Nguyen M, Chevrot A, Fermanian J (1998) Capacity of the clinical picture to characterize low back pain relieved by facet joint anesthesia. Proposed criteria to identify patients with painful facet joints. Spine 23:1972 – 6; discussion 1977
89. Revel ME, Listrat VM, Chevalier XJ, Dougados M, N'Guyen M P, Vallee C, Wybier M, Gires F, Amor B (1992) Facet joint block for low back pain: identifying predictors of a good response. Arch Phys Med Rehabil 73:824 – 8
90. Ridley MG, Kingsley GH, Gibson T, Grahame R (1988) Outpatient lumbar epidural corticosteroid injection in the management of sciatica. Br J Rheumatol 27:295 – 9
91. Riew KD, Yin Y, Gilula L, Bridwell KH, Lenke LG, Lauryssen C, Goette K (2000) The effect of nerve-root injections on the need for operative treatment of lumbar radicular pain. A prospective, randomized, controlled, double-blind study. J Bone Joint Surg Am 82-A:1589 – 93
92. Robecchi A, Capra R (1952) [Hydrocortisone (compound F); first clinical experiments in the field of rheumatology.]. Minerva Med 43:1259 – 63
93. Rocco AG, Frank E, Kaul AF, Lipson SJ, Gallo JP (1989) Epidural steroids, epidural morphine and epidural steroids combined with morphine in the treatment of post-laminectomy syndrome. Pain 36:297 – 303
94. Rowlingson JC, Kirschenbaum LP (1986) Epidural analgesic techniques in the management of cervical pain. Anesth Analg 65:938 – 42
95. Rozin L, Rozin R, Koehler SA, Shakir A, Ladham S, Barmada M, Dominick J, Wecht CH (2003) Death during transforaminal epidural steroid nerve root block (C7) due to perforation of the left vertebral artery. Am J Forensic Med Pathol 24:351 – 5

96. Saal JS (2002) General principles of diagnostic testing as related to painful lumbar spine disorders: a critical appraisal of current diagnostic techniques. Spine 27:2538 – 45; discussion 2546
97. Sachs BL, Vanharanta H, Spivey MA, Guyer RD, Videman T, Rashbaum RF, Johnson RG, Hochschuler SH, Mooney V (1987) Dallas discogram description. A new classification of CT/discography in low-back disorders. Spine 12:287 – 94
98. Schwarzer AC, Aprill CN, Bogduk N (1995) The sacroiliac joint in chronic low back pain. Spine 20:31 – 7
99. Schwarzer AC, Aprill CN, Derby R, Fortin J, Kine G, Bogduk N (1994) Clinical features of patients with pain stemming from the lumbar zygapophysial joints. Is the lumbar facet syndrome a clinical entity? Spine 19:1132 – 7
100. Schwarzer AC, Aprill CN, Derby R, Fortin J, Kine G, Bogduk N (1994) The false-positive rate of uncontrolled diagnostic blocks of the lumbar zygapophysial joints. Pain 58:195 – 200
101. Schwarzer AC, Aprill CN, Derby R, Fortin J, Kine G, Bogduk N (1994) The relative contributions of the disc and zygapophyseal joint in chronic low back pain. Spine 19:801 – 6
102. Schwarzer AC, Derby R, Aprill CN, Fortin J, Kine G, Bogduk N (1994) The value of the provocation response in lumbar zygapophyseal joint injections. Clin J Pain 10:309 – 13
103. Schwarzer AC, Wang SC, Bogduk N, McNaught PJ, Laurent R (1995) Prevalence and clinical features of lumbar zygapophysial joint pain: a study in an Australian population with chronic low back pain. Ann Rheum Dis 54:100 – 6
104. Schwarzer AC, Wang SC, O'Driscoll D, Harrington T, Bogduk N, Laurent R (1995) The ability of computed tomography to identify a painful zygapophysial joint in patients with chronic low back pain. Spine 20:907 – 12
105. Serrao JM, Marks RL, Morley SJ, Goodchild CS (1992) Intrathecal midazolam for the treatment of chronic mechanical low back pain: a controlled comparison with epidural steroid in a pilot study. Pain 48:5 – 12
106. Slipman CW, Bhat AL, Gilchrist RV, Issac Z, Chou L, Lenrow DA (2003) A critical review of the evidence for the use of zygapophysial injections and radiofrequency denervation in the treatment of low back pain. Spine J 3:310 – 6
107. Slipman CW, Lipetz JS, Jackson HB, Rogers DP, Vresilovic EJ (2000) Therapeutic selective nerve root block in the nonsurgical treatment of atraumatic cervical spondylotic radicular pain: a retrospective analysis with independent clinical review. Arch Phys Med Rehabil 81:741 – 6
108. Slipman CW, Lipetz JS, Plastaras CT, Jackson HB, Vresilovic EJ, Lenrow DA, Braverman DL (2001) Fluoroscopically guided therapeutic sacroiliac joint injections for sacroiliac joint syndrome. Am J Phys Med Rehabil 80:425 – 32
109. Slipman CW, Sterenfeld EB, Chou LH, Herzog R, Vresilovic E (1996) The value of radionuclide imaging in the diagnosis of sacroiliac joint syndrome. Spine 21:2251 – 4
110. Smith BM, Hurwitz EL, Solsberg D, Rubinstein D, Corenman DS, Dwyer AP, Kleiner J (1998) Interobserver reliability of detecting lumbar intervertebral disc high-intensity zone on magnetic resonance imaging and association of high-intensity zone with pain and anular disruption. Spine 23:2074 – 80
111. Snoek W, Weber H, Jorgensen B (1977) Double blind evaluation of extradural methyl prednisolone for herniated lumbar discs. Acta Orthop Scand 48:635 – 41
112. Stanley D, McLaren MI, Euinton HA, Getty CJ (1990) A prospective study of nerve root infiltration in the diagnosis of sciatica. A comparison with radiculography, computed tomography, and operative findings. Spine 15:540 – 3
113. Stojanovic MP, Vu TN, Caneris O, Slezak J, Cohen SP, Sang CN (2002) The role of fluoroscopy in cervical epidural steroid injections: an analysis of contrast dispersal patterns. Spine 27:509 – 14
114. Strobel K, Pfirrmann CW, Schmid M, Hodler J, Boos N, Zanetti M (2004) Cervical nerve root blocks: indications and role of MR imaging. Radiology 233:87 – 92
115. Suh PB, Esses SI, Kostuik JP (1991) Repair of pars interarticularis defect. The prognostic value of pars infiltration. Spine 16:S445 – 8
116. The Executive Committee of the North American Spine Society (1988) Position statement on discography. Spine 13:1343
117. Thomas E, Cyteval C, Abiad L, Picot MC, Taourel P, Blotman F (2003) Efficacy of transforaminal versus interspinous corticosteroid injection in discal radiculalgia – a prospective, randomised, double-blind study. Clin Rheumatol 22:299 – 304
118. Tuite MJ (2004) Facet joint and sacroiliac joint injection. Semin Roentgenol 39:37 – 51
119. Vad VB, Bhat AL, Lutz GE, Cammisa F (2002) Transforaminal epidural steroid injections in lumbosacral radiculopathy: a prospective randomized study. Spine 27:11 – 6
120. Valat JP, Giraudeau B, Rozenberg S, Goupille P, Bourgeois P, Micheau-Beaugendre V, Soubrier M, Richard S, Thomas E (2003) Epidural corticosteroid injections for sciatica: a randomised, double blind, controlled clinical trial. Ann Rheum Dis 62:639 – 43
121. Vallee JN, Feydy A, Carlier RY, Mutschler C, Mompoint D, Vallee CA (2001) Chronic cervical radiculopathy: lateral-approach periradicular corticosteroid injection. Radiology 218:886 – 92

122. van Akkerveeken PF (1993) The diagnostic value of nerve root sheath infiltration. Acta Orthop Scand Suppl 251:61 – 3
123. Walsh TR, Weinstein JN, Spratt KF, Lehmann TR, Aprill C, Sayre H (1990) Lumbar discography in normal subjects. A controlled, prospective study. J Bone Joint Surg Am 72:1081 – 8
124. Wang JC, Lin E, Brodke DS, Youssef JA (2002) Epidural injections for the treatment of symptomatic lumbar herniated discs. J Spinal Disord Tech 15:269 – 72
125. Watts RW, Silagy CA (1995) A meta-analysis on the efficacy of epidural corticosteroids in the treatment of sciatica. Anaesth Intensive Care 23:564 – 9
126. Weiner BK, Fraser RD (1997) Foraminal injection for lateral lumbar disc herniation. J Bone Joint Surg Br 79:804 – 7
127. Weinstein J, Claverie W, Gibson S (1988) The pain of discography. Spine 13:1344 – 8
128. Weishaupt D, Zanetti M, Hodler J, Boos N (1998) MR imaging of the lumbar spine: Prevalence of intervertebral disk extrusion and sequestration, nerve root compression, endplate abnormalities and osteoarthritis of the facet joints in asymptomatic volunteers. Radiology 209:661 – 666
129. Weishaupt D, Zanetti M, Hodler J, Min K, Fuchs B, Pfirrmann CW, Boos N (2001) Painful lumbar disk derangement: relevance of endplate abnormalities at MR imaging. Radiology 218:420 – 7
130. Willems PC, Jacobs W, Duinkerke ES, De Kleuver M (2004) Lumbar discography: should we use prophylactic antibiotics? A study of 435 consecutive discograms and a systematic review of the literature. J Spinal Disord Tech 17:243 – 7
131. Williams KN, Jackowski A, Evans PJ (1990) Epidural haematoma requiring surgical decompression following repeated cervical epidural steroid injections for chronic pain. Pain 42:197 – 9
132. Wilppula E, Jussila P (1977) Spinal nerve block. A diagnostic test in sciatica. Acta Orthop Scand 48:458 – 60
133. Winnie AP, Hartman JT, Meyers HL, Jr., Ramamurthy S, Barangan V (1972) Pain clinic. II. Intradural and extradural corticosteroids for sciatica. Anesth Analg 51:990 – 1003
134. Wood KB, Schellhas KP, Garvey TA, Aeppli D (1999) Thoracic discography in healthy individuals. A controlled prospective study of magnetic resonance imaging and discography in asymptomatic and symptomatic individuals. Spine 24:1548 – 55
135. Yates DW (1978) A comparison of the types of epidural injection commonly used in the treatment of low back pain and sciatica. Rheumatol Rehabil 17:181 – 6
136. Zeidman SM, Thompson K, Ducker TB (1995) Complications of cervical discography: analysis of 4400 diagnostic disc injections. Neurosurgery 37:414 – 7

# 11 Neurological Assessment in Spinal Disorders

Uta Kliesch, Armin Curt

## Core Messages

- ✔ There is a rather low prevalence of neurological deficits in spinal disorders
- ✔ Neurological deficits can range from very severe and obvious (complete paraplegia) to subtle (radicular sensory deficit)
- ✔ The neurological deficit per se is non-specific to the spinal disorder

The **neurological examination:**

- ✔ Is key to the reliable exclusion of a neurological deficit
- ✔ Complements and influences the diagnostic procedures
- ✔ Has to follow a standardized algorithm to identify the level and extent of a neurological lesion
- ✔ Distinguishes between lesions of the central (cortical, spinal) and peripheral nervous system (nerve roots, plexus, peripheral nerves)
- ✔ Seeks for a somatotopic localization of the lesion
- ✔ Impacts on the treatment decision (conservative versus surgical management) in the presence of a neurological deficit
- ✔ Is insensitive for the assessment of autonomic disorders which require additional testings (e.g. bladder assessment)

## Epidemiology

The presence of neurological deficits varies to a large extent in spinal disorders

Spinal disorders are associated with neurological symptoms to a very variable extent depending on the underlying pathology. In cervical myelopathy and lumbar spinal canal stenosis, a neurological deficit has been described in about 30–50% of patients depending on the applied clinical measures [3, 33, 65, 76, 105, 117]. Although in general neurological deficits are rather low in frequency, misdiagnosis or failure to detect neurological symptoms may lead to severe sequelae and can result in invalidity if inappropriate management is provided [40]. A knowledge of the typical neurological deficits associated with spinal disorders allows for the management of the diagnostic work-up in timely and comprehensive fashion, and the identification of potential neurological deficits in the treatment of patients with spinal disorders.

**Non-traumatic spinal disorders** are mainly due to degenerative diseases (e.g. disc herniation and spinal canal stenosis) and occur increasingly in the aging population [11, 24]. Also spine related pain syndromes have a high prevalence which increases with age. For instance, neck and arm pain will have affected about 20–34% of a general population once as shown in a large cross-sectional study and induces actual complaints in about 14% [16, 47]. However, only in about 4% of patients suffering from a cervico-cephalic-brachial pain syndrome is an MRI documented radicular lesion present, whereas functional disturbances in conjunction with cervical spondylosis occur in 80% [61]. Similar findings are reported in patients suffering from low back pain where a focal neurological lesion is present in a comparably low percentage [3, 7, 31, 60].

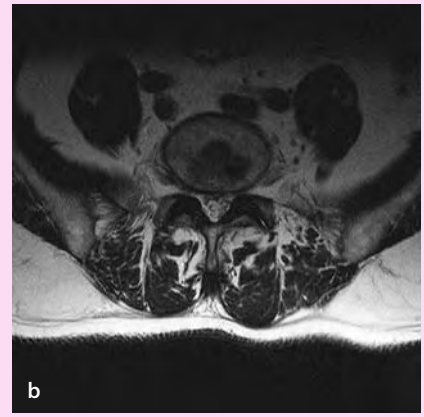

## Case Introduction

A 63-year-old male patient underwent a left-sided discectomy of L5/S1 for an S1 radiculopathy. After a pain free interval of 5 months, he presented again with severe recurrent left sided leg pain predominantly at the posterolateral aspect of the calf. An MRI scan showed a small recurrent sequestrated disc herniation at the level previously operated on (a, b). The patient was referred to a neurologist because the clinical findings and the imaging study did not completely match. A detailed history revealed that the patient reported pain in the lower back down to the left calf and heel. However, he additionally felt numbness in the thoracoabdominal skin on the left side. The neurological examination revealed an absent left Achilles tendon reflex, hypesthesia of the left T6–T10 and S1 dermatomes but no paresis. The L5 dermatome presented petechial efflorescence (c, d). The EMG of the gastrognemius muscle confirmed chronic denervation as a sign of a radicular lesion probably caused by the disc herniation of the S1 root. However, prolonged tibial somatosensory evoked potential, hypesthesia of the thoracic dermatomes as well as the dermatomal efflorescence suggested an additional neurological disorder. The suspected diagnosis of a herpes associated myelitis was confirmed by pathological antibody titers against herpes zoster virus, and increased cell count (65/µl) and protein level (1.66 g/l) in the CSF. The patient was treated with acyclovir (i.v. application over 5 days and continued oral medication for 3 months). Three months later the pain had completely subsided and the patient regained full neurological function.

Always differentiate radiculopathy and peripheral neuropathy

Peripheral neurological disorders may mimic radiculopathy and should be differentiated by the neurological examination and complementary neurophysiological tests.

Entrapment syndromes are easily confused with radiculopathy

For example, polyneuropathy can cause similar symptoms to lumbar stenosis. While the clinical examination might not be sensitive enough to distinguish between both disorders, neurophysiological testing (nerve conduction and reflex studies) can confirm the presence of a polyneuropathy. There are no reliable data available on the prevalence of polyneuropathy in a general population and the reported percentage ranges between 7 % and 57 % [120]. About 50 % of patients with diabetes and 60 % of patients with alcohol addiction suffer from polyneuropathy, indicating the importance of an extended differential diagnosis in this patient population when patients present with back and leg pain [32, 88, 90, 122]. Entrapment syndromes frequently show similarities to radicular syndromes. The carpal tunnel syndrome (CTS) is the most frequent entrapment (6 % in a general population) syndrome and occurs twice as often as the compression syndrome of the ulnar nerve [8, 9, 27, 28, 106]. Similar in symptoms, but less common, is the thoracic outlet syndrome (TOS), occurring in not more than 1 % in a general population [79]. The counterpart of the CTS is the tarsal tunnel syndrome of the foot, which is much rarer than the CTS. In electromyography (EMG) laboratories the incidence is reported to be lower than 0.5 % [78, 80].

The C5, C6, L5 and S1 nerve roots are most frequently affected

Due to the different vulnerability of specific nerve fibers and spinal cord tracts, **typical clinical syndromes** are frequently observed both in degenerative and in traumatic spinal disorders. Degenerative disorders, particularly spinal stenosis and disc herniation, most frequently occur in the cervical and lumbar spinal segments due to the biomechanical spine properties (anatomical characteristics) and dynamic/static forces acting on these segments. While a cervical spinal stenosis can result in cervical myelopathy with clinical signs of impaired longitudinal tracts (spasticity of lower limbs, numbness of feet), lumbar spinal stenosis can affect the cauda equina causing neurogenic claudication. Radiculopathies are mainly due to disc herniation and to hypertrophic facet joints. The most frequent cervical radicular lesion is the radiculopathy of C5 and C6, whereas in lumbar radiculopathy the L5 and S1 roots are most frequently involved [17, 38, 102, 128]. Furthermore, in 16 % of patients (study of 585 patients screened in a regional UK clinical neuroscience center) with a non-traumatic para- or tetraparesis, a metastatic or primary spinal tumor could be diagnosed [82, 112].

**Traumatic spinal disorders** (e.g. spinal cord injury, SCI) are mainly caused [30] by:

- motor vehicle accidents (40 – 50 %)
- sports accidents and falls (20 – 30 %)
- assaults (gunshot and stabbing) (5 – 20 %)
- occupational injuries (10 – 20 %)

Patients suffering from traumatic SCI are mainly young (average age 38 years) and male (male : female ratio = 4 : 1), while there is a second age peak between 60 and 80 years due to predominantly falling injuries [30, 34, 39, 56, 100, 118, 124]. The incidence of traumatic SCI (10 – 30/million) varies between countries with a slightly higher number of incomplete SCI and tetraplegia versus paraplegia (for reference see: www.spinalcord.uab.edu). While spontaneous (osteoporotic) compression fractures of the vertebral column rarely show neurological deficit, burst fractures of the cervical and thoracic spine are commonly associated with severe neurological deficits [4, 12, 21, 71, 72, 119].

About 55 % of patients with SCI suffer from tetraplegia

In patients with SCI, the cervical vertebral column is the most frequently injured spine segment resulting in incomplete tetraplegia in 34.3 % and complete tetraplegia in 22.1 % of cases.

In mid-thoracic traumatic fractures, patients mainly suffer from complete paraplegia while fractures at the thoracic-lumbar junction show an incomplete lesion in more than half of the patients [42, 119].

## Anatomy and Somatotopic Background

The spinal cord represents the only connection of neurological structures between body and brain for the conduction of motor, sensory and sympathetic-autonomous information. The **parasympathetic innervation** bypasses the spinal cord via the vagal nerve originating from the brainstem. Longitudinally oriented spinal tracts (white matter) surround central areas (**gray matter**) where neuronal cell bodies are located (Fig. 1). Sensory axons entering the dorsal part of the spinal cord originate in the **dorsal root ganglia**, which are located outside the spinal cord. Along with the motor axons originating from the central part of the spinal cord, they leave the spinal segment through the intervertebral foramen at every segment. Furthermore, it is important to realize that the motor synapses between the first and the second motoneurons are located in the ventral part of the gray matter (alpha-motoneuron), whereas the neuronal cell bodies of the peripheral sensory neuron are situated in the dorsal root ganglion within the intervertebral foramen.

The cell bodies of the motoneurons are located in the gray matter

The cell bodies of the sensory neurons are located in the dorsal root ganglion

In the cervical spine there is one pair of cervical nerve roots more than vertebrae bodies. Therefore, the anatomic relationship changes at the cervicothoracic junction. While in the cervical spine the C4 nerve root exits the C3/4 foramen, the L4 nerve root exits the L4/5 foramen in the lumbar spine. In the cervical spine, the cell bodies of the alpha-motoneuron are located approximately one level higher than the exiting nerve root. This is of clinical relevance as focal damage to the anterior spinal cord can cause a more distal deficit than one would expect from the location [25]. Essential **anatomical landmarks** of the somatotopic organization of the spinal cord are:

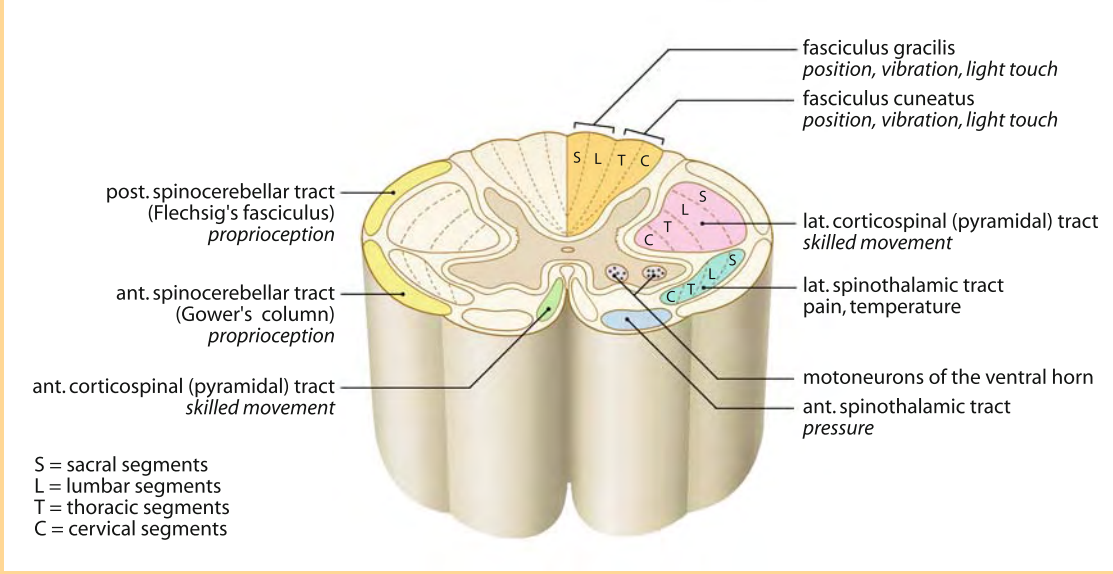


Figure 1. Somatotopic organization of the spinal cord

- the **posterior column** containing sensory nerve tracts conducting position sense (proprioception) and awareness of deep pressure
- the **ventrolateral column** contains spinothalamic tracts for the sensation of pain and temperature
- the **posterior-lateral tract** transmitting voluntary motor control through the pyramidal tract

## Classification

A straightforward differentiation of neurological impairment is related to the cause and onset of the disorders and **basically distinguishes** between:

- traumatic injuries
- non-traumatic disorders

Spinal disorders can further be differentiated with regard to the affected **neuronal structures**, i.e.:

- central (CNS) nervous system
- peripheral (PNS) nervous system

A CNS lesion indicates a compromise of the brain or spinal cord, i.e. longitudinal spinal tracts. In contrast, a PNS lesion includes impairment of all the neural structures outlying the spinal cord, i.e. ventral nerve roots and cauda equina nerve fibers within the spinal canal. Therefore, a lesion of the conus medullaris with degeneration of the alpha-motoneurons or the cauda equina shows typical clinical findings of PNS involvement while a lesion higher within the spinal cord mainly presents as a central sensorimotor deficit.

**Non-traumatic spinal disorders** can be differentiated as listed in Table 1.

Focal compression syndromes predominantly occur in the cervical or lumbar spine

Focal **compression syndromes** of the spinal cord in degenerative disorders are predominantly localized at the cervical and lumbar spinal level [3, 6, 92, 115]. Here, the spine has to cope with the highest biomechanical stress (a high range of motion and being under great strain during daily activities) and is prone to develop a degenerative stenosis resulting either in cervical myelopathy or lumbar spinal canal stenosis and neurogenic claudication. Furthermore, the cervical spinal canal can show a congenitally reduced diameter with increased vulnerability to degeneration or even minimal cervical trauma with severe neurological sequelae [107, 115, 130]. Cervical spinal canal stenosis due to obliterating hypertrophy of the occipital posterior longitudinal ligament (OPLL) and less frequently in the thoracic spine can also induce spinal cord compression even in younger patients [48, 53, 77, 129]. **Spine tumors** of different etiology (intra- or extradural) and dignity always have to be considered in patients assumed to suffer from spinal disorders [1, 44, 66, 81]. **Spinal hemorrhages** predominantly occur acutely/spontaneously in patients undergoing anticoagulation treatment, or suffering from tumors or arteriovenous malformations [37, 58, 83, 91, 114, 116, 126]. While spine compression, tumors and hemorrhages can be reliably diagnosed by imaging (preferably by MRI), the **ischemic, infectious, and degenerative disorders** need a thorough work-up to conclude the specific diagnosis [10, 46].

In atypical cases also consider non-spinal differential diagnosis

Specifically in cases with atypical presentation, disorders other than those of the spinal cord have to be considered in the differential diagnosis. Similarly, in older and multi-morbidity patients, peripheral nerve disorders can be confused with spinal cord disorders and have to be specifically addressed. In patients with a slowly developing polyneuritis, an increasing motor weakness, reduction of walking distance and occurring pain can mimic a lumbar spinal stenosis, while neurophysiological testing can be applied to distinguish between both disorders.

**Table 1.** Classification of non-traumatic neurological syndromes

| Impaired neurological structure | Cause of impairment | Major symptoms |
|---|---|---|
| Spinal cord compression | • disc herniation<br>• congenital cervical stenosis<br>• degenerative cervical stenosis<br>• ossification of the posterior longitudinal ligament (OPLL)<br>• lumbar spinal canal stenosis | • severe pain<br>• para-/tetraparesis<br>• bowel/bladder dysfunction<br>• clumsy hands with reduced dexterity<br>• ataxic gait<br>• bladder dysfunction micturition problems (urgency, frequency)<br>• pain<br>• slowly developing myelopathy<br>• radiculopathy (frequently)<br>• neurogenic claudication<br>• low back pain |
| Spinal cord tumor | • extramedullary intradural tumor (neurinoma, meningeoma, schwannoma)<br>• extramedullary extradural (metastases, lymphoma)<br>• intramedullary tumor (ependymoma, astrocytoma) | • pain syndromes<br>• progressive tetra-/paraparesis<br>• bladder-bowel dysfunction |
| Spinal hemorrhage | • spontaneous hemorrhage (AV malformation, cavernoma, anticoagulation) | • sudden onset<br>• acute girdle pain<br>• increasing tetra-/paraparesis |
| Ischemic spinal cord lesion | • ischemia of anterior spinal artery (arteria sulcocommissuralis)<br>• spinal cord malacia (arteria radicularis magna Adamkiewics)<br>• AV malformation | • girdle-like pain prior to weakness<br>• central cord syndrome<br>• acute paraplegia<br>• intermittent claudication |
| Demyelinating disorders | • multiple sclerosis<br>• acute demyelinating encephalomyelitis (ADEM)<br>• transverse myelitis<br>• neuromyelitis optica (Devic syndrome) | • recurrent episodes or primary chronic course of sensorimotor deficits<br>• visual disturbance<br>• acute onset<br>• cerebral symptoms associated with sensorimotor deficits (mostly after viral infection or vaccination)<br>• acute onset with rapid and profound deficits<br>• no clear association with viral infection or other demyelinating CNS disorders<br>• fulminating progressive para-/tetraplegia<br>• loss of vision |
| Infectious myelitis | • viral (HSV, HIV, HTLV, EBV, Coxsackie virus, echovirus, poliomyelitis)<br>• bacterial and fungal | • initial girdle-like pain<br>• progressive para- or tetraplegia<br>• spastic spinal paralysis |
| Physical myelopathy | • radiation/electrical spinal cord damage | • postradiation symptoms (early or late)<br>• beginning with pain<br>• variable syndromes |
| Hereditary/sporadic degeneration of spinal pathways | • variable mutations of genes, amyotrophic lateral sclerosis | • mainly associated with spastic paraplegia<br>• variable sensory loss<br>• muscle atrophy<br>• bladder dysfunction |

A mismatch of clinical findings and imaging studies must prompt a thorough neurological assessment

Therefore, in patients where the radiological and clinical findings are not fully in line with the patient complaints or imaging findings, a thorough neurological work-up should be initiated (Case Introduction). For example, the first clinical symptom of a diabetic neuropathy can appear as a severe painful affection of the femoral nerve with a marked paralysis of the quadriceps muscle. This symptom can be easily confused with an L3 radiculopathy and the mismatch between an extensive clinical picture (weakness, loss of reflexes and sensory deficit) and normally appearing lumbar imaging should indicate a further work-up.

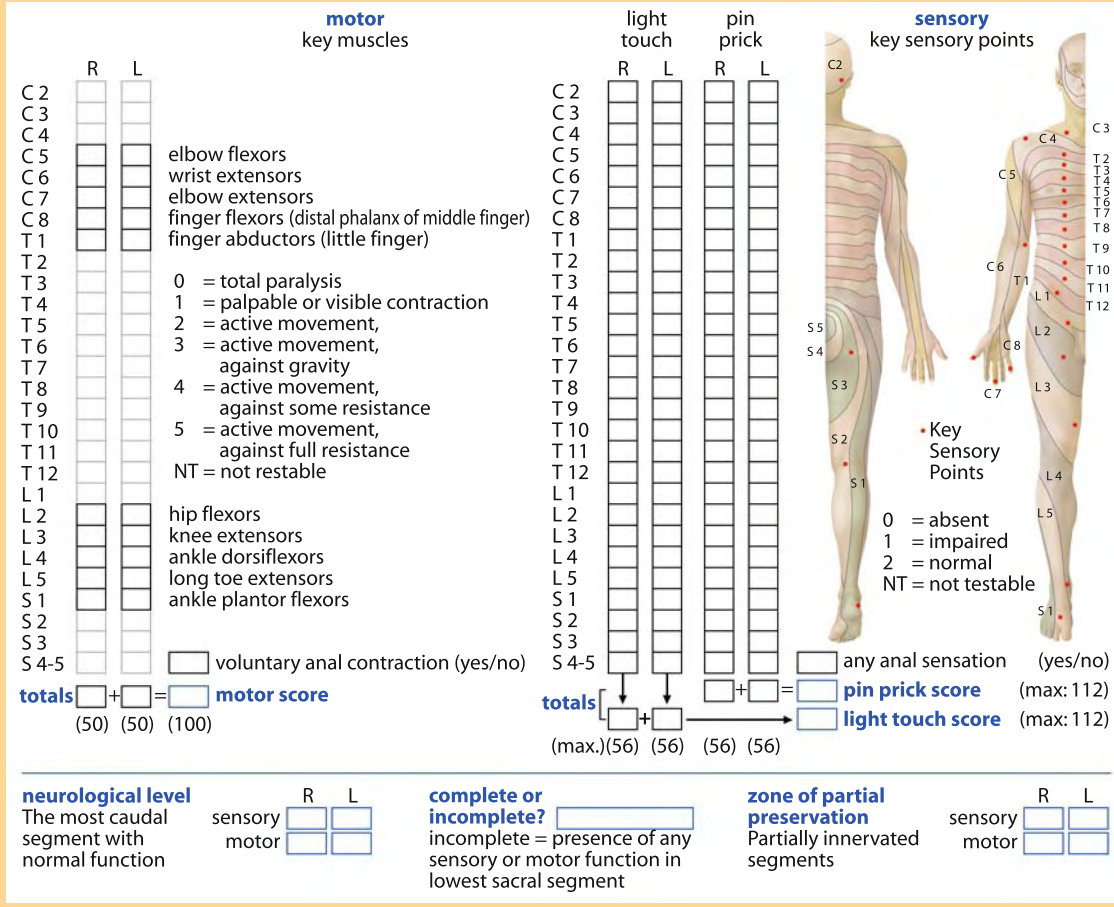


**Figure 2.** Standard neurological classification of spinal cord injuries (ASIA)

In **traumatic spinal cord injury** the main classification distinguishes between:

- paraplegia
- tetraplegia

The term "paraplegia" refers to the impairment or loss of motor and/or sensory function in the thoracic, lumbar or sacral (but not cervical) neural segments (T2–S5). Impairment or loss of motor and/or sensory function in the cervical segments (C0–T1) is called tetraplegia. In accordance with the standard neurological classification of spinal cord injury (Fig. 2) of the American Spinal Injury Association (**ASIA**), the defined muscles and sensory examination points should be assessed for diagnosis [68].

A further differentiation is made with regard to the **completeness of the lesion** as:

- complete
- incomplete

The distinction between complete and incomplete is based on the preservation of any sensory or motor function within the last sacral segments S4–S5. The ASIA impairment scale (AIS) allows a further grading (Table 2) of the completeness of the lesion [67, 70].

The preservation of lower sacral segments indicates an incomplete lesion

**Table 2.** ASIA Impairment Scale

| | |
|---|---|
| ASIA A | • sensory and motor complete |
| ASIA B | • sensory incomplete, motor complete |
| ASIA C | • sensory and motor incomplete, motor function below the level of lesion in mean M3 |
| ASIA D | • sensory and motor incomplete, motor function below the level of lesion in mean >M3 |
| ASIA E | • no relevant sensorimotor deficit, minor functional impairments of reflex-muscle tone changes |

## Neurological Assessment

Complementary to the physical and radiological examination of the spine, the neurological examination focuses on identifying:

- the level of the lesion
- the extent of neural compromise

A detailed history enables an initial broad diagnosis (involvement of upper versus lower limbs, time of onset, trauma) and the neurological examination determines more precisely any possible spinal cord damage. The clinical examination can be complemented by additional neurophysiological studies particularly when the clinical examination is limited due to poor cooperation by the patient. The following **clinical symptoms** should be distinguished by the examiner:

- motor weakness
- sensory deficit
- altered reflexes (cave: spinal shock)
- pain syndromes
- autonomic functions (bowel and bladder dysfunction)

The **examination** can allocate the symptoms to neurological syndromes such as:

- radiculopathy
- polyneuropathy
- myelopathy
- central paresis

Neurological syndromes are non-specific for the underlying pathology

However, neurological syndromes are non-specific with regard to their spinal cause, e.g. a radiculopathy can be caused by a disc herniation, an osseous spur, or a synovial facet joint cyst. From a practical point of view, it is reasonable to differentiate the assessment of patients with and without trauma and the course of symptom onset (acute versus slowly progressive). This differentiation is not always self-evident and has to be specifically identified.

### Pain

Pain is the most frequently complained of symptom which can lead one to the impaired neurological structure [49, 95, 108]. The pathophysiology and diagnostic assessment of pain are covered in Chapters 5 and 40.

### Sensory Deficits

Distinguish the sensory qualities (light touch, pin prick, proprioception)

Although multiple sensory qualities (heat–cold, pain, touch, pressure, static and dynamic two-point discrimination, vibration sensation) can be distinguished, the **examination of:**

- light touch
- pinprick
- proprioception

is most frequently applied in clinical practice to assess spinal cord dysfunction [13, 41, 51, 62, 84, 89, 99, 101]. While the light touch sensation assesses the perception of touch as applied by the finger or cotton wool, the pinprick sensation identifies the ability to sense a sharp needle tip. The latter function is transmitted via the spinothalamic spinal pathway and the actual examination does not produce different levels of pain. The **key** is that the patient identifies a sharp sensation, which is not necessarily painful. The vibration sense is reliably tested with a tuning fork that allows different grades of vibration recognition to be distinguished [45, 86, 98, 99].

It is important to be aware that particularly incomplete lesions of the spinal cord can cause more diffuse distributed sensory deficits whereas radicular and peripheral lesions result in circumscribed changes. Patients with cervical myelopathy often complain of pain, clumsiness and numbness of the whole hands and/or feet.

Consider central lesions in diffuse/dissociated sensory deficits

In ischemic lesions of the central part of the spinal cord, the predominant clinical finding is an impairment of pain and temperature sensation. In such cases, sensation to touch remains preserved while pain and temperature sensation is abolished, which is typically distributed in a segmental pattern. The affection of the posterior column as induced by a $B_{12}$ hypovitaminosis or rarely due to trauma causes a reduction of the vibration sense with predominant gait disturbance.

## Motor Deficits

The differentiation of the causes of muscle weakness can sometimes cause diagnostic difficulties. In general the following lesions should be distinguished:

- peripheral lesion
- radicular lesion
- central lesion

The muscle force should be assessed according to a standardized protocol either following the guidelines of the British Medical Research Council or as modified by the ASIA Standards (see Chapter 8) [70].

A monoparesis of upper or lower limbs is frequently caused by a plexus lesion. Radicular lesions are typically associated with pain emanating into the respective dermatomes and show paresis of the innervated muscles. The differentiation between radicular and peripheral nerve lesion is sometimes difficult (see below).

Painless muscle atrophy demands a detailed neurological differential diagnosis

A **painless atrophy** of hand or foot muscle always demands a neurological work-up and an extended differential diagnosis has to be considered:

- amyotrophic lateral sclerosis
- spinal muscular atrophy
- myelopathy
- neuropathy (hereditary motor neuropathies)

## Reflex Deficits

Screen for central lesions using reflex assessments

The clinical examination of upper and lower limbs as well as sacral reflexes is mandatory in the assessment of spinal disorders. Reflexes are not only helpful in defining the level of lesion but also in distinguishing acute versus chronic changes. Besides the muscle tendon reflexes, various signs (Figs. 3, 4) and muscle tone testing (clonus, stiffness) are used to screen for **pyramidal tract or conus lesions** [5, 18, 23, 36, 43, 54, 64, 75, 85, 104, 127].

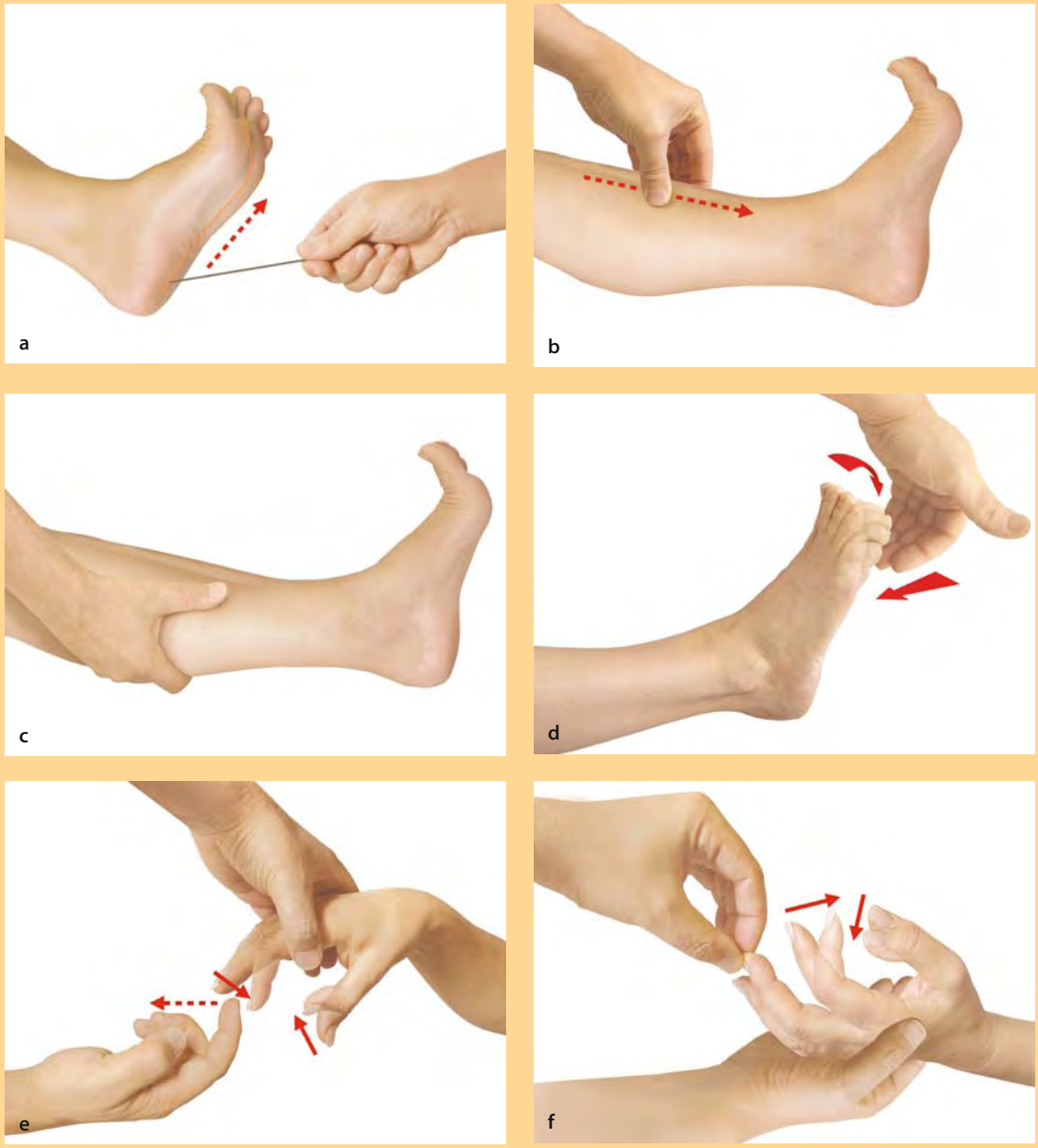


**Figure 3. Signs (reflexes) indicating pyramidal tract lesions**

a Babinski sign. b Oppenheim sign. c Gordon sign. d Rossolimo sign. e Trömner sign. f Hoffmann sign. The Hoffmann and Trömner signs can be observed in healthy individuals with hyperexcitability and are only pathologic if they occur unilaterally or in very pronounced fashion.

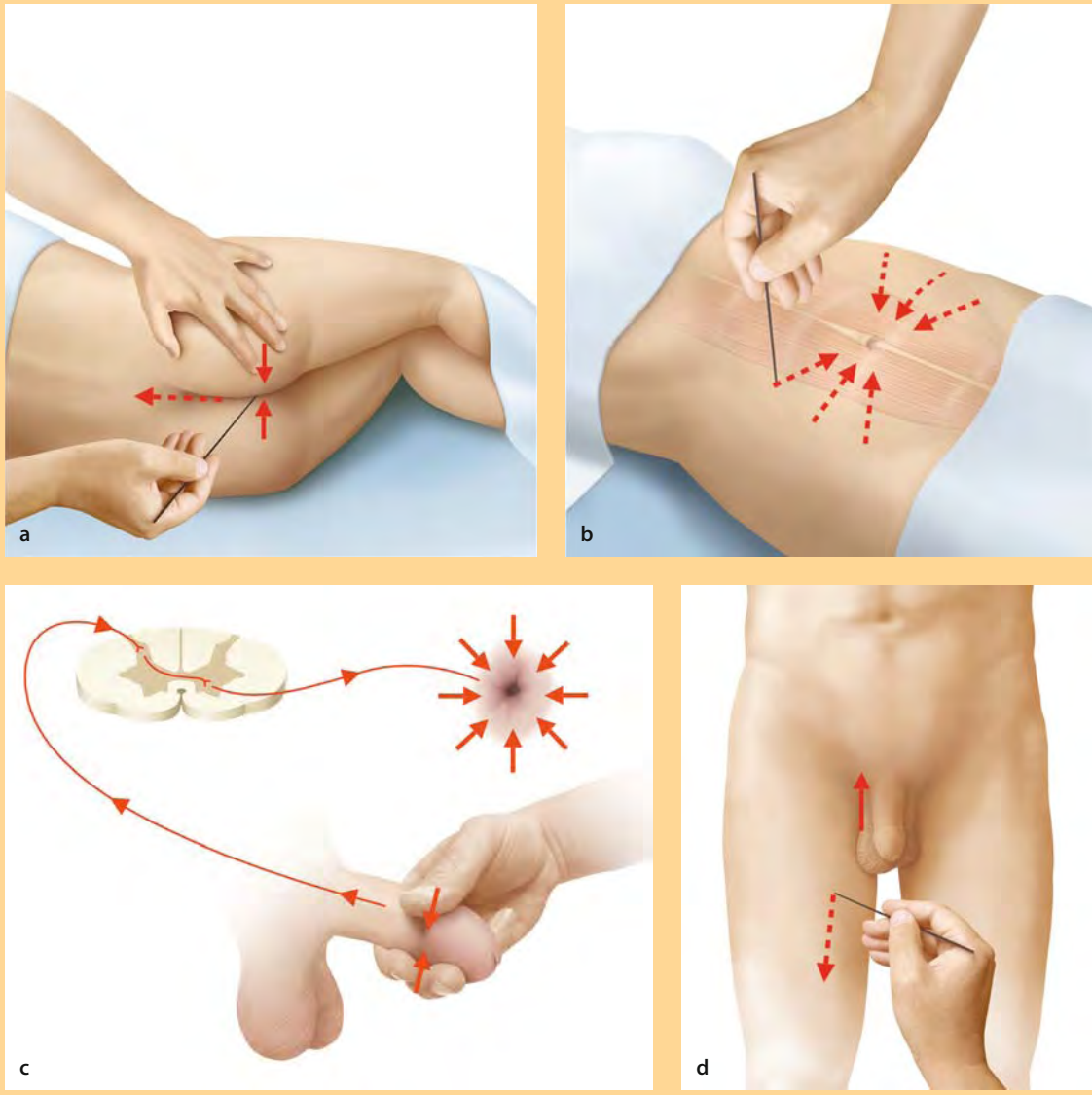


**Figure 4. Polysynaptic reflexes**

a The absence of the **anal reflex** indicates a lesion at S3–5. b Absence of the **abdominal reflex** indicates a lesion at T7–12 (screening test for patients with putative idiopathic scoliosis). c Absence of the **bulbocavernosus reflex** indicates a conus medullaris injury. After acute spinal cord injury, the bulbocavernosus reflex can be elicted within 72 h even in spinal shock in contrast to the lower limb tendon reflexes. Recovery of the bulbocavernosus reflex without sensory or motor function indicates a complete spinal cord lesion. d Absence of the **cremaster reflex** indicates a lesion at the level of L1/2.

## Gait Disorders

Gait disorder should be detailed by questioning and clinical tests. Ataxic gait with increased danger of falls (impaired balance and ability for line walking), need for an enlarged support base, and increased difficulty in walking in darkness are signs of disturbed proprioception. That may be caused (with decreasing frequency) by:

Gait disorders must be thoroughly differentiated

- polyneuropathy
- posterior column disorders
- cerebellar lesion

Several clinical tests can be applied to distinguish between these disorders.

In **polyneuropathy** the most specific finding is a pattern of loss of reflexes and sensory deficit in a distal and **sock like distribution** (below the knee and/or in the area covered by socks) of impaired light touch sensation and reduction of proprioception. The latter is clinically tested by passively moving the foot or toes up and down and asking the blindfolded patient to describe the direction of movement.

The impairment of **dorsal column function** is clinically tested by **Romberg's test**. This test is named after the German neurologist Moritz Heinrich Romberg (1795 – 1873).

**Romberg's test** is performed in two stages:

- First, the patient stands with feet together, **eyes open** and hands by the sides.
- Second, the patient **closes the eyes** while the examiner observes **for a full minute**.

Because the examiner is trying to elicit whether the patient falls when the eyes are closed, it is advisable to stand ready to catch the falling patient. For large patients, a strong assistant is recommended. Romberg's test is **positive** if, and only if, the following two conditions are both met:

- The patient can stand with the eyes open; **and**
- The patient falls when the eyes are closed.

The test **is not positive** if either:

- The patient falls when the eyes are open; **or**
- The patient sways but does not fall when the eyes are closed.

Maintaining balance while standing in the stationary position relies on intact sensory pathways, sensorimotor integration centers and motor pathways.

The main **sensory inputs** are:

- joint position sense (proprioception), carried in the dorsal columns of the spinal cord
- vision

Crucially, the brain can obtain sufficient information to maintain balance if either the visual or the proprioceptive inputs are intact. Sensorimotor integration is carried out by the cerebellum. The first stage of the test (standing with the eyes open) demonstrates that at least one of the two sensory pathways is intact, and that sensorimotor integration and the motor pathway are intact. In the second stage, the visual pathway is removed by closing the eyes. If the proprioceptive pathway is intact, balance will be maintained. But if proprioception is defective, both of the sensory inputs will be absent and the patient will sway then fall. Romberg's test is not a test of cerebellar function, as it is commonly misconceived. Patients with cerebellar ataxia will generally be unable to balance even with the eyes open: therefore, the test cannot proceed beyond the first step and no patient with cerebellar ataxia can correctly be described as *Romberg's positive*. Rather, Romberg's test is sensitive to an affection of the proprioception receptors and pathways caused by sensory peripheral neuropathies (such as polyneuropathy) or disorders of the **dorsal columns of the spinal cord**.

Romberg's test is not a test of cerebellar function

**Unterberger's stepping test** is a simple means of identifying labyrinth dysfunction, which can induce vertigo and dysbalance during walking and standing. During the clinical testing the patient is asked to perform stationary stepping for 1 min with their eyes closed and the arms lifted in front. A positive test is indicated by rotational movement of the patient towards the side of the lesion.

Unterberger's test identifies labyrinth dysfunction

**Cerebellar dysfunction** is clinically searched for by the **heel-to-knee test** and the **finger-to-nose test**. These tests assess dysmetric and ataxic lower and upper

limb control, which is independent from the impairment of the deep sensory system (proprioception). Patients move the right heel to the left knee and then move the heel with contact to the skin along the tibia bone to the ankle, or point with the tip of the index finger to the tip of the nose (with eyes closed and then opened). The performance of a dysmetric and ataxic movement indicates a cerebellar dysfunction which is not completely corrected with open eyes.

The finger-to-nose and heel-to-knee tests screen for cerebellar dysfunction

## Bowel and Bladder Dysfunction

In spinal disorders, bowl and bladder dysfunction are frequently underestimated and patients do not report these problems immediately because they do not realize there is any connection with their spinal problems. Patients have to be **specifically asked for** changes in:

- frequency of micturition
- urgency of voiding
- any kind of urine or bowel incontinence

A detailed history is needed for bladder dysfunction

Asking about **frequency** addresses the question of whether a patient has to visit the bathroom more frequently than they used to. **Urgency** describes whether a patient is able to withhold voiding after the first desire to void or has to visit the bathroom very quickly to avoid incontinence. **Incontinence** can describe a stress incontinence where a physical activity (lifting a heavy object or coughing) that increases the intra-abdominal pressure induces a non-voluntary urine loss or a neurogenic bladder dysfunction with non-voluntary urine loss due to uncontrolled bladder activity (hyperreflexive detrusor). Besides these questions the neurological examination of **sacral segments** is indispensable. After testing the perianal sensitivity for light touch and pinprick (segments S4/S5), the sacral reflexes, **bulbocavernosus reflex** (BCR) and **anal reflex** (AR) have to be examined [5, 104]. Both the BCR and the AR represent the sacral segments S2–S4 (Fig. 4).

Suspected bladder dysfunction should be investigated by urodynamic assessment

It is most important to acknowledge that the function of the bladder (detrusor muscle) cannot be clinically assessed. The clinical diagnosis of urine retention along with the possibility of overflow as a typical finding in an areflexive bladder cannot be reliably distinguished from a reflex bladder activity with incontinence by clinical inspection. Only a full **urodynamic examination** is able to diagnose in detail the bladder function (areflexive versus hyperreflexive detrusor, bladder capacity and compliance) and interaction with the sphincter functions (detrusor sphincter dyssynergia) [29, 76, 103]. The latter test should be considered when the clinical examination shows a pathological finding (sacral motor and reflex disturbance) or the patient describes pathological micturition behavior.

## Disorders of the Autonomic System

Deterioration of **autonomous column and sympathetic fibers** which are conducted through the spinal cord becomes obvious in changed hidrosis. Patients may report skin areas with increased (wheat) or reduced (dry skin) sweating (hidrosis). However, these symptoms have to be specifically explored because patients usually do not report these alterations spontaneously. Areas of reduced sweating can be tested by the so-called **spoon test**: A teaspoon is lightly stroked over the skin. On the line of demarcation between the normal (wheat) and impaired (dry) skin region, the spoon has a reduced friction as the skin with reduced hidrosis shows a lower adhesion [15, 20, 22, 74, 96, 97, 109, 121].

The spoon test indicates areas of altered hidrosis

## Spinal Cord Injury

SCI is assessed according to the ASIA protocol

For spinal cord injury (SCI), the **Standard for Neurological Classification of SCI** (Fig. 2) as developed by the American Spinal Injury Association (**ASIA**) provides a standardized assessment protocol that can be applied in patients with acute and chronic traumatic SCI [67–69].

The ASIA protocol allows important information to be obtained about the level and extent of lesions in a reasonably short time [35, 67, 68]. It is important to acknowledge that assigning one key muscle and one dermatome (defined by a specific point) to represent a single spinal nerve segment is a simplification. However, it could be shown that the ASIA testing allows for a reliable assessment of the level and extent of lesions [73]. The **neurological level** refers to the lowest segment of the spinal cord with normal sensory and motor function. Differentiation between complete (ASIA A) and incomplete SCI (ASIA B–E) is given by the absence (complete) or preservation (incomplete) of any sensory and motor function in the lowest sacral segment (S4/S5).

The ASIA protocol is not approved for non-traumatic SCI

In the ASIA protocol, appreciation of pinprick (algesia) and of light touch (esthesia) is scored semiquantitatively on a three point scale (absent, impaired, normal). The dermatomal key points defined by ASIA help to perform the sensory examination in a standardized form. The involvement of sacral segments is of predictable value for neurological outcome [125].

However, the ASIA protocol is not a suitable tool with which to guide the diagnosis of disorders affecting extraspinal neuronal structures, e.g. polyneuropathy, plexus lesions or other peripheral neurological lesions. Furthermore, it does not enable central lesions of spinal cord and brain disorders to be distinguished.

A pitfall in the diagnostic assessment of SCI is exhibited by the syndrome of **spinal shock**. This initial state of transient depression of spinal cord function below the level of injury is associated with loss of:

- all sensorimotor functions
- flaccid paralysis
- bowel and bladder dysfunction
- abolished tendon reflexes

Spinal shock can last from several days to weeks. The sacral reflexes [bulbocavernosus (BCR) and anal (AR) reflexes] can be reliably assessed within 72 h after injury and can be applied to search for an involvement of the conus medullaris and cauda equina [5, 123] (Fig. 4).

The **neurophysiological examination** enables valid information to be obtained about the functional deficit of the spinal cord at an early time point after SCI (see Chapter 12) [26, 55].

## Spinal Cord Syndrome

Impairment of the intraspinal neural structures, i.e. the myelon and cauda equina, results in typical clinical syndromes. These syndromes may occur with any cause of an incomplete spinal cord lesion and describe by clinical means the primarily affected areas of the spinal cord (Table 3).

- **Brown-Séquard syndrome** (spinal hemisyndrome). This is caused by the deterioration of only half of the spinal cord and results in ipsilateral proprioceptive and motor loss and contralateral loss of pain and temperature perception (dissociated sensitive disorder).
- **central cord syndrome.** This lesion affects the central gray structures of the spinal cord with deterioration of alpha-motoneurons and the crossing

**Table 3.** Spinal cord injury syndromes

| Syndrome | Paresis | Reflexes | | | Sensory function | | Vasomotor dysfunction | Bladder/bowel | Frequent cause |
|---|---|---|---|---|---|---|---|---|---|
| | | Tendon tap | Babinski | AR and BCR | Deep pressure | Pain | | | |
| **Complete lesion** | | | | | | | | | |
| spinal shock | flaccid | – | +/– | + | – | – | + | flaccid | trauma |
| C1–T1 | spastic tetra | ++ | +/– | + | – | – | + | spastic | trauma |
| T2–T12 | spastic para | ++ | +/– | + | – | – | + | spastic | trauma, tumor |
| conus | spastic and/or flabby | (+)– | (+) | – | – | – | – | spastic/flaccid | trauma |
| cauda | flaccid | – | – | – | – | – | – | flaccid | trauma, disc herniation |
| **Incomplete lesion** | | | | | | | | | |
| Brown-Séquard syndrome | spastic hemiparesis | ++ ipsilateral | + ipsilateral | + | – ipsilateral | – contralateral | +/– | –/spastic | trauma |
| central cord syndrome | spastic tetra (flaccid paresis of upper limbs) | ++ | + | + | +/– | – | + | spastic | trauma, cervical stenosis, syrinx, disc herniation, OPLL |
| anterior cord syndrome | flaccid paresis | – | +/– | + | + | – | – | spastic | ischemia |
| posterior cord syndrome | spastic or no paresis | +/++ | +/– | + | – | + | – | spastic | vitamin $B_{12}$ deficiency syndrome |

+ positive, ++ increased, – abolished

segmental spinothalamic fibers. The syndrome occurs most frequently in the cervical region.

- **anterior cord syndrome.** This syndrome refers to the disturbance of the anterior spinal artery with consecutive affection of the anterior part (bilateral) of the cord. Thus, there is loss of motor function and of sensitivity to pain and temperature (ventrolateral column).
- **posterior cord syndrome.** This syndrome occurs relatively seldom in trauma and is more frequently seen in non-traumatic disorders (such as $B_{12}$ deficiency). It produces primarily proprioceptive impairment as a result of impaired posterior column.
- **conus medullaris syndrome.** As a result of a compromise of the conus medullaris (sacral spinal enlargement approximately at the spinal level L1–L2 vertebrae) and/or cauda equina (lumbar nerve roots within the spinal canal), a distinct pattern of bladder-bowel dysfunction and lower limb impairment can be observed. Frequently a clear distinction between conus medullaris and/or cauda equina lesion cannot be achieved. A pure cauda equina lesion presents a remaining areflexive bladder dysfunction with loss of sacral reflexes (BCR and AR) and saddle anesthesia. The lower limbs show a flaccid paresis and in time a severe muscle atrophy. A conus medullaris lesion can present a mixture of flaccid and spastic symptoms of both the bladder and lower limbs depending on the localization within the conus. Impotence accompanies both syndromes. The extent of symptoms depends on the degree of damage (complete or incomplete) of the conus medullaris and cauda equina.

## Differential Diagnosis

### Differentiation of Central and Peripheral Paresis

Spasticity differentiates central and peripheral lesions

The neurological examination should not only confirm if there is any neurological deficit but provide a somatotopic assessment of the location of the lesion. A frequent problem is the **differentiation** between (Table 4):

- central paresis (spastic paresis)
- peripheral paresis (flaccid paresis)

Differentiation between spastic and flaccid paresis allows the distinction of central from peripheral lesions

The differentiation into spastic and flaccid paresis is one of the most significant factors for distinguishing between central and peripheral lesions.

A flaccid paresis indicates reduced or abolished muscle tone, while spastic paresis is described by increased muscle tone with resistance to passive extension, brisk jerks and cloni. The muscle resistance is especially present in fast passive extension and at the start of movement. In the presence of spasticity, the muscle tone should be assessed by the adapted Ashworth score (Table 5) [93, 110, 111].

### Differentiation of Radicular and Peripheral Nerve Lesions

If a peripheral lesion is assumed, differentiation of a radicular and peripheral nerve lesion is required. Differences in the dermatomal area of the roots and peripheral nerves as well as differences in the key muscles may be helpful. However, the sensory examination can be very challenging particularly in elderly and young patients, as well as in patients with impaired consciousness and psychiatric disorders. Also the muscle strength testing depends on the cooperation of the patient and is influenced by pain. The somatotopic relation between nerve root and peripheral nerve is summarized in Tables 6 and 7. Because of the similarity of symptoms, the clinical differentiation between some radicular syndromes and peripheral or plexus lesions can be difficult.

**Table 4.** Clinical differentiation of central and peripheral paresis

| Central paresis | Peripheral paresis |
|---|---|
| • brisk tendon reflexes, muscle cloni | • diminished or absent tendon reflexes |
| • uni- or bilateral increased stretch reflexes and enlarged reflex zones | • reduced or absent polysynaptic reflexes |
| • pathological reflexes (Babinski sign, Gordon and Oppenheimer reflexes), uni- and/or bilateral | • no evidence of pathological reflexes |
| • increased muscle tone | • flaccid muscle tone |
| • para- or hemi-like distribution of motor deficit | • distribution related to peripheral nerve innervation |
| • spinal lesions from C1 to L1 (conus medullaris) | • lesions below L2 |

**Table 5.** Assessment of spasticity

| Ashworth score | Degree of muscle tone |
|---|---|
| 0 | • no increase in muscle tone |
| 1 | • slight increase in muscle tone, manifested by a catch and release or by minimal resistance at the end of the range of motion when the affected part(s) is moved in flexion or extension |
| 2 | • slight increase in muscle tone, manifested by a catch, followed by minimal resistance throughout the reminder (less than half) of the ROM |
| 3 | • more marked increase in muscle tone through most of the ROM, but affected part(s) easily moved |
| 4 | • considerable increase in muscle tone passive, movement difficult |
| 5 | • affected part(s) rigid in flexion or extension |

**Table 6.** Peripheral and segmental innervation of upper extremity muscles

| | Peripheral innervation | Segmental innervation |
|---|---|---|
| **Muscles of the shoulder** | | |
| trapezius | • accessory n. | • C3–4 |
| latissimus dorsi | • thoracodorsal n. | • C6–8 |
| rhomboids | • dorsal scapular n. | • C5 |
| levator scapulae | • dorsal scapular n. | • C3–5 |
| serratus posterior (superior and inferior) | • thoracic n.s | • T1–12 |
| deltoideus | • axillary n. | • C5–6 |
| supraspinatus | • suprascapular n. | • C4–6 |
| infraspinatus | • suprascapular n. | • C4–6 |
| teres minor | • axillary n. | • C5–6 |
| teres major | • subscapular n. | • C5–6 |
| subscapularis | • subscapular n. | • C5–6 |
| **Muscles of the arm** | | |
| biceps brachii | • musculocutaneous n. | • C5–7 |
| brachialis | • musculocutaneous n. | • C5–7 |
| coracobrachialis | • musculocutaneous n. | • C5–7 |
| triceps brachii | • radial n. | • C7–8 |
| anconeus | • radial n. | • C7–8 |
| pronator teres | • median n. | • C6–7 |
| flexor carpi radialis | • median n. | • C6–7 |
| palmaris longus | • median n. | • C6–7 |
| flexor digitorum superficialis | • median n. | • C7–T1 |
| flexor carpi ulnaris | • ulnar n. | • C8–T1 |
| flexor digitorum profundus | • ulnar n. (ulnar side)<br>• median n. (radial side) | • C8–T1 |
| flexor pollicis longus | • anterior interosseous branch of median n. | • C8–T1 |
| pronator quadratus | • anterior interosseous branch of median n. | • C8–T1 |
| brachioradialis | • radial n. | • C5–6 |
| extensor carpi radialis longus | • radial n. | • C6–7 |
| extensor carpi radialis brevis | • radial n. | • C6–7 |
| extensor digitorum | • deep branch of radial n. | • C6–8 |
| extensor digiti minimi | • deep branch of radial n. | • C6–8 |
| extensor carpi ulnaris | • deep branch of radial n. | • C6–8 |
| extensor pollicis longus | • deep branch of radial n. | • C6–8 |
| extensor indicis longus | • deep branch of radial n. | • C6–8 |
| abductor pollicis longus | • deep branch of radial n. | • C6–8 |
| extensor pollicis brevis | • deep branch of radial n. | • C6–8 |
| supinator muscle | • deep branch of radial n. | • C6 |
| **Muscles of the hand** | | |
| palmaris brevis | • superficial branch of ulnar n. | • C8–T1 |
| abductor pollicis brevis | • median n. | • C8–T1 |
| opponens pollicis | • median n. | • C8–T1 |
| flexor pollicis brevis | • median n. (superficial head)<br>• ulnar n. (deep head) | • C8–T1 |
| adductor pollicis | • deep palmar branch of ulnar n. | • C8–T1 |
| lumbricales | • median n. (1st and 2nd)<br>• ulnar n. (3rd and 4th) | • C8–T1 |
| abductor digiti minimi | • deep palmar branch of ulnar n. | • C8–T1 |
| flexor digiti minimi brevis | • deep palmar branch of ulnar n. | • C8–T1 |
| opponens digiti minimi | • deep palmar branch of ulnar n. | • C8–T1 |
| palmaris brevis | • deep palmar branch of ulnar n. | • C8–T1 |
| interosseous | • deep palmar branch of ulnar n. | • C8–T1 |

According to Sobotta [113]

**Table 7.** Peripheral and segmental innervation of lower extremity muscles

| | Peripheral innervation | Segmental innervation |
|---|---|---|
| **Muscles of the hip and thigh** | | |
| iliopsoas | • muscular branch of the lumbar plexus | • L1–4 |
| sartorius | • femoral n. | • L2–3 |
| quadriceps | • femoral n. | • L2–4 |
| pectineus | • femoral n. | • L2–4 |
| adductor longus | • anterior branch of obturator n. | • L2–4 |
| adductor brevis | • anterior branch of obturator n. | • L2–4 |
| gracilis | • anterior branch of obturator n. | • L2–4 |
| obturator externus | • anterior branch of obturator n. | • L3–4 |
| adductor magnus | • posterior branch of obturator n.<br>• tibial part of sciatic n. | • L2–4<br>• L4–S1 |
| gluteus maximus | • inferior gluteal n. | • L5–S1 |
| gluteus medius | • superior gluteal n. | • L4–S1 |
| gluteus minimus | • superior gluteal n. | • L4–S1 |
| tensor fascia lata | • superior gluteal n. | • L4–S1 |
| piriformis | • 1st and 2nd sacral n.s | • S1–2 |
| obturatus internus | • n. to obturator internus | • L5–S2 |
| gemelli | • n. to obturator internus | • L5–S2 |
| quadratus femoris | • n. to quadratus femoris | • L5–S2 |
| **Muscles of the leg** | | |
| biceps femoris | • tibial portion of the sciatic n. (long head)<br>• peroneal portion of the sciatic n. (short head) | • S1–3<br>• L5–S2 |
| semitendinosus | • tibial portion of the sciatic n. | • L5–S2 |
| semimembranosus | • tibial portion of the sciatic n. | • L5–S2 |
| tibialis anterior | • deep peroneal n. | • L4–S1 |
| extensor hallucis longus | • deep peroneal n. | • L4–S1 |
| extensor digitorum longus | • deep peroneal n. | • L4–S1 |
| triceps surae | • tibial n. | • S1–2 |
| soleus | • tibial n. | • S1–2 |
| plantaris | • tibial n. | • S1–2 |
| popliteus | • tibial n. | • L4–S1 |
| tibialis posterior | • tibial n. | • L5–S1 |
| flexor digitorum longus | • tibial n. | • L5–S1 |
| flexor hallucis longus | • tibial n. | • L5–S1 |
| peroneus longus | • superficial peroneal n. | • L4–S1 |
| peroneus brevis | • superficial peroneal n. | • L4–S1 |
| **Muscles of the foot** | | |
| extensor digitorum brevis | • deep peroneal n. | • L5–S1 |
| extensor hallucis brevis | • deep peroneal n. | • L5–S1 |
| abductor hallucis | • medial plantar n. | • L5–S1 |
| flexor hallucis | • medial plantar n. | • L5–S1 |
| adductor hallucis | • lateral plantar n. | • S2–3 |
| abductor digiti minimi | • lateral plantar n. | • S2–3 |
| flexor digiti minimi | • lateral plantar n. | • S2–3 |
| opponens digiti minimi | • lateral plantar n. | • S2–3 |
| flexor digitorum brevis | • medial plantar n. | • L5–S1 |
| quadratus plantae | • lateral plantar n. | • S2–3 |
| interossei | • lateral plantar n. | • S1–2 |

According to Sobotta [113]

## Radiculopathies

The clinical presentations of the radicular syndromes are summarized in Table 8.

The exact differentiation between radicular and peripheral nerve damage may demand neurophysiological studies, i.e. EMG to show denervation of root- and/or nerve-specific muscles as well as neurography to exclude conduction delay of the peripheral nerve. **Entrapment syndromes** are an important differential diagnosis of radicular lesions. Knowledge of the characteristic symptoms is mandatory (Table 9).

### *C5 Radiculopathy*

In contrast to an isolated lesion of the **musculocutaneous nerve**, a C5 lesion causes not only a paresis of the biceps muscle, but also of the scapular muscle

**Table 8.** Radicular syndromes and differential diagnosis

| Root | Dermatome | Muscle | Reflex | Important differential diagnoses |
|---|---|---|---|---|
| C1–4 | • neck and collar | • neck muscles<br>• diaphragm (paradoxic abdominal muscle movements) | – | • lung carcinoma<br>• neuritis of brachial plexus<br>• lymphoma<br>• thymome |
| C5 | • lateral shoulder | • deltoid muscle | • biceps reflex | • frozen shoulder<br>• Erb's palsy<br>• neuralgic amyotrophy of the shoulder<br>• palsy of axillary nerve |
| C6 | • lateral arm and thumb | • extensors of hand, flexors of elbow | • biceps reflex<br>• brachioradial reflex | • carpal tunnel syndrome<br>• radial nerve palsy<br>• musculocutaneous nerve palsy |
| C7 | • dorsum of shoulder and arm into the long finger | • triceps, wrist flexors, finger extensors | • triceps reflex | • palsy of posterior interosseus nerve, brachial plexus paralysis (middle part) |
| C8–T1 | • medial arm into ulnar two digits | • intrinsic hand muscles | • Trömner's reflex | • palsy of anterior interosseus nerve<br>• brachial plexus paralysis (Klumpke type)<br>• thoracic outlet syndrome<br>• ulnar palsy |
| L2 | • inguinal ligament | • iliopsoas | • cremaster reflex | • femoral palsy<br>• hip osteoarthritis<br>• pelvic disorder (i.e. psoas muscle) |
| L3 | • medial femoral and knee | • femoral adductors, vastus medialis of quadriceps muscle | • adductor reflex | • paralysis of obturator nerve<br>• pelvic disorder (aseptic necrosis of symphysis)<br>• hip osteoarthritis |
| L4 | • lateral femoral and medial shank | • vastus lateralis of quadriceps muscle | • patellar reflex | • paralysis of femoral nerve |
| L5 | • lateral shank | • tibialis anterior muscle | • tibialis posterior reflex | • peroneal paralysis |
| S1 | • dorsal shank, along heel into fifth digit of foot | • gastrocnemius muscle | • Achilles tendon reflex | • tibial paralysis<br>• tarsal tunnel syndrome |
| S2 | • dorsal femoral | • ischiocrural muscles | • biceps femoris reflex | • sciatic pain syndrome |
| S3 | • proximal medial femoral | • bulbocavernosus muscle and anal sphincter | • bulbocavernosus and anal reflex | • palsy of cutaneus posterior femoral nerve (sacral plexus) |
| S4–5 | • perineum | • bulbocavernosus muscle and anal sphincter | • bulbocavernosus and anal reflex | • palsy of clunium medii<br>• palsy of anococcygei nerves (coccygeal plexus) |

**Table 9.** Frequent entrapment syndromes

| Syndrome | Findings |
|---|---|
| Carpal tunnel syndrome | • pain of hand and forearm, frequently at night (antebrachialgia nocturna)<br>hypesthesia of digits 1 to 3 including the radial side of digit 4<br>paresis and atrophy of the thenar muscles<br>positive Tinnel sign over the carpal tunnel |
| Sulcus ulnaris syndrome | • numbness of digits 4 and 5<br>paretic intrinsic hand muscles and hypothenar muscles<br>positive Tinnel sign over the ulnar sulcus |
| Thoracic outlet syndrome | • paresis of the intrinsic hand muscles<br>worsening of symptoms by elevating the shoulder<br>frequently associated with cervical rip or ligamental hypertrophy<br>pain of hand and forearm |
| Fibularis syndrome | • paretic foot elevation<br>numbness of the dorsal foot<br>often history of repeating pressure over the fibular caput |
| Tarsal tunnel syndrome | • paresis of short foot muscles<br>numbness of the plantar foot<br>atrophy of abductor hallucis muscle |

group (supra- and infraspinatus, teres major and minor muscles). The sensory deficits of a C5 radiculopathy are located at the posterolateral upper arm while the musculocutaneous nerve also innervates the ventral aspects (see Chapter 8).

### *C6 Radiculopathy*

The sensory deficits in a C6 lesion may mimic median nerve lesion. However, in median nerve lesion neither is the biceps tendon reflex (BTR) diminished nor the biceps muscle paretic. Similarly, the middle finger is typically not involved in a C6 hypesthesia but in a median nerve lesion.

### *C8/T1 Radiculopathy*

This radiculopathy must be distinguished from an **ulnar nerve lesion**. In C8/T1 radiculopathy, the ulnar side of the forearm is hypesthesic and all intrinsic hand muscles are affected. The ulnar nerve is mostly compressed within the sulcus, resulting in paresis of the hypothenar and only those intrinsic hand muscles innervated by the ulnar nerve. The sensory deficit affects the two ulnar fingers.

### *L3/4 Radiculopathy*

In a neuropathy of the **femoral nerve** and in L3/4 radiculopathy, the patellar tendon reflex (PTR) is reduced or abolished with a predominant weakness of the quadriceps muscles. However, detailed testing in femoral nerve neuropathy shows a sensory deficit restricted to the ventral aspect of the thigh with paralysis of hip flexion (iliopsoas muscle) while in L3/4 radiculopathy the sensory deficit is extended to the medial site and below the knee with weakness of the thigh adduction (adductor muscles).

### *L5 Radiculopathy*

Paresis of foot elevation can be due to a L5 radiculopathy and/or a lesion of the peroneal nerve (see Chapter 8, Case Introduction). Clinical differentiation is

possible by proving the hip abduction, which is also affected in a L5 radiculopathy with weakness of the gluteal muscles (gluteus medius, tensor fasciae latae).

### *S1 Radiculopathy*

In suspected S1 radiculopathy, damage of the **tibial nerve**, e.g. tibial tunnel syndrome or partial sciatic lesion, has to be excluded. While S1 radiculopathy is signaled by diminished Achilles tendon reflex and weak foot extension, the tibial nerve affection involves the toe and ankle extensor muscles while the peroneal nerve lesion shows paresis of the toe and ankle flexor muscles.

## Differential Diagnosis of Spinal Cord Compression Syndromes

This group of syndromes is due to obliteration of the spinal canal resulting in compression of the neural structures. Both cervical and lumbar stenosis frequently originate from degenerative (secondary) changes of the spine. Also a congenitally narrow spinal canal (primary spinal canal stenosis) can be present, which exposes the patient to an increased risk of compression syndromes and a greater danger of neuronal damage in minor spine trauma. In Asian people (e.g. Japanese individuals), an ossified posterior longitudinal ligament (OPLL) can cause spinal cord compression, which is only rarely described in Caucasian people. Although all compression syndromes present with distinct symptoms, differential diagnosis from other disorders is mandatory in equivocal cases (Table 10).

**Table 10.** Spinal cord compression syndromes

| Compression syndrome | Symptoms | Differential diagnosis |
|---|---|---|
| Cervical stenosis | • clumsy painful hands<br>• disturbed fine motor skills<br>• imbalance of gait<br>• numb feet<br>• urinary urgency | • multiple sclerosis<br>• Myelitis<br>• $B_{12}$ hypovitaminosis<br>• spinal tumors<br>• polyneuropathy (PNP)<br>• arteriovenous malformations |
| Thoracic stenosis | • lower limb sensory deficit<br>• thoracic sensory level<br>• spastic paraparesis<br>• bladder-bowel dysfunction | • disc herniation (often calcified)<br>• OPLL<br>• arteriovenous malformations<br>• spinal tumors |
| Lumbar stenosis | • tired legs and weakness on walking<br>• lumbar pain on walking<br>• pain relief during sitting, lying and forward bending | • vascular claudication<br>• spinal metastasis<br>• polyneuropathy |
| Cauda equina syndrome | • severe leg pain<br>• flaccid paraparesis<br>• sensory loss of legs<br>• urinary and bowel incontinence<br>• saddle anesthesia | • cauda equina radiculitis (Elsberg's syndrome)<br>• lesion of pelvic plexus |

## Miscellaneous Differential Diagnoses

### Neurovascular Disorders

Non-traumatic acute paraplegia may be due to spinal ischemic or hemorrhagic disorders. Typically, the first symptom is girdle-like pain in the dermatome referring to the involved level. Thereafter, motor paresis and sensory deficits appear, mostly within minutes to a few hours. A very special but not so uncommon disor-

Girdle-like pain may be an initial symptom of a spinal ischemic or hemorrhagic disorder

der is the spinal decompression syndrome, which can be seen in scuba divers. When the time requirement for decompression after deep diving is not adequately followed (decompression sickness), microembolisms of non-resolved nitrogen gas emboli can obstruct small branches of the anterior spinal artery and cause a spinal ischemia. This can induce an anterior/central cord syndrome or even complete SCI and represents one of the most serious complications in diving [2, 19, 57, 59, 87]. In contrast hemorrhagic disorders are mostly based on arteriovenous malformation or spontaneous spinal bleeding in patients with anticoagulation treatment and often result in complete paraplegia.

### Neurodegenerative Disorders

Neurodegenerative disorders can be easily confused with spinal disorders particularly in the early stages

Based on its frequency, **multiple sclerosis** is the most important differential diagnosis in suspected disorder of the spinal cord. Increased reflexes, ataxia, numbness and paresis of limbs and bladder dysfunction can occur in both multiple sclerosis and myelopathy. However, the presence of MRI signal changes (white spots in T2 weighted images) in the brain and of the spinal cord without or with only minor spinal cord compression indicating neurodegenerative-immunologic disorders should be taken into the differential diagnosis. The definitive differential diagnosis demands further diagnostics, particularly the examination of evoked potentials and the CSF [14, 50, 52, 63, 94].

Also very rare neurodegenerative disorders, e.g. **amyotrophic lateral sclerosis** (ALS), in combination with minor degenerative spinal disorders can potentially mimic a spinal disorder.

### Inflammatory Disorders

A number of infectious diseases can be associated with myelitis. Various viruses, i.e. herpes virus, human immune deficiency virus or poliomyelitis, may affect the spinal cord, roots or peripheral nerves. With regard to the opportunities for therapy, the diagnosis of a bacterial or viral infection of the spinal cord is particularly important. Inflammatory disorders are often associated with systemic signs of infection such as fever or respiratory infection and can show cutaneous efflorescences particularly in herpes zoster infection (Case Introduction). In patients with assumed herpes zoster infection, immediate treatment with antiviral medication (acyclovir) is recommended.

## Recapitulation

**Epidemiology.** Even though neurological symptoms in spinal disorders are not frequent, the neurological examination is most important for the planning of further diagnostic assessments and therapy. In contrast to patients with traumatic spinal disorders, who are mainly young patients suffering from non-traumatic spinal disorders, most patients are elderly. The most frequently involved nerve roots are C5, C6, L5 and S1. In SCI about 45 % of patients suffer from tetraplegia.

**Classification.** Neurological symptoms should be related to the involved neural structures and differentiate lesions of the central and peripheral nervous system. Depending on the impaired spinal segments, spinal cord injury is classified as paraplegia or tetraplegia and complete or incomplete.

**Pathogenesis.** Traumatic and non-traumatic spinal lesions are distinguished while the neurological symptoms are non-specific to the cause of lesion. Therefore, in spinal disorders with unknown pathology, a broad differential diagnosis has to be considered. In patients with acute onset of symptoms, spinal, radicular and peripheral nerve disorders should be distinguished.

**Clinical presentation.** The **medical history** focuses on the time of onset and duration of actual complaints, dependence on physical activities as well as other disorders that might impact spinal cord function. Radicular and peripheral lesions mostly cause localized pain, muscle paresis and sensory disorders in the related dermatomes. In contrast, deterioration of spinal cord function results in more bilateral and complex symptoms (impaired upper limb – hand function, gait disorder, bladder and bowl dysfunction). Duration of symptoms is important for the definition of etiology and urgency of therapy (e.g. cauda equina syndrome). While acute traumatic disorders are most obviously degenerative, metabolic and infectious diseases have be considered carefully.

**Neurological examination.** In spinal disorders it is absolutely mandatory to exclude any neurological lesions. Depending on the neurological deficit, further diagnostic assessments should be initiated. To assure a timely and thorough assessment, the clinical examination has to follow an appointed algorithm.
After observing the **gait**, **proprioceptive reflexes** and **pathologic reflexes** have to be assessed. In peripheral lesions, proprioceptive reflexes are absent or diminished, while in central lesions they might be increased (cave: spinal shock). Pathological reflexes indicate central (spinal and supraspinal) lesions. **Motor strength** is subdivided into six grades (M0 – M5), and key muscles both for radicular and spinal lesions should be examined. The **muscle tonus** has to be tested to differentiate spasticity (modified Ashworth scale 1 – 5) from flabby paresis. Subsequently, a **sensory examination** for touch and pinprick sensation is performed. Impairment of posterior column is diagnosed by assessing the sense of vibration. Deterioration of **sympathetic fibers** appears in changed hidrosis. In every case with or without complained of bladder or bowel dysfunction, the **sacral segments** have to be examined. However, the neurological examination is not sensitive to the assessment of autonomic disorders (bladder, bowl, sexual and cardiovascular dysfunction). In SCI the ASIA protocol enables the neurological examination to be performed in a standardized form. Further neurological tests depend on the results of the clinical examination (detailed examination of hand function, exclusion of cerebral damage, peripheral nerve lesion, etc.).

## Key Articles

**Maynard FM, Jr, Bracken MB, Creasey G, Ditunno JF, Jr, Donovan WH, Ducker TB, et al. (1997) International Standards for Neurological and Functional Classification of Spinal Cord Injury. American Spinal Injury Association. Spinal Cord 35(5):266 – 74**
This article describes the internationally standardized classification of a neurological deficit after a traumatic spinal cord injury to score the extent (complete–incomplete) and level of the spinal cord damage. It is the standard used in almost all SCI studies since 1996.

**Siddall PJ, Loeser JD (2001) Pain following spinal cord injury. Spinal Cord 39(2):63 – 73**
For the distinction of the frequently present different pain syndromes after SCI, the paper presents the first internationally accepted clinical algorithm to qualify the complained of pain and to distinguish the potential different causes.

**Priebe MM, Sherwood AM, Thornby JI, Kharas NF, Markowski J (1996) Clinical assessment of spasticity in spinal cord injury: a multidimensional problem. Arch Phys Med Rehabil 77(7):713 – 6**
The clinical description and quantification of spasticity in SCI can be semiquantitatively documented by a standardized score and allows for monitoring changes over time.

**Vroomen PC, de Krom MC, Wilmink JT, Kester AD, Knottnerus JA (2002) Diagnostic value of history and physical examination in patients suspected of lumbosacral nerve root compression. J Neurol Neurosurg Psychiatry 72(5):630 – 4**
This paper demonstrates that the medical history provided by the patient about the onset and characteristics of radicular pain is of highest value for the diagnosis of a lumbar-sacral nerve root compression. The study outlines that clinical tests and neuro-imagine provide additional information but are only relevant in combination with a thoroughly taken medical history.

**Verbiest H (1954) A radicular syndrome from developmental narrowing of the lumbar vertebral canal. J Bone Joint Surg 36:230 – 237**
Landmark paper describing the clinical characteristics of the neurogenic claudication due to lumbar spinal canal stenosis.

## References


1. Aguirre-Quezada DE, Martinez-Anda JJ, Aguilar-Ayala EL, Chavez-Macias L, Olvera-Rabiela JE (2006) Intracranial and intramedullary peripheral nerve sheath tumours. Case reports from 20 autopsies. Rev Neurol 43(4):197 – 200
2. Aito S, D'Andrea M, Werhagen L (2005) Spinal cord injuries due to diving accidents. Spinal Cord 43(2):109 – 16
3. Alvarez JA, Hardy RH Jr (1998) Lumbar spine stenosis: A common cause of back and leg pain. Am Fam Physician 57(8):1825, 1834, 1839 – 40
4. Alvarez L, Alcaraz M, Perez-Higueras A, Granizo JJ, de Miguel I, Rossi RE, et al. (2006) Percutaneous vertebroplasty: Functional improvement in patients with osteoporotic compression fractures. Spine 31(10):1113 – 8
5. Amarenco G, Bayle B, Ismael SS, Kerdraon J (2002) Bulbocavernosus muscle responses after suprapubic stimulation: Analysis and measurement of suprapubic bulbocavernosus reflex latency. Neurourol Urodyn 21(3):210 – 3
6. Amundsen T, Weber H, Lilleas F, Nordal HJ, Abdelnoor M, Magnaes B (1995) Lumbar spinal stenosis. Clinical and radiologic features. Spine 20(10):1178 – 86
7. Andersson GB (1999) Epidemiological features of chronic low-back pain. Lancet 354(9178):581 – 5
8. Atroshi I, Gummesson C, Johnsson R, Ornstein E, Ranstam J, Rosen I (1999) Prevalence of carpal tunnel syndrome in a general population. JAMA 282(2):153 – 8
9. Atroshi I, Gummesson C, Johnsson R, Ornstein E, Ranstam J, Rosen I (2000) Prevalence for clinically proved carpal tunnel syndrome is 4 percent. Lakartidningen 97(14):1668 – 70
10. Barker E, Saulino MF (2002) First-ever guidelines for spinal cord injuries. RN 65(10):32 – 7
11. Beck DW, Lovick DS (2005) Age and lumbar surgery. J Neurosurg Spine 3(6):507; author reply 507 – 8
12. Bensch FV, Koivikko MP, Kiuru MJ, Koskinen SK (2006) The incidence and distribution of burst fractures. Emerg Radiol 12(3):124 – 9
13. Bird SJ, Brown MJ, Spino C, Watling S, Foyt HL (2006) Value of repeated measures of nerve conduction and quantitative sensory testing in a diabetic neuropathy trial. Muscle Nerve 34(2):214 – 24
14. Borhani-Haghighi A, Samangooie S, Ashjazadeh N, Nikseresht A, Shariat A, Yousefipour G, et al. (2006) Neurological manifestations of Behçet's disease. Saudi Med J 27(10):1542 – 6
15. Bors E (1964) Simple methods of examination in paraplegia: I. The spoon test. Paraplegia 105:17 – 9
16. Bovim G, Schrader H, Sand T (1994) Neck pain in the general population. Spine 19(12): 1307 – 9
17. Bruneau M, Cornelius JF, George B (2006) Microsurgical cervical nerve root decompression by anterolateral approach. Neurosurgery 58(1 Suppl):ONS108,13; discussion ONS108 – 13
18. Calancie B, Molano MR, Broton JG (2004) Tendon reflexes for predicting movement recovery after acute spinal cord injury in humans. Clin Neurophysiol 115(10):2350 – 63
19. Carod-Artal FJ, Vilela-Nunes S, Fernandes-da Silva TV (2003) Acute myelopathy in a diver caused by decompression sickness. A case description and a survey of the literature. Rev Neurol 36(11):1040 – 4
20. Chemmanam T, Pandian JD, Kadyan RS, Bhatti SM (2007) Anhidrosis: A clue to an underlying autonomic disorder. J Clin Neurosci 14:94 – 96
21. Cheung G, Chow E, Holden L, Vidmar M, Danjoux C, Yee AJ, et al. (2006) Percutaneous vertebroplasty in patients with intractable pain from osteoporotic or metastatic fractures: A prospective study using quality-of-life assessment. Can Assoc Radiol J 57(1):13 – 21
22. Chou SH, Kao EL, Lin CC, Chang YT, Huang MF (2006) The importance of classification in sympathetic surgery and a proposed mechanism for compensatory hyperhidrosis: Experience with 464 cases. Surg Endosc 20(11):1749 – 53
23. Chung SG, Van Rey EM, Bai Z, Rogers MW, Roth EJ, Zhang LQ (2005) Aging-related neuromuscular changes characterized by tendon reflex system properties. Arch Phys Med Rehabil 86(2):318 – 27
24. Ciol MA, Deyo RA, Howell E, Kreif S (1996) An assessment of surgery for spinal stenosis: Time trends, geographic variations, complications, and reoperations. J Am Geriatr Soc 44(3):285 – 90
25. Curt A, Dietz V (1996) Neurographic assessment of intramedullary motoneurone lesions in cervical spinal cord injury: Consequences for hand function. Spinal Cord 34(6):326 – 32
26. Curt A, Dietz V (1999) Electrophysiological recordings in patients with spinal cord injury: Significance for predicting outcome. Spinal Cord 37(3):157 – 65
27. de Krom MC, Knipschild PG, Kester AD, Spaans F (1990) Efficacy of provocative tests for diagnosis of carpal tunnel syndrome. Lancet 335(8686):393 – 5
28. de Krom MC, Knipschild PG, Kester AD, Thijs CT, Boekkooi PF, Spaans F (1992) Carpal tunnel syndrome: Prevalence in the general population. J Clin Epidemiol 45(4):373 – 6

29. Denys P, Corcos J, Everaert K, Chartier-Kastler E, Fowler C, Kalsi V, et al. (2006) Improving the global management of the neurogenic bladder patient: Part I. The complexity of patients. Curr Med Res Opin 22(2):359 – 65
30. DeVivo MJ, Go BK, Jackson AB (2002) Overview of the national spinal cord injury statistical center database. J Spinal Cord Med 25(4):335 – 8
31. Deyo RA, Weinstein JN (2001) Low back pain. N Engl J Med 344(5):363 – 70
32. Dyck PJ, Kratz KM, Karnes JL, Litchy WJ, Klein R, Pach JM, et al. (1993) The prevalence by staged severity of various types of diabetic neuropathy, retinopathy, and nephropathy in a population-based cohort: The Rochester Diabetic Neuropathy Study. Neurology 43(4): 817 – 24
33. Egli D, Hausmann O, Schmid M, Boos N, Dietz V, Curt A (2007) Lumbar spinal stenosis: assessment of cauda equina involvement by electrophysiological recordings. J Neurol 254:741 – 50
34. Ekong CE, Tator CH (1985) Spinal cord injury in the work force. Can J Surg 28(2):165 – 7
35. El Masry WS, Tsubo M, Katoh S, El Miligui YH, Khan A (1996) Validation of the American Spinal Injury Association (ASIA) motor score and the National Acute Spinal Cord Injury Study (NASCIS) motor score. Spine 21(5):614 – 9
36. Engsberg JR, Lauryssen C, Ross SA, Hollman JH, Walker D, Wippold FJ, 2nd (2003) Spasticity, strength, and gait changes after surgery for cervical spondylotic myelopathy: A case report. Spine 28(7):E136 – 9
37. Er U, Yigitkanli K, Simsek S, Adabag A, Bavbek M (2006) Spinal intradural extramedullary cavernous angioma: Case report and review of the literature. Spinal Cord Nov 7
38. Ernst CW, Stadnik TW, Peeters E, Breucq C, Osteaux MJ (2005) Prevalence of annular tears and disc herniations on MR images of the cervical spine in symptom free volunteers. Eur J Radiol 55(3):409 – 14
39. Farmer JC, Vaccaro AR, Balderston RA, Albert TJ, Cotler J (1998) The changing nature of admissions to a spinal cord injury center: Violence on the rise. J Spinal Disord 11(5):400 – 3
40. Fehlings MG, Perrin RG (2006) The timing of surgical intervention in the treatment of spinal cord injury: A systematic review of recent clinical evidence. Spine 31(11 Suppl):S28, 35; discussion S36
41. Finnerup NB, Gyldensted C, Fuglsang-Frederiksen A, Bach FW, Jensen TS (2004) Sensory perception in complete spinal cord injury. Acta Neurol Scand 109(3):194 – 9
42. Fisher CG, Noonan VK, Dvorak MF (2006) Changing face of spine trauma care in North America. Spine 31(11 Suppl):S2,8; discussion S36
43. Fleuren JF, Nederhand MJ, Hermens HJ (2006) Influence of posture and muscle length on stretch reflex activity in poststroke patients with spasticity. Arch Phys Med Rehabil 87(7):981 – 8
44. Gerber DE, Grossman SA (2006) Does decompressive surgery improve outcome in patients with metastatic epidural spinal-cord compression? Nat Clin Pract Neurol 2(1):10 – 1
45. Gin H, Perlemoine C, Rigalleau V (2006) How to better systematize the diagnosis of neuropathy? Diabetes Metab 32(4):367 – 72
46. Guihan M, Bosshart HT, Nelson A (2004) Lessons learned in implementing SCI clinical practice guidelines. SCI Nurs 21(3):136 – 42
47. Gummesson C, Atroshi I, Ekdahl C, Johnsson R, Ornstein E (2003) Chronic upper extremity pain and co-occurring symptoms in a general population. Arthritis Rheum 49(5):697 – 702
48. Hale JJ, Gruson KI, Spivak JM (2006) Laminoplasty: A review of its role in compressive cervical myelopathy. Spine J 6(6 Suppl):S289 – 98
49. Hanley MA, Masedo A, Jensen MP, Cardenas D, Turner JA (2006) Pain interference in persons with spinal cord injury: Classification of mild, moderate, and severe pain. J Pain 7(2):129 – 33
50. Hauser SL, Oksenberg JR (2006) The neurobiology of multiple sclerosis: Genes, inflammation, and neurodegeneration. Neuron 52(1):61 – 76
51. Hayes KC, Wolfe DL, Hsieh JT, Potter PJ, Krassioukov A, Durham CE (2002) Clinical and electrophysiologic correlates of quantitative sensory testing in patients with incomplete spinal cord injury. Arch Phys Med Rehabil 83(11):1612 – 9
52. Hoenig H, McIntyre L, Hoff J, Samsa G, Branch LG (1999) Disability fingerprints: Patterns of disability in spinal cord injury and multiple sclerosis differ. J Gerontol A Biol Sci Med Sci 54(12):M613 – 20
53. Hori T, Kawaguchi Y, Kimura T (2006) How does the ossification area of the posterior longitudinal ligament progress after cervical laminoplasty? Spine 31(24):2807 – 12
54. Hornby TG, Kahn JH, Wu M, Schmit BD (2006) Temporal facilitation of spastic stretch reflexes following human spinal cord injury. J Physiol 571(3):593 – 604
55. Iseli E, Cavigelli A, Dietz V, Curt A (1999) Prognosis and recovery in ischaemic and traumatic spinal cord injury: Clinical and electrophysiological evaluation. J Neurol Neurosurg Psychiatry 67(5):567 – 71
56. Jackson AB, Dijkers M, Devivo MJ, Poczatek RB (2004) A demographic profile of new traumatic spinal cord injuries: Change and stability over 30 years. Arch Phys Med Rehabil 85(11):1740 – 8

57. Jallul S, Osman A, El-Masry W (2007) Cerebro-spinal decompression sickness: Report of two cases. Spinal Cord 45:116 – 120
58. Karabatsou K, Sinha A, Das K, Rainov NG (2006) Nontraumatic spinal epidural hematoma associated with clopidogrel. Zentralbl Neurochir Nov 14
59. Korres DS, Benetos IS, Themistocleous GS, Mavrogenis AF, Nikolakakos L, Liantis PT (2006) Diving injuries of the cervical spine in amateur divers. Spine J 6(1):44 – 9
60. Kostova V, Koleva M (2001) Back disorders (low back pain, cervicobrachial and lumbosacral radicular syndromes) and some related risk factors. J Neurol Sci 192(1 – 2):17 – 25
61. Krasny C, Tilscher H, Hanna M (2005) Neck pain: functional and radiological findings compared with topical pain descriptions. Orthopade 34(1):65 – 74
62. Krassioukov A, Wolfe DL, Hsieh JT, Hayes KC, Durham CE (1999) Quantitative sensory testing in patients with incomplete spinal cord injury. Arch Phys Med Rehabil 80(10): 1258 – 63
63. Lanctin C, Wiertlewski S, Moreau C, Verny C, Derkinderen P, Damier P, et al. (2006) Idiopathic acute transverse myelitis: Application of new diagnosis criteria to 17 patients. Rev Neurol (Paris) 162(10):980 – 9
64. Landau WM (2005) Plantar reflex amusement: Misuse, ruse, disuse, and abuse. Neurology 65(8):1150 – 1
65. Lemaire JJ, Sautreaux JL, Chabannes J, Irthum B, Chazal J, Reynoso O, et al. (1995) Lumbar canal stenosis. Retrospective study of 158 operated cases. Neurochirurgie 41(2):89 – 97
66. Lowey SE (2006) Spinal cord compression: An oncologic emergency associated with metastatic cancer: Evaluation and management for the home health clinician. Home Healthc Nurse 24(7):439,46; quiz 447 – 8
67. Marino RJ, Ditunno JF, Jr, Donovan WH, Maynard F, Jr (1999) Neurologic recovery after traumatic spinal cord injury: Data from the model spinal cord injury systems. Arch Phys Med Rehabil 80(11):1391 – 6
68. Marino RJ, Barros T, Biering-Sorensen F, Burns SP, Donovan WH, Graves DE, et al. (2003) International standards for neurological classification of spinal cord injury. J Spinal Cord Med 26 Suppl 1:S50 – 6
69. Marino RJ, Graves DE (2004) Metric properties of the ASIA motor score: Subscales improve correlation with functional activities. Arch Phys Med Rehabil 85(11):1804 – 10
70. Maynard FM, Jr, Bracken MB, Creasey G, Ditunno JF, Jr, Donovan WH, Ducker TB, et al. (1997) International standards for neurological and functional classification of spinal cord injury. American Spinal Injury Association. Spinal Cord 35(5):266 – 74
71. Melton LJ, 3rd, Kallmes DF (2006) Epidemiology of vertebral fractures: Implications for vertebral augmentation. Acad Radiol 13(5):538 – 45
72. Meves R, Avanzi O (2006) Correlation among canal compromise, neurologic deficit, and injury severity in thoracolumbar burst fractures. Spine 31(18):2137 – 41
73. Middleton JW, Truman G, Geraghty TJ (1998) Neurological level effect on the discharge functional status of spinal cord injured persons after rehabilitation. Arch Phys Med Rehabil 79(11):1428 – 32
74. Mijnhout GS, Kloosterman H, Simsek S, Strack van Schijndel RJ, Netelenbos JC (2006) Oxybutynin: Dry days for patients with hyperhidrosis. Neth J Med 64(9):326 – 8
75. Miller TM, Johnston SC (2005) Should the Babinski sign be part of the routine neurologic examination? Neurology 65(8):1165 – 8
76. Misawa T, Kamimura M, Kinoshita T, Itoh H, Yuzawa Y, Kitahara J (2005) Neurogenic bladder in patients with cervical compressive myelopathy. J Spinal Disord Tech 18(4):315 – 20
77. Mizuno J, Nakagawa H (2006) Ossified posterior longitudinal ligament: Management strategies and outcomes. Spine J 6(6 Suppl):S282 – 8
78. Mondelli M, Giannini F, Morana P, Rossi S (2004) Ulnar neuropathy at the elbow: Predictive value of clinical and electrophysiological measurements for surgical outcome. Electromyogr Clin Neurophysiol 44(6):349 – 56
79. Mondelli M, Giannini F, Ballerini M, Ginanneschi F, Martorelli E (2005) Incidence of ulnar neuropathy at the elbow in the province of Siena (Italy). J Neurol Sci 234(1 – 2):5 – 10
80. Mondelli M, Grippo A, Mariani M, Baldasseroni A, Ansuini R, Ballerini M, et al. (2006) Carpal tunnel syndrome and ulnar neuropathy at the elbow in floor cleaners. Neurophysiol Clin 36(4):245 – 53
81. Moon KS, Lee JK, Kim YS, Kwak HJ, Joo SP, Kim IY, et al. (2006) Osteochondroma of the cervical spine extending multiple segments with cord compression. Pediatr Neurosurg 42(5):304 – 7
82. Moore AP, Blumhardt LD (1997) A prospective survey of the causes of non-traumatic spastic paraparesis and tetraparesis in 585 patients. Spinal Cord 35(6):361 – 7
83. Neo M, Sakamoto T, Fujibayashi S, Nakamura T (2006) Delayed postoperative spinal epidural hematoma causing tetraplegia. Case report. J Neurosurg Spine 5(3):251 – 3
84. Nicotra A, Ellaway PH (2006) Thermal perception thresholds: Assessing the level of human spinal cord injury. Spinal Cord 44(10):617 – 24
85. Olsson MC, Kruger M, Meyer LH, Ahnlund L, Gransberg L, Linke WA, et al. (2006) Fibre type-specific increase in passive muscle tension in spinal cord-injured subjects with spasticity. J Physiol 577(1):339 – 52

86. O'Neill J, McCann SM, Lagan KM (2006) Tuning fork (128 Hz) versus neurothesiometer: A comparison of methods of assessing vibration sensation in patients with diabetes mellitus. Int J Clin Pract 60(2):174 – 8
87. Ozdoba C, Weis J, Plattner T, Dirnhofer R, Yen K (2005) Fatal scuba diving incident with massive gas embolism in cerebral and spinal arteries. Neuroradiology 47(6):411 – 6
88. Partanen J, Niskanen L, Lehtinen J, Mervaala E, Siitonen O, Uusitupa M (1995) Natural history of peripheral neuropathy in patients with non-insulin-dependent diabetes mellitus. N Engl J Med 333(2):89 – 94
89. Petersen KL, Rowbotham MC (2006) Quantitative sensory testing scaled up for multicenter clinical research networks: A promising start. Pain 123(3):219 – 20
90. Pirart J (1977) Diabetes mellitus and its degenerative complications: A prospective study of 4400 patients observed between 1947 and 1973 (author's translation). Diabetes Metab 3(2):97 – 107
91. Pons Amate J, Sancho J, Romero Martinez A, Juni J, Cervello Donderis A (2006) Evolution of severe pain associated to spontaneous spinal epidural hematoma. Neurologia 21(8): 405 – 10
92. Porter RW (1996) Spinal stenosis and neurogenic claudication. Spine 21(17):2046 – 52
93. Priebe MM, Sherwood AM, Thornby JI, Kharas NF, Markowski J (1996) Clinical assessment of spasticity in spinal cord injury: A multidimensional problem. Arch Phys Med Rehabil 77(7):713 – 6
94. Rafalowska J, Dziewulska D, Podlecka A, Zakrzewska-Pniewska B (2006) Extensive mixed vascular malformation clinically imitating multiple sclerosis – case report. Clin Neuropathol 25(5):237 – 42
95. Raichle KA, Osborne TL, Jensen MP, Cardenas D (2006) The reliability and validity of pain interference measures in persons with spinal cord injury. J Pain 7(3):179 – 86
96. Reisfeld R (2006) Sympathectomy for hyperhidrosis: Should we place the clamps at T2-T3 or T3-T4? Clin Auton Res 16:385 – 389
97. Rieger R, Pedevilla S (2007) Retroperitoneoscopic lumbar sympathectomy for the treatment of plantar hyperhidrosis: Technique and preliminary findings. Surg Endosc 21:129 – 135
98. Rolke R, Baron R, Maier C, Tolle TR, Treede RD, Beyer A, et al. (2006) Quantitative sensory testing in the German research network on neuropathic pain (DFNS): Standardized protocol and reference values. Pain 123(3):231 – 43
99. Rolke R, Magerl W, Campbell KA, Schalber C, Caspari S, Birklein F, et al. (2006) Quantitative sensory testing: A comprehensive protocol for clinical trials. Eur J Pain 10(1):77 – 88
100. Rosenberg NL, Gerhart K, Whiteneck G (1993) Occupational spinal cord injury: Demographic and etiologic differences from non-occupational injuries. Neurology 43(7):1385 – 8
101. Savic G, Bergstrom EM, Frankel HL, Jamous MA, Ellaway PH, Davey NJ (2006) Perceptual threshold to cutaneous electrical stimulation in patients with spinal cord injury. Spinal Cord 44(9):560 – 6
102. Schenk P, Laubli T, Hodler J, Klipstein A (2006) Magnetic resonance imaging of the lumbar spine: Findings in female subjects from administrative and nursing professions. Spine 31(23):2701 – 6
103. Schmid DM, Curt A, Hauri D, Schurch B (2005) Motor evoked potentials (MEP) and evoked pressure curves (EPC) from the urethral compressive musculature (UCM) by functional magnetic stimulation in healthy volunteers and patients with neurogenic incontinence. Neurourol Urodyn 24(2):117 – 27
104. Schurch B (1999) The predictive value of plantar flexion of the toes in the assessment of neuropathic voiding disorders in patients with spine lesions at the thoracolumbar level. Arch Phys Med Rehabil 80(6):681 – 6
105. Seichi A, Takeshita K, Kawaguchi H, Matsudaira K, Higashikawa A, Ogata N, et al. (2006) Neurologic level diagnosis of cervical stenotic myelopathy. Spine 31(12):1338 – 43
106. Seror P, Nathan PA (1993) Relative frequency of nerve conduction abnormalities at carpal tunnel and cubital tunnel in France and the United States: Importance of silent neuropathies and role of ulnar neuropathy after unsuccessful carpal tunnel syndrome release. Ann Chir Main Memb Super 12(4):281 – 5
107. Shaffrey CI, Wiggins GC, Piccirilli CB, Young JN, Lovell LR (1999) Modified open-door laminoplasty for treatment of neurological deficits in younger patients with congenital spinal stenosis: Analysis of clinical and radiographic data. J Neurosurg 90(2 Suppl):170 – 7
108. Siddall PJ, Middleton JW (2006) A proposed algorithm for the management of pain following spinal cord injury. Spinal Cord 44(2):67 – 77
109. Sidell AD. The spoon test for assessing sudomotor autonomic failure. J Neurol Neurosurg Psychiatry 48(11):1190
110. Smith AW, Kirtley C, Jamshidi M (2000) Intrarater reliability of manual passive movement velocity in the clinical evaluation of knee extensor muscle tone. Arch Phys Med Rehabil 81(10):1428 – 31
111. Smith AW, Jamshidi M, Lo SK (2002) Clinical measurement of muscle tone using a velocity-corrected modified Ashworth scale. Am J Phys Med Rehabil 81(3):202 – 6

112. Smoker WR, Biller J, Moore SA, Beck DW, Hart MN (1986) Intradural spinal teratoma: Case report and review of the literature. AJNR Am J Neuroradiol 7(5):905 – 10
113. Sobotta J (1990) Atlas of human anatomy. Staubesand J (ed) 11th English edn. Urban & Schwarzenberg, Baltimore, Munich
114. Sobottke R, Horch C, Lohmann U, Meindl R, Muhr G (2006) The spontaneous spinal epidural haematoma. Unfallchirurg Nov 23
115. Suzuki E, Nakamura H, Konishi S, Yamano Y (2002) Analysis of the spastic gait caused by cervical compression myelopathy. J Spinal Disord Tech 15(6):519 – 22
116. Tailor J, Dunn IF, Smith E (2006) Conservative treatment of spontaneous spinal epidural hematoma associated with oral anticoagulant therapy in a child. Childs Nerv Syst Sep 15
117. Takayama H, Muratsu H, Doita M, Harada T, Yoshiya S, Kurosaka M (2005) Impaired joint proprioception in patients with cervical myelopathy. Spine 30(1):83 – 6
118. Tator CH, Edmonds VE (1979) Acute spinal cord injury: Analysis of epidemiologic factors. Can J Surg 22(6):575 – 8
119. Thomas KC, Bailey CS, Dvorak MF, Kwon B, Fisher C (2006) Comparison of operative and nonoperative treatment for thoracolumbar burst fractures in patients without neurological deficit: A systematic review. J Neurosurg Spine 4(5):351 – 8
120. Trotta D, Verrotti A, Salladini C, Chiarelli F (2004) Diabetic neuropathy in children and adolescents. Pediatr Diabetes 5(1):44 – 57
121. Tsementzis SA, Hitchcock ER (1985) The spoon test: A simple bedside test for assessing sudomotor autonomic failure. J Neurol Neurosurg Psychiatry 48(4):378 – 80
122. Vittadini G, Buonocore M, Colli G, Terzi M, Fonte R, Biscaldi G (2001) Alcoholic polyneuropathy: A clinical and epidemiological study. Alcohol Alcohol 36(5):393 – 400
123. Vroomen PC, de Krom MC, Wilmink JT, Kester AD, Knottnerus JA (2002) Diagnostic value of history and physical examination in patients suspected of lumbosacral nerve root compression. J Neurol Neurosurg Psychiatry 72(5):630 – 4
124. Waters RL, Adkins RH (1997) Firearm versus motor vehicle related spinal cord injury: Preinjury factors, injury characteristics, and initial outcome comparisons among ethnically diverse groups. Arch Phys Med Rehabil 78(2):150 – 5
125. Waters RL, Adkins R, Yakura J, Vigil D (1994) Prediction of ambulatory performance based on motor scores derived from standards of the American Spinal Injury Association. Arch Phys Med Rehabil 75(7):756 – 60
126. Whedon JM, Quebada PB, Roberts DW, Radwan TA (2006) Spinal epidural hematoma after spinal manipulative therapy in a patient undergoing anticoagulant therapy: A case report. J Manipulative Physiol Ther 29(7):582 – 5
127. Woolacott AJ, Burne JA (2006) The tonic stretch reflex and spastic hypertonia after spinal cord injury. Exp Brain Res 174(2):386 – 96
128. Wu X, Zhuang S, Mao Z, Chen H (2006) Microendoscopic discectomy for lumbar disc herniation: Surgical technique and outcome in 873 consecutive cases. Spine 31(23):2689 – 94
129. Yamazaki M, Mochizuki M, Ikeda Y, Sodeyama T, Okawa A, Koda M, et al. (2006) Clinical results of surgery for thoracic myelopathy caused by ossification of the posterior longitudinal ligament: Operative indication of posterior decompression with instrumented fusion. Spine 31(13):1452 – 60
130. Yoshida M, Tamaki T, Kawakami M, Hayashi N, Ando M (1998) Indication and clinical results of laminoplasty for cervical myelopathy caused by disc herniation with developmental canal stenosis. Spine 15;23(22):2391 – 7

# 12 Neurophysiological Investigations

Armin Curt, Uta Kliesch

## Core Messages

- ✔ Neurophysiological investigations go beyond electromyographic recordings
- ✔ Evoked potentials (motor and sensory) allow for the assessment of spinal fiber tracts
- ✔ Electromyography and nerve conduction studies focus on the peripheral nerves
- ✔ Electrodiagnostics distinguish between acute nerve damage and preexisting neuropathies
- ✔ Neurophysiological reflex studies provide additional information about clinical reflexes
- ✔ Intraoperative monitoring improves neuroprotection in scoliosis surgery
- ✔ Electrodiagnostics predict clinical recovery in spinal cord injury (SCI)
- ✔ Subclinical spinal cord impairment can be objectified by neurophysiological recordings
- ✔ Electrodiagnostics confirm the clinical relevance of spinal cord pathologies exposed by neuroimages (morphological description by CT or MR)

## Historical Background

Electrical activity within the muscle is recorded by electromyography

The history of electrodiagnostics started in the 17–18th centuries with the discovery in frogs that stroking a nerve generates a muscle contraction (Jan Swammerdam, 1637–1680) and the development by Alessandro Volta (1745–1827) of the first device to produce electricity and to stimulate muscles (the term "volt" is named in his honor). Luigi Galvani (1737–1798) made the first approaches to neurophysiology by applying electrical stimulation to muscular tissue and recording muscle contractions and force. The proof of electrical activity in voluntary muscle contractions was demonstrated in 1843 by Carlo Matteucci (1811–1868) in frogs and by Emil Du Bois-Reymond (1818–1896) in humans. This was the basis for the term "**electromyography**" (EMG). Following Charles Sherrington's (1857–1952) proposal of the concept of the motor unit in 1925 and the invention of the concentric needle electrode by E.D. Adrian and D.E. Bronk in 1929, the clinical application of electrophysiological observations was developed [23]. Finally, Herbert Jasper (1906–1999) developed the first electromyography machine at McGill University (Montreal Neurological Institute), marking the broad introduction of EMG into clinical practice [3].

Evoked potentials allow for online surveillance of spinal cord function during surgery

The assessment of spinal pathways has been made possible by the introduction of **somatosensory evoked potential** (SSEP) recording since 1970 [the first guidelines for SSEPs by the American Association of Electrodiagnostic Medicine (AAEM) were released in 1984] and **motor evoked potential** (MEP) recording from about 20 years ago. In 1980, P.A. Merton and M.H. Morton published the first study on the stimulation of the cerebral cortex in the intact human subject [28]. Anthony Barker at the University of Sheffield introduced a device for transcranial magnetic stimulation (TMS) as a new clinical tool for non-invasive and painless stimulation of the cerebral cortex [9]. Using the principle that a time-

varying magnetic field will induce an electrical field for the activation of excitatory neurons enables MEPs to be recorded from several muscles.

Intraoperative neuromonitoring started in the late 1970s

In the late 1970s, **intraoperative neuromonitoring** using SSEPs during the correction of scoliosis was introduced, while recording using MEPs due to electrical stimulation was introduced in the mid 1990s [14].

## Neuroanatomy

The spinal cord covers upper and lower motoneuron pathways

In spinal disorders, an involvement of the central (CNS) and/or peripheral (PNS) nervous systems has to be considered [35]. While radiculopathies and lesions of the cauda equina exclusively affect branches of the PNS (radicular motor and sensory nerve fibers), spinal disorders inducing spinal cord malfunction almost always compromise both CNS and PNS structures. The **alpha-motoneuron** located in the central part of the spinal cord (ventral horn of the gray matter) represents the most proximal part of the peripheral motor fibers. Motor fibers from the alpha-motoneuron up to the motor endplates in the muscles constitute the secondary motor pathways, and lesions within this system show characteristic (clinical and electrophysiological) findings of a PNS lesion (lower motoneuron), e.g., flaccid weakness with muscle atrophy and signs of neurogenic denervation. In contrast, the peripheral sensory nerve fibers originate at the dorsal root ganglion, which is located outside the spinal canal. Therefore, in contrast to the motor fibers, even severe intramedullary lesions do not affect the peripheral branch of the sensory nerve fibers, and sensory nerve conduction studies remain normal.

Severity of SCI is related to localization, somatotopic extent and completeness of the lesion

The **somatotopic organization** (Fig. 1) of the longitudinal as-/descending spinal tracts (corticospinal, dorsal column, spinothalamic) allows the differentiation of the axial distribution of a lesion affecting more the anterior, posterior or central part of the cord, as well as the hemicord or total cord [24]. The sagittal localization and extension of a lesion are represented in the affection of motor

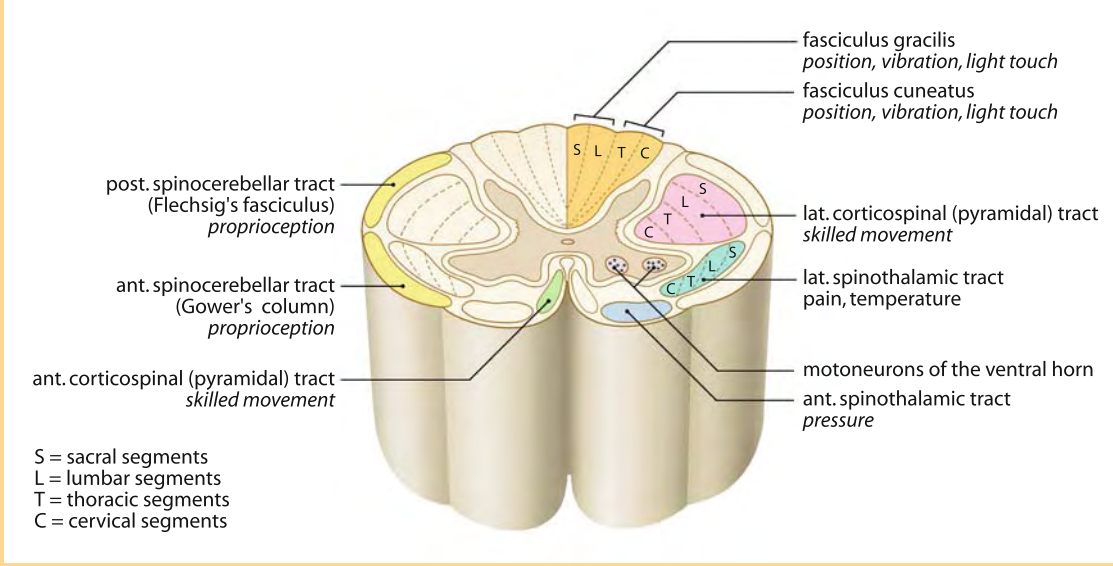


Figure 1. Somatotopic organization of the spinal cord

and sensory segments and can be demonstrated by the affected motor levels (extent of segments with denervation) as assessed by EMG. It has to be acknowledged that the intramedullary segments are more rostrally located than the related nerve roots and the alpha-motoneurons are distributed in columns over several segments.

## Neurophysiological Modalities

The purpose of this section is not to provide detailed technical and procedural descriptions but to outline the general indications (strengths) of the specific techniques and their limitations (weaknesses) in answering clinical questions. The section aims to give guidance about the various electrophysiological techniques and enables the correct technique to be chosen for the diagnostic assessment of a spinal disorder with an assumed or obvious neurological affection.

### Electromyography

Electromyography (EMG) is one of the most frequently applied electrophysiological techniques in spinal disorders and the term "EMG" is often almost synonymously used when asking for electrophysiological testing. It is the modality of choice for identification of a lesion within the peripheral nervous system affecting the lower motoneuron at any level (from the alpha-motoneuron within the spinal cord down to the distal motor endplates located in the muscle).

EMG is the modality of choice for the diagnosis of a peripheral nervous lesion

#### Technique

Needle and surface EMG recordings should be distinguished. **Surface EMG recordings** (cup electrodes attached to the skin) are primarily used for kinesiological studies (when investigating to what extent a muscle is activated during a complex motor task, such as walking) (Fig. 2), while **needle EMG recordings** are used to search for lower motoneuron lesions. They are performed with bi- or monopolar needles that have to be inserted into the target muscle. The insertion induces some discomfort comparable to when taking blood. It is an invasive procedure and therefore the specific indications and contraindications (anticoagulation treatment) need to be acknowledged. The EMG records the electrical activity within a muscle and is applied in the resting and activated muscle (some cooperation from the patient is needed). Besides the proof of a neurogenic lesion, myogenic motor disorders (myopathy, myotonic and muscle dystrophic disorders) can also be diagnosed [19, 25, 29].

#### Indications

In spinal disorders, EMG is the method of choice for the identification of damage within the **peripheral motor nerve fibers** (highest sensitivity). However, the delay between the time of the actual damage and the first signs of denervation (acute denervation potentials occur after a mean of 21 days) must be considered. Also the activation pattern (complete or reduced interference) assessed during voluntary activation (here the patient needs to cooperate and perform a voluntary activation) can be applied as soon as the very first few days after a lesion to disclose a pathological innervation. The performance of EMG in several muscles allows the specific localization of the nerve damage (somatotopic localization of a lesion) to be indicated and for the differentiation of acute, subacute and chronic axonal damage (denervation). EMG is also the method of choice for the demon-

Signs of denervation in EMG are temporarily delayed while innervation patterns change immediately

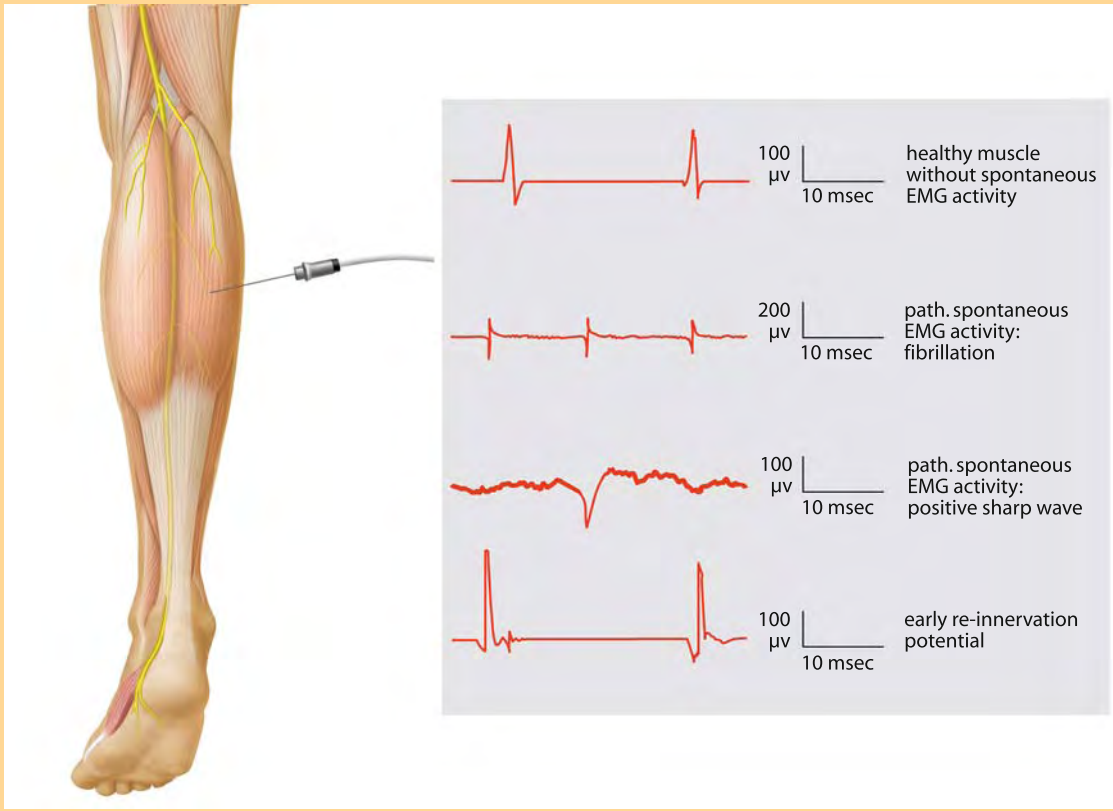


**Figure 2. Electromyography**

Spontaneous muscle activity is recorded at the target muscles.

stration of neurogenic reinnervation (subacute to chronic reinnervation pattern).

### Limitations

The extent of axonal nerve damage and reinnervation is difficult to quantify

Spinal disorders with demyelination of motor nerve fibers (very slowly evolving neural compression as in benign tumor or stenosis) are less assessable by EMG. The extent of axonal nerve damage and reinnervation cannot be easily quantified by EMG. Needle EMG recordings provide some discomfort (which can be painful) for patients.

## Nerve Conduction Studies

Motor and sensory nerve conduction studies (NCS) assess the **conduction velocity** (mainly properties provided by the myelination of peripheral nerves) and **amount of impulse transmission** (axonal transport capacity). These parameters distinguish between a primarily axonal and/or demyelinating neuropathy, which cannot be achieved by the clinical examination. Frequently NCS are combined with reflex recordings that provide additional information about changes in nerve conduction.

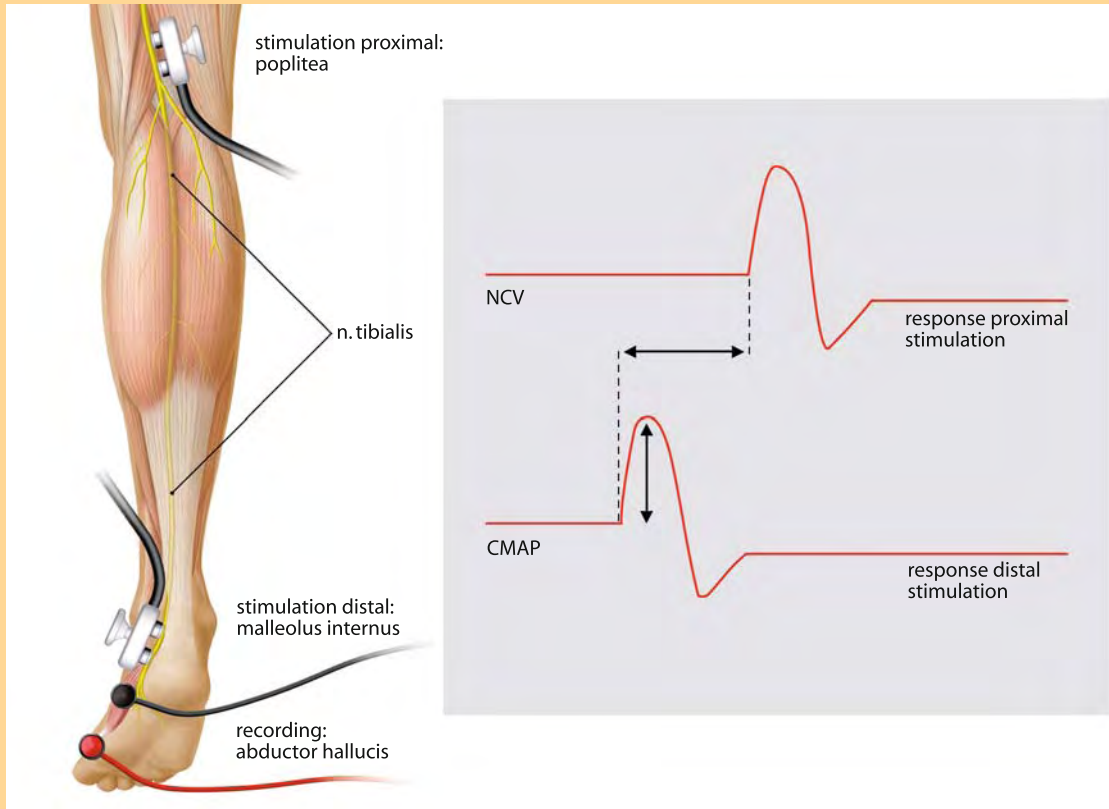


**Figure 3. Nerve conduction studies**

The nerve conduction velocity (NCV) is calculated dividing the distance between the stimulation points by the conduction time between these points.

### Technique

Electrical stimulations (Fig. 3) applied along the peripheral nerve branch (distal to proximal) and recordings by surface electrodes at the distal motor or sensory site allow for the assessment of responses separately and for the calculation of **nerve conduction velocities** (expressed in meters per second) by measuring the distance [8, 20]. The **compound muscle action potential** (CMAP, in millivolts) and the sensory action potential (in microvolts) are calculated to assess the axonal nerve integrity.

### Indications

Nerve conduction studies are primarily indicated in conditions assumed to affect the peripheral nerves (damage or disorders of the plexus, peripheral nerves, compartment syndromes, polyneuropathy), while they are not applicable for the diagnosis of a radiculopathy [34]. NCS are the method of choice for the diagnosis of a peripheral neuropathy (e.g., diabetic neuropathy) or nerve compression syndrome (carpal tunnel syndrome). They are very sensitive in demonstrating and **quantifying a conus medullaris and cauda equina lesion** (i.e., when combined with reflex recordings). However, isolated damage of S2–S5 roots can be missed. In **spinal cord injury** (SCI), intramedullary alpha-motoneuron damage induces a reduction of the CMAP of the related peripheral nerves, while the sensory NCS

NCS are indicated for the diagnosis of peripheral neuropathy but not radiculopathy

NCS are used to distinguish between axonal and demyelinating neuropathies

remains normal (a pattern which is able to exclude additional peripheral nerve injury). As sensory NCS in contrast to the motor NCS remain unaffected in spinal cord injuries, they enable the assessment of polyneuropathy in complete cauda and conus medullaris lesions.

### Limitations

The characteristic signs of acute nerve damage appear with a delay of about 10 days after damage (however, this is earlier than signs of denervation in the EMG), and single recordings do not enable the acuteness of damage to be demonstrated. Here, the EMG recordings are able to distinguish between an acute and chronic course of nerve damage due to specific denervation potentials, which is not possible by NCS. Changes in NCS allow the **differentiation between primarily demyelinating and axonal neuropathies**, which are typically neuronal complications in medical disorders (e.g., neuropathy due to diabetes mellitus or uremia) but cannot be used to determine the underlying disorder.

## F-Wave Recordings

F-wave recordings are not considered to be reflexes since only the motor branches of a peripheral nerve become involved. They are not mediated via a reflex arc where sensory and motor fibers are involved, like the tendon tap that induces an afferent input on the **spindle organ** (stretch of muscle) and an **excitation of motoneurons** in the spinal cord with an **efferent motor response** (the muscle jerk is the reflex response).

### Technique

The electrical stimulation of a peripheral nerve induces a bidirectional electrical volley with a **direct motor response** (M-response of the orthodromic volley) (Fig. 4) and an antidromic volley propagating to the alpha-motoneuron, inducing an efferent motor response which travels back on the peripheral motor nerve fibers. This response is called the **F-wave**. The patient should be in a relaxed position without activation of the muscle.

### Indications

F-waves are sensitive to spinal cord excitability

F-wave recordings assess the alpha-motoneuron excitability and conduction velocity of the peripheral motor branch [10, 22]. The excitability of F-wave responses (expressed as a percentage of F-wave responses to 20 stimuli) can be applied to diagnose the level of spinal shock as they become abolished or reduced. They are sensitive to **demyelinating motor neuropathies** (e.g., diabetes mellitus) and complement NCS.

### Limitations

F-waves cannot assess the extent of intramedullary and peripheral axonal damage

F-waves are not sensitive enough to assess the extent of intramedullary and peripheral axonal nerve damage (no quantification of damage). The responses are not related to spasticity and are recordable only in some motor nerves (ulnar, median, tibial nerves).

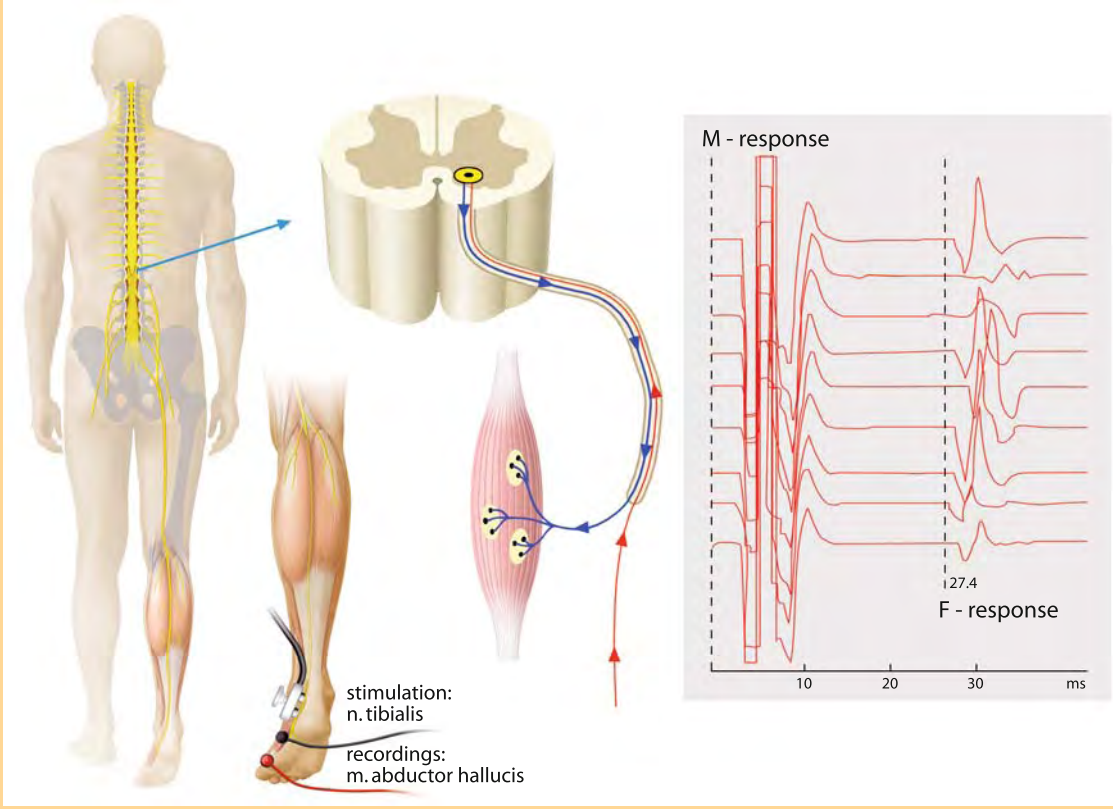


**Figure 4. F-wave**

The F-wave is elicited by antidromic excitation of motor axons and reflexion of this excitation at the motoneuron. The M-response is elicited by direct orthodromic excitation of the motor axon.

## H-Reflex

The H-reflex recording is an electrophysiological investigation comparable to the tendon-tap reflexes. This **segmental reflex** is activated by an afferent sensory stimulus (electrical stimulation of the tibial nerve) and a monosynaptic transmission to the corresponding efferent motoneuron (Fig. 5) [6, 7].

### Technique

By submaximal electrical stimulation of a nerve, sensory afferents induce a monosynaptically transmitted excitation of the corresponding alpha-motoneuron and an indirect motor response can be recorded by surface electrodes. The patient should be in a relaxed position without activation of the muscle.

### Indications

The H-reflex provides information about sensorimotor interaction

The excitability and calculation of the tibial nerve H-reflex latency is a sensitive measure in **neuropathy** and for the assessment of disturbance within the **L5 – S1 nerve roots**. The H-reflex is less affected by spinal shock (it is reestablished within 24 h after SCI) than clinical reflexes and the F-wave.

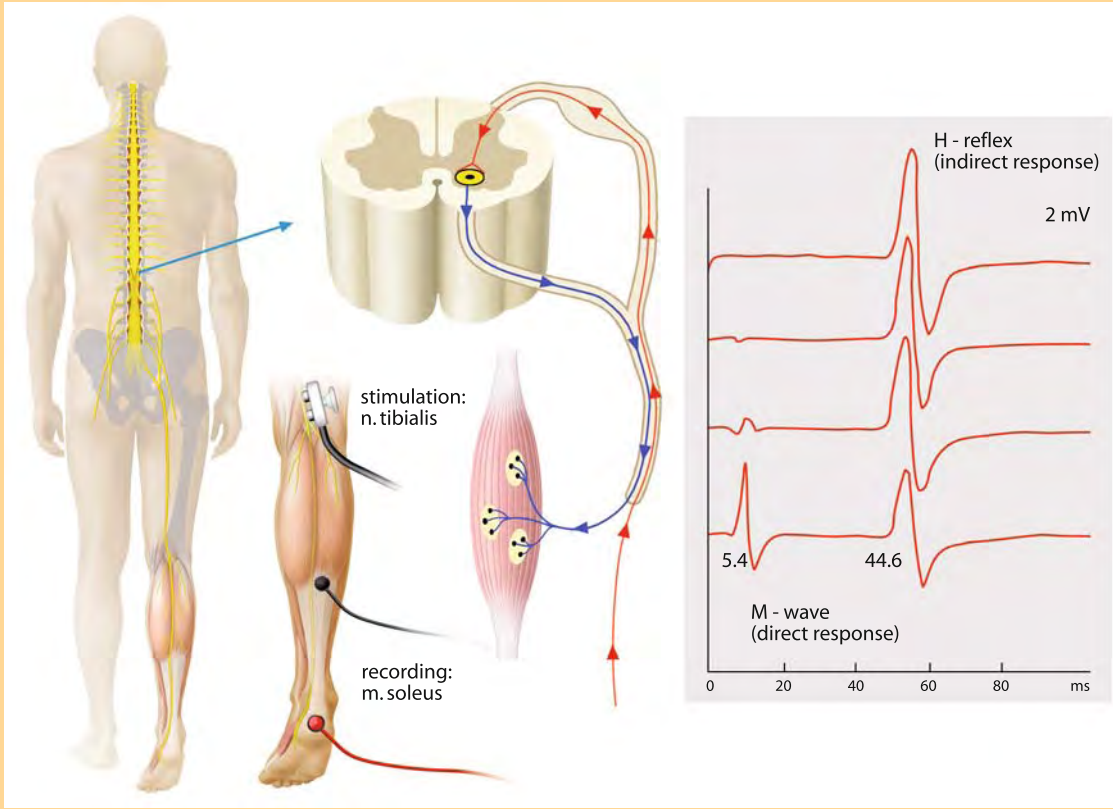


**Figure 5. H-reflex**

The H-reflex is elicited by excitation of low-threshold Ia-afferent nerve fibers which then excite the motoneuron monosynaptically (indirect response). The M-response is elicited by direct orthodromic excitation of the motor axon when using stronger stimulation intensity (indirect response).

### Limitations

The H-reflex can only be recorded from n. tibialis

The H-reflex recording per se is not able to distinguish between sensory or motor nerve damage as the response is dependent on the whole reflex arc. It has to be acknowledged that the reflex response can be modulated by several conditioning maneuvers (**Jendrassik maneuver**) that are able to influence spinal excitability. Clinically reliable H-reflex recordings are **only achievable from the tibial nerves**.

## Somatosensory Evoked Potentials

Somatosensory evoked potentials (SSEPs) enable the assessment of sensory nerve function across very long pathways through the body. By stimulation of distant body parts (distal peripheral nerves or dermatomes), nerve impulses are transmitted through parts of the peripheral and central nervous system and responses can be recorded at the cortical level. The additional recording of responses at different sites of the pathways (at the proximal segments of the peripheral nerve or the plexus, and even at different levels of the spinal cord) can be performed to localize the area or segment of the nerve affection. SSEPs do not represent one single type of sensory fiber but are most closely **related to vibration and proprioception**. These sensory qualities are propagated by the dorsal column within the spinal cord.

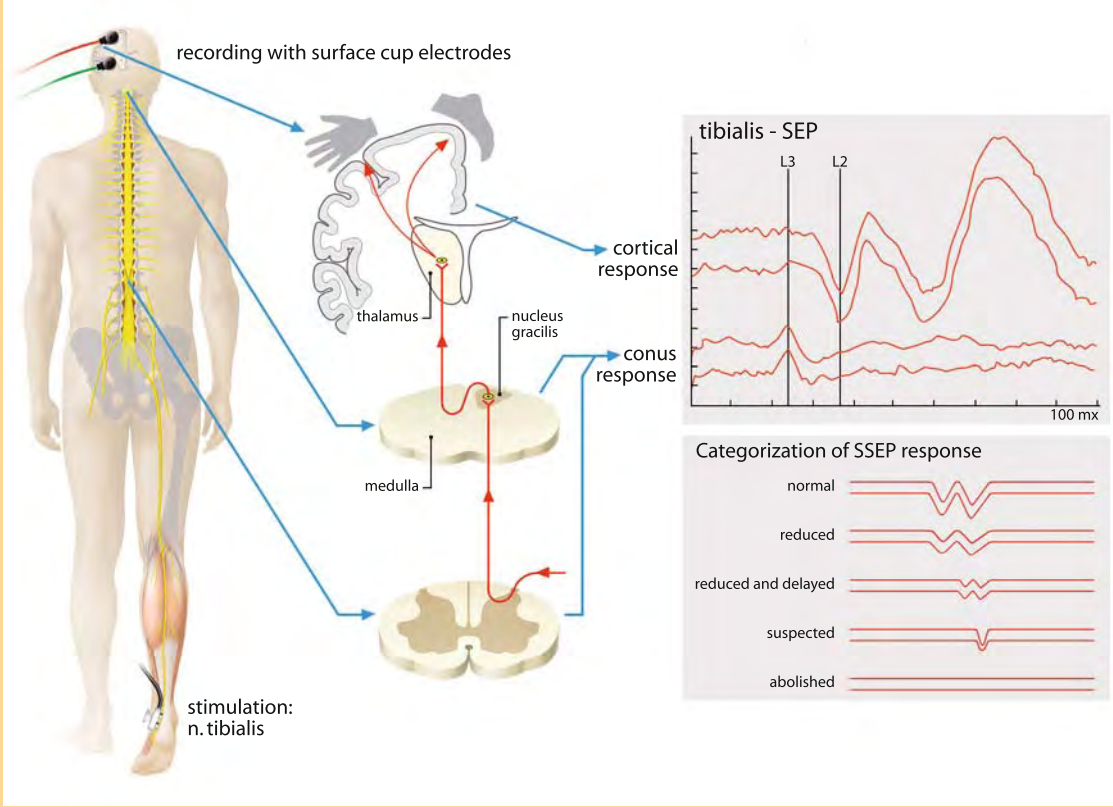


**Figure 6. Somatosensory evoked potentials**

SSEPs are elicited by peripheral stimulation of afferent nerves (e.g. n. tibialis, n. ulnaris) and recorded as stimulus-synchronized averaged brain activity.

## Technique

SSEPs (Fig. 6) are cortical responses to repetitive electrical stimulations of peripheral nerves that can be recorded without the necessary cooperation of the patient (emergency, intraoperative) and can provide a survey of the sensory pathway from very distal to the cortical level [36, 37]. The recordings can be performed using **surface electrodes**, the electrical stimulations are below the level of painful sensation and the responses represent averages of 100 and more stimulations.

## Indications

SSEPs assess damage of the dorsal column

Superior to clinical sensory testing, SSEPs provide objective measures (latencies and amplitudes) of dorsal column function and complement the subjective responses of patients to sensory testing. Especially in patients who are unable to cooperate sufficiently with difficult sensory tests or in whom due to a language barrier reliable clinical testing is not possible, SSEPs complement the clinical examination. **Repeated measures are valuable** for describing even minor changes within the sensory nerve fibers. In spinal disorders with nerve compression (spinal tumor or stenosis), even in clinically unsuspicious patients SSEPs can yield pathological findings. The responses are **only minimally influenced by medication.**

### Limitations

SSEPs do not allow one to differentiate whether touch or pinprick sensation is affected

SSEP recordings are not sensitive enough to assess specific sensory deficits. They do not explicitly prove whether touch or pinprick sensation is affected, although the excitability of an SSEP response in a patient reporting complete sensory loss is proof that some sensory function is preserved. SSEP recordings do not relate specifically to pain syndromes, which are one of the leading clinical syndromes in spinal disorders.

## Motor Evoked Potentials (Transcranial Magnetic Stimulation)

Motor evoked potentials (MEPs) comparable to SSEPs are able to assess the whole motor pathways from the cortical level down to the distal muscle and therefore are affected in **lesions of the peripheral** (peripheral nerve, plexus) and **central** (spinal, cortical) **nervous system.**

### Technique

In awake subjects, **transcranial magnetic stimulation** (TMS) enables non-painful excitation of cortical motoneurons to induce MEPs transmitted by the corticospinal tract of the spinal cord and obtained from several muscles by surface electrodes (Fig. 7) [15, 18]. Patients are required to cooperate with the examina-

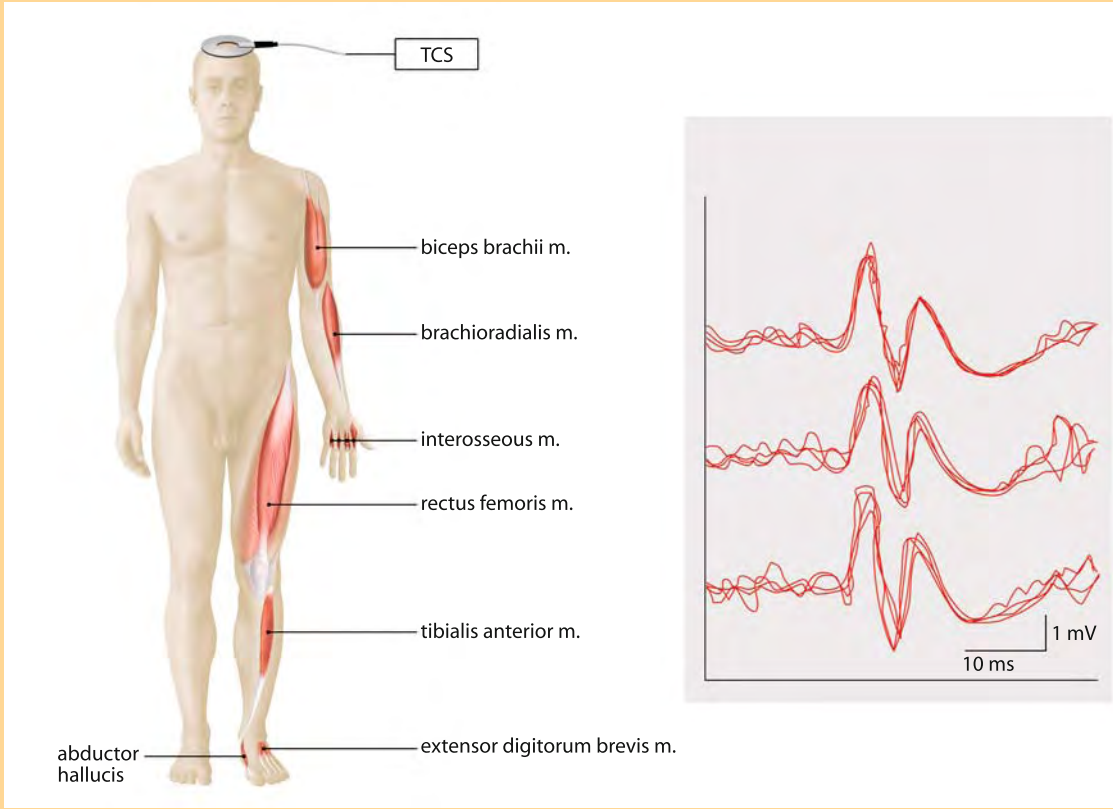


**Figure 7. Motor evoked potentials**

Transcranial magnetic stimulation at the skull level leads to excitation of motor cortical neurons which is conveyed to the spinal motoneurons. The excitation is recorded at the level of target muscles.

tion while they are asked to perform a small preactivation of the target muscle. Using the latter procedure, responses can be retrieved with a lower stimulation threshold and reliable latencies can be calculated to demonstrate delayed responses.

### Indications

In addition to clinical motor testing (according to MRC grades), latencies and amplitudes can be obtained for an objective quantification of the conduction velocity and amount of response. MEP recordings are the method of choice for demonstrating subclinical affections of the corticospinal motor tracts that are less evident from clinical testing. The application of combined MEPs and motor NCS can be performed to distinguish between spinal and peripheral affection of the motor nerve fibers.

MEPs are the method of choice for assessing lesions of the corticospinal tract

### Limitations

The results obtained are not directly related to the clinical motor strength, and MEP responses show a high variability of amplitude. **Patients need to cooperate** with the testing. In patients suffering from epilepsy or having intracranial ferromagnetic devices, TMS should be performed only with strict indications.

MEP responses are largely variable

## Intraoperative Neuromonitoring

Intraoperative neuromonitoring is used for **real-time surveillance of nerve function** during spine surgery. Especially postsurgical neurological complications such as paralysis are mainly due to an impaired vascular supply of the spinal cord that cannot be controlled by the spine surgeon. Therefore, continuous monitoring of sensory and motor nerve function ensures that the surgical manipulations (suture of vessels or vascular compression due to stretching/correction of the spine) do not compromise the mandatory blood supply for the maintenance of nerve function. Especially in corrections of spinal deformities and during operations on spinal tumors, intraoperative neuromonitoring is able to improve surgical outcome.

### Technique

In anesthetized patients, SSEPs and MEPs can be recorded to monitor spinal cord function during spine surgery [5, 21, 31]. Mainly needle electrodes (at the cortical level and muscles) are applied to ensure low impedance and reliable fixation during surgery. During anesthesia MEPs are routinely evoked by transcranial electrical (high voltage) stimulation with single or short train stimuli. While **SSEPs** are **averaged responses**, **MEPs** are retrieved as **single recordings**.

### Indications

In spinal deformity surgery and in tumor surgery of the spine, intraoperative neuromonitoring of the spinal cord is a recommended procedure to provide a high level of safety for the patient and to give some guiding information to the surgeon. In spinal cord injury the relevance of neuromonitoring has not been established.

Neuromonitoring is indicated in surgery with potential spinal cord compromise

### Limitations

The performance of intraoperative neuromonitoring requires a commitment of time (preparation of the setting) along with special equipment and trained staff. It has been shown that surgical teams using neuromonitoring have reduced the rate of neurological complications by more than 50 % [32]. However, even with spinal neuromonitoring some neurological complications can occur.

## Role of Neurophysiology in Specific Disorders

Given the complexity of neuronal functions within and close to the spine (spinal cord, radical nerve fibers, plexus, peripheral nerves), there is no single electrophysiological measurement capable of being applied for testing, and combined measures need to be used. The required combination should be determined by a neurophysiologist, and the spine specialist should know the potential strengths and weaknesses of the different neurophysiological assessments.

### Spinal Cord Injury

In traumatic disorders of the spine, neurological deficits are primarily examined according to the ASIA protocol, which allows for standardized assessment of sensorimotor deficit by describing the level and completeness of the SCI [17]. In patients not able to cooperate with a full clinical assessment, neurophysiological recordings can overcome this limitation and provide additional quantitative measures about spinal cord function.

#### Strengths

Neurophysiological studies allow neuronal damage to be objectified

Complementary to the clinical examination, **neurophysiological recordings:**

- objectify the neuronal damage (mainly independently of patient contribution) [11, 16, 27]
- describe the extent of spinal cord dysfunction in a superior manner to neuroimaging
- improve diagnosis and prognosis for treatment and rehabilitation [12]
- monitor the input of clinical treatment to the neural structures [13]

#### Weaknesses

The performance of neurophysiological recordings requires time and therefore needs to be carefully integrated into the clinical diagnosis and therapeutic procedures. There is also the need for specialized staff and equipment.

### Cervical/Lumbar Radiculopathy

Neurophysiological studies allow radiculopathy to be differentiated from peripheral neuropathy

Radiculopathy due to disc protrusion is the most frequent spinal disorder and can be clinically diagnosed in cases with typical presentation without any additional neurophysiological recordings. However, in less typical cases or in the presence of additional accompanying neurological and medical disorders, EMG recordings are the method of choice for objectifying a radiculopathy of the motor nerve fibers.

### Strengths

EMG recordings can be applied at all levels of radiculopathy. Using the needle EMG examination, the corresponding radicular muscles can be investigated:

- to objectify a motor radiculopathy
- to examine distal (extremities) or proximal (paraspinal) EMGs
- to exclude neuropathies that can mimic comparable pain syndromes (plexopathy)
- to reveal signs of reinnervation

### Weaknesses

The following shortcomings of EMG recordings have to be acknowledged:

Neurophysiological studies are not applicable in anticoagulated patients

- EMG is not capable of documenting a pure sensory radiculopathy
- A normal EMG does not exclude a nerve compromise (i.e., severe pain in a radiculopathy) that has not yet induced motor nerve damage
- EMG is not applicable in anticoagulated patients

## Cervical Myelopathy

Cervical myelopathy mainly is combined nerve damage within the spinal cord including: (1) affection of longitudinal pathways (dorsal column and corticospinal motor tract), and (2) segmental damage of the gray matter (alpha-motoneuron lesion). Predominantly patients complain about numbness of fingers, hands and feet, as well as unspecific difficulties in walking. These complaints can be easily misinterpreted as a neuropathic disorder.

### Strengths

Combined neurophysiological recordings provide the opportunity to objectify and quantify a neuronal compromise at the cervical level and:

Neurophysiological studies allow myelopathy and neuropathy to be differentiated

- distinguish between focal demyelination of longitudinal pathways (MEP, SSEP) and gray matter damage (CMAP, EMG) [30, 33]
- confirm that a stenotic area with or without an intramedullary signal change can be related to the presented neurological deficit
- exclude that in mainly elderly people neuropathies become misdiagnosed

### Weaknesses

Comparable to the poor correlation of radiological findings (extent and type of spinal canal stenosis) to clinical complaints:

- electrophysiological findings do not show a strong correlation with the extent of clinical complaints
- the specificity of neurophysiological recordings is reduced in combined spinal and peripheral nerve disorders

## Lumbar Spinal Canal Stenosis

In typical clinical cases, the diagnosis of a neurogenic claudication is based on a combined clinical and radiological (CT, MRI) examination. With the increase in the elderly population and due to the improved techniques for identifying lumbar spinal canal stenosis, the extent of surgery performed due to neurogenic claudication has dramatically increased in the last 20 years.

### Strengths

The combination of radiological, clinical and neurophysiological testing is improving diagnostic sensitivity and specificity. In atypical presentation of the disorder or in patients with other accompanying diseases:

- the affection of nerve function at the stenotic area can be disclosed and quantified [2, 4]
- neuropathies can be excluded that can induce similar pain syndromes (numbness of feet due to peripheral neuropathy) [1, 26]

### Weaknesses

Comparable to cervical stenosis there is only a low correlation of the radiological findings (extent and type of spinal canal stenosis) to the clinical complaints

- electrophysiological findings are not correlated to the extent of clinical complaints
- in combined spinal and peripheral nerve disorders the specificity of the neurophysiological recordings is reduced

## Neurophysiology in Differential Diagnosis

Not only in the population of elderly patients do several differential diagnoses have to be considered but especially when the complaints are demonstrated in an atypical presentation.

### Peripheral Nerve Lesion Versus Radiculopathy

Neurophysiological studies allow radiculopathy to be differentiated from peripheral neuropathy

Damage to the nerve roots presents in a radicular distribution (see Chapters 8, 11) of sensory (dermatome) and motor (myotome) deficits, and electrophysiological measurements are able to distinguish a peripheral nerve affection from a radiculopathy. A **peripheral nerve lesion**, like the compression of the peroneal nerve close to the fibula head, induces pathological findings in NCS (conduction failure with reduced or even abolished CMAP) and pathological EMG findings in the distal muscles innervated by the peroneal nerve; while a complete motor L5 radiculopathy shows no NCS pathology but produces pathological EMG findings (signs of denervation) in both the distal (anterior tibial muscle) and the proximal (gluteus medius, paravertebral muscles) L5 innervated muscles.

### Neuropathy Versus Spinal Canal Stenosis

Neurophysiological studies allow the exclusion of additional peripheral neuropathy

A polyneuropathy can mimic complaints similar to spinal canal stenosis (both lumbar and cervical) with numbness and some weakness mainly in the lower limbs. Also numbness of the fingers can be due to PNP, cervical myelopathy or carpal tunnel syndrome. Atypically presented complaints should indicate that combined SSEP and NCS recordings be performed, which are able to distinguish between these disorders. In spinal canal stenosis the peripheral nerve conduction velocity of the related nerves remains normal while the SSEP recordings become delayed due to a slowing within the spinal cord.

### Neuropathy

Four major forms of neuropathy can be distinguished:

- sensorimotor neuropathy
- autonomic neuropathy
- mononeuropathy
- polyneuropathy

The most common form is diabetic peripheral neuropathy, which mainly affects the feet and legs. Neuropathic pain is common in cancer as a direct result of the cancer in peripheral nerves (e.g., compression by a tumor), as a side effect of many chemotherapy drugs, and renal disorders. Neuropathy often results in numbness, and abnormal sensations called dysesthesia and allodynia that occur either spontaneously or in reaction to external stimuli. Neuropathic pain is usually perceived as a steady burning and/or "pins and needles" and/or "electric shock" sensations.

**Nerve entrapment syndromes** are mononeuropathies which usually affect middle-aged and elderly patients. In patients suffering from atypical pain syndromes of the upper limbs, carpal tunnel syndrome (CTS) should be excluded. A thoracic outlet syndrome (TOS) and peripheral nerve compression at the elbow or the loge de Guyon can confuse the clinical diagnosis. While typical representations of these entrapment syndromes do not cause any particular clinical problems in diagnosis, atypical cases can be challenging. Nerve conduction studies are the method of choice for objectifying a nerve entrapment and are able to identify the localization of nerve compression.

## Myopathy and Myotonic Disorders

In patients with walking difficulties and pain and fatigue after walking short distances, muscle disorders also have to be considered. Myopathies are neuromuscular disorders in which the primary symptom is muscle weakness due to dysfunction of muscle fibers but frequently present symptoms of muscle cramps, stiffness, and spasm. **Congenital myopathies** (mitochondrial myopathies, myoglobinurias) and muscular dystrophies (progressive weakness in voluntary muscles, sometimes evident at birth) are distinguished from **acquired myopathies** (dermatomyositis, myositis ossificans, polymyositis, inclusion body myositis). Neuromyotonias are characterized by alternating episodes of twitching and stiffness, while the stiff-man syndrome presents episodes of rigidity and reflex spasms that can be life threatening. EMG recordings are most sensitive for identifying **myopathic disorders** and are complemented by blood and biopsy work-ups for the specification of the disorder.

Neurophysiological studies are sensitive in diagnosing myopathic disorders

## Hereditary and Neurodegenerative Disease

Neurogenic spine deformities are frequently seen in juvenile **neuromuscular disorders** (hereditary sensorimotor neuropathies, e.g., Charcot-Marie-Tooth neuropathy, spinal muscle atrophy, hereditary myopathies), and electrodiagnostic assessments are mandatory when the underlying clinical disorder has not yet been identified. In adults, spinal deformities can develop due to **neurodegenerative diseases** [rarely in amyotrophic lateral sclerosis (ALS), atypical Parkinson's syndrome with trunk instability], and it is mandatory to define the pathology as this should have an impact on the surgical approach. In these disorders combined electrophysiological recordings are applied to assess alpha-motoneuron or peripheral nerve affections.

Neurophysiological studies are helpful in diagnosing neurodegenerative disorders

## Recapitulation

**Neurophysiological modalities.** The techniques and standards of clinical neurophysiological methods provide the capability to assess different components of the **peripheral and central nervous systems**. Besides the well-known EMG, several recordings are available that address very specific questions. Therefore, it is important to consider that **combined electrodiagnostic recordings** have to be applied to evaluate the different neuronal structures and functions. As spinal disorders are actually on the borderline between central (spinal) and peripheral (radicular, conus cauda) neuronal elements, the neurophysiological assessments need to cover these areas. Neurophysiological assessments only **complement the clinical neurological examination** and are intended to provide information that is not or is less precisely retrievable by clinical testing. These assessments in general do **not aim to evaluate complex body functions**, like walking and hand function, but to **objectify the function of neuronal subcomponents** (conduction velocity of nerve fibers) that contributes to the major function, as well as to improve the somatotopic localization of nerve damage.

**Specific spinal disorders.** The **neurophysiological investigations** should be **specifically targeted** to the assumed or evident spine disorders to identify and quantify the neuronal damage. In disorders that compromise the spinal cord or radicular nerves but have not yet induced structural damage, the neurophysiological recordings will not indicate any suspected disorder although the patients can be suffering from severe pain. Vice versa, in patients with only minor clinical complaints the neurophysiological recordings can reveal already advanced neural damage. Therefore, the main goal for neurophysiological recordings is to **objectify** whether a **radiologically exposed pathological finding** is related to assumed neuronal damage or to prove the presence of a neuronal compromise although the radiological findings are unsuspicious. In patients suffering from complex and/or multiple disorders the neurophysiological recordings can give confidence about the relevance of a pathological finding.

**Neurophysiology for differential diagnosis.** The different neurophysiological recordings allow for the diagnosis of a huge variety of neuronal diseases that have to be considered in spinal disorders. As recording the evoked potentials (SSEPs, MEPs) allows for the assessment of spinal cord function, EMG and nerve conduction studies focus on the peripheral nervous system and distinguish between the affection of motor and sensory fibers. These techniques enable the localization of injury and the distinction to be made between primary demyelination and axonal damage. The recordings can be utilized for follow-up recordings to monitor both the progression and the recovery from an injury/disorder.

## Key Articles

**Merton PA, Morton MH (1980) Stimulation of the cerebral cortex in the intact human subject. Nature 285:227**
Landmark paper introducing transcranial magnetic stimulation for the assessment of motor pathways of the central nervous system in the awake human subject.

**Forbes HJ, Allan PW, Waller CS, Jones SJ, Edgar MA, Webb PJ, Ransford AO (1991) Spinal cord monitoring in scoliosis surgery. Experience in 1168 cases. J Bone Joint Surg (Br) 73B:487–91**
First proof of the significance of intraoperative neuromonitoring in scoliosis surgery to reduce postoperative neurological deficits.

**Owen JH, Sponseller PD, Szymanski J, Hurdle M (1995) Efficacy of multimodality spinal cord monitoring during surgery for neuromuscular scoliosis. Spine 20:1480–88**
This study demonstrated the improvement of neuromonitoring by the application of combined recordings.

**de Noordhout AM, Rapisarda G, Bogacz D, Gerard P, De Pasqua V, Pennisi G, Delawaide PJ (1999) Corticomotoneuronal synaptic connections in normal man: an electrophysiological study. Brain 122:1327–1340**
This study showed that direct cortico-motoneuronal connections can be assessed by motor evoked potentials.

**Jones KE, Lyons M, Bawa P, Lemon RN (1994) Recruitment order of motoneurons during functional tasks. Exp Brain Res 100(3):503 – 508**
This paper showed the ability to assess different types of motoneurons in humans by the performance of specific motor tasks.

**Yamada T (2000) Neuroanatomic substrates of lower extremity somatosensory evoked potentials. J Clin Neurophysiol 17(3):269 – 79**
This paper summarizes the technical issues and the clinical indication of tibial SSEPs, as well as the pitfalls that have to be considered for the application in diagnostics of neurological and spine disorders.

**Angel RW, Hofmann WW (1963) The H reflex in normal, spastic, and rigid subjects. Arch Neurol 9:591 – 6**
Landmark paper introducing the H-reflex for clinical diagnostics.

## References


1. Adamova B, Vohanka S, Dusek L (2003) Differential diagnosis in patients with mild lumbar spinal stenosis: the contributions and limits of various tests. Eur Spine J 12:190 – 196
2. Adamova B, Vohanka S, Dusek L (2005) Dynamic electrophysiological examination in patients with lumbar spinal stenosis: Is it useful in clinical practice? Eur Spine J 14:269 – 76
3. Ajmone-Marsan C (1999) Herbert Henry Jasper M.D., Ph.D., 1906 – 1999. Clin Neurophysiol 110:1839 – 41
4. Baramki HG, Steffen T, Schondorf R (1999) Motor conduction alterations in patients with lumbar spinal stenosis following the onset of neurogenic claudication. Eur Spine J 8:411 – 416
5. Bose B, Sestokas AK, Schwartz DM (2004) Neurophysiological monitoring of spinal cord function during instrumented anterior cervical fusion. Spine J 4:202 – 7
6. Branddom RI, Johnson EW (1974) Standardization of H-reflex and diagnostic use in S1 radiculopathy. Arch Phys Med Rehabil 55:161 – 166
7. Burke D, Hallett M, Fuhr P, Pierrot-Deseilligny E (1999) H reflexes from the tibial and median nerves. Recommendations for the Practice of Clinical Neurophysiology 4, Chap 6, pp 259 – 262
8. Buschbacher RM (1999) Tibial nerve motor conduction to the abductor hallucis. AM J Phys Med Rehabil 78:15 – 20
9. Claus D, Weis M, Spitzer A (1991) Motor potentials evoked in tibialis anterior by single and paired cervical stimuli in man. Neurosci Lett 125:198 – 200
10. Curt A, Keck M, Dietz V (1997) Clinical value of F-wave recordings in traumatic cervical spinal cord injury. Electroencephalogr Clin Neurophysiol 105:189 – 193
11. Curt A, Keck ME, Dietz V (1998) Functional outcome following spinal cord injury: Significance of motor-evoked potentials. Arch Phys Med Rehab 79:81 – 86
12. Curt A, Dietz V (1999) Electrophysiological recordings in patients with spinal cord injury: Significance for predicting outcome. Spinal Cord 37:157 – 165
13. Curt A, Schwab ME, Dietz V (2004) Providing the clinical basis for new interventional therapies: refined diagnosis and assessment of recovery after spinal cord injury. Spinal Cord 42:1 – 6
14. Dawson EG, Sherman JE, Kanim LE, Nuwer MR (1991) Spinal cord monitoring. Results of the Scoliosis Research Society and the European Spinal Deformity Society Survey. Spine 16 (Suppl):S361 – 64
15. Di Lazzaro V, Oliviero A, Profice P, Ferrara L, Saturno E, Pilato F, Tonali P (1999) The diagnostic value of motor evoked potentials. Clin Neurophysiol 110:1297 – 1307
16. Diehl P, Kliesch U, Dietz V, Curt A (2006) Impaired facilitation of motor evoked potentials in incomplete spinal cord injury. J Neurology 253:51 – 7
17. Ditunno JF, Young W, Donovan WH, Creasey G (1994) The international standards booklet for neurological and functional classification of spinal cord injury. Paraplegia 32:70 – 80
18. Ellaway PH, Davey NJ, Maskill DW, Rawlinson SR, Lewis HS, Anissimova NP (1998) Variability in the amplitude of skeletal muscle responses to magnetic stimulation of the motor cortex in man. Electroencephalogr Clin Neurophysiol 109:104 – 113
19. Enoka RM (1995) Morphological features and activation patterns of motor units. J Clin Neurophysiol 12:538 – 559
20. Fuller G (2005) How to get the most out of nerve conduction studies and electromyography. J Neurol Neurosurg Psychiatry 76 Suppl 2:41 – 46
21. Hausmann O, Min K, Boni Th, Erni Th, Dietz V, Curt A (2003) SSEP analysis in surgery of idiopathic scoliosis: the influence of spine deformity and surgical approach. Eur Spine J 12:117 – 123

22. Hiersemenzel LP, Curt A, Dietz V (2000) From spinal shock to spasticity: Neuronal adaptations to a spinal cord injury. Neurology 54:1574 – 1582
23. Horwitz NH (1997) Charles S. Sherrington (1857 – 1952). Neurosurgery 41:1442 – 5
24. Hughes JT (1989) The new neuroanatomy of the spinal cord. Paraplegia 27:90 – 8
25. Jones KE, Lyons M, Bawa P, Lemon RN (1994) Recruitment order of motoneurons during functional tasks. Exp Brain Res 100:503 – 508
26. Leinonen V, Maatta S, Taimela S (2002) Impaired lumbar movement perception in association with postural stability and motor- and somatosensory-evoked potentials in lumbar spinal stenosis. Spine 27:975 – 83
27. Li C, Houlden DA, Rowed DW (1990) Somatosensory evoked potentials and neurological grades as predictors of outcome in acute spinal cord injury. J Neurosurg 72:600 – 9
28. Merton PA, Morton MH (1980) Stimulation of the cerebral cortex in the intact human subject. Nature 285:227
29. Mills KR (2005) The basics of electromyography. JNNP 76:32 – 35
30. Morishita Y, Hida S, Naito M, Matsushima U (2005) Evaluation of cervical spondylotic myelopathy using somatosensory-evoked potentials. Int Orthop 29:343 – 346
31. Novak K, de Camargo AB, Neuwirth M, Kothbauer K, Amassian VE, Deletis V (2004) The refractory period of fast conducting corticospinal tract axons in man and its implications for intraoperative monitoring of motor evoked potentials. Clin Neurophysiol 115:1931 – 41
32. Nuwer MR (1999) Spinal cord monitoring. Muscle Nerve 22:1620 – 30
33. Perlik SJ, Fisher MA (1987) Somatosensory evoked response evaluation of cervical spondylotic myelopathy. Muscle Nerve 10:481 – 9
34. Rutz S, Dietz V, Curt A (2000) Diagnostic and prognostic value of compound motor action potential of lower limbs in acute paraplegic patients. Spinal Cord 38:203 – 210
35. Schurch B, Dollfus P (1998) The 'Dejerines': an historical review and homage to two pioneers in the field of neurology and their contribution to the understanding of spinal cord pathology. Spinal Cord 36:78 – 86
36. Yamada T (2000) Neuroanatomic substrates of lower extremity somatosensory evoked potentials. J Clin Neurophysiol 17:269 – 79
37. Yamada T, Yeh M, Kimura J (2004) Fundamental principles of somatosensory evoked potentials. Phys Med Rehabil Clin N Am 15:19 – 42

# 13 Surgical Approaches

Norbert Boos, Claudio Affolter, Martin Merkle, Frank J. Ruehli

## Core Messages

- ✔ Preoperative planning of the procedure is key to surgical success
- ✔ An in-depth knowledge of the surgical anatomy is a prerequisite for successful surgery
- ✔ Detailed anatomical knowledge helps to avoid serious complications
- ✔ Optimal patient positioning is essential to facilitate the approach and avoid complications
- ✔ Use an image intensifier or radiographic control to avoid wrong level surgery
- ✔ A profound anatomical knowledge of screw trajectories is a prerequisite for safe spinal stabilization techniques
- ✔ Computer assisted surgery does not compensate for insufficient anatomical knowledge and can be dangerous in inexperienced hands

## Surgery and Planning

Surgery starts with detailed preoperative planning

Successful surgery always starts with a detailed preoperative planning of the intervention. Although as simple as it is obvious, a profound knowledge of the **surgical anatomy** is the prerequisite to achieving the goals of surgery and helping to avoid serious complications. Surgery is a three-dimensional process and none of the excellent but two-dimensional textbooks can substitute for anatomical dissection studies. The surgeon must always consider possible complications which may require extending the surgical approach or changing the approach site, i.e. a change from posterior to anterior or from one body cavity to another. This necessity regularly occurs and the surgeon needs to be prepared or to arrange for a more experienced surgeon to be on hand in case help is needed.

Patient positioning is key to an excellent outcome

Great care should also be taken to position the patient correctly on the operating table to avoid pressure sores, neural peripheral nerve compression, or pressure on the eyes, which can result in blindness [33, 37, 48, 69]. Insufficient prone positioning of a patient (compressed abdomen) can result in **excessive epidural bleeding**, which may prevent a successful neural decompression. Some elderly patients have reduced shoulder mobility and are unable to abduct and externally rotate the arm. This can cause a significant problem when positioning the patient prone for, e.g. posterior decompression surgery.

This chapter does not substitute for an in-depth study of anatomical or surgical textbooks with detailed descriptions of the surgical anatomy or techniques but aims to review and summarize the most frequently used surgical approaches to the spine.

## Anterior Medial Approach to Cervical Spine

The anteromedial approach is within anatomical planes

The anterior medial approach to the cervical spine was introduced in the late 1950s by Cauchoix [13] and Southwick [63]. This approach has become the gold

standard for the surgical access to the lower cervical spine. It is the most anatomical approach because it accesses the spine through anatomical planes with minimal collateral soft tissue damage.

## Indications

The anterior medial approach to the cervical spine is indicated in cases with a spinal pathology between C3 and T1. However, the anterocaudal surface of the axis can also be reached, which is of relevance in the case of an anterior screw fixation stabilizing a dens fracture. In slim patients with a long neck, the approach can be extended even down to T2. In these cases, a lateral radiograph should be performed prior to surgery to explore the feasibility of the approach (Table 1):

**Table 1.** Indications for the anteromedial approach (C3–T1)

- disc herniation
- spondylotic radiculopathy
- spondylotic myelopathy
- spinal deformities (anterior release)
- cervical fracture/instability
- dens fractures
- tumors
- infections

## Patient Positioning

Recurrent laryngeal nerve lesion is somewhat less frequent on the left side

Before positioning the patient, the decision has to be made whether the anteromedial approach is carried out from the left or the right side. Some right-handed surgeons prefer the right-sided approach for convenience. The left-sided approach is associated with a lower frequency of **recurrent laryngeal nerve lesions** particularly for the approach to the distal (C6–T1) cervical spine [17, 47, 53].

The patient is best positioned on a **horseshoe type headrest** with the head in extension. The shoulders and arms (parallel to the body) are pulled caudally with broad nylon tapes over the acromion to expose as much of the spine as possible for lateral imaging and verification of the level. To allow for this trapping, a footrest

Figure 1. Patient positioning for anterior cervical spine surgery

should be used; otherwise the patient slides down the operating table. In case of cervical fractures, a **Gardner-Wells extension** can be used simultaneously (Fig. 1).

## Surgical Exposure

### Landmarks for Skin Incision

The incision is parallel to the anterior border of the sternocleidomastoideus muscle for multilevel pathology and allows a wide exposure. In cases of one or two level surgery, a transverse incision along a skin fold allows for a minimal access surgery and a better cosmetic result. The horizontal skin incision should be centered directly over the pathology. Anatomical landmarks guiding the placement of the incision are (Fig. 2a):

An image intensifier is used for exact transverse incision placement

- angle/lower border of the mandible (C2)
- hyoid bone (C3/4)
- laryngeal prominence (C4/5)
- thyroid cartilage (C5)
- cricoid cartilage (C6)
- manubrium sterni (T1)

However, image intensifier control is always recommended because the landmarks can be variable.

### Superficial Surgical Dissection

After dissection of the subcutaneous fat, the platysma is preferably incised longitudinally, but transverse dissection is acceptable for better exposure. Underneath the platysma, the superficial layer of the cervical fascia is dissected. The medial border of the **sternocleidomastoid muscle** must be identified to guide the surgeon to the target anatomical plane between (Fig. 2b):

- musculovisceral column (infrahyoid muscles, esophagus, trachea) medially
- neurovascular bundle laterally (carotid artery, internal jugular vein, vagus nerve)

The superficial branch of the ansa cervicalis (anastomosis of the transverse colli nerve and the ramus colli of the facial nerve) is often not identifiable and is therefore difficult to preserve. Far lateral dissection lateral to the sternocleidomastoid muscle should be avoided to preserve the:

Avoid dissection lateral to the sternocleidomastoid muscle

- greater auricular nerve

The dense superficial layer of the cervical fascia is opened with scissors. With small sponge sticks (peanuts) the plane is further developed. Branches of the external jugular vein are ligated or coagulated (if small). The obliquely running **omohyoid muscle** has to be retracted superiorly, inferiorly, or cut (ligated) depending on the necessary exposure (Fig. 2c). After identifying the pulsating carotid artery laterally, the pretracheal lamina of the cervical fascia is incised medial to the neurovascular bundle.

### Intermediate Surgical Dissection

After the opening of the pretracheal fascia, further preparation is done bluntly with peanuts. The deep ansa cervicalis is an anastomosis of the radix inferior (C2 and C3) and radix superior (C1 and C2) and lies under the superior border of the omohyoid muscle. The deep ansa cervicalis has to be retracted cranially or cau-

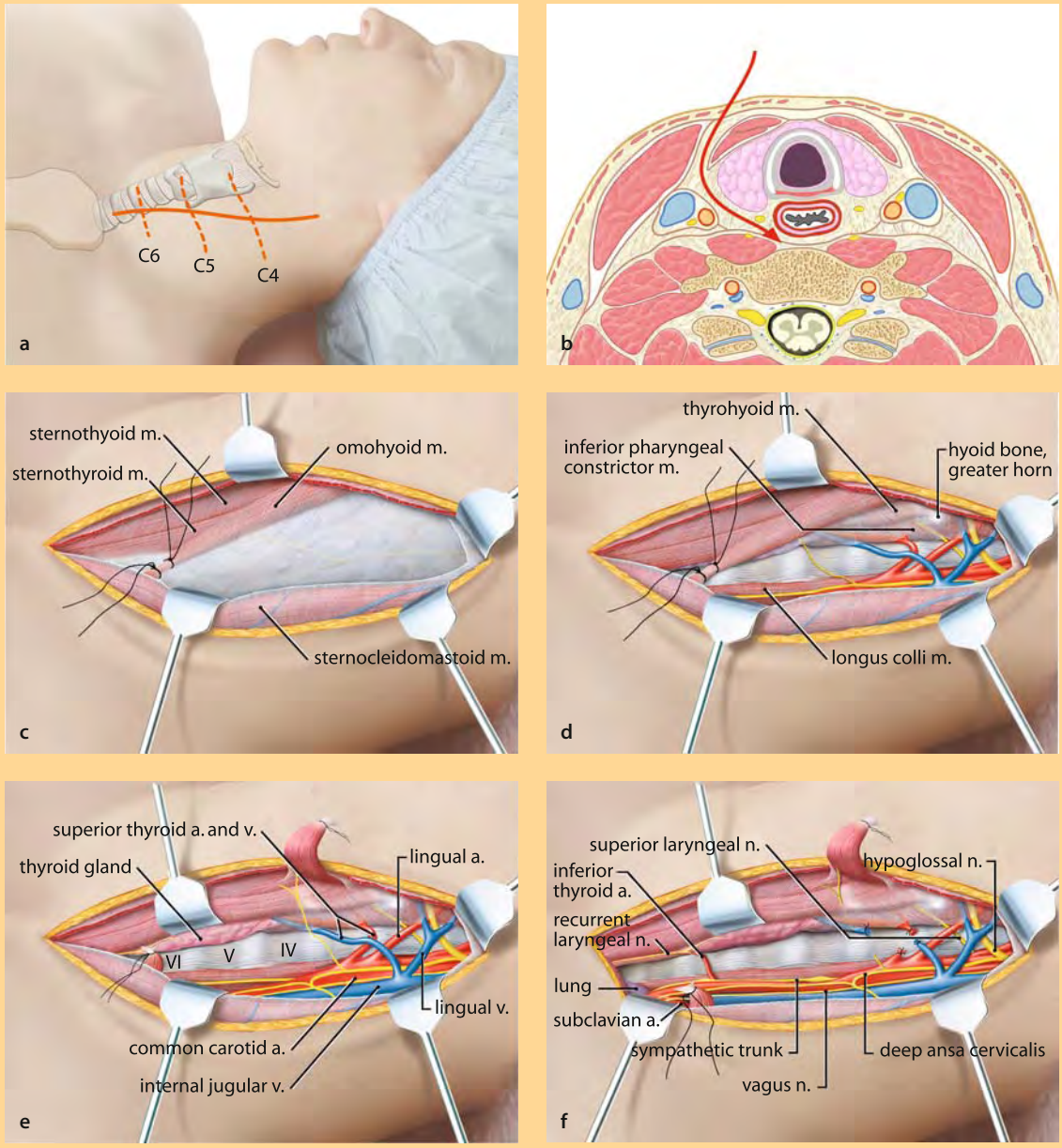


**Figure 2. Surgical anatomy of the anteromedial approach**

a Landmarks for skin incision. b Cross-sectional anatomy at the level of C6. c Superficial dissection. d Intermediate surgical dissection. e Deep surgical dissection. f Deep surgical dissection with exposure of the cervicothoracic junction.

dally. For multilevel exposure of the cervical spine a dissection may be required. Depending on the level of approach, either the superior (level C3–C4) or inferior (level C6–C7) **thyroid vein and artery** have to be identified, retracted either proximally or distally or dissected/ligated for multilevel exposure. For exposure of the upper part of the cervical spine (C4–C2), care must be taken not to injure the:

- hypoglossal nerve
- superior laryngeal nerve

The **hypoglossal nerve** lies medial to the vagal nerve and internal carotid artery close to the angle of the mandible. The nerve passes from laterally to medially and lies anterior to the lingual and facial artery (arcus hypoglossi). It reaches the tongue muscles over the anterior border of the hypoglossal muscle. If necessary, the lingual and facial artery (branches of the external carotid artery) can be ligated. However, they protect the hypoglossus nerve from too much tension and should therefore be preserved if possible. The **superior laryngeal nerve** lies medial to the internal carotid artery and separates into an external ramus (constrictor pharyngis inferior and cricothyroid muscle) and an internal ramus to the mucosa of the larynx (Fig. 2d).

Injury to the superior laryngeal nerve is a frequent cause of dysphagia

### Deep Surgical Dissection

The prevertebral fascia is exposed by retracting the musculovisceral column medially and the neurovascular bundle laterally. During this step, injury can occur to the:

- recurrent (inferior) laryngeal nerve

The **inferior laryngeal nerve** originates from the vagus nerve with a different course for each side. While the right-sided nerve crosses around the subclavian artery and takes a more anterolateral and vertical course, the left-sided nerve courses around the aortic arc and reaches the musculovisceral bundle more distally. Therefore, retraction of the musculovisceral column exposes the nerve to less tension on the left than on the right side [17, 47, 53].

The inferior laryngeal nerve exhibits a different course for each side

After a longitudinal incision of the prevertebral fascia of the cervical spine, the anterior longitudinal ligament is exposed in the midline. The longus colli muscle is elevated and retracted laterally to expose the vertebral bodies and intervertebral discs. Too far lateral exposure under the longus colli may jeopardize the vertebral artery, which usually enters the cervical spine at C6 [16, 57, 71]. The **sympathetic trunk** lies in the prevertebral fascia in front of the longus colli muscles and can be injured when stripped off the longus colli muscle to dissect the vertebrae and discs (Fig. 2e). Damage to the sympathetic trunk can lead to the development of a **Horner's syndrome** (i.e. ptosis, meiosis, and anhidrosis) [47].

Damage to the sympathetic trunk may result in Horner's syndrome

The distal angle of the exposure is limited by the level of the manubrium sterni in relation to the spine. In patients with a long neck, T2 can be reached by this approach. However, the maximum caudal exposure is limited by the great vessels of the mediastinum, which are situated in front of T3 [25]. When exposing the vertebral bodies and discs below C7, care must be taken not to injure the **thoracic duct** and the **pleura** (Fig. 2f).

### Wound Closure

The anterolateral approach is an anatomical approach achieved mainly by blunt dissection, which facilitates wound closure. The wound is closed by suturing the platysma, the subcutaneous tissue layer and the skin. Because large vessels are being dissected and ligated, there is a risk of recurrent bleeding. Such a hematoma can rapidly compress the trachea and make reintubation of the patient impossible. Therefore, a prevertebral suction drainage is mandatory, which needs to be sutured to avoid the loss of the drainage during transfer.

Always use prevertebral suction drainage

## Pitfalls and Complications

The most frequent pitfall in the approach to the cervical spine is the inappropriate level of approach. Therefore, we recommend using an image intensifier for

Identify and regularly check the pulsation of the carotid artery

level localization. The structures at risk during this approach have been listed above. A deleterious pitfall is the risk of unintentionally retracting the **carotid artery** medially instead of laterally. Therefore, the pulse of this artery must be palpated to ensure that the artery is indeed lateral.

The overall risk of operative complications remains small but significant [72]. In 450 cases of anterior cervical discectomy, the rates of recurrent nerve palsy and Horner's syndrome were 1.3 % and 1.1 %, respectively [9]. However, the true rate of nerve root injury based on laryngoscopy is substantially higher (24 %) [34]. Apfelbaum suggested monitoring endotracheal tube (ET) cuff pressure and release of the pressure after retractor replacement or repositioning has been used, which enables the ET to be recentered within the larynx [4]. The natural history of a **recurrent nerve lesion** is benign [34]. Complete recovery of vocal cord function was documented in 26 (93 %) of 28 patients who had undergone a thyroidectomy [46]. **Dysphagia** is a not uncommon problem after anterior cervical spine surgery. Overall the incidence of dysphagia 2 years after anterior cervical spine surgery was 13.6 % based on the analysis of 348 cases [43]. Risk factors for long-term dysphagia after anterior cervical spine surgery include gender, revision surgery, and multilevel surgery. The use of instrumentation, higher levels, or corpectomy versus discectomy did not significantly increase the prevalence of dysphagia [43]. **Vertebral artery injury** is a rare (0.3 %) complication in cervical discectomy [10]. However, in a report on 185 corpectomies, the vertebral artery was injured in four patients [18].

## Posterior Approach to the Cervical Spine

The anterior and posterior approaches are both frequently used to approach the cervical spine in a variety of disorders [58]. However, usually the anterior approach is preferred because of the minimal collateral soft-tissue damage. The posterior approach necessitates dissecting the neck muscles, which can be related to persistent postoperative neck pain.

### Indications

The posterior approach to the cervical spine is predominantly indicated in cases with multisegmental degenerative changes or with craniocervical disorders (Table 2):

**Table 2.** Indications for the posterior approach to the cranio-cervical-thoracic spine (C0–T)

- spondylotic radiculopathy
- spondylotic myelopathy
- cervical instability in rheumatoid arthritis
- multisegmental degenerative changes
- spinal deformities
- cervical fracture/instability
- chronic dens fractures
- tumors
- infections

### Patient Positioning

A Mayfield clamp is preferred for the headrest/fixation

The positioning of the patient in the prone position is best accomplished using a **Mayfield head clamp** (Fig. 3). The clamp is applied before turning the patient into the prone position. This fixation avoids pressure sores on the face, which are not infrequent when using other types of headrest (e.g. the horseshoe type). We use a carbon fiber clamp, which allows for anteroposterior imaging. The shoulders

**Figure 3. Patient positioning for posterior cervical spine surgery**

Positioning of the patient with a Mayfield clamp and electrodes on the head for neuromonitoring.

and arms (parallel to the body) are pulled down using nylon tapes to expose the cervical spine as much as possible. A footrest allows the whole table to be tilted head up, which accommodates the surgical approach.

## Surgical Exposure

### Landmarks for Skin Incision

The landmarks of skin incision are:

- external occipital protuberance
- spinous processes C2–C7

The skin incision is along the midline from the external occipital protuberance towards caudal depending on the target region. When a short level exposure is attempted, image intensifier control is recommended to avoid unnecessary detachment of the posterior spinal muscles (Fig. 4a).

### Superficial Surgical Dissection

After skin incision and splitting of the subcutaneous tissue, the superficial surgical dissection should first identify the nuchal ligament. With a diathermy knife the muscles are detached subperiosteally from the spinous process. The superficial muscle layer consists of (Fig. 4b):

- trapezius muscle
- posterior serratus muscle
- splenius capitis muscle

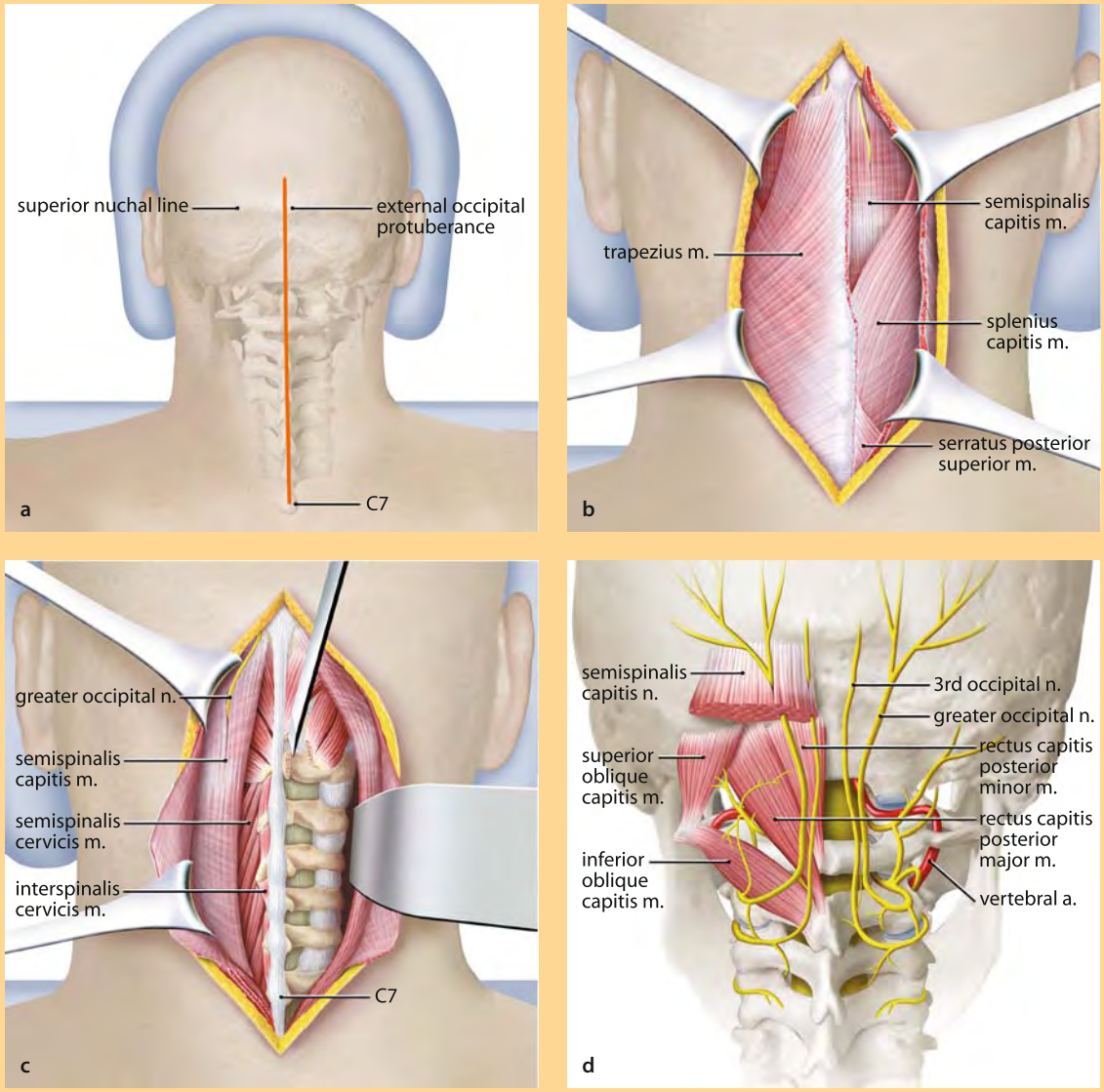


**Figure 4. Surgical anatomy of the posterior cervical approach**

a Landmark for skin incision. b Superficial and intermediate muscle layers. c Exposure of the craniocervical junction with osteotomy of the spinous process for osteoligamentous muscle detachment. d Surgical anatomy at the craniocervical junction.

The posterior cervical exposure can lead to significant bleeding

The intermediate muscle layer consists of:

- semispinalis capitis muscle

After sharp detachment the muscles are pushed laterally as one conglomerate with sponge rolls using a Cobb raspatory. Dissection of each muscle layer is unnecessary. In some patients, heavy bleeding is encountered which has to be borne in mind when performing this approach. Dense packing of the space between the spinous process and the laterally retracted muscles helps to control the bleeding. When the spine is exposed the bleeding usually stops, i.e. bleeding vessels can easily be identified and coagulated. During the superficial dissection

care has to be taken not to injure the **greater occipital nerve** (Fig. 4b), necessitating a midline approach.

### Deep Surgical Dissection

For exposure of the craniocervical junction, it is recommended to osteotomize with a chisel (or oscillating saw) the muscle insertion of the deep muscle layer from the spinous process of C2 (Fig. 4c). The deep muscle layer consists of cranially:

- rectus capitis posterior major and minor muscle
- oblique capitis inferior muscle

and caudally:

- multifidus muscle
- semispinalis cervicis muscle

The rationale for an osseous detachment is the better refixation of these muscles to counteract postoperative kyphosis.

When exposing the craniocervical junction (Fig. 4d), care has to be taken not to injure the:

Exposure of the atlantoaxial joint jeopardizes the 2nd cervical nerve

- vertebral artery
- second cervical nerve (greater occipital nerve)
- third cervical nerve

The vertebral artery turns around the lateral mass of the atlas from lateral to medial and disappears into the foramen magnum through the atlanto-occipital membrane. The **second cervical nerve** exits the spinal canal medial to the facet joint, crosses that joint posteriorly in a horizontal direction and curves around the oblique capitis inferior muscle before it runs cranially to innervate the occipital skin. The **third cervical nerve** exits the foramen and separates the posterior ramus, which runs medial to the second cervical nerve on its course to the occiput.

### Wound Closure

In cases in which the insertion of the neck muscles has been detached from the tip of the spinous process with an osteoligamentous flap, a transosseous suture of the detached muscle is done with a slowly dissolving suture. The wound is closed with one or two subfascial suction drainages. The fascia, subcutaneous tissue and skin are sutured in separate layers.

## Pitfalls and Complications

Exposure of C1 can cause vertebral artery injury

The vertebral artery is at risk when a sublaminar wire is passed around the arch of C1. It is therefore mandatory to start in the midline to subperiosteally liberate the atlanto-occipital membrane from the bone with a blunt probe before the wire is passed with a wire passer (Dechamps). During the exposure of the atlantoaxial joint, the second cervical nerve is endangered because of its horizontal course over the posterior aspect. The craniocervical junction is highly vascularized by a large venous plexus. Blind coagulation may jeopardize the second or third cervical nerve.

## Right-Sided Thoracotomy

The thoracotomy approach for the treatment of spinal disorders has been pioneered by Capener [12] and Hodgson [19, 31, 32]. Today, it has become a stan-

If not determined by the pathology, the right sided approach is preferred

dard approach for the treatment of thoracic spinal disorders including deformity, tumor or infection. In deformity surgery, the approach is always on the side of the apex of the curve, i.e. a right-sided thoracotomy is chosen for a right-sided curve. In cases in which the spinal pathology does not dictate the side of the thoracotomy, the **right side** is preferred because of the contralateral position of the aorta.

## Indications

The indication for a thoracotomy is a spinal pathology located between T4 and T10 (Table 3):

**Table 3.** Indications for a thoracotomy (T4–T11) and thoraco-phrenico-lumbotomy (T9–L5)

| | |
|---|---|
| • spinal deformities | • thoracic fractures/instabilities |
| • degenerative disorders | • tumors |
| | • infections |

## Patient Positioning

The patient is positioned in a left-sided decubitus position on a soft rubber mattress. Alternatively, a **vacuum mattress** can be used which is helpful in large patients and better stabilizes the patient. Both arms are positioned at 90 degrees elevation and flexion of the elbow (Fig. 5a, b). The legs are positioned straight with the right leg on top of the left leg. We use a foam rubber block with a cavity for the lower leg. The right leg can then easily be positioned on top of the block. The symphysis and the sacrum are supported by pads to avoid the patient rolling over.

## Surgical Exposure

### Landmarks for Skin Incision

Double-check the correct side of the thoracotomy

A deleterious complication is a wrong side thoracotomy. Therefore, it is mandatory to double-check the side of the thoracotomy at the beginning of the surgery.

Furthermore, it is of great importance to center the incision over the pathology and correctly select the target rib or the intercostal space. The relationship between the intercostal space and the vertebral level is dependent on how oblique or horizontal the ribs curve to the sternum (Fig. 6a). As a **rule of thumb**, the rib resected determines the highest vertebral level which can be reached (e.g. resection of the 7th rib allows T7 to be reached). It best exposes the vertebra two levels below the origin of the resected rib (e.g. resection of the 7th rib allows the best exposure of T9). This is crucial when a mini-open exposure is attempted. Because of the variant forms of the ribcage, we recommend checking the correct level with an image intensifier. Nothing jeopardizes the success of an operation so much as an inappropriate exposure.

Image intensifier control optimizes the spinal access

### Superficial and Intermediate Surgical Dissection

The skin incision ranges from the lateral border of the paraspinous musculature to the sternocostal junction of the rib which has to be resected. After the incision of the subcutaneous tissue, the latissimus dorsi muscle and the anterior serratus muscle also have to be divided over the course of the target rib with a diathermy

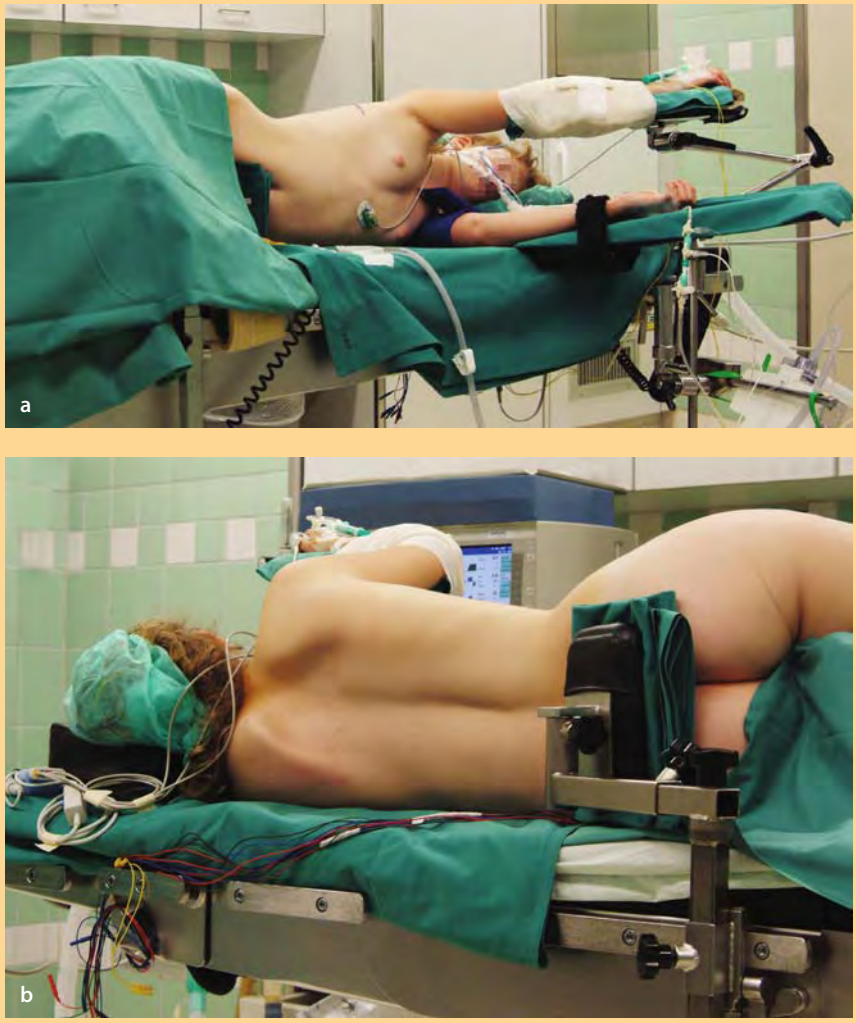


**Figure 5. Patient positioning for right-sided thoracotomy**

a Anterior view. b Posterior view.

knife. It is recommended to only partially transect the latissimus dorsi muscle and lift it off the ribcage with a Hohman retractor (Fig. 6b). When exposing the anterior part of the ribcage, care should be taken to spare the:

- long thoracic nerve (innervates the serratus muscle)

Therefore, the **serratus muscle** should be dissected as far distally as possible. This is particularly important when high thoracic levels are exposed.

The periosteum of the rib is dissected in the middle of the rib and liberated with a blunt dissector. A rib stripper is used to further liberate the rib. The rib is cut with a rib cutter as far posteriorly and anteriorly as possible to allow for a good exposure. When a thoracotomy is done with preservation of the rib, the intercostal muscle layer is cut in the lower half to preserve the neurovascular bundle which lies directly below the inferior edge.

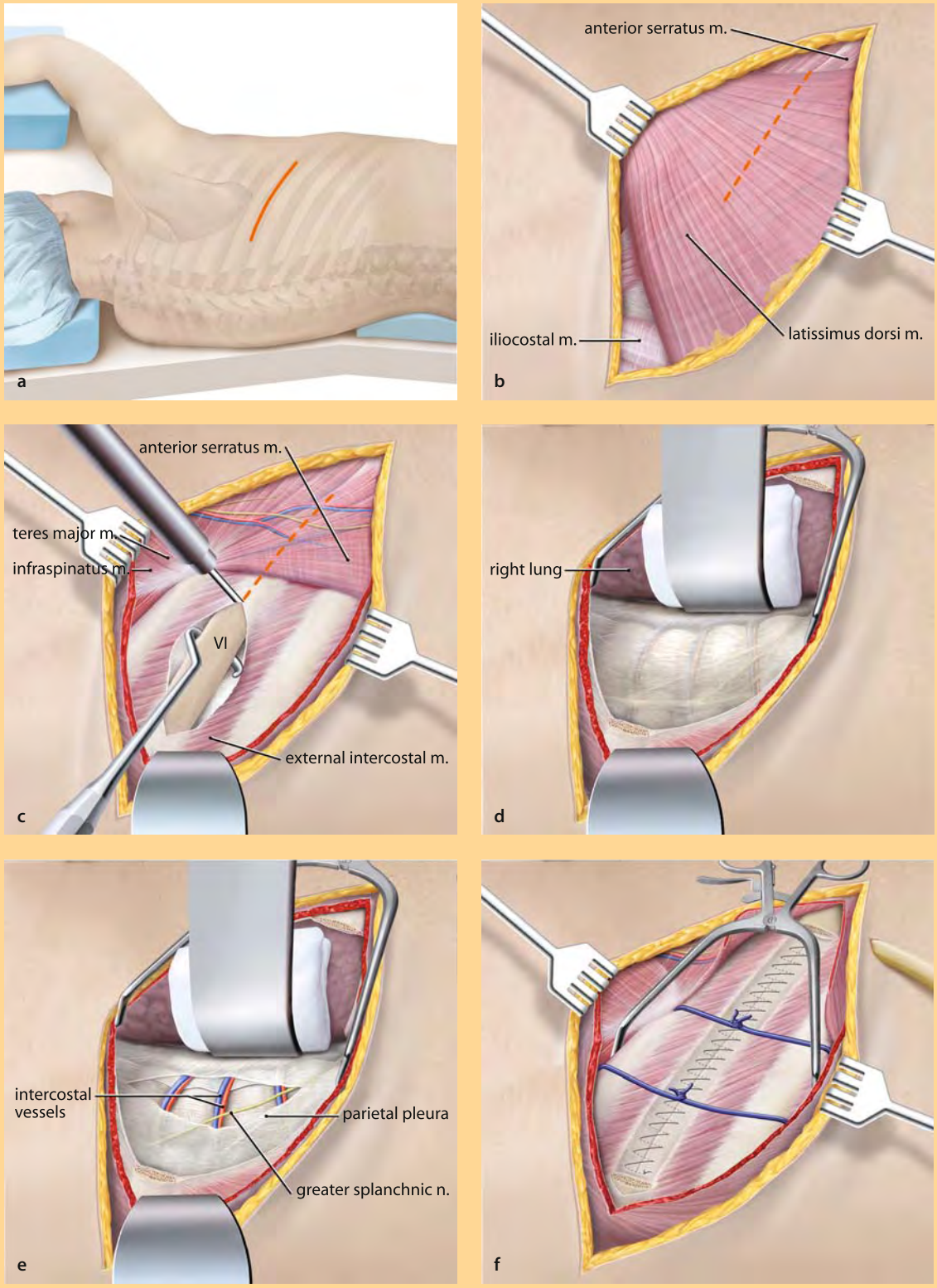


**Figure 6. Surgical anatomy for right-sided thoracotomy**

a Landmark for skin incision. b Superficial dissection. c Dissection of the rib for resection. d Exposure of the anterior spinal column. e Deep surgical dissection with ligation of the segmental vessels. f Insertion of a thorax drain and closure of the thorax.

### Deep Surgical Dissection

The parietal pleura is picked up with anatomical tweezers and opened with scissors. Depending on the necessary exposure, the anesthetist may then deflate the lung. The intercostal space is widened with a rib spreader (Fig. 6d). The lung can be covered with an abdominal towel and retracted. The anterior vertebral column becomes visible. The parietal pleura is lifted off the vertebral column with anatomical tweezers and opened to expose the segmental vessels (Fig. 6e). The **segmental vessels** are mobilized with an overhold and ligated 3–4 cm anterior to the rib head. In severe spinal deformities the segmental vessel can first be clamped to see whether a ligation has an influence on the blood supply of the spinal cord, which would result in a decrease in evoked potentials (neuromonitoring). A sponge stick is used to further expose the vertebral bodies and intervertebral discs.

### Wound Closure

Close the parietal pleura whenever possible

The parietal pleura is sutured whenever possible and it is attempted to cover the implant with pleura. Before closing, one or two **thorax drains** are inserted. We recommend using large rather than small drains particularly when significant bleeding has occurred. Small drains are easily blocked by blood coagula. The skin is incised about one level below the target intercostal level in order to allow for an anatomical closure when removing the drain. A large towel clamp is inserted through the wound to pick up the drain and pull out the drain from the inside. The drain is manually placed at the apex of the thorax rather anteriorly. Depending on the bleeding, we prefer to insert a second drain, which is placed over the spine posteriorly. A rib approximator is used to narrow the ribs and fix them with a suture running around both ribs including the intercostal soft tissue but avoiding the neurovascular bundle (Fig. 6f). We recommend placing all sutures first before tightening them. At this stage, the anesthetist is asked to reinflate the lung. Care has to be taken that all parts of the lung are inflated to avoid atelectasis. If parts of the lung are not inflatable, a gentle manual massage of the lung tissue usually resolves this problem. The muscle and soft tissue layers covering the ribcage are sutured sequentially.

## Pitfalls and Complications

We have already mentioned the deleterious pitfall of opening the thorax on the wrong site (**wrong site surgery**). The anterior approach to the spine carries a higher risk of serious complications than the posterior route for obvious reasons. The **most frequent problems** associated with this approach are:

- access through an intercostal space too high or too low in relation to the main pathology
- injury to the lung when incising the rib bed or opening the pleura
- injury to segmental vessels when exposing the spine
- injury to the azygos vein and aorta
- dissection into the intervertebral foramen

Details on the handling of complications associated with this approach are covered in Chapter 39.

## Left-Sided Thoraco-Phrenico-Lumbotomy

This approach gives excellent access to the thoracolumbar junction

This approach was introduced to spinal surgery by Hodgson mainly in the context of spinal tuberculosis [31, 32]. Similarly to a thoracotomy, an approach to the thoracolumbar junction is possible from the left as well as from the right side. When the pathology does not dictate the side of the approach, an access from the **left side** is preferred because the liver and the inferior vena cava are not hindering the approach [11].

### Indications

If not determined by the pathology, the right sided approach is preferred

The indication for a thoraco-phrenico-lumbotomy is a spinal pathology located between T9 and L5 and similar to those of a thoracotomy (Table 3).

### Patient Positioning

The patient is positioned on the right side inversely to a right-sided thoracotomy (Fig. 7a, b). The table can be slightly bent above the level of the pelvis to increase the distance between pelvis and ribcage.

### Surgical Exposure

#### Landmarks for Skin Incision

Depending on the target level, it is usually recommended to resect the 10th rib (T10–L5). In cases with more proximal pathology, the 9th rib can be resected (T10–L5) (Fig. 8a).

#### Superficial Surgical Dissection

After the incision of the skin and the subcutaneous tissue at the thoracolumbar junction, the superficial muscle layer is exposed consisting of (Fig. 8b):

- serratus anterior muscle
- latissimus dorsi muscle
- external oblique muscle

Whenever possible the muscles should be split in the direction of the fibers.

#### Intermediate Surgical Dissection

We recommend starting with the retroperitoneal approach. After splitting the external oblique muscle, the internal oblique and transversus muscles are split. With sponge sticks the peritoneal sac is mobilized to the midline and freed from the diaphragma. In a next step, the 9th or 10th rib is resected similarly to the method described above (Fig. 6c). The anterior resection is done close to the osseous-cartilage transition of the rib. The costal cartilage is split and the diaphragma is transected circumferentially about 2 cm medial to its insertion at the thorax wall. It is strongly recommended to use holding sutures bilateral to the transection to allow for a better orientation during diaphragma repair (Fig. 8d, e).

**Figure 7. Patient positioning for left-sided thoraco-phrenico-lumbotomy**

a Anterior view. b Posterior view.

### Deep Surgical Dissection

The left crus of the diaphragma is transected about 2 cm above the medial and lateral arcuate ligament. The parietal pleura is incised at the thoracic level as described above. The attachments of the psoas muscle need to be mobilized posteriorly. The vertebrae and intervertebral discs are further exposed with sponge sticks and rasps. The segmental vessels need to be ligated at the target level.

### Wound Closure

At the thoracic level, the parietal pleura needs to be sutured. The repair of the diaphragma is facilitated when bilateral stay sutures were used during prior dis-

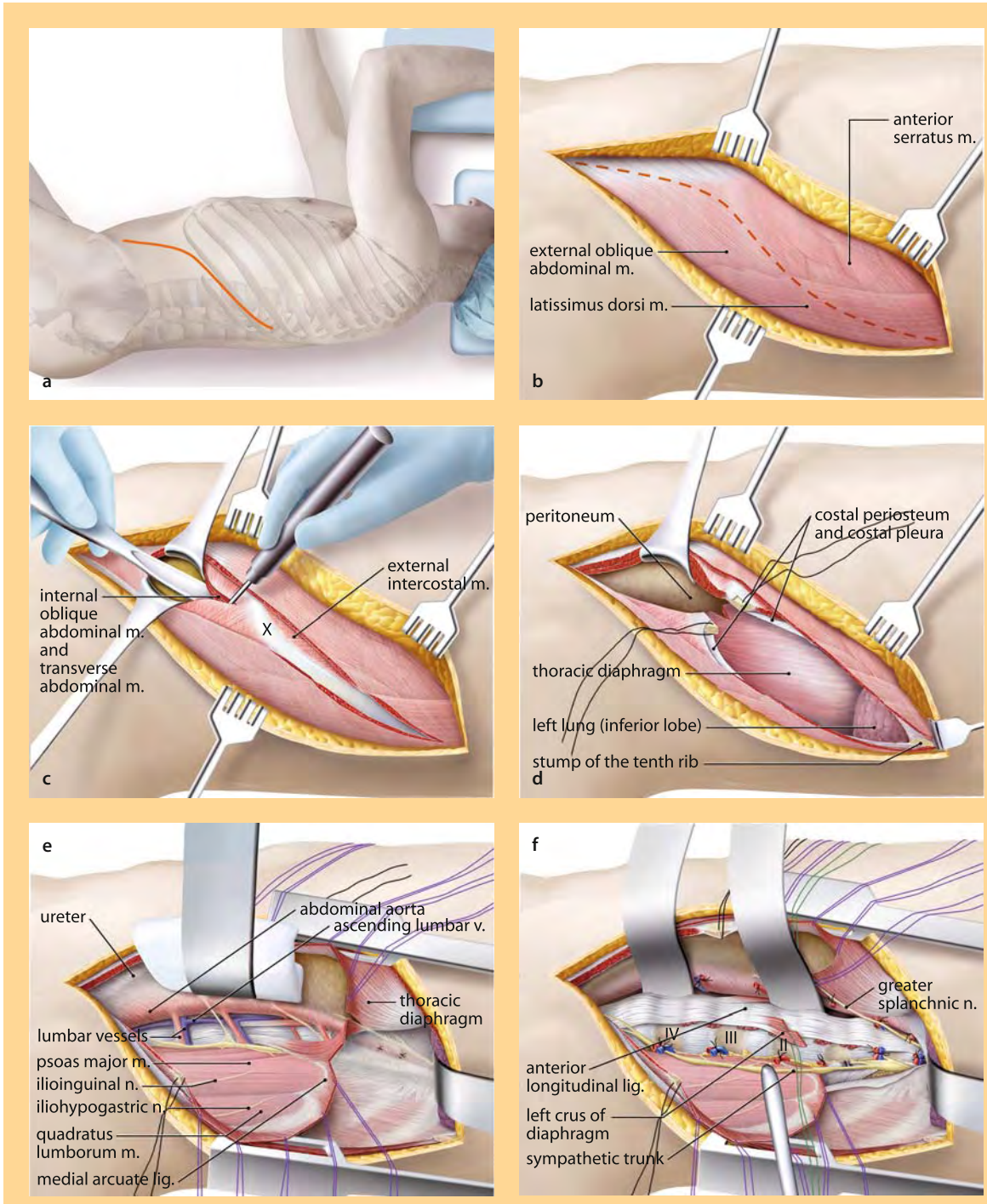


**Figure 8. Surgical anatomy for left-sided thoraco-phrenico-lumbotomy**

a Landmark for skin incision. b Superficial dissection. c Dissection of the rib for resection (see Fig. 6c). d The rib cartilage is split and marked with stay sutures. e The diaphragm is split about 2 cm medial to its rib insertion. f The medial and lateral crus of the diaphragm are transected and marked with stay sutures. The segmental vessels are ligated. The thoracic exposure is shown in Fig. 6d, e.

section. After repair of the diaphragma, the rib cartilage halves are refixed. The thorax is closed as described above. The abdominal wall is sutured in three separate layers (transverse, internal and external oblique muscles).

## Pitfalls and Complications

Injuries to the thoracic duct can result in a chylothorax

A frequent complication is to accidently open the peritoneal sac during dissection of the diaphragma. This can be avoided when the preparation of the two body cavities is started from the abdominal site and the peritoneum freed from the diaphragma. When taking the diaphragma down to its insertion at the spine, care has to be taken not to injure the:

- greater splanchnic nerve
- ascending lumbar vein
- sympathetic trunk
- thoracic duct (rarely visible during preparation)

A detailed discussion of the complications associated with this approach is included in Chapter 39.

# Anterior-Lateral Retroperitoneal Approach to L2–L5

The anterolateral retroperitoneal lumbar approach is easily applicable even in obese patients

The anterior-lateral retroperitoneal approach to the lumbar spine has been an established operative technique since the early 1960s. This approach can be carried out also from the right side. The left sided approach, however, is favored because the inferior vena cava is less at risk. This approach is easy to perform even in obese patients because the abdomen is hanging to the side and the flank is exposed.

## Indications

Indications for this approach are spinal disorders located between L2 and L5 (Table 4):

**Table 4.** Indications for a retroperitoneal lumbotomy (L2–L5)

| | |
|---|---|
| • spinal deformities | • lumbar fractures/instabilities |
| • degenerative disorders | • tumors |
| | • infections |

## Patient Positioning

For this approach the patient is positioned on the right side similarly to as performed for the thoraco-phrenico-lumbotomy (Fig. 7a, b).

## Surgical Exposure

### Landmarks for Skin Incision

We favor a mini-open approach to the lumbar spine, which necessitates image intensifier localization of the skin incision. With a 6- to 8-cm incision, a two-level fusion can be done without difficulty when using a retractor frame. The skin incision is done in the fiber direction of the external oblique muscle (Fig. 9a).

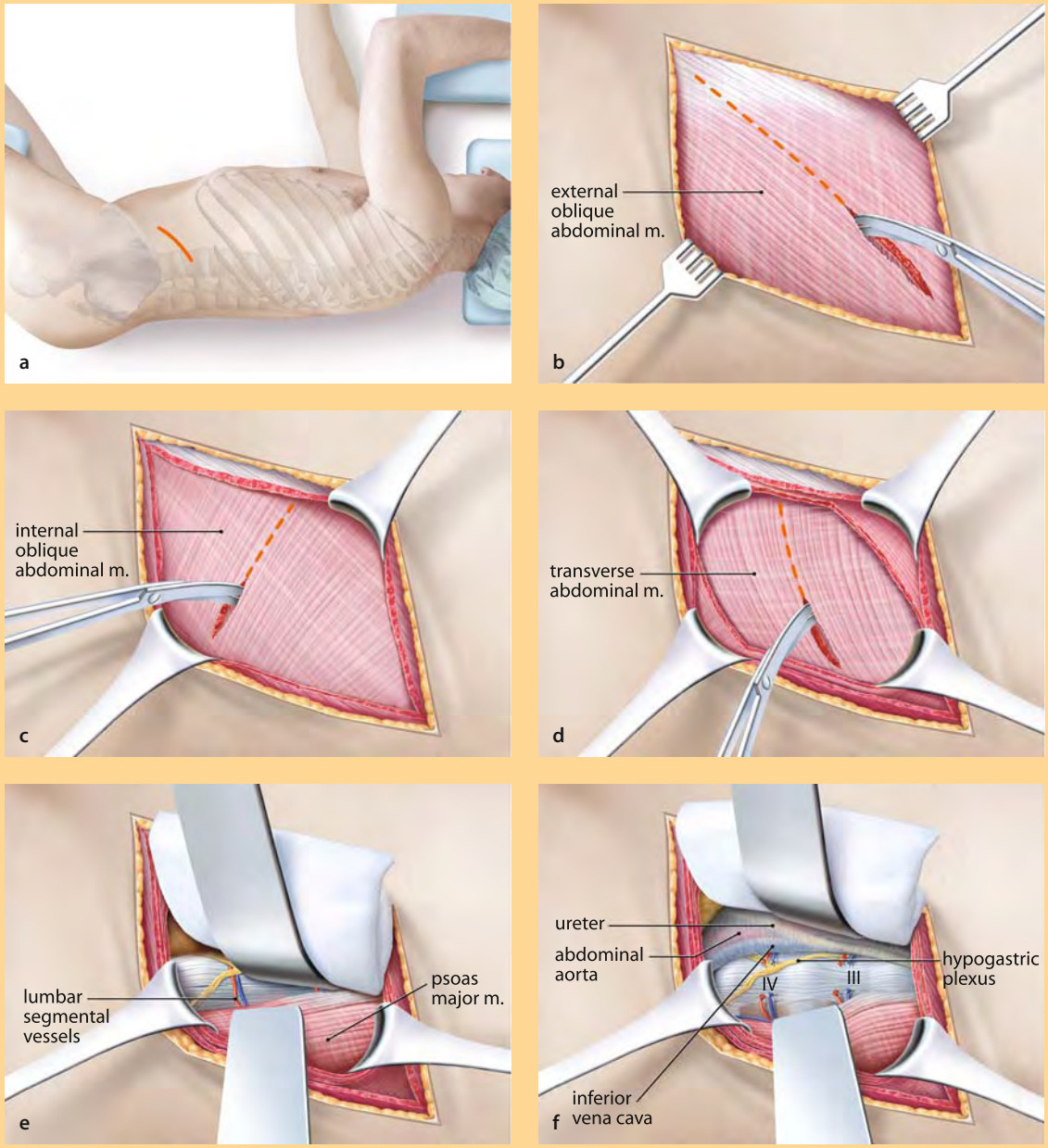


**Figure 9. Surgical anatomy for the anterior-lateral retroperitoneal approach to L2–L5**

a Landmarks for skin incision. b, c, d Transsection of the external oblique, internal oblique and transverse muscles. e Retraction of the psoas muscle exposing the vertebral column. f Medial retraction of the peritoneal sac exposing the large abdominal vessels. Ligation of the segmental vessel.

### Superficial Surgical Dissection

A muscle splitting approach is preferred

After the incision of the skin and the subcutaneous tissue, the three layers of the abdominal wall:

- external oblique muscle (Fig. 9b)
- internal oblique muscle (Fig. 9c)
- transversus muscle (Fig. 9d)

are separated in the direction of their fibers.

### Deep Surgical Dissection

With sponge sticks the peritoneal sac is mobilized in the medial direction to free the psoas muscle and the anterior spinal column. The peritoneal sac can be covered with a moistened abdominal towel. The paravertebral sympathetic chain medial to the psoas muscle as well as the ureter need to be identified and retracted together with the peritoneum carefully in a medial direction. The psoas is mobilized from the spine and retracted posteriorly. The **genitofemoral nerve** which lies on the anteromedial side of the psoas muscle needs to be preserved. Care has to be taken not to injure the segmental or great vessels anteriorly while liberating the spine with sponge sticks. Special attention has to be paid to the **iliolumbar vein** at level L4–L5, which requires ligation if it limits the mobilization of the common iliac vein. In men, the psoas muscle can be very big and covers almost the whole lateral aspect of the vertebra. In these cases, a **psoas splitting approach** can be used to approach the intervertebral discs for a fusion [8]. The latter approach is less suited to a complete corpectomy.

Take care with the iliolumbar vein when retracting the large vessels medially

### Wound Closure

Each layer of the abdominal wall needs to be sutured separately. Suction drainage is usually not needed.

## Pitfalls and Complications

Care has to be taken not to injure the:

- segmental vessels
- ascending lumbar vein
- iliac vein and artery
- genitofemoral nerve on the anteromedial side of the psoas muscle
- paravertebral sympathetic chain
- ureter (slightly attached to the peritoneum)

A detailed description of the management of complications is outlined in Chapter 39.

# Anterior Lumbar Retroperitoneal Approach

## Indications

The anterior lumbar retroperitoneal approach is indicated for spinal pathology located between S1 and L3. The indications are similar to those for the lumbotomy with the exception that the approach exposes the spine at S1–L2 (Table 4).

## Patient Positioning

The patient is positioned supine with both arms abducted. The table can be slightly bent at the level of the pelvis. The positioning should be done in a way to allow the application of a table mounted retractor system, which facilitates the spinal exposure (Fig. 10).

**Figure 10. Patient positioning for an anterior retroperitoneal approach**

A table mounted retractor facilitates the approach.

## Surgical Exposure

### Landmarks for Skin Incision

Landmarks for the skin incision are the umbilicus, symphysis and iliac wings. The umbilicus frequently projects onto the L4 level. However, this landmark is largely variable and necessitates image intensifier control to allow for a minimal length skin incision. The skin incision lies usually in the midline. Approaches to the L3/4 disc space, however, necessitate extending the incision above the level of the umbilicus. In these cases, we recommend using a slightly parasagittal incision (Fig. 11a).

### Superficial Surgical Dissection

After skin incision and dissection of the subcutaneous tissue, the anterior rectus sheath is exposed over a length of 6–8 cm and opened 2 cm lateral to the midline (Fig. 11b). The underlying rectus muscle is retracted laterally exposing the posterior rectus sheath and the arcuate line (Fig. 11c). The peritoneal sac is mobilized medially below the arcuate line. The peritoneal sac is adherent to the inferior surface of the posterior rectus sheath and needs to be liberated from it to allow further retraction. After liberation, the posterior rectus sheath is incised about 2 cm medial to the abdominal wall and the peritoneum can be further retracted over the midline (Fig. 11d).

### Deep Surgical Dissection

At depth, the bifurcation is often visible with a medial sacral artery and vein. Depending on the size of the vessels, a ligation is necessary. Coagulation at the disc level should be avoided to preserve the presacral sympathetic plexus. In males, damage to the sympathetic plexus may result in a retrograde ejaculation. The **L5/S1 disc** is exposed between the bifurcation (Fig. 11e) by slightly mobilizing the vessels to both sides. Manipulation at the bifurcation should be done very carefully (if needed) to avoid injuries to the vessels, which are difficult to repair.

The ascending lumbar vein is at risk when retracting the common iliac vein medially

The **L4/5 disc** space or levels above are exposed by retracting the left common iliac vein and artery to the contralateral side (Fig. 11e). During this maneuver, great care has to be taken not to tear the ascending lumbar vein from the common iliac vein. We recommend exposing the ascending lumbar vein and ligating it before retracting the vessels to the contralateral side. The paravertebral sympathetic chain lies medial to the psoas muscle and should be mobilized laterally while the ureter together with the peritoneum is retracted medially.

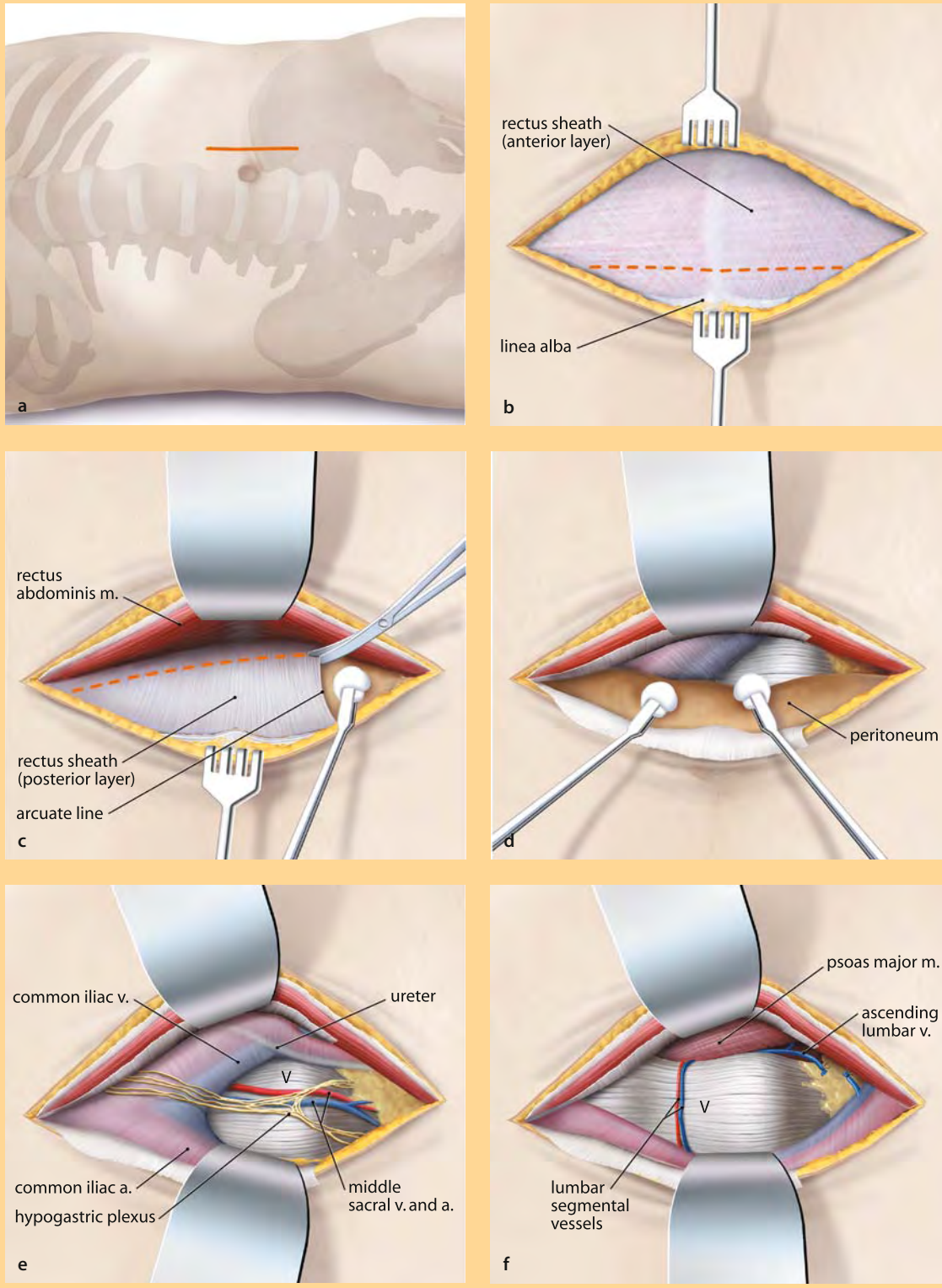


**Figure 11. Surgical anatomy of the anterior retroperitoneal approach**

a Landmarks for skin incision. b Exposure of the anterior rectus sheath. c Dissection of the posterior rectus sheath close to the abdominal wall (arcuate line). d Exposure of the anterior spinal column. e Deep surgical dissection at the L5/S1 level accessing below the bifurcation. f Deep surgical dissection at the L4/5 level retracting the common iliac artery and vein medially.

### Wound Closure

The posterior rectus sheath should be readapted if possible. Interrupted sutures are placed in the anterior rectus sheath using slowly dissolving sutures. We do not routinely use a suction drainage.

## Pitfalls and Complications

Care has to be taken not to injure the:

- segmental vessels
- ascending lumbar vein
- common iliac vein and artery
- paravertebral sympathetic chain
- ureter (slightly attached to the peritoneum)

Injury to the sympathetic chain can result in retrograde ejaculation in males

Injuries of the **sympathetic chain** may result in retrograde ejaculation (in males) or a sympathectomy syndrome with disturbed capability for vasoconstriction. This may result in the feeling of a hot (ipsilateral) or cold (contralateral) leg or foot, respectively. Weakness of the abdominal wall particularly in multiparas can result in abdominal herniations and needs to be repaired. A detailed description of the management of complications is provided in Chapter 39.

## Posterior Approach to the Thoracolumbar Spine

The posterior approach has been the most commonly used access to the spine since the 1950s. The exposure is straightforward but the collateral damage to the muscle is not negligible [23, 24, 39, 40]. Wiltse et al. [68] and Fraser et al. [21] have therefore suggested a so-called "**muscle splitting approach**" which can be used when midline exposure is not necessary for decompression, e.g. for posterolateral fusion of a spondylolisthesis. Minimal-access surgery is preferred whenever possible. The target level should be determined with image intensifier to expose the spine only as much as is needed.

## Indications

There are a wide variety of indications for this approach (Table 5):

**Table 5.** Indications for the posterior approach to the thoracolumbar spine

- spinal stenosis
- disc herniation
- painful motion segment degeneration
- spinal deformities
- thoracolumbar fracture/instability
- tumors
- infections

## Patient Positioning

An unobstructed abdomen is key to successful decompressive surgery

The patient is positioned prone on rubber foam blocks (Fig. 12a). A headrest with support for mouth, nose and eyes is used to avoid pressure sores (Fig. 12b). It is important that the abdomen is freely hanging and not compressed (Fig. 12c). This is particularly important for decompressive surgery where a compressed abdomen can result in congested epidural veins and result in excessive bleeding.

**Figure 12. Patient positioning for a posterior thoracolumbar approach**

a Rubber foam blocks supporting the patient in prone position. b Headrest. c Positioning of the patient with free hanging abdomen.

## Surgical Exposure

### Landmarks for Skin Incision

The landmarks for the posterior approach are:

- spinous processes
- posterior superior iliac spine
- iliac wings

The line drawn between the bilateral posterior superior iliac spine usually projects to the disc level of L4–L5 (Fig. 13a). However, this is unreliable and image intensifier control is necessary in every case.

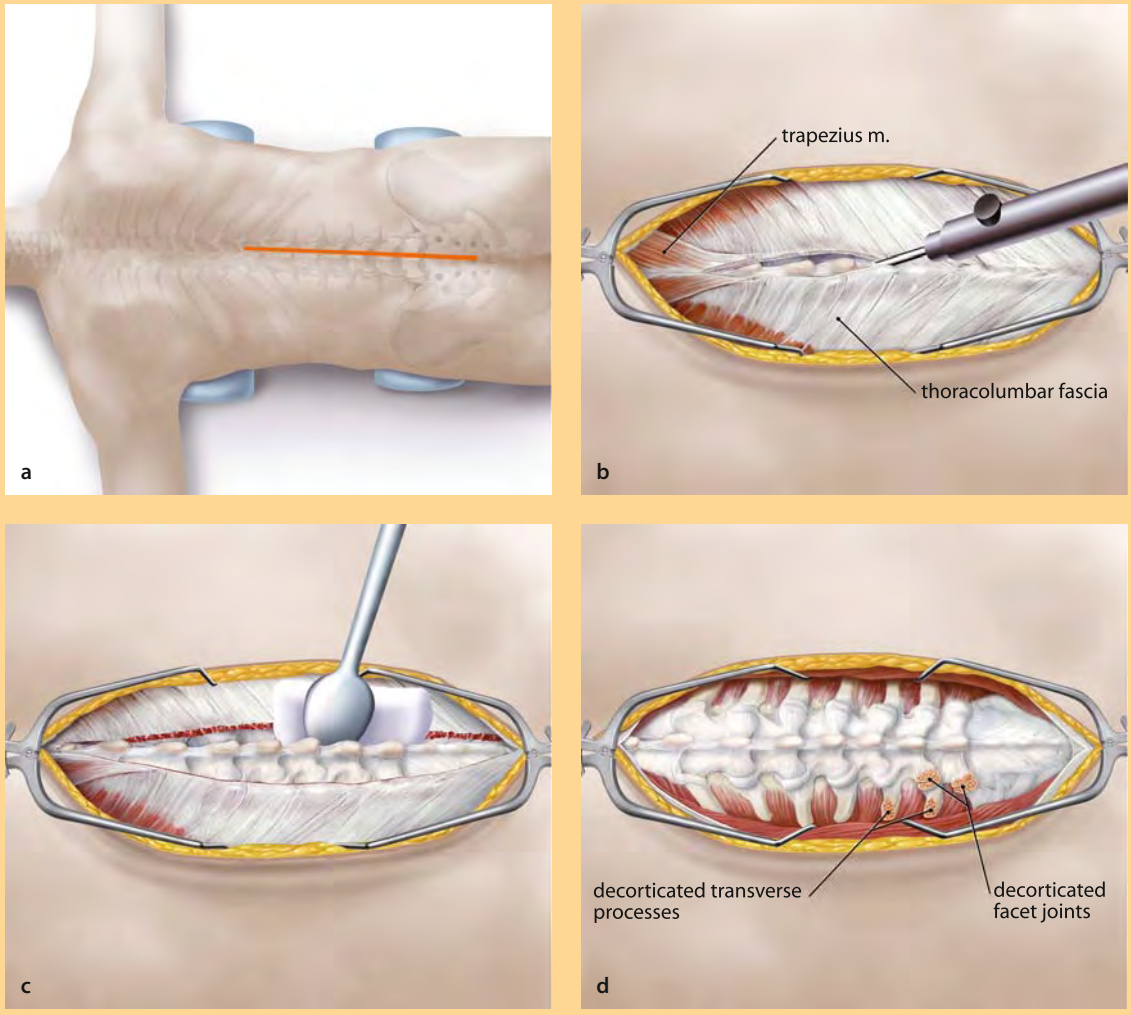


**Figure 13. Surgical anatomy of the posterior thoracolumbar approach**

a Landmarks for skin incision. b Superficial surgical dissection. c Deep surgical dissection. d Muscle retraction with pin-pointed retractors to minimize muscle damage. Note the decortication at L4–S1 on the left side as preparation of the bone graft bed.

### Superficial Surgical Dissection

After the incision of the skin in the midline above the spinous processes and the dissection of the subcutaneous layers, the thoracolumbar fascia is incised with a cautery knife (Fig. 13b). The paraspinal musculature is subperiosteally detached from the spinous process and the laminae. Sponges are used to push the paraspinal muscles laterally and control bleeding by densely packing the created space between the spinous process and the muscle (Fig. 13c). Care has to be taken not to injure:

- facet joint capsules

### Deep Surgical Dissection

In spinal fusion cases, the posterolateral bed has to be prepared for the bone graft. Therefore, the multifidus muscle must be detached from the laminae, facet

joint and transverse process (Fig. 11d). While dissecting the transverse process, the periarticular vessels which cross around the facet joint and transverse process usually tend to bleed and need to be controlled by electrocautery. We prefer to use pinpointed rather than rack type retractors because it causes less tissue damage. The retractors should be released intermittently (Fig. 11d).

Pin-pointed retractors minimize soft tissue damage

### Wound Closure

The thoracolumbar fascia needs to be closed over suction drains. The fascia needs to be sutured tightly either by close interrupted or running sutures.

## Pitfalls and Complications

The posterior access is usually a safe approach to the spine. In slim patients, however, the interlaminar window at L5/S1 can lie very superficially and can be injured with the cautery knife causing an unintended durotomy.

# Landmarks for Screw Insertion

Screw fixation has become a standardized technique throughout the entire spine. However, the prerequisite for a safe screw insertion is critically dependent on a profound knowledge of the surgical anatomy. Preoperative planning of the screw trajectories with CT scans is mandatory if an altered anatomy (e.g. in spinal deformities) is expected. Computer assisted surgery [7, 42, 55, 60] does not compensate for insufficient knowledge of the anatomy and can even be dangerous in inexperienced hands.

Computer assisted surgery provides a false security in inexperienced hands

## Cervico-occipital Spine

### Screw Placement of the Occiput

Screw fixation of the occiput should be in the area with the thickest bone, which is in the midline between the superior nuchal and inferior nuchal line [54] (Fig. 14). Above the superior nuchal line, injuries to the **intracranial sinus** must be expected. There is a wide variation in thickness of the occipital bone [61]. The maximum thickness of the occipital bone ranges from 11.5 to 15.1 mm in males and from 9.7 to 12.0 mm in females and is found at the level of the external occipital protuberance [15]. Fixation can be done using a Y-plate [26] or bilateral titanium plates [45]. The screws are inserted either in the midline or 2–3 mm parasagittally, respectively. The parasagittal cortical bone is substantially thinner and ranges between 3 and 7 mm [30]. The screw holes can be prepared using a drill guide (2.5 mm) with an adjustable drill penetration depth. Initially the depth is set at 4 mm and is increased incrementally until the distal cortex is penetrated. In areas of the occiput which are thicker than 7 mm, unicortical fixation is as strong as bicortical fixation [61]. The standard screw diameter is 3.5 mm and sometimes requires pre-taping. In case of a cerebrospinal fluid flow from the hole, insertion of the screw suffices to close the leak.

Screw insertion must be below the external occipital protuberance

### Posterior Atlantoaxial Transarticular Screw Fixation

Atlantoaxial transarticular screw fixation [27, 28] is a frequent stabilization technique for degenerative and traumatic disorders (Fig. 15a–c). Although lateral image intensifier control is sufficient, we recommend using a simultaneous bipla-

The vertebral artery is at risk laterally and the spinal cord medially

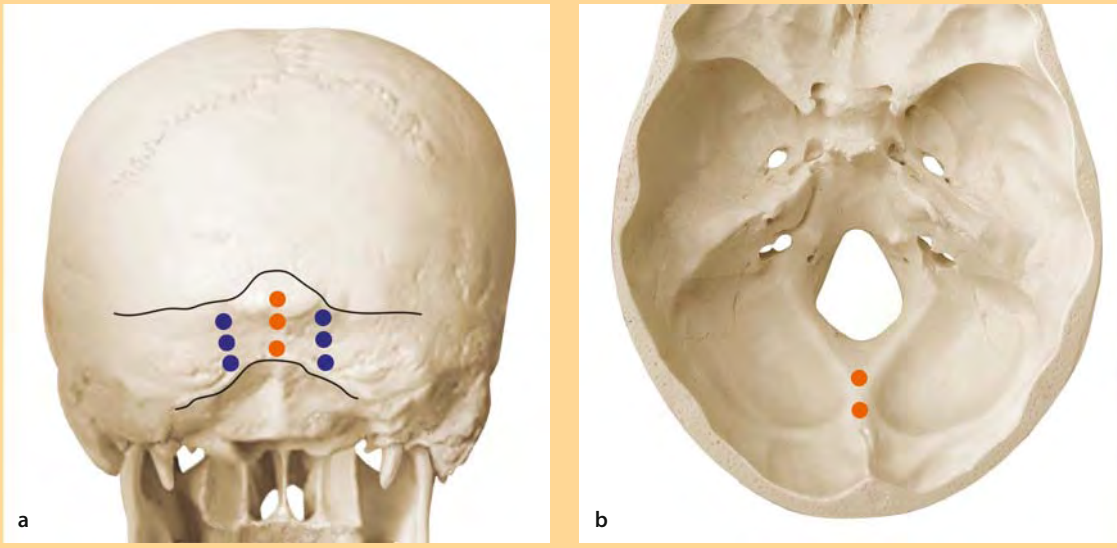


**Figure 14. Landmarks for occipital screw insertion**

a Posterior view. b Axial view.

nar control for optimal screw placement. The medial border of the C2 pedicle (2–5 mm axial diameter) should be palpated with a dissector or a nerve hook. The screw is positioned as medially as possible to avoid injuries to the vertebral artery, which lies immediately laterally. The **entry point** for screw insertion is about 3 mm cranial to the lower edge of the C2 inferior facet. Usually, there is a small groove at the transition of the inferior facet to the lamina which serves as a landmark for the entry point. The drill is angled to aim at the arch of C1 in a strictly sagittal plane. The screw should pass just below the posterior border of the C1/2 joint. In some cases, the craniocaudal angulation can only be achieved if the drill is significantly inclined. Rather than dissecting all the posterior muscles, we prefer only to expose the spine from C1 to C3 and choose a percutaneous insertion of the drill usually at the level of C7–T1 with a tissue protector. Injuries to the vertebral artery or spinal cord are rare if the technique is performed properly [22, 27].

Injuries to the spinal cord or vertebral artery are rare if the technique is applied

### Atlantoaxial Pedicle Screw Fixation

The 2nd cervical nerve is at risk when exposing the C1/2 joint

An alternative to the transarticular screw fixation is a stabilization of the spine with pedicle screws which are connected with rods [29, 64] (Fig. 15d–g). The screw **entry point in C2** is more lateral (4–5 mm) than the transarticular screw trajectory. The drill is directed 20°–35° cranially and 15°–20° medially. The **entry point in C1** is below the lamina and 2–3 mm lateral to the medial edge of the C1, which can be palpated with a dissector. The screw is aimed about 10°–15° medially and 15°–20° cranially. Care has to be taken not to injure the C2 exiting nerve root (greater occipital nerve).

### Anterior Atlantoaxial Transarticular Screw Fixation

A second alternative is an anterior transarticular screw fixation [59]. The screw entry point is 5 mm below the C1/2 joint line in the groove formed by the basis of

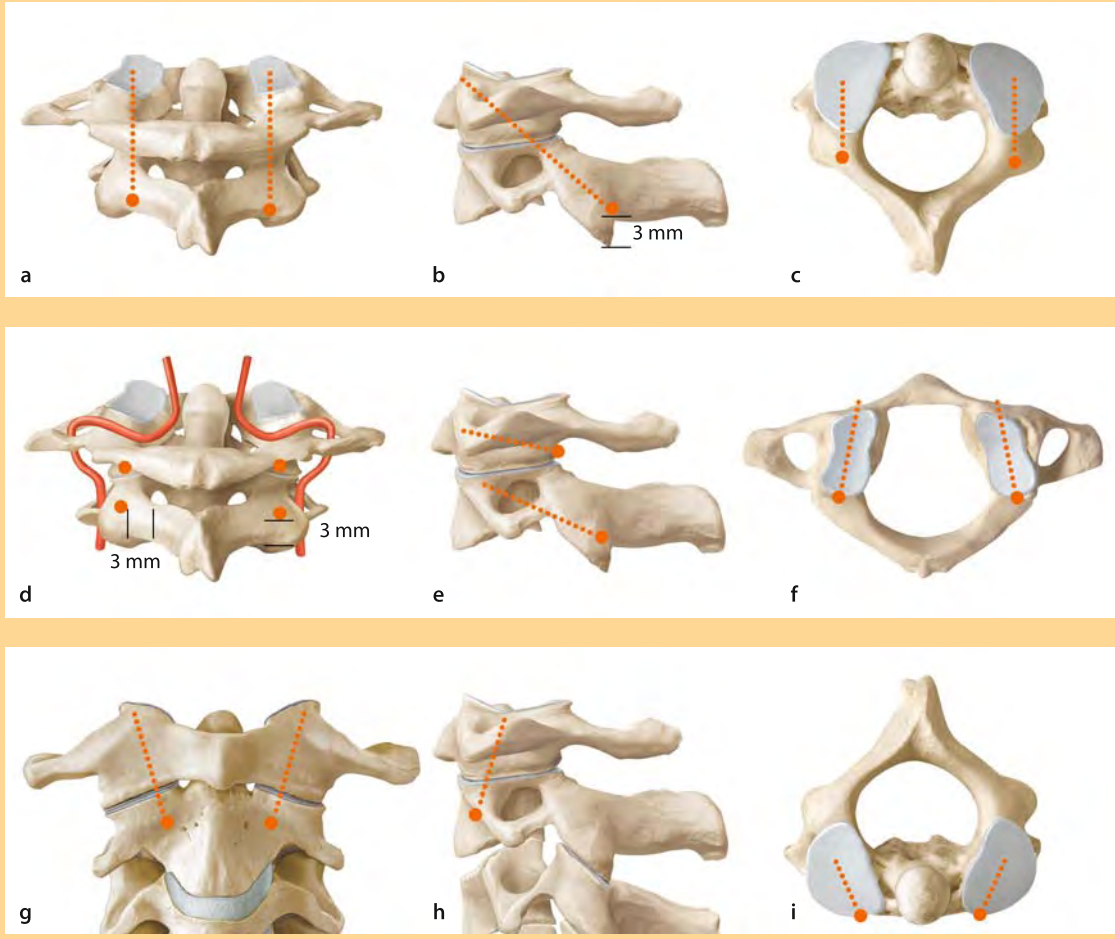


**Figure 15. Landmarks for upper cervical spine screw insertions**

**Posterior atlantoaxial transarticular screw fixation:** a posterior view; b lateral view; c axial view. **Atlantoaxial pedicle screw fixation:** d posterior view; e lateral view; f axial view at C2. **Anterior atlantoaxial transarticular screw fixation:** g anterior view; h lateral view; i axial view.

the dens and the lateral mass (Fig. 15h–j). The screw trajectory is angled 25° laterally and cranially. However, the exposure of the entry point is not easy because it is far up in the cervical spine. During exposure great care has to be taken not to injure the:

- hypoglossus nerve
- superior laryngeal nerve

### Lateral Mass Screw Fixation

There are two commonly used techniques for screw placement in the lateral mass of the lower cervical spine. The screw entry point according to **Roy-Camille** [50] is in the center of the lateral mass and the trajectory is directed 10° outwards rectangular to the posterior cortex. According to the **Magerl technique**, the screw's insertion point lies 2 mm medial and cranial to the facet center. The screw trajectory is parallel to the facet joints and angled 20°–25° outwards (Fig. 16a–c). Magerl's method exhibits longer screw lengths and is therefore biomechanically

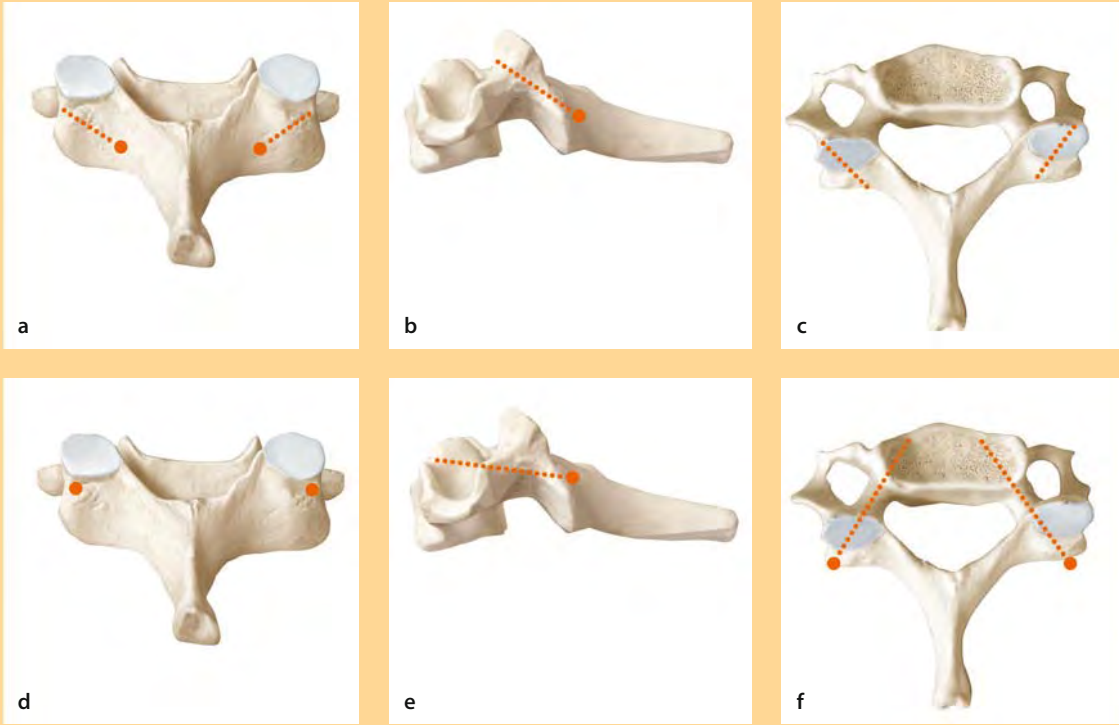


**Figure 16. Landmarks for lower cervical spine screw insertions**

**Lateral mass screw fixation:** a posterior view; b lateral view; c axial view. **Pedicle screw fixation:** d posterior view; e lateral view; f axial view.

superior to the Roy-Camille method [50]. Some studies have reported that the Magerl method is less likely to damage the neurovascular structures [51].

### Lower Cervical Spine Pedicle Screw Fixation

This screw insertion technique is reserved for the most experienced spine surgeons

Pedicle screw fixation in the lower cervical spine is demanding and reserved for the most experienced spine surgeons [38]. The risk potential of spinal cord and vertebral artery injury is high [70]. The pedicle dimensions are not infrequently smaller than the screw [36]. **Preoperative CT planning** is recommended to rule out anatomical anomalies. Computer assisted surgery may reduce the rate of misplaced screws [35, 60] but does not compensate for lack of profound knowledge of the cervical anatomy and surgical experience [2]. The technique according to **Abumi and Kaneda** [1] chooses an entry point slightly lateral to the center of the lateral mass and inferior to the facet joint line (Fig. 16d–f). The cortical bone at the entry point is opened with a burr and the hole is enlarged to bury the pedicle screw (3–4 mm). The **screw trajectory** is angled 25°–45° medially. A thin pedicle finder is used to dilate the pedicle under lateral image intensifier control. Perforations can be detected with a fine pedicle probe (feeler) (Fig. 17). In experienced hands, the complication rate is low [2, 38].

### Thoracic Spine Pedicle Screw Fixation

Screw placement in the thoracic spine requires a detailed knowledge of the anatomy of the thoracic spine. However, it can be done with a high safety margin

**Figure 17. Surgical instruments for screw hole preparations**

a Fine awl. b Thin pedicle finder. c Thick pedicle finder. d Pedicle feeler.

when the proper technique is applied [20]. The pedicle morphology of the thoracic and lumbar spine has been thoroughly investigated in several studies [49, 65–67, 73]. The landmarks for screw insertion T2–T11 are below the rim of the inferior facet. Sometimes it is necessary to osteotomize the lateral inferior part of the facet to clearly identify the base of the superior facet. The **entry point** is at the lateral border. The screw trajectory is angled 20° medially and 10° caudally. When the **extrapedicular technique** [14] is used, the entry point is slightly more lateral and the angle to the midline is higher (Fig. 18a–c) (see Chapter 3). This inside-out-inside technique involves a reduced risk of injuring the medial border of the pedicle [14]. The entry point at T1 is slightly more medial and the screw trajectory is less angled to the midline. The **entry point for the pedicle of T12** is at the level of the mammillary process, which is opened/removed with a rongeur (Fig. 18d–f). The screw trajectory is angled more medially similarly to the lumbar spine. The screws for adult patients usually have a diameter of 5 (lower thoracic spine) and 6 mm (lower thoracic spine) and have a length of 30–35 mm at T1 and 45–55 mm at T12, respectively.

Our preferred technique (Fig. 17) is to use a sharp fine awl to open the cortical bone at the entry point. This position is checked in the lateral plane using an image intensifier. A thin pedicle finder is used to probe the pedicle again under fluoroscopic guidance. A fine pedicle feeler is entered into the pedicle hole to verify that the cortical shell of the pedicle is intact particularly medially, inferiorly and anteriorly. In the lower thoracic spine, a thicker pedicle finder is used to further widen the pedicle. In questionable cases, the screw is inserted somewhat deeper than the base of the pedicle, which can be checked in the lateral view with an image intensifier. The screw is then removed and the medial pedicle wall is palpated with the pedicle feeler. When the medial wall is intact the screw can be reinserted.

Check for potential perforations with a fine pedicle feeler

### Lumbar Spine Pedicle Screw Fixation

The pedicle morphology of the lumbar spine has been accurately described in several studies [41, 49, 56, 62, 67, 74].

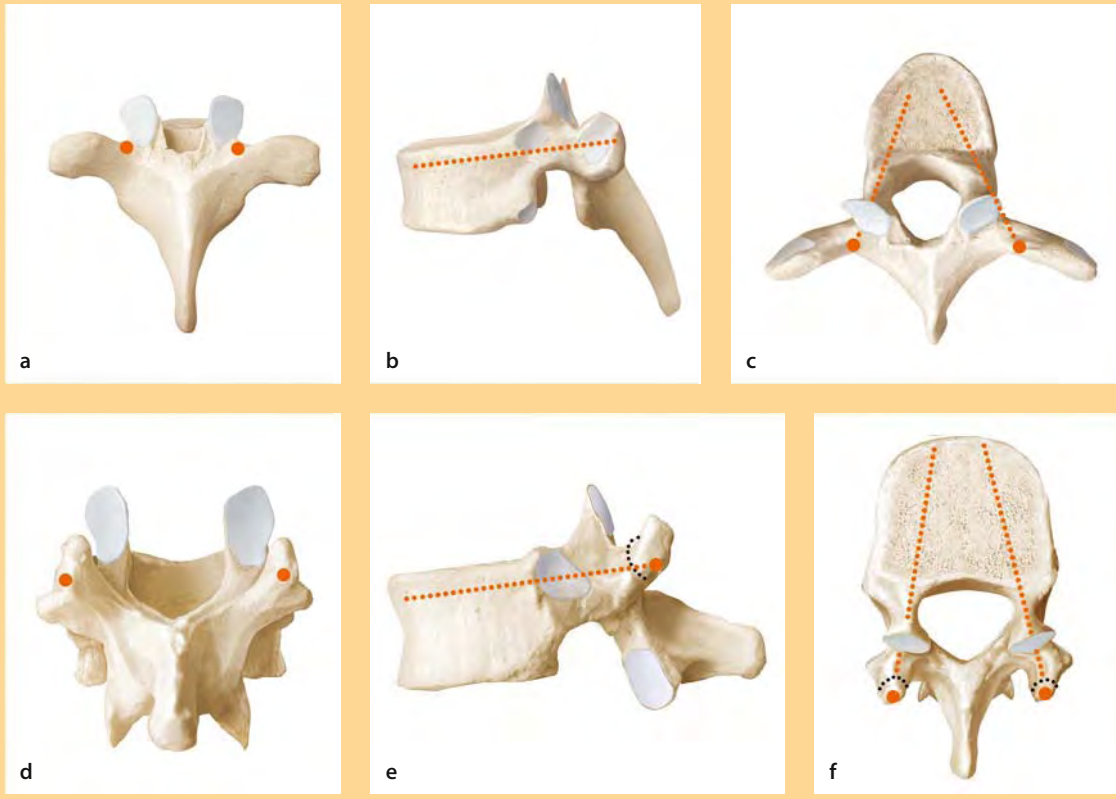


**Figure 18. Landmarks for thoracic pedicle screw insertions**

Thoracic pedicle fixation at the level of T6: a posterior view; b lateral view; c axial view. Note the alternative extrapedicular screw position on the right side. Thoracic pedicle fixation at the level of T12: d posterior view; e lateral view; f axial view.

Several techniques have been described. We prefer a more lateral insertion point with a larger angulation to the midline, which is also biomechanically more stable than a straight anterior screw insertion. The pedicle entrance point is at the lateral border of the base of the superior articular process. The same technique is used as described for the insertion of thoracic screws. The screw trajectory is angled 20°–25° to the midline. In the sagittal plan the screws take a course parallel to the upper vertebral endplates (Fig. 19a–c).

A double sacral screw fixation provides a strong sacral anchorage

Knowledge of the size and anatomy of the pedicle is required, but also an understanding of the topography of nerve and vascular structures in relation to the pedicle is indispensable for safe pedicle placement. The nerve roots are located directly at the medial-inferior border of the pedicle. Screws should not penetrate the anterior cortex except in cases in which this is absolutely necessary to enhance the pullout resistance. The screws should not be in contact with an artery because pulsation can cause vessel wall erosion and the formation of an aneurysm.

### Sacral and Iliac Screw Fixation

The most frequent technique is screw placement in the first sacral pedicle located just below the L5/S1 facet angled medially 20° cranially toward the anterior corner of the promontorium. Another alternative is to insert the screws at a 30° – 45° lateral and cranial direction into the sacral alae (Fig. 19d–g). Both screw posi-

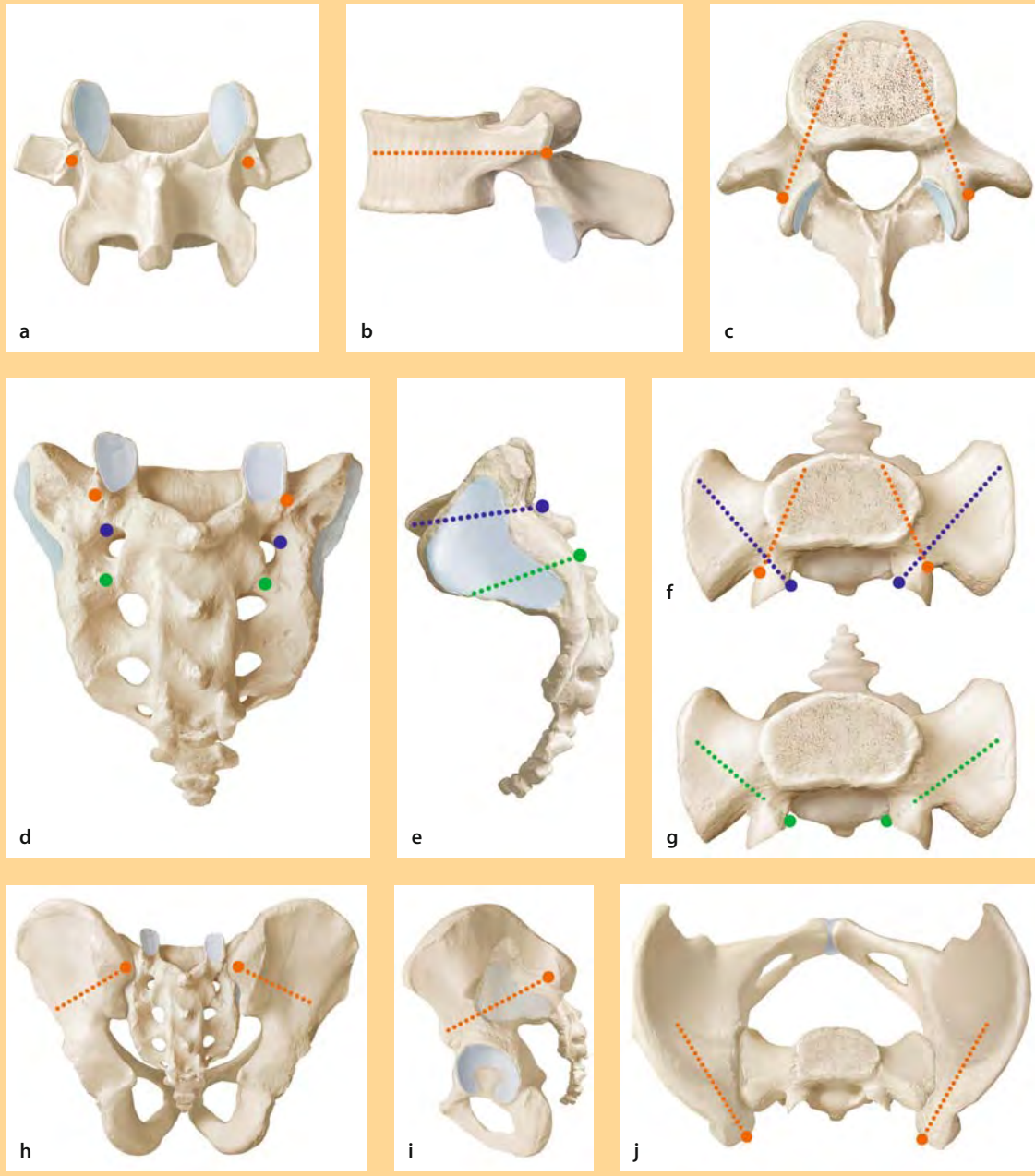


**Figure 19. Landmarks for lumbosacral and iliac screw insertions**

**Lumbar pedicle screw fixation at the level of L4:** a posterior view; b lateral view; c axial view. **Sacral screw fixation techniques** (*red* convergent S1 screw, *green* divergent S1 screw, *blue* divergent S2 screw): d posterior view; e lateral view; f axial view at S1; g axial view at S2. **Pelvic fixation in the iliac wing:** h posterior view; i lateral view; j axial view.

tions can be combined to enhance the sacral fixation [6, 62, 74]. The insertion point for the S2 screw is in the middle between the first and second dorsal foramina. The screws should be directed 5° caudally and 30° laterally [6]. The slightest risk of injury is from placement of S1 pedicle screws. Lateral screw placement carries a risk of injury to the internal iliac vein or the lumbosacral plexus. Anterior cortical penetration of the S2 segment could cause injury of the bowel [44, 52].

In neuromuscular scoliosis, **fixation to the pelvis** is often required to treat pelvic obliquity or because of insufficient screw purchase at the sacrum. The original technique was introduced by Allan and Ferguson as the so-called **Galveston technique** with insertion of a contoured rod into the iliac wing [3]. However, this technique has the disadvantage of resulting in a painful loosening of the rod in the iliac wing with time ("**windshield wiper effect**"). A modification is to use a screw instead of the contoured rod for pelvic fixation, which results in an excellent bony purchase. An even stronger fixation is the so-called MW sacropelvic fixation [5] (see Chapter 24). The pelvic screw fixation starts with decortication of the posterior superior iliac spine with a Luer. A pedicle finder is inserted and aimed 20°–40° laterally and caudally aiming at the iliac notch and superior to the acetabulum (Fig. 19h–j). A pedicle feeler is used to check that the iliac cortical laminae have not been perforated. Simultaneously the length is determined. Usually, 7–8 mm strong 80- to 100-mm-long screws can be inserted.

## Recapitulation

**Surgical planning.** Preoperative planning and a profound knowledge of the surgical anatomy are the prerequisites to achieving the goals of surgery and helping to avoid serious complications. **Anatomical dissection studies** are extremely valuable and supplement in-depth study of textbooks on surgical anatomy. The surgeon must **proactively** consider potential extensions of the approach and must be familiar with this anatomy.

**Surgical approaches.** Image intensifier or radiographic verification of the correct level is an absolute must. Wrong level surgery is one of the most frequent complications. The **anteromedial approach** to the cervical spine approaches the anterior column through anatomical planes. Great care must be taken to retract the carotid artery laterally and not medially. Particularly, the recurrent laryngeal and the superior laryngeal nerve are at risk during this approach. The **posterior approach** to the cervical spine can be associated with heavy bleeding. For exposure of the craniocervical junction, the muscle insertion at the spinous process of C2 should be detached with an osteoligamentous flap. The vertebral artery is at risk when exposing C1. A deleterious complication of **thoracotomy** is wrong site surgery. The neurovascular bundle below the rib must be preserved to avoid painful neuralgias. The parietal pleura should be closed whenever possible. Correct placement of the chest tubes minimizes postoperative pulmonary complications. The **thoraco-phrenico-lumbotomy** gives an excellent exposure of the thoracolumbar junction but is major surgery. The dissection should start with the retroperitoneal abdominal approach to minimize peritoneal tears. Corresponding stay sutures at both sides of the diaphragma incision facilitate repair when closing the wound. The thoracic duct is at risk when exposing the thoracolumbar junction but difficult to identify during preparation. The **anterolateral retroperitoneal approach** to the lumbar spine L5–L2 is easily possible even in obese patients. A muscle splitting approach is recommended. In males, the psoas muscle can cover the whole lateral aspect of the anterior column. Rather than dissecting and retracting the psoas posterolaterally, a psoas splitting approach is the preferred alternative for discectomy and interbody fusion. The **anterior lumbar retroperitoneal approach** approaches the spine through anatomical planes. The liberation of the peritoneal sac requires a dissection of the posterior rectus sheath at the arcuate line. When retracting the common iliac vein medially to expose the L4/5 disc space, the ascending lumbar vein must be controlled and ligated prior to vessel retraction. The **posterior thoracolumbar approach** results in considerable collateral damage to the spinal muscles, which can be minimized by mini-access surgery and use of pinpointed retractors which are intermittently released. The target level must be identified prior to surgery to avoid unnecessary and extensive detachment of back muscles.

**Landmarks for screw fixation.** **Occipital screw fixation** must be accomplished in the midline between the superior nuchal and inferior nuchal line where the bone is thick enough to bury a screw. **Posterior transarticular atlantoaxial screw fixation** puts the vertebral artery at risk laterally and the spinal cord medially. **Atlantoaxial pedicle screw fixation** is an

alternative but the 2nd cervical nerve is at risk when exposing the atlantoaxial joint. **Lateral mass screws** are safe when performed with the proper technique. **Cervical pedicle screws** carry a high risk of neurovascular complications and are preserved for the most experienced spine surgeons. **Thoracic and lumbar pedicle screws** can be placed with minimal risk with detailed anatomical knowledge. The use of a fine awl to open the cortical bone (image guided verification in the lateral and possibly anteroposterior plane), bluntly probing the pedicle and verification with a pedicle feeler, is a safe method for screw hole preparation. **Sacral screws** can be placed in a divergent direction at S1 and S2 as well as in a convergent direction at S1. A double sacral screw fixation provides a strong anchorage at the sacrum. For neuromuscular deformities with pelvic obliquity, an **iliac screw** provides a solid pelvic fixation.

### Key Articles

These texthooks are recommended for a study of the surgical anatomy of the spine and surgical approaches:

**Bauer RF, Kerschbaumer F, Poisel S (ed) (1993) Atlas of spinal operations. Thieme, Stuttgart**

**Nazarian S (2007) Surgical anatomy of the spine. In: Aebi M, Arlet V, Webb J. AOSPINE manual: principles and techniques, vol. 1. Thieme, Stuttgart, pp 131 – 239**

**Louis R (1983) Surgery of the spine. Surgical anatomy and operative approaches. Springer, Heidelberg**

**Watkins RG (2003) Surgical approaches to the spine. Springer, Heidelberg**

## References


1. Abumi K, Kaneda K (1997) Pedicle screw fixation for nontraumatic lesions of the cervical spine. Spine 22:1853 – 63
2. Abumi K, Shono Y, Ito M, Taneichi H, Kotani Y, Kaneda K (2000) Complications of pedicle screw fixation in reconstructive surgery of the cervical spine. Spine 25:962 – 9
3. Allen BL, Ferguson RL (1982) The Galveston technique for L rod instrumentation of the scoliotic spine. Spine 7:276 – 284
4. Apfelbaum RI, Kriskovich MD, Haller JR (2000) On the incidence, cause, and prevention of recurrent laryngeal nerve palsies during anterior cervical spine surgery. Spine 25:2906 – 12
5. Arlet V, Marchesi D, Papin P, Aebi M (1999) The 'MW' sacropelvic construct: an enhanced fixation of the lumbosacral junction in neuromuscular pelvic obliquity. Eur Spine J 8:229 – 31
6. Asher MA, Strippgen WE (1986) Anthropometric studies of the human sacrum relating to dorsal transsacral implant designs. Clin Orthop Relat Res:58 – 62
7. Berlemann U, Monin D, Arm E, Nolte LP, Ozdoba C (1997) Planning and insertion of pedicle screws with computer assistance. J Spinal Disord 10:117 – 24
8. Bertagnoli R, Vazquez RJ (2003) The Anterolateral TransPsoatic Approach (ALPA): a new technique for implanting prosthetic disc-nucleus devices. J Spinal Disord Tech 16:398 – 404
9. Bertalanffy H, Eggert HR (1989) Complications of anterior cervical discectomy without fusion in 450 consecutive patients. Acta Neurochir (Wien) 99:41 – 50
10. Burke JP, Gerszten PC, Welch WC (2005) Iatrogenic vertebral artery injury during anterior cervical spine surgery. Spine J 5:508 – 14; discussion 514
11. Burrington JD, Brown C, Wayne ER, Odom J (1976) Anterior approach to the thoracolumbar spine: technical considerations. Arch Surg 111:456 – 63
12. Capener N (1954) The evolution of lateral rhachotomy. J Bone Joint Surg Br 36-B:173 – 9
13. Cauchoix J, Binet JP (1957) Anterior surgical approaches to the spine. Ann R Coll Surg Engl 21:234 – 43
14. Dvorak M, MacDonald S, Gurr KR, Bailey SI, Haddad RG (1993) An anatomic, radiographic, and biomechanical assessment of extrapedicular screw fixation in the thoracic spine. Spine 18:1689 – 94

15. Ebraheim NA, Lu J, Biyani A, Brown JA, Yeasting RA (1996) An anatomic study of the thickness of the occipital bone. Implications for occipitocervical instrumentation. Spine 21:1725 – 9; discussion 1729 – 30
16. Ebraheim NA, Lu J, Brown JA, Biyani A, Yeasting RA (1996) Vulnerability of vertebral artery in anterolateral decompression for cervical spondylosis. Clin Orthop Relat Res:146 – 51
17. Ebraheim NA, Lu J, Skie M, Heck BE, Yeasting RA (1997) Vulnerability of the recurrent laryngeal nerve in the anterior approach to the lower cervical spine. Spine 22:2664 – 7
18. Eleraky MA, Llanos C, Sonntag VK (1999) Cervical corpectomy: report of 185 cases and review of the literature. J Neurosurg 90:35 – 41
19. Fang HS, Ong GB, Hodgson AR (1964) Anterior spinal fusion: The operative approaches. Clin Orthop Relat Res 35:16 – 33
20. Fisher CG, Sahajpal V, Keynan O, Boyd M, Graeb D, Bailey C, Panagiotopoulos K, Dvorak MF (2006) Accuracy and safety of pedicle screw fixation in thoracic spine trauma. J Neurosurg Spine 5:520 – 6
21. Fraser RD, Gogan WJ (1992) A modified muscle-splitting approach to the lumbosacral spine. Spine 17:943 – 8
22. Gebhard JS, Schimmer RC, Jeanneret B (1998) Safety and accuracy of transarticular screw fixation C1-C2 using an aiming device. An anatomic study. Spine 23:2185 – 9
23. Gejo R, Kawaguchi Y, Kondoh T, Tabuchi E, Matsui H, Torii K, Ono T, Kimura T (2000) Magnetic resonance imaging and histologic evidence of postoperative back muscle injury in rats. Spine 25:941 – 6
24. Gejo R, Matsui H, Kawaguchi Y, Ishihara H, Tsuji H (1999) Serial changes in trunk muscle performance after posterior lumbar surgery. Spine 24:1023 – 8
25. Gieger M, Roth PA, Wu JK (1995) The anterior cervical approach to the cervicothoracic junction. Neurosurgery 37:704 – 9; discussion 709 – 10
26. Grob D, Dvorak J, Panjabi M, Froehlich M, Hayek J (1991) Posterior occipitocervical fusion. A preliminary report of a new technique. Spine 16:S17 – 24
27. Grob D, Jeanneret B, Aebi M, Markwalder TM (1991) Atlanto-axial fusion with transarticular screw fixation. J Bone Joint Surg Br 73:972 – 6
28. Grob D, Magerl F (1987) Surgical stabilization of C1 and C2 fractures. Orthopade 16:46 – 54
29. Harms J, Melcher RP (2001) Posterior C1-C2 fusion with polyaxial screw and rod fixation. Spine 26:2467 – 71
30. Hertel G, Hirschfelder H (1999) In vivo and in vitro CT analysis of the occiput. Eur Spine J 8:27 – 33
31. Hodgson AR, Stock FE (1956) Anterior spinal fusion: a preliminary communication on the radical treatment of Pott's disease and Pott's paraplegia. Br J Surg 44:266 – 75
32. Hodgson AR, Stock FE, Fang HS, Ong GB (1960) Anterior spinal fusion. The operative approach and pathological findings in 412 patients with Pott's disease of the spine. Br J Surg 48:172 – 8
33. Hoski JJ, Eismont FJ, Green BA (1993) Blindness as a complication of intraoperative positioning. A case report. J Bone Joint Surg Am 75:1231 – 2
34. Jung A, Schramm J, Lehnerdt K, Herberhold C (2005) Recurrent laryngeal nerve palsy during anterior cervical spine surgery: a prospective study. J Neurosurg Spine 2:123 – 7
35. Kamimura M, Ebara S, Itoh H, Tateiwa Y, Kinoshita T, Takaoka K (2000) Cervical pedicle screw insertion: assessment of safety and accuracy with computer-assisted image guidance. J Spinal Disord 13:218 – 24
36. Karaikovic EE, Daubs MD, Madsen RW, Gaines RW, Jr. (1997) Morphologic characteristics of human cervical pedicles. Spine 22:493 – 500
37. Kasodekar VB, Chen JL (2006) Monocular blindness: a complication of intraoperative positioning in posterior cervical spine surgery. Singapore Med J 47:631 – 3
38. Kast E, Mohr K, Richter HP, Borm W (2006) Complications of transpedicular screw fixation in the cervical spine. Eur Spine J 15:327 – 34
39. Kawaguchi Y, Matsui H, Tsuji H (1996) Back muscle injury after posterior lumbar spine surgery. A histologic and enzymatic analysis. Spine 21:941 – 4
40. Kawaguchi Y, Yabuki S, Styf J, Olmarker K, Rydevik B, Matsui H, Tsuji H (1996) Back muscle injury after posterior lumbar spine surgery. Topographic evaluation of intramuscular pressure and blood flow in the porcine back muscle during surgery. Spine 21:2683 – 8
41. Krag MH, Weaver DL, Beynnon BD, Haugh LD (1988) Morphometry of the thoracic and lumbar spine related to transpedicular screw placement for surgical spinal fixation. Spine 13:27 – 32
42. Laine T, Schlenzka D, Makitalo K, Tallroth K, Nolte LP, Visarius H (1997) Improved accuracy of pedicle screw insertion with computer-assisted surgery. A prospective clinical trial of 30 patients. Spine 22:1254 – 8
43. Lee MJ, Bazaz R, Furey CG, Yoo J (2007) Risk factors for dysphagia after anterior cervical spine surgery: a two-year prospective cohort study. Spine J 7:141 – 7
44. Licht NJ, Rowe DE, Ross LM (1992) Pitfalls of pedicle screw fixation in the sacrum. A cadaver model. Spine 17:892 – 6

45. Lieberman IH, Webb JK (1998) Occipito-cervical fusion using posterior titanium plates. Eur Spine J 7:308 – 12
46. Lo CY, Kwok KF, Yuen PW (2000) A prospective evaluation of recurrent laryngeal nerve paralysis during thyroidectomy. Arch Surg 135:204 – 7
47. Lu J, Ebraheim NA, Nadim Y, Huntoon M (2000) Anterior approach to the cervical spine: surgical anatomy. Orthopedics 23:841 – 5
48. Manfredini M, Ferrante R, Gildone A, Massari L (2000) Unilateral blindness as a complication of intraoperative positioning for cervical spinal surgery. J Spinal Disord 13:271 – 2
49. Marchesi D, Schneider E, Glauser P, Aebi M (1988) Morphometric analysis of the thoracolumbar and lumbar pedicles, anatomo-radiologic study. Surg Radiol Anat 10:317 – 22
50. McCullen GM, Garfin SR (2000) Spine update: cervical spine internal fixation using screw and screw-plate constructs. Spine 25:643 – 52
51. Merola AA, Castro BA, Alongi PR, Mathur S, Brkaric M, Vigna F, Riina JP, Gorup J, Haher TR (2002) Anatomic consideration for standard and modified techniques of cervical lateral mass screw placement. Spine J 2:430 – 5
52. Mirkovic S, Abitbol JJ, Steinman J, Edwards CC, Schaffler M, Massie J, Garfin SR (1991) Anatomic consideration for sacral screw placement. Spine 16:S289 – 94
53. Miscusi M, Bellitti A, Peschillo S, Polli FM, Missori P, Delfini R (2007) Does recurrent laryngeal nerve anatomy condition the choice of the side for approaching the anterior cervical spine? J Neurosurg Sci 51:61 – 4
54. Mullett JH, McCarthy P, O'Keefe D, McCabe JP (2001) Occipital fixation: effect of inner occipital protuberance alignment on screw position. J Spinal Disord 14:504 – 6
55. Nolte LP, Visarius H, Arm E, Langlotz F, Schwarzenbach O, Zamorano L (1995) Computer-aided fixation of spinal implants. J Image Guid Surg 1:88 – 93
56. Olsewski JM, Simmons EH, Kallen FC, Mendel FC, Severin CM, Berens DL (1990) Morphometry of the lumbar spine: anatomical perspectives related to transpedicular fixation. J Bone Joint Surg Am 72:541 – 9
57. Pait TG, Killefer JA, Arnautovic KI (1996) Surgical anatomy of the anterior cervical spine: the disc space, vertebral artery, and associated bony structures. Neurosurgery 39:769 – 76
58. Raynor RB (1983) Anterior or posterior approach to the cervical spine: an anatomical and radiographic evaluation and comparison. Neurosurgery 12:7 – 13
59. Reindl R, Sen M, Aebi M (2003) Anterior instrumentation for traumatic C1-C2 instability. Spine 28:E329 – 33
60. Richter M, Cakir B, Schmidt R (2005) Cervical pedicle screws: conventional versus computer-assisted placement of cannulated screws. Spine 30:2280 – 7
61. Roberts DA, Doherty BJ, Heggeness MH (1998) Quantitative anatomy of the occiput and the biomechanics of occipital screw fixation. Spine 23:1100 – 7; discussion 1107 – 8
62. Roy-Camille R, Saillant G, Mazel C (1986) Internal fixation of the lumbar spine with pedicle screw plating. Clin Orthop Relat Res:7 – 17
63. Southwick WO, Robinson RA (1957) Surgical approaches to the vertebral bodies in the cervical and lumbar regions. J Bone Joint Surg Am 39-A:631 – 44
64. Stulik J, Vyskocil T, Sebesta P, Kryl J (2007) Atlantoaxial fixation using the polyaxial screw-rod system. Eur Spine J 16:479 – 84
65. Vaccaro AR, Rizzolo SJ, Allardyce TJ, Ramsey M, Salvo J, Balderston RA, Cotler JM (1995) Placement of pedicle screws in the thoracic spine. Part I: Morphometric analysis of the thoracic vertebrae. J Bone Joint Surg Am 77:1193 – 9
66. Vaccaro AR, Rizzolo SJ, Balderston RA, Allardyce TJ, Garfin SR, Dolinskas C, An HS (1995) Placement of pedicle screws in the thoracic spine. Part II: An anatomical and radiographic assessment. J Bone Joint Surg Am 77:1200 – 6
67. Weinstein JN, Rydevik BL, Rauschning W (1992) Anatomic and technical considerations of pedicle screw fixation. Clin Orthop Relat Res:34 – 46
68. Wiltse LL, Bateman JG, Hutchinson RH, Nelson WE (1968) The paraspinal sacrospinalis-splitting approach to the lumbar spine. J Bone Joint Surg Am 50:919 – 26
69. Wolfe SW, Lospinuso MF, Burke SW (1992) Unilateral blindness as a complication of patient positioning for spinal surgery. A case report. Spine 17:600 – 5
70. Xu R, Kang A, Ebraheim NA, Yeasting RA (1999) Anatomic relation between the cervical pedicle and the adjacent neural structures. Spine 24:451 – 4
71. Yamaki K, Saga T, Hirata T, Sakaino M, Nohno M, Kobayashi S, Hirao T (2006) Anatomical study of the vertebral artery in Japanese adults. Anat Sci Int 81:100 – 6
72. Zeidman SM, Ducker TB, Raycroft J (1997) Trends and complications in cervical spine surgery: 1989 – 1993. J Spinal Disord 10:523 – 6
73. Zindrick MR, Wiltse LL, Doornik A, Widell EH, Knight GW, Patwardhan AG, Thomas JC, Rothman SL, Fields BT (1987) Analysis of the morphometric characteristics of the thoracic and lumbar pedicles. Spine 12:160 – 6
74. Zindrick MR, Wiltse LL, Widell EH, Thomas JC, Holland WR, Field BT, Spencer CW (1986) A biomechanical study of intrapeduncular screw fixation in the lumbosacral spine. Clin Orthop Relat Res:99 – 112

# 14 Preoperative Assessment

Stephan Blumenthal, Youri Reiland, Alain Borgeat

## Core Messages

- ✔ The preoperative patient assessment is the occasion most likely to reduce anxiety and fear
- ✔ More and more elderly patients with comorbidities are scheduled for elective spinal surgery
- ✔ Spinal cord injury can severely affect other organ systems
- ✔ Scoliosis can cause restrictive pulmonary disease. The most common blood-gas abnormality is reduced $PaO_2$ with normal $PaCO_2$. Restrictive lung disease can progress to irreversible pulmonary hypertension and cor pulmonale
- ✔ Patients with Duchenne muscular dystrophy are a special group deserving special attention and precaution with regard to cardiac and pulmonary problems
- ✔ Surgery for malignant tumors often requires extensive blood transfusions
- ✔ Spinal shock begins immediately after the injury and can last up to 3 weeks
- ✔ Post-traumatic autonomic dysreflexia may be present after 3–6 weeks following the spinal cord injury
- ✔ Preexisting drug therapy needs careful assessment and sometimes adaptation

## Aim of Preanesthetic Evaluation

The preanesthetic evaluation of the patient for spinal surgery is not unique; it follows the general approach used before any patient is given anesthesia. Both adult and pediatric patients present for spinal surgery, which may be elective or urgent. Procedures range from minimally invasive microdiscectomy to prolonged operations involving multiple spinal levels and anterior/posterior surgery. When assessing patients before spinal surgery, particular attention should be given to:

A thorough preoperative assessment of patients with scheduled spinal interventions helps to minimize complications

- respiratory function
- cardiovascular system
- metabolic conditions
- neurological function

A clear understanding of the surgical procedure as well as complete knowledge of the patient's status are essential requirements in resolving perioperative problems, particularly in high-risk patients. This helps in the development of an appropriate and optimal anesthetic plan for intraoperative and postoperative management. **Risk factors** for postoperative complications are:

- combined procedures (single or two staged anterior/posterior surgery)
- multiple levels involved
- age over 60 years
- spinal cord injury or preexisting myelopathy
- preexisting comorbidities, ASA physical status classification

**Table 1.** The American Society of Anesthesiologists (ASA) Score

| Class | Physical status |
|---|---|
| I | Healthy patient |
| II | Patient with mild systemic disease |
| III | Patient with severe systemic disease, but not incapacitating |
| IV | Patient with incapacitating disease that is a constant threat to life |
| V | Moribund patient who is not expected to live 24 h with or without surgery |
| E | Emergency case |

The ASA score assesses the cardiovascular risk

The **American Society of Anesthesiologists (ASA)** has adopted a six-category physical status classification system to assess the patient preoperatively (Table 14.1). The ASA score makes no adjustments for age, sex, weight and pregnancy, nor does it reflect the nature of the planned surgery. Although this system was not intended as such, it generally correlates with the perioperative mortality [40].

The most frequently cited **comorbidities** [14] include:

- cardiovascular disease
- hypertension
- pulmonary disease
- diabetes mellitus

The general approach should be to characterize those conditions which can be improved by preoperative preparation and to take into account those conditions which will add to the risk of anesthesia and surgery.

### Information and Instructions

One aim of the preoperative visit is to explain and describe the anesthetic procedure to the patient and to describe the procedure. This usually reduces the patient's anxiety.

The patient should be **informed about**:

- the possibility of an intraoperative wake-up test
- the importance of following orders to move the extremities at the end of the procedure (if necessary)
- the need for a prolonged intubation and mechanical ventilation
- surveillance on an intensive care unit

Reduce anxiety and give information

The decision to provide a period of postoperative mechanical ventilation should be made before surgery commences. This should be explained to the patient as well as the possibility of unexpected complications leading to prolonged mechanical ventilation. The patient should be reassured that no pain will be felt during the procedure and the wake-up test.

## Patient Assessment

### History

The preoperative history should clearly establish the presence of medical problems, their severity and any prior or present treatments. Because of potential drug interactions with anesthetics and analgesics, a complete medication history including any herbal therapeutics, the use of tobacco, alcohol and illicit drugs should be elicited. True **drug allergies** must be distinguished from **drug intolerance**. Detailed questioning about previous operations and anesthetics may unco-

ver earlier complications, and a family history of anesthetic problems may indicate whether malignant hyperthermia should be considered.

A general review of the organ systems is important in identifying undiagnosed medical problems. **Questions should emphasize:**

- previous cardiovascular problems
- pulmonary diseases
- endocrine dysbalance
- hepatic dysfunction
- renal insufficiency
- neurological illness

## Physical Examination

The physical examination complements the history and helps to detect abnormalities not apparent from the history. Examination of healthy asymptomatic patients should minimally consist of measurement of vital signs (blood pressure, heart rate, respiratory rate, temperature). Using standard techniques of inspection, auscultation, palpation and percussion, the airway, heart and lungs should be examined when the history shows this to be necessary. An abbreviated neurological assessment serves to demonstrate a subtle preexisting neurological deficit. The patient's extremities and joint mobility should be assessed with regard to positioning (e.g., assessment of shoulder mobility for prone positioning).

A physical assessment is mandatory to detect putative intraoperative complications

## Laboratory Studies

Requirements for preoperative laboratory studies, chest X-ray and electrocardiogram are determined by the age and health of the patient as well as by the scope of the procedure. There has been a trend toward decreased routine testing in many patients.

In a recent study with elderly surgical patients, the prevalence of abnormal preoperative values for electrolytes, hemoglobin, platelets, creatinine and glucose values was low and was not predictive of postoperative adverse outcomes [12].

Additional **preoperative cardiac testing** is indicated only in those patients at intermediate risk according to the Revised Cardiac Risk Index (Table 2). When the functional status is poor or unclear and the risk of coronary heart disease is increased, additional apparative examinations are indicated, although there is no evidence of improved outcome. In those patients clearly at high risk, the possibility and urgency of an intervention related to their cardiac disease must be weighed against the urgency and invasiveness of planned non-cardiac surgery [27].

Preoperative cardiac testing is indicated when functional status is poor or unclear and the risk of coronary heart disease is increased

**Table 2.** Revised Cardiac Risk Index [20]

| Risk factors | Criteria |
|---|---|
| high risk surgery | • thoracic, abdominal and vascular surgery |
| coronary heart disease | • myocardiac infarction, angina pectoris, positive stress testing |
| congestive heart failure | • history, physical status |
| cerebrovascular insults | • TIA, apoplexia |
| diabetes mellitus | • insulin dependency |
| renal insufficiency | • serum creatinine > 177 (mol/l) |

Stable patients undergoing major non-cardiac surgery with at least three of these factors have an increased risk for cardiovascular complications during the subsequent 6 months, even if they do not have major perioperative cardiac complications

## Organ-Specific Assessment

### Airway Assessment

Difficulties in airway management should always be considered

The potential for difficulties in airway management should always be considered [9, 46], particularly in those patients presenting for surgery of the upper thoracic or cervical spine.

A careful airway assessment should be made with regard to:

- previous difficulty in intubation
- degree of mouth opening
- size of the tongue
- visibility of the pharynx
- the state of dentition
- restriction of neck movement
- stability of the cervical spine

Assessment of cervical stability is mandatory in patients with Down's syndrome and rheumatoid arthritis

In **rheumatoid arthritis** [45] at least 20 % and in **Down's syndrome** [1] up to 20 % of patients suffer from compromised stability of the cervical spine, particularly the atlantoaxial joints. This makes careful manipulations during laryngoscopy, intubation and positioning mandatory to avoid dislocation with subsequent spinal cord compression. In such cases, some authors recommend functional views of the cervical spine to assess the degree of instability.

The cervical spine of traumatized patients is unstable until demonstrated otherwise

Severely traumatized patients or patients with head injury should be assumed to have an unstable cervical spine. It is essential to discuss preoperatively the stability of the spine with the surgeon who is responsible for the clinical and radiological assessment. In patients with an unstable spine, awake intubation is required.

Awake fiberoptic intubation is recommended in patients with an unstable cervical spine

**Several methods** may be used to **intubate** these patients:

- awake fiberoptic intubation after topical anesthesia
- intubation with manual stabilization of the neck by the surgeon (in selected cases)

Awake fiberoptic intubation of a mildly sedated patient is preferred, because intubation of the unconscious patient predisposes to greater risk of hypoxic injury [2].

The type of intubation in patients with an unstable spine needs to be determined preoperatively

In these patients, nasotracheal fiberoptic intubation is usually easier than oral fiberoptic intubation because the nasopharynx, oropharynx and glottis are commonly in the same axis. Fiberoptic guided nasal intubation should be attempted only if there is no evidence of facial trauma or skull fracture to avoid neurological injuries. In an airway emergency, direct laryngoscopy and intubation can be necessary before cervical spine injury is excluded. In this situation, a second person should stabilize the cervical spine during the procedure to avoid as much as possible flexion and extension of the neck. In the presence of minor clinical instability, intubation can be carried out with manual stabilization of the cervical spine, which should preferably be done by the surgeon.

Some inherited disorders such as Duchenne muscular dystrophy or Down's syndrome may lead to **glossal hypertrophy** [39], which may cause a problem during intubation.

Previous radiotherapy of tumors of the head and neck can cause difficulty in direct laryngoscopy.

### Respiratory System

The value of routine preoperative chest radiographs in asymptomatic patients is very limited, since abnormal findings are reported to be few, rarely leading to

changes in clinical management and with an unknown effect on patient outcomes [32]. One of the most important reasons for this investigation may be to resolve medicolegal issues.

Pulmonary complications are frequent in major spinal surgery

**Pulmonary complications** such as pneumonia, lobar collapse and atelectasis are the most common form of postoperative morbidity experienced by patients who undergo general surgical abdominal procedures and thoracotomy. These surgical procedures cause large reductions in vital capacity and functional residual capacity [15]. The latter has long been identified as the single most important lung volume measurement involved in the etiology of postoperative respiratory complications. Functional residual capacity decreases after upper abdominal operations and thoracotomy by 30 – 35 %.

According to the extent of the surgical procedure and the preoperative patient condition, the respiratory function should be assessed with **pulmonary function testing** including blood gas analysis in patients with:

- asthma
- chronic obstructive pulmonary disease
- chronic intrinsic restrictive pulmonary diseases such as fibrosis and sarcoidosis
- extrinsic restrictive pulmonary diseases such as kyphoscoliosis and neuromuscular disorders

As a rough guideline, the **risk of postoperative pulmonary complications** can be assumed to be increased when:

- forced vital capacity (FVC)
- forced expiratory volume in 1 s ($FEV_1$)
- $FEV_1$/FVC ratio
- peak expiratory flow rate (PEFR)

Respiratory function should be assessed focusing on functional impairment

are lower than 50 % of the predicted value based on patient age, weight and height [4]. In patients with Duchenne muscular dystrophy, the limits for FVC and PEFR will have to be set at lower values [31]. The result of these investigations can influence the decision on the kind of anesthesia (epidural or spinal anesthesia instead of general anesthesia), and in the case of very limited conditions with respiratory global insufficiency, the dimension of the surgical procedure may be discussed and reevaluated with the surgeon.

**Respiratory function** should be optimized by treating any reversible cause of pulmonary dysfunction, including infection, with physiotherapy and nebulized bronchodilators as indicated. Although a controversial topic in the literature [19, 42], for patients at increased risk for postoperative pulmonary complications, preoperative instruction and training on how to perform postoperative pulmonary rehabilitation can still be recommended.

There is controversy as to whether surgery for idiopathic scoliosis improves or worsens **pulmonary function** [8, 23]. In one study, surgery involving the thorax (anterior or combined approach, rip resection) was associated with an initial decline in forced vital capacity, forced expiratory volume in 1 s and total lung capacity at 3 months, followed by subsequent improvement to preoperative baseline values at 2 years postoperatively. Surgery involving an exclusively posterior approach, however, was associated with an improvement in pulmonary function tests by 3 months (statistically not significant) and after 2 years (statistically significant) [44].

A history of dependence on **continuous nasal positive airway pressure at night** is also a sign of severe functional impairment and of reduced physiological reserve. These findings should prompt serious consideration as to whether surgery represents an appropriate balance between its potential benefits and the high risk of long-term postoperative ventilation in such patients.

## Cardiovascular Assessment

Perioperative cardiac risk assessment with the Revised Cardiac Risk Index is recommended

Perioperative cardiac morbidity is one of the major challenges for the anesthetist. The elderly patient population presenting for spinal surgery has substantially increased over the last decade. Consequently, the incidence of spinal surgery in patients with coronary heart disease has increased. Special attention must be paid to those patients at increased risk and where coronary heart disease has not been formally assessed. This patient population represents the vast majority. The use of a **Revised Cardiac Risk Index** [25] (Table 2), which includes patient-related as well as surgery-related risk, is recommended as its predictive value has been confirmed to be very high in elective non-cardiac surgery.

In patients with proven coronary heart disease, poor functional status and/or positive stress testing, a preoperative coronary angioplasty can reduce the risk of suffering from cardiac complications, but only when performed at least 90 days before the non-cardiac surgical intervention [27].

Elective surgery should be postponed for 3–6 months after myocardial infarction

Patients who have had a myocardial infarction should have their operations postponed for at least 3–6 months after the infarct in order to avoid the greatest risk of reinfarction.

An atrial septal defect (ASD) is apparent in 10% of patients with congenital heart disease. There is an accumulating incidence in patients with Marfan, Turner's and Down's syndromes. The ostium secundum form is caused by failure of closure of the foramen ovale and is the most common type (75%) of ASD. Most children with this defect are minimally symptomatic. Often adults in the 4th decade become symptomatic for the first time with congestive heart failure or hypertension. In the absence of heart failure, anesthetic responses to inhalational or intravenous agents are not altered. The presence of shunt flow between the right and left heart, regardless of the direction of blood flow, mandates the exclusion of air bubbles or clots from intravenous fluids to prevent paradoxical embolism into the cerebral or coronary circulation [16].

The anesthetist must be aware of the impaired cardiovascular function in patients with systemic rheumatoid arthritis, since cardiovascular disease (e.g., myocardial infarction secondary to coronary arteritis or pericardial manifestation of cardial disease) is the leading cause of death in the rheumatoid patient [29].

In contrast, most pediatric cardiac compromise is a direct result of the **underlying pathology**, such as:

- cardiomyopathy in Duchenne muscle dystrophy or Friedrich's ataxia
- aneurysmal dilatation in Marfan syndrome with potential risk for acute dissection
- cardiac dysfunction in severe kyphoscoliosis with distortion of the mediastinum, and secondary cor pulmonale

Assessment of **functional cardiovascular impairment** is difficult in patients who are wheelchair-bound. Minimum investigations should include electrocardiography and echocardiography to assess left ventricular function. Dobutamine stress echocardiography may be used to assess cardiac function in patients with a limited exercise tolerance [36].

The indications for preoperative transthoracic echocardiography are evaluation of ventricular dysfunction and evaluation of valvular function in patients with a murmur. But these investigations add only little information to routine clinical and electrocardiographic data for predicting ischemic outcomes [27].

Angiography should only be performed before spinal surgery in those high-risk patients who warrant revascularization for medical reasons, independent of surgery [27].

Furthermore, there is an increased incidence of cardiac complications during emergency non-cardiac surgery [25]. The reason is simply because there is no (or only limited) time for a proper risk stratification with adequate consecutive diagnostic and therapeutic management.

If the history and physical status taken by the surgeons reveal the presence of pathological conditions of the large vessels such as stenosis of the carotid artery, aortic aneurysm or peripheral vascular disease, it should be discussed whether spinal surgery needs to be postponed. The anesthesiologist can help to evaluate carefully the individual risk-benefit balance for this patient and to define the risk management in this situation (planned operation, necessary anesthetic procedure).

### Neurological Assessment

Avoid further neurological deterioration during tracheal intubation and patient positioning

A neurological examination of the patient should be made preoperatively including assessment of gait, motor or sensory deficits and reflexes. This should be documented since the anesthesiologist has a responsibility to avoid further neurological deterioration during maneuvers such as tracheal intubation and patient positioning. Congenital kyphosis and scoliosis, postinfectious scoliosis, neurofibromatosis and patients with skeletal dysplasias carry an increased neurological risk as well as patients with neurological deficits prior to surgery.

## Perioperative Drug Therapy

Assess any history of drug allergies

There is a need to assess the present drug therapy and any history of potential drug allergies. Together with the history and physical examination this will help to decide which drugs should be stopped, continued or added to provide the best possible perioperative conditions.

### What to Stop, to Continue and to Add?

Treatment of systemic hypertension should be continued

Even on the day of surgery, treatment of systemic hypertension should be continued with **antihypertensive drug therapy** as usual. It is important that patients under therapy with **beta-blocking agents** continue to receive their medication to avoid complications that accompany a sudden withdrawal. However, it is controversial as to whether **ACE inhibitors** should be administered perioperatively when profound blood loss is expected.

Therapy with digoxin should be continued perioperatively, but control of serum concentration is recommended in the elderly patient if the renal function is impaired, if patient compliance is doubtful or comedication with, e.g., amiodarone has been introduced.

Perioperative prophylaxis with beta-blocking agents is advised in patients with increased cardiac risk

Patients with increased cardiac risk can receive a benefit from prophylaxis (for up to 5–7 days postoperatively) with **cardioselective beta-blocking agents** such as atenolol, metoprolol and bisoprolol by the blocking of adverse cardiac effects of an activated sympathetic tone. It has been shown that this perioperative medication can prevent perioperative cardiac complications, can reduce the incidence of perioperative ischemic episodes and can improve survival rate up to 2 years postoperatively [26, 47].

Preoperatively, therapy with **inhibitors of the platelet aggregation** (e.g., aspirin, clopidogrel, abciximab or tirofiban) or therapy with coumarin derivates must be replaced 7–10 days before the intervention with continuous unfractioned heparin or repetitive bolus of low-molecular weight heparins [30].

Long-acting antihyperglycemic drugs should be stopped preoperatively

**Oral antihyperglycemic drugs** should be stopped preoperatively because of potential dangerous hypoglycemic episodes (e.g., sulfonylurea) and lactacidosis (e.g., biguanide). Long-acting insulins are preferably changed to intermediate- or short-acting insulins that offer better glucose control in the perioperative setting.

The use of **bronchodilating agents** such as $\beta_2$-agonists may be of value in optimizing respiratory function preoperatively in patients with chronic obstructive pulmonary disease. A preoperative therapy with these drugs should be continued.

Chronic neurotrophic medication with:

- tricyclic antidepressants
- selective serotonin reuptake inhibitors
- lithium, neuroleptic agents
- anti-Parkinson drugs

should all be continued perioperatively. However, therapy with first generation inhibitors of monoaminoxidase should be interrupted 2 weeks prior to surgery.

Patients on long-term steroid medication are prone to an acute Addison's crisis

Patients with rheumatoid arthritis are often on long-term **steroid therapy**. Patients who have received potentially adrenal gland suppressive doses of steroids (e.g., the daily equivalent of 5 mg of prednisone) by any route of administration for more than 2 weeks in the previous 12 months should be considered unable to respond appropriately to surgical stress. This medication should be continued perioperatively and these patients require careful observation so as not to miss an acute adrenal insufficiency; sometimes they will require perioperative steroid supplementation. What represents adequate steroid coverage is still controversial. Drugs such as penicillamine, methotrexate and azathioprine have immunosuppressant properties and may retard wound healing.

In patients with a high spinal cord lesion, or those undergoing fiberoptic intubation, administration of anticholinergic agents such as atropine should be considered.

Many patients will have factors which increase the risk of regurgitation and aspiration of gastric contents such as:

- high spinal cord injury
- recent traumatic injury
- stomach ulcers and gastritis
- gastroesophageal reflux disease
- nasogastric tubes in situ (compromise of the upper esophageal sphincter)

In these circumstances, it may be prudent to premedicate patients with a histamine-2 receptor antagonist, a proton pump inhibitor or even sodium citrate [13].

## Premedication

The goal of premedication is to have a mentally relaxed and comfortable patient arriving in the operating room. No single drug or dose will accomplish this satisfactorily and it must be decided for every patient what and how much to use. **Anxiolytic drugs** such as oral benzodiazepines (e.g., midazolam) are effective for this purpose. If the patient is currently receiving appropriate analgesics (e.g., oral opioids), it is logical to continue this medication if there are no contraindications.

## Thromboembolic Prophylaxis

The risk of developing a venous thromboembolism increases continuously with aging. Surgery, especially orthopedic surgery, can increase this risk about 20 times and thus also increase the danger of developing a pulmonary embolism

(PE) [5]. While clear schemes do exist for the prevention of venous thromboembolism in orthopedic hip and knee surgery, there is little concordance in spine surgery. The possibility of developing deep vein thrombosis (DVT), PE and serious bleeding is often present in the same patient. Bleeding in spine surgery, such as spinal epidural hematoma (SEH), can result in grave complications, e.g., residual paraplegia. In spine surgery the risk of developing a DVT without prophylaxis is around 5 % (0.3 – 15.5 %) [10, 34], while serious bleeding complications manifest in only 0.1 – 1 % of patients [7, 24]. There are no studies dealing with bleeding complications under thromboembolic prophylaxis, but the risk of a DVT can decrease to 0.05 – 1 % [18]. Another study showed that there was no significant difference between the occurrence of DVT and/or PE with or without thromboembolic prophylaxis in lumbar disc surgery [11]. A clear significance in the efficacy of DVT prevention could be seen in favor of intermittent pneumatic compression (IPS) vs compression stockings [10].

If the decision is made to perform antithrombotic therapy for spine surgery, the question arises about the onset and modality. Options for the latter include mechanical prophylaxis such as compression stockings and intermittent pneumatic compression and medicamentous prophylaxis such as **low molecular weight heparins** (LMWH) and low dose **unfractioned heparins** (LDUH).

The **American College of Chest Physicians** (ACCP) suggest following the procedures for elective spine surgery without giving firm recommendations [17]:

There are no firm recommendations for anti-thromboembolic prophylaxis

- The use of compressive stockings and the best possible early mobilization in every case.
- Patients without or few risk factors should receive standardized LMWH.
- Patients at risk should receive standardized LMWH and IPS, or postoperative LDUH.
- In high risk patients or patients with DVT/PE, a caval umbrella should be considered preoperatively.

The onset of antithrombotic treatment by LMWH, especially in spine surgery, has not yet been standardized. In Europe the initiation of the thromboembolic prophylaxis starts on the preoperative evening with mostly one dose of 0.4 ml (40 mg) enoxaparin subcutaneously (s.c.). The second administration takes place about 8 h postoperatively and then is dispensed once daily. In the United States the first dose of LMWH, mostly 0.3 ml/30 mg of nadroparin s.c., is given about 12 – 24 h postoperatively, then twice daily.

In a literature review, taking the levels of evidence into account, the following schedule is proposed [17, 37]:

The most effective **timing for prophylaxis** onset is 2 h preoperatively, but increases the risk of bleeding tremendously. The administration of LMWH more than 12 h preoperatively is no longer effective. The particular risk of developing a DVT/PE starts about 6 h postoperatively, when no LMWH has been administered previously. A suggested timing for antithrombotic treatment in spine surgery is to administer 0.4 ml enoxaparin s.c. between 12 and 8 h preoperatively and/or 8 h postoperatively.

In our center, we routinely follow the ACCP guidelines for the prevention of venous thromboembolism in spine surgery with LMWH, despite the implantation of caval umbrellas. In a retrospective review of 1 400 patients whose spines were operated on in our institution, 16 (1.1 %) had postoperative spinal epidural hematomas needing surgical revision. Fourteen of those had high risk factors for either DVT or postoperative bleeding (Table 1) and received more than the standard LMWH dosage perioperatively.

Spinal epidural hematoma (SHE) remains a rare postoperative incident also in patients receiving thromboembolic prophylaxis with LMWH. It mainly occurs in

patients who are at risk of bleeding complications, as well as DVT and/or PE. Optimized patient management with the awareness of present risk factors may not prevent the development of a SHE, but will allow the recognition of this problem at an early stage and result in a rapid operative intervention. Revision surgery should take place a maximum of 12 h after the first appearance of symptoms, which will be mostly severe radiculopathic pain followed by spinal compression symptoms. With early decompression, the sequelae will remain distinctive and transient. In decompression surgery with laminectomy over more than one level, or anterior approaches, the higher risk of DVT/PE can be minimized by perioperative application of mechanical and medicamentous prophylaxis.

## Special Conditions Requiring Spinal Surgery

### Spinal Deformity

Scoliosis can cause restrictive pulmonary disease

It is mandatory to evaluate pulmonary and cardiac function before scoliosis correction. The heart and lungs may be directly affected (such as by mechanical pulmonary compromise) or they may be affected as part of a syndrome.

#### Pulmonary Assessment

The most common blood-gas abnormality is reduced $PaO_2$ with normal $PaCO_2$

Scoliosis causes restrictive pulmonary deficit and the severity of functional impairment is related to the angle of the scoliosis, the number of vertebrae involved, a cephalad location of the curve, and a loss of the normal thoracic kyphosis [28] (**Table 3**). The extent of functional impairment cannot, therefore, be directly inferred from the angle of scoliosis alone. The most common blood-gas abnormality is a reduced arterial oxygen tension with a normal arterial carbon dioxide tension (normal range of $PaO_2$ 9.5 – 14.5 kPa, normal range of $PaCO_2$ 4.5 – 6 kPa), as a result of the mismatch between ventilation and perfusion in hypoventilated lung units.

**Table 3.** Influence on pulmonary impairment in patients with scoliosis

- angle of scoliosis
- number of vertebra bodies involved
- cephalad location of the curve
- loss of normal thoracic kyphosis
- neuromuscular disease

Restrictive lung disease can progress to irreversible pulmonary hypertension and cor pulmonale

An important clinical determinant is assessment of the patient's exercise tolerance, which is a clinical indicator of pulmonary reserve. As the disease progresses, hypercapnia may be seen, which is an indicator of severe pulmonary compromise. Pulmonary disease can progress to the point of irreversible pulmonary hypertension and cor pulmonale [29]. In patients with idiopathic scoliosis, a curvature of less than 65° is usually not associated with pulmonary compromise. However, patients with neuromuscular disease, paralysis or congenital scoliosis may show significant pulmonary compromise with lesser degrees of curvature. Scoliosis associated with neuromuscular disease has also been shown to be accompanied by abnormalities in central respiratory control. Routine preoperative testing should therefore include chest X-ray, spirometry, arterial blood gas analysis and an echocardiogram.

### Cardiac Assessment

Cardiovascular abnormalities are most commonly caused by **pulmonary hypertension** (secondary to chronic hypoxia and hypercapnia). Right ventricular hypertrophy and cor pulmonale may develop as a result of the elevated pulmonary resistance. ECG changes associated with pulmonary hypertension and right atrial enlargement (P wave greater than 2.5 mm, R greater than S in $V_1$ and $V_2$) may be seen but are usually not evident until late in the disease process.

Scoliosis is also associated with congenital heart abnormalities [30]. Mitral valve prolapse is common in patients with idiopathic scoliosis with a prevalence of about 25 %. If a murmur is heard on physical examination, an echocardiogram is recommended.

Mitral valve prolapse can be associated with idiopathic scoliosis

**Marfan syndrome** may be associated with mitral valve prolapse, dilatation of the aortic root and aortic insufficiency. Prophylaxis against infective endocarditis should be administered to patients who have mitral valve prolapse or other lesions resulting in disturbances of flow.

Echocardiogram is recommended to assess pulmonary hypertension and congenital heart abnormalities

## Neuromuscular Disease

The most common neuromuscular disease is **Duchenne muscular dystrophy**, with an incidence of one in 3 300 male births. It is inherited as a sex-linked recessive condition affecting skeletal, cardiac and smooth muscle. Over 90 % of these patients develop a progressive scoliosis when they become wheelchair bound. Patients lack the membrane cytoskeletal protein dystrophin and typically present between the ages of 2 and 6 years with progressive weakness of proximal muscle groups. Up to one-third of patients have intellectual impairment. Duchenne muscular dystrophy patients have a high incidence of deteriorating lung function and cardiac abnormalities (50 ± 70 %). In the later stages of the disease, a dilated cardiomyopathy may occur associated with mitral valve incompetence. Dysrhythmias occur and up to 50 % of patients have cardiac conduction defects [31]. Cardiac arrest in patients with Duchenne muscular dystrophy has been reported during spinal surgery [32].

Duchenne muscular dystrophy warrants thorough cardiac assessment

## Cerebral Palsy

Cerebral palsy is a non-progressive disorder of motion and posture and is the result of an injury to the developing brain. Clinical manifestations relate to the area affected and these children require special consideration because of their various disabilities. Visual and hearing deficits are common and will make communication difficult. This often leads to anxiety, but premedication has to be balanced with the unpredictable response. These patients should be accompanied by their carers at induction and in the recovery room, as they usually know how to communicate with the patient. Their understanding may be greater than seems apparent on first meeting. About one-third of these patients suffer from epilepsy and the anticonvulsive therapy should be continued. Respiratory problems can include pulmonary aspiration from reflux, recurrent respiratory infections and reduced ability to cough. The airway should be assessed for difficult laryngoscopy because of loose teeth and temporomandibular joint dysfunction. Other problems during the perioperative period that require caution may include hypothermia, nausea and vomiting and pain induced muscle spasm [33].

Anticonvulsive therapy should be continued perioperatively

## Malignancy

Patients with primary or secondary malignant disease of the vertebral column and spinal cord are increasingly being considered for surgery. Metastatic tumors occur three to four times more frequently than primary neoplasms within the vertebral column, and solitary vertebral lesions are often metastatic in the elderly. The vast majority of neoplastic cord compressions derive from metastatic tumors of the breast, lung, prostate or hematopoietic system. The thoracic spine is the most commonly affected [35].

Cancer patients are prone to complications

These patients have commonly lost a large amount of weight and have reduced physiological reserve. Respiratory complications of malignancy are common in such patients. **Further risks** include [36]:

- wound healing disturbance (protein loss)
- infection
- pleural effusion
- pulmonary toxicity (secondary to chemotherapy)
- increased risk for myocardial infarction (secondary to chemotherapy)
- metabolic derangements (e.g., hypercalcemia, SIADH)
- risk of coagulopathies (prostate cancer, hypernephroma)

The syndrome of inappropriate secretion of antidiuretic hormone (SIADH) is associated with small cell lung tumors, carcinoma of the prostate, pancreas and bladder, and central nervous system neoplasms [37].

Surgery for malignant tumors often requires extensive blood transfusions

Prior to surgery enough units of packed red blood cells should be available since spinal decompressive surgery for malignant processes often leads to a large blood loss.

## Spinal Cord Injury

Spinal shock begins immediately after the insult and lasts up to 3 weeks

Patients with traumatic spinal injury frequently present for surgical spinal stabilization during the period of spinal shock, which is the result of a **traumatic sympathectomy**. It begins almost immediately after the insult and may last for up to 3 weeks [38]. The clinical effects depend on the level of the lesion to the spinal cord and may involve several organ systems.

A traumatic sympathectomy occurs below the level of the spinal cord lesion with the risk of hypotension secondary to arteriolar and venular vasodilatation. Injuries at or above T6 are particularly associated with hypotension, as the sympathetic outflow to splanchnic vascular beds is lost. Bradycardia will occur if the lesion is higher than the sympathetic cardioaccelerator fibers (T1–T4), with the parasympathetic cranial outflow being preserved. A complete cervical cord injury produces a total sympathectomy and therefore hypotension will be more marked. Above the level of the lesion, sympathetic outflow is preserved. Vasoconstriction in the upper body vascular beds and tachycardia may be observed in response to the hypotension resulting from reduced systemic vascular resistance in the lower part of the body. Hypotension associated with spinal cord injury responds poorly to i.v. fluid loading, which may cause **pulmonary edema**. Vasopressors are the treatment of choice. Hypoxia or manipulation of the larynx or trachea during intubation may cause profound **bradycardia** or asystolia in these patients because of the unopposed vagal tone. In these situations atropine may be administered to attenuate the vagal effects. Other causes of hypotension should be excluded such as blood loss associated with other injuries, since a hemorrhagic shock will not be accompanied by a compensatory tachycardia. Positive pressure ventilation causes marked arterial hypotension as the systemic vascular resistance cannot be raised to offset the changes in intrathoracic pressure caused by positive pressure ventilation [38, 39].

Ventilatory impairment increases with higher levels of spinal injury. A high cervical lesion that includes the diaphragmatic segments (C3–C5) will result in **respiratory failure** and death unless artificial pulmonary ventilation is instituted. Mid to low cervical spine injuries (C5–C8) spare the diaphragm but the intercostal and abdominal muscles may be paralyzed. Further complications [39] of the paralysis due to a cervical spinal cord injury include:

Perioperative management of spinal cord injured patients is demanding

- an inadequate cough mechanism
- ineffective secretion clearing
- paradoxical rib movement on spontaneous ventilation
- decreased vital capacity (20 – 50 %)
- decrease in functional residual capacity (10 – 20 %)
- loss of active expiration
- paralytic ileus
- gastric distension
- thromboembolism

The paralytic ileus and the gastric distension increase abdominal pressure, further compromising diaphragmatic excursion. This gastric distension can be reduced by placement of a nasogastric tube and attaching it to suction.

**Autonomic dysreflexia** is a syndrome associated with chronic spinal cord injury and may be present after 3 – 6 weeks following the spinal cord injury. This condition is characterized by extreme autonomic responses such as:

- severe paroxysmal hypertension associated with bradycardia
- ventricular ectopy
- various degrees of heart block

Autonomic dysreflexia may be present after 3 – 6 weeks following the spinal cord injury

The initiation of these events can be stimulation of nerves below the level of the spinal cord lesion (for example, cutaneous, rectal, urological, peritoneal stimulation). Injuries higher than T7 have an 85 % chance of producing serious cardiovascular derangement [40]. Treatment involves removal of the noxious stimulus (e.g., bladder distension), increasing the level of analgesia and/or anesthesia and the administration of direct-acting vasodilators. If left untreated, the syndrome can provoke a hypertensive crisis causing seizures, myocardial ischemia or cerebral hemorrhage. Avoidance of this phenomenon in scheduled patients with chronic spinal injury necessitates either regional or general anesthesia despite a lack of motor or sensory function in the area of the surgery.

## Recapitulation

**Patient assessment.** The **preanesthetic evaluation** of patients for spinal surgery follows the general approach used before any patient is given anesthesia. Particular care should be given to the respiratory, cardiovascular, and neurological systems that can all be affected by the spinal pathology. The aim of the preoperative visit is to explain the anesthetic procedure and reduce the patient's anxiety. The need for **preoperative testings** is determined by the patient's age and health and by the scope of the procedure.

**Organ-specific assessment.** When assessing the **airway**, difficulties should always be considered. Traumatized patients or those with head injury are assumed to have an unstable cervical spine until this has been ruled out; the stability of the spine should be discussed preoperatively with the surgeon. These patients may be managed with awake fiberoptic intubation after topical anesthesia. **Respiratory function** should be assessed by a thorough history, focusing on functional impairment, and reversible causes of pulmonary dysfunction should be optimized. Because of the increased prevalence of coronary heart disease, **cardiac assessment** is a challenge to the anesthesiologist. Special attention should be paid to patients bear-

ing an increased risk where coronary heart disease has not been proven. Most pediatric cardiac compromise is a result of the underlying pathology, e.g., in patients with Duchenne muscle dystrophy, Marfan syndrome or scoliosis. Preoperative **neurological examination** should be documented since the anesthesiologist is responsible for avoiding further neurological deterioration during tracheal intubation and patient positioning. In **scoliosis** the thoracic deformity causes restrictive lung disease that can progress to irreversible pulmonary hypertension and cor pulmonale. Duchenne muscle dystrophy is a **neuromuscular disease** with a high incidence of lung function and cardiac abnormalities. Patients with **malignancy** have impaired physiological reserves, and metabolic derangements and surgery for malignant processes often lead to large blood loss. Spinal injury patients frequently present during **spinal shock**, a traumatic sympathectomy below the lesion which begins almost immediately after the insult and which may last up to 3 weeks. Vasopressors are the treatment of choice for the resulting hypotension. **Autonomic dysreflexia** may be present after 3–6 weeks following the spinal cord injury and is characterized by extreme autonomic responses such as severe paroxysmal hypertension. Avoidance of this phenomenon necessitates regional or general anesthesia for patients with chronic spinal cord damage scheduled for surgery.

**Perioperative drug therapy.** It is important to decide which **drugs** to stop, continue or add. Perioperative prophylaxis with beta-blocking agents in patients with increased cardiac risk can improve postoperative survival rate.

## Key Articles

**Mangano DT (1999) Assessment of the patient with cardiac disease: an anesthesiologist's paradigm. Anesthesiology 91:1521–6**
Systematically presented suggestions for selection of preoperative tests and therapy, based on the presence of coronary artery disease (or risk factors) and the patient's functional capacity.

**Lee TH, Marcantonio ER, Mangione CM, Thomas EJ, Polanczyk CA, Cook EF, Sugarbaker DJ, Donaldson MC, Poss R, Ho KK, Ludwig LE, Pedan A, Goldman L (1999) Derivation and prospective validation of a simple index for prediction of cardiac risk of major noncardiac surgery. Circulation 100:1043–9**
Useful and clinically applicable index for cardiac risk stratification in the context of elective major non-cardiac surgery. The authors outlined six risk factors for cardiac complications such as high risk type of surgery, ischemic heart disease, congestive heart failure, history of cerebrovascular insult, insulin dependent diabetes mellitus and increased preoperative serum creatinine.

**Hambly PR, Martin B (1998) Anaesthesia for chronic spinal cord lesions. Anaesthesia 53:273–89**
An excellent review of this topic.

**Mangano DT, Layug EL, Wallace A, Tateo I (1996) Effect of atenolol on mortality and cardiovascular morbidity after noncardiac surgery. Multicenter Study of Perioperative Ischemia Research Group. N Engl J Med 335:1713–20**
In patients who have or are at risk for coronary artery disease and who are undergoing non-cardiac surgery, it has been shown by these authors that the administration of atenolol throughout hospitalization can substantially reduce mortality and cardiovascular events after discharge from the hospital, particularly during the first 6–8 months after surgery, and the effects on survival persist for at least 2 years.

## References


1. Ali FE, Al-Bustan MA, Al-Busairi WA, Al-Mulla FA, Esbaita EY (2006) Cervical spine abnormalities associated with Down syndrome. Int Orthop 30:284 – 289
2. American Society of Anesthesiologists Task Force on Management of the Difficult Airway (2003) Practice guidelines for management of the difficult airway: an updated report by the American Society of Anesthesiologists Task Force on Management of the Difficult Airway. Anesthesiology 98:1269 – 77
3. Amzallag M (1993) Autonomic hyperreflexia. Int Anesthesiol Clin 31:87 – 102
4. Boushy SF, Billig DM, North LB, Helgason AH (1971) Clinical course related to preoperative pulmonary function in patients with bronchogenic carcinoma. Chest 59:383 – 91
5. Bramlage P, Pittrow D, Kirch W (2005) Current concepts for the prevention of venous thromboembolism. Eur J Clin Invest 35 (Suppl 1):4 – 11
6. Byrne TN (1992) Spinal cord compression from epidural metastases. N Engl J Med 327:614 – 9
7. Cabana F, Pointillart V, Vital JM, Sénégas J (2000) Postoperative compressive spinal epidural hematomas: 15 cases and a review of the literature. Rev Chir Orthop 86:335 – 345
8. Chen SH, Huang TJ, Lee YY, Hsu RW (2002) Pulmonary function after thoracoplasty in adolescent idiopathic scoliosis. Clin Orthop 399:152 – 61
9. Crosby ET, Cooper RM, Douglas MJ, Doyle DJ, Hung OR, Labrecque P, Muir H, Murphy MF, Preston RP, Rose DK, Roy L (1998) The unanticipated difficult airway with recommendations for management. Can J Anaesth 45:757 – 76
10. Dearborn JT, Serena SH, Clifford BT, Bradford DS (1999) Thromboembolic complications after major thoracolumbar spine surgery. Spine 24 (14):1471 – 1476
11. Desbordes JM, Mesz M, Maissin F, Bataille B, Guenot M (1993) Retrospective multicenter study of prevention of thromboembolic complications after lumbar disc surgery. Neurochirurgie 39 (3):178 – 181
12. Dzankic S, Pastor D, Gonzalez C, Leung JM (2001) The prevalence and predictive value of abnormal preoperative laboratory tests in elderly surgical patients. Anesth Analg 93:301 – 8
13. Engelhardt T, Webster NR (1999) Pulmonary aspiration of gastric contents in anaesthesia. Br J Anaesth 83:453 – 60
14. Faciszewski T, Winter RB, Lonstein JE, Denis F, Johnson L (1995) The surgical and medical perioperative complications of anterior spinal fusion surgery in the thoracic and lumbar spine in adults. A review of 1 223 procedures. Spine 20:1592 – 9
15. Ferguson MK (1999) Preoperative assessment of pulmonary risk. Chest 115:58S–63S
16. Findlow D, Doyle E (1997) Congenital heart disease in adults. Br J Anaesthesia 78:416 – 430
17. Geerts WH, Pineo GF, Heit JA, Bergqvist D, Lassen MR, Colwell CW, Ray JG (2004) Prevention of venous thromboembolism. The seventh ACCP conference on antithrombotic and thrombolytic therapy. Chest 126:338 – 400S
18. Gerlach R, Raabe A, Beck J, Woszczyk, Seifert V (2004) Postoperative nadroparin administration for prophylaxis of thromboembolic events is not associated with an increased risk of hemorrhage after spinal surgery. Eur Spine J 13:9 – 13
19. Hall JC, Tarala RA, Tapper J, Hall JL (1996) Prevention of respiratory complications after abdominal surgery: a randomised clinical trial. BMJ 12:148 – 52
20. Hambly PR, Martin B (1998) Anaesthesia for chronic spinal cord lesions. Anaesthesia 53:273 – 89
21. Kawakami N, Mimatsu K, Deguchi M, Kato F, Maki S (1995) Scoliosis and congenital heart disease. Spine 20:1252 – 5
22. Kearon C, Viviani GR, Kirkley A, Killian KJ (1993) Factors determining pulmonary function in adolescent idiopathic thoracic scoliosis. Am Rev Respir Dis 148:288 – 94
23. Kinnear WJ, Johnston ID (1993) Does Harrington instrumentation improve pulmonary function in adolescents with idiopathic scoliosis? A meta-analysis. Spine 18:1556 – 9
24. Kou J, Fischgrund J, Biddinger A, Herkowitz H (2002) Risk factors for spinal epidural hematoma after spinal surgery. Spine 27 (15):1670 – 1673
25. Lee TH, Marcantonio ER, Mangione CM, Thomas EJ, Polanczyk CA, Cook EF, Sugarbaker DJ, Donaldson MC, Poss R, Ho KK, Ludwig LE, Pedan A, Goldman L (1999) Derivation and prospective validation of a simple index for prediction of cardiac risk of major noncardiac surgery. Circulation 100:1043 – 9
26. Mangano DT, Layug EL, Wallace A, Tateo I (1996) Effect of atenolol on mortality and cardiovascular morbidity after noncardiac surgery. Multicenter Study of Perioperative Ischemia Research Group. N Engl J Med 335:1713 – 20
27. Mangano DT (1999) Assessment of the patient with cardiac disease: an anesthesiologist's paradigm. Anesthesiology 91:1521 – 6
28. Mansel JK, Norman JR (1990) Respiratory complications and management of spinal cord injuries. Chest 97:1446 – 52
29. Matti MV, Sharrock NE (1998) Anesthesia on the rheumatoid patient. Rheum Dis Clin North Am 24:19 – 34

30. Meyer B, Jende C, Rikli D, Moerloose de P, Wuillemin WA (2003) Periinterventionelles Management der oralen Antikoagulation: Fallbeispiele und Empfehlungen. Schweiz Med Forum 9:213
31. Morris P (1997) Duchenne muscular dystrophy: a challenge for the anaesthetist. Paediatr Anaesth 7:1 – 4
32. Munro J, Booth A, Nicholl J (1997) Routine preoperative testing: a systematic review of the evidence. Health Technology Assessment 1:I – IV; 1 – 62
33. Nolan J, Chalkiadis GA, Low J, Olesch CA, Brown TC (2000) Anaesthesia and pain management in cerebral palsy. Anaesthesia 55:32 – 41
34. Oda T, Fuji T, Kato Y, Fujita S, Kanemitsu N (2000) Deep venous thrombosis after posterior spinal surgery. Spine 25 (22):2962 – 2967
35. Pehrsson K, Larsson S, Oden A, Nachemson A (1992) Long-term follow-up of patients with untreated scoliosis. A study of mortality, causes of death, and symptoms. Spine 17:1091 – 6
36. Poldermans D, Boersma E, Bax JJ, Thomson IR, van de Ven LL, Blankensteijn JD, Baars HF, Yo TI, Trocino G, Vigna C, Roelandt JR, van Urk H (1999) The effect of bisoprolol on perioperative mortality and myocardial infarction in high-risk patients undergoing vascular surgery. Dutch Echocardiographic Cardiac Risk Evaluation Applying Stress Echocardiography Study Group. N Engl J Med 341:1789 – 94
37. Raskob GE, Hirsh J (2003) Controversies in timing of the first dose of anticoagulant prophylaxis against venous thromboembolism after major orthopaedic surgery. Chest 124:379S–385S
38. Reid JM, Appleton PJ (1999) A case of ventricular fibrillation in the prone position during back stabilisation surgery in a boy with Duchenne's muscular dystrophy. Anaesthesia 54:364 – 7
39. Sethna NF, Rockoff MA, Worthen HM, Rosnow JM (1988) Anesthesia-related complications in children with Duchenne muscular dystrophy. Anesthesiology 68:462 – 5
40. Sidi A, Lobato EB, Cohen JA (2000) The American Society of Anesthesiologists' Physical Status: category V revisited. J Clin Anesth 12:328 – 34
41. Sorensen JB, Andersen MK, Hansen HH (1995) Syndrome of inappropriate secretion of antidiuretic hormone (SIADH) in malignant disease. J Intern Med 238:97 – 110
42. Stiller K, Montarello J, Wallace M, Daff M, Grant R, Jenkins S, Hall B, Yates H (1994) Efficacy of breathing and coughing exercises in the prevention of pulmonary complications after coronary artery surgery. Chest 105:741 – 7
43. Supkis DE, Varon J (1998) Uncommon problems related to cancer. In: Benumof J (ed) Anesthesia and uncommon diseases, 4th edn. Philadelphia: WB Sanders Co., 545 – 60
44. Vedantam R, Lenke LG, Bridwell KH, Haas J, Linville DA (2000) A prospective evaluation of pulmonary function in patients with adolescent idiopathic scoliosis relative to the surgical approach used for spinal arthrodesis. Spine 25:82 – 90
45. Wolfs JF, Peul WC, Boers M, Tulder van MW, Brand R, Houwelingen van HC, Thomeer RT (2006) Rationale and design of The Delphi Trial – I(RCT)2: international randomized clinical trial of rheumatoid craniocervical treatment, and intervention-prognostic trial comparing 'early' surgery with conservative treatment. BMC Musculoskelet Disord 7:14
46. Yentis SM (2002) Predicting difficult intubation – worthwhile exercise or pointless ritual? Anaesthesia 57:105 – 9
47. Zaugg M, Tagliente T, Lucchinetti E, Jacobs E, Krol M, Bodian C, Reich DL, Silverstein JH (1999) Beneficial effects from beta-adrenergic blockade in elderly patients undergoing noncardiac surgery. Anesthesiology 91:1674 – 86

# 15 Intraoperative Anesthesia Management

Juan Francisco Asenjo

## Core Messages

- ✔ Communicate with your anesthetist. Talk to him before surgery if you have particular concerns about the patient or the procedure you are planning. Let him know constantly about how things are going during the surgery. Share your thoughts and team up
- ✔ Patients having major spine procedures must be properly assessed by the anesthesia team beforehand to increase safety and success in the perioperative period
- ✔ Special airway management and positioning could be challenging for the anesthesia team, sometimes involving longer preparation
- ✔ The anesthesia technique must allow for reliable neuromonitoring; SSEP recordings and wake-up test, short-acting drugs, TIVA and low-dose gases are indicated
- ✔ Blood preservation is a must. Careful surgical technique and positioning, antifibrinolytics, blood predeposit, cell recovery and controlled hypotension (CH) are the way to go. CH is contraindicated in the presence of spinal cord compression (tumor, trauma, etc.)
- ✔ Some cervical spine surgeries, long cases or those with massive transfusions might require postoperative ventilation
- ✔ Good pain control after surgery is associated with lower rates of postoperative chronic pain conditions and faster recovery. Multimodal analgesia is the cornerstone. NSAIDs could be controversial, but in low doses they are 17 times less likely than smoking to be linked to malunion
- ✔ Anesthesia should be tailored to fast-track minimally invasive spine surgery, emphasizing prevention of nausea, vomiting and pain control

## Historical Background

Precise information is not available about the first anesthesia for spine surgery. Definitive improvements began in the 1950s with the use of muscle relaxants, orotracheal intubation, introduction of halothane and more generous use of intravenous crystalloids. In the 1970s the wake-up test was described to assess the integrity of the spinal function. At the same time larger doses of opiates became popular to help maintain stable hemodynamic conditions and better pain control intra- and postsurgery. In the 1980s and 1990s new short-acting drugs contributed to the enhancement of the perioperative experience in patients having day surgery procedures, as well as permitting better neurophysiologic monitoring.

## Goals of Anesthesia in Spinal Surgery

The role of anesthesia care in spinal surgery must be appreciated within the context of comprehensive perioperative care where a dedicated team takes care of a patient from preoperative planning and perioperative care to rehabilitation and discharge. In many places this is accomplished through the design of "**Clinical Pathways**," a

Optimal teamwork between the surgeon and anesthetist is a prerequisite for successful surgery

road map for a particular surgical procedure with standardization of each step to reduce variability, cost and errors. The anesthesia contribution is a key component in this continuum. In a successful Clinical Pathway all players have agreed upon a road map, they have contributed the best evidence from their fields and everybody understands his or her own role and each other's inputs. In this chapter the most relevant features of anesthesia for spinal surgical procedures are discussed. Particular emphasis on trauma, scoliosis, and degenerative and cancer surgery is given.

## Preoperative Patient Assessment

Anesthesia for spine surgery can only be as good as the preoperative assessment and optimization

Recommendations for preoperative assessment, diagnostic work-up and condition dependent patient optimization have been provided in Chapter 14. Safe and efficient anesthesia for spinal interventions depends crucially on the quality of the preoperative assessment and patient optimization. A detailed preoperative assessment minimizes life-threatening risks and helps to avoid intra- and postoperative complications.

Optimal communication between surgeon and anesthetist is mandatory for successful surgery

The surgeon and anesthesiologist must team up, discuss and plan the operative procedure in advance, particularly in nonroutine cases. Good preoperative communication and a clear bilateral understanding of the procedure and the overall condition of the patient are prerequisites to successful surgery. Although seemingly trivial, the consequences of these rules being ignored are often seen in daily clinical practice.

## Induction of Anesthesia

Patients being admitted for surgery of the spine benefit from premedication with gabapentin. Our experience confirms recent publications [80] supporting the use of 300–600 mg before going to the operating room. It provides mild sedation and a powerful antihyperalgesic effect. If a **wake-up test** (WUT) is considered, benzodiazepines or other amnesic drugs are not recommended since the patient will not retain the information about the WUT provided before the induction of general anesthesia.

Patient identification and type and level of procedure must be checked prior to anesthesia

Prior to starting the anesthetic procedures, the identification of the patient, the type of procedure and the level to be operated at (which is key in spine surgery) must be checked and confirmed to avoid "**wrong patient, wrong side and wrong site surgery**" particularly if patients with identical surnames are on the operating list.

Before starting the anesthetics, the **minimum standard monitoring** for general anesthesia in an otherwise healthy patient undergoing low risk spine surgery encompasses:

- hemoglobin-$O_2$ saturation
- noninvasive blood pressure
- end-tidal $CO_2$
- continuous ECG

The patient's preoperative condition and type of surgery will dictate the use of other monitoring before starting the operation.

At least one large bore i.v. cannula should be in place prior to the induction of anesthesia and for major cases. A second cannula is inserted after the patient is asleep unless a central venous catheter is considered.

The choice of induction agent (propofol, thiopental, opiates, etomidate or inhaled agents in children) will depend on the general condition of the patient and the presence of trauma associated hypovolemia, cardiac conditions and cord com-

pression with marginal blood perfusion. The choice of muscle relaxants to facilitate the intubation will be influenced by conditions like full stomach, gastroesophageal reflux and trauma. Nondepolarizing agents such as rocuronium, vecuronium and cisatracurium have a safe record and are widely used today in spine surgery. Succinylcholine should be avoided in patients with muscular dystrophy as well as in patients with spinal cord injury between 3 and 180 days postdenervation because of the potential for hyperkalemia, secondary arrythmias, and cardiac arrest. Acute denervation induces an increment in the number of cholinergic receptors in the perijunctional area. Succinylcholine is a depolarizing type of muscle relaxant; therefore in this condition it will release massive amounts of potassium [30, 70].

Succinylcholine should be avoided in patients with muscular dystrophy and spinal cord injury

## Airway Control and Endotracheal Intubation

A decision should be made whether to gain control of the airway in advance of or after the induction of anesthesia to assess neurological status after airway manipulation and positioning the patient on the table. Patients with unstable C-spine or using a halo vest might need **fiberoptic intubation** and awake positioning to ensure preservation of neurological function. If awake positioning is needed with traction devices anchored to the skull (e.g., a skull clamp or Mayfield head support), infiltrating the area where the pins are going to be placed (with 4–6 ml of bupivacaine 0.25 % with epinephrine 5 µg/ml at each point) **at least 10 min prior to pin insertion** is suggested. Occasionally a low-dose infusion of remifentanyl (0.05–0.1 µg/kg/min) is maintained during the whole procedure of intubation and positioning. In the event that the patient's mental status is not reliable enough to ensure a safe surgical positioning, an alternative is to do a baseline somatosensory evoked potential (SSEP)/motor evoked potential (MEP) recording before anesthesia and positioning and compare it to the one immediately after installation on the surgical table (Table 1).

**Table 1.** Indications for awake fiberoptic intubation

| Absolute | Relative |
|---|---|
| • prior occipitocervical fusion<br>• cervical spinal cord compression<br>• patient to be positioned awake on the table<br>• cervical spine trauma<br>• atlantoaxial instability | • history of difficult intubation<br>• prior extensive C-spine fusion<br>• risk of aspiration<br>• halo vest in position<br>• severe kyphoscoliosis<br>• orofacial malformations |

There is controversy as to whether direct laryngoscopy is a major factor contributing to cord injury in patients with **cervical spine instability** [48]. In this setting, however, other factors such as hypotension and patient positioning may be even more important. Laryngoscopy with manual inline stabilization by the surgeon or with a stiff collar is an accepted means of intubation for many patients with an unstable cervical spine as long as movement of the neck can be avoided [48]. Patients with difficult airways may require fiberoptic intubation, a GlideScope device (a fiberoptic laryngoscope with a screen, see Fig. 1) or a laryngeal airway mask (the "fast track") to gain airway control. Careful freezing of the airway with local anesthetic is important to avoid coughing during tube placement in patients with unstable C-spine.

Direct laryngoscopy should be avoided in patients with spinal cord compromise

In the case of anterior access to the thoracic spine, selective collapse of the ipsilateral lung facilitates performance of the procedure by the surgeon. Some choices exist in this situation between:

- a regular orotracheal (OT) tube with a bronchial blocker, which is possibly the first option. It requires a regular OT tube to be placed, followed by fiber-

**Figure 1. GlideScope**

Direct laryngoscopy without moving the head or C-spine. Observe on the screen the deflated cuff of the endotracheal tube under the epiglottis crossing the vocal cords.

optic deployment of a bronchial blocker (type Cohen or Arndt) similar to a Fogarty catheter to restrict the ventilation to the nondependent lung. It is the simplest way of isolating and deflating the lung.

- a Univent OT tube, which is a slightly larger tube because of a bronchial blocker channel built-in to its wall. This tube is placed in the trachea like a regular OT tube. The built-in bronchial blocker is advanced under direct fiberscopic vision through its channel to the main bronchus of the nondependent lung. It is the fastest way of isolating the lung.
- a **classic double lumen device** which is very reliable, but which can be more traumatic for the airway and vocal cords. If the patient remains intubated in the postop, this is the only type of tube that will need to be changed for a regular one. Placement of this type of tube may also be more difficult in patients with complex airways.

Standard use of the more expensive reinforced armored orotracheal tube in patients operated on in the prone position is not clearly justified in the literature [34]. Furthermore, if the patient bites the armored tube (for instance, face-down during a WUT or while on ventilator support in the recovery room or ICU), it will remain deformed and collapsed, diminishing or totally blocking the gas flow, causing a major problem to breathing. Changing the tube with the patient in the prone or lateral position or during cervical spine surgery might be catastrophic. A nasogastric or orogastric tube is routinely passed intraoperatively and removed before extubation in anterior C-spine procedures to help the surgeon identify the esophagus and decrease postoperative nausea and vomiting. For anterior lumbar approaches, the stomach is decompressed of gas and secretions by using the gastric tube. **Careful eye protection** with cream, occlusive tape and peripheral padding is mandatory in particular in patients positioned prone or in anterior approaches to the cervical spine (Fig. 2). In prepping the neck for posterior approaches, irritant solutions might reach the eyes from behind, remaining there for hours with the potential for severe corneal damage.

Careful eye and face protection is crucial

**Figure 2. Eye and face protection**

Details of the eye (a) and face protection (b) in a patient having anterior C-spine surgery due to trauma. The eyes are covered with cream and seal and are then padded to avoid damage by pressure or sharp objects. Nasogastric tube is in place.

After deployment of the surgical retractors in anterior cervical spine surgery, the pressure inside the endotracheal tube cuff frequently reaches 40–50 mm Hg. It should be rechecked in order to maintain it between 15 and 20 mm Hg; this is even more important if the anesthetist is using $N_2O$ in the gas mixture due to its fast diffusion into the cuff. These marked increases in the cuff pressure along with lengthy total intubation time are frequently reported to elevate tracheal and pharyngeal morbidity such as hoarseness and vocal cord palsy [3]. Once the surgical team finishes positioning the patient, it is wise to confirm that the endotracheal tube has not moved and that bilateral ventilation and breath sounds are adequate.

It is also a good time to verify that the bronchial blocker is still in the right place if one lung ventilation is desired.

## Antibiotic Prophylaxis

Routine antibiotic prophylaxis today is standard in spinal surgery

Postoperative infections in spine surgery are primarily monomicrobial, although in about half of infected patients more than one organism can be identified. The bacteria most commonly cultured from wounds are *Staphylococcus aureus* and *epidermidis* [17]. Postoperative infections occur in 0.3–9% of patients undergoing spine surgery [75]. **Increased risk of spine postoperative infections** has been associated with:

- staged procedures
- blood loss in excess of 1000 ml
- surgery longer than 4 h
- smoking
- diabetes
- malnutrition
- obesity
- immunocompromised patients
- alcoholism
- posterior approach
- postoperative incontinence

- cancer surgery
- extended preoperative hospitalization
- intraoperative hypothermia

For the **antibiotic prophylaxis** to be effective, a drug with bactericidal activity against the most common infecting organisms must be present in the tissues at risk from the moment of the incision and for the duration of the surgery. Cefazolin's spectrum is sufficiently broad to be effective but limited enough to avoid resistance and superinfection. Cefazolin's penetration into the subcutaneous tissue and the intervertebral disc is adequate if serum concentration is maintained. In most hospitals, cefazolin is the agent of choice because it has an optimal antimicrobial coverage, is relatively nontoxic and inexpensive, and has excellent penetration into the tissues at risk. The agent should be started within 30 min before skin incision. A blood loss greater than 1 500 ml or a duration of surgery exceeding 4 h warrants redosing of the antibiotic, which should only be given for 24 h perioperatively. The responsibility for the prudent administration of prophylactic agents has therefore moved to the domain of the anesthesiologist. These practices will result in the most efficacious and judicious use of antibiotics [14]:

Redose antibiotics in cases with prolonged surgery and/or substantial blood loss

- maintaining therapeutic concentrations when appropriate
- avoiding excessive cost
- minimizing emergence of resistant microbial pathogens

Although adverse reactions are actually rare, patients with a history of these events should receive an alternative antibiotic; vancomycin or clindamycin are second line choices in this setting. In selecting the antibiotic, local patterns of pathogens from infection control data should play a role. Hospitals with a high prevalence of resistant microbes, such as the methicillin-resistant *S. aureus* (MRSA), may consider using alternative agents. Most procedures with the implantation of foreign material warrant prophylaxis. Foreign bodies not only allow more efficient colonization, but also protect the organisms from systemic antibiotics, making these complications extremely difficult to treat. Due to the high rate of infection without prophylaxis, the severe associated morbidity, and the lack of effective therapy, prophylaxis is indicated in any spinal procedure where the intervertebral disc is manipulated. The use of antimicrobial prophylaxis in spinal surgery can reduce the number of both superficial and deep wound infections. The benefits of this intervention include less patient pain and discomfort, shorter hospital stays, and fewer expenses.

## Patient Positioning

Correct patient positioning is mandatory for a successful outcome

Patient position for surgery depends on the level of the spine to be operated on and the kind of intervention to be performed. In some procedures (such as anteroposterior lumbar surgery) the patient is repositioned while asleep to complete the operation. It is not clear whether positioning a patient with an unstable cervical spine is safer awake or asleep. In elderly patients with severe cervical spondylosis, positioning with the neck in extension may result in spinal cord compression between the ligamentum flavum and posterior vertebral body osteophytes. Cervical approaches can be done with the patient prone or supine. Thoracolumbar surgery might require lateral decubitus to gain access to the intrathoracic spine as well as the upper lumbar section. Most scoliosis procedures are done with the patient in the prone position.

Attention must be given to **protect**:

- bony prominences and joints (elbows, anterior superior iliac spines, facial/forehead area, knees and ankles/feet)

**Figure 3. Position on the Jackson table**

Observe the abdomen hanging free of pressure. The arms rest without axillary or elbow pressure and at a 90-degree angle in the shoulders and elbows. Elbows are padded and the head is in neutral position with eyes, mouths and nose in the hole of the foam holder with no pressure. The warming blower is in place over the lower limbs.

- blood vessels (carotid/jugular, femoral, axillary artery)
- nerves (ulnar, femoral, femorocutaneous, sciatic, peroneal, brachial plexus)

A 90° angle between the trunk and arms and between arms and forearms is recommended in the prone position. The abdomen must hang free [58] to decrease pressure on the inferior vena cava and subsequently reduce epidural vein pressure and bleeding (Fig. 3). The external genitals should be unloaded of any pressure or traction. In the prone position the eyes and nose should remain free of pressure. A small risk of corneal abrasion exists if the patient wakes up too actively in a WUT and the cornea remains uncovered afterwards in the face-down position. The prone position might represent an advantage from a respiratory point of view in patients properly positioned with a free-hanging abdomen due to functional improvement in residual capacity and oxygenation [59].

The abdomen must hang free with the patient in the prone position

Sequential anteroposterior spinal access presents a challenge to keep the monitoring and lines in place when flipping from one position to the other. Coordination and communication are required since this is a combined effort of many people in the OR. Jackson tables provide some advantages; however, precautions must be taken to minimize compression and traction of lines and anatomic structures. Cervical spine procedures call for a thorough final check of lines and tubes before prepping and draping. The endotracheal tube, nasogastric tube and temperature probe have to be secured.

**Skin Preparation.** Current evidence based preoperative recommendations do not endorse shaving the skin. If hair requires removal, it should be done by clipping with an electrical device not by shaving (in fact shaving might lead to higher

operative site infection rates than no hair removal or clipping) and the best timing is immediately before bringing the patient into the theater (not in the OR). The patient's skin should be physically scrubbed and cleaned before the application of antiseptic [2, 35, 40].

### Ischemic Optic Neuropathy

Perioperative increased intraocular pressure may lead to ischemic optic neuropathy

Increases in intraocular pressure with ischemic optic neuropathy have been linked to blindness after the patient has been in the face-down position in spine surgery [72]. Ocular perfusion pressure (OPP) relates directly to mean arterial pressure (MAP) and inversely to intraocular pressure (IOP), venous pressure in the eye and central venous pressure. In patients free of ocular pathology undergoing spine surgery in the prone position, Cheng et al. [11] found a change in the IOP from 19 ± 1 mm Hg preinduction/supine, to 13 ± 1 mm Hg 10 min postinduction/supine, to 27 ± 2 mm Hg prone/before surgery, to 40 ± 2 mm Hg prone/end of surgery, to 31 ± 2 mm Hg after returning the patient to the face-up position. They also described a moderate correlation ($r^2 = 0.6$) between the time spent in the prone position and the elevation of the IOP. To minimize the chances of visual troubles, a neutral-head or slight head-up position is recommended along with equilibrated fluid balance and a MAP of not below 60 mm Hg (eye perfusion pressure = MAP – [CVP + IOP]). The most common cause of amaurosis after spine surgery is anterior or posterior ischemic optic neuropathy (ION). Less common causes are central retinal artery or vein occlusion and occipital lobe infarct. Risk factors for ION are diabetes mellitus, hypertension, head-down position, smoking, and the combination of intraoperative anemia and hypotension [62]. We favor the use of the Mayfield head clamp for posterior cervical spine procedures because pressure on eyes, nose, and chin can be avoided. Post spine surgery blindness is an important topic that led The American Society of Anesthesiology to evaluate this theme through the ASA Postoperative Visual Loss Registry. Preliminary results have been published. Established in July 1999, the registry collects information anonymously (http:depts.washington.edu/asaccp) to identify risk factors to prevent this complication in the future [41, 43].

## Maintenance of Anesthesia

Maintenance of anesthesia is intended to provide good surgical (a dry field, good neuromonitoring, adequate muscle relaxation when needed) and anesthetic conditions (amnesia, nociceptive suppression, temperature preservation, hemodynamic and organ function stability). These goals can be achieved with total intravenous anesthesia (TIVA) or a gas/opioid approach. TIVA with target controlled infusions (TCIs) has come into fashion in many places of the world except in North America, because of its minimal interference with intraoperative neuromonitoring, smooth and fast anesthesia and quick control of the level of anesthetic depth. However, a low dose (0.3 – 0.5 minimum alveolar concentration or MAC-awake) of desflurane or sevoflurane with remifentanil [4] can actually be as good as or better than TIVA for neuromonitoring without the effect of propofol on platelet function. Blood preservation is a primary goal in major spine surgery. Propofol is known to decrease platelet function in studies describing the inhibitory effect of propofol on human platelet aggregation [12, 49]. Because patients often use prophylactic doses of aspirin or **nonsteroidal anti-inflammatory drugs** (NSAIDs) for pain control preoperatively, the use of continuous infusions of propofol is a theoretical risk for more bleeding. If a WUT is required, patients on low-dose desflurane or sevoflurane can be weaned faster and tend to respond earlier to commands from the anesthetist than those on propofol. Remifentanil is an

Blood preservation is important

Preoperative NSAID intake substantially increases bleeding and should be stopped beforehand

ultrashort acting and potent opiate that is completely metabolized and eliminated from the circulation in 3–6 min by plasma esterases. It makes a perfect match with the low-dose gases technique. In continuous infusion, it not only provides excellent analgesia, but it also allows for quick changes in the depth of anesthesia for WUT and it is a versatile tool for induction of controlled hypotension. It has been our experience that for thoracolumbar and lumbar spine surgery the use of intrathecal single shot morphine (0.3–0.6 mg preservative-free) before the induction of anesthesia greatly contributes to intraoperative and early postoperative stability and smooth WUT. Using this approach for the last 5 years we have had no infections attributed to the technique and both surgeons and patients appreciate it in equal measure. The same result is achieved with high thoracic epidural analgesia (catheter at C6–T5) for thoracolumbar procedures where a thoracotomy and chest drain are required. Any choice of maintenance drugs must aim to give a stable depth or level of anesthesia. Neuromuscular relaxant drugs should be used to facilitate airway control and then only as necessary according to the surgical conditions.

Muscle relaxants do not interfere with SSEPs

Muscle relaxants are generally not recommended when MEPs are being monitored; however, if surgical conditions mandate some muscle relaxation while monitoring MEPs, a low-dose continuous infusion of intermediate-acting muscle relaxants (rocuronium, cisatracurium, etc.) titrated to keep 3 out of 4 twitches (3/4 TOF) from the nerve stimulator can be used without impairing the MEP monitoring [38]. After the intubation dose of the muscle relaxant wears off, MEPs should begin to get a baseline recording (unless baselines for SSEPs and MEPs were obtained before muscle relaxation was induced). Then, the titration of the muscle relaxant infusion should proceed. A theoretical advantage of having some degree of muscle relaxation in major posterior procedures is better abdominal decompression as opposed to the abdominal tightness of an unrelaxed patient.

## Intraoperative Monitoring Techniques

### Advanced Monitoring of Vital Functions

Advanced monitoring of vital cardiopulmonary functions is suggested only in patients with systemic pathology or those scheduled to have major spine procedures. A central venous catheter is often inserted to measure central venous pressure (CVP), administer volume and have separate lines for drugs. In anterior lumbar spine surgery, monitoring hemoglobin saturation and plethysmographic curves from the ipsilateral toes to the surgical access to the spine are recommended (Fig. 4). This simple measure can provide early warning of vascular compression with retractors [33].

#### Cardiovascular System

Consider cardiac compromise in patients with Duchenne's muscular dystrophy

Cardiac compromise may be a direct result of the underlying pathology, for example in patients with Duchenne's muscular dystrophy or from unrelated cardiovascular disease such as hypertension or coronary artery disease. Cardiac dysfunction may also result from severe scoliosis or kyphosis, which causes distortion of the mediastinum, and cor pulmonale secondary to chronic hypoxemia and pulmonary hypertension. A direct arterial blood pressure line will be required in the case of major surgery, patients with preoperative cardiopulmonary pathologies or other anesthetic considerations (Table 2).

An arterial catheter is usually inserted in the radial or femoral arteries for this purpose.

**Figure 4. Plethysmography of the toe**

Simultaneous monitoring of the Hbsat and plethysmography in the toe and finger to detect arterial compression in the anterior lumbar approach.

**Table 2.** Indications for direct arterial pressure monitoring

| Preoperative conditions | Surgical indications |
|---|---|
| • coronary artery disease<br>• other cardiac conditions limiting heart function<br>• uncontrolled hypertension<br>• severe peripheral vascular disease<br>• advanced chronic obstructive pulmonary disease | • long operations (requiring blood sampling)<br>• expected major blood loss<br>• controlled hypotension to be used<br>• postoperative mechanical ventilation |

Prone patient position reduces cardiac function

With the patient in the prone position, the CVP may be a misleading indicator of right and left ventricular end diastolic volume [71]. In a study in pediatric patients scheduled for scoliosis surgery, the CVP rose from 9 to 18 mmHg on turning patients from the supine to the prone position. The increase seems to correlate with the pulmonary artery pressure (PAP). The left ventricular end diastolic diameter measured by transesophageal echocardiography (TEE) fell from 37 to 33 mm, indicating a transient and positional diastolic ventricular dysfunction. Pulmonary artery catheters are controversial because they do not decrease perioperative mortality and can cause significant morbidity. In healthy adults [73], the face-down position reduces the cardiac index (15–25%) and increases systemic vascular resistance possibly due to a decrease in venous return and ventricular compliance. These changes are more pronounced with propofol-based anesthesia than with gas. The main take-home message from this study is that greater changes should be expected in individuals with established preoperative cardiorespiratory pathology. Near infrared spectroscopy, a novel technology with potential application in spine surgery patients undergoing controlled hypotensive anesthesia (CHA), is enjoying a period of intense interest and research [29]. This is a noninvasive device for following brain Hb-oxygen mixed saturation in the territories supplied by the anterior and middle cerebral arteries. With

CHA a small risk of brain hypoperfusion in the presence of unrecognized carotid stenosis exists. This method has been extensively used in cardiac anesthesia to reduce postoperative strokes and provides a transcranial reading of brain tissue $O_2$sat that is made up of 75 % venous blood and 25 % arterial blood, allowing the anesthesiologist to adjust the brain blood flow and oxygenation to a safe level.

### Maintenance Fluids

The type and volume of fluid maintenance will vary depending upon the magnitude of blood loss, the preoperative intravascular filling status, the systemic preoperative condition of the individual and the length of the procedure. Patients scheduled for discectomy or simple hardware removal with minimal blood loss can receive "normal" saline or balanced solutions (lactated Ringer's, Hartmann's solution, etc.). Those that will be fast-tracked in day-surgery programs should have (under normal conditions) no bladder catheter and crystalloid volumes below 1 000 – 1 500 ml perioperatively. For major operations, fluid therapy should be guided by the CVP and blood loss, and the latter replaced with the appropriate solution/blood product. **Balanced crystalloid solutions** are recommended to avoid hyperchloremic acidosis induced by the so-called "normal" saline due to the high content of chloride in it [8]. Preoperative fasting is usually replaced in the first hour of surgery with 10 ml/kg of Ringer's lactate solution. Recent publications [28] have raised concern about the potential harm of overloading patients with fluids; therefore fluid volume therapy must follow a rational indication to replace preoperative negative balance, intraoperative maintenance, intraoperative blood loss and postoperative requirements.

Fluid therapy should be guided by CVP

Bladder catheters are routinely inserted before procedures lasting for more than 3 h to preclude bladder distension and to monitor urine output. Large blood volume changes and the frequent use of vasoactive drugs make their use mandatory to observe urine output in these situations. Foley catheters are also recommended to be inserted in elderly male patients who suffer from prostate hyperplasia and patients with urinary incontinence.

### Body Temperature

Mild perioperative hypothermia (reductions of core body temperature of 1 – 2 °C) is associated with [64]:

- increased postoperative cardiac complications
- impaired hemostasis
- impaired neutrophil function
- wound area hypoxia
- increased postoperative protein wasting
- altered pharmacodynamics of muscle relaxants
- delayed discharge from recovery room
- increased infectious complications [24]

A temperature probe should be placed, particularly in juvenile and infantile patients undergoing scoliosis surgery as well as in patients expecting to have large blood volume changes. Body temperature decreases very quickly in uncovered and anesthetized children and elderly patients; the main mechanisms are redistribution of heat from the core compartment to the periphery along with decreased heat production. Routine **use of air-warming blankets** and intravenous blood/liquid warming systems is recommended. Unless they are warmed, each unit of blood or 1 000 ml of crystalloid solution at room temperature will reduce body temperature by 0.25 °C. Patients that are only partially paralyzed

produce more heat compared with those fully paralyzed. Temperature monitoring must be used when neurophysiologic monitoring is planned since a normal temperature is a requirement for successful WUT and neurophysiologic recording. Although malignant hyperthermia nowadays is a very rare condition, its incidence is increased in patients with scoliosis because of their association with neuromuscular pathology.

## Monitoring Depth of Anesthesia (Consciousness)

Since the introduction of anesthesia almost 150 years ago, the depth of anesthesia has been monitored through surrogate variables (heart rate, arterial pressure, eye behavior, etc.). Today, the level of consciousness at induction, steady-state and wake-up phase can be monitored directly. The anesthesiologist uses these tools in spine surgery to keep patients at an appropriate level of anesthesia, to prevent recall of intraoperative events and to facilitate WUT performance (see below). **Bispectral Index** (BIS) and other techniques (auditory evoked potentials, entropy, etc.) have been evaluated and validated to correlate with consciousness during anesthesia with propofol, isoflurane or sevoflurane [7]. The BIS is a processed presentation of the EEG as a numerical rating from 100 (fully awake) to 0 (isoelectric EEG, total suppression of brain activity). Numbers between 45 and 60 are desirable as indicators of an appropriate consciousness level for surgery. The interaction of gases and propofol on the pharmacodynamic effects of opioids and the BIS has been studied recently [52]. Bear in mind that the other components of anesthesia (autonomic response, muscular relaxation, nociception, etc.) are monitored with other instruments.

Monitoring the level of consciousness during the anesthesia is necessary

**Neuromuscular monitoring** is performed in order to evaluate muscular relaxation during the intubation phase as well as during the surgical period and prior to the WUT and extubation. The **train-of-four** (TOF) is a simple way for the anesthesiologist to assess neuromuscular relaxation in anesthetized patients. It consists of a barrage of four electrical impulses delivered transcutaneously over the ulnar nerve at 2 Hz to activate the adductor pollicis. Three responses in the TOF are normally observed when there are over 75 % of the neuromuscular receptors free of a muscle relaxant effect. Patients monitored for MEP and/or nerve root integrity must have at least 3/4 twitches in the TOF.

Neuromuscular monitoring assesses the level of muscular relaxation

## Intraoperative Blood Preserving Techniques

Use blood preserving techniques

Blood product transfusions are frequently required in major spinal surgery. Transfusion thresholds for red blood cells commonly used are a hemoglobin concentration of 7 – 9 g %, compensatory tachycardia and an increasing lactate blood level. Patients with cardiopulmonary diseases and patients actively bleeding are considered for transfusion in the upper threshold margin. Complications of transfusions include transfusion transmitted infections (1 : 1 900 000 transfused units for HIV, 1 : 1 600 000 for hepatitis C, 1 : 220 000 for hepatitis B), bacterial contamination (1 : 1 000 or 2 000 for platelet concentrates), immunosuppression, transfusion-related acute lung injury, transfusion reactions (cutaneous, cardiovascular, respiratory) and graft-versus-host reaction. The **Cumulative Serious Hazards of Transfusions (SHOT)** survey in the United Kingdom over 6 years describes 35 reports of transfusion transmitted infections of which 21 were bacterial with 6 fatalities. Of these, 17/21 were due to platelets and also 5/6 deaths were related to platelets. The SHOT report will not pick up viral complications as they are often more chronic and may develop outside of the considered “window” for reporting [5].

Nosocomial infection rates increase fivefold in patients receiving allogenic transfusions with a dose-response pattern; the more units received the higher the odds of infection [16]. Potential problems with fresh frozen plasma transfusions are well described in pediatric surgery, including hypotension and cardiac arrest linked to sudden hypocalcemia [63, 77].

Transfusions increase the risk of postoperative infections

Good spine surgeons complete the surgical procedures in less time, are careful with hemostasis, and pay attention to optimal patient positioning while looking for better outcomes. In posterior surgical approaches there is more bleeding because of the bigger incisions, more work on the laminae and facet joints, greater chances of epidural vein damage and bleeding and bone graft harvesting [15]. Neuromuscular scoliosis patients have greater blood loss during spinal fusion surgery than idiopathic scoliosis patients. Prolongation of the prothrombin time and decrease in Factor VII activity suggest activation of the extrinsic coagulation pathway. Depletion of clotting factors during scoliosis surgery occurs to a greater extent in patients with underlying neuromuscular disease [32] (see Table 3).

Neuromuscular scoliosis surgery is prone to increase blood loss

**Table 3.** Factors associated with a higher risk of homologous blood transfusion

- low preoperative hemoglobin
- spine surgery in cancer patients
- multilevel posterior fusion
- decreased amount of autologous blood units available
- no use of Jackson table
- neuromuscular scoliosis surgery

## Controlled Hypotensive Anesthesia

Spinal cord blood flow (SCBF) autoregulation has been studied in humans [27]. SCBF autoregulation is similar to the brain's with a stable plateau between 50 and 100 mm Hg mean arterial pressure (MAP). It changes in lineal fashion with $CO_2$ between 15 and 90 mm Hg and remains unchanged with $PaO_2$ above 50 mm Hg. A reference MAP of 60–65 mm Hg in spine surgery is supported in the literature [15]. It is important to preserve the end-tidal $CO_2$ in the normal/high range to improve brain and spinal cord perfusion while under controlled hypotensive anesthesia (CHA) conditions. Inducing CHA in patients in the prone position is facilitated by the sequestration of volume in the lower limbs (particularly using an Andrew's table) and the effect of anesthetics on hemodynamics. Fluids must be given to keep a normal cardiac output/organ perfusion while on low MAP since the blood container (vascular system) has been expanded, and in the prone position the heart and pulmonary circulation are affected. The most frequently used **agents to produce CHA** are:

Controlled hypotensive anesthesia is frequently used in spinal surgery

- remifentanil
- sodium nitroprusside
- labetalol and nitroglycerin
- calcium channel antagonist
- fenoldopam
- propofol (it might interfere with SSEPs in the high range of doses required to induce CH)
- inhaled anesthetics (sevoflurane or desflurane, same comment as propofol)

CHA reduces blood losses by 55 % and transfusion requirements by 53 %, while operating time has been reported to be shorter [74] in scoliosis surgery. It has been applied in a variety of spine procedures including idiopathic scoliosis, degenerative scoliosis, instrumentation for Duchenne's patients and others.

CHA reduces blood loss, transfusion requirement and operative time

Although limited clinical experience is available so far, prostaglandin $E_1$ ($PGE_1$) seems to be an interesting alternative to inducing CHA. An infusion of

$PGE_1$ is capable of reducing MAP smoothly, maintaining the autoregulation of the spinal cord blood flow [79].

In spinal cord injury and compression, CHA can compromise remaining spinal cord function

Caution should be exercised in patients with spinal cord trauma or tumors compressing the spinal cord where the normal autoregulation might be impaired and the perfusion compromised in some areas.

Secondary injury prevention is paramount to avoid further damage to the spinal cord function; therefore a normal or higher perfusion pressure should be preserved [85] until the surgical decompression is achieved.

## Intrathecal Opiates

Two groups incidentally observed a decrease in intraoperative bleeding in spine surgery with the use of preoperatively injected intrathecal opiates. This effect was not observed when the drug was injected at the end of the procedure. Goordarzi et al. [23] noticed in ten adolescents receiving morphine 20 µg/kg intrathecally with 50 µg of sufentanyl that the combination facilitated intraoperative CHA to a MAP of 55 mm Hg. Gall [19] observed in 30 patients 9 – 19 years old undergoing spinal fusion a significant trend towards lower bleeding volumes when morphine 5 µg/kg intrathecally was injected before starting the operation. This study does not provide information about the impact of that trend on the transfusion rates.

## Blood Predeposit and Erythropoietin Injection

For surgeries with expected blood losses of over 1 – 1.5 l, a blood predeposit of 1 or 2 units is recommended when feasible in adolescents and adult patients [63]. A **predeposit hemoglobin** of between 11 and 14.5 g % is considered to be the optimal range. Over 90 % of patients coming for spinal fusions that predeposit their own blood avoid receiving allogeneic blood [53]. Iron supplementation with erythropoietin in patients with production problems should be prescribed. A prospective randomized study of epoetin alfa vs. placebo in patients scheduled for complex spine deformity surgery showed that patients in the treatment group were more likely to complete predonation, decrease homologous transfusions and have shorter hospital stays [66]. Colomina suggested that using recombinant erythropoietin (rEPO) in spine surgery patients with expected blood loss of around 30 % of their blood volume might substitute blood predeposit. They also mentioned that patients expecting around 50 % blood volume loss can avoid allogeneic blood transfusions by predeposit and bone marrow stimulation with rEPO [10]. Recommended dose is 600 U/kg/week subcutaneously for 4 weeks (usually one vial of 40 000 U/week), and 200 – 300 mg/day of iron should be given, along with folic acid and vitamin $B_{12}$ over the entire period of rEPO supplementation. Once the Hb level reaches 15 g % the rEPO should be suspended.

Recombinant erythropoietin may substitute blood predeposit

## Cell Salvage

Intraoperative cell salvage consists of collecting the blood from the surgical field to a machine that separates red blood cells from detritus, washing and concentrating them to be reinfused into the patient. Its use is indicated when blood losses over 15 – 20 ml/kg are expected. **Cell salvage is contraindicated** in:

- infected patients
- cancer surgery

In a provocative approach, some authors have reinfused collected blood in a large number of cancer patients after irradiation of the bag to kill any malignant cells which are potentially present [25]. More research is needed before recommend-

ing this approach. Blood collected in the drains within the first 2–4 postoperative hours can also be processed and reinfused with the cell saver system.

## Pharmacological Measures

Tranexamic acid or aprotinin [81] used with the induction of anesthesia has been reported both in adults and children to reduce blood losses in spinal procedures. Because of its price (1 g tranexamic acid costs C$19.35 vs. C$210 per allogenic blood unit vs. C$338 per autologous blood unit vs. C$344.40 per vial of 500 000 U of aprotinin), good tolerance and effectiveness, we and others [54, 65] prefer tranexamic acid in a protocol of 15–50 mg/kg in a bolus with the induction of anesthesia plus an infusion of 1 g/h or boluses of 10–25 mg/kg every 3 h intraoperatively and then q8 h for the first 24 h postoperatively. An increase in coagulability, changes in kaolin/Celite times or severe allergic reactions associated with the use of aprotinin have not been reported with tranexamic acid [26]. Recently, the use of aprotinin was associated with a doubling of the risk of renal failure, a 55% increased risk of myocardial infarction and a 181% increase in the risk of stroke in cardiac surgery when compared to tranexamic acid [45]. Desmopressin has not proven useful in decreasing blood losses [76] in idiopathic scoliosis surgery.

We do not use hemodilution since there is no demonstrated advantage of adding it to patients having CHA and antifibrinolytics. More importantly, ION seems to be much more likely to occur when combining anemia (or hemodilution) and low CHA.

Anemia/hemodilution and low CHA increase the risk of ION

## Blood Transfusion and Coagulation Factor Substitution

The question of when to start transfusing blood products in spine surgery boils down to what are the thresholds for the red cells (RBCs), platelets, plasma and factors. Blood is separated in blood banks into its components to optimize the use of resources by allowing blood subproducts to be transfused in different patients. Two different approaches to blood component replacement have been recommended. The first is to transfuse fresh frozen plasma (FFP) and platelets prophylactically after a certain number of units of RBCs have been transfused. However, there is no agreement on the optimal ratios; these vary widely, ranging from 1:10 to 2:3 for FFP:RBCs and from 6:10 to 12:10 for platelets:RBCs. The second approach is to transfuse FFP, platelets or cryoprecipitate only when there is clinical or laboratory evidence of coagulopathy; for instance, when there is microvascular bleeding, a prothrombin time (PT) or a partial thromboplastin time (PTT) > 1.5 times the normal value, thrombocytopenia with a platelet count < 50 000–100 000/l or a fibrinogen concentration < 100 mg%.

The following are recommendations from international publications summarized by Leal-Noval [42] and the American Society of Anesthesiologist Task Force on Perioperative Blood Transfusions 2005 (www.asahq.org).

### RBC Concentrates Transfusion Criteria

- Hb < 8 g%
- Hb between 8 and 10 g% in normovolemic patients, but with clinical signs of myocardial, cerebral, or respiratory dysfunction; and
- intraoperative hemorrhage, i.e., bleeding of 10 ml/kg in the first hour or 5 ml/kg × h in the first 3 h (averaged)

**Note**: 10 ml/kg of RBC concentrate will increase the Hb by 1–2 g% or 3–6 points of hematocrit

### FFP Transfusion Criteria

Patients with active bleeding and:

Each unit of FFP contains 2–4 mg of fibrinogen/ml; therefore each FFP unit delivers the equivalent of 2 units of cryoprecipitate

- PT or PTT 1.5 times that of control subjects; International Normalized Ratio (INR) > 2.0
- massive transfusion of RBC concentrates > 30 ml/kg of packed red cells
- previous treatment with coumadin derivatives and unscheduled surgery (to give FFP 5–8 ml/kg)
- correction of factor deficiencies when specific factors are unavailable (to give FFP 10–15 ml/kg)
- heparin resistance (antithrombin III deficit)

### Platelet Transfusion Criteria

Patients with severe hemorrhaging and:

- diffuse bleeding suggestive of platelet dysfunction
- platelet count < 50 000–100 000/l
- massive transfusion of RBC concentrates
- normal platelet count and platelet dysfunction (antiplatelet agents, thrombasthenia, uremia, etc.)

### Cryoprecipitate and Factor Transfusion Criteria

- patients with active bleeding and fibrinogen < 80 mg%
- bleeding patients with von Willebrand's disease in absence of specific concentrates

**Note**: Each unit of cryoprecipitate contains 150–250 mg of fibrinogen. The starting dose is 1 unit for 10 kg body weight to increase fibrinogen level by 50 mg% (the hemostatic level is around 100 mg%). Cryoprecipitate does not contain Factor V. Therefore, it should not be the sole replacement therapy for disseminated intravascular coagulopathy (DIC), which is almost always associated with a variety of factor deficiencies and thrombocytopenia. Intermediate purity **Factor VIII** concentrates are preferred for von **Willebrand's disease** and recombinant or highly purified Factor VIII concentrate for **hemophilia A** because of its greater efficacy and safety. The intermediate purity concentrate contains significant therapeutic quantities of the von Willebrand's component of Factor VIII, whereas the high purity preparations contain principally the hemophilia A component of Factor VIII.

### Transfusion Criteria for rFVIIa

rFVIIa is approved in many countries for patients with hemophilia and inhibitors (antibodies) to coagulation factors VIII or IX. High circulating concentrations of FVIIa, achieved by exogenous administration, initiate hemostasis by combining with tissue factor at the site of injury, producing thrombin, activating platelets and coagulation factors II, IX and X, thus providing for the full thrombin burst that is essential for hemostasis. This "bypass" therapy has led some clinicians to use rFVIIa "off-label" for disorders of hemostasis other than hemophilia. The Israeli Multidisciplinary rFVIIa Task Force published their guidelines for its use in uncontrolled bleeding [47], which recommended that optimal conditions (fibrinogen concentration > 50 mg%, platelet count > 50 000/l, pH > 7.2) should be achieved before the administration of rFVIIa. There are no clear recommended doses yet for rFVIIa. A wide range of between 50 and 200 µg/kg has been

advocated. Because of its clearance (35 ml/kg/h), it is suggested to repeat the dose every 2 h in case of persistent hemorrhage [82].

**Massive transfusion** can be defined as the acute replacement of more than one blood volume within 6 h. In previously healthy adults, coagulation defects develop primarily from dilution of protein coagulation factors and platelets when crystalloid, colloid and RBCs are used to replace lost volume. **Coagulopathy** associated with massive transfusion is clinically characterized by the presence of microvascular bleeding or oozing from the mucosae, wound and puncture sites. The development of acidosis, DIC, hypothermia and, rarely, a hemolytic transfusion reaction may accompany massive transfusion and complicate the ability to diagnose the coagulopathy. While thrombocytopenia may develop in massively transfused patients, administration of platelets should be reserved for the patient exhibiting microvascular bleeding and a platelet count of less than 50 000/l. In the massively transfused patient, clinical bleeding associated with coagulation factor deficiencies is unlikely until factor activity levels fall below 20 % of normal. This usually does not occur until greater than one blood volume has been replaced. FFP may be administered for correction of microvascular bleeding in patients transfused with more than one blood volume. PT and PTT along with platelet count and fibrinogen level should guide the use of component therapy. Whole blood clotting analysis, as seen with thromboelastography, provides a dynamic picture of the entire clotting process. Some potential metabolic problems resulting from blood transfusion are hyperkalemia, hypocalcemia, citrate toxicity, hypomagnesemia, acidosis and impaired oxygen-carrying capacity of hemoglobin. The electrocardiogram should be monitored in all patients for signs of electrolyte abnormality during rapid infusions. **Hyperkalemia** exacerbates the cardiovascular effects of hypocalcemia. Administration of calcium rapidly antagonizes **hyperkalemia** by promoting transfer of potassium into the cells.

Massive transfusions may result in acidosis, DIC, hypothermia and hemolytic transfusion reactions

## Intraoperative Spinal Cord Monitoring

Patients undergoing corrective surgery for deformity are at a higher risk of spinal cord injury. Similarly, patients who have sustained an incomplete traumatic spinal cord injury are at risk of further damage. Neurological deterioration can occur because of ischemia of the neural structures secondary to mechanical compression and/or vascular stretching. Monitoring must be performed by an experienced team and the surgeon must be interested in acting on the findings [18]. Teamwork and communication between the electrophysiology technician, anesthesiologist and surgeon are necessary to make spinal cord monitoring useful for the patient. Important facts regarding anesthesia stability and depth, hemodynamics, blood volume, blood flow autoregulation of the spinal cord and temperature must be considered. MAP below 60 mm Hg or hypovolemia can result in significant changes in SSEPs [55, 57]. During surgery, a MAP of 60–65 mm Hg is usually maintained to reduce blood loss. Drops in temperature can affect SSEP waveforms [46]. If the limbs, brain or spinal cord become cooler during surgery, SSEP latencies will increase without an actual injury to the neural pathway. The anesthesia goals to facilitate neuromonitoring are highlighted in Table 4. An elec-

Spinal cord monitoring requires clinical practice for its effective use

**Table 4.** Goals of anesthesia management to facilitate neuromonitoring

- tight and stable hypotensive blood pressure control
- normothermia
- stable depth of anesthesia compatible with neuromonitoring
- normal end tidal $CO_2$
- normovolemia
- Hb level above 7 g %

tric line interference of 60 Hz coming from the operating room table or other electric equipment may severely affect the SSEP recordings [56].

In the presence of intraoperative spinal cord monitoring (IOM), **neurological deficits after spine surgery** relate to [56]:

- type of procedure
- the surgeon's experience of spine surgery
- the surgeon's experience using SSEP
- the technician's experience (experience with less than 100 cases doubled the deficits compared with > 300 cases)
- Low (or narrower) cut filtering (30 Hz to 1 kHz) is better than 1 Hz to 5 kHz).

## Anesthetic Effects on SSEPs

Halogenated anesthetics produce a dose-related **reduction in amplitude** and an **increase in the latency** of responses to SSEPs [69]. Nitrous oxide adds more intense changes in cortical SSEP recording than those of halogenated drugs and in fact they are synergic with isoflurane when used together. Sevoflurane, desflurane or mixtures of $N_2O$ opiates may be used during SSEP monitoring as long as the concentration of the **inhaled agents is kept low (below 0.7 MAC) and stable** to avoid artificial effects due to changes in depth of anesthesia. Subcortical recordings (from C2) are relatively resistant to the depressing effects seen when cortical level recordings are made. Cortical evoked potential (CEP) changes related to deepening anesthesia may be indistinguishable from spinal cord injury. For this reason, subcortically generated SSEP recordings should be obtained to corroborate CEP changes, while peripheral nerve responses should be recorded to ensure that the adequacy of stimulation has not changed to account for the CEP change. Intravenous opiates used with inhaled agents in clinical anesthesia produce little impact on the amplitude of EEG; however, they may increase the latency of SSEPs.

Intravenous opiates may increase the latency of SSEPs

This small effect of the systemic opiates on latency recordings seems to be μ-receptor dependent and occurs at a supraspinal level since spinal/epidurally administered morphine or fentanyl minimally affects SSEPs [67]. Ketamine is an NMDA antagonist, which has become more popular lately as part of a multimodal anesthetic approach. Ketamine is known to increase amplitude responses in cortical SSEPs as well as spinal and muscle recordings after spinal activation [39]. Nonetheless, ketamine could be a problem when a WUT is required. A similar observation about SSEPs has been made with etomidate [37]. Thiopental is a barbiturate and poses no problems for monitoring neurological parameters during spine surgery after the rapid redistribution of the single induction dose. Short-acting benzodiazepines are combined with opiates or ketamine as part of a balanced technique. Induction and maintenance of anesthesia with midazolam induces negligible changes to cortical SSEP recordings [66]. Combinations of midazolam-fentanyl and midazolam-ketamine along with $N_2O$ have been found equally appropriate in spine surgery and SSEP recording [39]. Propofol is dependable for both the induction and maintenance of anesthesia with a very predictable pharmacodynamic response when used with target controlled infusions (TCIs). Propofol slightly depresses the amplitude of SSEPs at the brain cortex level with negligible action at clinical doses on spinal cord physiology. Propofol is regarded as a very good alternative for anesthesia during functional monitoring in spine surgery [69]. Muscle relaxants do not affect SSEPs and in fact they might enhance the SSEP signal by decreasing electric noise by eliminating muscle artifacts. Epidural/intrathecal, but not i.v., local anesthetics increase SSEP latency and are contraindicated because of their direct effect in spinal cord conduction [36].

### Red Flags in SSEP Recordings

SSEP recordings can be affected in two dimensions: amplitude and/or latency. A 50 % decrease in amplitude and/or a 10 % or 2-ms increase in latency in a hemodynamically stable, normothermic patient are considered as indicators of spinal cord insult [56]. In this case, **counteractive measures** encompass surgical and anesthetic reactions (see Table 5). Changes in recordings that do not reverse to normal after corrective measures and are still present at the end of the procedure correlate with new postoperative nerve deficits [72].

**Table 5.** Course of action suggested for deteriorating neuromonitoring

| Surgical interventions | Anesthetic interventions |
|---|---|
| • reduction of correction<br>• removal of implant | • increase in blood pressure<br>• correction of anemia<br>• correction of hypovolemia<br>• normalization of temperature<br>• lighter anesthesia level<br>• IV steroids<br>• normalization of $CO_2$ |

## Anesthetic Effects on MEPs

MEPs are obtained by transcranial electrical (tcEMEP) or magnetic (tcMMEP) stimulation of the motor cortex and recordings are made in muscles or peripheral nerves. Stimulation can also be made at a high epidural level next to the spinal cord. In patients with spinal cord deficits, MEPs can be present when SSEPs are absent and vice versa. Repetitive transcranial stimulation (trains of three to five impulses as opposed to a single stimulus) can overcome some of the depressant actions of anesthetics by temporal summation of the descending input on the motoneurons. MEP changes during spine surgery correlate well with neurological outcome. MEPs are complementary to SSEPs in reducing spinal cord risk of damage in complex spinal surgery. tcMMEP seems to be more affected by anesthetics than tcEMEP [69]. MEPs may allow adequate recordings of patients who are otherwise "unmonitorable" by SSEPs. MEP signals should have an amplitude of at least 50 μV before they are considered to be "monitorable." Ketamine based anesthesia allows for appropriate MEP recording because of its minimal depressing actions. Barbiturates must be avoided if early recording of tcMMEPs is required because up to 45 min of deep depression has been reported [21]. Midazolam and thiopental share the same depressing effect on tcMMEPs, so these agents are not recommended when that kind of monitoring is to be used [31]. Complete motor blockade will prevent muscle response and recording of cranial or spinal cord induced MEPs. Partial neuromuscular blockade with continuous and stable infusions of muscle relaxants to keep a train-of-four of 3/4 has been successfully reported [38]. Constant evaluation with nerve stimulators or closed-loop systems might produce a level of relaxation compatible with optimal recording of MEPs and very good surgical conditions. These evoked potentials are large responses clear of signal averaging that can provide the surgeon with good feedback. MEPs may be contaminated by sudden patient movement and anesthetic agents.

MEP changes predict neurological outcome

### Red Flags in MEP Recordings

A rapid and permanent decrease in signal amplitude larger than 50 %, or a 100 V increase in the threshold of the MEP muscle response, is indicative of a neural compromise [50, 84] with potential neurological consequences.

## Nerve Root Monitoring

SSEPs and MEPs are less likely to alert the surgeon about single root potential damage than techniques monitoring that particular root. Electrical stimulation of screws placed in the pedicles can confirm correct placement or signal a breach in the bone cortex by lowering the current needed to activate a sustained neurotonic electromyogram (EMG) discharge from the muscles innervated by that root [13]. Some consider there is a malpositioned screw when a recording of compound muscle action potential is obtained of less than 10 mA and 200 µs pulse width stimulation. No response with intensities above 15 mA was found to be 98 % accurate for properly implanted screws [20]. The reported rate for false negatives and sensitivity is 8 % and 93 %, respectively [44, 83]. This technique also allows for continuous EMG recording, so that changes can be observed on decompressing the roots, cage positioning and rod placement. No neuromuscular relaxant drug (NMB) effects have to be observed (at least three out of four twitches in the train-of-four) over the period of surgical EMG monitoring.

## Wake-up Test

A WUT consists of stopping the anesthetics after surgical spine manipulation to assess the motor function of the spinal cord and nerve roots. Usually the spinal cord, brachial plexus roots, and L5 and S1 can be evaluated by asking the patient to move their hands and feet. The WUT is an outstanding procedure for ascertaining corticospinal and motoneuron integrity. In experienced hands a WUT is quick, reliable, safe and reproducible. It requires 5 – 15 min notice from the surgeon to conduct it. Many spine surgeons feel comfortable omitting a WUT when reliable data with SSEPs and MEPs are obtained and maintained. The WUT is currently performed when there is no SSEP/MEP data available or in circumstances where these methods are not reliable. The **limitations of the WUT** are:

Spinal cord monitoring has replaced WUTs in many centers

- intermittent rather than continuous monitoring
- not applicable in mentally handicapped patients
- not feasible in small children
- preexisting severe spinal cord damage (incomplete lesion)

Venous embolism, corneal damage, loss of vascular access, violent wake-up, accidental extubation or hardware dislodgement is unlikely when the test is conducted in skilled hands. The WUT technique requires training and practice to master and be used with confidence. A normal WUT with posterior column damage or “false negative” (with documented intraoperative SSEP deficit) has been reported by Ben-David [6]. This is not a true false negative because SSEPs and the classic WUT are aimed at different anatomic structures: dorsal column and anterior spinal cord blood supply. We have refined a WUT that allows us to test both sensory/proprioceptive and motor components in a reliable and quiet fashion.

## End of Anesthesia

Planning for postoperative pain control, elective postoperative ventilatory support and postoperative destination should be conducted before starting the surgery. However, emergency cases and unexpected intraoperative events might require fast intraoperative decision-making. Ideally patients should be quickly regaining the ability to follow commands to assess their neurological status, be comfortable with coughing to clear secretions and starting with physiotherapy. The provision for pain management is discussed in the next section. Elective and last minute decisions to keep the patient in the intensive care unit are shown in Table 6. Patients with major comorbidities before surgery and/or unexpected adverse intraoperative events account for most indications for the postoperative ICU. **Which patients should have postoperative ventilation?** Most spine surgery patients are extubated on the table at the end of the surgery. Consideration for postoperative mechanical ventilation should be given to patients undergoing neuromuscular scoliosis correction, with preoperative respiratory or cardiac dysfunction, having intraoperative hemodynamic and respiratory instability, with unexpected decreases in body temperature, with difficult airway access, or with slow recovery from anesthesia [60]. Although it is not our regular practice, some groups suggest elective ventilation for a few hours after C-spine surgery to make certain no airway compromise by hematoma is present after surgery and before extubation.

The need for postoperative mechanical ventilation must be considered prior to surgery

**Table 6.** Perioperative considerations regarding overnight ICU requirement

| Preoperative reasons | Intraoperative reasons | Postoperative reasons |
|---|---|---|
| • preoperative severe respiratory impairment<br>• mental disability<br>• congestive heart failure<br>• chronic obstructive pulmonary disease<br>• chronic renal failure<br>• muscular dystrophy<br>• patient coming from ICU | • cervical spine surgery: laryngeal nerve damage or hematoma<br>• hemodynamic instability<br>• continued correction of hypovolemia<br>• surgical complications<br>• coagulopathy<br>• anesthetic complications<br>• hypothermia | • respiratory failure<br>• hemodynamic instability<br>• special monitoring requirements |

## Postoperative Pain Management

Postoperative pain and gastrointestinal dysfunction (nausea, vomiting, ileus, constipation and anorexia) secondary to analgesics and other drugs are among the main factors delaying the recovery process in spinal surgery. **The goals of postoperative pain control therapies are to enhance recovery and decrease complications rather than just to decrease pain measured scores**. Challenges relate to preoperative pain and opioid tolerance, cognitive impairment, extremes of life and difficulties assessing the symptoms and the results of the treatments applied. A multimodal approach is recommended, involving acetaminophen, low-dose NSAIDs, systemic opioids, wound infiltration with local anesthetics and coadjuvants (i.e., low-dose ketamine, stool softeners and gabapentin). The requirements of preoperative opioids do not disappear right after the surgery. It might take weeks. Therefore, it is recommended to restart them as baseline analgesia as soon as the patient can receive them orally or to replace them temporarily intravenously.

**Multimodal Analgesia.** Acetaminophen is extremely well tolerated and can be used before beginning the surgery per rectum, per os or intravenously (as propa-

The postoperative use of NSAIDs remains a matter of debate

racetamol) in doses of 15 mg/kg every 4–6 h. Metamizol (Dypirone) is an excellent alternative to acetaminophen at the same dose regimen provided the patient is not allergic to it and has no bone marrow disease. The postoperative use of NSAIDs has been the subject of heated controversy in the literature because of data coming from animal studies and retrospective human chart reviews. There is not a single prospective randomized trial on spine surgery in humans demonstrating a higher incidence of malunion or a slower consolidation secondary to short use (3–5 days) of NSAIDs. On the contrary, the literature shows similar surgical outcomes with better pain control in patients who received ketorolac at less than 110 mg/day after spine procedures [22, 51, 61]. These analyses have actually emphasized that preoperative smoking increases the risk of malunion by 8–15 times. NSAIDs only become an issue when they are used in high doses in smokers. If the patient is going to have low molecular weight heparin postsurgery (uncommon in spine procedures), it seems safer to use a **COX-2** specific such as celecoxib (rule out cardiovascular contraindications). Wound infiltration at the beginning and the end of the operation greatly reduces the amount of anesthetics and opioids required in the first few hours after surgery, allowing patients to be scheduled to go home the same day (i.e., after disc surgery) and a smoother transition and discharge. **Patient controlled analgesia** (PCA), nurse or parent assisted PCA or regular subcutaneous opioids are the most commonly used analgesia technique after spine procedures. Side effects are often prominent including gastrointestinal, excessive sedation, respiratory depression and poor incidental pain relief.

The advantages of using epidural analgesia after scoliosis surgery (Fig. 5) have been reported by Blumenthal [9] and Tobias [78]. Both methods (PCA and epidural) provided efficient postoperative analgesia. However, the double epidural catheter technique provides better postoperative analgesia, earlier recovery of bowel function, fewer side effects, and higher patient satisfaction.

**Figure 5. Cervicothoracic epidural catheter**

Epidural catheter at the level of C7/T1 allows for excellent pain control in cases with posterior fusion and/or a transthoracic approach.

## Recapitulation

**Communication.** Anesthesiologists with special expertise in spine surgery play an important role in the perioperative team in charge of patients. The anesthesiologist will lay out a plan to manage anesthesia in each case, but this plan must be closely integrated into the surgical plan. Therefore, the anesthesiologist must be involved before surgery to permit a team plan for the case, no matter how simple it may seem.

**Goals in spinal surgery.** Critical aspects of the intraoperative anesthesia care are airway management, positioning on the operative table, techniques to minimize surgical bleeding, pain control and organ perfusion. Techniques to control bleeding must be balanced against ocular complications and cord function and perfusion. Techniques to secure the airway must be balanced against spinal cord injury. Techniques to achieve proper pain control postsurgery must be balanced against effective bone fusion and clean healing.

**Induction of anesthesia.** In this period, the critical issues are airway control and hemodynamic stability. Patients with an unstable cervical spine require careful fiberoptic tube placement, avoiding drops in blood pressure that might further jeopardize the cord condition. Patients coming for transthoracic surgical approaches might require lung deflation by using a bronchial blocker or other device to facilitate surgical exposure. There is no evidence to support the use of armored endotracheal tubes. Antibiotic prophylaxis before starting the operation is mandatory in most spine surgery cases to preclude colonization of implants.

**Maintenance of anesthesia.** In the maintenance period of major spine cases, controlled hypotension to MAP not below 60–65 mm Hg along with tranexamic acid is an efficacious means to control bleeding and allow for a drier surgical field. Intraoperative neuromonitoring requires stable temperature, anesthesia depth with low doses of gases or TIVA and good cord perfusion. Guidelines are provided for transfusions in the spine surgery scenario as well as a clear and simple description of the wake-up test for places without an SSEP machine. In simple cases of day surgery procedures, the goals are rapid recovery of anesthesia without nausea, vomiting and pain. Local anesthesia infiltration before the surgery and at the end facilitates an anesthetic approach with minimal opioids.

**End of anesthesia.** At the conclusion of the anesthesia and surgery, the issues are pain control and again airway management. Multimodal analgesia along with epidural catheters offers excellent results with low morbidity and high levels of patient (and surgeon) satisfaction. NSAIDs in low doses (ketorolac <90 mg/day or celecoxib <200 mg/day) and for less than 72 h postoperatively are a safe and effective part of the cocktail as long as the patient is a nonsmoker. The decision to keep the patient intubated in the first few hours after C-spine or major spine operations should rely on the clinical assessment by the team regarding the physiologic and anatomic conditions of the individual patient.

## Key Articles

**Lauer KK (2004) Visual loss after spine surgery. J Neurosurg Anesthesiol 16:77–79**
Brief review of the topic with excellent and concise information to understand why this complication occurs in spine surgery.

**Sessler D (2001) Complications and treatment of mild hypothermia. Anesthesiology 95:531–43**
The author analyzes the clinical implications of perioperative hypothermia. An important paper that presents very practical information about the deleterious effects of mild hypothermia on infectious, metabolic and hemostatic aspects usually unknown to many clinicians.

**Tobias JD (2004) Strategies for minimizing blood loss in orthopedic surgery. Semin Hematol 41(1):145–56**
Comprehensive review of the current techniques to preserve blood in spine surgery.

## Key Articles

**www.asahq.org/publicationsAndServices/transfusion.pdf**
This web site of the American Society of Anesthesiology presents very well documented guidelines about blood product therapy in the perioperative period. It is frequently updated with new information and is easy to read.

**Duffy G, Neal KR (1996) Differences in postoperative infection rates between patients receiving autologous and allogeneic blood transfusions: a meta-analysis of published randomized and nonrandomized studies. Transfus Med 6(4):325 – 28**
The authors reviewed seven trials comparing autologous vs. allogeneic transfusions; only two were prospective randomized trials with around 80 patients on each arm. This meta-analysis suggested at least a twofold increase in postoperative infections in patients having allogeneic transfusions of 1 – 4 units.

**Sethna NF, Zurakowski D, Brustowicz RM, Bacsik J, et al. (2005) Tranexamic acid reduces intraoperative blood loss in pediatric patients undergoing scoliosis surgery. Anesthesiology 102:727 – 32**
A recent and well done protocol that demonstrates a greater than 40 % reduction in bleeding during spine surgery by using tranexamic acid. There was a clear trend to lower transfusion rates in the tranexamic group; however, it did not reach statistical significance.

**Tobias JD (2004) A review of intrathecal and epidural analgesia after spinal surgery in children. Anesthes Analg 98(4):956 – 65**
A close look into the pediatric field of post spine surgery analgesia by an expert in pediatric orthopedic anesthesia. An interesting view of the use of regional anesthesia and spinal opioids.

## References


1. American Society of Anesthesia (2005) Guidelines on intraoperative monitoring. http://www.asahq.org/publicationsandservices/standards/02.pdf. Web site accessed Jan 05, 2005
2. Anonymous (2003) Best Practice 7(2):1 – 6
3. Apfelbaum RI, Kriskovich MD, Haller JR (2000) On the incidence, cause, and prevention of recurrent laryngeal nerve palsies during anterior cervical spine surgery. Spine 25(22): 2906 – 12
4. Banoub M, Tetzlaff JE, Schubert A (2003) Pharmacologic and physiologic influences affecting sensory evoked potentials: implications for perioperative monitoring. Anesthesiology 99(3):716 – 37
5. Beaumont AC (2003) Blood transfusion: Reducing use, increasing safety. CPD Anesthesia 5(1):7 – 12
6. Ben-David B, Taylor PD, Haller GS (1987) Posterior spinal fusion complicated by posterior column injury. A case report of a false-negative wake-up test. Spine 12(3):540 – 3
7. Blake DW, Hogg MN, Hackman CH, et al. (1998) Induction of anaesthesia with sevoflurane, preprogrammed propofol infusion or combined sevoflurane/propofol for laryngeal mask insertion: cardiovascular, movement and EEG bispectral index responses. Anaesthesia Intensive Care 26(4):360 – 5
8. Blanloeil Y, Roze B, Rigal JC, Baron JF (2002) Hyperchloremic acidosis during plasma volume replacement. Ann Francaises Anesth Reanim 21(3):211 – 20
9. Blumenthal S, Min K, Nadig M, Borgeat A (2005) Double epidural catheter with ropivacaine versus intravenous morphine: A comparison for postoperative analgesia after scoliosis correction surgery. Anesthesiology 102:175 – 80
10. Colomina MJ, Bagó J, Pellisé F, et al. (2004) Preoperative erythropoietin in spine surgery. Eur Spine J 13(1):S40–S49
11. Cheng MA, Todorov A, Tempelhoff R, et al. (2001) The effect of prone positioning on intraocular pressure in anesthetized patients. Anesthesiology 95:1351 – 5
12. De La Cruz JP, Carmona JA, Paez MV, et al. (1997) Propofol inhibits in vitro platelet aggregation in human whole blood. Anesth Analg 84:919 – 21
13. DiCindio S, Schwartz DM (2005) Anesthetic management for pediatric spinal fusion: Implications of advances in spinal cord monitoring. Anesthesiol Clin N Am 23:765 – 87
14. Dimick JB, Lipsett PA, Kostuik JP (2000) Spine update: Antimicrobial prophylaxis in spine surgery. Basic principles and recent advances. Spine 25(19):2544 – 48
15. Dubos J, Mercier C (1993) Problemes anesthesiques et reanimation postoperatoire pour la chirurgie des scoliosis. Agressologie 34(1):27 – 32

16. Duffy G, Neal KR (1996) Differences in postoperative infection rates between patients receiving autologous and allogeneic blood transfusions: a meta-analysis of published randomized and nonrandomized studies. Transfusion Med 6(4):325 – 28
17. Fang A, Hu SS, Endres N, Bradford DS (2005) Risk factors for infection after spinal surgery. Spine 30 (12):1460 – 65
18. Fisher RS, Raudzens P, Nunemacher M (1988) Efficacy of intraoperative neurophysiological monitoring. J Clin Neurophysiol 12:97 – 109
19. Gall O, Aubineau JV, et al. (2001) Analgesic effects of low-dose intrathecal morphine after spinal fusion in children. Anesthesiology 94:447 – 52
20. Glassman SD, Dimar JR, Puno RM, et al. (1995) A prospective analysis of intraoperative electromyographic monitoring of pedicle screw placement with computed tomographic scan confirmation. Spine 20(12):1375 – 9
21. Glassman SD, Johnson JR, Shield CB, et al. (1993) Correlation of motor-evoked potentials, somatosensory-evoked potentials, and the wake-up test in a case of kyphoscoliosis. Spine 18:1083 – 9
22. Glassman SD, Rose SM, John R et al. (1998) The effect of postoperative NSAIDs administration on spinal fusion. Spine 23(7):834 – 38
23. Goodarzi M, Shier NH, Grogan DP (1996) Effect of intrathecal opioids on somatosensory-evoked potentials during spinal fusion in children. Spine 21(13):1565 – 68
24. Guest JD, Vanni S, Silbert MSN (2004) Mild hypothermia, blood loss and complications in elective spine surgery. Spine J 4:130 – 37
25. Hansen E, Altmeppen J, Taeger K (1998) Practicability and safety of intra-operative autotransfusion with irradiated blood. Anaesthesia 53 Suppl 2:42 – 3
26. Henry DA (2001) Cochrane database of systematic reviews. (1):CD001886
27. Hickey R, et al. (1995) Functional organization and physiology of the spinal cord. In: Porter SS (ed) Anesthesia for spine surgery. McGraw-Hill, New York, pp 24 – 26
28. Holte K, Sharrock NE, Kehlet H (2002) Pathophysiology and clinical implications of perioperative fluid excess. Br J Anaesth 89(4):622 – 32
29. Iglesias I, Murkin JM, et al. (2003) Monitoring cerebral oxygen saturation significantly decreases postoperative length of stay: A prospective randomized blinded study. Heart Surgery Forum 6(4):204 – 5
30. John DA, Tobey RE, Homer LD, Rice CL (1976) Onset of succinylcholine-induced hyperkalemia following denervation. Anesthesiology 45:294 – 9
31. Kalkman CJ, Drummond JC, Ribberink AA, et al. (1992) Effects of propofol, etomidate, midazolam, and fentanyl on motor evoked responses to transcranial electrical or magnetic stimulation in humans. Anesthesiology 76(4):502 – 9
32. Kannan S, Meert KL, Mooney JF, Hillman-Wiseman C, Warrier I (2002) Bleeding and coagulation changes during spinal fusion surgery: A comparison of neuromuscular and idiopathic scoliosis patients. Pediatr Crit Care Med 3 (4):364 – 69
33. Khazim R, Boos N, Webb JK (1998) Progressive thrombotic occlusion of the left common iliac artery after anterior lumbar interbody fusion. Eur Spine J 7:239 – 41
34. King KP, Stolp BW, Borel CO (1999) Damage to an armored endotracheal tube introduced via the intubating laryngeal mask airway induced by biting. Anesth Analg 89:1324 – 5
35. Kjonniksen I, Andersen BM, et al. (2002) Preoperative hair removal. A systematic literature review. AORN J 75(5):928 – 40
36. Klasen J, Thiel A, Detsch O, et al. (1995) The effect of epidural and intravenous lidocaine on somatosensory evoked potentials after stimulation of the posterior tibialis nerve. Anesth Analg 81(2):332 – 37
37. Kochs E, Treede RD, Schulte am Esch JE (1986) Increase in somatosensory evoked potentials during anesthesia induction with etomidate. Anaesthetist 35(6):359 – 64
38. Lang EW, Beutler AS, Chesnut RM, et al. (1996) Myogenic motor-evoked potential monitoring using partial neuromuscular blockade in surgery of the spine. Spine 21(14): 1676 – 86
39. Langeron O, Lille F, Zerhouni O, et al. (1997) Comparison of the effect of ketamine-midazolam with those of fentanyl-midazolam on cortical somatosensory evoked potentials during major spine surgery. Br J Anaesth 78(6):701 – 6
40. Larson E (1988) Guideline for use of topical antimicrobial agents. Am J Infect Control 16:253 – 66
41. Lauer KK (2004) Visual loss after spine surgery. J Neurosurg Anesthesiol 16:77 – 79
42. Leal-Noval SR, Rincón-Ferrari MD, García-Curiel A, et al. (2001) Transfusion of blood components and postoperative infection in patients undergoing cardiac surgery. Chest 119: 1461 – 1468
43. Lee L, et al. (2000) Postoperative visual loss. ASA Annual Meeting 2000: A2092
44. Maguire J, Wallace S, Madiga R, et al. (1995) Evaluation of intrapedicular screw position using intraoperative evoked electromyography. Spine 20:1068 – 74
45. Mangano DT, Tudor JC, Dietzel C, et al. (2006) The risk associated with aprotinin in cardiac surgery. N Engl J Med 354(4):353 – 65

46. Markand ON, Warren C, Mallik GS, et al. (1990) Effects of hypothermia on short latency somatosensory evoked potentials in humans. Electroencephalogr Clin Neurophysiol 77(6): 416 – 24
47. Martinowitz U, Michaelson M (2005) Guidelines for the use of recombinant activated factor VII (rFVIIa) in uncontrolled bleeding: a report by the Israeli Multidisciplinary rFVIIa Task Force. J Thromb Haemost 3(4):640 – 8
48. McLeod AD, Calder I (2000) Spinal cord injury and direct laryngoscopy – the legend lives on. Br J Anaesth 84:705 – 9
49. Mendez D, De la Cruz JP, Arrebola MM, Guerrero A, Gonzalez-Correa JA, Garcia-Temboury E, Sanchez de la Cuesta F (2003) The effect of propofol on the interaction of platelets with leukocytes and erythrocytes in surgical patients. Anesth Analg 96(3):713 – 9
50. Morota N, Deletis V, Constantini S, et al. (1997) The role of motor evoked potentials during surgery for intramedullary spinal cord tumors. Neurosurgery 41:1327
51. Munro HM, Walton S, Malviya S, et al. (2002) Low-dose ketorolac improves analgesia and reduces morphine requirements following posterior spinal fusion in adolescents. Can J Anaesth 49(5):461 – 66
52. Muñoz HR, Cortínez LI, Altermatt FR, Dagnino JA (2002) Remifentanil requirements during sevoflurane administration to block somatic and cardiovascular responses to skin incision in children and adults. Anesthesiology 97:1142 – 5
53. Murray DJ, Forbes RB, Titone MB, et al. (1997) Transfusion management in pediatric and adolescent scoliosis surgery. Efficacy of autologous blood. Spine 22(23):2735 – 40
54. Neilipovitz DT (2004) Tranexamic acid for major spine surgery. Eur Spine J 13(Suppl 1): S62–S65
55. Noonan KJ, Walker T, Feinberg JR, et al. (2002) Factors related to false-versus tru-positive neuromonitoring changes in adolescent idiopathic scoliosis surgery. Spine 27(8): 825 – 30
56. Nuwer MR, Dawson EG, Carlson LG, et al. (1995) Somatosensory evoked potential spinal cord monitoring reduces neurologic deficits after scoliosis surgery: results of a large multicenter survey. Electroencephalogr Clin Neurophysiol 96(1):6 – 11
57. Owen JH (1999) The application of intraoperative monitoring during surgery for spinal deformity. Spine 24:2649 – 62
58. Park Ch K (2000) The effect of patient positioning on intraabdominal pressure and blood loss in spinal surgery. Anesth Analg 91(3):552 – 57
59. Pelosi P, Croci M, et al. (1995) The prone position during general anesthesia minimally affects respiratory mechanics while improving functional residual capacity and increasing oxygen tension. Anesth Analg 80:995 – 6
60. Raw DA, Beattie JK, Hunter JM (2003) Anesthesia for spinal surgery in adults. Br J Anaesth 91:886 – 904
61. Reuben SS, Ablertt D, Kaye R (2005) High dose NSAIDs compromise spine fusion. Can J Anesth 52(5):506 – 12
62. Roth S, Nunez R, Schreider BD (1997) Unexplained visual loss after lumbar spinal fusion. J Neurosurg Anesthesiol 9(4):346 – 8
63. Scottish Intercollegiate Guideline Network. Perioperative Blood Transfusion for elective surgery. A national clinical guideline www.sign.ac.uk Accessed November 2005
64. Sessler D (2001) Complications and treatment of mild hypothermia. Anesthesiology 95: 531 – 43
65. Sethna NF, Zurakowski D, Brustowicz RM, Bacsik J, et al. (2005) Tranexamic acid reduces intraoperative blood loss in pediatric patients undergoing scoliosis surgery. Anesthesiology 102:727 – 32
66. Shapiro GS, Boachie-Adjei O, Dhawlikar SH, et al. (2002) The use of epoietin alfa in complex spine deformity surgery. Spine 27(18):2067 – 71
67. Schubert A, Licina MG, Lineberry PJ, et al. (1991) The effect of intrathecal morphine on somatosensory evoked potentials in awake humans. Anesthesiology 75(3):401 – 5
68. Sloan TB, Fugina ML, Toleikis JR (1990) Effects of midazolam on median nerve somatosensory evoked potentials. Br J Anaesthesia 64(5):590 – 3
69. Sloan T (1998) Anesthetic effects on electrophysiologic recordings. J Clin Neurophysiol 15(3):217 – 26
70. Solares G, Herranz JL, Sanz MD (1986) Suxamethonium-induced cardiac arrest as an initial manifestation of Duchenne muscular dystrophy. Br J Anaesth 58:576 – 0
71. Soliman DE, Maslow AD, Bokesch PM, et al. (1998) Transesophageal echocardiography during scoliosis repair: comparison with CVP monitoring. Can J Anaesth 45:925 – 32
72. Stevens WR, Glazer P, Kelley SD, et al. (1997) Ophthalmic complications after spinal surgery. Spine 22:1319 – 24
73. Sudheer PS, Logan SW, et al. (2006) Haemodynamics effects of prone position: a comparison of propofol total intravenous and inhalation anesthesia. Anaesthesia 61:138 – 41
74. Sum DC, Chung PC, Chen WC (1996) Deliberate hypotensive anesthesia with labetalol in reconstructive surgery for scoliosis. Acta Anesth Sinica 34(4):203 – 7

75. Thalgott JS, Cotler HB, Sasso RC, et al. (1991) Postoperative infections in spinal implants: Classification and analysis – a multicenter study. Spine 16:981 – 4
76. Theroux MC, Corddry DH, Tietz AE, et al. (1997) A study of desmopressin and blood loss during spinal fusion for neuromuscular scoliosis: a randomized, controlled, double-blinded study. Anesthesiology 87(2):260 – 7
77. Tobias JD (2004) Strategies for minimizing blood loss in orthopedic surgery. Semin Hematol 41(1):145 – 56
78. Tobias JD (2004) A review of intrathecal and epidural analgesia after spinal surgery in children. Anesth Analg 98(4):956 – 65
79. Tsuji T, Matsuyama Y, Sato K, et al. (2001) Evaluation of the spinal cord blood flow during PGE1-induced hypotension with power Doppler ultrasonography. Spinal Cord 39(1):31 – 6
80. Turan A, Karamanlýoðlu B, MemiÞ D, Hamamcýoglu MK, Tükenmez B, Pamukçu Z, Kurt I (2004) Analgesic effects of gabapentin after spinal surgery. Anesthesiology 100:935 – 8
81. Urban MK, Beckman J, Gordon M, et al. (2001) The efficacy of antifibrinolytics in the reduction of blood loss during complex adult reconstructive spine surgery. Spine 26(10):1152 – 56
82. Weiskopf RB (2004) The use of recombinant activated coagulation factor VII for spine surgery. Eur Spine J 13(Suppl 1):S83–S88
83. Welch WC, Rose RD, Balzer JR, et al. (1997) Evaluation with evoked and spontaneous electromyography during lumbar instrumentation: a prospective study. J Neurosurg 87(3): 397 – 402
84. Zentner J (1989) Noninvasive motor evoked potential monitoring during neurosurgical operations on the spinal cord. Neurosurgery 24:709 – 12
85. Zigler JE, Anderson PA, Bridwell K, et al. (2001) What's new in spine surgery. J Bone Joint Surg 83A(8):1285 – 92

# 16 Postoperative Care and Pain Management

Stephan Blumenthal, Alain Borgeat

## Core Messages

- ✔ The necessity for careful postoperative assessment of the different organ systems is self-evident
- ✔ Perioperative tachycardias are often combined with ischemic episodes, and their treatment is mandatory because of the high mortality of perioperative myocardiac infarction
- ✔ Intensive insulin therapy can reduce morbidity and mortality
- ✔ Following cervical spine surgery, perform airway assessment before extubation. Suction drainage and close surveillance minimize the risk of unrecognized bleeding
- ✔ Aggressive postoperative pulmonary care minimizes the risk of respiratory complications
- ✔ Close neurological surveillance is mandatory to detect deterioration
- ✔ Postoperative paralytic bowel dysfunction can be ameliorated by thoracic epidural analgesia
- ✔ Spinal surgery is painful and a multimodal approach for peri- and postoperative analgesia is mandatory
- ✔ Opioid-related side-effects are independent of the route of administration
- ✔ Administration of regional anesthesia (e.g., epidural techniques) following complex spinal surgery may be of great help

## Postoperative Care

Major spinal surgery is prone to complications but can be minimized with proper postoperative care

Despite advances in anesthesia care and surgical techniques, major surgery is still prone to undesirable consequences [6] such as:

- infection
- thromboembolic complications
- cardiorespiratory morbidity
- cerebral dysfunction
- postoperative nausea and vomiting
- gastrointestinal paralysis
- pain
- fatigue
- prolonged convalescence

The **key pathogenetic factor** in postoperative morbidity is the surgical stress response with subsequent increased demands on organ function [6]. One of the key issues for the anesthesiologist is to decrease this surgical stress response as far as possible to limit its adverse effects.

Patients undergoing spinal surgery frequently have significant comorbidities which can have a significant impact on the postoperative recovery. Surgery can further compromise the organ system as a result of:

- significant blood loss requiring mass transfusions
- coagulopathy

- prolonged anesthesia with the problem of hypothermia
- residual impaired pulmonary function
- difficulties in acute postoperative pain management

Perioperative tachycardia often is combined with ischemic episodes

Even a single perioperative ischemic episode increases the **risk of cardiac mortality** within the ensuing 2 years. Most of these ischemic events are clinically silent and can only be detected with continuous ECG control. They are usually combined with perioperative tachycardia, which can be either a cause of or a reaction to ischemia. Treatment of a perioperative tachycardia is mandatory since it corrects the imbalance between oxygen supply and oxygen consumption and therefore has a cardioprotective effect.

Perioperative myocardiac infarction has a high mortality

**Perioperative myocardiac infarction** most often occurs during the first postoperative day and has a mortality rate which remains high, although it decreases with duration after surgery [25].

Intensive insulin therapy can reduce morbidity and mortality

**Hyperglycemia** and **insulin resistance** are common in postoperative and critically ill patients, even if the patients have not previously had diabetes mellitus. Intensive insulin therapy to maintain blood glucose at or below 6.1 mmol/l can reduce morbidity and mortality, compared to a more conventional treatment with insulin infusion only when blood glucose exceeds 11.9 mmol/l [28]. Since diabetes mellitus is recognized as a risk factor of infection after spinal surgery [9, 14], appropriate insulin therapy may help to reduce the incidence of postoperative wound infection as has been shown in the context of other operations [11].

## Postoperative Ventilation or Extubation

Most spinal surgery patients, including those who have undergone posterior fusion, can be extubated shortly after the procedure if preoperative pulmonary function was acceptable. Extubation is also advantageous since the neurological assessment is facilitated. However, residual narcotics or muscle relaxants can lead to hypoventilation or apnea, especially in patients with an associated neuromuscular disease. The need for **postoperative ventilation** [23, 29] is determined by patient and surgery related factors (Table 1). Frequently, it is necessary only to provide artificial ventilation for a few hours in the postoperative care unit, until hypothermia and metabolic derangements have been corrected.

**Table 1.** Influences on the need for postoperative ventilation

| Patient-related factors | Surgery-related factors |
|---|---|
| • presence of a preexisting neuromuscular disorder<br>• severe restrictive pulmonary dysfunction with a preoperative <35% predicted vital capacity<br>• congenital cardiac abnormality<br>• right ventricular failure<br>• obesity | • prolonged procedure (>5 h)<br>• exposing >3 vertebral bodies<br>• thoracic approach<br>• blood loss >30 ml/kg<br>• transfusion of large volumes of blood and fluid<br>• hypothermia |

### Cervical Spine Surgery

Perform airway assessment before extubation

At the conclusion of anterior cervical spine surgery, before extubation, it is advisable to perform a thorough airway assessment, in order to avoid a “can’t intubate, can’t ventilate” situation. This can be done by direct laryngoscopy, fiberoptic evaluation or by performing a cuff test.

Suction drainage and close surveillance minimize the risk of unrecognized bleeding after anterior cervical spine surgery

Postoperative bleeding after anterior cervical spine surgery can become a life-threatening situation when reintubation is impossible due to the hematoma pressure. In such cases, on-site emergency opening of the wound and reintubation or tracheotomy is the only means to save the patient. We therefore recommend rou-

tine suction drainage after anterior cervical spine surgery to minimize the risk of this delirious complication and we keep these patients in the recovery room overnight for surveillance.

### Thoracic Spine Surgery

Anterior thoracic and thoracolumbar approaches usually require chest tube placement. These drains should be checked regularly to ensure patency. Obstruction may lead to a pneumo- or hemothorax. This should always be considered as a potential cause of postoperative respiratory distress.

**Aggressive pulmonary care**, including spirometry, physiotherapy and early mobilization, is necessary to avoid postoperative atelectasis and pneumonia.

Aggressive postoperative pulmonary care minimizes the risk of atelectasis and pneumonia

If prolonged periods of mechanical ventilation are necessary because of respiratory insufficiency, the endotracheal tube should be replaced by a cuffed tracheostomy tube. This should be performed sooner rather than later if prolonged ventilation is anticipated.

## Hemodynamic Assessment

Continued hemorrhage remains a concern during the postoperative period and **careful monitoring is essential** with regard to:

- blood pressure
- urine output
- central venous pressure
- wound drainage

If postoperative bleeding is considerable, removal of the vacuum can solve the problem in the vast majority of cases. If coagulation abnormalities are suspected from clinical findings, the hemostasis parameter should be checked.

Gravity suction drainage and correction of hemostasis reduce excessive postoperative bleeding

## Neurological Assessment

Surgeons prefer patients to be conscious and able to respond to commands immediately after anesthesia for early neurological assessment [20]. Therefore, postoperatively patients should be adequately analgo-sedated to allow neurological evaluation, and motor control of the extremities should be possible at any time. **Neurological control** should be performed regularly at short intervals to detect neurological deterioration.

Neurological surveillance is mandatory to detect neurological deterioration

When such a finding is noted, an immediate investigation should be done to determine the cause and reversibility of the process. When available, magnetic resonance imaging should be performed to detect extrinsic spinal cord compression by bone, intramedullary swelling or hematoma.

Magnetic resonance imaging should be performed to determine the cause of a de novo neurological deficit

After correction of severe spinal deformities, postoperative (late onset) neurological deterioration can arise because of interference with the circulation to the spine leading to anterior spinal artery syndrome [26].

After anterior cervical fusion, **recurrent laryngeal nerve injury** has been reported [15]. Dissection involving levels T1 – 2 can result in a postoperative Horner syndrome caused by injury to the stellate ganglion [8]. A case of bilateral phrenic nerve palsy as a complication of anterior decompression and fusion has been described [10]. After iliac crest bone grafting, one has to be aware of possible neurological deficits involving the lateral femoral cutaneous, ilioinguinal and superior cluneal nerves [19].

## Gastrointestinal Function

Postoperative paralytic bowel dysfunction can be ameliorated by thoracic epidural analgesia

Intraoperative irritation of sympathetic splanchnic nerves causes postoperative **paralytic bowel dysfunction**, which can be made worse by activation of the sympathetic system due to pain and the large amounts of opioids necessary for sufficient analgesia. After major spinal surgery, a more rapid recovery of bowel function has been documented if postoperative analgesia is performed through a thoracic epidural catheter [2, 3].

## Thromboembolic Prophylaxis

Low-molecular-weight heparins prevent deep vein thrombosis and thromboembolic complications

Although deep vein thrombosis and thromboembolic complications occur after spinal surgery at a lower rate compared to other orthopedic procedures, they can contribute disproportionately to morbidity and mortality [7]. Patients undergoing spinal surgery may be at increased risk of thromboembolic disease as a result of prolonged surgery, prone positioning, malignancy, and extended periods of postoperative recumbency. Appropriate preventive measures include the use of compressive stockings, **early mobilization** and prophylactic administration of **low-molecular-weight heparins** [22].

# Postoperative Pain Management

## Consequences of Pain

Postoperative pain after spinal surgery can be severe

Pain management can be a **major challenge** after spinal surgery (see Chapter 5). The alleviation of postoperative pain is primarily provided for humanitarian reasons, but also to reduce nociception-induced responses, which may adversely influence organ functioning and contribute to morbidity [16]. A common feature shared by all surgical patients is the widespread changes in several biological cascade systems, including a predominance of catabolic hormones, activation of cytokines, complement arachidonic acid metabolites, nitric oxide, and free oxygen radicals, all of which may secondarily lead to organ dysfunction and morbidity. Pain may obviously be considered as another neurophysiological response to surgery but with its own secondary effects on biological functions. Pain amplifies the metabolic response, autonomic reflexes, ileus, and nausea and delays mobilization and feeding. **Effective treatment** of postoperative pain, therefore, results in modification of the biological response to surgery, but the extent of modification is dependent on the choice of analgesic technique [18].

Patients undergoing spinal surgery, particularly through a **thoracic approach**, may have a large incision extending over several dermatomes. Many patients have preexisting chronic pain conditions, may be cognitively impaired (some have neuromuscular disorders), or may be very young. A multimodal approach to analgesia (see Chapter 5) is recommended [17], using an appropriate combination of (Table 2):

**Table 2.** Multimodal analgesia

- acetaminophen (paracetamol)
- non-selective cyclooxygenase inhibitors
- COX-2 inhibitors
- opioids
- local anesthetics
- $\alpha_2$-agonists
- ketamine
- regional anesthesia techniques

A multimodal approach to analgesia facilitates ambulation and respiratory care

Adequate analgesia facilitates early ambulation and aggressive respiratory care, which are important to decrease patient morbidity postoperatively.

## Non-narcotics

Non-opioid analgesics (acetaminophen) and non-steroidal anti-inflammatory drugs (NSAIDs) play a central role in the management of postoperative pain, since they have shown an opioid-sparing effect, but there is little evidence for an additive analgesic effect of two non-opioid analgesics.

Acetaminophen and NSAIDs exhibit an opioid-sparing effect

Acetaminophen can be part of a multimodal pain therapy without great risk, with the exception of patients with impaired liver function. It has an additional antipyretic potency.

Acetaminophen should not be given in patients with impaired liver function

## Non-steroidal Drugs

Both non-selective cyclooxygenase inhibitors (NSAIDs) and the selective cyclooxygenase-2 (COX-2) inhibitors have been used successfully for pain therapy in different orthopedic surgical contexts, including spinal surgery [21].

The use of **non-selective NSAIDs** may increase bleeding time by 30 ± 35 %, cause gastritis and be associated with acute renal failure, particularly in the presence of hypovolemia and hypotension. COX-2 inhibitors have an analgesic efficacy comparable to non-selective NSAIDs, but are associated with an absence of antiplatelet activity and reduced gastrointestinal side effects. However, because both COX-1 and COX-2 are present in the kidney, COX-2 inhibitors require the same caution with their use regarding renal toxicity as non-selective NSAIDs, and special caution is warranted not to further decrease an already impaired renal function, especially in diabetic patients under concomitant ACE-inhibitor therapy for blood pressure control.

The influence of these drugs on bone healing and bone-tendon healing is controversial [12]. The results of experimental and animal studies with long-term administration probably cannot be transferred to the perioperative setting when these drugs are prescribed for a limited duration of some days.

The concerns regarding increased cardiac risk following the long-term administration of **COX-2 inhibitors** have to date only been demonstrated for rofecoxib, which therefore has been withdrawn from the market. In our hands, the use of NSAIDs and COX-2 inhibitors for up to 10 days after surgery has become a standard of (our) care and does not seem to have noticeable side effects.

Non-selective NSAIDs and selective COX-2 inhibitors should be used for a short postoperative period

## Opioids

Opioids can be administered by different routes. The use of parenteral opioids has been the mainstay of analgesia for all patients undergoing spinal surgery. Subcutaneous or intramuscular administration has the major drawback of uncontrolled absorption and distribution, unpredictable time to maximal effect and unpredictable duration of action. Because of the aspects mentioned, intravenous administration [**continuous infusion** and **patient-controlled analgesia** (PCA) devices with or without background infusions] should be preferred.

Subcutaneous or intramuscular opioid administration exhibit a poorly predictable time course for the maximum analgesic effect

Opioids can also be given epidurally or intrathecally. The thecal sac is readily accessible during spinal surgical procedures and intrathecal medication can be injected with technical ease before wound closure. Early reports of the use of intrathecal opioids for analgesia in children after spinal surgery and other major surgeries have suggested that the use of morphine 20 – 30 mg/kg is associated with excellent analgesia for up to 24 h. More recent studies suggest the optimum dose of morphine to be 2 ± 5 mg/kg, which provides a comparable analgesia for 24 h but with fewer side effects [5, 13].

Independently of the way they are administered, the use of opioids is associated with **side effects** such as:

- respiratory depression
- nausea and vomiting
- pruritus
- urinary retention
- sedation
- ileus

Opioid-related side-effects are independent of the route they are administered

The latter gastrointestinal side-effect may be especially disadvantageous after major spinal surgery, when some degree of paralytic ileus is common.

There is the possibility of reducing postoperative parenteral opioid consumption by the administration of an oral slow release opioid formula, which is introduced preoperatively [4]. Patients with cancer or other patients who have received long-term opioids preoperatively by different routes (e.g., enteral, transdermal) must be assumed to have acquired a degree of opioid tolerance and these drugs should also be restarted as early as possible postoperatively.

## Local Anesthetics

Administration of local anesthetics through epidural catheters allows for excellent pain control

The use of local anesthetic agents alone or in combination with opioids by the epidural route after spinal surgery has been described [27]. For scoliosis correction surgery with a dorsal or ventrodorsal approach, the use of continuous epidural analgesia with plain local anesthetic solution through one or two epidural catheters placed intraoperatively by the surgeon has been shown to provide efficient postoperative pain control with early recovery of bowel function, few side-effects and a high patient satisfaction [2, 3].

Epidural analgesia with local anesthetic agents can make neurological assessment difficult. Since the early postoperative period is critical for the appearance of a postoperative neurological deficit, there is the possibility of performing analgesia with a potent opioid (e.g., remifentanil) up to the first postoperative morning. After a thorough assessment of the neurological status, epidural analgesia can be introduced. The administration rate of the local anesthetic can be guided according to the level of motor and sensory blockade [2, 3].

Continuous administration of local anesthetics to the iliac crest after bone grafting relieves donor site pain

The continuous administration of local anesthetics to the iliac crest after bone grafting through a catheter placed by the surgeon at the end of the procedure is another new indication for these drugs [1].

### *N*-Methyl-D-aspartate Antagonists

Low-dose ketamine is helpful for acute postoperative pain

The role of the *N*-methyl-D-aspartate (NMDA) receptor in the processing of nociceptive input has led naturally to renewed clinical interest in NMDA receptor antagonists such as ketamine. It is a well-known general anesthetic and short-acting analgesic which has been in use for almost three decades. The efficacy of low-dose **ketamine** in the management of acute postoperative pain when administered alone or in conjunction with other agents via the oral, intramuscular, subcutaneous, intravenous or epidural routes has been described and evidence suggests that low-dose ketamine may play an important role in postoperative pain management when used as an adjunct to local anesthetics, opioids or other analgesic agents [24]. Low-dose ketamine is defined as a bolus dose of less than 2 mg/kg body weight when given intramuscularly or less than 1 mg/kg body weight when administered via the intravenous or epidural route. For continuous i.v. administration, low-dose ketamine is defined as a rate of at most 20 μg/kg body weight per minute.

Ketamine may provide clinicians with a tool to improve postoperative pain management and to reduce postoperative opioid consumption and consecutively opioid-related adverse effects. The S-enantiomer of this drug, which is not available in all countries, has about a two times increased potency with a preferable side-effect profile.

## Recapitulation

**Postoperative care.** Patients for spinal surgery often have significant comorbidities, and surgery imposes further stresses of blood loss, mass transfusion, coagulopathy, hypothermia, impaired pulmonary function and acute postoperative pain. Perioperative tachycardia has to be treated since it is often combined with ischemia, which increases the risk of **perioperative myocardiac infarction**. Intensive postoperative insulin therapy can reduce mortality. The need for **postoperative ventilation** is suggested by patient and surgical factors, but most spinal surgery patients can be extubated shortly after the procedure or need artificial ventilation only for a few hours. Aggressive postoperative **pulmonary care** helps to avoid atelectasis and pneumonia. **Monitoring** of blood pressure, urine output, central venous pressure, chest tubes and wound drainage is essential. **Neurological assessment** to detect neurological deterioration is important, and immediate investigation (and when available magnetic resonance imaging) should follow any suspicious finding. Intraoperative irritation of sympathetic splanchnic nerves, activation of the sympathetic system due to pain and large amounts of opioids cause postoperative **paralytic bowel dysfunction**. Preventive measures for **thromboembolic disease** include the administration of low-molecular-weight heparins.

**Postoperative pain management.** A **multimodal approach to analgesia** is recommended since adequate analgesia allows early ambulation and aggressive respiratory care. Non-opioid analgesics have shown an opioid-sparing effect. **Acetaminophen** can be given without great risk. **Non-selective NSAIDs** cannot be recommended for intraoperative and early postoperative analgesia. **COX-2 inhibitors** have analgesic efficacy comparable to non-selective NSAIDs, but are associated with an absence of antiplatelet activity and reduced gastrointestinal side effects, while requiring the same cautions regarding renal toxicity as non-selective NSAIDs. **Opioids** are potent analgesics and can be administered by different routes. Intravenous administration (continuous infusion or patient-controlled) is preferred. Independently of the way they are administered, their use is associated with side effects such as respiratory depression, nausea and vomiting, pruritus, urinary retention, sedation, and gastrointestinal ileus. Continuous **local anesthetic agents** through the epidural route after spinal surgery have been shown to provide efficient postoperative pain control with early recovery of bowel function, few side effects and high patient satisfaction. Continuous local anesthetic administration to the iliac crest after bone grafting is another new indication for these drugs. The efficacy and opioid-sparing effect of low-dose **ketamine** in the management of acute postoperative pain has been described. The S-enantiomer of this drug has an increased potency with a preferable side-effect profile.

## Key Articles

**van den Berghe G, Wouters P, Weekers F, Verwaest C, Bruyninckx F, Schetz M, Vlasselaers D, Ferdinande P, Lauwers P, Bouillon R (2001) Intensive insulin therapy in the critically ill patients. N Engl J Med 345:1359 – 67**
It was proven for the first time in this prospective study of 1 548 adults admitted to the surgical intensive care unit that intensive intravenous insulin therapy to maintain blood glucose at between 4.4 and 6.1 mmol/l can reduce mortality during intensive care and during hospital stay, decrease the incidence of infectious complications and shorten mechanical ventilation.

**Kehlet H (1997) Multimodal approach to control postoperative pathophysiology and rehabilitation. Br J Anaesth 78:606 – 17**
The author demonstrates why no single technique or drug has been shown to eliminate postoperative morbidity and mortality, and why multimodal interventions may lead to a

major reduction in the undesirable sequelae of surgical injury with improved recovery and reduction in postoperative morbidity and overall costs.

**Blumenthal S, Min K, Nadig M, Borgeat A (2005) Double epidural catheter with ropivacaine versus intravenous morphine: a comparison for postoperative analgesia after scoliosis correction surgery. Anesthesiology 102:175 – 180**
In this prospective study, following scoliosis correction surgery, continuous epidural local anesthetics administered through two epidural catheters have been shown not only to provide better postoperative analgesia compared to intravenous morphine, but also to reduce side effects, improve bowel function and increase patient satisfaction.

## References


1. Blumenthal S, Dullenkopf A, Rentsch K, Borgeat A (2005) Continuous infusion of ropivacaine for pain relief after iliac crest bone grafting for shoulder surgery. Anesthesiology 102:392 – 397
2. Blumenthal S, Min K, Nadig M, Borgeat A (2005) Double epidural catheter with ropivacaine versus intravenous morphine: a comparison for postoperative analgesia after scoliosis correction operation. Anesthesiology 102:175 – 180
3. Blumenthal S, Borgeat A, Nadig M, Min K (2006) Postoperative analgesia after anterior correction of thoracic scoliosis: a prospective randomized study comparing continuous double epidural catheter technique with intravenous morphine. Spine 31:1646 – 51
4. Blumenthal S, Min K, Marquardt M, Borgeat A (2007) Postoperative intravenous morphine consumption, pain scores, and side effects with perioperative oral controlled-release oxycodone after lumbar disectomy. Anesth Analg 105:233 – 7
5. Boezaart AP, Eksteen JA, Spuy GV, Rossouw P, Knipe M (1999) Intrathecal morphine. Double-blind evaluation of optimal dosage for analgesia after major lumbar spinal surgery. Spine 24:1131 – 7
6. Carli F (1999) Perioperative factors influencing surgical morbidity: what the anesthesiologists need to know. Can J Anesth 46:R70 – 79
7. Dearborn JT, Hu SS, Tribus CB, Bradford DS (1999) Thromboembolic complications after major thoracolumbar spine surgery. Spine 24:1471 – 6
8. Ebraheim NA, Lu J, Yang H, Heck BE, Yeasting RA (2000) Vulnerability of the sympathetic trunk during the anterior approach to the lower cervical spine. Spine 25:1603 – 6
9. Fang A, Hu SS, Endres N, Bradford DS (2005) Risk factors for infection after spinal surgery. Spine 30:1460 – 5
10. Fujibayashi S, Shikata J, Yoshitomi H, Tanaka C, Nakamura K, Nakamura T (2001) Bilateral phrenic nerve palsy as a complication of anterior decompression and fusion for cervical ossification of the posterior longitudinal ligament. Spine 26:E281 – 6
11. Furnary AP, Zerr KJ, Grunkemeier GL, Starr A (1999) Continuous intravenous insulin infusion reduces the incidence of deep sternal wound infection in diabetic patients after cardiac surgical procedures. Ann Thorac Surg 67:352 – 60
12. Gajraj NM (2003) The effect of cyclooxygenase-2 inhibitors on bone healing. Reg Anesth Pain Med 28:456 – 65
13. Gall O, Aubineau JV, Berniere J, Desjeux L, Murat I (2001) Analgesic effect of low-dose intrathecal morphine after spinal fusion in children. Anesthesiology 94:447 – 52
14. Glassman SD, Alegre G, Carreon L, Dimar JR, Johnson JR (2003) Perioperative complications of lumbar instrumentation and fusion in patients with diabetes mellitus. Spine J 3: 496 – 501
15. Jung A, Schramm J, Lehnerdt K, Herberhold C (2005) Recurrent laryngeal nerve palsy during anterior cervical spine surgery: a prospective study. J Neurosurg Spine 2:123 – 7
16. Kehlet H (1994) Postoperative pain relief – what is the issue? Br J Anaesth 72:375 – 8
17. Kehlet H (1997) Multimodal approach to control postoperative pathophysiology and rehabilitation. Br J Anaesth 78:606 – 17
18. Kehlet H (2000) Manipulation of the metabolic response in clinical practice. World J Surg 24:690 – 5
19. Kurz LT, Garfin SR, Booth RE, Jr. (1989) Harvesting autogenous iliac bone grafts. A review of complications and techniques. Spine 14:1324 – 31
20. Mineiro J, Weinstein SL (1997) Delayed postoperative paraparesis in scoliosis surgery. A case report. Spine 22:1668 – 72
21. Reuben SS, Connelly NR (2000) Postoperative analgesic effects of celecoxib or rofecoxib after spinal fusion surgery. Anesth Analg 91:1221 – 5
22. Roderick P, Ferris G, Wilson K, Halls H, Jackson D, Collins R, Baigent C (2005) Towards evi-

dence-based guidelines for the prevention of venous thromboembolism: systematic reviews of mechanical methods, oral anticoagulation, dextran and regional anaesthesia as thromboprophylaxis. Health Technol Assess 9:1 – 78
23. Sagi HC, Beutler W, Carroll E, Connolly PJ (2002) Airway complications associated with surgery on the anterior cervical spine. Spine 27:949 – 53
24. Schmid RL, Sandler AN, Katz J (1999) Use and efficacy of low-dose ketamine in the management of acute postoperative pain: a review of current techniques and outcomes. Pain 82:111 – 25
25. Sprung J, Abdelmalak B, Gottlieb A, Mayhew C, Hammel J, Levy PJ, O'Hara P, Hertzer NR (2000) Analysis of risk factors for myocardial infarction and cardiac mortality after major vascular surgery. Anesthesiology 93:129 – 40
26. Stockl B, Wimmer C, Innerhofer P, Kofler M, Behensky H (2005) Delayed anterior spinal artery syndrome following posterior scoliosis correction. Eur Spine J 14:906 – 9
27. Tobias JD (2004) A review of intrathecal and epidural analgesia after spinal surgery in children. Anesth Analg 98:956 – 65
28. van den Berghe G, Wouters P, Weekers F, Verwaest C, Bruyninckx F, Schetz M, Vlasselaers D, Ferdinande P, Lauwers P, Bouillon R (2001) Intensive insulin therapy in the critically ill patients. N Engl J Med 345:1359 – 67
29. Vedantam R, Lenke LG, Bridwell KH, Haas J, Linville DA (2000) A prospective evaluation of pulmonary function in patients with adolescent idiopathic scoliosis relative to the surgical approach used for spinal arthrodesis. Spine 25:82 – 90

# 17 Degenerative Disorders of the Cervical Spine

Massimo Leonardi, Norbert Boos

## Core Messages

- ✔ Age-related changes of the cervical spine can lead to cervical spondylosis, disc herniation and spondylotic radiculopathy/myelopathy
- ✔ Neck pain often lacks a clear morphological correlate (i.e. is non-specific)
- ✔ Cervical spondylosis more frequently causes radiculopathy than disc herniation and predominantly affects C5/6 and C6/7
- ✔ Mechanical compression and inflammatory changes cause the clinical syndrome of radiculopathy
- ✔ Cervical spondylotic myelopathy is caused by static (spinal canal stenosis), dynamic (instability), vascular and cellular (cell injuries, apoptosis) factors
- ✔ The cardinal symptom of cervical radiculopathy is radicular pain with or without a sensorimotor deficit
- ✔ Early symptoms of cervical myelopathy are "numb, clumsy, painful hands" and disturbance of fine motor skills. Late symptoms comprise atrophy of the interosseous muscles, gait disturbance, ataxia and symptoms of progressive tetraparesis
- ✔ The diagnostic accuracy of functional radiographs to reliably identify segmental instability is low. Instability remains a clinical diagnosis
- ✔ MRI is the imaging modality of choice for quantifying the extent of degenerative alterations and spinal cord compression
- ✔ CT myelography favorably demonstrates spurs, ossifications and foraminal stenosis in relation to the neural structures
- ✔ Neurophysiological studies are helpful in diagnosing subclinical myelopathy and differentiating radiculopathy from peripheral neuropathy
- ✔ The natural history of radiculopathy is benign while the spontaneous course of myelopathy is characterized either by long periods of stable disability followed by episodes of deterioration or a linear progressive course
- ✔ Scientific evidence for treatment guidelines of degenerative cervical disorders is poor
- ✔ Neck pain is treated non-operatively in the vast majority of patients. Indications for surgery are rare
- ✔ Cervical radiculopathy frequently responds favorably to conservative care. Surgery is indicated in patients with persistent symptoms or progressive neurological deficits
- ✔ The gold standard of treatment of radiculopathy is anterior discectomy and fusion, resulting in a favorable outcome in 80–90% of patients
- ✔ Alternative methods (i.e. additional anterior plate fixation, cage fusions, total disc arthroplasty, or minimally invasive decompressions without fusion) have not been shown to result in a superior outcome
- ✔ Mild cervical myelopathy without progression can be treated conservatively. Surgery is indicated in moderate to severe myelopathy. Complete recovery of advanced myelopathy is rare and early surgery is therefore indicated
- ✔ The principal aim of surgery for cervical spondylotic myelopathy is the decompression of the spinal cord. The surgical techniques include multilevel discectomies or corpectomies with or without instrumented fusion, laminectomy with or without instrumented fusion or laminoplasty.
- ✔ The choice of technique is dependent on the target pathology and patient characteristics

## Case Introduction

A 28-year-old female suffered from neck and arm pain for 3 weeks without neurological deficits. She was referred for physical therapy and manipulation. At the fourth session, the patient felt an excruciating sharp pain in her neck subsequent to a manipulation. She was unable to stand and developed a rapidly progressive tetraparesis sub C6. The patient was referred for emergency diagnosis and treatment. A lateral radiograph (a) did not show any evidence for a fracture/dislocation. MRI revealed a massive disc herniation (*arrow*) with severe spinal cord compression (*arrowheads*) at the level of C6/7 (b, c). Immediate spinal cord decompression was prompted by anterior cervical discectomy, sequestrectomy and fusion (Robinson-Smith technique) (d). The patient improved rapidly after the surgery. At 1-year follow, the patient had full neurological recovery and was symptom-free.

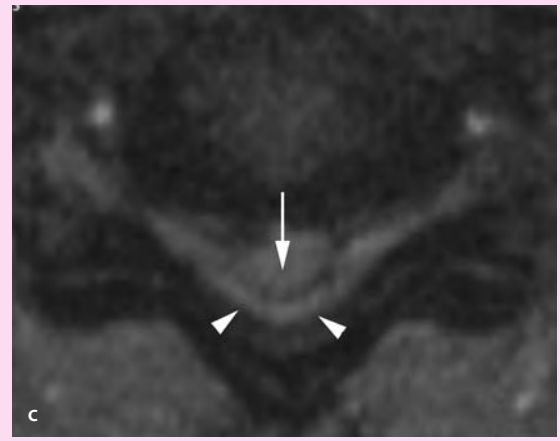


## Epidemiology

Degenerative alterations of the cervical spine are usually referred to as **cervical spondylosis**. This entity represents a mixed group of pathologies involving the intervertebral discs, vertebrae, and/or associated joints and can be due to aging ("wear and tear", degeneration) or secondary to trauma. The predominant clinical symptom is neck pain, which is often associated with shoulder pain. The degenerative alterations can lead to a central or foraminal stenosis compromising nerve roots or spinal cord (Fig. 1). These pathologies are termed **cervical spondylotic radiculopathy** (CSR) and **cervical spondylotic myelopathy** (CSM), respectively. CSR should be differentiated from disc herniation related radiculopathy.

The annual incidence of neck pain is about 15 %

In a Dutch national survey, there was an incidence of 23.1 per 1 000 person-years for **neck pain** and 19.0 per 1 000 person-years for shoulder symptoms [38]. Dutch general practitioners were consulted approximately seven times each week for a complaint relating to the neck or upper extremity; of these, three were new complaints or new episodes [38]. The annual incidence of neck pain was 14.6 % in a cohort of 1 100 randomly selected Saskatchewan adults, 0.6 % of whom developed disabling neck pain [66]. Women were more likely to develop neck pain

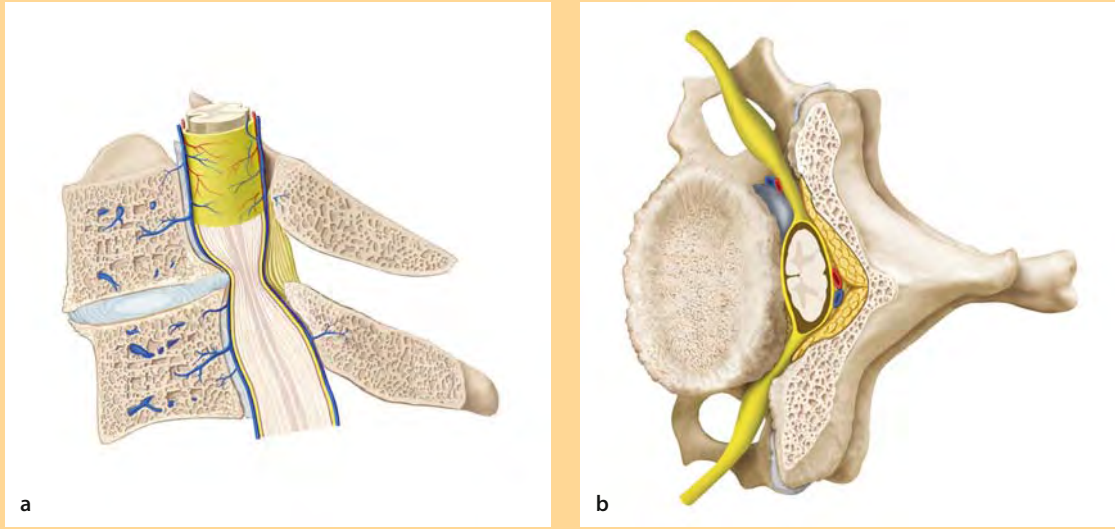


**Figure 1. Cervical spondylosis**

a, b Age-related changes can lead to disc herniations, cervical spondylosis, osteophyte formations, facet joint osteoarthritis, and compromise of the exiting nerve roots and the spinal cord.

than men [66]. In a Swedish survey on 4415 subjects, a prevalence rate of 17% for neck pain was found. Fifty-one percent of the neck pain subjects also had chronic low back pain [108]. A history of a neck injury was reported by 25% of patients with neck pain [108]. In a prospective longitudinal investigation in France, the prevalence and incidence rates of neck and shoulder pain were assessed in an occupational setting [48]. The authors found that the prevalence (men 7.8%, women 14.8% in 1990) and incidence (men 7.3%, women 12.5% for the period 1990–1995) of chronic neck and shoulder pain increased with age, and were higher among women than men in every birth cohort examined. The disappearance rate of chronic neck and shoulder pain decreased with age. The paper highlighted that adverse working conditions (e.g. repetitive work under time constraints, awkward work for men, repetitive work for women) contributed to the development of neck and shoulder pain, independently of age [48].

Neck pain is often associated with shoulder pain and LBP

**Cervical radiculopathy** is much less frequent than neck and shoulder pain with a prevalence of 3.3 cases per 1000 people. The peak annual incidence is 2.1 cases per 1000 and it occurs in the 4th and 5th decades of life [278]. In a Sicilian population of 7653 subjects [237], a prevalence of 3.5 cases per 1000 was found for cervical spondylotic radiculopathy, which increased to a peak at age 50–59 years, and decreased thereafter. The age-specific prevalence was consistently higher in women [237]. An epidemiological survey of cervical radiculopathy at the Mayo Clinic in Rochester [222] revealed that the average annual age-adjusted incidence rate per 100000 population for cervical radiculopathy was 83.2 (107.3 for males, 63.5 for females). The age-specific annual incidence rate per 100000 population reached a peak of 202.9 for the age group 50–54 years. A history of physical exertion or trauma preceding the onset of symptoms occurred in only 14.8% of cases. The median duration of symptoms prior to diagnosis was 15 days. A mono-radiculopathy involving C7 nerve root was most frequent, followed by C6.

The most frequent radiculopathy is C6 and C7

The most frequent cause of cervical radiculopathy is spondylosis

A confirmed disc protrusion was responsible for cervical radiculopathy in 21.9% of patients; in 68.4% it was related to spondylosis. During the median duration of follow-up of 4.9 years, recurrence of the condition occurred in 31.7%,

and 26 % underwent surgery for cervical radiculopathy. At last follow-up, 90 % of patients were asymptomatic or only mildly incapacitated due to cervical radiculopathy [222].

OPLL is a frequent cause of cervical myelopathy in Asians

The epidemiology data of **cervical spondylotic myelopathy** have not been well explored. The aging process results in degenerative changes of the cervical spine that, in advanced stages, can cause compression of the spinal cord. It is the most common cause of spinal cord dysfunction in the elderly [300]. A special form of cervical myelopathy is caused by the ossification of the posterior longitudinal ligament (**OPLL**). It is a multifactorial disease in which complex genetic and environmental factors interact. This disease is especially found in the Asian population [134]. In the Japanese population, the reported prevalence rate ranges from 1.8 % to 4.1 % [169, 196, 254]. The prevalence rate of OPLL in the cervical spine was significantly lower in the Chinese (0.2 %) and Taiwanese populations (0.4 %) [169]. A radiographic evaluation of cervical spine films at the Rizzoli Orthopaedic Institute in Bologna, Italy, revealed a prevalence of 1.83 % with a peak in the 45 – 64 year age group (2.83 %). This prevalence was much higher than that so far reported in Caucasians [266].

## Pathogenesis

Age-related changes are only weakly correlated with symptoms

Age-related changes of the intervertebral disc initiate the degenerative cascade and lead to a progressive deterioration of the motion segment (see Chapter 4). The disc height decreases leading to disc bulging as a result of progressive changes to the extracellular matrix of the disc. Microinstability results in reactive hyperostosis with formation of osteophytes at the vertebral endplates which can penetrate into the spinal canal and compromise the spinal cord and nerve roots (Fig. 1). **Osteophytes** of the uncovertebral and facet joints reduce the mobility of the segment. **Segmental instability** leads to a hypertrophy of the yellow ligament and causes a narrowing of the spinal canal and foramen. During later stages of segmental degeneration, **kyphosis** of the cervical spine can occur and further compromise the spinal cord and nerve roots [250]. Although cervical spondylosis can lead to symptoms such as neck pain, CSR and CSM, we should bear in mind that the vast majority of changes are asymptomatic [29].

## Neck Pain

A morphological correlate is rarely found for neck pain

The most common causes of subaxial neck pain are muscular and ligamentous factors related to improper posture, poor ergonomics and muscle fatigue [223]. The intervertebral disc and facet joints are richly innervated [51, 81, 176]. Degenerative alterations can therefore lead to pain generation (see Chapters 4, 5) representing a specific cause of neck pain. In the vast majority of cases, however, no structural correlate can be found to explain axial neck pain, i.e. neck pain most often is **non-specific**.

## Cervical Disc Herniation

Disc extrusions and sequestrations tend to resorb with time

Cervical radiculopathy due to disc herniation usually occurs during early stages of motion segment degeneration and mainly affects individuals in the 4th and 5th decades of life [222]. The main causes of disc herniation are age-related changes of the intervertebral disc making the anulus fibrosus susceptible to fissuring and tearing (see Chapter 4). The so-called "**soft herniation**" exhibits a chance for spontaneous resorption particularly in cases with disc extrusion and sequestration. Vascular supply probably plays a role in the mechanism of resorp-

tion [177]. The phase and position of the extrusion were identified as significant factors affecting cervical disc herniation resorption [177].

The pathophysiology of radiculopathy involves both **mechanical deformation** and **chemical irritation** of the nerve roots [232]. The release of **proinflammatory cytokines** and **nerve growth factor** (NGF) was recently identified to play a major role in the development of radicular arm pain [272]. Our current understanding of the pathogenesis of disc herniation related radiculopathy is mainly based on studies of the lumbar spine. We therefore prefer to provide a detailed overview of this issue in Chapter 18.

Spondylotic radiculopathy is caused by mechanical and inflammatory factors

## Cervical Spondylotic Radiculopathy

Spondylotic radiculopathy develops during later stages of motion segment degeneration and is caused by osteophytes of the endplates, facet and uncovertebral joints narrowing the spinal canal and neuroforamen (Fig. 1). These radicular entrapments (often referred to as "**hard herniations**") do not spontaneously improve and usually exhibit a slowly progressing deterioration. Humphreys et al. [130] showed that in symptomatic patients foraminal heights, widths and areas are smaller than in asymptomatic controls. Foraminal stenosis can cause permanent or intermittent mechanical irritation of the nerve roots and can lead to hypoxia of the nerve root and dorsal root ganglion. The subsequent release of proinflammatory cytokines and NGF is responsible for the generation of radicular pain [272]. Spontaneous resolution of these **inflammatory processes** can occur and explain why some patients can have long asymptomatic periods. This is supported by the finding that the incidence of radiculopathy does not closely correlate with age although there is an age-related increase of radiological alterations [278].

Mechanical nerve root compromise is not closely related to symptoms

## Cervical Spondylotic Myelopathy

In contrast to the lumbar spine, obliteration of the spinal canal by a disc herniation or osseous spurs can lead to severe neurological deficits because of a direct compromise of the spinal cord resulting in the clinical syndrome of **myelopathy**.

Myelopathy can result from (Table 1):

Cervical spondylosis is the most frequent cause of myelopathy in Caucasians

**Table 1.** Etiology of cervical myelopathy

| Acute | Chronic |
|---|---|
| • large disc herniation<br>• traumatized narrow spinal canal | • cervical spondylosis<br>• ossified posterior longitudinal ligament (OPLL) |

CSM generally can cause a variety of neurological disturbances like spastic gait, ataxia, hyperreflexia, sensory impairment, sphincter disturbances, and motor deficit. The degree and combination of each symptom can vary extensively and there is no close relationship between the extent of compression and clinical symptoms. The **pathophysiology of CSM** involves [16, 32, 80]:

- static factors
- dynamic factors
- biologic and molecular factors

### Static Factors

The normal sagittal diameter of the spinal canal (C3–7) is 14–22 mm [44, 74, 119, 207] with enough space for the neural elements, ligaments and epidural fat.

A narrow spinal canal predisposes to CSM

The spinal cord occupies about three-quarters of the size of the spinal canal in the subaxial spine [80]. A narrowing of the **spinal canal size** can result from disc degeneration, vertebral osseous spurs, osteophyte formation at the level of the facet joints, and yellow ligament hypertrophy, calcification or ossification [205]. Patients with a **congenitally narrow spinal canal** (< 13 mm) have a higher risk for the development of symptomatic cervical myelopathy [9, 74]. Penning et al. [209] showed that concentric compression of the cord resulted in long tract signs only after the cross-sectional area of the cord had been reduced by about 30 % to a value of about 60 $mm^2$ or less. This is in line with findings by Teresi et al. [267], who reported that spinal cord compression was observed in seven of 100 asymptomatic patients. The percentage of cord area reduction never exceeded 16 % and averaged approximately 7 %. Ogino et al. [194] found that the degree of cord compromise was in good correlation with the ratio of the anteroposterior diameter to the transverse diameter, designated as an anteroposterior compression ratio.

### Dynamic Factors

Instability and kyphosis aggravate CSM

**Dynamic compression** appears to play a major role in CSM. Flexion of the cervical spine causes a lengthening of the spinal cord which can be stretched over posterior vertebral spondylosis. In an already narrow canal this motion may damage anterior spinal cord structures [80]. Extension of the cervical spine provokes a buckling of the ligamentum flavum with dorsal compression of the spinal cord combined with anterior compression due to posterior disc bulging and/or vertebral body osteophytes [80]. This results in a **pincer effect** that places the neurons of the spinal cord at great risk [40, 201, 205]. Advanced disc degeneration and height loss may allow for a translative movement with spondylolisthesis in an anterior or posterior direction decreasing the spinal canal by 2 – 3 mm. Loss of disc height and hypermobility of facet joints can lead to loss of lordosis and finally to **kyphosis**. Dynamic changes and increasing kyphosis place increased strain and shear forces on the spinal cord [16].

### Biologic and Molecular Factors

Corticospinal tracts are very vulnerable to ischemia

**Vascular factors** can play a significant role in the development of myelopathy. Mechanical and vascular mechanisms can add to each other. A compressed spinal cord will not tolerate a diminished perfusion and a marginally vascularized cord will not tolerate compression [98, 252]. **Blood supply** of the different tracts in the spinal cord impacts on the pattern of ischemia and subsequent axonal degeneration. Transverse perforating vessels arising from the anterior sulcal arterial system are very susceptible to tension and likely to cause early ischemia and degeneration of the gray matter and medial white matter (anterior spinal cord syndrome) [87]. **Spinal cord ischemia** especially affects oligodendrocytes, which results in demyelination exhibiting features of chronic degenerative disorders (e.g. multiple sclerosis) [67]. Particularly the corticospinal tracts are very vulnerable and undergo early demyelination initiating the pathologic changes of cervical myelopathy [40, 80, 95, 255].

Static mechanical factors causing compression, shear and distraction and dynamic repetitive compromise are seen as primary injury whereas ischemia and the subsequent cascade at the cellular and molecular level are considered as secondary injury. These **secondary mechanisms** include [80, 151, 204]:

- glutamatergic toxicity
- free radical-mediated cell injury

- cationic-mediated cell injury
- apoptosis

Secondary cellular and molecular changes further compromise spinal cord function

Traumatic and ischemic injuries lead to an increase in extracellular levels of glutamate, which is assumed to be excitotoxic leading to neuronal death. The generation of free radicals and lipid peroxidation reactions may render neurons sensitive to the excitotoxic effects of glutamate [80]. The failure of the $Na^+$-$K^+$-adenosine triphosphatase pump results in an accumulation of axonal $Na^+$ through non-inactivated $Na^+$ channels. The $Na^+$ channels can permit intracellular $Ca^{2+}$ entry activating enzymes (e.g. calpain, phospholipases and protein kinase C) resulting in cytoskeletal injury [80]. **Apoptosis** represents a fundamental biological process that contributes to the progressive neurological deficits observed in spondylotic cervical myelopathy [151]. A common finding of many investigations of spinal cord disorders is the observation that oligodendrocytes appear to be particularly sensitive to a wide range of oxidative, chemical, and mechanical injuries, all of which lead to oligodendrocyte apoptosis [67, 167, 255]. The early apoptotic loss of oligodendrocytes is assumed to precede axonal degeneration and participate in the expression of profound and irreversible neurological deficits caused by destructive pathologic spinal cord changes under chronic mechanical compression seen in CSM [16, 151].

Gene polymorphism is associated with OPLL

A particular entity is the **ossification of the posterior longitudinal ligament** (OPLL), which particularly affects Japanese individuals and leads to a progressive stenosis of the cervical spinal canal and subsequently CSM [254]. OPLL is a multifactorial disease in which complex genetic as well as environmental factors play a major role [134, 282]. Gene analysis studies identified specific collagen **gene polymorphisms** that may be associated with OPLL, which encode for extracellular matrix proteins [134]. Recently, it has been shown that polymorphism of the **nucleotide pyrophosphatase** (NPPS) **gene** plays an important role in the pathogenesis of OPLL [155, 186]. NPPS is a membrane-bound glycoprotein assumed to produce inorganic pyrophosphate which acts as a major inhibitor of calcification and mineralization. Furthermore, the involvement of many growth factors and cytokines, including bone morphogenetic proteins and transforming growth factor-β, were identified in various histochemical and cytochemical analyses. Recent epidemiological studies confirmed an earlier finding that diabetes mellitus is a distinct risk factor for OPLL [134, 282].

## Clinical Presentation

Patients with a degenerative cervical disorder can present with a spectrum of symptoms ranging from benign, self-limiting neck pain to excruciating upper extremity pain with progressive severe neurological deficits. The **primary goal** of the clinical assessment is to differentiate (see Chapter 8):

- specific cervical disorders, i.e. **with** pathomorphological correlate
- non-specific cervical disorders, i.e. **without** evident pathomorphological correlate

In **specific cervical disorders** a pathomorphological (structural) correlate can be found which is consistent with the clinical presentation. Accordingly, in **non-specific cervical disorders** no such correlate can be detected. Patients can only be classified in the latter group after they have undergone a thorough clinical and diagnostic work-up. Patients frequently present with pain syndrome located in the neck-shoulder-arm region, which sometimes makes it difficult to differentiate neck and shoulder problems. Before the diagnosis of non-specific neck pain

can be made, it is mandatory to exclude differential diagnoses, e.g. shoulder pathology, or nerve entrapment syndromes. In this chapter, we focus on a pathology oriented approach. General aspects of history-taking and physical examination are presented in Chapter 8.

## History

Differentiate neck and arm pain

The predominant symptom for patients with degenerative cervical disorders is **pain**. Rarely, patients present with neurological symptoms without pain. The key question in differentiating the origin of patients' pain is (Table 2):

**Table 2.** Key question

- How much of your pain is in your arm(s)/hand(s) and in your neck/shoulder(s)?

In patients with **predominant arm pain**, the patients' symptoms are frequently part of a radicular or myelopathic syndrome (Table 3):

**Table 3.** Cardinal symptoms of radiculopathy and myelopathy

| Radicular syndrome | Myelopathic syndrome |
|---|---|
| • radicular pain<br>• sensory disturbances<br>• motor weakness<br>• reflex deficits | • numb, clumsy, painful hands<br>• difficulty writing<br>• disturbed fine motor skills<br>• difficulty walking<br>• symptoms of progressive tetraparesis (late)<br>• bowel and bladder dysfunction (late) |

The key finding in patients with a radicular syndrome is **radicular pain**, i.e. pain following a dermatomal distribution. The sensory, motor and reflex deficits are dependent on the affected nerve root. It is important to note that the pain not only radiates into the skin (dermatome) but also into the muscles (**myotomes**) and bone (**sclerotomes**) (see Chapter 8).

Differentiation of radicular and referred arm pain is sometimes difficult

The referred type of pain is sometimes difficult to differentiate from non-specific radiating pain, which is not caused by a nerve root compromise. The radicular pain can be preceded by neck pain which results from an incipient disc herniation, i.e. stretching of the anulus.

**Cervical radiculopathy** can be caused by a:

- disc herniation
- spondylotic stenosis

Disturbed fine motor skills may indicate CSM

In contrast to radiculopathy, a **myelopathic syndrome** can begin very subtly and can therefore pose a diagnostic challenge. The leading symptoms are **numb, clumsy, painful hands** [192, 198]. The examiner should particularly ask for disturbed fine motor skills (particularly writing skills). The degree of neck pain is largely variable. The pathoanatomical cause of the myelopathy characterizes the clinical presentation. Patients with cervical myelopathy can present with a broad spectrum of signs and symptoms. Cervical myelopathy is a clinical syndrome and dysfunction of the spinal cord, depending on the magnitude of spinal cord dysfunction and its chronicity. **Early symptoms** include diminished dexterity and subtle changes in balance and gait. Difficulty in manipulating small objects (e.g. buttons, needles) is typical. Myelopathy can concomitantly appear with radiculopathy since central stenosis is often combined with foraminal stenosis.

In patients with **predominant neck pain**, the patients' symptoms are frequently part of a so-called **spondylotic syndrome** (Table 4).

**Table 4.** Spondylotic syndrome

- recurrent episodes of neck pain
- pain aggravation with motion
- position dependent neck pain
- non-radicular arm and shoulder pain
- night and early morning pain
- vegetative symptoms
- vertigo and dizziness
- headaches

The **spondylotic syndrome** is more difficult to describe than a radicular and myelopathic syndrome. The pain arises from painful motion segment degeneration and can be attributed to different pathoanatomical alterations, i.e.:

- disc degeneration
- facet joint osteoarthritis
- segmental instability

In contrast to the lumbar spine, it is more difficult to clinically differentiate these pain origins. We therefore prefer to generally summarize the neck pain resulting from the degenerative motion segment as spondylotic pain. The pain can be accentuated by **movement** and during specific positions (e.g. reading, computer work, driving). Pain during the night may indicate severe facet joint osteoarthritis (OA). Pain is often associated with non-dermatomal shoulder girdle pain. Patients often report vague numbness, thermal sensations, and tingling. The causes of **vertigo and dizziness** are not well explored [39, 90]. Some of these vegetative symptoms are caused by disturbance of sympathetic nerves which richly innervate the cervical spine [152, 308]. **Headaches** are frequent concomitant symptoms [118] and sometimes pose a difficult differential diagnosis.

Vegetative symptoms and vertigo are not uncommon

As indicated in Chapter 8, the **history should include:**

- assessment of pain intensity (VAS or Likert scale)
- assessment of temporal course
- diurnal pain variation
- positional and activity modulators of pain
- functional limitations (ADL, job)

The functional limitations for activities of daily living (ADL) or professional activities should best be assessed using an established questionnaire (Chapter 40).

## Physical Findings

Even if the patient presents only with shoulder arm pain, a thorough examination of the whole spine is recommended. The general examination of the spine is detailed in Chapter 8. The need for a thorough neurological examination is self-evident (Chapter 11).

In patients with **radiculopathy**, frequent findings are [272]:

- sensory deficit
- motor deficit
- reflex deficits
- positive Spurling test
- positive shoulder abduction or depression test
- positive axial traction test

The **Spurling test** or neck compression test is performed with the patient in the sitting position (see Chapter 8) [272]. The neck is extended and rotated to the side of the pain. Then, a careful axial compression of the head is applied; if positive, the patient reports pain radiating along the compromised nerve root [75].

Provocation tests are helpful in diagnosing radiculopathy

Some patients report additional vegetative disturbances such as a feeling of coolness in the hand or arm and trophic changes. In general, the Spurling test demonstrated low to moderate sensitivity and high specificity, as did traction/neck distraction, and Valsalva's maneuver. The **upper limb tension test** (ULTT) demonstrated high sensitivity and low specificity, while the **shoulder abduction test** demonstrated low to moderate sensitivity and moderate to high specificity [231].

In patients with **cervical myelopathy**, frequent findings are [68, 172, 238]:

- atrophy of the interosseous muscles
- gait disturbances and ataxia
- spasticity, hyperreflexia, and clonus
- pathologic reflexes, positive Babinski sign
- sensory and vibratory deficits
- muscle weakness
- positive Lhermitte sign

The myelopathic gait is broad, abrupt and jerky

Cervical spondylotic myelopathy is a combination of symptoms resulting from an impairment of segmental neural compromise and long tracts. The segmental compromise includes sensorimotor deficits consistent with a radicular deficit. Early symptoms are numb, clumsy hands and later **atrophy of the interosseous muscles**. Good et al. [97] reported a series of patients with cervical myelopathy in whom the main complaint was numbness in the hands. In this context, a loss of power of adduction and extension of the ulnar two or three fingers and an inability to grip and release rapidly with these fingers can be observed [198]. These patients have **decreased vibratory and positional sense**, and diminished fine motions in the hands. Gait disturbance occurs late in cervical spondylotic myelopathy. The gait disturbance manifests as spasticity and paretic dysfunction of the lower extremities. Additional symptoms are loss of balance, unsteadiness, stiffness with ambulation, and complaints of loss of power in the lower extremities. The myelopathic gait is broad based with abrupt motion sometimes more hesitant and jerky.

Gait is assessed by asking the patient to walk on the line and walk with closed eyes. Spinal ataxia is present in the case of a positive Rhomberg test (Chapter 11) or when the patient's unsteady gait worsens with closed eyes. Sensory changes vary widely according to the location and extent of the spinal cord dysfunction. Upper motor neuron findings such as spasticity, clonus and hyperreflexia may be present in upper and lower extremities. Long tract signs such as Babinski, Oppenheimer and Gordon as well as persistent clonus are indicative of upper motor neuron lesion. Sensory disturbances in cervical myelopathy include loss of pain and temperature, proprioception, and vibration below the level of the lesion, whereas touch is often preserved [57]. Altered vibratory sense and proprioceptive changes are often present in cases with chronic or severe myelopathy. Reflexes are enhanced below and decreased at the level of the anatomical lesion. The Lhermitte sign (i.e. pain on sudden head flexion causing an electrical shock along the spine and extremities) may be present in cases with acute stenosis. Upper motor neuron involvement also includes bowel and bladder dysfunction which can be found in up to 50 % of CSM patients [172]. In a study of 55 patients with cervical spondylotic myelopathy, Gregorius et al. [104] found gait abnormalities, lower extremity weakness, sensory deficits, and sphincter disturbances in over 60 % of cases.

In patients with **spondylotic syndrome**, findings are:

- stiff neck with limited range of cervical motion
- neck pain on extension and rotation
- referred pain on motion (occiput, shoulder, upper limb)
- chronic trapezius myalgia

## Functional Assessment

A standardized functional assessment is required to assess outcome

One of the first outcome assessments of cervical spinal disorders was proposed by Odom and is still frequently used [193]. Odom differentiated the result into four categories (i.e. excellent, good, satisfactory, poor). However, there is a consensus that such a crude outcome assessment is insufficient and not patient-based [36]. It is therefore recommended to use self-rating scales such as the Neck Pain and Disability Questionnaire [285] and the Neck Disability Index [275] (Chapter 40). With regard to the assessment of CSM, a more detailed emphasis on compromised function is required. Nurick developed a grading system focusing on CSM related gait abnormalities [190, 191]. The grading system involves six grades (0 to 5) with progressive disability for ambulation (not affected to chair-bound/bedridden). The Japanese Orthopaedic Association (JOA) suggested a more comprehensive grading system (**JOA score**) to assess the severity of the myelopathy, recording motor function of upper and lower extremities, sensory function of upper and lower extremities and trunk, and bladder function [126, 128]. However, the application of this score for non-Asian patients is limited by the fact that one assessment considers the use of chopsticks. Modifications have therefore been suggested by Benzel et al. [20] and Keller et al. [149]. In Europe, the so-called **European Myelopathy Score** was developed [123] and compares favorably to various other outcome assessment tools for CSM [259, 276].

## Diagnostic Work-up

The causes of neck pain are not well defined

A thorough history and physical examination allow the diagnosis of radiculopathy and myelopathy in the vast majority of cases. In this regard, imaging studies are helpful in identifying the correct level of neural compromise. On the contrary, the diagnostic work-up for neck pain remains challenging because degenerative alterations are frequent in asymptomatic individuals [29, 215]. The correlation of structural alterations to neck pain often requires further investigation. Even with spinal injections, the sources of axial neck pain cannot be identified with certainty.

## Imaging Studies

Radiographs provide an excellent initial appraisal of cervical spondylosis

Although magnetic resonance imaging (MRI) has become the imaging modality of choice, standard radiographs are still helpful because they provide a straightforward assessment of cervical spondylosis. However, in the absence of signs of radiculopathy or myelopathy, imaging studies are not necessary within the first 4–6 weeks after onset of symptoms and an initial conservative therapy is indicated [15].

### Standard Radiographs

Standard radiographs of the cervical spine in the anteroposterior and lateral planes demonstrate:

- sagittal profile (e.g. loss of lordosis, kyphosis) (Fig. 2a)
- sagittal spinal canal diameter (Fig. 2a, b)
- spinal alignment and bony relationship (e.g. spondylolisthesis) (Fig. 2c)
- disc space narrowing (Fig. 2c)
- bony vertebral structures (vertebral collapse, osteophytes)
- developmental anomalies (os odontoideum, Klippel-Feil syndrome)

**Figure 2. Standard radiography**

Conventional X-rays demonstrate: **a** sagittal profile (loss of lordosis, kyphosis), spinal canal to vertebral body sagittal diameter ratio (normal Pavlov index); **b** congenitally narrow spinal canal (decreased Pavlov index); **c** sagittal alignment (spondylolisthesis), osteophyte formations; **d** atlantoaxial facet joint osteoarthritis (*arrowheads*); **e** foraminal stenosis (*arrowheads*).

- facet joint osteoarthritis (Fig. 2e)
- diffuse idiopathic skeletal hyperostosis (DISH)

Patients with a sagittal diameter < 10 mm are at risk of developing CSM

The **sagittal diameter** of the spinal canal is measured from the posterior aspect of the midvertebral body to the spinolaminar line and is 14 – 22 mm in a normal subject [44, 74, 119, 207]. A patient with a spinal canal diameter of less than 10 mm is regarded at high risk of developing CSM [74]. A spinal canal to vertebral body sagittal diameter ratio (**Pavlov index**) (Fig. 2a) of 0.8 or less was demonstrated to correlate with an increased risk of developing myelopathy [206, 269]. However, with the advent of MRI these measurements have become

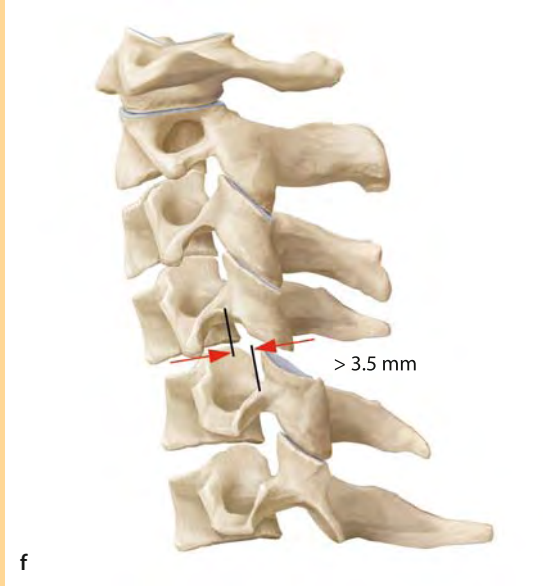


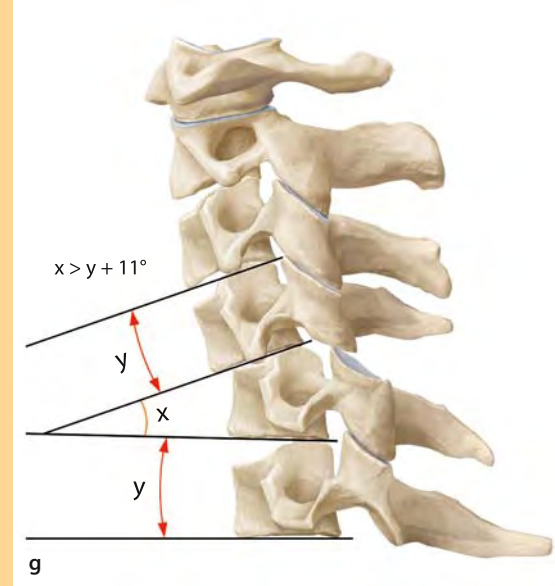


**Figure 2.** (*Cont.*)

The radiological criteria of segmental instability according to White et al. [286] must be interpreted tentatively. f, g However, an anterolisthesis of more than 3.5 mm or an angulation of 11 degrees more than in the adjacent segment indicates a putative instability.

less important, because the extent of neural compromise can be directly visualized.

**Oblique radiographs** allow facet joint alignment, facet joint OA and foraminal stenosis to be assessed (Fig. 2e). Whereas the utility of standard anteroposterior and lateral radiographs of the cervical spine is well accepted, the value of flexion and extension radiographs remains controversial. Debate continues on the radiological definition of **instability.** White et al. [286] have suggested criteria for subaxial instability (Fig. 2f, g) but stressed that their interpretation remains subjective [286]. Similar to the lumbar spine, imaging studies have failed to allow for a reliable diagnosis and instability therefore remains a clinical diagnosis.

Instability remains a clinical diagnosis

White et al. [289] retrospectively analyzed radiographs of 258 patients. They diagnosed spondylolisthesis in 23 patients from neutral lateral images, 6 of which (3%) showed changes of 2–4 mm in flexion and extension. Only two patients (1%) showed spondylolisthesis on flexion-extension not seen on neutral lateral radiographs. The authors concluded that spondylolisthesis revealed on flexion-extension radiographs did not lead to a change in management after reviewing the medical charts, and considering the radiation exposure and costs dynamic radiographs are no longer regarded as useful in degenerative cervical disorders.

Flexion/extension views frequently do not change treatment stategy

## Magnetic Resonance Imaging

MRI is the imaging modality of choice because of its non-invasiveness, excellent tissue contrast and multiplanar capabilities (Fig. 3a–c). Some limitation exists with regard to a detailed assessment of bony alterations. MRI is a very sensitive imaging modality but its specificity is hampered by the high rate of asymptomatic alterations found in asymptomatic individuals. MRI exhibits disc herniation

T2W images overemphasize spinal cord compression

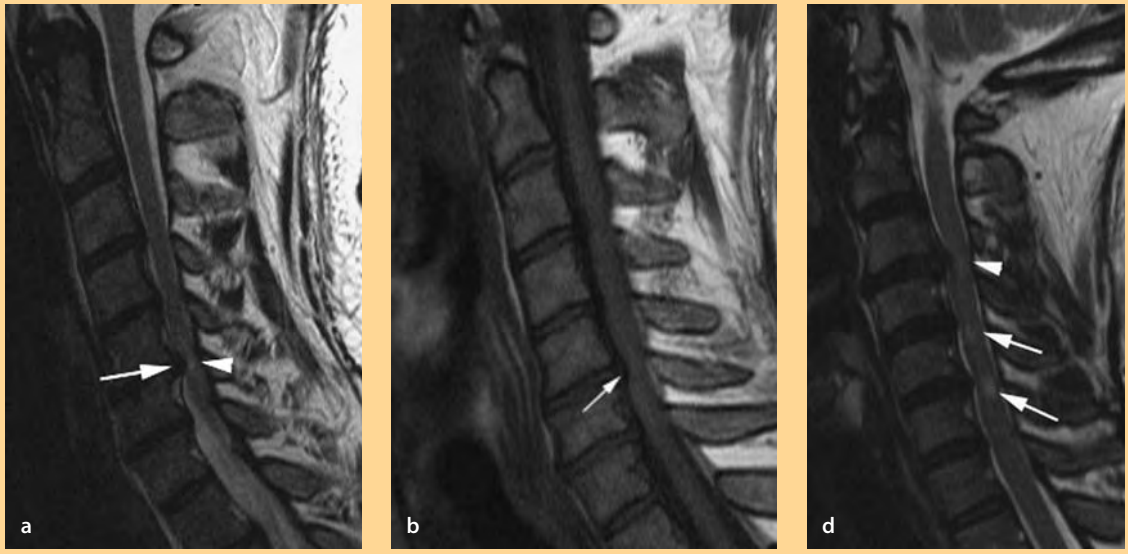


**Figure 3. Magnetic resonance imaging**

MRI is the imaging modality of choice to demonstrate degenerative alterations and neural compression. a T2W image showing disc herniations (*arrow*) and spinal cord signal intensity changes. T2W images tend to overestimate spinal cord compression. b T1W images (same patient as in a) should preferably be used for this assessment. c Axial T2W images demonstrating a large disc herniation and spurs (*arrowheads*) compressing the spinal cord. d T2W image of a patient suffering from multilevel cervical disc herniations with compression of the spinal cord at C3/4 (*arrowhead*). The severe signal intensity changes at C4/5 and C5/6 (*arrows*) do not correlate with the site and extent of cord compression and are therefore indicative of an additional disorder (e.g. multiple sclerosis, as in this case).

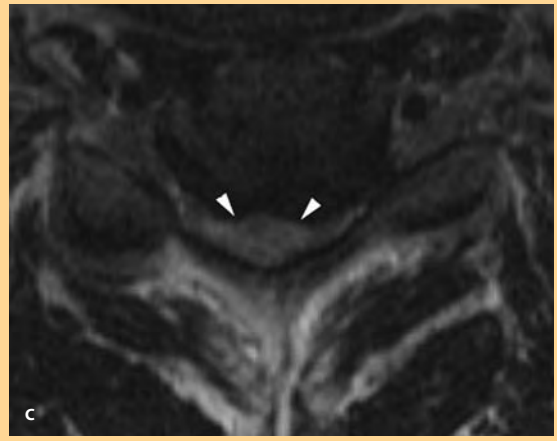


in 20–35% and disc bulging in 56% of asymptomatic adults under 60 years of age. MRI frequently demonstrates endplate (Modic) changes (see Chapter 9) which have been shown to be indicative of symptomatic disc degeneration in the lumbar spine [283]. An important aspect in the assessment of CSM is the CSF anterior and posterior of the spinal cord. This assessment should best be done using a T1W sequence, because T2W sequences tend to overemphasize the compression (Fig. 3a, b).

A T1W image overestimates spinal cord compression

MRI also allows for an excellent assessment of the craniocervical junction (C0–C2) [214, 215]. However, alterations of ligamentous structures and particularly **rotational abnormalities** are frequently seen in asymptomatic controls [214, 215].

Spinal cord signal intensity changes indicate myelopathy

**MR signal intensity changes** within the spinal cord are thought to represent structural lesions of the spinal cord. Based on histopathologic investigations, Oshiho et al. [195] found that abnormally high T2W image signal intensities are non-specific in mildly altered lesions or areas with edema. In the gray matter, a low T1W image in conjunction with a high T2W image signal intensity appeared in severely altered lesions with necrosis, myelomalacia, or spongiform changes. In the white matter, abnormally high T1W image intensities appeared in severely altered lesions. However, there is a controversy regarding the prognostic signifi-

cance of these changes [6, 173, 178, 302]. Care must be taken with regard to the diagnosis in cases in which the extent of the signal changes does not correspond to the amount of compression. In these cases other neurological causes, e.g. multiple sclerosis, must be considered (Fig. 3d).

### CT Myelography

CT myelography favorably demonstrates spurs, ossifications and foraminal stenosis

Prior to MRI, computed tomography (CT) myelography was frequently used and is still preferred by some surgeons because of its excellent depiction of the osseous structures (e.g. osteophytes, OPLL) in relation to spinal nerve roots and cord (Fig. 4a, b). Image reformations in the foraminal plane are helpful for preoperative planning of decompression for CSR (Fig. 4c). CT myelography still has its indications in cases with contraindications for MRI (e.g. pacemaker) or in the presence of implants. Images in flexion and extension help to display **dynamic compression** of the spinal cord [209] but its relevance remains undetermined.

### Injection Studies

Discography and facet joint blocks are controversial for fusion level selection

The problem of successfully treating axial neck pain is the exact localization of the pain source. It is apparently difficult to define discogenic neck pain considering only MRI [246, 307]. **Discography** in degenerative cervical disc disease has limited application, because pain provocation is seen in multiple discs. The surgical decision of which disc should be treated is therefore difficult. Similarly, the accuracy and reliability of cervical facet blocks is controversial (see Chapter 10).

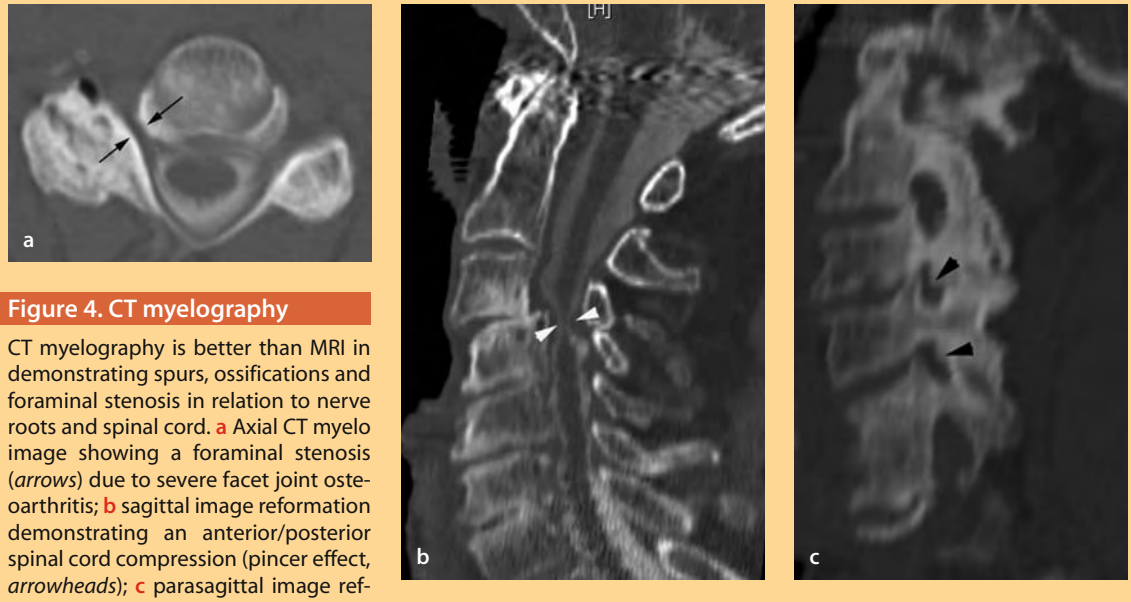


**Figure 4. CT myelography**

CT myelography is better than MRI in demonstrating spurs, ossifications and foraminal stenosis in relation to nerve roots and spinal cord. **a** Axial CT myelo image showing a foraminal stenosis (*arrows*) due to severe facet joint osteoarthritis; **b** sagittal image reformation demonstrating an anterior/posterior spinal cord compression (pincer effect, *arrowheads*); **c** parasagittal image reformation demonstrating severe foraminal stenosis (*arrowheads*).

## Neurophysiological Assessment

Neurophysiological studies allow the diagnosis of subclinical myelopathy

Neurophysiological examinations are indicated in situations where the clinical picture does not correlate with the radiological findings. Neurophysiological studies (Chapter 12) are helpful to exclude peripheral nerve damage, e.g. ulnar nerve syndrome and carpal tunnel syndrome. Neurophysiological studies may allow the recognition of subclinical neurogenic lesions but have the drawback of frequent false-positive findings (i.e. findings without clinical relevance). In CSM, neurophysiological investigations play a more important role than in radiculopathy. **Somatosensory evoked potential** (SSEP) abnormalities are strongly correlated with clinical myelopathy, but not with radiculopathy [301]. In subclinical cord compression, abnormalities of SSEPs and **motor evoked potentials** (MEPs) were found in half of the individuals with putative CSM and one-third developed manifest myelopathy in the follow-up of 2 years [18]. Probably, the most important role of neurophysiological assessment is to **monitor the progression of cervical myelopathy**, which can add to the surgical decision-making. However, SSEPs and MEPs are of limited use for evaluating the results of therapy in an individual patient but are useful in the group assessment of therapy results and in labeling a subgroup of patients with potentially favorable postsurgical outcome [19].

## Differential Diagnosis

Differential diagnosis is very important because a great number of other pathologies may mimic cervical radiculopathy and myelopathy (see Chapter 11). The most **frequent differential diagnoses** are [45]:

- nerve entrapment syndromes
- shoulder girdle disorders (rotator cuff tears, impingement syndrome, tendinitis)
- acute brachial plexopathy (Parsonage-Turner syndrome, neuralgic amyotrophy)
- thoracic outlet syndrome
- brachial plexitis/neuritis (e.g. herpes zoster)
- amyotrophic lateral sclerosis
- tumors (e.g. Pancoast tumors)
- coronary heart disease

Differential diagnosis can almost always be excluded by a thorough exam and neurophysiological studies

These differential diagnoses can be excluded in the vast majority of cases by a thorough clinical neurological and neurophysiological assessment (see Chapters 11, 12).

## Non-operative Treatment

The spectrum of symptoms in degenerative cervical disorders ranges from benign self-limiting non-specific neck pain to severe pain states with progressive tetraparesis as seen in CSM. Accordingly, the treatment decision is critically dependent on the underlying pathology. In general, the goals of treatment are (Table 5):

**Table 5.** General objectives of treatment

| | |
|---|---|
| • relieve pain | • prevent neurological deterioration |
| • improve functional limitations | • reverse or improve neurological deficits |

The choice of treatment is closely dependent on the natural history. Its knowledge is important when consulting patients on the most appropriate treatment. The expected outcome of treatment has to be weighed against the risks and benefits in the light of the natural history.

## Natural History

### Neck Pain

Neck pain frequently recurs and becomes moderate to severe in about one-third of cases

Most cases of non-specific acute neck pain resolve within a few days or weeks after onset [291]. The natural history of neck pain is not well explored since patients with persistent pain receive non-operative care. However, a large epidemiologic study on 1 100 Saskatchewan adults revealed that among subjects with prevalent neck pain at baseline, 37 % report persistent problems and 9.9 % experience an aggravation during follow-up. Twenty-three percent of those patients with prevalent neck pain at baseline report a recurrent episode. The annual incidence of disabling neck pain is 6 %. Cote et al. concluded that in contrast to prior belief, most individuals with neck pain do not experience complete resolution of their symptoms and disability [66]. In a 10-year follow-up study on 205 patients, Gore et al. [103] observed that 79 % had a decrease in pain, and 43 % were free of pain. However, 32 % continued to have moderate or severe residual pain. Patients injured and initially suffering from severe pain are the most likely to have an unsatisfactory outcome. The presence or severity of pain, however, was not related to the presence of degenerative changes, the sagittal diameter of the spinal canal, or the degree of cervical lordosis [103].

Morphological alterations are not closely correlated with symptoms

### Cervical Disc Herniation and Radiculopathy

The natural history of CSR is benign

Mochida et al. [177] analyzed the **spontaneous resorption** of cervical disc herniation, using MRI. The authors found that in about one-third of the patients, the size of the herniated material decreases with time. Patients with disc migration showed more regression than patients with protrusions. Herniated soft discs seem to be the only static compression factor that disappears spontaneously. But this is undermined by case reports [277]. Knowledge of the natural history of radiculopathy is very sparse [45]. In an epidemiological survey of cervical radiculopathy in Rochester, 90 % of 561 patients were asymptomatic or only mildly incapacitated due to cervical radiculopathy at an average follow-up of 5 years [222].

### Cervical Myelopathy

Spinal canal diameter is the most critical risk factor of CSM

The developmental **spinal canal size** is one of the most critical risk factors predisposing to CSM. Humphreys et al. [130] demonstrated that foraminal heights, widths, and areas were larger in asymptomatic patients than in symptomatic patients. One of the first reports on the natural history of CSM was provided by Clark and Robinson [58]. The authors reported that once the disorder was diagnosed, complete remission to normality never occurred, and spontaneous remission to normality was uncommon. In 75 % of the patients, episodic worsening with neurological deterioration occurred, 20 % had slow steady progression, whereas 5 % had rapid onset progression. Lees and Turner [166] reported that there is a progression of neurological deterioration, but the course is not predictable. The natural history of cervical myelopathy has a **variable clinical course** with long periods of stable disability which can be followed by a few progressively deteriorating courses [73, 223]. In a study by Symon and Lavender [264], two-

thirds of the patients exhibited a linear rather than an episodic progression course. Philipps [217] observed an improvement in 50 % of patients with symptoms for less than 1 year and in 40 % of patients with symptoms for between 1 and 2 years, whereas in patients with symptoms for more than 2 years no improvement could be determined. Yonenobu [297] reported that a **minor trauma** can significantly alter the natural history of OPLL. In a study by the Japanese investigation committee on OPLL, 21 % of patients experienced acute deterioration of neurological symptoms on occasion of a trivial trauma such as slipping [297]. In a small series with a short follow-up, Kadanka et al. [142] found that patients with no, or very slow, insidious progression and a relatively long duration of symptoms have a favorable course no better or worse than surgery.

The natural history of CSM is poorly predictable in the individual patient

Twenty years ago, Henry LaRocca [164] outlined that the determinants of the clinical course are not well enough known to forecast the likely course in a newly presenting patient. This statement is still valid today.

## Conservative Treatment Modalities

The scientific evidence for most treatment modalities is poor

Non-specific neck pain and spondylosis related neck pain are best managed with non-operative treatment because a clear structural correlate which could be addressed by surgery is missing. In cases with radiculopathy, an initial trial of non-operative care is strongly recommended in the absence of relevant motor deficits (MRC Grade > 3). Anecdotally, soft disc herniations respond more favorably to conservative care than CSR [234]. However, the indication for surgery should be prompted after failure of an adequate trial of a non-operative approach [234]. Non-surgical treatment is only indicated in mild forms of CSM, but in cases with circumferential spinal cord compression deterioration under conservative care must be expected [251]. For many treatment modalities, insufficient scientific data is available to allow for evidence-based treatment guidelines [5, 106].

### *Oral Medications*

Drug treatment for neck pain disorders consists of:

- analgesics
- NSAIDs
- muscle relaxants
- psychotropic drugs

In contrast to the lumbar spine, oral medications commonly used in clinical practice (e.g. NSAIDs, tricyclic antidepressants, neuroleptic agents and opioid analgesics) lack evidence of clinical effectiveness for mechanical neck pain [175, 208]. No comprehensive analyses are available for acute neck and radicular arm pain [175].

### *Cervical Collar*

The treatment effect of cervical collars is unproven

In acute neck pain episodes, **no benefit of cervical collars** over “act-as-usual” or active mobilization was observed [154]. On the other hand, collar treatment was no better or worse than alternative treatments for radiculopathy (i.e. physiotherapy or surgery) [211, 212]. No evidence-based recommendations can be provided for the use of cervical collars.

### *Manipulative Therapy*

Manipulative therapy remains a **mainstay of conservative treatment** for degenerative disorders of the cervical spine. Particularly, traction has been reported to result in short-term relief of radiculopathy [60, 61, 197]. Debate continues on the safety of manipulative therapy of the cervical spine. Based on a national survey of 19 122 patients, minor side effects (headache, fainting/dizziness, numbness/tingling) were not uncommon up to 7 days after the intervention, with an incidence rate ranging from 4 to 15/1 000. Serious adverse events (leading to in-hospital treatment or permanent disability) were very rare (1/10 000). However, this does not rule out a deleterious course in individual patients (Case Introduction). Rubinstein et al. [230] concluded that the benefits of chiropractic care for neck pain seem to outweigh the potential risks. There is moderate evidence that **spinal manipulative therapy** (SMT) and mobilization is superior to general practitioner management for short-term pain reduction of **chronic neck pain**. However, SMT offers at most similar pain relief to high-technology rehabilitative exercise in the short and long term. In a mix of acute and chronic neck pain, there is moderate evidence that mobilization is superior to physical therapy and family physician care [41]. There are only a few studies on acute neck pain and the evidence is currently inconclusive [41].

There is moderate evidence for the effectiveness of manipulative treatment

### *Physical Exercises*

There is **moderate evidence** supporting the effectiveness of both long-term dynamic as well as isometric resistance exercises of the neck and shoulder musculature for chronic or frequent neck disorders. No evidence supports the long-term effectiveness of postural and proprioceptive exercises or other very low intensity exercises [106, 296].

Moderate evidence supports physiotherapy for chronic neck pain

### *Multidisciplinary Rehabilitation Programs*

In contrast to the lumbar spine, there appears to be little scientific evidence so far for the effectiveness on neck and shoulder pain of multidisciplinary rehabilitation programs compared with other rehabilitation methods [145]. However, this conclusion is due to the low quality of available clinical trials [145].

### *Massage*

No clinical practice recommendations can be made for the effectiveness of massage for neck pain [115].

### *Spinal Injections*

Anecdotally, transforaminal injections with epidural steroid application can result in instant pain relief in patients suffering from cervical radiculopathy [70, 163, 262], although injection of local anesthetic appears to have similar effects [8]. However, recent articles have prompted major concerns over the safety of **transforminal steroid injections** because of cases with subsequent deleterious spinal cord injuries [120, 181, 245]. For chronic neck pain, intramuscular injection of lidocaine was superior to placebo or dry needling at short-term follow-up, but similar to ultrasound. There is limited evidence of effectiveness of epidural injection of methylprednisolone and lidocaine for chronic neck pain with radicular symptoms [208].

Transforaminal injections can results in serious complications

### *Radiofrequency Denervation*

The treatment effect of radiofrequency denervation is unproven

Although some studies reported satisfactory results [170, 253], there is limited evidence that radiofrequency denervation offers short-term relief for chronic neck pain of **zygapophysial joint origin** and for chronic cervicobrachial pain [188].

### *Acupuncture*

The evidence for acupuncture is considered **inconclusive** and difficult to interpret [27].

### *Electrotherapy*

The systematic review by Kroeling et al. [158] could not make any definitive conclusions about electrotherapy for neck pain. The present evidence on galvanic current (direct or pulsed), iontophoresis, electromuscle stimulation (EMS), transcutaneous electrical nerve stimulation (TENS), pulsed electromagnetic field (PEMF) and permanent magnets is either lacking, limited, or conflicting.

### *Infrared Laser Therapy*

The review by Chow et al. [55] provided limited evidence from one randomized controlled trial (RCT) for the use of infrared laser for the treatment of acute neck pain and chronic neck pain from four RCTs.

## Operative Treatment

### General Principles

Degenerative disorders of the cervical spine are a heterogeneous group of pathologies with a wide spectrum of treatment modalities. For the vast majority of clinical entities, surgery is only indicated after an adequate trial of non-operative treatment has failed. As outlined in the preceding paragraph, the scientific evidence for the effectiveness of many conservative measures is very limited. Similarly, the **evidence is limited** for the surgical treatment options. While surgery for chronic neck pain is not broadly supported, it appears that patients with CSR and CSM benefit from surgery after non-operative care has failed [86, 297]. Indications for surgery for CSR and CSM include (Table 6):

**Table 6.** Indications for surgery

| Cervical spondylotic radiculopathy | Cervical spondylotic myelopathy |
|---|---|
| • progressive, functionally important motor deficit<br>• definitive evidence for nerve root compression<br>• concordant symptoms and signs of radiculopathy<br>• persistent pain despite non-surgical treatment for at least 6–12 weeks | • progressive myelopathy despite non-operative care<br>• acute onset, deterioration or progression of neurological deficits<br>• definitive evidence of spinal cord compression with moderate-to-severe myelopathic symptoms<br>• progressive kyphosis with neurological deficits |

The goal of CSM treatment primarily is to arrest progression

Surgery for cervical radiculopathy is generally recommended when all of the aforementioned criteria are present [45]. The primary goal of surgery in CSM is the **prevention of further progression** of the neurological symptoms because improvement of established myelopathic changes is rare [164, 166]. One of the most important aspects in dealing with CSM is to inform the patients preopera-

tively that the goal of surgery is primarily to arrest progression of the disease. Patients are frequently disappointed by the results of surgery when neurological recovery is lacking although the vast majority of patients do show improvements [76, 127, 225, 294]. It is therefore reasonable to extensively inform patients about the goals and realistic expectations of surgery.

## Surgical Techniques

There is an ongoing debate on the approach to deal with disc herniation related radiculopathy, CSR or CSM, i.e.:

- anterior approach
- posterior approach

Each technique has its advantages and drawbacks. The **controversy** which of the two approaches is better cannot be generalized but must always be related to the target pathology. It is important to recognize whether the compressing structure is anterior or posterior to the neural structures. The pathology should be treated where it is. Thus, an anterior neural compression is better removed from anterior and a multisegmental posterior compression from a posterior approach. In cases with three or more level stenosis, a posterior approach is preferred unless there is no coexisting substantial anterior compression.

The pathology should be treated where it is

### Anterior Cervical Discectomy and Fusion

In 1955, **Robinson and Smith** [229] reported on a technique for removal of cervical disc and fusion with a horseshoe-shaped graft which later became the **gold standard** for the treatment of disc herniations and cervical spondylotic radiculopathy [260]. **Cloward** [62] developed a similar anterior approach, i.e. drilling a hole in the intervertebral disc space and adjacent vertebrae to insert a bone dowel. In contrast to the Robinson-Smith technique, Cloward removed the compressing structures at the level of the posterior longitudinal ligament. Robinson and Smith [229] did not decompress the neural structures, but believed that by immobilizing the segment osteophytes and herniated disc would be reabsorbed. In the following years many variations of this technique were developed [12, 35, 37, 77, 99, 258]. **Anterior cervical discectomy and fusion** (ACDF) with a tricortical bone graft harvested from the iliac crest is the most widely used technique and has become the gold standard for the treatment of cervical radiculopathy (Case Introduction).

Anterior cervical discectomy and fusion remains the gold standard for CSR

The radiological **fusion rate** is dependent on the amount of levels to be fused. Bohlmann et al. [33] reported a solid fusion for one, two and multilevel fusions of 89 %, 73 % and 67 %, respectively. Cauthen et al. [49] analyzed the outcome of anterior cervical discectomy and interbody fusion (Cloward technique) in 348 patients with an average follow-up of 5 years. The fusion rate was 88 % for one level and 75 % for multilevel fusions. Emery et al. [78] reported a fusion rate of only 56 % for three-level fusions.

Fusion rates are dependent on the number of levels treated

Clinical outcome of ACDF for cervical radiculopathy is good to excellent in 70 – 90 % of patients [223] and mainly dependent on the **decompression** of the **compromised nerve root** [45]. However, Bohlmann et al. have reported a significant association between the presence of non-union and postoperative neck or arm pain [33].

The surgical outcome is mainly dependent on the decompression effect

### *Autograft Versus Allograft*

Autograft is superior to allograft for ACDF

The use of allograft for spinal fusion in conjunction with anterior decompression for degenerative cervical disorders has a long tradition. Cloward [62, 63] used allografts from the 1950s. However, there are only a few studies [7, 28, 42, 303] comparing allografts versus autografts which were analyzed in a meta-analysis [83]. Floyd and Ohnmeiss [83] concluded from their meta-analysis that for both one- and two-level anterior cervical discectomy and fusion, autograft demonstrated a higher rate of radiographic union and a lower incidence of graft collapse. However, it was not possible to ascertain whether autograft is clinically superior to allograft. The authors advised that the decision of the bone graft should not be solely based on the radiographic results but that additionally donor site morbidity, transmission of infectious disease, quality of the autograft (osteoporosis) and patient preference must be taken into consideration [83].

### *Plate Fixation*

The conventional fusion techniques were not universally successful. Complications causing persistent pain included [10, 33, 69, 78, 102, 228, 287, 288, 292, 304]:

- non-union (particularly for multilevel fusions)
- graft displacement
- graft collapse
- sagittal malalignment (kyphosis)

For traumatic cervical lesions, **anterior plate fixation** gained widespread acceptance because it provides immediate stability and high fusion rates [4, 31, 46]. Similarly, instrumented fusion was introduced for degenerative cervical disorders [156, 247, 279]. Additional plating theoretically increases the fusion rate, preserves cervical lordosis, and prevents graft subsidence and migration particularly when two or more levels are involved [247].

Plate fixation increases the fusion rate for multilevel fusions

However, three RCTs failed to demonstrate the superiority of additional plate fixation for one-level fusions in terms of clinical or radiological outcome [105, 244, 309]. For **multilevel fusion**, there is some evidence that plating appears to result in higher fusion rates [47, 94, 146, 280, 281].

Anterior plate fixation does not suffice for three-level fusions

Wang et al. [281] indicated that a **three-level fusion** is still associated with a high non-union rate (18%), although the use of cervical plates decreased the pseudarthrosis rate. Bolesta reported that three- and four-level modified Robinson cervical discectomy and fusion results in an unacceptably high rate of pseudarthrosis which is not improved by a cervical spine plate alone [34]. Additional posterior fixation is advocated in three and more level fusion to decrease the non-union rate [180] (Case Study 1).

### *Fusion with Cages*

Bone graft donor site pain remains a drawback of ACDF

One drawback of the conventional fusion (Smith-Robinson or Cloward) techniques could not be overcome by plating, i.e. bone graft donor side pain. Persistent pain from the anterior iliac crest is reported in up to 31% of patients [110]. During the last decade, cages have become increasingly popular in stabilizing and fusing the cervical spine subsequent to anterior discectomy. Compared to conventional fusion techniques, the **theoretical advantages** of cages are to:

- restore disc height
- restore cervical lordosis
- prevent graft collapse

## Case Study 1

A 47-year-old male had experienced some numbness, clumsiness and tingling in his hands for over 1 year before he suddenly developed gait disturbance and weakness in both legs. The patient was admitted to the Neurology Department for further diagnostic work-up. Clinically, the patient presented with an incomplete tetraparesis sub C4. A lateral radiograph (a) demonstrates a congenitally narrow spinal canal with cervical spondylosis particularly at the levels C5/6 and C6/7 and decrease of cervical lordosis. Sagittal T2W image (b) demonstrating a large disc herniation at C4/5 with compression of the spinal cord, advanced disc degeneration with endplate changes (Modic Type II), signal intensity changes within the spinal cord at C5/6, and a disc protrusion with spinal cord compression at C6/7. Axial T2W images confirm the severe myelon compression at the levels of C4/5 (c) and C6/7 (d). The patient underwent multilevel anterior cervical discectomy and fusion with a tricortical iliac bone graft and anterior plating. In a second operation, the patient underwent posterior laminectomy and instrumented fusion to completely decompress the narrow spinal canal and spinal cord (e, f). Postoperatively, the patient substantially improved with regard to his neurological function but a residual tetraparesis remained at latest follow-up.

- avoid donor site pain
- reduce operative time

Many different **cage designs** (e.g. cylindrical, mesh, ring or box shaped) and **materials** (e.g. titanium, carbon, polyetheretherketone, hydroxyapatite coated)

have been introduced [54, 110, 144, 216, 221, 271]. Debate continues on the fact of the **cage filling** with bone (autograft or allograft), bone graft substitutes or void and favorable clinical results have been reported with each technique [53, 132, 157, 168, 203, 233, 248].

Cage fusions are not better than conventional ACDF

Randomized studies have so far not been able to reveal a significantly better clinical outcome of patients undergoing cage fusion compared to conventional techniques [111, 210, 233, 273] although the rate of non-union appears to be higher and bone graft donor site pain lower [273].

### Anterior Corpectomy

In patients suffering from CSM, anterior discectomy and osteophyectomy may not suffice to sufficiently decompress the spinal cord. The spinal cord may not only be compromised by disc protrusions and spondylophytes but also by a spinal malalignment (kyphosis) or a narrow spinal canal. In these cases, a subtotal **corpectomy** is required [236]. Partial vertebral body resection and decompression was first used to treat traumatic cervical disorders [91] and later adopted for degenerative disorders [114, 236].

Compared to ACDF, a **median corpectomy** offers the advantage of:

- enlarging the spinal canal
- allowing for a more radical decompression
- increasing the fusion rate

Corpectomy allows for better decompression and a high fusion rate

A variety of techniques were developed to stabilize the cervical spine after decompression through vertebrectomy [21, 35, 113, 116, 298]. The extent to which decompression should be performed depends on the pathology and the size of the spinal canal [125, 295]. Most authors [143] advocate the complete removal of the posterior osteophytes and PLL to achieve maximum decompression (Fig. 5). Compared to multilevel ACDF, corpectomy offers the advantage of reducing the **host-graft interfaces**. Swank et al. [263] have shown that the non-union rate of two-level ACDF was 36 % while one-level corpectomy resulted in a non-union rate of 10 % (Case Study 2). Similar results were obtained by Hilibrand et al. [125], who reported a non-union rate of 34 % for ACDF (one to four levels) and 7 % for corpectomy.

**One-level corpectomies** are best reconstructed using iliac crest autograft. The angulation of the iliac crest limits its applicability for longer anterior reconstructions. Therefore, **fibula strut allografts** have been used with satisfactory results [263]. However, the fusion rate of allograft fibula is somewhat lower than with autograft [100, 263]. This limitation can be overcome with additional posterior instrumented fusion [180]. Recently, **cages** constructs have been used for long anterior column reconstructions [56, 187, 261, 268, 293]. The drawbacks of cage buttressing for anterior cervical reconstructions include subsidence, limited assessment of fusion status, and difficult revision surgery because of frequent partial incorporation [180].

Three-level corpectomies necessitate anterior-posterior fixation

**Anterior plating** currently is recommended to increase fusion rate and decrease the incidence of graft dislocation [153]. However, the ability of plate fixation to stabilize a three-level corpectomy is limited [136, 242, 270] and additional posterior stabilization is recommended to circumvent implant failure and non-union [73, 93, 162, 226].

### Anterior Discectomy Without Fusion

A drawback of the classic Robinson-Smith technique is that the intervertebral disc is removed to reach the location of the neural compromise. Attempts have

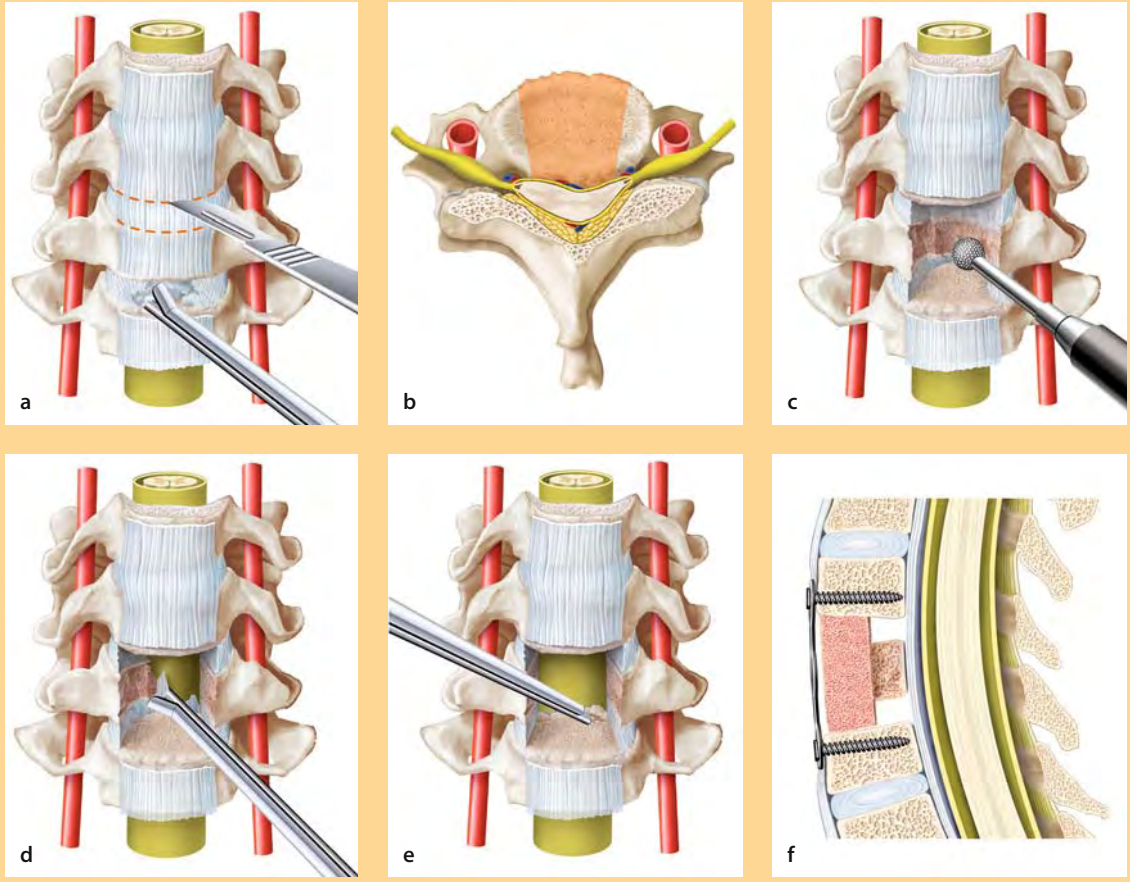


**Figure 5. Technique of corpectomy and instrumented fusion**

The cervical spine is exposed by an anteromedial approach. **a** The intervertebral discs are excised adjacent to the target level. **b** The medial three-thirds of the vertebral body are resected. The lateral wall is preserved to protect the vertebral arteries. **c** A high-speed diamond burr is used to remove the median part of the vertebral body. **d** The remaining part of the posterior vertebral wall is elevated away from the spinal cord and resected with a Kerrison rongeur. **e** Kerrison rongeur and curettes are used to remove posterior osteophytes and decompress spinal cord and exiting nerve roots. **f** The spine is reconstructed by insertion of a tricortical iliac bone block and anterior plating.

therefore been made to remove the disc herniation without completely resecting the intervertebral disc. **Indications** of this technique are:

- soft disc herniation
- disc sequestration
- young individual
- no spondylosis
- no segmental instability

Retrospective case series did not report a clinical outcome inferior to discectomy and fusion [24, 25, 183, 192, 219, 220]. The **disadvantages** of this method, however, were:

- recurrent herniation
- motion segment degeneration
- segmental instability
- chronic neck pain
- spontaneous fusion

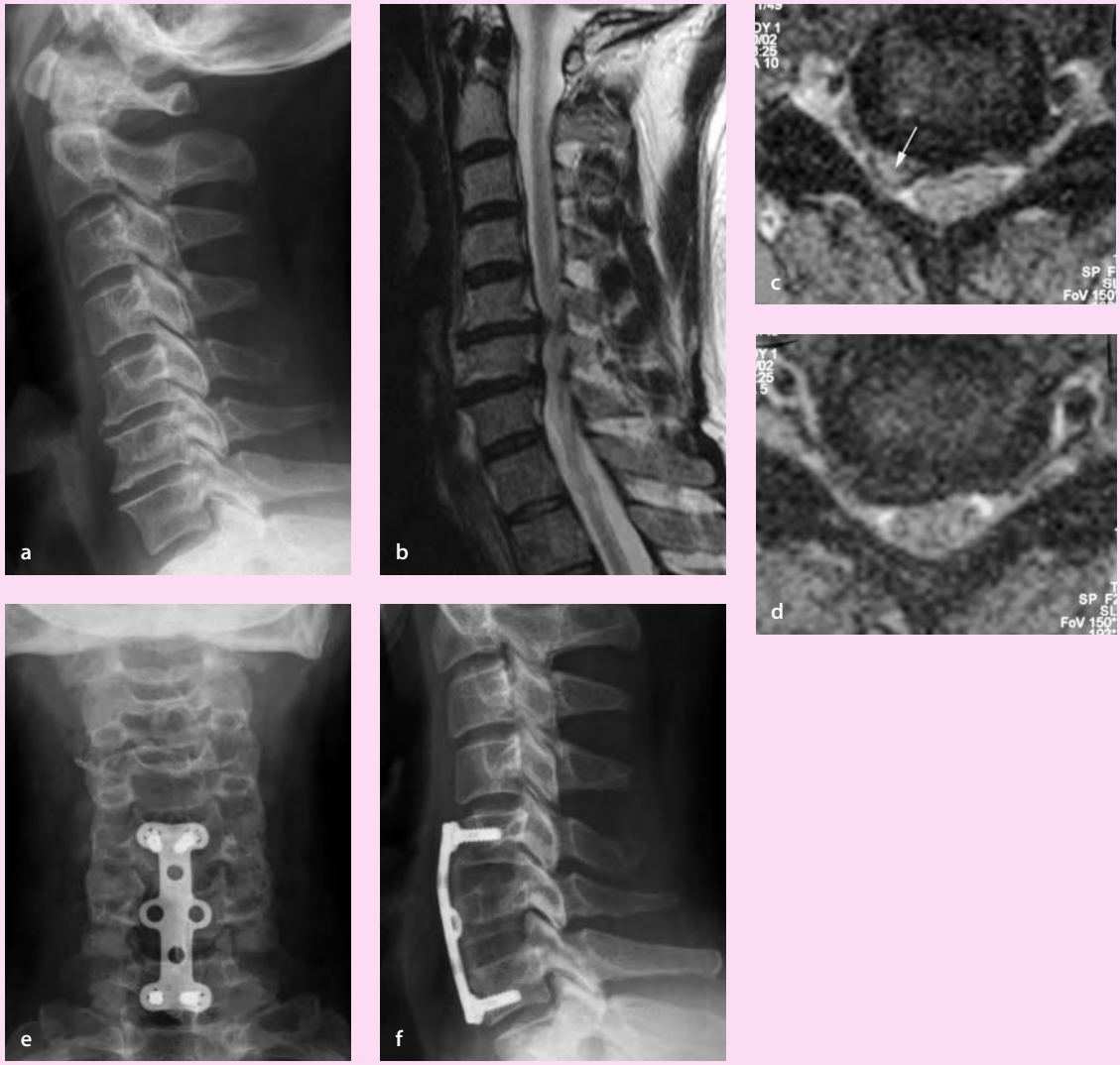


## Case Study 2

A 56-year-old male had recurrent episodes of neck pain with occasional radiating pain to his right forearm for 18 months before he developed acute onset excruciating arm pain followed by a progressive sensorimotor deficit of C6 on the right side. Lateral radiograph (a) showing cervical spondylosis at the level of C5/6 and C6/7. Sagittal T2W image (b) reveals cervical spondylosis and disc protrusions at C5/6 and C6/7. Axial T2W image shows a sequestrated disc herniation at C5/6 (*arrow*) with compression of the exiting nerve root C6 (c) and a disc protrusion at C6/7 with compromise of the C7 nerve root (d). The indication for surgery was prompted by the progression of the paresis. The patient underwent a corporectomy of C6, decompression of the C6 and C7 nerve root, reconstruction with a tricortical iliac bone block and anterior plating (e, f). At 1 year follow-up, the sensorimotor deficit had completely recovered. The patient was fully functional but occasionally had some episodes of benign neck pain.

Outcome of discectomy without fusion is not inferior to that of ACDF

In a prospective randomized study on 91 patients with single-level cervical root compression, Savolainen et al. [244] analyzed three different treatment groups: discectomy without fusion, fusion with autologous bone graft, and fusion with autologous bone graft plus plating. Clinical outcomes were good for 76 %, 82 %, and 73 % of the patients, respectively. A slight kyphosis developed in 62.5 % of the patients who had undergone discectomy, 40 % of the patients who had undergone fusion, and 44 % of the patients who had undergone fusion plus

plating [244]. This study indicates that discectomy without fusion is not inferior to ACDF.

Techniques were developed to **preserve the intervertebral disc**, which often is not substantially degenerated and can therefore be preserved. Verbiest [274] suggested a lateral approach while Hakuba [112] described a **trans-unco-discal approach**. The latter approach is a combined anterior and lateral approach to the cervical discs. Interbody fusion was not performed except for special cases with significant kyphosis or instability [112]. Minimally invasive techniques were suggested by Jho [140] and Saringer et al. [240], who reported on a **microsurgical anterior foraminotomy** which provides direct anatomical decompression of the compressed nerve root by removing the compressive spondylotic spur or disc fragment. Saringer et al. [241] modified this technique by using an endoscopic approach. Other authors removed the herniated disc under endoscopic view using a transdiscal route [13, 84].

Disc preserving anterior nerve root decompression is feasible

## Total Disc Arthroplasty

**Adjacent segment degeneration** (Fig. 6) has been mentioned as the main argument against spinal fusion and therefore favoring total disc arthroplasty (TDA). However, the data on adjacent segment degeneration is sparse [14, 52, 124, 160]. Hilibrand et al. [124] followed 374 patients who had a total of 409 anterior cervical fusions for a maximum of 20 years. Symptomatic adjacent-segment disease occurred at an incidence of 2.9% per year during the 10 years after operation. About one-fourth of the patients who had an anterior cervical fusion were at risk of developing symptomatic adjacent segment disease within 10 years. A single-level arthrodesis involving C5/6 or C6/7 and preexisting radiographic evidence of degeneration at adjacent levels appeared to be the greatest risk factors for new

Adjacent segment degeneration is the main argument for TDA

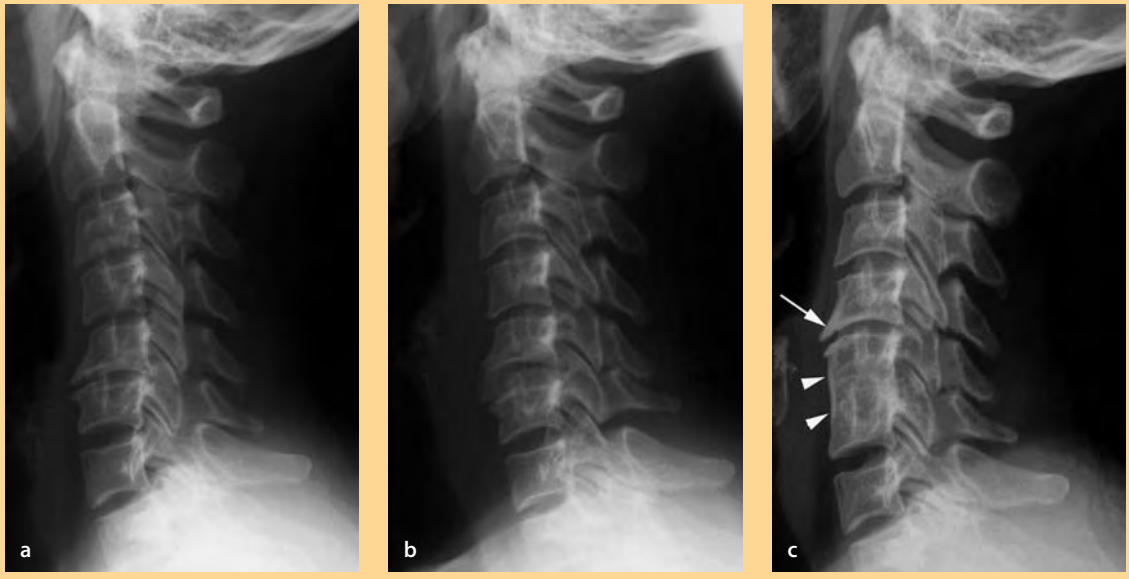


**Figure 6. Adjacent segment degeneration**

a Symptomatic cervical spondylosis at C5/6 with anterior and posterior osteophytes. b Postoperative lateral radiograph after anterior cervical discectomy and fusion with a tricortical iliac bone graft (Robinson-Smith technique). c Lateral radiographs at 6 years follow-up demonstrate a perfect fusion at C5/6 with remodeling of the osseus structures (*arrowheads*). Note the adjacent segment degeneration at C4/5 (*arrow*).

disease [124]. Importantly, no study so far was able to differentiate the effect of natural history versus the effect of the arthrodesis on the development of adjacent segment degeneration [52, 101].

More than 15 **different designs** are now under pre-clinical and clinical evaluation (e.g. Prestige II, Bryan, PCM, ProDisc-C, Cervicore, Discover) [199]. Current TDA designs include one-piece implants and implants with single or double gliding articulations with either metal-on-metal or metal-on-polymer bearing sur-

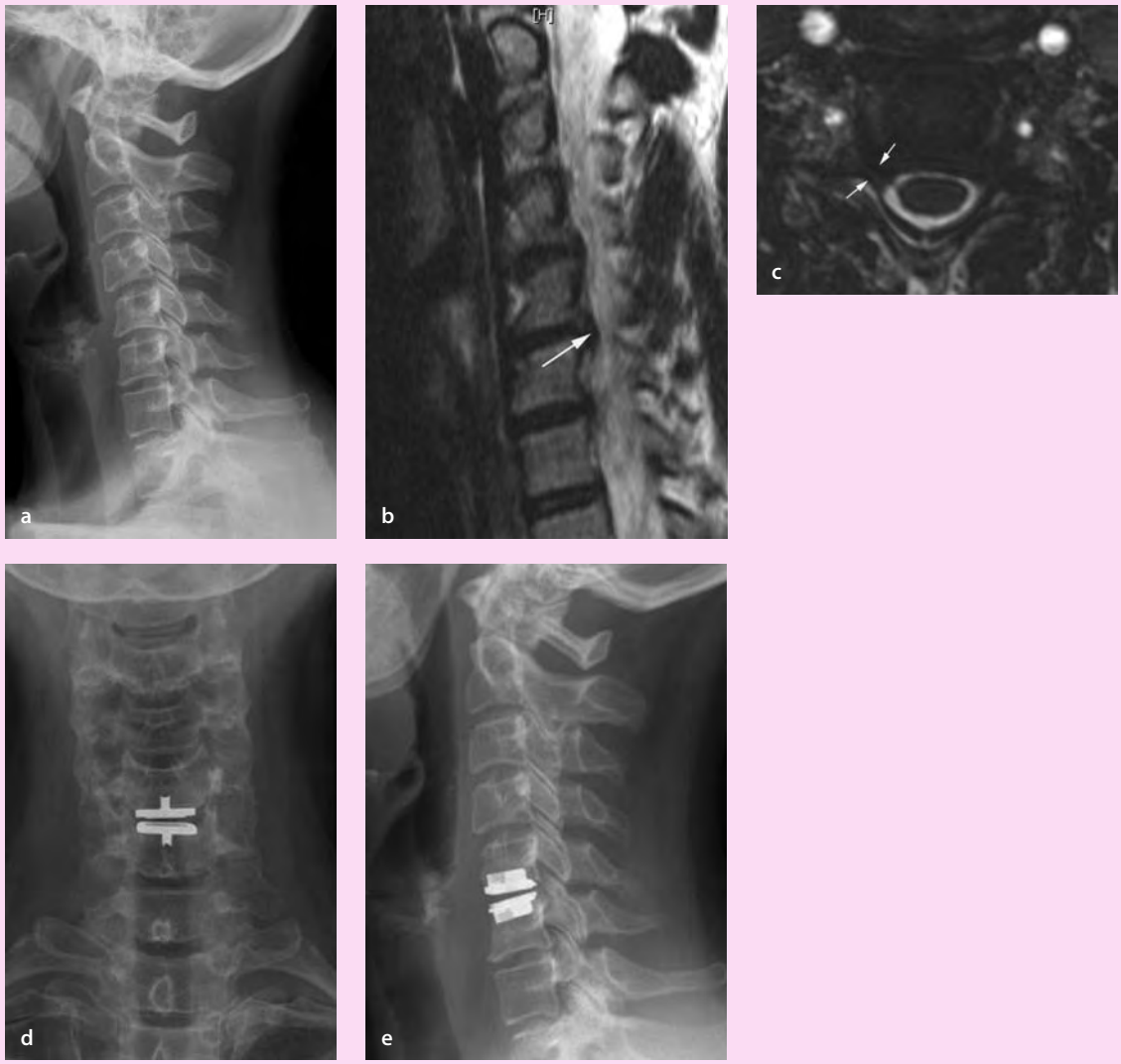


## Case Study 3

A 53-year-old female patient complained of persistent (4 months) right-sided shoulder/arm pain and was referred to our shoulder specialists with suspected impingement syndrome. A thorough physical examination revealed a normal shoulder function but a decreased sensation at the lateral aspect of the radial forearm and thumb as well as weakness in dorsiflexion of the hand. The biceps tendon reflex was diminished on the right. A lateral radiograph (a) showed segmental kyphosis at C4/5 and minimal cervical spondylosis at C5/6 and C6/7. Parasagittal T2W image (b) revealed a lateral disc protrusion at C5/6. Axial T2W image (c) confirms the foraminal disc protrusion with compression of the exiting C6 nerve root. Non-operative therapy (medication, physiotherapy) failed to provide persistent substantial pain relief. A nerve root block (C6) completely alleviated the symptoms for 1 week. Discectomy, nerve root decompression and total disc arthroplasty at C5/6 was carried out (d, e). Immediately after surgery, the patient had complete pain relief and was fully functional 2 weeks after surgery. At the 2-year follow-up, the patient was still completely symptom-free.

faces [218] (Case Study 3). Current indications and contraindications for TDA include [11] (Table 7):

**Table 7.** Indications and contraindications for TDA

| Indications | Contraindications |
|---|---|
| • symptomatic cervical disc disease<br>• one- or two-level involvement (C3–T1)<br>• structural correlate (i.e. herniated nucleus pulposus, cervical spondylosis)<br>• failed conservative therapy of 6 weeks<br>• age between 20 and 70 years<br>• no contraindications | • three vertebral levels requiring treatment<br>• cervical instability (translation > 3 mm and/or > 11° angulational difference)<br>• cervical fusion adjacent to the target level<br>• previous surgery/fracture at target level<br>• known allergy to implant materials<br>• severe spondylosis (bridging osteophytes, disc height loss > 50 %, and absence of motion < 2°, facet joint OA)<br>• axial neck pain as the solitary presenting symptom<br>• systemic and metabolic diseases (AIDS, HIV, hepatitis B or C, insulin-dependent diabetes, infections, obesity, BMI > 40) |

Preliminary outcome data demonstrated that TDA preserves segmental motion [50, 185] in the short term and compares very favorably to ACDF in terms of clinical outcome [23, 179, 184, 243]. However, no convincing data was provided so far that TDA will prevent adjacent segment degeneration [243].

Outcome of TDA is not superior to conventional ACDF techniques

### Posterior Laminectomy

Cervical laminectomy was first performed by Sir Victor Horsley (1857 – 1916) for the treatment of tumor related myelopathy [265]. Laminectomy is a versatile and technically facile approach to decompress the spinal cord [171].

**Indications for laminectomy** are mainly for the management of:

- multilevel cervical myelopathy
- predominant posterior neural compression
- elderly CSM patients with comorbidities
- CSM with preserved cervical lordosis

**In elderly patients** suffering from significant comorbidities and CSM due to multilevel spinal cord compression, laminectomy is a short and effective procedure to arrest or improve neurological deficits. In the presence of kyphosis, however, laminectomy only has a limited effect since the spinal cord cannot migrate posteriorly and move away from osteophytes or discs compressing the spine anteriorly. Good to excellent results have been reported in 56 – 85 % of patients after laminectomy [171]. The lateral extension of laminectomy should not include more than 50 % of the facet joint. The resection greater than 50 % compromises joint strength significantly and can lead to segmental instability and kyphosis. In multilevel laminectomy, even 25 % resection of the facet can reduce cervical stability considerably and require fusion [189].

Laminectomy provides favorable results in selected cases

#### *Laminectomy and Instrumented Fusion*

The main drawbacks of laminectomies are **progressive postoperative deformity** and instability, which may subsequently lead to neurological deterioration [109, 135, 257, 299]. These limitations can be overcome by additional instrumented fusion. Most commonly **lateral mass screw fixation** is used allowing for a good biomechanical stability of the decompressed segments and a high rate of solid fusion [71, 121]. The technique of screw insertion is reviewed in Chapter 13. With proper technique the risk of complications (vertebral artery or nerve root

Instrumented fusion prevents postoperative deformity and instability

injury) is minimal [71, 79, 121]. **Pedicle cervical screw fixation** (see Chapter 13) is an alternative but is rarely needed in degenerative disorders with good bone quality [1, 2]. For cases in which correction of a kyphotic deformity is attempted, pedicle screw fixation is advisable for better bony purchase [3].

### Posterior Foraminotomy

Posterior foraminotomy remains a valid treatment alternative for CSR

A posterior foraminotomy for the treatment of cervical nerve root compression was first described by **Frykholm** [88] (Fig. 7) and subsequently by Scoville [249] and Murphey [182]. Despite favorable results [122, 305], this approach fell out of favor because of the limitations of treating anterior neural compression of

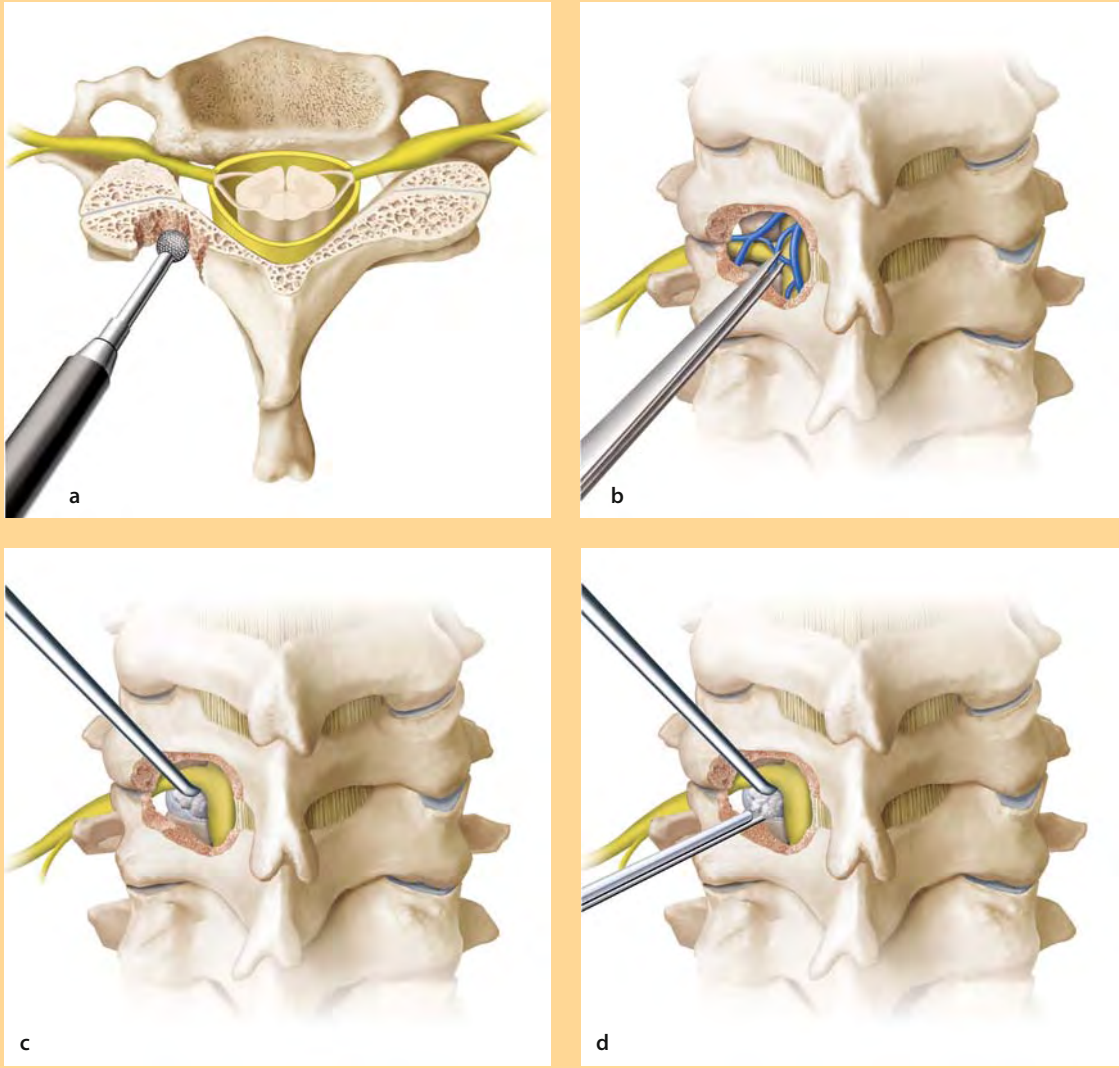


**Figure 7. Technique of posterior foraminotomy (Frykholm)**

The spine is exposed by a unilateral posterior approach. Tubular retractors allow collateral damage to the neck muscles to be minimized. **a** A high-speed diamond burr is used to create a keyhole laminotomy exposing the exiting nerve root. **b** After resection of the ligamentum flavum, epidural veins may become visible which may require coagulation (low-energy bipolar). **c** The exiting nerve root can gently be lifted cranially to expose the underlying pathology (disc herniation, spur). **d** The disc herniation or spur can be removed with a rongeur or curette.

median pathology. Many surgeons therefore prefer the anterior approach with discectomy and osteophytectomy in conjunction with interbody fusion. However, posterior foraminotomy remains a valid option in cases with CSR predominantly caused by lateral recess stenosis and lateral disc herniations [159, 161]. The muscles of the neck are rich in proprioceptors that send afferents directly to the vestibular and optical neurons controlling head position on the trunk [148, 213]. This can be the major cause of postoperative persistent neck pain. Recently, **minimally invasive procedures** were introduced to minimize the trauma to the neck muscles avoiding detachment of the extensor cervical muscles from the lamina and spinous process [82]. Burke and Caputy [43] reported on a microendoscopic technique through a transmuscular access with only separation and dilatation of the muscles. Boehm et al. [30] used a working channel of an outer diameter of 11 mm to expose the interlaminar-facet region and reported favorable results with this technique. Clarke et al. [59] have shown that posterior foraminotomy is associated with a low rate of same- and adjacent-segment disease.

Access technology makes the posterior approach appealing

### Laminoplasty

The potential destabilization, sagittal malalignment (kyphosis) and the lack of spinal cord protection subsequent to multilevel cervical laminectomy led Japanese surgeons to develop cervical laminoplasty techniques [127]. Accordingly, the **general advantages** of laminoplasty are to [297]:

- expand the spinal canal
- secure spinal cord protection
- maintain spinal stability
- preserve spinal mobility
- decrease the risk of adjacent segment degeneration

Hirabayashi introduced a new surgical technique called "**expansive open-door laminoplasty**" which is still widely used today [126–128]. As an alternative, the "**French open-door laminoplasty**" was introduced by Hoshi and Kurokawa [129]. Although numerous surgical modifications [117, 137, 147, 165, 174] have been suggested, the basic concept of most of the procedures is similar to one of these two techniques (Fig. 8).

Laminoplasty has predominantly been developed to treat OPLL

A **recent critical review** concluded that the literature has yet to support the purported benefits of laminoplasty [225]. Ratcliff and Cooper [225] concluded that neurological outcome and change in spinal alignment appear to be similar after laminectomy and laminoplasty. Patients treated with laminoplasty appear to develop progressive **limitation of cervical range of motion** (ROM) similar to that seen after laminectomy and fusion. However, data is lacking on the role of laminoplasty in young individuals with cervical myelopathy due to a congenitally narrow spinal canal and where multilevel decompression and instrumented fusion is not a favorable alternative.

The benefits of laminoplasty are not well supported

## Surgical Decision-Making

When considering surgery to treat degenerative cervical disorders, the **surgical strategy** must be based on patient as well as morphological factors (Table 8).

Radiographic alterations are common in asymptomatic patients [29]. The most important factor in patient selection therefore is that clinical and morphological findings must match to obtain a satisfactory outcome. Innumerable articles cover the outcome of surgical treatment for degenerative cervical disorders. Almost all articles cover technical aspects, and safety and early clinical results

The fundamental question remains "when to operate and when not to"

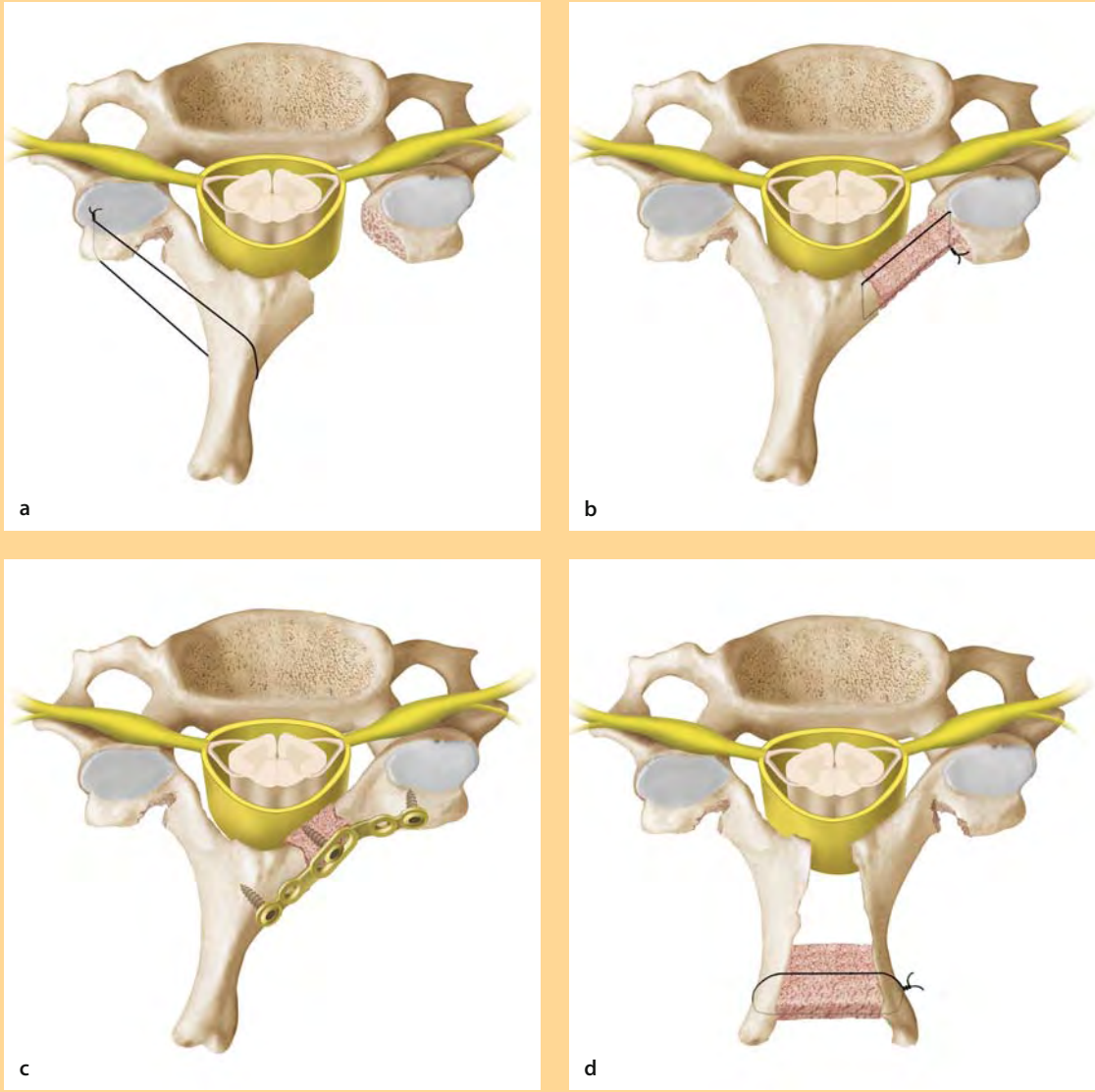


**Figure 8. Laminoplasty techniques**

a Expansive open-door laminoplasty according to Hirabayashi [127]. The opened lamina is fixed with a suture through the inferior articular process. b Hemilateral open-door laminoplasty with interposition of a bone graft and fixation according to Itoh [137]. c Alternative fixation with an AO small fragment reconstruction plate. d French open-door laminoplasty according to Hoshi and Kurokawa [129]. Intraspinous insertion of a bone block and fixation with a suture or cerclage wire.

**Table 8.** Decision factors for surgical strategy

| Clinical factors | Morphological factors |
|---|---|
| • predominant symptoms (neck pain vs. arm pain) | • presence of neural compression |
| • presence of radicular symptoms | • extent and localization of neural compression |
| • presence of myelopathic symptoms | • soft vs. hard compression |
| • severity and duration of symptoms | • segmental instability |
| • onset of symptoms (acute, insidious) | • spinal deformity (kyphosis) |
| • age | • number of levels involved |
| • general patient condition | • spinal canal width |
| • comorbidities | • spinal cord MR signal changes |

without adequate control groups. Many of the anecdotal studies incorporated a whole variety of indications, which limits conclusions on degenerative cervical disorders. However, when the scientific literature is reduced to **Level A recommendations** (i.e. consistent evidence in multiple high-quality RCTs, Level I evidence), only very few RCTs can be identified. The fundamental question regarding treatment option is always related to the choice between surgery and non-operative care. However, the literature is equally sparse on such comparisons. These findings greatly limit treatment recommendations. In this section, we therefore try to provide as best evidence-enhanced rather than evidence-based treatment recommendations and the reader should acknowledge this limitation.

### Neck Pain

Scientific evidence for the effectiveness of neck pain surgery is poor

Axial neck pain is **multifactorial** and often lacking a structural correlate which can be treated by surgery. Therefore, surgery for neck pain is rarely indicated [15, 223, 291].

However, a certain subset of these patients present with atypical radicular pain particularly when upper nerve roots are involved and may benefit from surgery. In this setting, compression of the C4 nerve root has been recognized as a source of neck pain which was successfully treated by surgery [139].

In patients with severe, disabling neck pain who failed an adequate trial of conservative care, the indication for surgery can be explored by using detailed imaging and injection studies [223]. However, the identification of the pain source and painful levels (e.g. by discography or facet joint blocks) remains challenging and often unreliable [64, 107, 150, 200, 256]. Treatment of axial neck pain by fusion is only supported by a few cohort studies [65, 92, 138, 200, 224, 290, 307]. Of note, neck pain alone as the presenting symptom is listed as one of the current contraindications for TDA [11].

Rarely, patients present with severe osteoarthritis at the craniocervical junction (Fig. 2d), which may necessitate fusion. In selected cases, fusion can result in a significant improvement [284].

### Cervical Radiculopathy

Conservative care compares favorably to surgery for CSR

Only one study so far systematically compared non-operative treatment and surgery for radiculopathy [86]. In the prospective study by Persson et al. [211, 212], 81 patients were included who presented with cervicobrachial pain of at least 3 months duration due to spondylotic encroachment with or without an additional bulging disc. The patients were divided into three treatment arms, i.e. surgery (Cloward technique), individually adapted physiotherapy or cervical collar. Pain intensity, muscle weakness and sensory loss can be expected to improve within a few months after surgery. Although a short-term benefit for the surgically treated patients was noted, there was no difference in visual analogue scale, Sickness Impact Profile, and Mood Adjective Check List measurements among the groups at 1 year follow-up. The authors concluded that cervical collar, physiotherapy, or surgery are equally effective in the treatment of patients with long-lasting cervical radicular pain.

ACDF remains the gold standard for treatment of CSR

In some patients, however, radicular symptoms are so severe or persistent despite non-operative care that they opt for a surgical solution. Regarding the current literature, ACDF still remains the gold standard for surgical treatment [45].

There is no evidence that **additional anterior plate fixation** influences clinical outcome for one-level disease [105, 244, 309] and limited evidence that anterior plating increases the fusion rate for two-level disease [47, 94, 146, 280, 281]. The

Cage fusion and TDA are superior to ACDF only regarding donor site pain

evidence for the superiority of **cage fusions** [111, 210, 233, 273] or **TDA** [23, 179, 184, 243] compared to ACDF is lacking except in terms of iliac crest donor site pain. Particularly, the superiority of TDA in terms of adjacent segment degeneration studies remains unproven.

**Minimally invasive decompressions** (anterior or posterior) for the treatment of selected radiculopathy patients [30, 43, 140, 240, 241] remain intriguing because they preserve segmental motion and do not require instrumentation (potential cost-effectiveness). But, so far, scientific evidence is lacking for their role in the treatment of cervical radiculopathy.

Treatment outcome is primarily dependent on nerve root decompression

In general, the treatment outcome of surgical treatment of cervical radiculopathy is favorable with good to excellent results in 83–97% [33, 96, 102, 110] and primarily dependent on the nerve root decompression and not so much on the specific surgical technique.

### Cervical Spondylotic Myelopathy

There is no evidence against surgery in moderate to severe CSM cases

It is not known whether surgery results in better results than conservative care in mild to moderate CSM [142]. In a prospective study, Kadanka et al. [142] randomized 48 patients with mild to moderate CSM into a conservative and an operative arm. There was no significant deterioration in modified JOA score, recovery ratio, or timed 10-m walk within either group during the 2 years of follow-up. The authors concluded that surgical treatment of mild and moderate forms of CSM, consisting of patients with no or very slow, insidious progression and a relatively long duration of symptoms, was not superior to conservative care [142]. However, there is no controversy as to whether severe or progressive CSM should be treated by decompression [22, 223].

The goal of surgery is to completely decompress the spinal cord

The **primary surgical objective** in CSM is the arrest or improvement of neurological deficits by spinal cord decompression. In a prospective, multicenter nonrandomized study, surgically treated patients had a significant improvement in functional status and overall pain, with improvement also observed in neurological symptoms [239]. Conservatively treated patients had a significant worsening of their ability to perform activities of daily living, with worsening of neurological symptoms [239]. A meta-analysis of more than 2000 patients treated by laminoplasty revealed a mean improvement rate of 80% [225].

The choice of the surgical technique is dependent on the target pathology and patient characteristics

The **decompression of the spinal cord** can be achieved either by:

- anterior approach (multilevel ACDF or corpectomy ± plate fixation)
- posterior approach (laminoplasty, laminectomy ± instrumented fusion)
- combined anterior/posterior approach

Corpectomy and anteroposterior instrumented fusion results in a reliable outcome

Although innumerable studies have been reported for each of these approaches, the scientific evidence for treatment recommendations remains limited. Only a few studies have provided some evidence which is helpful for surgical decision-making. There is moderate evidence that **multilevel ACDFs** are associated with a high non-union rate [33, 49, 78] and limited evidence that **corpectomies** result in a lower non-union rate for multilevel decompression [263]. In three and more level ACDFs or corpectomies, anterior plate fixation does not suffice [136, 242, 270, 281] and additional **posterior fixation** is recommended [73, 93, 162, 226]. There is limited evidence that both **multilevel corpectomy** and **laminoplasty** are equally effective in arresting myelopathic progression in multilevel cervical myelopathy and can lead to significant neurological recovery and pain reduction in a majority of patients [72]. The neurological recovery appears not to be dependent on the laminoplasty technique [225]. However, there is limited evidence that patients treated with laminoplasty develop progressive limitation of cervical ROM similar to that seen after laminectomy and fusion [225].

### *Factors Affecting Outcome*

Spinal canal dimensions and signal intensity changes predict outcome

The outcome of surgery appears to be critically dependent on the extent of the spinal canal stenosis and cord compression. Yamazaki et al. [294] analyzed the prognostic factors by comparing younger and elderly patient groups on the basis of preoperative radiological and clinical data. The authors found that for elderly patients, the **transverse area** of the spinal cord at the level of maximum compression and symptom duration were the factors that predicted an excellent recovery. In younger patients, the transverse area was the only predictor of excellent recovery. Age, preoperative JOA score, canal diameter, and an intensity change on the spinal cord were not predictive in either age range [294]. Fujiwara et al. [89] showed that the transverse cord area at the site of maximum compression correlates significantly with the results of surgery. In most patients with less than 30 $mm^2$ of spinal cord area, the results are poor. Patients with high **intramedullary signal change** on T2W images who do not have clonus or spasticity may experience a good surgical outcome and may have reversal of the MRI abnormality [6]. A less favorable surgical outcome is predicted by the presence of low intramedullary signal on T1W images, clonus, or spasticity [6]. Based on these findings, Alafifiet et al. [6] suggested that there may be a window of opportunity for obtaining optimal surgical outcomes in patients with CSM. Yonenobu [297] has indicated that surgery performed too late in a stage with already severe myelopathy generally had a poor prognosis and therefore advocates early surgery.

Staged combined anterior/posterior decompression for myelopathy is safer

Some debate continues on the question of whether combined anterior/posterior surgery to decompress moderate to severe myelopathy should be done **staged or in one surgery** [180]. There is no evidence to support one approach over the other. Anecdotally, we have seen patients admitted to our spinal cord injury unit who experience substantial neurological deterioration after combined surgery. We therefore recommend performing anterior/posterior spinal cord decompression staged in moderate to severe myelopathy cases to minimize edema and allow blood supply to the spinal cord to readapt between the surgeries.

## Complications

A comprehensive review of complications is provided in Chapter 39. In general, complications of surgery for CSR and CSM are uncommon but can include [45, 85, 306]:

- cerebrospinal fluid leak (0.2 – 0.5 %)
- recurrent laryngeal nerve injury (0.8 – 3.1 %)
- dysphagia (0.02 – 9.5 %)
- Horner's syndrome (0.02 – 1.1)
- cervical nerve root injury (0.2 – 3.3 %)
- hematoma (0.2 – 5.6 %)
- tetraparesis (0.4 %)
- death (0.1 – 0.8 %)
- infection (0.1 – 1.4 %)
- esophageal perforations (0.2 – 0.3 %)
- non-union (dependent on technique)
- graft dislodgement/collapse (dependent on technique)
- instrumentation failure (dependent on technique)

Dysphagia is a common postoperative complication

**Dysphagia** is a quite frequent symptom after anterior cervical surgery and can be encountered in up to 50 % of cases in the immediate postoperative period [17]. Dysphagia is dependent on the number of levels treated [227]. At 12 months post-

operatively, however, the rate of moderate to severe dysphagia decreases to about 13 % [17]. The etiology of this complication is not fully understood. An injury to the superior laryngeal nerve has been suggested as a potential cause [131]. Papavero et al. [202] have reported that no correlation exists between the pharynx/esophagus retraction and postoperative swallowing disturbances.

RLN injury is not dependent on the approach site

**Recurrent laryngeal nerve (RLN) palsy** has been reported in 2 – 11 % [223]. In contrast to common belief, the injury rate does not appear to be related to the side of the approach [26]. Postoperative laryngoscopy revealed that the true incidence of initial and persisting RLN palsy after anterior cervical spine surgery was much higher than anticipated [141]. Jung et al. [141] reported that the postoperative rate of clinically symptomatic RLN palsy was 8.3 %, and the incidence of RLN palsy not associated with hoarseness (i.e. clinically unapparent without laryngoscopy) was 15.9 %. At 3 months postoperatively, these rates decrease to 2.5 % and 10.8 %, respectively [141].

C5 radiculopathy is a serious complication of spinal cord decompression

An infrequent but serious complication is a postoperative **C5 palsy** which can develop in up to 3 – 5 % of patients after posterior decompression surgery particularly laminoplasty [133, 235]. It has been suggested that this neural compromise is a result of traction on the short C5 nerve root due to posterior migration of the cord after posterior decompression [223]. However, a systematic review did not reveal significant differences between patients undergoing anterior decompression and fusion and laminoplasty, nor were distinctions apparent between unilateral hinge laminoplasty and French-door laminoplasty, or between cervical spondylotic myelopathy and ossification of the posterior longitudinal ligament [235]. The pathogenesis of postoperative C5 palsy remains unclear at the present time. Patients with postoperative C5 palsy generally have a good prognosis for functional recovery, but the severely paralyzed cases required significantly longer recovery times than the mild cases [235].

## Recapitulation

**Epidemiology.** Degenerative changes of the cervical spine (cervical spondylosis) can result in cervical disc herniation with radiculopathy, cervical spondylotic radiculopathy (CSR) and myelopathy (CSM). Degenerative cervical spondylosis is very common in the aging population but not necessarily associated with symptoms. The prevalence of **neck pain** ranges between 17 % and 34 % in a general population. More than half of the adult population suffer from **cervical radiculopathy** (CR) at least once in their lifetime. The C6 and C7 nerve roots are most frequently affected. Cervical spondylosis more frequently causes CR than disc herniation (3:1). **Cervical spondylotic myelopathy** (CSM) is the most common cause of spinal cord dysfunction in individuals older than 55 years. A special form of cervical myelopathy is caused by an ossification of the posterior longitudinal ligament (**OPLL**) and is common in the Asian population.

**Pathogenesis.** Predominant neck pain can arise from painful degeneration of the motion segment and can be attributed to disc degeneration, facet joint osteoarthritis and segmental instability. In the vast majority of cases with subaxial neck pain the correlation of morphological alterations and neck pain remains weak (**non-specific neck pain**). Radiculopathy due to disc herniation (so-called soft herniations) usually occurs during early stages of disc degeneration in the 4th–5th life decades. Compressive spondylotic spurs usually develop during later degenerative stages (so-called hard herniations). Both **mechanical** and **inflammatory processes** cause the clinical syndrome of radiculopathy. **CSM** is mainly due to a compression of the spinal cord by osteophytes, calcified disc herniations, yellow ligament hypertrophy or OPLL. Mechanical compression and vascular insufficiency lead to pathobiologic alterations resulting in myelopathy. The clinical manifestation of CSM depends on the degree of cord compression and time course of compression. The major risk factor is a **congenitally narrow spinal canal** (sagittal diameter < 13 mm). Minor trauma can acutely increase the compression which the spinal cord cannot toler-

ate any more, leading to sudden severe neurological deficits. **Dynamic compression** can aggravate spinal cord compression. Flexion lengthens the spinal cord and extension leads to a buckling of the ligamentum flavum which results in a bilateral cord compression (pincer effect). In addition to mechanical compression, **vascular factors** play a significant role in the development of myelopathy. Ischemia and a **cascade of cellular and molecular events** (glutamatergic toxicity, free radical cell injuries, and apoptosis) aggravate the compromise of the spinal cord. The causes of the OPLL are not well explored but **gene polymorphisms** appear to play an essential role.

**Clinical presentation.** The clinical assessment aims to differentiate between patients with **specific and non-specific** cervical disorders. Patients quite frequently present with pain syndrome located in the neck-shoulder-arm region. **Neck pain** most frequently is non-specific (i.e. without a clear structural correlate) but can seldomly be part of a so-called **spondylotic syndrome** (i.e. painful motion segment degeneration). The cardinal symptoms of **cervical radiculopathy** are a predominant radicular arm pain with or without sensorimotor and reflex deficits. Accompanying vegetative symptoms, dizziness, vertigo and headaches are not uncommon. A thorough neurological examination and nerve root provocation tests (e.g. Spurling test) are helpful in diagnosing radiculopathy. Radiculopathy can be associated with myelopathy because cervical spondylosis not only affects the foramen but also the spinal canal. A **myelopathic syndrome** can begin very subtly and can therefore pose a diagnostic challenge. Patients with cervical myelopathy can present with a broad spectrum of signs and symptoms depending on the magnitude of spinal cord dysfunction and chronicity. The leading symptoms are **numb, clumsy, painful hands** and compromised fine motor skills. Further findings are atrophy of the interosseous muscles, gait disturbances, ataxia, and symptoms of progressive tetraparesis.

**Diagnostic work-up.** Morphological alterations in imaging studies are frequent in asymptomatic controls, jeopardizing their role in identifying the pain source. **Standard radiographs** (anteroposterior, lateral, oblique views) of the cervical spine may give important information about spinal alignment, spinal curvature, disc space narrowing, spondylophytes, facet joint osteoarthritis, foraminal stenosis, developmental anomalies, and DISH. **Functional radiographs** have failed to reliably allow the diagnosis of segmental instability. Therefore, **instability** remains a **clinical diagnosis**. The imaging modality of choice is **MRI.** Sagittal T2W images tend to overestimate the spinal cord compression, favoring T1W images for this assessment. **MR signal intensity changes** represent structural alterations of the spinal cord and have some prognostic value for treatment outcome. **CT myelography** provides better information than MRI regarding the relationship between neural compression by osteophytes or ossifications. **Injection studies** (facet joint blocks, discography) do not reliably allow identification of the pain source. **Neurophysiological studies** are helpful in differentiating radiculopathy and peripheral neuropathy. Furthermore, they allow the recognition of subclinical myelopathy.

**Non-operative treatment.** Most cases of non-specific acute neck pain resolve within a few days or weeks. But neck pain frequently recurs and can become disabling in about 6 % of cases. The **natural history of CSR** generally is benign. However, CSR has a somewhat worse course than disc related radiculopathy because disc extrusion/sequestrations tend to regress with time while osseous compression tends to increase. The **natural history of CSM** has a variable clinical course which is characterized either by long periods of stable disability followed by episodes of deterioration or a linear progressive course. In advanced stages, complete remission to normality never occurs. **Non-specific neck pain** and spondylosis related neck pain are best managed with conservative care because a clear morphological correlate which could be addressed by surgery is often missing. In the absence of major (MRC Grade >3) or progressive motor deficits, **CSR** should be treated with an initial trial of non-operative care. Persistence of severe pain and sensorimotor deficits despite adequate non-operative care should prompt the indication for surgery in cases with a clear morphological correlate. Non-surgical treatment is only indicated in mild forms of **CSM**. In cases with circumferential spinal cord compression, deterioration under conservative care must be expected. The **mainstay of non-surgical care** consists of oral medications (e.g. analgesics, NSAIDs, muscle relaxants, psychotropic drugs), manipulative treatment, and physical exercises. There is moderate evidence that **spinal manipulative therapy** (SMT) and **mobilization** is superior to general practitioner management for

short-term pain reduction of chronic neck pain. There is limited evidence for the effectiveness of spinal injections, which are more dangerous than previously thought. Radiofrequency denervation of facet joints is only supported by limited evidence. There is no evidence for the effectiveness of massage, acupuncture, or electrotherapy.

**Operative treatment.** In general, patients with progressive neurological symptoms and those failing to respond to non-operative treatment should be considered candidates for surgery. Axial neck pain is multifactorial and often lacking a structural correlate which can be treated by surgery. Therefore, **surgery for neck pain** is **rarely indicated**. Anterior cervical discectomy and fusion (ACDF) still remains the gold standard for surgical treatment of **CR**. There is no evidence that **additional anterior plate fixation** influences clinical outcome for one-level disease and only limited evidence for the increase of the fusion rate for two-level disease. Similarly, there is no evidence for the superiority of **cage fusions** or **total disc arthroplasty** (TDA) compared to ACDF with the exception of iliac crest donor site pain. **Minimally invasive decompressions** (anterior or posterior) for the treatment of selected radiculopathy patients remain intriguing because they preserve segmental motion and do not require instrumentation. The outcome of surgery for CR is largely dependent on the successful decompression of the nerve root(s) and not per se on the chosen surgical technique. The **primary surgical objective** in **CSM** is to arrest or improve neurological deficits by spinal cord decompression, which is possible in about 80% of patients depending on the disease state. Spinal decompression can be achieved by (multilevel) ACDF, corpectomy, laminectomy or laminoplasty. The surgical techniques must be tailored to the target pathology. There is moderate evidence that **multilevel ACDFs** are associated with a high non-union rate and limited evidence that **corporectomies** result in a lower non-union rate for multilevel decompression. In three and more level ACDFs or corpectomies, **anterior plate fixation** does not suffice and additional posterior fixation is recommended. There is limited evidence that both multilevel corpectomy and laminoplasty are equally effective in arresting myelopathic progression in multilevel cervical myelopathy. Patients treated with **laminoplasty** develop progressive limitation of cervical ROM similar to that seen after laminectomy and fusion. The neurological recovery appears not to be dependent on the decompression technique but spinal canal dimensions and MR signal intensity changes of the spinal cord are strong **predictors of surgical outcome**. **Dysphagia** is a quite frequent symptom after anterior cervical surgery and can be encountered in up to 50% of cases in the immediate postoperative period. However, most patients (90%) recover within 1 year after surgery. **Recurrent laryngeal nerve (RLN)** injury is reported in 2–11% and independently of the approach site. An infrequent but serious complication is a postoperative **C5 palsy** which can develop in up to 3–5% of patients after posterior decompression surgery, particularly laminoplasty.

## Key Articles

**Baptiste DC, Fehlings MG (2006) Pathophysiology of cervical myelopathy. Spine J 6(6 Suppl):190S–197S**
Excellent review of the current knowledge of the pathophysiology of cervical myelopathy.

**Gross AR, Goldsmith C, Hoving JL, Haines T, Peloso P, Aker P, Santaguida P, Myers C (2007) Conservative management of mechanical neck disorders: a systematic review. J Rheumatol 34:1083–102**
This comprehensive review noted strong evidence for the benefit of exercise plus mobilization/manipulation in the treatment of subacute/chronic mechanical neck pain. There was moderate evidence for the long-term benefit of direct neck strengthening and stretching exercises for chronic neck pain. Many other treatments only demonstrated short-term effects.

**Persson LC, Carlsson CA, Carlsson JY (1997) Long-lasting cervical radicular pain managed with surgery, physiotherapy, or a cervical collar. A prospective, randomized study. Spine 22:751–8**

**Persson LC, Moritz U, Brandt L, et al. (1997) Cervical radiculopathy: pain, muscle weakness and sensory loss in patients with cervical radiculopathy treated with surgery, physiotherapy or cervical collar. A prospective, controlled study. Eur Spine J 6:256 – 66**
In this prospective study on 81 patients with cervical spondylotic radiculopathy, the authors found that a cervical collar, physiotherapy, or surgery were equally effective in the long term. However, better short-term pain relief was noted for the surgically treated patients.

**Robinson RA, Smith GW (1955) Anterolateral cervical disc removal and interbody fusion for cervical disc syndrome. Bull Johns Hopkins Hosp 96:223**
**Smith GW, Robinson RA (1958) The treatment of certain cervical-spine disorders by anterior removal of the intervertebral disc and interbody fusion. J Bone Joint Surg Am 40-A:607 – 24**
**Cloward RB (1958) The anterior approach for removal of ruptured cervical disks. J Neurosurg 15:602 – 17**
Classic articles on the technique of anterior cervical discectomy and fusion.

**Frykholm R (1951) Cervical nerve root compression resulting from disc degeneration and root-sleeve fibrosis. A clinical investigation. Acta Orthop Scand (Suppl) 160:1 – 149**
Classic article on the techniques of posterior foraminotomy.

**Bohlman HH, Emery SE, Goodfellow DB, Jones PK (1993) Robinson anterior cervical discectomy and arthrodesis for cervical radiculopathy. Long-term follow-up of one hundred and twenty-two patients. J Bone Joint Surg (Am) 75-A:1298 – 1307**
In this classic case series, Bohlman et al. demonstrated that the fusion results of ACDF are critically dependent on the amount of levels fused. The fusion rates for one, two and multilevel fusions were 89 %, 73 % and 67 %, respectively.

**Savolainen S, Rinne J, Hernesniemi J (1998) A prospective randomized study of anterior single-level cervical disc operations with long-term follow-up: surgical fusion is unnecessary. Neurosurgery 43:51 – 5**
In this RCT, the authors demonstrated that the radiological results indicated that complete bony union was achieved in almost all cases at 4 years of follow-up. A slight kyphosis developed in 62.5 % of the patients who had undergone discectomy, 40 % of the patients who had undergone fusion, and 44 % of the patients who had undergone fusion plus plating. The clinical outcomes were good for 76 % of the patients who had undergone discectomy, 82 % who had undergone fusion, and 73 % who had undergone fusion plus plating. The authors concluded that satisfactory results can be achieved by performing simple discectomy to treat single-level cervical root compressive disease.

**Grob D, Peyer JV, Dvorak J (2001) The use of plate fixation in anterior surgery of the degenerative cervical spine: a comparative prospective clinical study. Eur Spine J 10: 408 – 13**
In this small RCT, the authors demonstrated that outcome and fusion rates of one- and two-level fusion were independent of anterior plating.

**Wang JC, McDonough PW, Endow KK, Delamarter RB (2000) Increased fusion rates with cervical plating for two-level anterior cervical discectomy and fusion. Spine 25:41 – 5**
This study demonstrates the benefits of anterior plating for three-level fusions on the radiological outcome. However, the study also indicated that a three-level procedure is still associated with a high non-union rate and additional posterior fusion may be indicated in these cases.

**Kadanka Z, Bednarik J, Vohanka S, Vlach O, Stejskal L, Chaloupka R, Filipovicova D, Surelova D, Adamova B, Novotny O, Nemec M, Smrcka V, Urbanek I (2000) Conservative treatment versus surgery in spondylotic cervical myelopathy: a prospective randomised study. Eur Spine J 9:538 – 44**
In a prospective randomized study, the authors compared the conservative and operative treatment of 48 patients with mild and moderate forms of cervical spondylotic myelopathy (CSM). The authors concluded that surgical treatment of mild to moderate forms of CSM in the present study design, comprising patients with no or very slow, insidious progression and a relatively long duration of symptoms, did not show better results than conservative treatment at 2-year follow-up.

**Hirabayashi K, Miyakawa J, Satomi K, Maruyama T, Wakano K (1981) Operative results and postoperative progression of ossification among patients with ossification of cervical posterior longitudinal ligament. Spine 6:354–64**
Classic article on the technique of laminoplasty.

**Edwards CC, 2nd, Heller JG, Murakami H (2002) Corpectomy versus laminoplasty for multilevel cervical myelopathy: an independent matched-cohort analysis. Spine 27:1168–75**
In this matched cohort study, the authors demonstrated that both multilevel corpectomy and laminoplasty reliably arrest myelopathic progression in multilevel cervical myelopathy. Significant neurological recovery and pain reduction can be expected in a majority of patients. The authors suggested that laminoplasty may be the preferred method of treatment for multilevel cervical myelopathy in the absence of preoperative kyphosis.

**Ratliff JK, Cooper PR (2003) Cervical laminoplasty: a critical review. J Neurosurg 98: 230–8**
The authors conducted a metaanalysis on laminoplasty including more than 2000 patients from 71 studies. Twenty-three papers provided data on the percentage of patients improving (mean approximately 80%). The recovery was independent of the technique. A postoperative deterioration of cervical alignment was found in approximately 35%, and 10% developed postoperative kyphosis in the long term. In the long-term follow-up, progressive loss of cervical ROM was observed. Final ROM appears to be similar to that seen in patients who had undergone laminectomy and fusion. In only seven articles were the rates of postoperative axial neck pain quantified, noting an incidence between 6% and 60%. In approximately 8% of patients, C5 nerve root dysfunction was reported (in 12 articles).

## References


1. Abumi K, Kaneda K (1997) Pedicle screw fixation for nontraumatic lesions of the cervical spine. Spine 22:1853–63
2. Abumi K, Kaneda K, Shono Y, Fujiya M (1999) One-stage posterior decompression and reconstruction of the cervical spine by using pedicle screw fixation systems. J Neurosurg 90:19–26
3. Abumi K, Shono Y, Taneichi H, Ito M, Kaneda K (1999) Correction of cervical kyphosis using pedicle screw fixation systems. Spine 24:2389–96
4. Aebi M, Zuber K, Marchesi D (1991) Treatment of cervical spine injuries with anterior plating. Indications, techniques, and results. Spine (Suppl) 16:S38–45
5. Aker PD, Gross AR, Goldsmith CH, Peloso P (1996) Conservative management of mechanical neck pain: systematic overview and meta-analysis. BMJ 313:1291–6
6. Alafifi T, Kern R, Fehlings M (2007) Clinical and MRI predictors of outcome after surgical intervention for cervical spondylotic myelopathy. J Neuroimaging 17:315–22
7. An HS, Simpson JM, Glover JM, Stephany J (1995) Comparison between allograft plus demineralized bone matrix versus autograft in anterior cervical fusion. A prospective multicenter study. Spine 20:2211–6
8. Anderberg L, Annertz M, Persson L, Brandt L, Saveland H (2007) Transforaminal steroid injections for the treatment of cervical radiculopathy: a prospective and randomised study. Eur Spine J 16:321–8
9. Arnold JG, Jr. (1955) The clinical manifestations of spondylochondrosis (spondylosis) of the cervical spine. Ann Surg 141:872–89
10. Aronson N, Filtzer DL, Bagan M (1968) Anterior cervical fusion by the Smith-Robinson approach. J Neurosurg 29:397–404
11. Auerbach JD, Jones KJ, Fras CI, Balderston JR, Rushton SA, Chin KR (2007) The prevalence of indications and contraindications to cervical total disc replacement. Spine J (in press)
12. Awasthi D, Voorhies RM (1992) Anterior cervical vertebrectomy and interbody fusion. Technical note. J Neurosurg 76:159–63
13. Aydin Y, Kaya RA, Can SM, Turkmenoglu O, Cavusoglu H, Ziyal IM (2005) Minimally invasive anterior contralateral approach for the treatment of cervical disc herniation. Surg Neurol 63:210–8; discussion 218–9
14. Baba H, Furusawa N, Imura S, Kawahara N, Tsuchiya H, Tomita K (1993) Late radiographic findings after anterior cervical fusion for spondylotic myeloradiculopathy. Spine 18: 2167–73

15. Bambakidis NC, Feiz-Erfan I, Klopfenstein JD, Sonntag VK (2005) Indications for surgical fusion of the cervical and lumbar motion segment. Spine 30:S2 – 6
16. Baptiste DC, Fehlings MG (2006) Pathophysiology of cervical myelopathy. Spine J 6:190S–197S
17. Bazaz R, Lee MJ, Yoo JU (2002) Incidence of dysphagia after anterior cervical spine surgery: a prospective study. Spine 27:2453 – 8
18. Bednarik J, Kadanka Z, Vohanka S, Novotny O, Surelova D, Filipovicova D, Prokes B (1998) The value of somatosensory and motor evoked evoked potentials in pre-clinical spondylotic cervical cord compression. Eur Spine J 7:493 – 500
19. Bednarik J, Kadanka Z, Vohanka S, Stejskal L, Vlach O, Schroder R (1999) The value of somatosensory- and motor-evoked potentials in predicting and monitoring the effect of therapy in spondylotic cervical myelopathy. Prospective randomized study. Spine 24: 1593 – 8
20. Benzel EC, Lancon J, Kesterson L, Hadden T (1991) Cervical laminectomy and dentate ligament section for cervical spondylotic myelopathy. J Spinal Disord 4:286 – 95
21. Bernard TN, Jr., Whitecloud TS, 3rd (1987) Cervical spondylotic myelopathy and myeloradiculopathy. Anterior decompression and stabilization with autogenous fibula strut graft. Clin Orthop Relat Res:149 – 60
22. Bernhardt M, Hynes RA, Blume HW, White AA, 3rd (1993) Cervical spondylotic myelopathy. J Bone Joint Surg Am 75:119 – 28
23. Bertagnoli R, Yue JJ, Pfeiffer F, Fenk-Mayer A, Lawrence JP, Kershaw T, Nanieva R (2005) Early results after ProDisc-C cervical disc replacement. J Neurosurg Spine 2:403 – 10
24. Bertalanffy H, Eggert HR (1988) Clinical long-term results of anterior discectomy without fusion for treatment of cervical radiculopathy and myelopathy. A follow-up of 164 cases. Acta Neurochir (Wien) 90:127 – 35
25. Bertalanffy H, Eggert HR (1989) Complications of anterior cervical discectomy without fusion in 450 consecutive patients. Acta Neurochir (Wien) 99:41 – 50
26. Beutler WJ, Sweeney CA, Connolly PJ (2001) Recurrent laryngeal nerve injury with anterior cervical spine surgery – risk with laterality of surgical approach. Spine 26:1337 – 42
27. Birch S, Hesselink JK, Jonkman FA, Hekker TA, Bos A (2004) Clinical research on acupuncture. Part 1. What have reviews of the efficacy and safety of acupuncture told us so far? J Altern Complement Med 10:468 – 80
28. Bishop RC, Moore KA, Hadley MN (1996) Anterior cervical interbody fusion using autogeneic and allogeneic bone graft substrate: a prospective comparative analysis. J Neurosurg 85:206 – 10
29. Boden SD, McCowin PR, Davis DO, Dina TS, Mark AS, Wiesel S (1990) Abnormal magnetic-resonance scans of the cervical spine in asymptomatic subjects. A prospective investigation. J Bone Joint Surg Am 72:1178 – 84
30. Boehm H, Greiner-Perth R, El-Saghir H, Allam Y (2003) A new minimally invasive posterior approach for the treatment of cervical radiculopathy and myelopathy: surgical technique and preliminary results. Eur Spine J 12:268 – 73
31. Bohler J, Gaudernak T (1980) Anterior plate stabilization for fracture-dislocations of the lower cervical spine. J Trauma 20:203 – 5
32. Bohlman HH, Emery SE (1988) The pathophysiology of cervical spondylosis and myelopathy. Spine 13:843 – 6
33. Bohlman HH, Emery SE, Goodfellow DB, Jones PK (1993) Robinson anterior cervical discectomy and arthrodesis for cervical radiculopathy. Long-term follow-up of one hundred and twenty-two patients. J Bone Joint Surg (Am) 75-A:1298 – 1307
34. Bolesta MJ, Rechtine GR, 2nd, Chrin AM (2000) Three- and four-level anterior cervical discectomy and fusion with plate fixation: a prospective study. Spine 25:2040 – 4; discussion 2045 – 6
35. Boni M, Cherubino P, Denaro V, Benazzo F (1984) Multiple subtotal somatectomy. Technique and evaluation of a series of 39 cases. Spine 9:358 – 62
36. Boos N (2006) Outcome assessment and documentation: a friend or foe? Eur Spine J 15 Suppl 1:S1 – 3
37. Bosacco DN, Berman AT, Levenberg RJ, Bosacco SJ (1992) Surgical results in anterior cervical discectomy and fusion using a countersunk interlocking autogenous iliac bone graft. Orthopedics 15:923 – 5
38. Bot SD, van der Waal JM, Terwee CB, van der Windt DA, Schellevis FG, Bouter LM, Dekker J (2005) Incidence and prevalence of complaints of the neck and upper extremity in general practice. Ann Rheum Dis 64:118 – 23
39. Brandt T (1996) Cervical vertigo – reality or fiction? Audiol Neurootol 1:187 – 96
40. Breig A, Turnbull I, Hassler O (1966) Effects of mechanical stresses on the spinal cord in cervical spondylosis. A study on fresh cadaver material. J Neurosurg 25:45 – 56
41. Bronfort G, Haas M, Evans RL, Bouter LM (2004) Efficacy of spinal manipulation and mobilization for low back pain and neck pain: a systematic review and best evidence synthesis. Spine J 4:335 – 56

42. Brown MD, Malinin TI, Davis PB (1976) A roentgenographic evaluation of frozen allografts versus autografts in anterior cervical spine fusions. Clin Orthop Relat Res:231 – 6
43. Burke TG, Caputy A (2000) Microendoscopic posterior cervical foraminotomy: a cadaveric model and clinical application for cervical radiculopathy. J Neurosurg 93:126 – 9
44. Burrows EH (1963) The sagittal diameter of the spinal canal in cervical spondylosis. Clin Radiol 14:77 – 86
45. Carette S, Fehlings MG (2005) Clinical practice. Cervical radiculopathy. N Engl J Med 353:392 – 9
46. Caspar W, Barbier DD, Klara PM (1989) Anterior cervical fusion and Caspar plate stabilization for cervical trauma. Neurosurgery 25:491 – 502
47. Caspar W, Geisler FH, Pitzen T, Johnson TA (1998) Anterior cervical plate stabilization in one- and two-level degenerative disease: overtreatment or benefit? J Spinal Disord 11: 1 – 11
48. Cassou B, Derriennic F, Monfort C, Norton J, Touranchet A (2002) Chronic neck and shoulder pain, age, and working conditions: longitudinal results from a large random sample in France. Occup Environ Med 59:537 – 44
49. Cauthen JC, Kinard RE, Vogler JB, Jackson DE, DePaz OB, Hunter OL, Wasserburger LB, Williams VM (1998) Outcome analysis of noninstrumented anterior cervical discectomy and interbody fusion in 348 patients. Spine 23:188 – 92
50. Chang UK, Kim DH, Lee MC, Willenberg R, Kim SH, Lim J (2007) Range of motion change after cervical arthroplasty with ProDisc-C and prestige artificial discs compared with anterior cervical discectomy and fusion. J Neurosurg Spine 7:40 – 6
51. Chen C, Lu Y, Kallakuri S, Patwardhan A, Cavanaugh JM (2006) Distribution of A-delta and C-fiber receptors in the cervical facet joint capsule and their response to stretch. J Bone Joint Surg Am 88:1807 – 16
52. Cherubino P, Benazzo F, Borromeo U, Perle S (1990) Degenerative arthritis of the adjacent spinal joints following anterior cervical spinal fusion: clinicoradiologic and statistical correlations. Ital J Orthop Traumatol 16:533 – 43
53. Cho DY, Lee WY, Sheu PC, Chen CC (2005) Cage containing a biphasic calcium phosphate ceramic (Triosite) for the treatment of cervical spondylosis. Surg Neurol 63:497 – 503; discussion 503 – 4
54. Cho DY, Liau WR, Lee WY, Liu JT, Chiu CL, Sheu PC (2002) Preliminary experience using a polyetheretherketone (PEEK) cage in the treatment of cervical disc disease. Neurosurgery 51:1343 – 49; discussion 1349 – 50
55. Chow RT, Barnsley L (2005) Systematic review of the literature of low-level laser therapy (LLLT) in the management of neck pain. Lasers Surg Med 37:46 – 52
56. Chuang HC, Cho DY, Chang CS, Lee WY, Jung-Chung C, Lee HC, Chen CC (2006) Efficacy and safety of the use of titanium mesh cages and anterior cervical plates for interbody fusion after anterior cervical corpectomy. Surg Neurol 65:464 – 71; discussion 471
57. Clark CR (1988) Cervical spondylotic myelopathy: history and physical findings. Spine 13:847 – 9
58. Clark E, Robinson PK (1956) Cervical myelopathy: a complication of cervical spondylosis. Brain 79:483 – 510
59. Clarke MJ, Ecker RD, Krauss WE, McClelland RL, Dekutoski MB (2007) Same-segment and adjacent-segment disease following posterior cervical foraminotomy. J Neurosurg Spine 6:5 – 9
60. Cleland JA, Fritz JM, Whitman JM, Heath R (2007) Predictors of short-term outcome in people with a clinical diagnosis of cervical radiculopathy. Phys Ther 87:1619 – 32
61. Cleland JA, Whitman JM, Fritz JM, Palmer JA (2005) Manual physical therapy, cervical traction, and strengthening exercises in patients with cervical radiculopathy: a case series. J Orthop Sports Phys Ther 35:802 – 11
62. Cloward RB (1958) The anterior approach for removal of ruptured cervical disks. J Neurosurg 15:602 – 17
63. Cloward RB (1980) Gas-sterilized cadaver bone grafts for spinal fusion operations. A simplified bone bank. Spine 5:4 – 10
64. Cohen SP, Hurley RW (2007) The ability of diagnostic spinal injections to predict surgical outcomes. Anesth Analg 105:1756 – 75, table of contents
65. Colhoun E, McCall IW, Williams L, Cassar Pullicino VN (1988) Provocation discography as a guide to planning operations on the spine. J Bone Joint Surg Br 70:267 – 71
66. Cote P, Cassidy JD, Carroll LJ, Kristman V (2004) The annual incidence and course of neck pain in the general population: a population-based cohort study. Pain 112:267 – 73
67. Crowe MJ, Bresnahan JC, Shuman SL, Masters JN, Beattie MS (1997) Apoptosis and delayed degeneration after spinal cord injury in rats and monkeys. Nat Med 3:73 – 6
68. Denno JJ, Meadows GR (1991) Early diagnosis of cervical spondylotic myelopathy. A useful clinical sign. Spine 16:1353 – 5
69. DePalma AF, Rothman RH, Lewinnek GE, Cannale ST (1972) Anterior interbody fusion for severe cervical disc degeneration. Surg Gynecol Obstet 134:755 – 758

70. Dreyfuss P, Baker R, Bogduk N (2006) Comparative effectiveness of cervical transforaminal injections with particulate and nonparticulate corticosteroid preparations for cervical radicular pain. Pain Med 7:237 – 42
71. Ebraheim NA, Rupp RE, Savolaine ER, Brown JA (1995) Posterior plating of the cervical spine. J Spinal Disord 8:111 – 5
72. Edwards CC, 2nd, Heller JG, Murakami H (2002) Corpectomy versus laminoplasty for multilevel cervical myelopathy: an independent matched-cohort analysis. Spine 27: 1168 – 75
73. Edwards CC, 2nd, Riew KD, Anderson PA, Hilibrand AS, Vaccaro AF (2003) Cervical myelopathy: current diagnostic and treatment strategies. Spine J 3:68 – 81
74. Edwards WC, LaRocca H (1983) The developmental segmental sagittal diameter of the cervical spinal canal in patients with cervical spondylosis. Spine 8:20 – 7
75. Ellenberg MR, Honet JC, Treanor WJ (1994) Cervical radiculopathy. Arch Phys Med Rehabil 75:342 – 52
76. Emery SE, Bohlman HH, Bolesta MJ, Jones PK (1998) Anterior cervical decompression and arthrodesis for the treatment of cervical spondylotic myelopathy. Two to seventeen-year follow-up. J Bone Joint Surg Am 80:941 – 51
77. Emery SE, Bolesta MJ, Banks MA, Jones PK (1994) Robinson anterior cervical fusion comparison of the standard and modified techniques. Spine 19:660 – 3
78. Emery SE, Fisher JRS, Bohlman HH (1997) Three-level anterior cervical discectomy and fusion. Radiographic and clinical results. Spine 22:2622 – 2625
79. Fehlings MG, Cooper PR, Errico TJ (1994) Posterior plates in the management of cervical instability: long-term results in 44 patients. J Neurosurg 81:341 – 9
80. Fehlings MG, Skaf G (1998) A review of the pathophysiology of cervical spondylotic myelopathy with insights for potential novel mechanisms drawn from traumatic spinal cord injury. Spine 23:2730 – 7
81. Ferlic DC (1963) The nerve supply of the cervical intervertebral disc in man. Bull Johns Hopkins Hosp 113:347 – 51
82. Fessler RG, Khoo LT (2002) Minimally invasive cervical microendoscopic foraminotomy: an initial clinical experience. Neurosurgery 51:S37 – 45
83. Floyd T, Ohnmeiss D (2000) A meta-analysis of autograft versus allograft in anterior cervical fusion. Eur Spine J 9:398 – 403
84. Fontanella A (1999) Endoscopic microsurgery in herniated cervical discs. Neurol Res 21:31 – 8
85. Fountas KN, Kapsalaki EZ, Nikolakakos LG, Smisson HF, Johnston KW, Grigorian AA, Lee GP, Robinson JS, Jr. (2007) Anterior cervical discectomy and fusion associated complications. Spine 32:2310 – 7
86. Fouyas IP, Statham PF, Sandercock PA (2002) Cochrane review on the role of surgery in cervical spondylotic radiculomyelopathy. Spine 27:736 – 47
87. Fried LC, Doppman JL, Di Chiro G (1970) Direction of blood flow in the primate cervical spinal cord. J Neurosurg 33:325 – 30
88. Frykholm R (1951) Cervical nerve root compression resulting from disc degeneration and root-sleeve fibrosis. A clinical investigation. Acta Orthop Scand (Suppl) 160:1 – 149
89. Fujiwara K, Yonenobu K, Ebara S, Yamashita K, Ono K (1989) The prognosis of surgery for cervical compression myelopathy. An analysis of the factors involved. J Bone Joint Surg Br 71:393 – 8
90. Galm R, Rittmeister M, Schmitt E (1998) Vertigo in patients with cervical spine dysfunction. Eur Spine J 7:55 – 8
91. Garger WN, Fisher RG, Halfmann HW (1969) Vertebrectomy and fusion for "tear drop fracture" of the cervical spine: case report. J Trauma 9:887 – 93
92. Garvey TA, Transfeldt EE, Malcolm JR, Kos P (2002) Outcome of anterior cervical discectomy and fusion as perceived by patients treated for dominant axial-mechanical cervical spine pain. Spine 27:1887 – 95; discussion 1895
93. Geck MJ, Eismont FJ (2002) Surgical options for the treatment of cervical spondylotic myelopathy. Orthop Clin North Am 33:329 – 48
94. Geisler FH, Caspar W, Pitzen T, Johnson TA (1998) Reoperation in patients after anterior cervical plate stabilization in degenerative disease. Spine 23:911 – 20
95. Gledhill RF, Harrison BM, McDonald WI (1973) Demyelination and remyelination after acute spinal cord compression. Exp Neurol 38:472 – 87
96. Goldberg EJ, Singh K, Van U, Garretson R, An HS (2002) Comparing outcomes of anterior cervical discectomy and fusion in workman's versus non-workman's compensation population. Spine J 2:408 – 14
97. Good DC, Couch JR, Wacaser L (1984) "Numb, clumsy hands" and high cervical spondylosis. Surg Neurol 22:285 – 91
98. Gooding MR, Wilson CB, Hoff JT (1975) Experimental cervical myelopathy. Effects of ischemia and compression of the canine cervical spinal cord. J Neurosurg 43:9 – 17
99. Gore DR (1984) Technique of cervical interbody fusion. Clin Orthop Relat Res:191 – 5

100. Gore DR (2001) The arthrodesis rate in multilevel anterior cervical fusions using autogenous fibula. Spine 26:1259 – 63
101. Gore DR (2001) Roentgenographic findings in the cervical spine in asymptomatic persons: a ten-year follow-up. Spine 26:2463 – 6
102. Gore DR, Sepic SB (1984) Anterior cervical fusion for degenerated or protruded discs. A review of one hundred forty-six patients. Spine 9:667 – 671
103. Gore DR, Sepic SB, Gardner GM, Murray MP (1987) Neck pain: a long-term follow-up of 205 patients. Spine 12:1 – 5
104. Gregorius FK, Estrin T, Crandall PH (1976) Cervical spondylotic radiculopathy and myelopathy. A long-term follow-up study. Arch Neurol 33:618 – 25
105. Grob D, Peyer JV, Dvorak J (2001) The use of plate fixation in anterior surgery of the degenerative cervical spine: a comparative prospective clinical study. Eur Spine J 10:408 – 13
106. Gross AR, Goldsmith C, Hoving JL, Haines T, Peloso P, Aker P, Santaguida P, Myers C (2007) Conservative management of mechanical neck disorders: a systematic review. J Rheumatol 34:1083 – 102
107. Grubb SA, Kelly CK (2000) Cervical discography: clinical implications from 12 years of experience. Spine 25:1382 – 9
108. Guez M, Hildingsson C, Nasic S, Toolanen G (2006) Chronic low back pain in individuals with chronic neck pain of traumatic and non-traumatic origin: a population-based study. Acta Orthop 77:132 – 7
109. Guigui P, Benoist M, Deburge A (1998) Spinal deformity and instability after multilevel cervical laminectomy for spondylotic myelopathy. Spine 23:440 – 7
110. Hacker RJ (2000) A randomized prospective study of an anterior cervical interbody fusion device with a minimum of 2 years of follow-up results. J Neurosurg 93:222 – 6
111. Hacker RJ, Cauthen JC, Gilbert TJ, Griffith SL (2000) A prospective randomized multicenter clinical evaluation of an anterior cervical fusion cage. Spine 25:2646 – 54; discussion 2655
112. Hakuba A (1976) Trans-unco-discal approach. A combined anterior and lateral approach to cervical discs. J Neurosurg 45:284 – 91
113. Hanai K, Fujiyoshi F, Kamei K (1986) Subtotal vertebrectomy and spinal fusion for cervical spondylotic myelopathy. Spine 11:310 – 5
114. Hanai K, Inouye Y, Kawai K, Tago K, Itoh Y (1982) Anterior decompression for myelopathy resulting from ossification of the posterior longitudinal ligament. J Bone Joint Surg Br 64:561 – 4
115. Haraldsson BG, Gross AR, Myers CD, Ezzo JM, Morien A, Goldsmith C, Peloso PM, Bronfort G (2006) Massage for mechanical neck disorders. Cochrane Database Syst Rev 3:CD004871
116. Harsh GRt, Sypert GW, Weinstein PR, Ross DA, Wilson CB (1987) Cervical spine stenosis secondary to ossification of the posterior longitudinal ligament. J Neurosurg 67:349 – 57
117. Hase H, Watanabe T, Hirasawa Y, Hashimoto H, Miyamoto T, Chatani K, Kageyama N, Mikami Y (1991) Bilateral open laminoplasty using ceramic laminas for cervical myelopathy. Spine 16:1269 – 76
118. Hasvold T, Johnsen R (1993) Headache and neck or shoulder pain – frequent and disabling complaints in the general population. Scand J Prim Health Care 11:219 – 24
119. Hayashi H, Okada K, Hamada M, Tada K, Ueno R (1987) Etiologic factors of myelopathy. A radiographic evaluation of the aging changes in the cervical spine. Clin Orthop Relat Res:200 – 9
120. Heckmann JG, Maihofner C, Lanz S, Rauch C, Neundorfer B (2006) Transient tetraplegia after cervical facet joint injection for chronic neck pain administered without imaging guidance. Clin Neurol Neurosurg 108:709 – 11
121. Heller JG, Silcox DH, 3rd, Sutterlin CE, 3rd (1995) Complications of posterior cervical plating. Spine 20:2442 – 8
122. Henderson CM, Hennessy RG, Shuey HM, Jr., Shackelford EG (1983) Posterior-lateral foraminotomy as an exclusive operative technique for cervical radiculopathy: a review of 846 consecutively operated cases. Neurosurgery 13:504 – 12
123. Herdmann J, Linzbach M, Krzan M (1994) The European Myelopathy Score. Adv Neurosurg 22:266 – 268
124. Hilibrand AS, Carlson GD, Palumbo MA, Jones PK, Bohlman HH (1999) Radiculopathy and myelopathy at segments adjacent to the site of a previous anterior cervical arthrodesis. J Bone Joint Surg Am 81:519 – 28
125. Hilibrand AS, Fye MA, Emery SE, Palumbo MA, Bohlman HH (2002) Increased rate of arthrodesis with strut grafting after multilevel anterior cervical decompression. Spine 27:146 – 51
126. Hirabayashi K, Miyakawa J, Satomi K, Maruyama T, Wakano K (1981) Operative results and postoperative progression of ossification among patients with ossification of cervical posterior longitudinal ligament. Spine 6:354 – 64
127. Hirabayashi K, Satomi K (1988) Operative procedure and results of expansive open-door laminoplasty. Spine 13:870 – 6

128. Hirabayashi K, Watanabe K, Wakano K, Suzuki N, Satomi K, Ishii Y (1983) Expansive open-door laminoplasty for cervical spinal stenotic myelopathy. Spine 8:693 – 9
129. Hoshi K, Kurokawa T, Nakamura K, Hoshino Y, Saita K, Miyoshi K (1996) Expansive cervical laminoplasties – observations on comparative changes in spinous process lengths following longitudinal laminal divisions using autogenous bone or hydroxyapatite spacers. Spinal Cord 34:725 – 8
130. Humphreys SC, Hodges SD, Patwardhan A, Eck JC, Covington LA, Sartori M (1998) The natural history of the cervical foramen in symptomatic and asymptomatic individuals aged 20 – 60 years as measured by magnetic resonance imaging. A descriptive approach. Spine 23:2180 – 4
131. Hurtado-Lopez LM, Zaldivar-Ramirez FR (2002) Risk of injury to the external branch of the superior laryngeal nerve in thyroidectomy. Laryngoscope 112:626 – 9
132. Hwang SL, Lee KS, Su YF, Kuo TH, Lieu AS, Lin CL, Howng SL, Hwang YF (2007) Anterior corpectomy with iliac bone fusion or discectomy with interbody titanium cage fusion for multilevel cervical degenerated disc disease. J Spinal Disord Tech 20:565 – 570
133. Ikenaga M, Shikata J, Tanaka C (2005) Radiculopathy of C-5 after anterior decompression for cervical myelopathy. J Neurosurg Spine 3:210 – 7
134. Inamasu J, Guiot BH, Sachs DC (2006) Ossification of the posterior longitudinal ligament: an update on its biology, epidemiology, and natural history. Neurosurgery 58:1027 – 39; discussion 1027 – 39
135. Ishida Y, Suzuki K, Ohmori K, Kikata Y, Hattori Y (1989) Critical analysis of extensive cervical laminectomy. Neurosurgery 24:215 – 22
136. Isomi T, Panjabi MM, Wang JL, Vaccaro AR, Garfin SR, Patel T (1999) Stabilizing potential of anterior cervical plates in multilevel corpectomies. Spine 24:2219 – 23
137. Itoh T, Tsuji H (1985) Technical improvements and results of laminoplasty for compressive myelopathy in the cervical spine. Spine 10:729 – 36
138. Jansen J, Sjaastad O (2007) Cervicogenic headache: long-term prognosis after neck surgery. Acta Neurol Scand 115:185 – 91
139. Jenis LG, An HS (2000) Neck pain secondary to radiculopathy of the fourth cervical root: an analysis of 12 surgically treated patients. J Spinal Disord 13:345 – 9
140. Jho HD (1996) Microsurgical anterior cervical foraminotomy for radiculopathy: a new approach to cervical disc herniation. J Neurosurg 84:155 – 60
141. Jung A, Schramm J, Lehnerdt K, Herberhold C (2005) Recurrent laryngeal nerve palsy during anterior cervical spine surgery: a prospective study. J Neurosurg Spine 2:123 – 7
142. Kadanka Z, Bednarik J, Vohanka S, Vlach O, Stejskal L, Chaloupka R, Filipovicova D, Surelova D, Adamova B, Novotny O, Nemec M, Smrcka V, Urbanek I (2000) Conservative treatment versus surgery in spondylotic cervical myelopathy: a prospective randomised study. Eur Spine J 9:538 – 44
143. Kadoya S, Nakamura T, Kwak R (1984) A microsurgical anterior osteophytectomy for cervical spondylotic myelopathy. Spine 9:437 – 41
144. Kandziora F, Pflugmacher R, Schafer J, Born C, Duda G, Haas NP, Mittlmeier T (2001) Biomechanical comparison of cervical spine interbody fusion cages. Spine 26:1850 – 7
145. Karjalainen K, Malmivaara A, van Tulder M, Roine R, Jauhiainen M, Hurri H, Koes B (2001) Multidisciplinary biopsychosocial rehabilitation for neck and shoulder pain among working age adults: a systematic review within the framework of the Cochrane Collaboration Back Review Group. Spine 26:174 – 81
146. Katsuura A, Hukuda S, Imanaka T, Miyamoto K, Kanemoto M (1996) Anterior cervical plate used in degenerative disease can maintain cervical lordosis. J Spinal Disord 9:470 – 6
147. Kawai S, Sunago K, Doi K, Saika M, Taguchi T (1988) Cervical laminoplasty (Hattori's method). Procedure and follow-up results. Spine 13:1245 – 50
148. Kelders WP, Kleinrensink GJ, van der Geest JN, Feenstra L, de Zeeuw CI, Frens MA (2003) Compensatory increase of the cervico-ocular reflex with age in healthy humans. J Physiol 553:311 – 7
149. Keller A, von Ammon K, Klaiber R, Waespe W (1993) Spondylogenic cervical myelopathy: conservative and surgical therapy. Schweiz Med Wochenschr 123:1682 – 91
150. Kikuchi S, Macnab I, Moreau P (1981) Localisation of the level of symptomatic cervical disc degeneration. J Bone Joint Surg Br 63-B:272 – 7
151. Kim DH, Vaccaro AR, Henderson FC, Benzel EC (2003) Molecular biology of cervical myelopathy and spinal cord injury: role of oligodendrocyte apoptosis. Spine J 3:510 – 9
152. Kiray A, Arman C, Naderi S, Guvencer M, Korman E (2005) Surgical anatomy of the cervical sympathetic trunk. Clin Anat 18:179 – 85
153. Kirkpatrick JS, Levy JA, Carillo J, Moeini SR (1999) Reconstruction after multilevel corpectomy in the cervical spine. A sagittal plane biomechanical study. Spine 24:1186 – 90; discussion 1191
154. Kongsted A, Qerama E, Kasch H, Bendix T, Bach FW, Korsholm L, Jensen TS (2007) Neck collar, "act-as-usual" or active mobilization for whiplash injury? A randomized parallel-group trial. Spine 32:618 – 26

155. Koshizuka Y, Kawaguchi H, Ogata N, Ikeda T, Mabuchi A, Seichi A, Nakamura Y, Nakamura K, Ikegawa S (2002) Nucleotide pyrophosphatase gene polymorphism associated with ossification of the posterior longitudinal ligament of the spine. J Bone Miner Res 17: 138 – 44
156. Kostuik JP, Connolly PJ, Esses SI, Suh P (1993) Anterior cervical plate fixation with the titanium hollow screw plate system. Spine 18:1273 – 8
157. Krayenbuhl N, Schneider C, Landolt H, Fandino J (2008) Use of an empty, plasmapore-covered titanium cage for interbody fusion after anterior cervical microdiscectomy. J Clin Neurosci 15:11 – 7
158. Kroeling P, Gross A, Houghton PE (2005) Electrotherapy for neck disorders. Cochrane Database Syst Rev:CD004251
159. Krupp W, Schattke H, Muke R (1990) Clinical results of the foraminotomy as described by Frykholm for the treatment of lateral cervical disc herniation. Acta Neurochir (Wien) 107:22 – 9
160. Kulkarni V, Rajshekhar V, Raghuram L (2004) Accelerated spondylotic changes adjacent to the fused segment following central cervical corpectomy: magnetic resonance imaging study evidence. J Neurosurg 100:2 – 6
161. Kumar GR, Maurice-Williams RS, Bradford R (1998) Cervical foraminotomy: an effective treatment for cervical spondylotic radiculopathy. Br J Neurosurg 12:563 – 8
162. Kwon BK, Vaccaro AR, Grauer JN, Beiner JM (2007) The use of rigid internal fixation in the surgical management of cervical spondylosis. Neurosurgery 60:S118 – 29
163. Kwon JW, Lee JW, Kim SH, Choi JY, Yeom JS, Kim HJ, Kwack KS, Moon SG, Jun WS, Kang HS (2007) Cervical interlaminar epidural steroid injection for neck pain and cervical radiculopathy: effect and prognostic factors. Skeletal Radiol 36:431 – 6
164. LaRocca H (1988) Cervical spondylotic myelopathy: natural history. Spine 13:854 – 5
165. Lee TT, Manzano GR, Green BA (1997) Modified open-door cervical expansive laminoplasty for spondylotic myelopathy: operative technique, outcome, and predictors for gait improvement. J Neurosurg 86:64 – 8
166. Lees F, Turner JW (1963) Natural history and prognosis of cervical spondylosis. Br Med J 2:1607 – 10
167. Li Y, Field PM, Raisman G (1999) Death of oligodendrocytes and microglial phagocytosis of myelin precede immigration of Schwann cells into the spinal cord. J Neurocytol 28: 417 – 27
168. Liao JC, Niu CC, Chen WJ, Chen LH (2007) Polyetheretherketone (PEEK) cage filled with cancellous allograft in anterior cervical discectomy and fusion. Int Orthop (in press)
169. Liu KC (1990) Epidemiological study on ossification of the posterior longitudinal ligament (OPLL) in the cervical spine – comparison of the prevalence between Japanese and Taiwanese. Nippon Seikeigeka Gakkai Zasshi 64:401 – 8
170. Lord SM, Barnsley L, Wallis BJ, McDonald GJ, Bogduk N (1996) Percutaneous radio-frequency neurotomy for chronic cervical zygapophyseal-joint pain. N Engl J Med 335: 1721 – 6
171. Lu JJ (2007) Cervical laminectomy: technique. Neurosurgery 60:S149 – 53
172. Lunsford LD, Bissonette DJ, Zorub DS (1980) Anterior surgery for cervical disc disease. Part 2: Treatment of cervical spondylotic myelopathy in 32 cases. J Neurosurg 53:12 – 9
173. Matsumoto M, Toyama Y, Ishikawa M, Chiba K, Suzuki N, Fujimura Y (2000) Increased signal intensity of the spinal cord on magnetic resonance images in cervical compressive myelopathy. Does it predict the outcome of conservative treatment? Spine 25:677 – 82
174. Matsuzaki H, Hoshino M, Kiuchi T, Toriyama S (1989) Dome-like expansive laminoplasty for the second cervical vertebra. Spine 14:1198 – 203
175. Mazanec D, Reddy A (2007) Medical management of cervical spondylosis. Neurosurgery 60:S43 – 50
176. McLain RF (1994) Mechanoreceptor endings in human cervical facet joints. Spine 19:495 – 501
177. Mochida K, Komori H, Okawa A, Muneta T, Haro H, Shinomiya K (1998) Regression of cervical disc herniation observed on magnetic resonance images. Spine 23:990 – 5; discussion 996 – 7
178. Morio Y, Teshima R, Nagashima H, Nawata K, Yamasaki D, Nanjo Y (2001) Correlation between operative outcomes of cervical compression myelopathy and MRI of the spinal cord. Spine 26:1238 – 45
179. Mummaneni PV, Burkus JK, Haid RW, Traynelis VC, Zdeblick TA (2007) Clinical and radiographic analysis of cervical disc arthroplasty compared with allograft fusion: a randomized controlled clinical trial. J Neurosurg Spine 6:198 – 209
180. Mummaneni PV, Haid RW, Rodts GE, Jr. (2007) Combined ventral and dorsal surgery for myelopathy and myeloradiculopathy. Neurosurgery 60:S82 – 9
181. Muro K, O'Shaughnessy B, Ganju A (2007) Infarction of the cervical spinal cord following multilevel transforaminal epidural steroid injection: case report and review of the literature. J Spinal Cord Med 30:385 – 8

182. Murphey F, Simmons JC, Brunson B (1973) Surgical treatment of laterally ruptured cervical disc. Review of 648 cases, 1939 to 1972. J Neurosurg 38:679 – 83
183. Murphy MG, Gado M (1972) Anterior cervical discectomy without interbody bone graft. J Neurosurg 37:71 – 4
184. Nabhan A, Ahlhelm F, Pitzen T, Steudel WI, Jung J, Shariat K, Steimer O, Bachelier F, Pape D (2007) Disc replacement using Pro-Disc C versus fusion: a prospective randomised and controlled radiographic and clinical study. Eur Spine J 16:423 – 30
185. Nabhan A, Ahlhelm F, Shariat K, Pitzen T, Steimer O, Steudel WI, Pape D (2007) The ProDisc-C prosthesis: clinical and radiological experience 1 year after surgery. Spine 32:1935 – 41
186. Nakamura I, Ikegawa S, Okawa A, Okuda S, Koshizuka Y, Kawaguchi H, Nakamura K, Koyama T, Goto S, Toguchida J, Matsushita M, Ochi T, Takaoka K, Nakamura Y (1999) Association of the human NPPS gene with ossification of the posterior longitudinal ligament of the spine (OPLL). Hum Genet 104:492 – 7
187. Nakase H, Park YS, Kimura H, Sakaki T, Morimoto T (2006) Complications and long-term follow-up results in titanium mesh cage reconstruction after cervical corpectomy. J Spinal Disord Tech 19:353 – 7
188. Niemisto L, Kalso E, Malmivaara A, Seitsalo S, Hurri H (2003) Radiofrequency denervation for neck and back pain: a systematic review within the framework of the Cochrane Collaboration Back Review Group. Spine 28:1877 – 88
189. Nowinski GP, Visarius H, Nolte LP, Herkowitz HN (1993) A biomechanical comparison of cervical laminaplasty and cervical laminectomy with progressive facetectomy. Spine 18:1995 – 2004
190. Nurick S (1972) The natural history and the results of surgical treatment of the spinal cord disorder associated with cervical spondylosis. Brain 95:101 – 8
191. Nurick S (1972) The pathogenesis of the spinal cord disorder associated with cervical spondylosis. Brain 95:87 – 100
192. O'Laoire SA, Thomas DG (1983) Spinal cord compression due to prolapse of cervical intervertebral disc (herniation of nucleus pulposus). Treatment in 26 cases by discectomy without interbody bone graft. J Neurosurg 59:847 – 53
193. Odom GL, Finney W, Woodhall B (1958) Cervical disk lesions. JAMA 166:23 – 28
194. Ogino H, Tada K, Okada K, Yonenobu K, Yamamoto T, Ono K, Namiki H (1983) Canal diameter, anteroposterior compression ratio, and spondylotic myelopathy of the cervical spine. Spine 8:1 – 15
195. Ohshio I, Hatayama A, Kaneda K, Takahara M, Nagashima K (1993) Correlation between histopathologic features and magnetic resonance images of spinal cord lesions. Spine 18: 1140 – 9
196. Ohtsuka K, Terayama K, Yanagihara M, Wada K, Kasuga K, Machida T, Furukawa K (1986) An epidemiological survey on ossification of ligaments in the cervical and thoracic spine in individuals over 50 years of age. Nippon Seikeigeka Gakkai Zasshi 60:1087 – 98
197. Olivero WC, Dulebohn SC (2002) Results of halter cervical traction for the treatment of cervical radiculopathy: retrospective review of 81 patients. Neurosurg Focus 12:ECP1
198. Ono K, Ebara S, Fuji T, Yonenobu K, Fujiwara K, Yamashita K (1987) Myelopathy hand. New clinical signs of cervical cord damage. J Bone Joint Surg Br 69:215 – 9
199. Orr RD, Postak PD, Rosca M, Greenwald AS (2007) The current state of cervical and lumbar spinal disc arthroplasty. J Bone Joint Surg Am 89 Suppl 3:70 – 5
200. Palit M, Schofferman J, Goldthwaite N, Reynolds J, Kerner M, Keaney D, Lawrence-Miyasaki L (1999) Anterior discectomy and fusion for the management of neck pain. Spine 24:2224 – 8
201. Panjabi M, White A, 3rd (1988) Biomechanics of nonacute cervical spinal cord trauma. Spine 13:838 – 42
202. Papavero L, Heese O, Klotz-Regener V, Buchalla R, Schroder F, Westphal M (2007) The impact of esophagus retraction on early dysphagia after anterior cervical surgery: does a correlation exist? Spine 32:1089 – 93
203. Papavero L, Zwonitzer R, Burkard I, Klose K, Herrmann HD (2002) A composite bone graft substitute for anterior cervical fusion: assessment of osseointegration by quantitative computed tomography. Spine 27:1037 – 43
204. Park E, Velumian AA, Fehlings MG (2004) The role of excitotoxicity in secondary mechanisms of spinal cord injury: a review with an emphasis on the implications for white matter degeneration. J Neurotrauma 21:754 – 74
205. Parke WW (1988) Correlative anatomy of cervical spondylotic myelopathy. Spine 13:831 – 7
206. Pavlov H, Torg JS, Robie B, Jahre C (1987) Cervical spinal stenosis: determination with vertebral body ratio method. Radiology 164:771 – 5
207. Payne EE, Spillane JD (1957) The cervical spine; an anatomico-pathological study of 70 specimens (using a special technique) with particular reference to the problem of cervical spondylosis. Brain 80:571 – 96
208. Peloso P, Gross A, Haines T, Trinh K, Goldsmith CH, Aker P (2005) Medicinal and injection therapies for mechanical neck disorders. Cochrane Database Syst Rev:CD000319

209. Penning L, Wilmink JT, van Woerden HH, Knol E (1986) CT myelographic findings in degenerative disorders of the cervical spine: clinical significance. AJR Am J Roentgenol 146:793 – 801
210. Peolsson A, Vavruch L, Hedlund R (2007) Long-term randomised comparison between a carbon fibre cage and the Cloward procedure in the cervical spine. Eur Spine J 16:173 – 8
211. Persson LC, Carlsson CA, Carlsson JY (1997) Long-lasting cervical radicular pain managed with surgery, physiotherapy, or a cervical collar. A prospective, randomized study. Spine 22:751 – 8
212. Persson LC, Moritz U, Brandt L, Carlsson CA (1997) Cervical radiculopathy: pain, muscle weakness and sensory loss in patients with cervical radiculopathy treated with surgery, physiotherapy or cervical collar. A prospective, controlled study. Eur Spine J 6:256 – 66
213. Pettorossi VE, Manni E, Errico P, Ferraresi A, Bortolami R (1997) Otolithic and extraocular muscle proprioceptive influences on the spatial organization of the vestibulo- and cervico-ocular quick phases. Acta Otolaryngol 117:139 – 42
214. Pfirrmann CW, Binkert CA, Zanetti M, Boos N, Hodler J (2000) Functional MR imaging of the craniocervical junction. Correlation with alar ligaments and occipito-atlantoaxial joint morphology: a study in 50 asymptomatic subjects. Schweiz Med Wochenschr 130:645 – 51
215. Pfirrmann CW, Binkert CA, Zanetti M, Boos N, Hodler J (2001) MR morphology of alar ligaments and occipitoatlantoaxial joints: study in 50 asymptomatic subjects. Radiology 218:133 – 7
216. Pflugmacher R, Schleicher P, Gumnior S, Turan O, Scholz M, Eindorf T, Haas NP, Kandziora F (2004) Biomechanical comparison of bioabsorbable cervical spine interbody fusion cages. Spine 29:1717 – 22
217. Phillips DG (1973) Surgical treatment of myelopathy with cervical spondylosis. J Neurol Neurosurg Psychiatry 36:879 – 84
218. Phillips FM, Garfin SR (2005) Cervical disc replacement. Spine 30:S27 – 33
219. Plotz GM, Benini A (1995) Surgical treatment of degenerative spondylolisthesis in the lumbar spine: no reposition without prior decompression. Acta Neurochir (Wien) 137:188 – 91
220. Plotz GM, Benini A, Kramer M (1996) Micro-technological anterior discectomy without fusion in cervical disk displacement with radicular symptoms. Orthopade 25:546 – 53
221. Profeta G, de Falco R, Ianniciello G, Profeta L, Cigliano A, Raja AI (2000) Preliminary experience with anterior cervical microdiscectomy and interbody titanium cage fusion (Novus CT-Ti) in patients with cervical disc disease. Surg Neurol 53:417 – 26
222. Radhakrishnan K, Litchy WJ, O'Fallon WM, Kurland LT (1994) Epidemiology of cervical radiculopathy. A population-based study from Rochester, Minnesota, 1976 through 1990. Brain 117(2):325 – 35
223. Rao RD, Currier BL, Albert TJ, Bono CM, Marawar SV, Poelstra KA, Eck JC (2007) Degenerative cervical spondylosis: clinical syndromes, pathogenesis, and management. J Bone Joint Surg Am 89:1360 – 78
224. Ratliff J, Voorhies RM (2001) Outcome study of surgical treatment for axial neck pain. South Med J 94:595 – 602
225. Ratliff JK, Cooper PR (2003) Cervical laminoplasty: a critical review. J Neurosurg 98:230 – 8
226. Riew KD, Sethi NS, Devney J, Goette K, Choi K (1999) Complications of buttress plate stabilization of cervical corpectomy. Spine 24:2404 – 10
227. Riley LH, 3rd, Skolasky RL, Albert TJ, Vaccaro AR, Heller JG (2005) Dysphagia after anterior cervical decompression and fusion: prevalence and risk factors from a longitudinal cohort study. Spine 30:2564 – 9
228. Riley LH, Robinson RA, Johnsson KA, Walker AE (1969) The results of anterior interbody fusion of the cervical spine. Review of ninety-three consecutive cases. J Neurosurg 30:127 – 133
229. Robinson RA, Smith GW (1955) Anterolateral cervical disc removal and interbody fusion for cervical disc syndrome. Bull Johns Hopkins Hosp 96:223
230. Rubinstein SM, Leboeuf-Yde C, Knol DL, de Koekkoek TE, Pfeifle CE, van Tulder MW (2007) The benefits outweigh the risks for patients undergoing chiropractic care for neck pain: a prospective, multicenter, cohort study. J Manipulative Physiol Ther 30:408 – 18
231. Rubinstein SM, Pool JJ, van Tulder MW, Riphagen, II, de Vet HC (2007) A systematic review of the diagnostic accuracy of provocative tests of the neck for diagnosing cervical radiculopathy. Eur Spine J 16:307 – 19
232. Rydevik B, Garfin S (1989) Spinal nerve root compression. In: Szabo RM (ed) Nerve root compression syndromes: diagnosis and treatment. Slack Medical, New York, pp 247 – 261
233. Ryu SI, Mitchell M, Kim DH (2006) A prospective randomized study comparing a cervical carbon fiber cage to the Smith-Robinson technique with allograft and plating: up to 24 months follow-up. Eur Spine J 15:157 – 64
234. Saal JS, Saal JA, Yurth EF (1996) Nonoperative management of herniated cervical intervertebral disc with radiculopathy. Spine 21:1877 – 83
235. Sakaura H, Hosono N, Mukai Y, Ishii T, Yoshikawa H (2003) C5 palsy after decompression surgery for cervical myelopathy: review of the literature. Spine 28:2447 – 51

236. Sakou T, Miyazaki A, Tomimura K, Maehara T, Frost HM (1979) Ossification of the posterior longitudinal ligament of the cervical spine: subtotal vertebrectomy as a treatment. Clin Orthop Relat Res:58 – 65
237. Salemi G, Savettieri G, Meneghini F, Di Benedetto ME, Ragonese P, Morgante L, Reggio A, Patti F, Grigoletto F, Di Perri R (1996) Prevalence of cervical spondylotic radiculopathy: a door-to-door survey in a Sicilian municipality. Acta Neurol Scand 93:184 – 8
238. Salvi FJ, Jones JC, Weigert BJ (2006) The assessment of cervical myelopathy. Spine J 6:182S–189S
239. Sampath P, Bendebba M, Davis JD, Ducker TB (2000) Outcome of patients treated for cervical myelopathy. A prospective, multicenter study with independent clinical review. Spine 25:670 – 6
240. Saringer W, Nobauer I, Reddy M, Tschabitscher M, Horaczek A (2002) Microsurgical anterior cervical foraminotomy (uncoforaminotomy) for unilateral radiculopathy: clinical results of a new technique. Acta Neurochir (Wien) 144:685 – 94
241. Saringer WF, Reddy B, Nobauer-Huhmann I, Regatschnig R, Reddy M, Tschabitscher M, Knosp E (2003) Endoscopic anterior cervical foraminotomy for unilateral radiculopathy: anatomical morphometric analysis and preliminary clinical experience. J Neurosurg 98:171 – 80
242. Sasso RC, Ruggiero RA, Jr., Reilly TM, Hall PV (2003) Early reconstruction failures after multilevel cervical corpectomy. Spine 28:140 – 2
243. Sasso RC, Smucker JD, Hacker RJ, Heller JG (2007) Clinical outcomes of BRYAN cervical disc arthroplasty: a prospective, randomized, controlled, multicenter trial with 24-month follow-up. J Spinal Disord Tech 20:481 – 91
244. Savolainen S, Rinne J, Hernesniemi J (1998) A prospective randomized study of anterior single-level cervical disc operations with long-term follow-up: surgical fusion is unnecessary. Neurosurgery 43:51 – 5
245. Scanlon GC, Moeller-Bertram T, Romanowsky SM, Wallace MS (2007) Cervical transforaminal epidural steroid injections: more dangerous than we think? Spine 32:1249 – 56
246. Schellhas KP, Smith MD, Gundry CR, Pollei SR (1996) Cervical discogenic pain. Prospective correlation of magnetic resonance imaging and discography in asymptomatic subjects and pain sufferers. Spine 21:300 – 11; discussion 311 – 2
247. Schneeberger AG, Boos N, Schwarzenbach O, Aebi M (1999) Anterior cervical interbody fusion with plate fixation for chronic spondylotic radiculopathy: A 2- to 8-year follow-up. J Spinal Disord 12:215 – 220
248. Schroder J, Schul C, Hasselblatt M, Wassmann H (2007) Bony fusion through an empty cervical disc interspace implant. Zentralbl Neurochir 68:139 – 41
249. Scoville WB (1966) Types of cervical disk lesions and their surgical approaches. JAMA 196:479 – 81
250. Shedid D, Benzel EC (2007) Cervical spondylosis anatomy: pathophysiology and biomechanics. Neurosurgery 60:S7 – 13
251. Shimomura T, Sumi M, Nishida K, Maeno K, Tadokoro K, Miyamoto H, Kurosaka M, Doita M (2007) Prognostic factors for deterioration of patients with cervical spondylotic myelopathy after nonsurgical treatment. Spine 32:2474 – 2479
252. Shimomura Y, Hukuda S, Mizuno S (1968) Experimental study of ischemic damage to the cervical spinal cord. J Neurosurg 28:565 – 81
253. Shin WR, Kim HI, Shin DG, Shin DA (2006) Radiofrequency neurotomy of cervical medial branches for chronic cervicobrachialgia. J Korean Med Sci 21:119 – 25
254. Shingyouchi Y, Nagahama A, Niida M (1996) Ligamentous ossification of the cervical spine in the late middle-aged Japanese men. Its relation to body mass index and glucose metabolism. Spine 21:2474 – 8
255. Shuman SL, Bresnahan JC, Beattie MS (1997) Apoptosis of microglia and oligodendrocytes after spinal cord contusion in rats. J Neurosci Res 50:798 – 808
256. Siebenrock KA, Aebi M (1994) Cervical discography in discogenic pain syndrome and its predictive value for cervical fusion. Arch Orthop Trauma Surg 113:199 – 203
257. Sim FH, Svien HJ, Bickel WH, Janes JM (1974) Swan-neck deformity following extensive cervical laminectomy. A review of twenty-one cases. J Bone Joint Surg Am 56:564 – 80
258. Simmons EH, Bhalla SK (1969) Anterior cervical discectomy and fusion. A clinical and biomechanical study with eight-year follow-up. J Bone Joint Surg Br 51:225 – 37
259. Singh A, Crockard HA (2001) Comparison of seven different scales used to quantify severity of cervical spondylotic myelopathy and post-operative improvement. J Outcome Meas 5:798 – 818
260. Smith GW, Robinson RA (1958) The treatment of certain cervical-spine disorders by anterior removal of the intervertebral disc and interbody fusion. J Bone Joint Surg Am 40-A:607 – 24
261. Soderlund CH, Pointillart V, Pedram M, Andrault G, Vital JM (2004) Radiolucent cage for cervical vertebral reconstruction: a prospective study of 17 cases with 2-year minimum follow-up. Eur Spine J 13:685 – 90
262. Strobel K, Pfirrmann CW, Schmid M, Hodler J, Boos N, Zanetti M (2004) Cervical nerve root blocks: indications and role of MR imaging. Radiology 233:87 – 92

263. Swank ML, Lowery GL, Bhat AL, McDonough RF (1997) Anterior cervical allograft arthrodesis and instrumentation: multilevel interbody grafting or strut graft reconstruction. Eur Spine J 6:138 – 43
264. Symon L, Lavender P (1967) The surgical treatment of cervical spondylotic myelopathy. Neurology 17:117 – 27
265. Tan TC, Black PM (2002) Sir Victor Horsley (1857 – 1916): pioneer of neurological surgery. Neurosurgery 50:607 – 11; discussion 611 – 2
266. Terayama K, Ohtsuka K, Merlini L, Albisinni U, Gui L (1987) Ossification of the spinal ligament. A radiographic reevaluation in Bologna, Italy. Nippon Seikeigeka Gakkai Zasshi 61:1373 – 8
267. Teresi LM, Lufkin RB, Reicher MA, Moffit BJ, Vinuela FV, Wilson GM, Bentson JR, Hanafee WN (1987) Asymptomatic degenerative disk disease and spondylosis of the cervical spine: MR imaging. Radiology 164:83 – 8
268. Thalgott JS, Xiongsheng C, Giuffre JM (2003) Single stage anterior cervical reconstruction with titanium mesh cages, local bone graft, and anterior plating. Spine J 3:294 – 300
269. Torg JS, Pavlov H, Genuario SE, Sennett B, Wisneski RJ, Robie BH, Jahre C (1986) Neurapraxia of the cervical spinal cord with transient quadriplegia. J Bone Joint Surg Am 68:1354 – 70
270. Vaccaro AR, Falatyn SP, Scuderi GJ, Eismont FJ, McGuire RA, Singh K, Garfin SR (1998) Early failure of long segment anterior cervical plate fixation. J Spinal Disord 11:410 – 5
271. van Jonbergen HP, Spruit M, Anderson PG, Pavlov PW (2005) Anterior cervical interbody fusion with a titanium box cage: early radiological assessment of fusion and subsidence. Spine J 5:645 – 9; discussion 649
272. Van Zundert J, Harney D, Joosten EA, Durieux ME, Patijn J, Prins MH, Van Kleef M (2006) The role of the dorsal root ganglion in cervical radicular pain: diagnosis, pathophysiology, and rationale for treatment. Reg Anesth Pain Med 31:152 – 67
273. Vavruch L, Hedlund R, Javid D, Leszniewski W, Shalabi A (2002) A prospective randomized comparison between the Cloward procedure and a carbon fiber cage in the cervical spine: a clinical and radiologic study. Spine 27:1694 – 701
274. Verbiest H (1968) A lateral approach to the cervical spine: technique and indications. J Neurosurg 28:191 – 203
275. Vernon H, Mior S (1991) The Neck Disability Index: a study of reliability and validity. J Manipulative Physiol Ther 14:409 – 15
276. Vitzthum HE, Dalitz K (2007) Analysis of five specific scores for cervical spondylogenic myelopathy. Eur Spine J 16:2096 – 2103
277. Wada E, Yonenobu K, Suzuki S, Kanazawa A, Ochi T (1999) Can intramedullary signal change on magnetic resonance imaging predict surgical outcome in cervical spondylotic myelopathy? Spine 24:455 – 61; discussion 462
278. Wainner RS, Gill H (2000) Diagnosis and nonoperative management of cervical radiculopathy. J Orthop Sports Phys Ther 30:728 – 44
279. Wang JC, McDonough PW, Endow K, Kanim LE, Delamarter RB (1999) The effect of cervical plating on single-level anterior cervical discectomy and fusion. J Spinal Disord 12:467 – 71
280. Wang JC, McDonough PW, Endow KK, Delamarter RB (2000) Increased fusion rates with cervical plating for two-level anterior cervical discectomy and fusion. Spine 25:41 – 5
281. Wang JC, McDonough PW, Kanim LE, Endow KK, Delamarter RB (2001) Increased fusion rates with cervical plating for three-level anterior cervical discectomy and fusion. Spine 26:643 – 6; discussion 646 – 7
282. Wang PN, Chen SS, Liu HC, Fuh JL, Kuo BI, Wang SJ (1999) Ossification of the posterior longitudinal ligament of the spine. A case-control risk factor study. Spine 24:142 – 4; discussion 145
283. Weishaupt D, Zanetti M, Hodler J, Min K, Fuchs B, Pfirrmann CW, Boos N (2001) Painful lumbar disk derangement: relevance of endplate abnormalities at MR imaging. Radiology 218:420 – 7
284. Wertheim SB, Bohlman HH (1987) Occipitocervical fusion. Indications, technique, and long-term results in thirteen patients. J Bone Joint Surg Am 69:833 – 6
285. Wheeler AH, Goolkasian P, Baird AC, Darden BV, 2nd (1999) Development of the neck pain and disability scale. Item analysis, face, and criterion-related validity. Spine 24:1290 – 4
286. White AA, 3rd, Johnson RM, Panjabi MM, Southwick WO (1975) Biomechanical analysis of clinical stability in the cervical spine. Clin Orthop Relat Res:85 – 96
287. White AA, Panjabi MM (1990) Clinical biomechanics of the spine, 2nd edn. JB Lippincott Co, Philadelphia, pp 528 – 570
288. White AA, Southwick WO, DePonte RK, Gainor JW, Hardy R (1973) Relief of pain by anterior cervical-spine fusion for spondylosis. A report of sixty-five patients. J Bone Joint Surg (Am) 55A:525 – 534
289. White AP, Biswas D, Smart LR, Haims A, Grauer JN (2007) Utility of flexion-extension radiographs in evaluating the degenerative cervical spine. Spine 32:975 – 9

290. Whitecloud TS, 3rd, Seago RA (1987) Cervical discogenic syndrome. Results of operative intervention in patients with positive discography. Spine 12:313 – 6
291. Wieser ES, Wang JC (2007) Surgery for neck pain. Neurosurgery 60:S51 – 6
292. Williams JL, Allen MB, Harkess JW (1968) Late results of cervical discectomy and interbody fusion: Some factors influencing the results. J Bone Joint Surg (Am) 50-A:277 – 286
293. Woiciechowsky C (2005) Distractable vertebral cages for reconstruction after cervical corpectomy. Spine 30:1736 – 41
294. Yamazaki T, Yanaka K, Sato H, Uemura K, Tsukada A, Nose T (2003) Cervical spondylotic myelopathy: surgical results and factors affecting outcome with special reference to age differences. Neurosurgery 52:122 – 6; discussion 126
295. Ying Z, Xinwei W, Jing Z, Shengming X, Bitao L, Tao Z, Wen Y (2007) Cervical corpectomy with preserved posterior vertebral wall for cervical spondylotic myelopathy: a randomized control clinical study. Spine 32:1482 – 7
296. Ylinen J (2007) Physical exercises and functional rehabilitation for the management of chronic neck pain. Eura Medicophys 43:119 – 32
297. Yonenobu K (2000) Cervical radiculopathy and myelopathy: when and what can surgery contribute to treatment? Eur Spine J 9:1 – 7
298. Yonenobu K, Fuji T, Ono K, Okada K, Yamamoto T, Harada N (1985) Choice of surgical treatment for multisegmental cervical spondylotic myelopathy. Spine 10:710 – 6
299. Yonenobu K, Okada K, Fuji T, Fujiwara K, Yamashita K, Ono K (1986) Causes of neurologic deterioration following surgical treatment of cervical myelopathy. Spine 11:818 – 23
300. Young WF (2000) Cervical spondylotic myelopathy: a common cause of spinal cord dysfunction in older persons. Am Fam Physician 62:1064 – 70, 1073
301. Yu YL, Jones SJ (1985) Somatosensory evoked potentials in cervical spondylosis. Correlation of median, ulnar and posterior tibial nerve responses with clinical and radiological findings. Brain 108(2):273 – 300
302. Yukawa Y, Kato F, Yoshihara H, Yanase M, Ito K (2007) MR T2 image classification in cervical compression myelopathy: predictor of surgical outcomes. Spine 32:1675 – 8; discussion 1679
303. Zdeblick TA, Ducker TB (1991) The use of freeze-dried allograft bone for anterior cervical fusions. Spine 16:726 – 9
304. Zdeblick TA, Hughes SS, Riew KD, Bohlman HH (1997) Failed anterior cervical discectomy and arthrodesis. Analysis and treatment of thirty-five patients. J Bone Joint Surg (Am) 79-A:523 – 532
305. Zeidman SM, Ducker TB (1993) Posterior cervical laminoforaminotomy for radiculopathy: review of 172 cases. Neurosurgery 33:356 – 62
306. Zeidman SM, Ducker TB, Raycroft J (1997) Trends and complications in cervical spine surgery: 1989 – 1993. J Spinal Disord 10:523 – 6
307. Zheng Y, Liew SM, Simmons ED (2004) Value of magnetic resonance imaging and discography in determining the level of cervical discectomy and fusion. Spine 29:2140 – 5; discussion 2146
308. Zhou HY, Chen AM, Guo FJ, Liao GJ, Xiao WD (2006) Sensory and sympathetic innervation of cervical facet joint in rats. Chin J Traumatol 9:377 – 80
309. Zoega B, Karrholm J, Lind B (1998) One-level cervical spine fusion. A randomized study, with or without plate fixation, using radiostereometry in 27 patients. Acta Orthop Scand 69:363 – 8

# 18 Disc Herniation and Radiculopathy

Massimo Leonardi, Norbert Boos

## Core Messages

- ✔ Lumbar disc herniation is most frequently found in the 3rd and 4th decades of life at the level of L4/5 and L5/S1
- ✔ The cardinal symptom of lumbar disc herniation is radicular leg pain with or without a sensorimotor deficit of the affected nerve root
- ✔ The radiculopathy is not only caused by a mechanical compression of the nerve root but also by an inflammatory process caused by nucleus pulposus tissue
- ✔ MRI is the imaging modality of choice for the diagnosis of disc herniation
- ✔ In contrast to large disc extrusion and sequestrations, disc protrusions are frequently found in asymptomatic individuals
- ✔ The best discriminator of symptomatic and asymptomatic disc herniation is nerve root compromise
- ✔ The natural history of lumbar radiculopathy is benign
- ✔ Mild radiculopathy responds well to non-operative treatment, but surgical treatment results in better short-term results in selected patients
- ✔ Severe radiculopathy responds poorly to non-operative treatment and should be treated surgically
- ✔ With the exception of chemonucleolysis, none of the minimally invasive surgical techniques has been shown to provide a better outcome than conservative treatment
- ✔ The surgical treatment of choice is an open standard interlaminar discectomy or microsurgical discectomy
- ✔ Cauda equina syndromes require an emergency decompression and should be treated by complete laminectomy and wide decompression
- ✔ The surgical results are crucially dependent on patient selection
- ✔ There is increasing scientific evidence that surgically treated patients have a better short term outcome than patients treated non-operatively

## Epidemiology

Sciatica has been known since antiquity

Sciatica has been known since antiquity, but the relationship between sciatica and disc herniation was not discovered until the beginning of the 20th century. In 1934, Mixter and Barr were the first to describe this correlation in their landmark paper [95]. At that time, herniated discs were removed by a **transdural approach**. In 1939, Love [84] and Semmes [122] independently developed the classic approach, which consisted of a subtotal laminectomy and retraction of the thecal sac medially to expose and remove the disc herniation [5]. Herniated nucleus pulposus (HNP) used to be synonymous with disc herniation, but the definition of disc herniation today is wider. A disc herniation can be defined as a focal displacement of nuclear, annular, or endplate material beyond the margins of the adjacent vertebral bodies. As a result of the displacement of the disc material, there is a focal contour abnormality of the disc margin [52].

A herniation is a focal displacement of disc material beyond the vertebral body margins

Among a cohort of 2 077 employees in Finland who had no sciatic pain at baseline, 194 (9 %) experienced sciatic pain during a 1-year follow-up period. Women and men had an equal risk of suffering from sciatic pain, but the incidence increased with age. Smokers who have smoked for more than 15 years and sub-

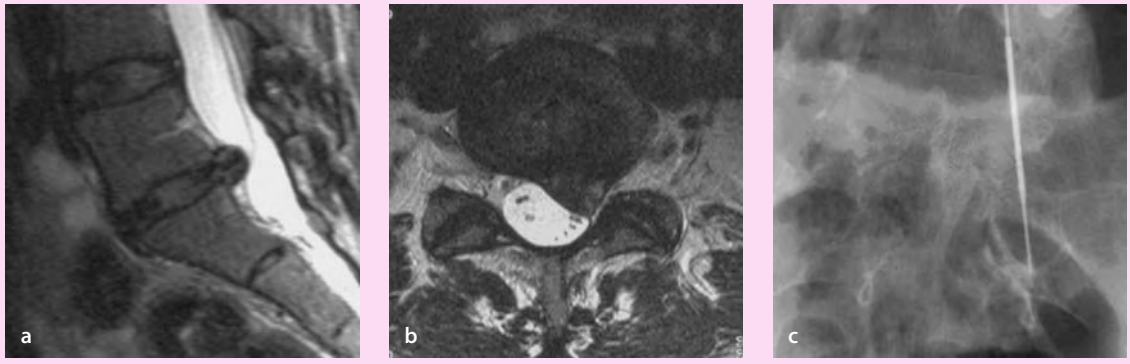


## Case Introduction

A 42-year-old mother of two young children developed severe leg pain without a previous episode of back pain. Within one week, the leg pain increased and the patient developed a mild sensorimotor deficit of S1. At the time of presentation 4 weeks later, the patient still complained of incapacitating leg pain. T2 weighted MR images (a, b) show a large disc extrusion compressing the left S1 nerve root. The patient did not want surgery because of her family situation. A nerve root block (c) was done with an injection of corticosteroids and local anesthetics which resulted in a regression of the severe pain within 3 days. The motor deficit recovered completely during a 3-month period. At one year follow-up, the patient only occasionally had back pain without sciatica. However, she desired to have a repeat MRI scan for prognosis. Follow-up MR images (d, e) demonstrate a resolution of the large herniation.

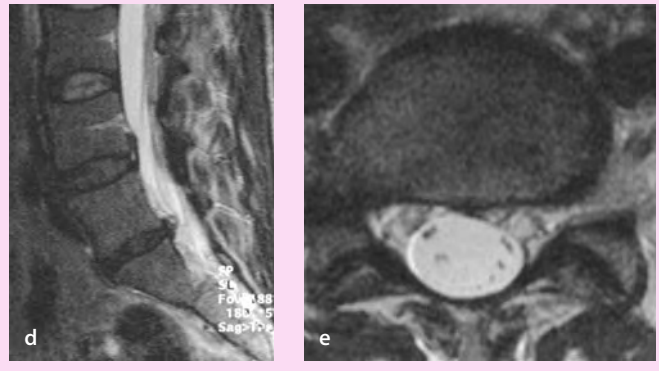


jects with mental stress are at risk from developing sciatic pain [94]. In surveys done in the 1950s, 40 % of men and 35 % of women older than 34 years experienced a history of low back and leg pain [79]. In a Swedish sample of 15- to 71-year-old females, sciatica was reported in 13.8 % [53]. In a Danish population of 4 753 men aged 40 – 59 years, 11 % experienced sciatica during 1 year of observation [49]. Bell and Rothman found prevalences of sciatic pain in a population older than 35 years of 4.8 % in men and 2.5 % in women [17]. The first episode of sciatic pain was at an average age of 37 years, with precipitating low back pain in 76 % of these patients a decade earlier [17]. In a study by Waddell on about 900 patients with low back pain, 70 % also complained of leg pain. Of these, 23 % had leg pain that was characterized as true radicular pain [141]. The epidemiology of cauda equina and conus medullaris lesions is not well known. In a study of **cauda equina/conus medullaris lesions**, an **annual incidence** rate of 3.4/1.5 per million, and period prevalence of 8.9/4.5 per 100 000 population, were calculated [110].

The annual incidence of sciatica is about 5 – 10 %

In contrast to lumbar disc herniation, symptomatic thoracic disc herniations are rare. An incidence of 0.25 – 0.75 % of protruded discs is found in the thoracic region. A peak incidence is noted in the 4th decade with 75 % of the protruded discs occurring below T8. However, the prevalence of **asymptomatic disc herniations** is high [150, 153].

The prevalence of asymptomatic thoracic disc herniations is as high as in the lumbar spine

Lumbar disc herniation is the pathologic condition for which spinal surgery is most often performed. In a computer aided analysis of 2 504 operations for disc herniation, Spangfort [128] reported that the average age was 40.8 years (range, 15 – 74 years). Males were operated on more than twice as often as female patients

Discectomy is the most frequently performed spinal surgery

(sex ratio 2:1). Surgery was done most often at the level of L5/S1 (50.5 %) and L4/5 (47.5 %) [128].

The incidence of disc surgery is 160/100 000 inhabitants in the United States and 62/100 000 in Switzerland, indicating **large geographic variations** [6, 18, 144, 145]. Five- to 15-fold variations in the surgery rates have been documented in geographically adjacent small areas, between large regions of the United States, and in other Western countries [11, 34].

Discectomy rates exhibit strong geographic variations

## Pathogenesis

Lumbar intervertebral disc herniation typically occurs as a result of age-related changes within the extracellular matrix of the intervertebral disc, which can lead to a weakening of the anulus fibrosus, making it susceptible to fissuring and tearing (see Chapter 4).

### Risk Factors

Andersson [7] has emphasized that the identification of risk factors in low back pain and sciatica is hampered by methodological limitations. In the pre-MRI era, sciatica was used synonymously with disc herniation and radiculopathy. Image verification most often was not available. Therefore, many epidemiologic studies are confounded by the missing proof of a disc herniation in sciatica. Nevertheless, several occupational factors are believed to be associated with an **increased risk** of sciatica and disc herniation:

Occupational physical factors increase the risk of disc herniation

- frequent heavy lifting [66, 96]
- frequent twisting and bending [96]
- exposure to vibration [65, 66]
- sedentary activity [65]
- driving [67]

A more comprehensive analysis of **risk factors**, however, showed that, e.g., professional driving, was not associated with any overall tendency for greater degeneration or pathology in occupational drivers in a case control twin study [16]. Battié and Videman have demonstrated in studies of Finnish monozygotic twins that **heredity** has a dominant role in disc degeneration and would explain the variance of up to 74 % seen in adult populations [15]. The studies by Heikkilä et al. [51] and Masui et al. [91] support the strong influence of **genetic disposition** in disc herniation and sciatica. It can be deduced that the role of the aforementioned classic occupational risk factors was overestimated and they are assumed only to play a minor modulating role.

Controversy continues with regard to the occurrence of **traumatic disc herniations**. However, true traumatic disc herniation is extremely rare without additional severe injuries such as vertebral fractures or ligamentous injuries [1, 3, 44, 107]. In an in vitro biomechanical study, a disc protrusion could be produced as a result of a hyperflexion injury [2]. We recommend being very tentative using the term "traumatic disc herniation" because the injury frequently affects a motion segment which already exhibits age-related (degenerative) changes.

True traumatic disc herniations are very rare in a clinical setting

The clinical syndrome of sciatica is a direct result of the effect of the disc herniation on the adjacent nerve root. This leads to radiculopathy, which is characterized by radiating pain following a dermatomal distribution. This symptom can be accompanied by nerve root root tension signs and a sensorimotor deficit (nerve dysfunction).

## Radiculopathy

Both mechanical compression and chemical irritation lead to radiculopathy

The pathophysiology of radiculopathy caused by a herniated disc is still not completely understood. In the last decade, substantial progress was gained in our understanding of disc-related radiculopathy [103]. Today, there is evidence that sciatica involves a compromise of the nerve root both in terms of mechanical deformation and chemical irritation (Fig. 1).

### Mechanical Deformation

The extent of the nerve root compromise by mechanical deformation is a result of several effects:

- impaired blood supply
- edema
- onset of compression (rapid or slow progression)
- compromised CSF-related nutritional fluid flow
- level of compression (one or multiple)

Nerve root compression leads to intraneural edema

Olmarker et al. demonstrated in an experimental model of the pig cauda equina that there was a significant correlation between the **systemic blood pressure** and the pressure required to stop the flow in the nerve root arterioles [105]. In nerve roots exposed to significant compression, an **intraneural edema** developed. Olmarker et al. [104] further demonstrated that a rapid onset of compression induced more pronounced effects than a slow onset at corresponding pressure levels. The authors assumed that this observed difference may be related to the magnitude of intraneural edema formed outside the compression zone. The results also indicate that the **nutritional transport** might be impaired at very low pressure levels and that diffusion from adjacent tissues with a better nutritional supply, including the cerebrospinal fluid, may not fully compensate for any compression-induced impair-

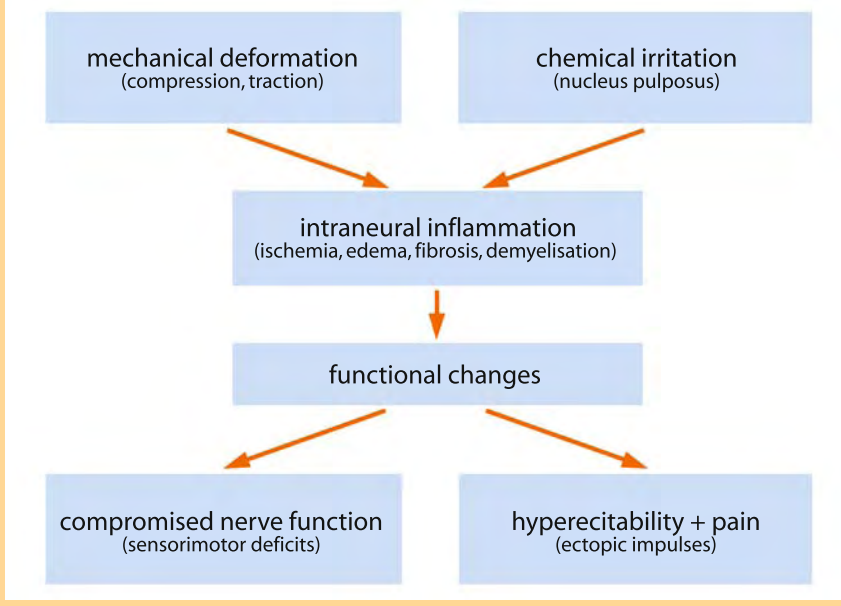


**Figure 1. Pathophysiology of radiculopathy**

Modified from Rydevik and Garfin [118].

ment of the **intraneural blood flow** [104]. In a subsequent study, Takahashi et al. [133] showed that double-level compression of the cauda equina induces impairment of blood flow, not only at the compression sites, but also in the intermediate nerve segments located between two compression sites, even at very low pressures.

Nerve root compression is not necessarily painful

In 1947, Inman and Saunders [57] realized that the concept that sciatica is caused solely by compression of the nerve root is not based on experimental evidence. In a clinical study on patients with disc herniation, Smyth and Wright [127] passed a nylon strip around the involved nerve root and brought its two ends to the surface. With this setup, the authors were able to show that the affected nerve root remains hypersensitive and causes pain when gently pulling at the ends of the nylon strips. Later, Kuslich et al. [75] demonstrated in a less traumatic approach that only the compressed nerve root consistently produces sciatica, while the normal, uncompressed, or unstretched nerve root was completely insensitive without causing pain. These clinical observations [75] were corroborated by an in vivo model which showed that ligation of the nerve root per se does not cause pain. Only the use of irritant gut suture material made the mechanical injury painful [63, 64]. It was hypothesized that **chemical factors** from the chromic gut play a role in the pathophysiology and development of lumbar radiculopathy [63].

### Chemical Irritation

Chemical irritation plays a decisive role in sciatica

The involvement of a chemical irritation in the pathophysiology of sciatica has been suspected for many years [37, 88, 89]. First evidence of the **inflammatory properties of nucleus pulposus** was presented by McCarron et al. [92]. In a study on dogs, nucleus pulposus material was applied in the epidural space and resulted in inflammatory alterations. Olmarker et al. [106] demonstrated in a pig model that epidural application of autologous nucleus pulposus without mechanical compression induces nerve tissue injury by mechanisms other than mechanical compression. Such mechanisms are based on the **direct biochemical effects** of nucleus pulposus components on nerve fiber structure and function and microvascular changes including inflammatory reactions in the nerve [106]. In subsequent studies, the same researcher showed that the epidural application of nucleus pulposus causes proinflammatory reactions as indicated by leukotaxis and an increase in vascular permeability [100], results in an increased endoneurial fluid pressure and decreased blood flow in the dorsal root ganglia [154], and leads to morphologic changes in terms of minor axonal and Schwann cell damage [28]. Membrane-bound structures and substances of nucleus pulposus cells are responsible for axonal changes, a characteristic **myelin injury**, increased vascular permeability, and intravascular coagulation. These effects have been found to be efficiently blocked by methylprednisolone [101].

### Proinflammatory Cytokines

TNFα plays a dominant role in the generation of sciatica

In searching for the pathophysiologic mechanisms of chemical irritation, the role of several substances and **proinflammatory cytokines** was explored [103], i.e.:

- hydrogen [37]
- nitric oxide (NO) [62]
- phospholipase (PL) $A_2$ and $E_2$ [62, 119]
- tumor necrosis factor (TNF) α [102]
- interleukin (IL)-1β and IL-6 [10, 62]

Of these mediators of inflammation, **TNFα** plays a dominant role in the cascade leading to the clinical symptom of sciatica [102]. Olmarker et al. [102] first showed that TNFα has been linked to the nucleus-pulposus-induced effects of

nerve roots after local application. Exogenous TNFα also produced neuropathologic changes and behavior deficits that mimicked experimental studies with herniated nucleus pulposus applied to nerve roots [55]. Olmarker et al. [102] also showed that a **selective antibody to TNFα** limited the deleterious effect of nucleus pulposus on the nerve root. Furthermore, it was shown that a selective inhibition of TNFα prevents nucleus-pulposus-induced histologic changes in the dorsal root ganglion [99]. The same researchers demonstrated in a subsequent study that an increase in the concentration of TNFα applied to the nerve root induced **allodynia and hyperalgesia** responses [98]. These experimental findings justified the application of TNFα inhibitors in a clinical setting to treat sciatica [103]. Although preliminary studies were intriguing [70, 72], a randomized trial did not demonstrate results in favor of this treatment [71].

Anti-TNF treatment is an intriguing approach to treating radiculopathy

## Clinical Presentation

### History

Most lumbar disc herniations occur between 30 and 50 years of age. Low back pain may or may not be present in the medical history of the patient. Frequently, the patients report an acute episode with back pain which radiates increasingly into one leg within hours or a few days. With further persistence of the symptoms, patients exclusively or predominantly complain of leg pain.

The **cardinal symptoms** of a symptomatic disc herniation are:

The cardinal symptoms of disc herniation are radicular leg pain with or without a sensorimotor deficit

- radicular leg pain
- sensory loss
- motor weakness

These symptoms must correspond to the respective dermatome and myotome of the compromised nerve root to allow for a conclusive diagnosis.

Additional but **less frequent findings** may be:

- paresthesia in the affected dermatome
- radicular pain provoked by pressing, sneezing or pressing
- pain relief in supine position with hips and knees flexed
- previous episodes of acute back pain

In contrast to adults, back pain can be the prevailing symptom in children

Symptoms **in children and adolescents** can differ significantly from those of adults [135, 157]. In this young age group, patients often present with:

- predominant back pain
- radicular or pseudoradicular leg pain
- hamstring tightness
- difficulties stooping and picking up things
- restriction in running and jumping
- diminished stride

Patients infrequently present with a massive disc herniation (Case Study 1) which compresses the cauda equina, causing a **cauda equina syndrome** which is characterized by:

- incapacitating back and leg pain
- numbness and weakness of the lower extremities
- inability to urinate (early)
- paradoxic incontinence (later)
- bowel incontinence (late)

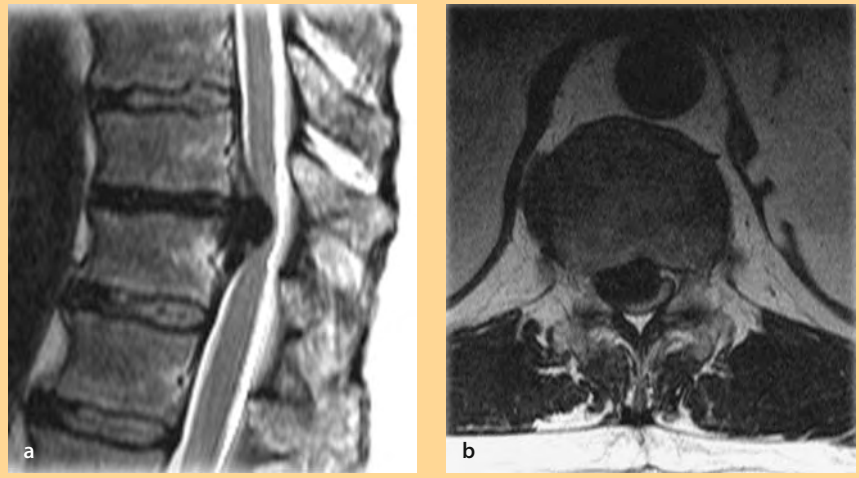


**Figure 2. Thoracic disc herniation**

a T2 weighted sagittal MR image showing a large disc extrusion at the level of T10/11 with significant compression of the spinal cord. b T2 weighted axial MR image demonstrating the severe spinal canal obliteration with compression and deformation of the spinal cord.

Always inquire about bladder and bowel dysfunction

It is astonishing that patients often do not spontaneously report a bladder dysfunction as they do not see the correlation to their back problems. Therefore, it is crucial to inquire about bowel and/or bladder dysfunction. In the acute onset, patients present with an inability to urinate. With increasing bladder distension, the patients develop a paradoxic incontinence caused by urinary retention.

The history of patients with a **thoracic disc herniation** depends on the extent of the herniation and the time course of the compression (Fig. 2). Large disc herniations which are rapidly compromising the spinal cord result in a progressive paraparesis. A slowly progressive compression causes symptoms comparable to a cervical myelopathy with the difference that the upper extremities are spared (see Chapter 17). In patients in whom the compromise of the spinal cord is less severe, diagnosis is often delayed. Frequent symptoms indicating thoracic symptoms are:

- localized dorsal pain
- belt-like pain radiation
- increased pain with coughing and sneezing
- gait disturbance
- non-dermatomal sensory deficits
- motor weakness in the lower extremities

## Physical Findings

Check for perianal sensitivity

The clinical examination of patients with radicular leg pain is predominantly focused around a neurologic examination (see Chapter 11). A precise testing of dermatomal sensation and the muscle force of the lower extremities is mandatory. The neurologic assessment should include testing for sensation in the perianal region (search for saddle anesthesia) and sphincter tonus.

Patients with a **herniated disc** often present with:

- positive Lasègue (straight leg raising) sign (L4–S1)
- positive reversed Lasègue sign (L2–4)
- crossed Lasègue test
- vertebral shift (Case Study 2)
- restricted spinal movements (non-specific)
- trigger points along the ischiadic nerve (non-specific)

A positive Lasègue sign with radicular pain is indicative of a radiculopathy

Testing of the **Lasègue sign** (straight leg raising) is crucial for the diagnosis of a radiculopathy (see Chapter 8). The definition of a Lasègue test is largely variable in the literature [120, 128]. Most articles do not determine radicular pain as a criterion for a positive Lasègue test. We define the Lasègue sign based on the original publication as positive if the patient reports radicular leg pain while raising the ipsilateral straight leg. Radicular pain must be differentiated from non-radicular leg pain, which is frequent and often related to **tight hamstrings**. The **key feature** is the occurrence of radicular leg pain which is pathologic regardless of whether it occurs at 10 or 70 degrees of hip flexion. The positive contralateral straight-leg raising test is most specific for disc herniation indicating a large herniation ranging to the contralateral side. The reverse straight leg raising test or femoral stretch test causes root tension at L2, L3 and L4 (see Chapter 8). A positive ipsilateral straight leg raising test is a sensitive (72 – 97 %) but less specific finding (11 – 66 %). However, the results are critically dependent on the definition of the test. The criterion of radicular leg pain substantially increases the diagnostic accuracy. In contrast, a positive crossed straight leg raising test is less sensitive (23 – 42 %), but much more specific (85 – 100 %) [6].

In **children and adolescents** key findings are [135, 157]:

- tight hamstrings
- and severely restricted spinal motion

The neurologic examination is often diagnostic

Beside the neurologic findings, the physical assessment (see Chapter 8) in patients with disc herniation is less diagnostic.

In patients with **thoracic disc herniations**, the physical findings are subtle unless the patients present with an obvious paraparesis or paraplegia. However, a careful examination may reveal [137]:

Symptomatic thoracic disc herniation presents with signs of a myelopathy

- disturbed gait
- sensory deficits (non-dermatomal)
- decreased motor weakness of the lower extremities (uni- or bilateral)
- increased muscle reflexes
- clonus
- decreased abdominal reflexes
- positive Babinski reflex
- bowel and bladder dysfunction

## Diagnostic Work-up

### Imaging Studies

#### Standard Radiographs

Standard radiographs are not helpful for the diagnosis of disc herniation and radiculopathy. Disc height decrease is not a reliable indicator of the correct level. However, the images are useful in eliminating confusion with regard to lumbosacral transitional anomalies.

#### Magnetic Resonance Imaging

MRI is the imaging modality of choice

Magnetic resonance imaging (MRI) has become the imaging modality of choice for the assessment of degenerative disc disorders. Compared to computed tomography (CT), the advantages of MRI are:

- absence of radiation
- better visualization of conus/cauda

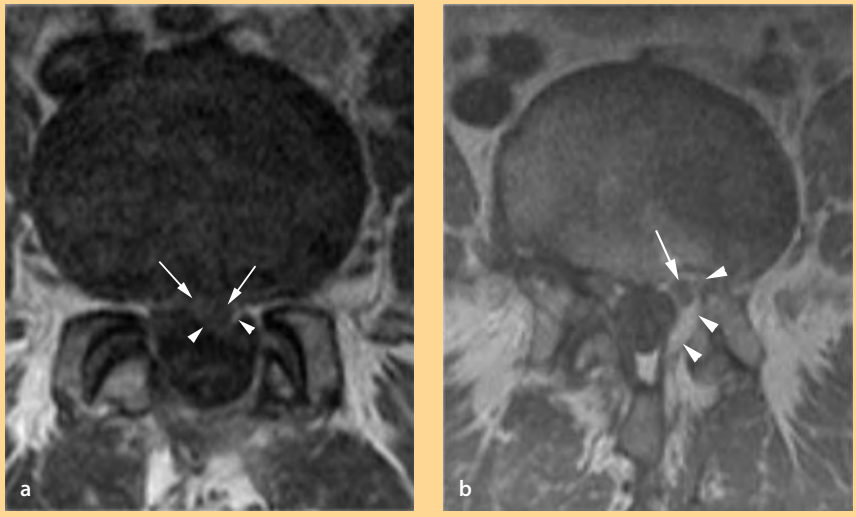


**Figure 3. Postoperative MRI**

MRI is helpful in differentiating recurrent herniation and scar formation. **a** T1 weighted contrast-enhanced MR image showing a small recurrent disc protrusion (*arrows*). Note the slight contrast enhancement around the disc herniation (*arrowheads*). **b** T1 weighted contrast-enhanced MR image demonstrating intense contrast medium uptake (*arrowheads*) around the nerve root (*arrow*) indicating scar formation.

- assessment of the grade of disc degeneration
- better assessment of the neural compromise

MRI is also better than CT in the postoperative period in differentiating scar from recurrent herniations. In this context, debate continues on the value of contrast enhancement to improve diagnostic accuracy. Contrast medium (gadolinium-DTPA) administered intravenously helps to differentiate between epidural fibrosis and recurrent herniations only in the late postoperative period [45] (**Fig. 3a, b**). However, MRI may be less sensitive in the diagnosis of a bony nerve root entrapment.

Large disc extrusions and sequestrations are rare in asymptomatic individuals

The diagnostic accuracy of MRI (and any other imaging modality) is hampered by the frequent occurrence of asymptomatic disc herniations [23]. The prevalence of asymptomatic disc herniations ranges from 0 % (sequestration) to 67 % (protrusions) depending on the asymptomatic population studied and the classification/definition of disc herniation [22, 23, 58, 148].

In children, simple disc protrusion must be differentiated from a slipped vertebral apophysis, which most frequently occurs at the inferior rim of the L4 vertebral body and at the superior rim of the sacrum. Often T1-weighted images demonstrate interposed tissue connected with the intervertebral disc. Adjacent vertebral discs may demonstrate a decrease in signal intensity [56].

Thoracic disc abnormalities are frequent

Similar to the lumbar spine, disc alterations are frequently found in the thoracic spine of asymptomatic individuals. In an MRI study, 73 % of the 90 asymptomatic individuals had positive anatomical findings at one level or more. These findings included disc herniation (37 %), disc bulging (53 %), annular tears (58 %) and deformations of the spinal cord (29 %). This study documented the high prevalence of anatomical irregularities, including herniation of a disc and deformation of the spinal cord, on the magnetic resonance images of the thoracic spine in asymptomatic individuals. The authors emphasized that these findings represent MRI abnormalities without clinical significance [153].

### Computed Tomography

In patients with contraindications for MRI, CT suffices to diagnose disc herniation

Although CT has made substantial advances such as multiplanar reformations due to multislice acquisitions, and the diagnostic accuracy has substantially improved to the level of MRI, the vast majority of surgeons today prefer MRI. The application is therefore mostly limited to patients with contraindications for MRI such as pacemakers and metal implants. However, in these cases CT is often combined with myelography for better depiction of the nerve roots. Forristall et al. studied MRI and **CT myelography** in the examination of 25 patients with a suspected disc herniation who underwent surgery [46]. Compared with the surgical findings, the accuracy of MRI was 90.3 % and of CT myelography 77.4 % [52]. In another controlled comparison of myelography, CT, and MRI in 80 patients with monoradicular sciatica, the largest amount of diagnostic information was gained from CT, followed by MRI and myelography. It was concluded that both CT and MRI were significantly informative and should be the first choice for imaging in patients with suspected lumbar disc herniation [52].

### Injection Studies

Nerve root blocks are applied for diagnostic and therapeutic objectives

Selective nerve root blocks (SNRBs) were first described by Macnab [86] in 1971 as a diagnostic test for the evaluation of patients with negative imaging studies and clinical findings of nerve root irritation. Indications for selective nerve root block are applied for a diagnostic as well as a therapeutic purpose. **Diagnostic selective nerve** root blocks are indicated in cases with:

- equivocal radicular leg or atypical arm pain
- discrepancy between the morphologic alterations and the patient's symptoms
- multiple nerve root involvement
- abnormalities related to a failed back surgery syndrome

Numerous studies [33, 38, 130, 139, 143] have shown that nerve root blocks are helpful in cases where this close correlation is lacking. In the case of a positive response (i.e., resolution of leg pain), the nerve root block allows the affected nerve root to be diagnosed with a sensitivity of 100 % in cases with disc protrusions and with a positive predictive value of 75 – 95 % in cases of foraminal stenosis [33, 139] (see Chapter 10).

## Neurophysiologic Assessment

Neurophysiologic studies can differentiate peripheral and radicular neural compromise

Neurophysiologic studies do not offer any added diagnostic value in patients presenting with the typical radicular symptoms and concordant imaging findings. Furthermore, the neurophysiology has the disadvantage of exhibiting a latency in the detection of neural compromise. Neurophysiologic studies are helpful in equivocal cases and allow the differentiation of (see Chapter 12):

- radicular versus peripheral nerve entrapment
- additional neuropathic disease
- symptomatic level in multilevel nerve encroachment

## Urologic Assessment

Patients with severe back pain and sciatica frequently present with subjective difficulties in emptying their bladder, prompting the suspicion of a cauda equina lesion. In this context, an ultrasonographic assessment of a putative **urinary retention** is indicated. In the case of a normal neurologic assessment (i.e., normal

perianal sensitivity and normal sphincter tonus), a urinary retention of **less than 50 ml** rules out a cauda lesion with a very high probability. If the neurologic assessment is somewhat questionable, uroflowmetry is the next diagnostic step. The absence of urinary retention together with a normal uroflow profile rules out an acute cauda equina lesion.

Ultrasonic assessment of urinary retention is helpful in diagnosing cauda equina syndrome

## Differential Diagnosis

A related entity in children is the so-called **slipped vertebral apophysis**, which can be confused with a common disc herniation [29]. The ring apophysis is a weak point during growth which can dislocate and migrate [19, 20]. It is believed that disc material displaces the posterior ring apophysis from the vertebra and produces symptoms. Takata et al. [134] suggested a classification into three types:

A slipped vertebral apophysis should not be confused with a simple disc herniation in children

- simple separation of the entire margin
- vertebral body avulsion fracture including the margin
- localized fracture

In patients presenting with a typical radicular syndrome, an extraspinal etiology is very rare [68] (see Chapter 11). Kleiner et al., in a study of 12 125 patients who had been referred during a 7-year period to a spine specialist, reported on 12 in whom an extraspinal cause of radiculopathy or neuropathy of the lower extremity was discovered. The cause of the symptoms was an occult malignant tumor in nine patients, a hematoma, an aneurysm of the obturator artery and a neurilemoma of the sciatic nerve. The clinical course was characterized by a delayed diagnosis (range 1 month to 2 years). In one-third of these patients, an operation was performed on the basis of an incorrect diagnosis [68]. The most important aspect is to search for rare differential diagnosis in cases with minor disc herniation and non-concordant symptoms.

## Classification

Disc herniations can be classified according to their **localization** as:

- median
- posterolateral
- lateral (intra-/extraforaminal)

Most disc herniations are located posterolaterally, i.e., where the posterior longitudinal ligament is the weakest or absent. Mediolateral herniations are the main localizations in the axial plane, whereas **lateral disc herniations** (Fig. 4) are less common (3 – 12 %) [113].

Two anatomically different types of lumbar disc herniation have been described with regard to a penetration of the posterior anulus and longitudinal ligament, respectively. Disc herniations can be classified as:

- contained
- non-contained

**Contained discs**, which are completely covered by outer annular fibers or posterior longitudinal ligament, are not in direct contact with epidural tissue. By contrast, **non-contained discs** are in direct contact with epidural tissue. This differentiation is of importance for minimally invasive surgical procedures such as chemonucleolysis or percutaneous disc decompression.

The most commonly used classification today is based on the MR morphology of the disc herniation [90] (Fig. 5).

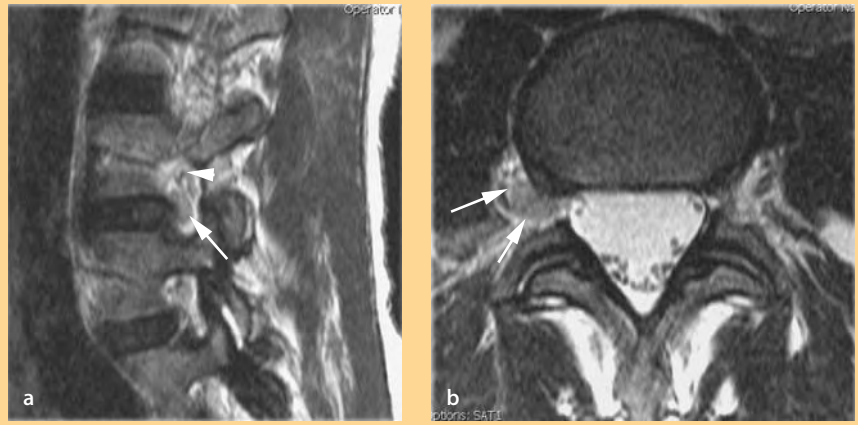


**Figure 4. Lateral disc herniation**

a T2 weighted parasagittal MR image of the foramen clearly showing the sequestrated disc material (*arrow*) pushing the nerve root (*arrowhead*) cranially. b Axial T2 weighted MR image demonstrating a large extraforaminal disc extrusion (*arrows*).

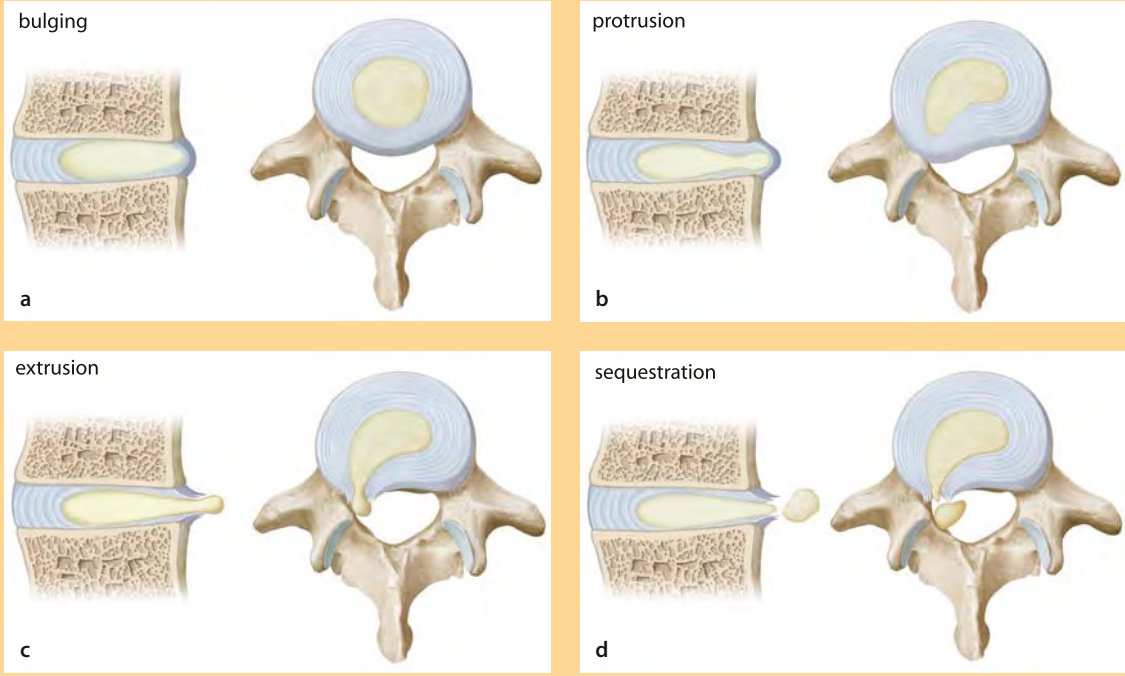


**Figure 5. Classification of lumbar disc herniation**

Modified from Masaryk et al. [90].

The size of the spinal canal determines whether a disc herniation becomes symptomatic

Particularly the definition of disc bulging is problematic because of the frequent finding (51 %) in discs of asymptomatic individuals [23]. Therefore, this classification is not helpful in **discriminating symptomatic and asymptomatic disc herniation**. A large disc extrusion in a wide spinal canal may not produce symptoms. On the contrary, a small disc protrusion in a congenitally narrow spinal canal may cause a significant sensorimotor deficit (Case Introduction). In a matched pair control study, Boos et al. [23] demonstrated that the **best discriminator** between symptomatic and asymptomatic disc herniation is nerve root compromise. Dora et al. [40] have shown that a symptomatic disc herniation is critically dependent on the size of the spinal canal. These findings have led to the suggestion [109] of a classification based on neural compromise (Fig. 6).

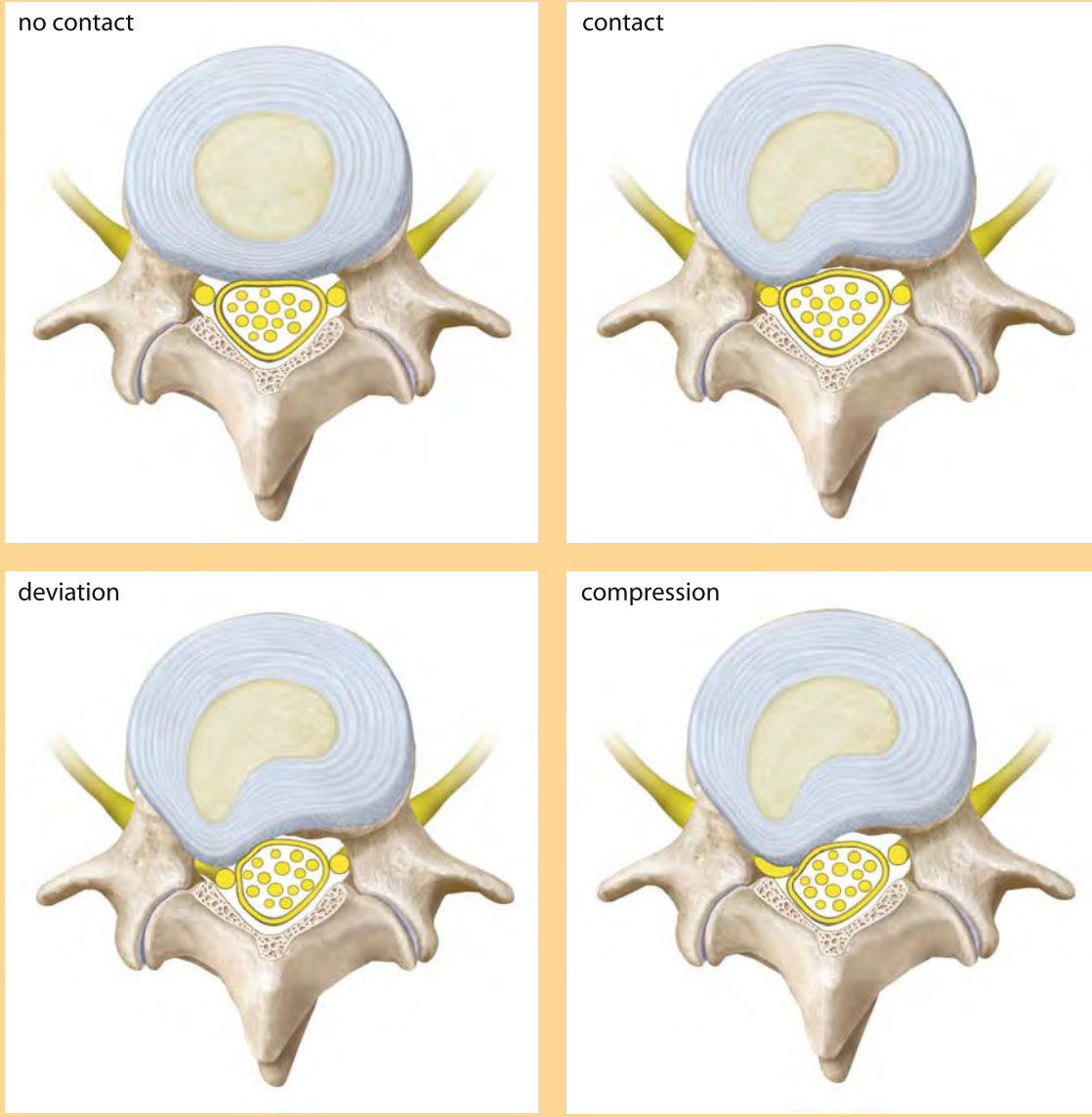


**Figure 6. Classification of nerve root compromise**

Modified from Pfirrmann et al. [109].

## Non-operative Treatment

Symptomatic lumbar disc herniation is a condition which exhibits a benign natural history. The patients who exhibit an absolute but rare indication for surgery are those who present with a cauda equina syndrome or a severe paresis (< MRC Grade 3). The general goals of treatment are shown in Table 1:

The natural history of disc herniation is benign

**Table 1.** General objectives of treatment

- relief of pain
- reversal of neurologic function
- regaining of activities of daily living
- return to work and leisure activities

Although based more on anecdotal experience than scientific evidence, several factors have been associated with a favorable outcome of non-operative treatment (Table 2):

**Table 2.** Favorable indications for non-operative treatment

- sequestrated disc herniation
- young age
- minor neural compromise
- small herniation
- mild disc degeneration
- mild to moderate sciatica

A detailed knowledge of the natural history is a prerequisite for advising patients on the appropriate choice of treatment.

## Natural History

Radicular symptoms have a benign course

The natural history of sciatica is generally benign. In most cases, an acute episode of sciatica takes a brief course. This phase is normally followed by a subacute or chronic period of residual symptoms. Most patients recover within 1 month, but the recurrence rate is approximately 10–15% [21]. In most patients with an extruded or sequestered herniation, the symptoms disappear with the herniation within a few weeks or months [112] (Case Introduction).

Extruded and sequestrated discs have a strong tendency to resolve

Bozzao et al. [25] evaluated prospectively the evolution of lumbar disc herniation using MRI. Follow-up MRI scan performed 6–15 months after baseline demonstrated that 48% of patients had a reduction in size of their lumbar disc herniation greater than 70%, 15% had a reduction of 30–70%, 29% had no change in size, and only 8% had an increase in size. There was a good clinical outcome in 71% of patients, and outcome correlated with the size reduction of the lumbar disc herniation. The largest disc herniations showed the greatest degree of reduction in size of lumbar disc herniation [25]. Komori et al. [69] investigated the morphologic changes in 77 patients with disc herniation and radiculopathy by sequential MRI. In 64 patients clinical improvement corresponded to a decrease of herniated disc, and in 13 patients no changes on MRI could be noticed despite symptom improvement. A decrease in size was observed in 46% of herniated discs within 3 months. Patients with marked morphologic changes showed significantly lower duration of leg pain compared to patients with slight clinical improvement. In this study morphologic changes corresponded to clinical outcome. Clinical improvement tended to be earlier than morphologic changes. Dislocated herniated discs frequently showed an obvious **decrease in size**, and in seven cases complete disappearance was observed. The further the herniated disc migrated, the more decrease in size could be observed [69]. However, disc protrusion, i.e., contained discs, did not have a tendency to resolve over a 5-year period [24]. These findings indicate that the highest chance for a **resolution** is exhibited by a sequestrated disc in a young patient. The exact mechanism of disc disappearance is not known. The contact between disc material and the vascular system may lead to an inflammatory response, invasion of macrophages and phagocytosis of the fragment.

## Conservative Measures

The **key measures** of non-operative treatment include:

- Bed rest (<3 days)
- Analgesics
- Anti-inflammatory medication
- Physiotherapy

Acute sciatica may be so severe that the patient cannot be mobilized. In this first period, the most important goal is to reduce pain and gradually increase the physical activity. It is also very important to reassure the distressed patient that the course is usually benign. However, bed rest should not be prolonged for more than 3 days [50, 140]. **Anti-inflammatory drugs** aim to tackle the inflammatory component. Physiotherapy in the acute phases focuses on a pain reducing positioning. After the acute phases therapeutic exercises which strengthen the back muscles and improve health status of the patients represent a cornerstone of conservative treatment. Exercise that improves trunk strength and balance and does not exacerbate leg pain appears to be preferable.

Conservative treatment has a 70–80% success rate

Non-operative treatment consists of analgesics, NSAIDs and physiotherapy

However, the clinical course is quite different in patients with **severe sciatica** and sensorimotor deficits. In a prospective study performed by Balague et al., 82 consecutive patients with severe acute sciatica were evaluated after 3, 6 and 12 months of conservative treatment. Only a minority of the patients (29%) had fully recovered after 12 months and one-third had surgery within 1 year. The recovery of clinical symptoms and signs was observed mainly in the first 3 months [14].

The natural history of severe sciatica is not benign

### Nerve Root and Epidural Blocks

Epidural corticoid therapy of patients with sciatica is done in many centers based on anecdotal experience, but the scientific evidence is still lacking for the effectiveness of this treatment [81]. We prefer the transforaminal route for the application of the steroids because the medication can be injected directly at the site of the nerve root compromise under fluoroscopic guidance. The pain resolution usually starts immediately with the main effect evident after 3 days. In patients with minor sensorimotor deficits and radiculopathy, an effective pain treatment can facilitate non-operative care and bridge the time until a potential resolution of the herniation (Case Introduction).

Nerve root blocks are a useful adjunct to non-operative care

Buttermann reported on a prospective, non-blinded study in which patients were randomly assigned to receive either epidural steroid injection or discectomy after a minimum of 6 weeks of non-invasive treatment. Patients who underwent discectomy had the most rapid decrease in symptoms, with 92–98% of patients reporting that the treatment had been successful over the various follow-up periods. Only 42–56% of the 50 patients who had undergone the epidural steroid injection reported that the treatment had been effective [27]. Carette et al. reported on a randomized, double blind trial with 158 patients who had sciatica due to herniated nucleus pulposus. Patients with epidural injections of methylprednisolone acetate had no significantly better outcome after 3 months compared to patients in the placebo group. They found no reduction of the cumulative probability of back surgery after 12 months [30]. In another prospective, randomized, double blind study, 55 patients with lumbar radicular pain and radiographic confirmation of nerve root compression underwent a selective nerve-root injection with either bupivacaine alone or bupivacaine with betamethasone. Of the 27 patients who had bupivacaine alone, nine elected not to have decompression surgery, compared to 20 of the 28 patients who had bupivacaine with betamethasone [114]. The authors concluded that selective nerve-root injections of corticosteroids are significantly more effective than those of bupivacaine alone in obviating the need for a decompression for a period of 13–28 months (see Chapter 10).

Nerve root blocks can reduce the need for surgery by an effective pain treatment

## Operative Treatment

### General Principles

The goal of surgery in degenerative disc herniation is decompression of neural structures. There must be a strong correlation between clinical symptoms and radiological compression of nerve root [138]. Under these conditions, the results of lumbar disc surgery are very favorable.

Absolute indications for surgery are a cauda equina syndrome or acute/subacute compression syndrome of the spinal cord. In this case, surgery must be performed early. A further indication is significant muscle paresis (MRC Grade < 3) and severe incapacitating pain that do not respond to any form of pharmacological therapy. A relative indication is a persistent radiculopathy unresponsive to an adequate trial of non-operative care for at least 4 weeks (Table 3):

**Table 3.** Indications for surgery

| Absolute indications | Relative indications |
|---|---|
| • cauda equina syndrome<br>• severe paresis (MRC < 3)<br>• paraparesis/paraplegia (thoracic disc herniation) | • severe sciatica with large herniation non-responsive to analgesics and NSAIDs<br>• persistent mild sensorimotor deficit (MRC > 3) and sciatica > 6 weeks<br>• persistent radicular leg pain unresponsive to conservative measures for 6–12 weeks<br>• persistent radicular leg pain in conjunction with a narrow spinal canal |

The indications for surgery in **children and adolescents** with slipped apophysis are similar to those of true disc herniation and consist of removal of both the slipped apophysis and prolapsed disc material [29, 47].

Surgery is indicated for thoracic herniations with spinal cord compromise

Indications for the surgical treatment of **thoracic disc herniation** must be made very carefully because of the high rate of asymptomatic disc alterations. However, indications for surgery are progressive myelopathy, lower extremity weakness and pain refractory to conservative treatment.

#### Timing of Surgery

Cauda equina syndrome or a progressive paresis should be operated on as early as possible

In the case of a cauda equina syndrome (Case Study 1), debate continues about the correct timing of surgery. Although it is recommended that surgery should be performed as early as possible, Kostuik [73] has found that decompression does not have to be performed in less than 6 h if recovery is to occur, as has been suggested in the past. A meta-analysis of surgical outcomes of 322 patients with cauda equina syndrome due to lumbar disc herniation showed no significantly better outcome if surgery was performed within 24 h from the onset of cauda equina syndrome compared to patients treated within 24–48 h. Significantly better resolutions of sensory and motor deficits as well as urinary and rectal function were found in patients treated within 48 h compared to those operated on after 48 h after onset of cauda syndrome [4]. Further, the study showed that preoperative back pain was associated with worse outcomes in urinary and rectal function, and preoperative rectal dysfunction was associated with a worsened outcome in urinary continence [4].

Prolonged conservative care may be associated with poorer outcome in patients requiring surgery

McCulloch [93] stated that surgical intervention in patients with acute radiculopathy who do not respond to conservative management should occur before 3 months of symptoms to avoid chronic pathologic changes within a nerve root. It is an anecdotal finding that patients with long-standing preoperative symptoms are less likely to obtain satisfactory results from surgery than those in whom symptoms are of short duration. In a prospective study, Rothoerl et al.

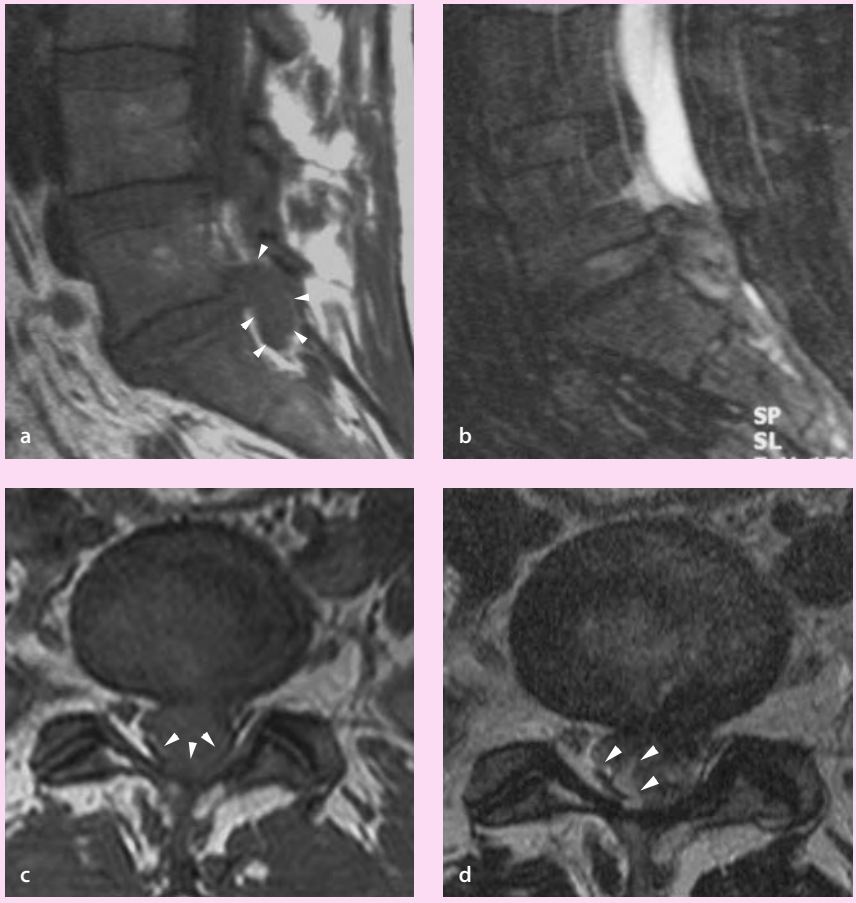


**Case Study 1**

A 35-year-old female felt a sharp pain in her back while bending down. Within 6 h she developed severe incapacitating back pain. She realized there was increasing numbness in her buttocks and weakness in both feet which was more pronounced on the left side. During the night, she consulted her family practitioner, who immediately referred her to our emergency department. On admission, the patient was diagnosed with a sensorimotor deficit of S1 (MRC Grade 2), flaccid sphincter tonus, and inability to urinate with a full bladder. An emergency MRI was indicated. T1 and T2 weighted images (a, b) demonstrate a massive sequestrated disc filling up the lumbosacral spinal canal. Axial T1 and T2 weighted MR images (c, d) show the severe obliteration of the thecal sac and cauda equina compression (*arrowheads*). Immediate surgery was indicated to decompress the cauda equina. Surgery consisted of a complete removal of the yellow ligament and a partial laminectomy of S1 and L5 to completely remove the massive herniation. The patient completely recovered from her pain but bladder dysfunction only resolved 6 months later.

[116] found that patients suffering for more than 60 days from disc herniation have a statistically worse outcome than patients suffering for 60 days or less. The authors recommend not to extend conservative treatment beyond 2 months and are in favor of surgery after that time period.

## Surgical Techniques

### Chemonucleolysis

Chemonucleolysis is effective for selected indications

Chemonucleolysis is a percutaneous intradiscal injection of chymopapain into the intervertebral disc. In 1963, Smith first described the dissolution of the disc by chemopapain [126]. The role of chemonucleolysis as an alternative to disc sur-

Chemonucleolysis is effective based on RCTs

gery became controversial because of the occurrence of rare but significant complications such as transverse myelitis and paraplegia [26, 97]. Chemonucleolysis is the only minimally invasive technique shown to be effective in prospective randomized studies. A meta-analysis showed that chymopapain was more effective than placebo. But, surgical discectomy produces better clinical outcomes than chemonucleolysis [48]. In this analysis approximately 30 % of patients with chemonucleolysis had further disc surgery within 2 years, and a second procedure was more likely after chemonucleolysis [124, 126].

### Percutaneous Techniques

These techniques have several theoretical advantages over open procedures:

- less collateral damage to the back muscles
- shorter hospital stay
- less scar formation
- cosmetic result

The indications for percutaneous techniques are limited

The percutaneous posterolateral approach to a herniated disc allows evacuation of extruded disc material and decompression of nerve root without entrance into the spinal canal and without destruction of the articular processes and ligamentum flavum. These procedures are limited in the extent to which migrated or sequestrated fragments can be retrieved or ablated, and proper patient selection is critical to their success. The approach to the L5/S1 disc space is more difficult because of limitations imposed by the iliac crest.

#### *Automated Percutaneous Lumbar Discectomy*

APLD is inferior to microdiscectomy

Automated percutaneous lumbar discectomy (APLD) and laser discectomy are percutaneous techniques which indirectly decompress the neural structures [87]. Both procedures were performed in patients with contained disc herniations or protrusions. The method was applied especially in the 1990s and the success rate ranged between 55 % and 85 %. Automated percutaneous discectomy was compared to microdiscectomy in two trials. In one trial similar clinical outcomes were achieved, whereas the other showed less satisfactory outcomes in percutaneous technique compared to microdiscectomy (29 % vs. 80 %) [48].

#### *Endoscopic Discectomy*

Endoscopic discectomy is compelling but must still pass the test of time

Kambin in 1988 published the first discoscopic view of a herniated disc. Percutaneous endoscopic removal of lumbar herniated disc can be performed via a midline or a posterolateral approach. Endoscopic procedures moved from indirect discectomy to direct excision of extruded fragments under vision. Further development of tools and techniques by Kambin and Yeung allowed uniportal direct decompression of the nerve root by foraminotomy, osteophytectomy and sequestrectomy [155]. Kambin et al. reported a favorable outcome in 87 % of cases similar to those of open disc surgery in selected patients [61]. Yeung reported about 307 patients who underwent percutaneous posterolateral nucleotomy for herniated discs [155]. After 1 year, 90.7 % of patients were satisfied and would undergo the same procedure again. He concluded that percutaneous endoscopic discectomy has comparable results to open microdiscectomy. The procedure offers the advantages of outpatient surgery, less surgical trauma, and early functional recovery. In a prospective study, Ruetten et al. reported about 463 patients who had removal of herniated lumbar disc via an extreme lateral access. Using an endoscopic uniportal transforaminal approach, 81 % of patients had a com-

pletely resolved leg pain [117]. With the recent improvement in endoscopic techniques, a greater acceptance rate, patient demand and dissemination can be expected in the future.

### Standard Limited Laminotomy

Standard discectomy today consists of a unilateral exposure of the interlaminar window and partial flavectomy to expose the dura and nerve roots as well as the intervertebral disc. An excision of a 1- to 2-$cm^2$ area of the superior and inferior lamina results in a better exposure which is not always needed [42, 111]. Optionally, this technique can be used with **magnification loops** and **headlights** [129] to enhance visibility.

Standard limited laminotomy is the current gold standard for discectomy

A more extensive approach with complete bilateral removal of the yellow ligament and partial laminotomy may be indicated in cases with massive disc herniations and patients with a congenitally narrow spinal canal (Case Study 2). Extrac-

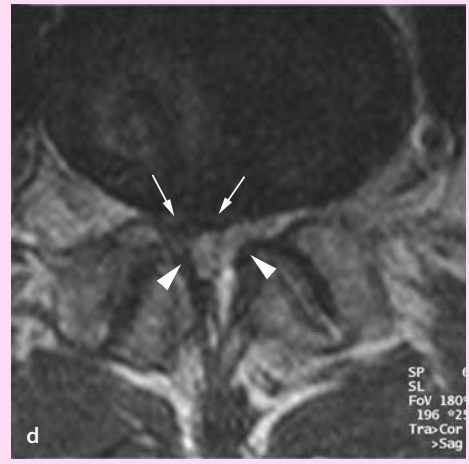


**Case Study 2**

A 33-year-old male reported recurrent episodes of low back pain. One morning, he woke up immobilized by back pain and could hardly move. Symptomatic treatment with analgesics, NSAIDs and physiotherapy was begun after a visit to his general practitioner. After 3–4 days the back pain slowly disappeared but the patient developed severe leg pain. During the course of one week the patient developed paresthesia and weakness of the right foot. On referral 6 weeks after symptom onset, the patient still presented with a severe spinal shift to the right (a). A standing anteroposterior radiograph confirmed this shift and ruled out scoliosis (b). On examination, the patient presented with a sensorimotor (MRC Grade 3) deficit for dorsiflexion of the greater toe (L5). Sagittal T2 weighted MR image (c) shows a small disc protrusion at the level of L4/5 on the right side. The axial T2 weighted MR image (d) demonstrates a congenitally narrow spinal canal with flavum hypertrophy (*arrowheads*) and a small disc protrusion compressing the L5 nerve root. After failure of non-operative care, surgery at L4/5 was carried out not only decompressing the nerve root L5 but also the congenitally narrow spinal canal with the beginning of stenosis.

tion of a large disc fragment through a tiny opening in the flavum may cause a rapid increase in intrathecal pressure and may lead to neurologic deterioration. In cases with cauda equina syndrome, complete flavectomy and in some cases laminectomy is therefore needed before the fragments can be extracted (Case Study 1).

### Microdiscectomy

The technique of microsurgical discectomy was introduced by **Caspar** [32] and **Williams** [151] in the late 1970s [32] (Fig. 7). The use of the operating microscope to expose the compressed nerve root has several theoretical advantages. The most important reason is the maintenance of a three-dimensional view in the

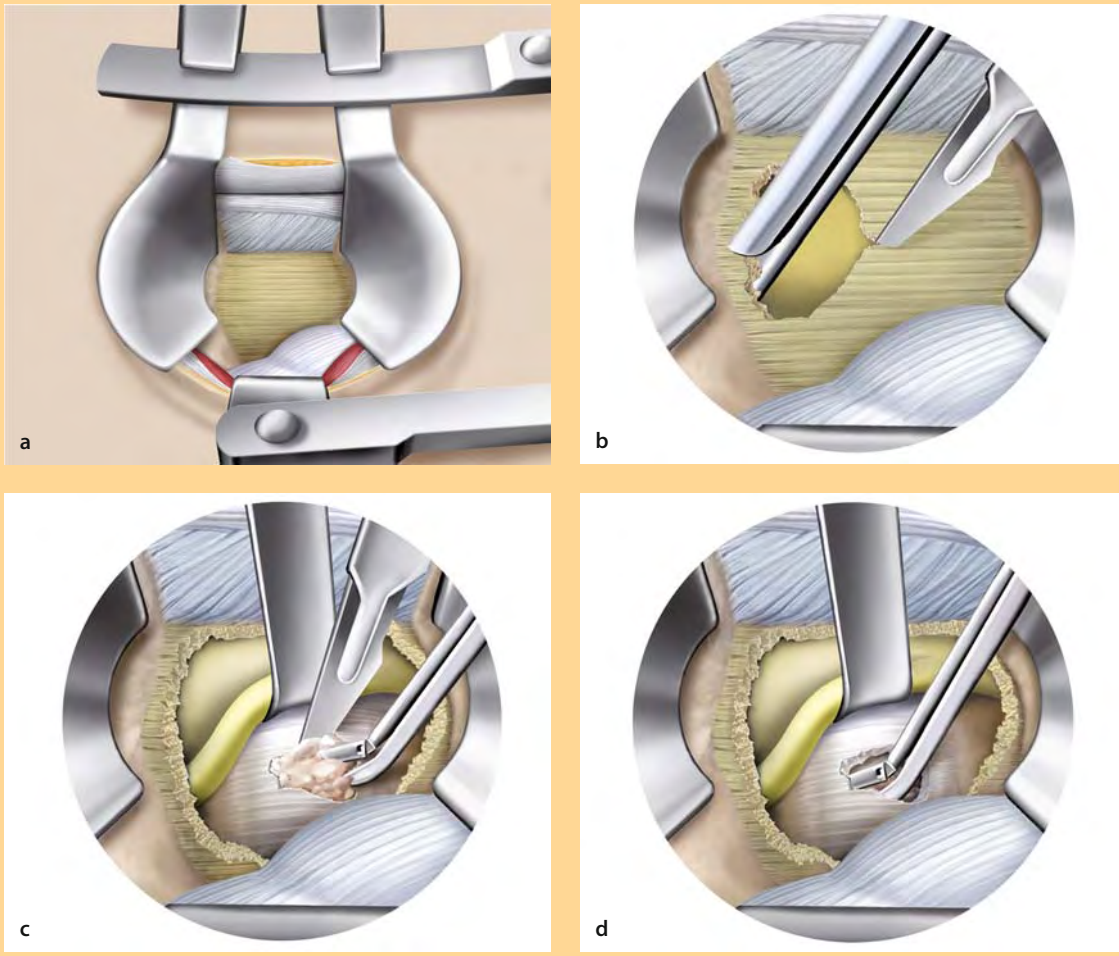


**Figure 7. Interlaminar approach**

The patient is positioned with the abdomen hanging freely minimizing intra-abdominal pressure and related epidural bleeding. Verification of the correct level before and after exposure of the target interlaminar window is mandatory. a Interlaminar approach with a tubular retractor after a 3-cm skin incision placed over the target interlaminar window. b Incision of the yellow ligament with a knife or a Kerrison rongeur. c Partial flavectomy and exposure of the nerve root and disc herniation. The lateral border of the nerve root must be identified clearly before further preparation. The nerve root should only be retracted medially to avoid nerve root and dura injuries. Sometimes the nerve root must be decompressed laterally first by undercutting the facet joint before it can be mobilized over the disc herniation. d The decompression of the intervertebral disc should be limited to the extraction of free intradiscal fragments. Resection of the anulus increases the risk of recurrent herniation.

depth of a spinal wound. Furthermore, microscopic discectomy exhibits the advantage of stronger illumination and magnification of the operative field and a smaller approach, which may result in a more rapid recovery [8, 60]. In an EMG study, it was shown that the use of a microscope resulted in less irritation of the nerve root [121]. Debate continues about the superiority of microdiscectomy over standard limited laminotomy [93, 123]. So far, no convincing evidence has been provided in the literature [48]. McCulloch has indicated that the outcome of lumbar discectomy does not appear to be affected by the use of a microscope and depends more on patient selection than on surgical technique [93].

Microdiscectomy results in less nerve root irritation than with standard techniques

Outcome of discectomy is independent of the type of open surgical technique

The microscopic approach has also been described for the treatment of **lateral (extracanicular) disc herniations** in which full visual control allows a decompression of the respective spinal nerve or ganglion and removal of the herniated disc [113]. With this approach, there is minimal resection of bone and facet joint and minimal risk of injury to neural structures (Fig. 8).

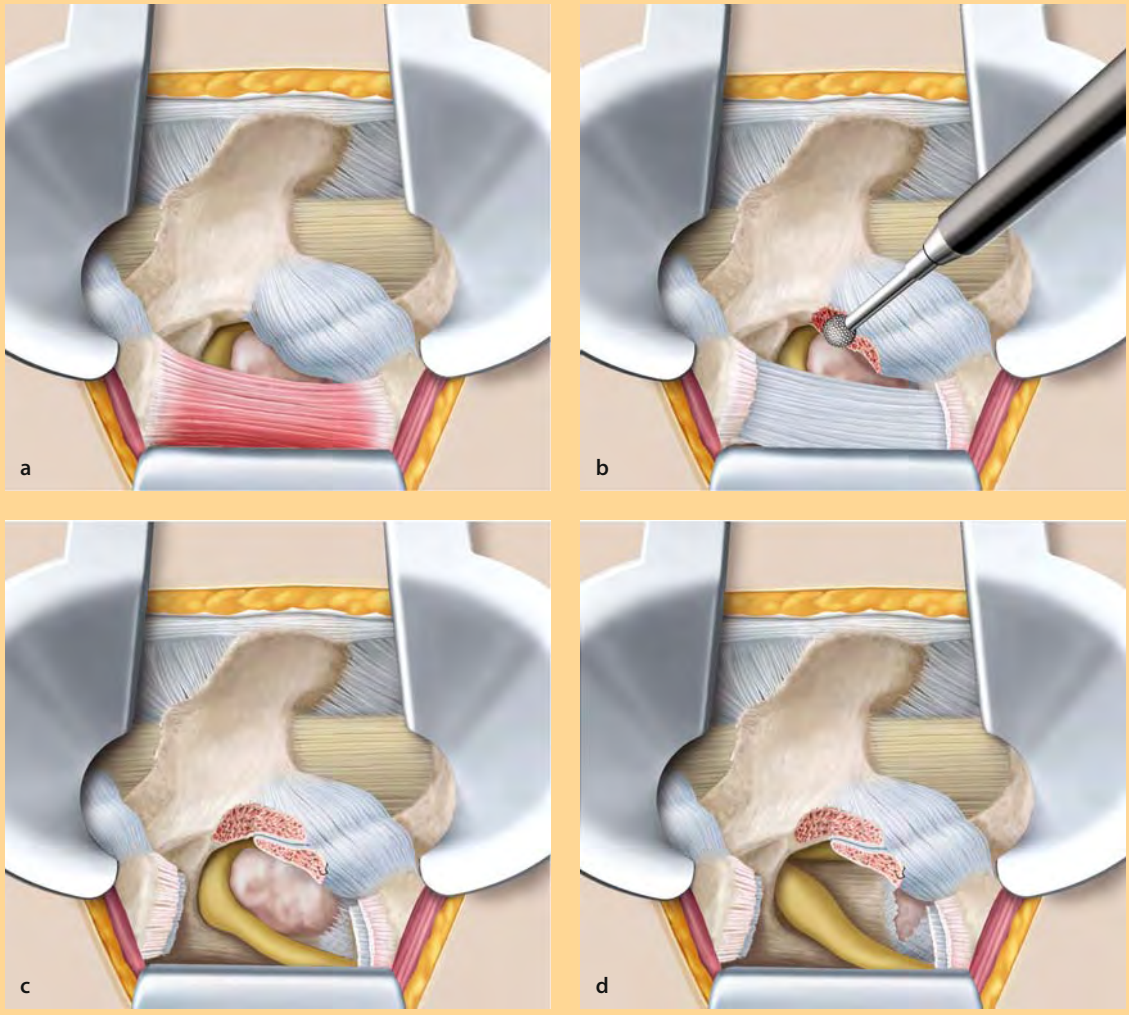


**Figure 8. Extraforaminal approach**

The extraforaminal approach is similar to the interlaminar approach using a tubular retractor. a Exposure of the facet joint, isthmus of the lamina and the superior and inferior transverse process. b Resection of the lateral inferior border of the isthmus with a high-speed diamond burr is sometimes necessary for a better exposure. c Exposure of the exiting nerve root, search and extraction of free fragments. d Decompression of the intervertebral disc may be necessary to completely liberate the nerve root in case of a disc protrusion deviating or compressing the nerve root.

### *Complete Discectomy Versus Sequestrectomy*

Debate also continues about the extent of discectomy. Williams has advocated an approach without laminectomy or curettement of the disc space, preservation of extradural fat and blunt perforation of the anulus fibrosus, rather than scalpel incision with the goal of minimizing reherniations and adhesion reactions [151, 152]. In a prospective randomized study [136], 84 consecutive patients with free, subligamentary, or transannular herniated lumbar discs were randomized to sequestrectomy alone or microdiscectomy groups. At 4 and 6 months, SF-36 scales and PSI scores showed a trend in favor of sequestrectomy, leaving 3% of patients unsatisfied compared with 18% of those treated with discectomy. Reherniation occurred in four patients after discectomy (10%) and two patients after sequestrectomy (5%) within 18 months [136]. There appears to be little benefit from more radical disc excisions compared with removing only sequestered fragments in the case of adequate decompression of the nerve root.

Sequestrectomy is preferred over radical discectomy

### Surgery for Thoracic Disc Herniations

The choice of surgical approach depends on the **location and extent** of the herniation but also on the general condition of the patient. Surgery for the treatment of thoracic disc herniations is demanding because:

- the spinal cord does not tolerate any retraction for exposure of the disc herniation
- correct localization of the target level is difficult
- the herniation is usually hard (calcified) and difficult to remove
- corpectomy may be required to remove dislocated fragments
- verification of a complete removal is hampered by the limited sight
- bone resection for exposure may require subsequent spinal instrumentation

**Several approaches** have been described (Table 4):

**Table 4.** Surgical approaches for thoracic disc herniations

| Posterolateral approaches | Anterior transthoracic approaches |
|---|---|
| • costotransversectomy [54]<br>• lateral extracavitary [77]<br>• transverse arthro-pediculectomy [82]<br>• transfacet pedicle-sparing [131] | • anterior transpleural [36]<br>• thoracoscopic [115] |

Laminectomy alone is contraindicated

**Laminectomy alone** is contraindicated in thoracic disc herniation (TDH) because the compression is anterior, which is not addressed by a posterior decompression. For many years, the **costotransversectomy** was the gold standard for surgery of the TDH. Nearly all types of TDH can be reached with this approach. The approach was introduced by Hulme in 1960 [54]. After a median or paramedian incision, the processus transversus must be removed followed by resection of 10–15 cm of the medial rib of the lower vertebra. After reaching the disc space, the discectomy can be performed. The parietal pleura of the lung is pushed ventrally and the disc fragment can be resected without touching the thecal sac. This approach was modified in many ways to a less invasive procedure. The transfacet pedicle-sparing approach allows for complete disc removal with limited spinal column disruption and soft-tissue dissection [131]. With additional use of the microscope good removal of lateral and centrolateral TDH is possible. Anterior approaches have been developed for direct exposure of central calcified and centrolateral herniations. In 1958, Crafoord reported on the

removal of TDH by the anterior transthoracic transpleural approach [36]. In the 1990s, Rosenthal and others [80, 85] developed a thoracoscopic approach for thoracic herniations. The clinical outcome of surgery for thoracic disc herniations is satisfactory in 76–86% of cases [83, 108, 125, 131, 156]. However, the risk of postoperative paraplegia is imminent [83].

The risk of postoperative neurologic deterioration is imminent

## Conservative Versus Operative Treatment

One of the first randomized controlled trials in spinal surgery was the comparison of conservative and surgical treatment for lumbar disc herniations by **Weber** [142]. Two hundred and eighty patients with herniated lumbar discs, verified by radiculography, were divided into three groups. One group consisted of 126 patients with uncertain indications for surgical treatment, who had their therapy decided by randomization, which permitted comparison between the results of surgical and conservative treatment. Another group comprising 67 patients had symptoms and signs that were beyond doubt, requiring surgical therapy. The third group of 87 patients were treated conservatively because there were no indications for operative intervention. Follow-up examinations in the first group ($n=126$) were performed after 1, 4, and 10 years. The controlled trial showed a statistically significantly better result in the surgically treated group at the 1-year follow-up examination. After 4 years, the operated on patients still showed better results, but the difference was no longer statistically significant. Only minor changes took place during the last 6 years of observation [142].

The **Maine Lumbar Spine Study** demonstrated that while patients with sciatica generally improve regardless of the type of treatment given, those who are surgically treated report significantly greater improvement in symptoms, health-related quality of life, and satisfaction compared with non-surgically treated patients at a 1-year follow-up. In this study 86% of surgically treated patients stated if they were to do it again they would still choose surgery [11, 12]. The **SPORT** (**Spine Patient Outcomes Research Trial**) trial consisted of 1 220 prospectively followed patients with sciatica due to disc herniation who were divided into surgical and non-surgical groups [146, 147]. One part of the study included 501 patients who were randomized into two groups (surgery vs. conservative). The remaining patients ($n=719$) who chose one of the two treatment options were included in an observational arm. In the randomized group, adherence to the assigned treatment was limited: 50% of patients assigned to surgery received surgery within 3 months of enrollment, while 30% of those assigned to non-operative treatment received surgery in the same period. Intent-to-treat analyses demonstrated substantial improvements for all primary and secondary outcomes in both treatment groups. Between-group differences in improvements were consistently in favor of surgery for all periods but were small and not statistically significant for the primary outcomes. The randomized study was hampered by the large numbers of patients who crossed over in both directions. Conclusions about the superiority or equivalence of the treatments are not warranted based on an intent-to-treat analysis. Of the 743 patients enrolled in the observational cohort, 528 patients received surgery and 191 received the usual non-operative care. At 3 months, patients who chose surgery had greater improvement in the primary outcome measures of bodily pain, physical function, and Oswestry Disability Index. These differences narrowed somewhat at 2 years. The overall comparison demonstrated a significantly better outcome for surgery compared to conservative care. However, the authors stressed that non-randomized comparisons of self-reported outcomes are subject to potential confounding and must be interpreted cautiously (Table 5).

Surgery provides better short-term results than non-operative care

Sciatica patients improve with surgery as well as with conservative care

The outcome benefits of surgery seem to vanish over time

**Table 5.** Treatment outcome

| Author | Study | Patients and treatment | Follow-up and outcome |
|---|---|---|---|
| Weber [142] | prospective randomized | operative ($n=66$) vs. non-operative ($n=60$) treatment | significantly better outcome of surgery at one year which is no longer significant at 4 and 10 years |
| Atlas et al. [11–13] | prospective cohort study | operative ($n=217$) vs. non-operative ($n=183$) treatment | surgically treated patients are more satisfied (71% vs. 56%) and have less back and leg pain (56% vs. 40%) at 10 years follow-up |
| Weinstein et al. [147] | prospective randomized | operative ($n=245$) vs. non-operative ($n=256$) treatment | better outcome in the surgical group which did not reach statistical significance. Methodological problems (high number of cross-overs) limit the conclusions |
| Weinstein et al. [146] | prospective observational | operative ($n=528$) vs. non-operative ($n=191$) treatment | significantly better outcome of the surgical group at 1 and 2 year follow-up |

## Complications

Complications in surgery for lumbar disc herniation are rare

For all kinds of surgery, the benefits have to be weighed against the risks. In general, the risks associated with discectomy are very low. **Early complications** of the procedure may include [76, 149]:

- nerve root injuries or increasing neurologic deficit (0.5–1%)
- cerebrospinal fluid leaks (0.8–7.3%)
- infections (0–2%)
- great vessel or intestinal injury (0–0.04%)

**Late complications** could be segmental instability and the so-called "failed back surgery syndrome." The overall rate of unsatisfactory results following discectomy is between 5% and 20% [78, 132].

The frequent **causes of persistent sciatica** after discectomy are [74, 132]:

- wrong level surgery
- insufficient disc removal
- recurrent herniation
- unrecognized additional nerve root compromise
- nerve root injury
- insufficient decompression of concomitant spinal stenosis
- spondylolisthesis
- extravertebral nerve compression

### Recurrent Herniation

The rate of recurrent herniations ranges between 5% and 11%

Contained disc exhibits a higher recurrency rate

Minimal disc degeneration is a risk factor for recurrent herniations

The recurrence of back and/or sciatic pain can be caused by a true recurrent herniation or an incomplete removal. The reported rate of recurrent disc herniation after primary discectomy ranges between 5% and 11% [35, 43, 132]. Carragee et al. [31] presented a prospective observational study with 187 patients who underwent primary lumbar discectomy. The morphology of the disc herniations was recorded according to **annular deficiency** and **presence of fragments**. Patients with fragments and small annular defects had a recurrence rate of 1%, patients with fragments and contained disc herniation 10%, patients with fragments and massive posterior annular loss 27%. The highest recurrence rate (38%) had patients with no fragments and **contained disc herniations** [31]. In a case-control study, MR findings of patients with and without recurrent disc herniation were analyzed [39]. Advanced disc degeneration (Grades IV and V) was significantly less frequent in the study group than in the control group ($P<0.006$). The risk of recurrent disc herniation decreased by a factor of 3.4 with each grade of disc degeneration. Mean disc herniation volume as a percentage of intervertebral disc volume was equal in both groups. The authors concluded that minor disc degen-

eration but not herniation volume represents a risk factor for the recurrence of disk herniation after discectomy.

The **results of revision surgery** for recurrent lumbar disc herniation are as good as those of primary surgery when a true recurrent herniation is the source of sciatica [41, 59]. Controversy exists as to whether **epidural fibrosis** may be a reason for persistent back and leg pain after discectomy. In a contrast-enhanced MRI study, however, no differences regarding the presence and extent of epidural fibrosis between symptomatic and asymptomatic patients were found, questioning the role of epidural fibrosis as the causative agent in the lumbar postdiscectomy syndrome [9]. Many attempts have been made to reduce postoperative perineural fibrosis by interposition membranes but so far no convincing evidence has been provided in the literature for a superior outcome or a lower reoperation rate when applying such material [48]. We concur with Johnsson and Stromqvist [59] that sciatica due to nerve-root scarring is seldom improved by repeat operations.

The clinical significance of epidural fibrosis is unclear

Reoperation for epidural fibrosis is rarely successful

## Recapitulation

**Epidemiology.** Lumbar disc herniation is the pathologic condition most commonly responsible for radicular pain. Episodes of back pain usually precede sciatica. Spinal surgery is most frequently carried out for disc herniation. The incidence rate of surgery for disc herniation exhibits substantial regional variations. Symptomatic thoracic disc herniations are very rare.

**Pathophysiology.** Disc herniation results from age-related (degenerative) alterations of the intervertebral disc leading to annular incompetence. Nuclear migration caused by annular disruption leads to the disc herniation. The major **risk factor** is genetic predisposition and classic risk factors (e.g., heavy lifting, twisting and bending, vibration) may only have a modulating effect. The pathophysiology of radiculopathy involves both **mechanical deformation** and **chemical irritation** of the nerve root. **Proinflammatory cytokines** play a major role in the development of sciatica.

**Clinical presentation.** The **cardinal symptom** of a disc herniation is radicular leg pain with or without a sensorimotor deficit. Neurologic examination is important to determine the involved nerve root(s) and rule out a cauda equina lesion. Children and adolescents with disc herniation may present only with back pain and hamstring tightness. **Potential bowel and bladder dysfunction** must be systematically assessed. Thoracic disc herniations can lead to progressive paraparesis but are rarely the cause of dorsal pain.

**Diagnostic work-up.** MRI has become the imaging modality of choice for assessing degenerative or herniated intervertebral discs. Diagnostic and prognostic implications are limited by the high prevalence of asymptomatic disc alterations. MRI and CT are equally good at diagnosing disc herniation. In equivocal cases, selective nerve root blocks can be helpful to identify the involved nerve root. Urologic assessment may be required in cases with questionable cauda equina syndrome. Nerve root compromise is the best indicator for symptomatic disc herniation.

**Non-operative treatment.** The **natural history** of disc herniations is favorable. Large sequestrated discs exhibit a tendency to resolve with time. Conservative care consists of analgesics, NSAIDs, physiotherapy and **epidural/nerve root blocks**. The scientific evidence for therapeutic injections is limited. Prolonged conservative treatment (>3 months) may result in an inferior outcome in the presence of a large disc herniation with concordant clinical symptoms.

**Surgical treatment.** Patient selection is the most important issue when considering surgical decompression. The high prevalence of asymptomatic disc herniations indicates that there must be a strong correlation between clinical-neurologic compression signs and radiological findings to justify surgery. **Absolute indications** for surgery are progressive neurologic deficit, cauda equina syndrome or paraparesis (thoracic disc herniation). Relative indications include persistent leg pain with or without mild sensorimotor deficits. **Chemonucleolysis** is the only minimally invasive technique which has been shown to be superior to non-operative treat-

ment. Endoscopic techniques are compelling but still require the test of time. Standard interlaminar discectomy and **microdiscectomy** are the most frequently used techniques. So far, the microscopic approach has not been demonstrated to be superior to the conventional technique. Less degenerated discs exhibit a high rate of **recurrent disc herniations**. Surgical and non-surgical treatment have an equally satisfactory outcome but surgical candidates report better short-term results.

## Key Articles

**Mixter WJ, Barr JS (1934) Rupture of intervertebral disc with involvement of the spinal canal. N Engl J Med 211:210**
Classic paper with the first description of disc herniation as the cause of sciatica.

**Williams RW (1978) Microlumbar discectomy: a conservative surgical approach to the virgin herniated lumbar disc. Spine 3:175 – 82**
Landmark paper introducing microdiscectomy as a surgical technique.

**Atlas SJ, Keller RB, Wu YA, Deyo RA, Singer DE (2005) Long-term outcomes of surgical and non-surgical management of sciatica secondary to a lumbar disc herniation: 10 year results from the Maine Lumbar Spine Study. Spine 30:927 – 935**
This paper presents the long term treatment outcomes of sciatica caused by lumbar disc herniation. Focus is on the relative benefits of surgical and conservative therapy. The 10-year outcome for 402 patients is reported. Outcomes included patient-reported symptoms of leg and back pain, functional status, satisfaction, and employment and compensation status. The Maine Lumbar Spine Study demonstrated that while patients with sciatica generally improve regardless of the type of treatment given, those who are surgically treated report significantly greater improvement in symptoms, health-related quality of life, and satisfaction compared with non-surgically treated patients at a 1-year follow-up. In this study 86 % of surgically treated patients stated if they were to do it again they would still choose surgery.

**Balague F, Nordin M, Sheikhzadeh A, Echegoyen AC, Brisby H Hoogewoud HM, Fredman P (1999) Recovery of severe sciatica. Spine 24(23):2516 – 2524**
In this prospective study, the recovery rates of 82 consecutive patients with severe acute sciatica were evaluated after 3, 6 and 12 months of conservative treatment. Only a minority of the patients (29 %) had fully recovered after 12 months and one-third had surgery within 1 year. The recovery of clinical symptoms and signs was observed mainly in the first 3 months. The authors concluded that the outcome of non-operative care for severe sciatica is poor.

**Weber H (1983) Lumbar disc herniation. A controlled, prospective study with ten years of observation. Spine 8:131 – 140**
This paper first reported in a randomized, prospective study the outcome of surgically treated patients compared to non-operatively treated patients. In 126 patients, the authors found significantly better results in the surgical group at 1 year. This significance is lost at 4 and 10 years with the surgical patients still being better.

**Weinstein JN, Lurie JD, Tosteson TD, et al. (2006) Surgical vs nonoperative treatment for lumbar disk herniation. The Spine Patient Outcomes Research Trial (SPORT), a randomized trial. JAMA 296:2441 – 2450**
**Weinstein JN, Lurie JD, Tosteson TD, et al. (2006) Surgical vs nonoperative treatment for lumbar disk herniation. The Spine Patient Outcomes Research Trial (SPORT) observational cohort. JAMA 296:2451 – 2459**
These two papers are important papers comparing the conservative treatment with discectomy in patients with sciatica due to lumbar disc herniation. The SPORT trial consists of 1 220 prospectively followed patients who were divided into surgical and non-surgical groups. One part of the study included 501 patients who were randomized to the two groups; the other part included 719 patients who chose one of the two treatment options. In the latter study part, more patients had good results and less pain after surgery compared to those who choose non-operative care. In the randomized part improvements

were also found consistently more in the surgical group, but the differences did not reach significance. Both papers showed a trend toward a better outcome for the surgically treated patients.

**Gibson JN, Grant IC, Waddell G (1999) The Cochrane review of surgery for lumbar disc prolapse and degenerative lumbar spondylosis. Spine 24:1820 – 1832**
**Gibson JN, Waddell G (2005) Surgery for degenerative lumbar spondylosis: updated Cochrane Review. Spine 30:2312 – 20**
Excellent summary of the scientific evidence for the treatment of disc herniations.

## References


1. Adams MA, Hutton WC (1981) The relevance of torsion to the mechanical derangement of the lumbar spine. Spine 6:241 – 8
2. Adams MA, Hutton WC (1982) Prolapsed intervertebral disc. A hyperflexion injury 1981 Volvo Award in Basic Science. Spine 7:184 – 91
3. Adams MA, Hutton WC, Stott JR (1980) The resistance to flexion of the lumbar intervertebral joint. Spine 5:245 – 53
4. Ahn UM, Ahn NU, Buchowski JM, Garrett ES, Sieber AN, Kostuik JP (2000) Cauda equina syndrome secondary to lumbar disc herniation: a meta-analysis of surgical outcomes Spine 25:1515 – 22
5. Anderson GBJ (1997) The epidemiology of spinal disorders, 2nd edn. Lippincott-Raven, New York, p 126
6. Andersson GB, Deyo RA (1996) History and physical examination in patients with herniated lumbar discs. Spine 21:10S–18S
7. Andersson GBJ (1991) Epidemiology of spinal disorders. In: Frymoyer JW (ed) The adult spine. Principles and practice. Raven Press, New York, pp 107 – 146
8. Andrews DW, Lavyne MH (1990) Retrospective analysis of microsurgical and standard lumbar discectomy. Spine 15:329 – 35
9. Annertz M, Jonsson B, Stromqvist B, Holtas S (1995) No relationship between epidural fibrosis and sciatica in the lumbar postdiscectomy syndrome. A study with contrast-enhanced magnetic resonance imaging in symptomatic and asymptomatic patients. Spine 20:449 – 53
10. Aoki Y, Rydevik B, Kikuchi S, Olmarker K (2002) Local application of disc-related cytokines on spinal nerve roots. Spine 27:1614 – 7
11. Atlas SJ, Deyo RA, Keller RB, Chapin AM, Patrick DL, Long JM, Singer DE (1996) The Maine Lumbar Spine Study, Part II. 1-year outcomes of surgical and nonsurgical management of sciatica. Spine 21:1777 – 86
12. Atlas SJ, Deyo RA, Keller RB, Chapin AM, Patrick DL, Long JM, Singer DE (1996) The Maine Lumbar Spine Study, Part III. 1-year outcomes of surgical and nonsurgical management of lumbar spinal stenosis. Spine 21:1787 – 94; discussion 1794 – 5
13. Atlas SJ, Keller RB, Wu YA, Deyo RA, Singer DE (2005) Long-term outcomes of surgical and nonsurgical management of sciatica secondary to a lumbar disc herniation: 10 year results from the Maine Lumbar Spine Study. Spine 30:927 – 35
14. Balague F, Nordin M, Sheikhzadeh A, Echegoyen AC, Brisby H, Hoogewoud HM, Fredman P, Skovron ML (1999) Recovery of severe sciatica. Spine 24:2516 – 24
15. Battie MC, Videman T (2006) Lumbar disc degeneration: epidemiology and genetics. J Bone Joint Surg Am 88 Suppl 2:3 – 9
16. Battie MC, Videman T, Gibbons LE, Manninen H, Gill K, Pope M, Kaprio J (2002) Occupational driving and lumbar disc degeneration: a case-control study. Lancet 360:1369 – 74
17. Bell GR, Rothman RH (1984) The conservative treatment of sciatica. Spine 9:54 – 6
18. Berney J, Jeanpretre M, Kostli A (1990) [Epidemiological factors of lumbar disk herniation]. Neurochirurgie 36:354 – 65
19. Bick EM, Copel JW (1950) Longitudinal growth of the human vertebra; a contribution to human osteogeny. J Bone Joint Surg Am 32:803 – 14
20. Bick EM, Copel JW (1951) The ring apophysis of the human vertebra; contribution to human osteogeny. II. J Bone Joint Surg Am 33A:783 – 7
21. Biering-Sorensen F, Thomsen C (1986) Medical, social and occupational history as risk indicators for low-back trouble in a general population. Spine 11:720 – 5
22. Boden SD, Davis DO, Dina TS, Patronas NJ, Wiesel SW (1990) Abnormal magnetic-resonance scans of the lumbar spine in asymptomatic subjects. A prospective investigation. J Bone Joint Surg Am 72:403 – 8

23. Boos N, Rieder R, Schade V, Spratt KF, Semmer N, Aebi M (1995) 1995 Volvo Award in clinical sciences. The diagnostic accuracy of magnetic resonance imaging, work perception, and psychosocial factors in identifying symptomatic disc herniations. Spine 20:2613 – 25
24. Boos N, Semmer N, Elfering A, Schade V, Gal I, Zanetti M, Kissling R, Buchegger N, Hodler J, Main CJ (2000) Natural history of individuals with asymptomatic disc abnormalities in magnetic resonance imaging: predictors of low back pain-related medical consultation and work incapacity. Spine 25:1484 – 92
25. Bozzao A, Gallucci M, Masciocchi C, Aprile I, Barile A, Passariello R (1992) Lumbar disk herniation: MR imaging assessment of natural history in patients treated without surgery. Radiology 185:135 – 41
26. Brown MD (1996) Update on chemonucleolysis. Spine 21:62S–68S
27. Buttermann GR (2004) Treatment of lumbar disc herniation: epidural steroid injection compared with discectomy. A prospective, randomized study. J Bone Joint Surg Am 86A: 670 – 9
28. Byrod G, Rydevik B, Nordborg C, Olmarker K (1998) Early effects of nucleus pulposus application on spinal nerve root morphology and function. Eur Spine J 7:445 – 9
29. Callahan DJ, Pack LL, Bream RC, Hensinger RN (1986) Intervertebral disc impingement syndrome in a child. Report of a case and suggested pathology. Spine 11:402 – 4
30. Carette S, Leclaire R, Marcoux S, Morin F, Blaise GA, St-Pierre A, Truchon R, Parent F, Levesque J, Bergeron V, Montminy P, Blanchette C (1997) Epidural corticosteroid injections for sciatica due to herniated nucleus pulposus. N Engl J Med 336:1634 – 40
31. Carragee EJ, Han MY, Suen PW, Kim D (2003) Clinical outcomes after lumbar discectomy for sciatica: the effects of fragment type and anular competence. J Bone Joint Surg Am 85A:102 – 8
32. Caspar W (1977) A new surgical procedure for lumbar disc herniation causing less tissue damage through a microsurgical approach. Adv Neurosurg 4:74 – 81
33. Castro WH, van Akkerveeken PF (1991) Der diagnostische Wert der selektiven lumbalen Nervenwurzelblockade. Z Orthop Ihre Grenzgeb 129:374 – 9
34. Cherkin DC, Deyo RA, Loeser JD, Bush T, Waddell G (1994) An international comparison of back surgery rates. Spine 19:1201 – 6
35. Connolly ES (1992) Surgery for recurrent lumbar disc herniation. Clin Neurosurg 39:211 – 6
36. Crafoord C, Hiertonn T, Lindblom K, Olsson SE (1958) Spinal cord compression caused by a protruded thoracic disc; report of a case treated with antero-lateral fenestration of the disc. Acta Orthop Scand 28:103 – 7
37. Diamant B, Karlsson J, Nachemson AL (1968) Correlation between lactate levels and pH in discs of patients with lumbar rhizopathies. Experimentia 24:1195 – 1196
38. Dooley JF, McBroom RJ, Taguchi T, Macnab I (1988) Nerve root infiltration in the diagnosis of radicular pain. Spine 13:79 – 83
39. Dora C, Schmid MR, Elfering A, Zanetti M, Hodler J, Boos N (2005) Lumbar disk herniation: do MR imaging findings predict recurrence after surgical diskectomy? Radiology 235:562 – 7
40. Dora C, Walchli B, Elfering A, Gal I, Weishaupt D, Boos N (2002) The significance of spinal canal dimensions in discriminating symptomatic from asymptomatic disc herniations. Eur Spine J 11:575 – 81
41. Ebeling U, Kalbarcyk H, Reulen HJ (1989) Microsurgical reoperation following lumbar disc surgery. Timing, surgical findings, and outcome in 92 patients. J Neurosurg 70:397 – 404
42. Eismont F, Currier B (1989) Current concepts review. Surgical management of lumbar intervertebral-disc disease. J Bone Joint Surg 71A:1266 – 1271
43. Fandino J, Botana C, Viladrich A, Gomez-Bueno J (1993) Reoperation after lumbar disc surgery: results in 130 cases. Acta Neurochir (Wien) 122:102 – 4
44. Farfan HF, Cossette JW, Robertson GH, Wells RV, Kraus H (1970) The effects of torsion on the lumbar intervertebral joints: The role of torsion in the production of disc degeneration. J Bone Joint Surg 52A:468 – 497
45. Floris R, Spallone A, Aref TY, Rizzo A, Apruzzese A, Mulas M, Castriota Scanderbeg A, Simonetti G (1997) Early postoperative MRI findings following surgery for herniated lumbar disc. Part II: A gadolinium-enhanced study. Acta Neurochir (Wien) 139:1101 – 7
46. Forristall RM, Marsh HO, Pay NT (1988) Magnetic resonance imaging and contrast CT of the lumbar spine. Comparison of diagnostic methods and correlation with surgical findings. Spine 13:1049 – 54
47. Garrido E, Humphreys RP, Hendrick EB, Hoffman HJ (1978) Lumbar disc disease in children. Neurosurgery 2:22 – 26
48. Gibson JN, Grant IC, Waddell G (1999) The Cochrane review of surgery for lumbar disc prolapse and degenerative lumbar spondylosis. Spine 24:1820 – 32
49. Gyntelberg F (1974) One year incidence of low back pain among male residents of Copenhagen aged 40 – 59. Dan Med Bull 21:30 – 6
50. Hagen KB, Hilde G, Jamtvedt G, Winnem MF (2000) The Cochrane review of bed rest for acute low back pain and sciatica. Spine 25:2932 – 9

51. Heikkila JK, Koskenvuo M, Heliovaara M, Kurppa K, Riihimaki H, Heikkila K, Rita H, Videman T (1989) Genetic and environmental factors in sciatica. Evidence from a nationwide panel of 9365 adult twin pairs. Ann Med 21:393–8
52. Herzog RJ (1996) The radiologic assessment for a lumbar disc herniation. Spine 21:19S–38S
53. Hirsch C, Jonsson B, Lewin T (1969) Low-back symptoms in a Swedish female population. Clin Orthop Relat Res 63:171–6
54. Hulme A (1960) The surgical approach to thoracic intervertebral disc protrusions. J Neurol Neurosurg Psychiatry 23:133–7
55. Igarashi T, Kikuchi S, Shubayev V, Myers RR (2000) 2000 Volvo Award winner in basic science studies: Exogenous tumor necrosis factor-alpha mimics nucleus pulposus-induced neuropathology. Molecular, histologic, and behavioral comparisons in rats. Spine 25:2975–80
56. Ikata T, Morita T, Katoh S, Tachibana K, Maoka H (1995) Lesions of the lumbar posterior end plate in children and adolescents. An MRI study. J Bone Joint Surg Br 77:951–5
57. Inman V, Saunders J (1947) Anatomicophysiological aspects of injuries to the intervertebral disc. J Bone Joint Surg 29A:461–475
58. Jensen MC, Brant-Zawadzki MN, Obuchowski N, Modic MT, Malkasian D, Ross JS (1994) Magnetic resonance imaging of the lumbar spine in people without back pain. N Engl J Med 331:69–73
59. Jonsson B, Stromqvist B (1993) Repeat decompression of lumbar nerve roots. A prospective two-year evaluation. J Bone Joint Surg Br 75:894–7
60. Kahanovitz N, Viola K, Muculloch J (1989) Limited surgical discectomy and microdiscectomy. A clinical comparison. Spine 14:79–81
61. Kambin P, Zhou L (1996) History and current status of percutaneous arthroscopic disc surgery. Spine 21:57S–61S
62. Kang JD, Georgescu HI, McIntyre-Larkin L, Stefanovic-Racic M, Donaldson WF, 3rd, Evans CH (1996) Herniated lumbar intervertebral discs spontaneously produce matrix metalloproteinases, nitric oxide, interleukin-6, and prostaglandin E2. Spine 21:271–7
63. Kawakami M, Weinstein JN, Chatani K, Spratt KF, Meller ST, Gebhart GF (1994) Experimental lumbar radiculopathy. Behavioral and histologic changes in a model of radicular pain after spinal nerve root irritation with chromic gut ligatures in the rat. Spine 19:1795–802
64. Kawakami M, Weinstein JN, Spratt KF, Chatani K, Traub RJ, Meller ST, Gebhart GF (1994) Experimental lumbar radiculopathy. Immunohistochemical and quantitative demonstrations of pain induced by lumbar nerve root irritation of the rat. Spine 19:1780–94
65. Kelsey JL (1975) An epidemiological study of the relationship between occupations and acute herniated lumbar intervertebral discs. Int J Epidemiol 4:197–205
66. Kelsey JL, Githens PB, White AA (1984) An epidemiologic study of lifting and twisting on the job and risk for acute prolapsed lumbar intervertebral discs. J Orthop Res 2:61–66
67. Kelsey JL, Hardy RJ (1975) Driving of motor vehicles as a risk factor for acute herniated lumber intervertebral disc. Am J Epidemiol 102:63–73
68. Kleiner JB, Donaldson WF, 3rd, Curd JG, Thorne RP (1991) Extraspinal causes of lumbosacral radiculopathy. J Bone Joint Surg Am 73:817–21
69. Komori H, Shinomiya K, Nakai O, Yamaura I, Takeda S, Furuya K (1996) The natural history of herniated nucleus pulposus with radiculopathy. Spine 21:225–9
70. Korhonen T, Karppinen J, Malmivaara A, Autio R, Niinimaki J, Paimela L, Kyllonen E, Lindgren KA, Tervonen O, Seitsalo S, Hurri H (2004) Efficacy of infliximab for disc herniation-induced sciatica: one-year follow-up. Spine 29:2115–9
71. Korhonen T, Karppinen J, Paimela L, Malmivaara A, Lindgren KA, Bowman C, Hammond A, Kirkham B, Jarvinen S, Niinimaki J, Veeger N, Haapea M, Torkki M, Tervonen O, Seitsalo S, Hurri H (2006) The treatment of disc-herniation-induced sciatica with infliximab: one-year follow-up results of FIRST II, a randomized controlled trial. Spine 31:2759–66
72. Korhonen T, Karppinen J, Paimela L, Malmivaara A, Lindgren KA, Jarvinen S, Niinimaki J, Veeger N, Seitsalo S, Hurri H (2005) The treatment of disc herniation-induced sciatica with infliximab: results of a randomized, controlled, 3-month follow-up study. Spine 30:2724–8
73. Kostuik JP, Harrington I, Alexander D, Rand W, Evans D (1986) Cauda equina syndrome and lumbar disc herniation. J Bone Joint Surg Am 68:386–91
74. Kramer J (1986) Bandscheibenbedingte Erkrankungen. Ursachen, Diagnose, Behandlung, Vorbeugung, Begutachtung. 2nd edn. Thieme, Stuttgart
75. Kuslich SD, Ulstrom CL, Michael CJ (1991) The tissue origin of low back pain and sciatica: a report of pain response to tissue stimulation during operations on the lumbar spine using local anesthesia. Orthop Clin North Am 22:181–7
76. Lacombe M (2006) Vascular complications of lumbar disk surgery. Ann Chir 131:583–9
77. Larson SJ, Holst RA, Hemmy DC, Sances A, Jr (1976) Lateral extracavitary approach to traumatic lesions of the thoracic and lumbar spine. J Neurosurg 45:628–37
78. Law JD, Lehman RA, Kirsch WM (1978) Reoperation after lumbar intervertebral disc surgery. J Neurosurg 48:259–63
79. Lawrence JS (1969) Disc degeneration. Its frequency and relationship to symptoms. Ann Rheum Dis 28:121–38

80. Lee YY, Huang TJ, Liu HP, Hsu RW (1998) Thoracic disc herniation treated by video-assisted thoracoscopic surgery: case report. Changgeng Yi Xue Za Zhi 21:453 – 7
81. Leonardi M, Pfirrmann CW, Boos N (2006) Injection studies in spinal disorders. Clin Orthop Relat Res 443:168 – 82
82. Lesoin F, Jomin M (1985) Posterolateral approach to thoracic disk herniations through transversoarthropediculectomy. Surg Neurol 23:375 – 9
83. Levi N, Gjerris F, Dons K (1999) Thoracic disc herniation. Unilateral transpedicular approach in 35 consecutive patients. J Neurosurg Sci 43:37 – 42; discussion 42 – 3
84. Love JG (1939) Removal of intervertebral disc without laminectomy. Proc Staff Meet Mayo 14:800
85. Mack MJ, Regan JJ, McAfee PC, Picetti G, Ben-Yishay A, Acuff TE (1995) Video-assisted thoracic surgery for the anterior approach to the thoracic spine. Ann Thorac Surg 59:1100 – 6
86. Macnab I (1971) Negative disc exploration. An analysis of the causes of nerve-root involvement in sixty-eight patients. J Bone Joint Surg Am 53:891 – 903
87. Maroon JC, Onik G, Sternau L (1989) Percutaneous automated discectomy. A new approach to lumbar surgery. Clin Orthop 238:64 – 70
88. Marshall LL, Trethewie ER (1973) Chemical irritation of nerve-root in disc prolapse. Lancet 2:320
89. Marshall LL, Trethewie ER, Curtain CC (1977) Chemical radiculitis. A clinical, physiological and immunological study. Clin Orthop 129:61 – 67
90. Masaryk TJ, Ross JS, Modic MT, Boumphrey F, Bohlman H, Wilber G (1988) High-resolution MR imaging of sequestered lumbar intervertebral disks. AJR Am J Roentgenol 150:1155 – 62
91. Matsui H, Kanamori M, Ishihara H, Yudoh K, Naruse Y, Tsuji H (1998) Familial predisposition for lumbar degenerative disc disease. A case-control study. Spine 23:1029 – 34
92. McCarron RF, Wimpee MW, Hudkins PG, Laros GS (1987) The inflammatory effect of nucleus pulposus. A possible element in the pathogenesis of low-back pain. Spine 12: 760 – 794
93. McCulloch JA (1996) Focus issue on lumbar disc herniation: macro- and microdiscectomy. Spine 21:45S–56S
94. Miranda H, Viikari-Juntura E, Martikainen R, Takala EP, Riihimaki H (2002) Individual factors, occupational loading, and physical exercise as predictors of sciatic pain. Spine 27:1102 – 9
95. Mixter WJ, Barr JS (1934) Rupture of intervertebral disc with involvement of the spinal canal. N Engl J Med 211:210
96. Mundt DJ, Kelsey JL, Golden AL, Pastides H, Berg AT, Sklar J, Hosea T, Panjabi MM (1993) An epidemiologic study of non-occupational lifting as a risk factor for herniated lumbar intervertebral disc. Spine 18:595 – 602
97. Muralikuttan KP, Hamilton A, Kernohan WG, Mollan RA, Adair IV (1992) A prospective randomized trial of chemonucleolysis and conventional disc surgery in single level lumbar disc herniation. Spine 17:381 – 7
98. Murata Y, Onda A, Rydevik B, Takahashi I, Takahashi K, Olmarker K (2006) Changes in pain behavior and histologic changes caused by application of tumor necrosis factor-alpha to the dorsal root ganglion in rats. Spine 31:530 – 5
99. Murata Y, Onda A, Rydevik B, Takahashi K, Olmarker K (2004) Selective inhibition of tumor necrosis factor-alpha prevents nucleus pulposus-induced histologic changes in the dorsal root ganglion. Spine 29:2477 – 84
100. Olmarker K, Blomquist J, Stromberg J, Nannmark U, Thomsen P, Rydevik B (1995) Inflammatogenic properties of nucleus pulposus. Spine 20:665 – 9
101. Olmarker K, Byrod G, Cornefjord M, Nordborg C, Rydevik B (1994) Effects of methylprednisolone on nucleus pulposus-induced nerve root injury. Spine 19:1803 – 8
102. Olmarker K, Larsson K (1998) Tumor necrosis factor alpha and nucleus-pulposus-induced nerve root injury. Spine 23:2538 – 44
103. Olmarker K, Myers RR, Kikuchi S, Rydevik B (2004) Pathophysiology of nerve root pain in disc herniation and spinal stenosis. In: Herkovitz HN, Dvorak J, Bell G, Nordin M, Grob D (eds) The lumbar spine. Lippincottt Williams & Wilkins, Philadelphia, pp 11 – 30
104. Olmarker K, Rydevik B, Hansson T, Holm S (1990) Compression-induced changes of the nutritional supply to the porcine cauda equina. J Spinal Disord 3:25 – 9
105. Olmarker K, Rydevik B, Holm S, Bagge U (1989) Effects of experimental graded compression on blood flow in spinal nerve roots. A vital microscopic study on the porcine cauda equina. J Orthop Res 7:817 – 23
106. Olmarker K, Rydevik B, Nordborg C (1993) Autologous nucleus pulposus induces neurophysiologic and histologic changes in porcine cauda equina nerve roots. Spine 18:1425 – 32
107. Perey O (1957) Fracture of the vertebral end-plate in the lumbar spine; an experimental biochemical investigation. Acta Orthop Scand Suppl 25:1 – 101
108. Perez-Cruet MJ, Kim BS, Sandhu F, Samartzis D, Fessler RG (2004) Thoracic microendoscopic discectomy. J Neurosurg Spine 1:58 – 63

109. Pfirrmann CW, Dora C, Schmid MR, Zanetti M, Hodler J, Boos N (2004) MR image-based grading of lumbar nerve root compromise due to disk herniation: reliability study with surgical correlation. Radiology 230:583 – 8
110. Podnar S (2006) Epidemiology of cauda equina and conus medullaris lesions. Muscle Nerve (in press)
111. Postacchini F (1999) Management of herniation of the lumbar disc. J Bone Joint Surg Br 81:567 – 76
112. Postacchini F (2001) Lumbar disc herniation: a new equilibrium is needed between nonoperative and operative treatment. Spine 26:601
113. Reulen HJ, Pfaundler S, Ebeling U (1987) The lateral microsurgical approach to the "extracanalicular" lumbar disc herniation. I: A technical note. Acta Neurochir (Wien) 84:64 – 7
114. Riew KD, Yin Y, Gilula L, Bridwell KH, Lenke LG, Lauryssen C, Goette K (2000) The effect of nerve-root injections on the need for operative treatment of lumbar radicular pain. A prospective, randomized, controlled, double-blind study. J Bone Joint Surg Am 82A: 1589 – 93
115. Rosenthal D, Rosenthal R, de Simone A (1994) Removal of a protruded thoracic disc using microsurgical endoscopy. A new technique. Spine 19:1087 – 91
116. Rothoerl RD, Woertgen C, Brawanski A (2002) When should conservative treatment for lumbar disc herniation be ceased and surgery considered? Neurosurg Rev 25:162 – 5
117. Ruetten S, Komp M, Godolias G (2005) An extreme lateral access for the surgery of lumbar disc herniations inside the spinal canal using the full-endoscopic uniportal transforaminal approach technique and prospective results of 463 patients. Spine 30:2570 – 8
118. Rydevik B, Garfin S (1989) Spinal nerve root compression. In: Szabo RM (ed) Nerve root compression syndromes: diagnosis and treatment. Slack Medical, New York, pp 247 – 261
119. Saal JS, Franson RC, Dobrow R, Saal JA, White AH, Goldthwaite N (1990) High levels of inflammatory phospholipase A2 activity in lumbar disc herniations. Spine 15:674 – 678
120. Scham SM, Taylor TK (1971) Tension signs in lumbar disc prolapse. Clin Orthop Relat Res 75:195 – 204
121. Schick U, Dohnert J, Richter A, Konig A, Vitzthum HE (2002) Microendoscopic lumbar discectomy versus open surgery: an intraoperative EMG study. Eur Spine J 11:20 – 6
122. Semmes RE (1939) Diagnosis of ruptured intervertebral disc without contrast myelography and comment upon recent experience with modified hemilaminectomy for their removal. Yale J Biol Med 11:433
123. Silvers HR (1988) Microsurgical versus standard lumbar discectomy. Neurosurgery 22: 837 – 41
124. Simmons JW, Nordby EJ, Hadjipavlou AG (2001) Chemonucleolysis: the state of the art. Eur Spine J 10:192 – 202
125. Simpson JM, Silveri CP, Simeone FA, Balderston RA, An HS (1993) Thoracic disc herniation. Re-evaluation of the posterior approach using a modified costotransversectomy. Spine 18:1872 – 7
126. Smith L (1964) Enzyme dissolution of the nucleus pulposus in humans. JAMA 187:137 – 40
127. Smyth MJ, Wright VJ (1977) The classic: Sciatica and the intervertebral disk. An experimental study. Clin Orthop 129:9 – 21
128. Spangfort EV (1972) The lumbar disc herniation. A computer-aided analysis of 2 504 operations. Acta Orthop Scand Suppl 142:1 – 95
129. Spengler DM (1982) Lumbar discectomy. Results with limited disc excision and selective foraminotomy. Spine 7:604 – 7
130. Stanley D, McLaren MI, Euinton HA, Getty CJ (1990) A prospective study of nerve root infiltration in the diagnosis of sciatica. A comparison with radiculography, computed tomography, and operative findings. Spine 15:540 – 3
131. Stillerman CB, Chen TC, Day JD, Couldwell WT, Weiss MH (1995) The transfacet pedicle-sparing approach for thoracic disc removal: cadaveric morphometric analysis and preliminary clinical experience. J Neurosurg 83:971 – 6
132. Suk KS, Lee HM, Moon SH, Kim NH (2001) Recurrent lumbar disc herniation: results of operative management. Spine 26:672 – 6
133. Takahashi K, Olmarker K, Holm S, Porter RW, Rydevik B (1993) Double-level cauda equina compression: an experimental study with continuous monitoring of intraneural blood flow in the porcine cauda equina. J Orthop Res 11:104 – 9
134. Takata K, Inoue S, Takahashi K, Ohtsuka Y (1988) Fracture of the posterior margin of a lumbar vertebral body. J Bone Joint Surg Am 70:589 – 94
135. Takata K, Takahashi K (1994) Hamstring tightness and sciatica in young patients with disc herniation. J Bone Joint Surg Br 76:220 – 4
136. Thome C, Barth M, Scharf J, Schmiedek P (2005) Outcome after lumbar sequestrectomy compared with microdiscectomy: a prospective randomized study. J Neurosurg Spine 2:271 – 8
137. Tokuhashi Y, Matsuzaki H, Uematsu Y, Oda H (2001) Symptoms of thoracolumbar junction disc herniation. Spine 26:E512 – 8

138. Vader JP, Porchet F, Larequi-Lauber T, Dubois RW, Burnand B (2000) Appropriateness of surgery for sciatica: reliability of guidelines from expert panels. Spine 25:1831 – 6
139. van Akkerveeken PF (1993) The diagnostic value of nerve root sheath infiltration. Acta Orthop Scand Suppl 251:61 – 3
140. van Tulder MW, Koes B, Malmivaara A (2006) Outcome of non-invasive treatment modalities on back pain: an evidence-based review. Eur Spine J 15 Suppl 1:S64 – 81
141. Waddell G (1982) An approach to backache. Br J Hosp Med 28:187, 190 – 1, 193 – 4, passim
142. Weber H (1983) Lumbar disc herniation. A controlled, prospective study with ten years of observation. Spine 8:131 – 40
143. Weiner BK, Fraser RD (1997) Foraminal injection for lateral lumbar disc herniation. J Bone Joint Surg Br 79:804 – 7
144. Weinstein JN, Bronner KK, Morgan TS, Wennberg JE (2004) Trends and geographic variations in major surgery for degenerative diseases of the hip, knee, and spine. Health Aff (Millwood) Suppl Web Exclusives:VAR81 – 9
145. Weinstein JN, Lurie JD, Olson PR, Bronner KK, Fisher ES (2006) United States' trends and regional variations in lumbar spine surgery: 1992 – 2003. Spine 31:2707 – 14
146. Weinstein JN, Lurie JD, Tosteson TD, Skinner JS, Hanscom B, Tosteson AN, Herkowitz H, Fischgrund J, Cammisa FP, Albert T, Deyo RA (2006) Surgical vs nonoperative treatment for lumbar disk herniation: the Spine Patient Outcomes Research Trial (SPORT) observational cohort. JAMA 296:2451 – 9
147. Weinstein JN, Tosteson TD, Lurie JD, Tosteson AN, Hanscom B, Skinner JS, Abdu WA, Hilibrand AS, Boden SD, Deyo RA (2006) Surgical vs nonoperative treatment for lumbar disk herniation: the Spine Patient Outcomes Research Trial (SPORT): a randomized trial. JAMA 296:2441 – 50
148. Weishaupt D, Zanetti M, Hodler J, Boos N (1998) MR imaging of the lumbar spine: prevalence of intervertebral disk extrusion and sequestration, nerve root compression, end plate abnormalities, and osteoarthritis of the facet joints in asymptomatic volunteers. Radiology 209:661 – 6
149. Wiese M, Kramer J, Bernsmann K, Ernst Willburger R (2004) The related outcome and complication rate in primary lumbar microscopic disc surgery depending on the surgeon's experience: comparative studies. Spine J 4:550 – 6
150. Williams MP, Cherryman GR, Husband JE (1989) Significance of thoracic disc herniation demonstrated by MR imaging. J Comput Assist Tomogr 13:211 – 4
151. Williams RW (1978) Microlumbar discectomy: a conservative surgical approach to the virgin herniated lumbar disc. Spine 3:175 – 82
152. Williams RW (1986) Microlumbar discectomy. A 12-year statistical review. Spine 11:851 – 2
153. Wood KB, Garvey TA, Gundry C, Heithoff KB (1995) Magnetic resonance imaging of the thoracic spine. Evaluation of asymptomatic individuals. J Bone Joint Surg Am 77:1631 – 8
154. Yabuki S, Kikuchi S, Olmarker K, Myers RR (1998) Acute effects of nucleus pulposus on blood flow and endoneurial fluid pressure in rat dorsal root ganglia. Spine 23:2517 – 23
155. Yeung AT, Tsou PM (2002) Posterolateral endoscopic excision for lumbar disc herniation: Surgical technique, outcome, and complications in 307 consecutive cases. Spine 27:722 – 31
156. Young S, Karr G, O'Laoire SA (1989) Spinal cord compression due to thoracic disc herniation: results of microsurgical posterolateral costotransversectomy. Br J Neurosurg 3:31 – 8
157. Zhu Q, Gu R, Yang X, Lin Y, Gao Z, Tanaka Y (2006) Adolescent lumbar disc herniation and hamstring tightness: review of 16 cases. Spine 31:1810 – 4

# 19 Lumbar Spinal Stenosis

Patrick O. Zingg, Norbert Boos

## Core Messages

- ✔ Lumbar spinal stenosis can be defined as any narrowing of the spinal canal, lateral recess or intervertebral foramen
- ✔ Spinal stenosis most frequently results from degenerative alterations of the motion segment
- ✔ Lumbar spinal stenosis is a common condition in elderly patients
- ✔ Spinal stenosis is often associated with degenerative spondylolisthesis
- ✔ Degenerative spondylolisthesis most frequently occurs at the L4/5 level in females
- ✔ The cardinal symptom of spinal stenosis is neurogenic claudication
- ✔ Neurologic examination of a patient often is remarkably normal
- ✔ The most important differential diagnosis is intermittent ischemic claudication
- ✔ MRI is the imaging modality of choice
- ✔ Conservative treatment may only relieve symptoms for a short time period
- ✔ Conservative treatment does not affect the natural history of spinal canal narrowing
- ✔ Surgery is generally accepted when the quality of life is substantially limited because of the neurogenic claudication
- ✔ Selective decompression (laminotomy) with preservation of the lamina is the preferred technique in the absence of segmental instability
- ✔ Instrumented fusion as an adjunct to laminectomy improves the long-term results in degenerative spondylolisthesis with spinal stenosis

## Epidemiology

Narrowing of the spinal canal was first described by Portal in 1803 [74]. However, **Verbiest** was the first to describe the clinical symptom of neurogenic claudication as a result of spinal canal stenosis and established this pathology as a clinical entity in the 1950s [97].

Verbiest first established lumbar spinal stenosis as a clinical entity

Arnoldi proposed one of the first definitions of spinal stenosis and classically defined the pathology as "any type of narrowing of the spinal canal, nerve root canals or intervertebral foramina" [5]. Kirkaldy-Willis substantially contributed to our understanding of the pathogenesis of lumbar spinal stenosis [54–56].

Spinal stenosis can be defined as any type of narrowing of the spinal canal, lateral recess or intervertebral foramina

Various conditions can lead to a narrowing of the spinal canal but it is most frequently due to degenerative changes. Congenital narrowing of the spinal canal is relatively rare and often associated with generalized disorders such as achondroplasia. Data on the incidence and prevalence of a congenitally narrow spinal canal is very limited.

Spinal stenosis is predominantly due to degenerative changes

Degenerative lumbar stenosis is a common condition in elderly patients after the fifth life decade, a finding which is supported by autopsy studies. Disc degeneration, facet joint osteoarthritis, or osteophytes are encountered in 90–100% of subjects over 64 years of age [65, 99].

Lumbar spinal stenosis is a common condition in elderly patients

By the age of 65 years, myelographic evidence of lumbar spinal stenosis is present in 1.7–6% of adults [16]. Moreover, stenosis has been found in up to 80% of

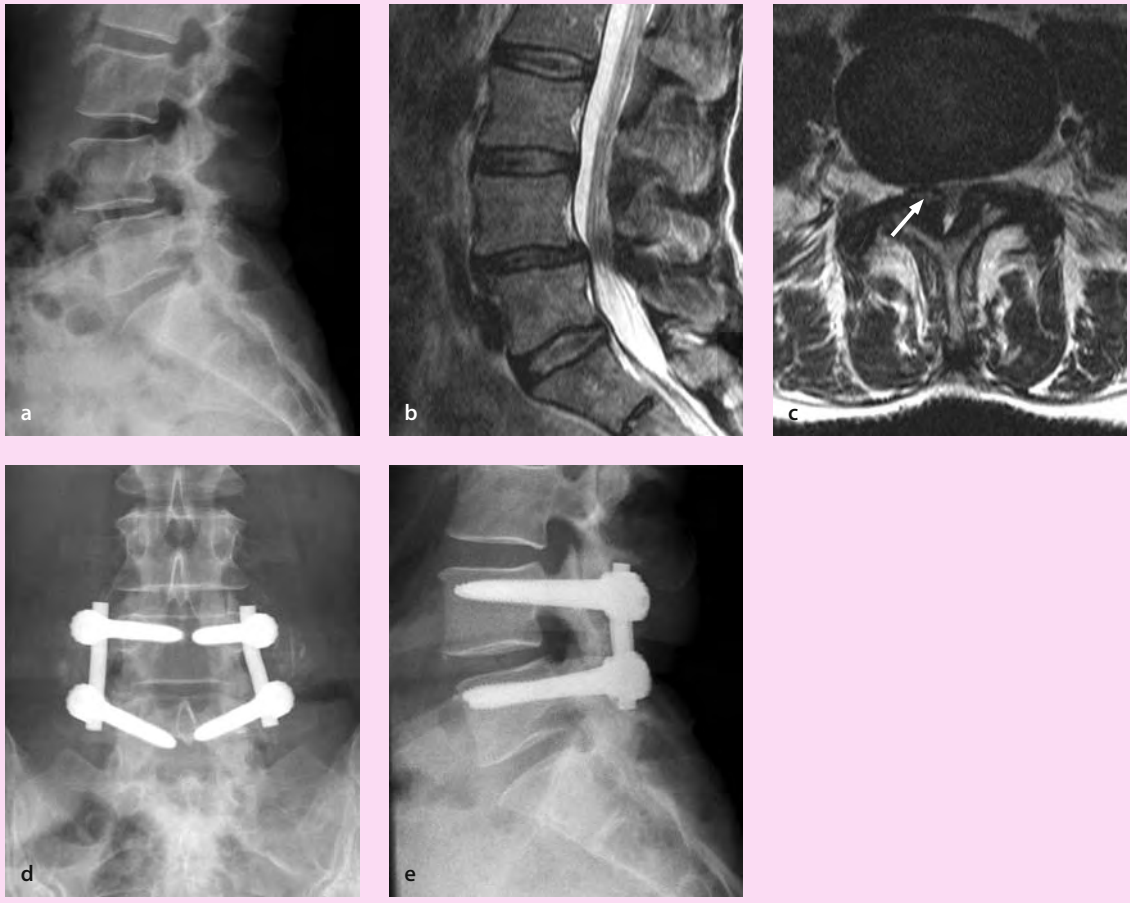


## Case Introduction

A 68-year-old woman presented with severe buttock and posterior thigh pain during standing and walking. While sitting the patient was completely pain free. She had concomitant back pain which did not respond well to physiotherapy. Walking distance was limited to 100–200 m. The physical and neurological assessment was unremarkable. Standing lateral radiograph showed a degenerative spondylolisthesis at the level of L4/5 (a). An MRI scan revealed an hourglass form of the thecal sac at the level of L4/5 (b) and a severe stenosis in the axial view. Note the small facet joint cyst on the right L4/5 joint causing a lateral recess stenosis (*arrow*) (c). Because of the severely limited quality of life and ineffective nonoperative treatment, the patient opted for surgery. A decompression of the L4/5 level with resection of the inferior two-thirds of the lamina was necessary to completely decompress the spinal stenosis, which was most severe under the lamina of L4. An instrumented fusion with pedicle screws was done to stabilize the degenerative spondylolisthesis and allow for better long term results (d, e). The patient's symptoms completely disappeared immediately after surgery and she returned to her regular activities within 3 months postoperatively.

The extent of the stenosis is poorly correlated with clinical symptoms

subjects aged over 70 years [87]. However, a poor correlation exists between radiological stenosis and symptoms [33, 34]. Up to 21% of non-symptomatic subjects over 60 years of age demonstrate stenosis on MRI [13]. In a Swedish study, the annual incidence of lumbar spinal stenosis was 5 per 100000 inhabitants [42]. Other studies reported that among patients who consult a general physician or a specialist for low-back pain, 3% and 14%, respectively, may have spinal stenosis [23, 30, 61]. The rate of spinal stenosis surgery reported is 3 to 11.5 per 100000 inhabitants per year [11, 40, 42]. With an improved life expectancy and the proportion of individuals older than 65 years (20% in 2026 [51]), the incidence of spinal stenosis will further increase proportionally.

## Pathogenesis

### Anatomy

In adults, the lumbar spinal canal may show an elliptical, rounded triangular, or trefoil **configuration**. Commonly, the transition from the thoracic to the sacral spine is characterized by a gradual change from a more circular to a more triangular shape. The trefoil shape of the spinal canal mostly occurs at the fifth lumbar level.

Size and shape of the spinal canal are dependent on the level

The anteroposterior diameter of the lumbar spinal canal usually decreases from L1 to L3 and increases from L3 to L5 [58, 59, 71]. In compensation, a small increase in the transverse diameter from L1 to L3 is present. Below L3, the transverse and anteroposterior diameters increase simultaneously [71]. Cross-sectional areas tend to decrease from L1 to L2 and remain rather constant between L2 and L4, followed by an increase at L5 [71]. The results of a number of morphometric studies are indicative of racial differences in transverse and sagittal diameters of the lumbar spinal canal [2, 59, 72, 100]. It is evident that relatively more space is available for the neural tissue in the lower lumbar spine.

The **ligamentum flavum** covers the posterolateral aspect of the spinal canal and is longitudinally oriented. The large amount of elastin fibers explains its typical yellow aspect. The yellow ligament originates from the anterior aspect of the upper lamina and it inserts at the upper rim of the lower lamina. Laterally, it represents the anterolateral capsule of the zygapophyseal joints and reaches into the lateral recess. The capsular portion is thinner than the interlaminar portion. Particularly, the interlaminar portion may hypertrophy and result in spinal stenosis [103].

The **intervertebral foramen** has an inverted tear-drop or ear-shaped sagittal cross section and is more oval at the exit [82]. The anterior wall of the foramen consists of the posterolateral aspect of the vertebrae and the intervertebral disc, respectively. The ligamentum flavum, the pars interarticularis of the upper vertebra and the superior articular facet of the lower vertebra form the posterior border of the foramen. The two adjacent pedicles form the upper and lower foramen borders. The foramen is mostly narrowed by osteophytes, decreasing disc height and foraminal disc protrusions.

### Pathogenesis

Differentiate a narrow from a stenotic canal

Lumbar spinal stenosis can be defined as any type of narrowing of the spinal canal, nerve root canals, or the intervertebral foramina [66]. However, if compression of neural structures is absent, the canal should be described as narrow but not stenotic [77].

The sequences of the progressive age-related changes which finally lead to the occurrence of a central or lateral stenosis have been nicely described by Kirkaldy-Willis [54–56]. This suggested sequence of events highlights the relationship within the **three-joint complex** (Fig. 1).

The hypertrophy of the yellow ligament results in a progressive stenosis

The pathomechanism of **central spinal stenosis** is predominantly related to a hypertrophy of the yellow ligament which is a result of a compensatory mechanism to restabilize a segmental hypermobility (Case Introduction). Furthermore, bony canal compromise is caused by the occurrence of facet joint enlargement (osteoarthrosis), osteophyte formation, and degenerative spondylolisthesis. This finally results in a progressive compression of the cauda equina (Fig. 2).

The majority of **lateral recess stenosis** is produced by disc height decrease, posterolateral disc protrusion or hypertrophy of the superior articular process. As a result of the degenerative changes with disc height loss, enlargement of the facet joints and foraminal disc herniation, the exiting nerve root is compressed.

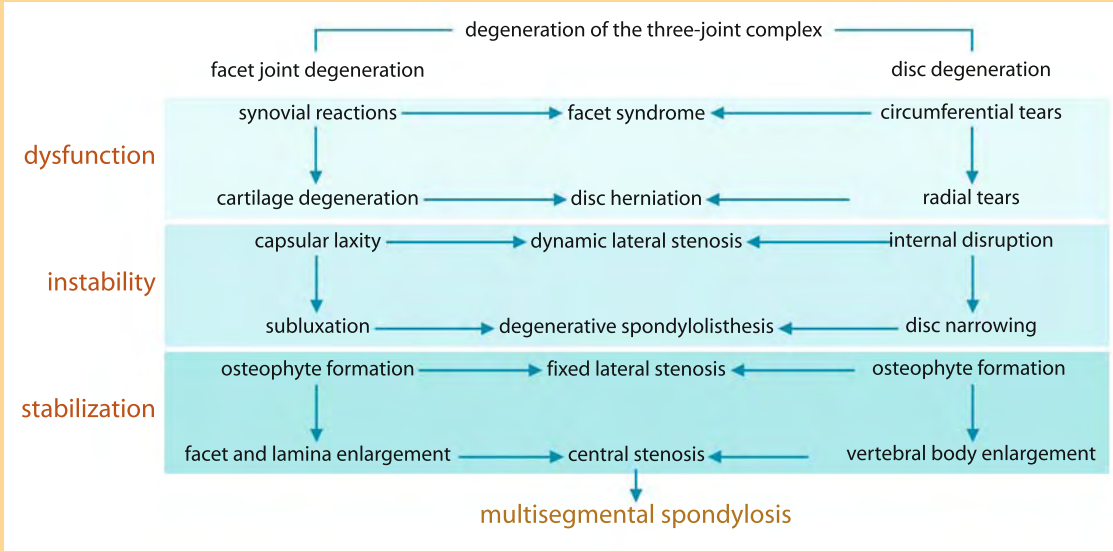


**Figure 1. Degeneration of the three-joint complex**

According to Kirkaldy-Willis et al. [55] (modified).

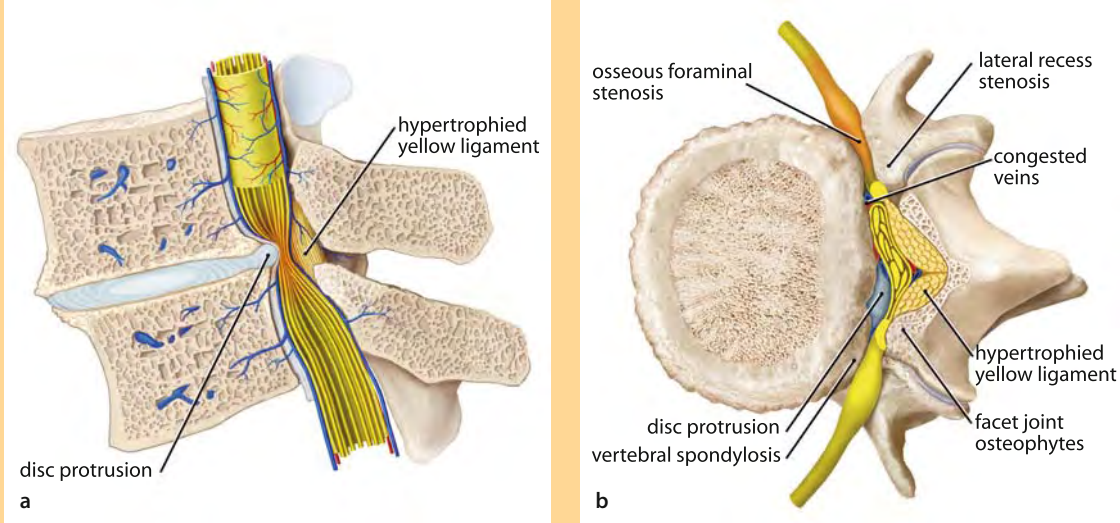


**Figure 2. Pathomorphology of central, lateral recess and foraminal stenosis**

Foraminal and lateral recess stenosis frequently cause radiculopathy

**Foraminal stenosis** may also result from isthmic spondylolisthesis when the nerve root is compressed as a result of the olisthetic vertebra and disc height loss [5]. Lateral recess and foraminal stenosis are a common cause of lumbar radiculopathy (see Chapter 18).

Narrowing of the spinal canal can also be seen as a complication of **metabolic disorders** such as:

- diffuse idiopathic skeletal hyperostosis (DISH)
- Paget's disease
- acromegaly

- hypoparathyroidism, pseudohypoparathyroidism
- X-linked hypophosphatemic osteomalacia

## Spinal Claudication Syndrome

The narrowing of the spinal canal leads to a compression of the cauda equina and its nerve roots. However, there is no direct relationship between the extent of the stenosis and clinical symptoms. This finding remains unexplained. Furthermore, patients are usually asymptomatic when sitting and lying indicating a strong functional influence. There are two prevailing theories that try to explain **intermittent claudication**:

The extent of stenosis is not closely correlated with symptoms

- neurologic compression theory
- vascular compression theory

### Neurogenic Compression Theory

Prolonged compression of a peripheral nerve followed by mechanical stimulation is known to produce abnormal electrical discharge [36], thereby causing pain in experimental animal studies [10]. Long-standing direct mechanical compression of nerve roots leads to decreased cerebrospinal fluid supply of the nerve root [85, 86]. Impaired nutritional supply [68] results in microvascular changes [85, 86], and causes edema [69], accumulation of noxious substances, deterioration [17, 104] and fibrosis [62]. The combination of these changes may explain neurological dysfunction. This theory does not cover well the functional aspects of neurogenic claudication.

Mechanical nerve root compression results in decreased nutrition, microvascular changes, edema and fibrosis

### Vascular Compression Theory

The vascular compression theory suggests that spinal stenosis has pathologic effects on the blood supply of the cauda equina. Particularly, multiple-level central stenosis is associated with spinal claudication. It is assumed that **venous congestion** between the levels of stenosis [67, 70, 76] compromises nerve root nutrition and results in clinical symptoms. Additionally, the compressed nerve root arterioles may lose the ability to respond to exercise by vasodilatation [9]. This compromise explains that walking produces back, buttock and leg pain as well as heaviness and discomfort in the lower limbs. During rest the vascular (nutritional) supply may suffice and the patient may be asymptomatic.

Venous congestion and inadequate arterial vasodilation impairs nerve root nutrition during walking

However, a critical look indicates that some aspects of the clinical syndrome still remain not well explained. This is particularly valid for the fact that patients even with severe stenosis can be asymptomatic.

## Classification

The classification of lumbar stenosis is important because of its impact on the treatment approach [78]. Spinal stenosis may be **classified according to** its:

- etiology
- location
- pathomorphology

Arnoldi et al. [5] suggested an **etiology-based classification** distinguishing two major groups (Table 1).

Congenital stenosis is divided additionally into idiopathic and achondroplastic etiologies. Congenital lumbar stenosis is rare and is often associated with gen-

**Table 1.** Etiology-based classification

| Congenital stenosis | Acquired stenosis |
|---|---|
| • idiopathic<br>• achondroplastic | • degenerative<br>• congenital with secondary degenerative changes<br>• isthmic spondylolisthesis<br>• metabolic<br>• iatrogenic (postlaminectomy)<br>• post-traumatic |

eralized disorders such as achondroplasia. Identification is usually in infancy or childhood. Stenosis may develop at several levels of the vertebral column and may often lead to serious neurologic deficits. The vast majority of patients present with acquired lumbar canal stenosis. It may occur due to degenerative processes of the lumbar spine during aging [65, 99] or less frequently is caused by general metabolic disorders, postsurgical or post-traumatic conditions.

An **anatomic classification** differentiates (Fig. 3):

- central stenosis
- lateral recess stenosis
- foraminal stenosis

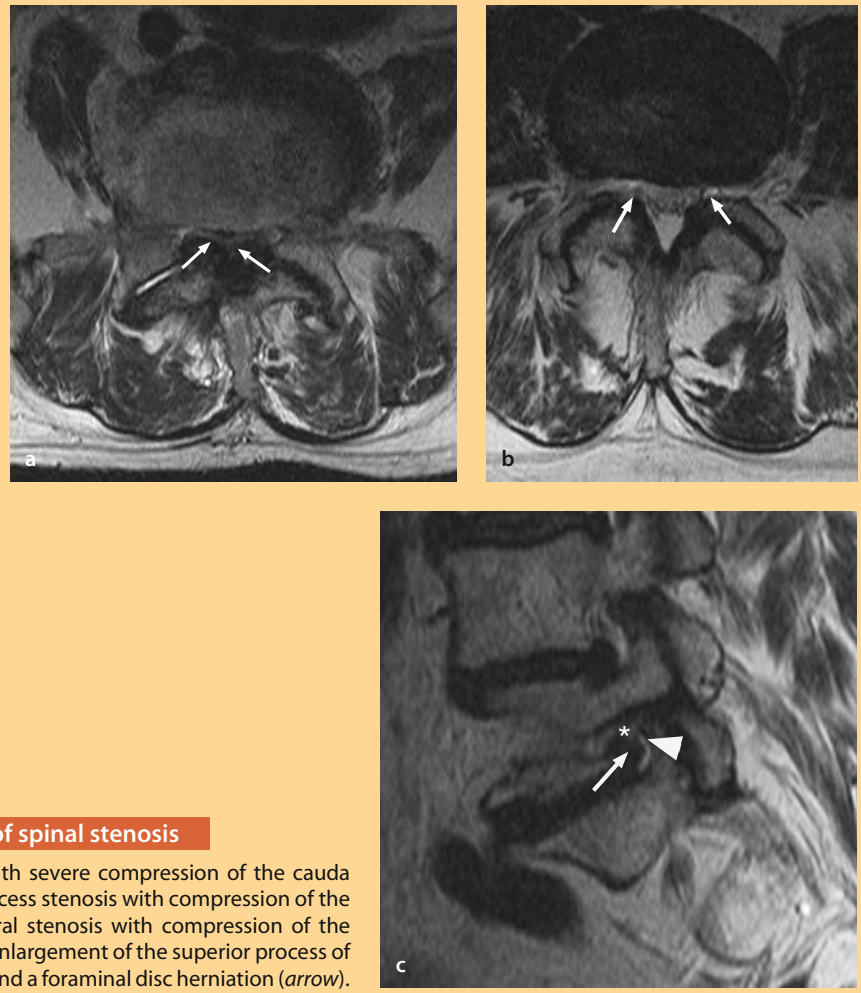


**Figure 3. Classification of spinal stenosis**

a Central spinal stenosis with severe compression of the cauda equina (*arrows*). b Lateral recess stenosis with compression of the exiting nerve roots. c Lateral stenosis with compression of the nerve root (*) as a result of enlargement of the superior process of the facet joint (*arrowhead*) and a foraminal disc herniation (*arrow*).

A **pathomorphological classification** considers the underlying pathology such as:

- hypertrophy of the ligamentum flavum
- hypertrophy of the facet joints
- osteophyte formations (spurs)
- disc herniation
- synovial facet joint cysts
- vertebral displacements (anterior/lateral)

## Clinical Presentation

### History

Lumbar spinal stenosis is usually a chronic condition, sometimes but not typically with a long history of low-back pain. Occasionally, the stenosis may become symptomatic after a minor trauma or unusual physical stress but usually the onset is insidious. Patients with a congenitally narrow canal may acutely present with major neurologic deficit due to the occurrence of an additional disc protrusion. In patients with severe congenital stenosis, symptoms may occur in their twenties to thirties, whereas symptom onset in the sixth and seventh decades is common for acquired degenerative stenosis.

The symptom onset of spinal stenosis is usually insidious

The **cardinal symptom** of spinal stenosis is **neurogenic claudication**, which presents as:

- numbness, weakness and discomfort in the legs while walking or prolonged standing
- regression of symptoms during sitting and rest

The characteristic finding in neurogenic claudication is that the symptoms regress during **sitting and rest**.

Leg symptoms usually improve or disappear during sitting

During sitting (forward bending) the spinal canal is widened, which decreases the compression of the cauda equina. Patients may be asymptomatic while riding a bicycle because they are in a forward bend position.

The **painfree walking distance** may vary from day to day. Typically symptoms will occur at a smaller distance if walking downhill due to the increased lumbar lordosis with consecutive narrowing of the spinal canal. Patients may provoke symptoms after a certain walking distance but be able to continue further before having to bend forward or sitting for pain relief. Furthermore, the distance required to develop these symptoms will decrease with increasing severity of the degenerative changes. At rest, the patients usually complain of few or no symptoms at all. The leg symptoms may also be described as paresthesia, cramps, burning pain, or weakness. Some patients only report heaviness or deadness of the limbs and a sense that their legs are giving way.

The painfree walking distance can vary from day to day

Patients with lateral canal stenosis may present with a **radicular claudication**. Similarly to neurogenic claudication, the symptoms can be provoked during walking and prolonged standing but are localized to a nerve root dermatome. The symptoms are not so clear in cases of a multilevel foraminal stenosis. These patients, however, often report signs of a mild radiculopathy during rest which worsens on activity. However, some patients present with a radicular pain syndrome during rest and particularly during the night. It is assumed that in those cases the postural change results in a narrowing of the foramen, which results in the pain provocation.

Nerve root claudication is characterized by radicular pain on walking

Additional but **less frequent symptoms** may be:

- mechanical low-back pain (worse on activity)
- atypical leg pain (non-radicular distribution)
- cauda equina syndrome (very rare)

Walking-related back and buttock pain is not uncommon

In patients suffering from lumbar spinal stenosis, pain in the lower spine, buttocks or posterior legs is not uncommon. Often this back pain becomes worse on activity. This finding can be due to the stenosis itself and can be explained by an involvement of the posterior rami of the nerve roots. It may also be related to a segmental instability, e.g. degenerative spondylolisthesis (Case Introduction). Rarely, the patients present with an acute or subacute onset of a cauda equina syndrome. Nevertheless, it is important to explore the urinary function and ask for bowel incontinence because many patients do not see the correlation with their main symptoms and tend not to report bowel and bladder dysfunction.

Always explore for bowel and bladder dysfunction

## Physical Findings

The physical exam most frequently is normal

Clinical examination in spinal stenosis most often is remarkably normal. As in any spinal disorder, a thorough neurological examination (see Chapter 11) is mandatory. The **most frequent physical findings** are [50]:

- limited lumbar extension 66 – 100 %
- sensory deficit 32 – 58 %
- muscle weakness 18 – 52 %
- straight leg raising 10 – 90 %
- absent knee reflexes 10 – 50 %
- absent ankle reflexes 50 – 68 %

Consider peripheral neuropathy in cases of absent ankle jerks and sensory deficits

However, these symptoms are obviously non-specific. Pain with extension or a voluntary decrease in the range of lumbar extensions is often seen. Dermatomal sensory loss and muscle weakness are uncommon at rest, although they may appear if the patient is reexamined after walking to their tolerance limit. Loss of ankle jerks and distal vibration sense may be present, but are common in the older age group. Straight-leg raising is usually normal.

Assess the peripheral pulses to detect vascular stenosis

Diminished peripheral pulses or limitation of hip movement may increase suspicion for the most frequent differential diagnosis, i.e. **vascular claudication** and **osteoarthritis** of the hip joint. Sometimes signs of a cervical myelopathy may be seen, because lumbar stenosis is associated with cervical canal narrowing in 5 % of cases [21].

A reliable assessment of the walking distance is an important parameter for determining the outcome of surgical treatment. The so-called **shuttle walking test** has been evaluated for spinal stenosis and can be recommended for this purpose [93].

# Diagnostic Work-up

The diagnosis of spinal stenosis is mainly based on the patient's clinical symptoms and signs. However, the confirmation of a clinical diagnosis is only made by imaging studies [3, 12, 14, 52, 90]. Neurophysiologic studies can be helpful to further confirm the diagnosis and allow for a differential diagnosis.

## Imaging Studies

### Standard Radiographs

Standard anteroposterior and lateral radiographs do not permit a final diagnosis. Nevertheless, findings (Fig. 4) often associated with spinal stenosis are:

- degenerative spondylolisthesis
- degenerative scoliosis
- congenitally narrow spinal canal

Degenerative spondylolisthesis is indicative of a spinal stenosis

**Degenerative spondylolisthesis** particularly at the L4/5 level in females is frequently associated with spinal stenosis (Fig. 4a). Isthmic spondylolisthesis is most common at the L5/S1 level and will produce nerve root impingement at the level of the defect while degenerative spondylolisthesis is more likely to produce constriction of the entire cauda equina. In patients with degenerative scoliosis, the stenosis is often found at the apex of the curve (L2/3 and L3/4) (Fig. 4b). On the anteroposterior view, the interpedicular distance should be identified. In healthy individuals it increases progressively from the L1 to the L5 level. If the interpedicular distance is narrow (Fig. 4c), it indicates a narrow spinal canal. Radiological signs for congenital or developmental stenosis in the lateral view are short pedicles indicating a decreased sagittal canal diameter (Fig. 4d).

**Less reliable findings** implying lateral recess or foraminal stenosis are:

- disc space narrowing
- isthmic spondylolisthesis
- severe facet osteoarthritis

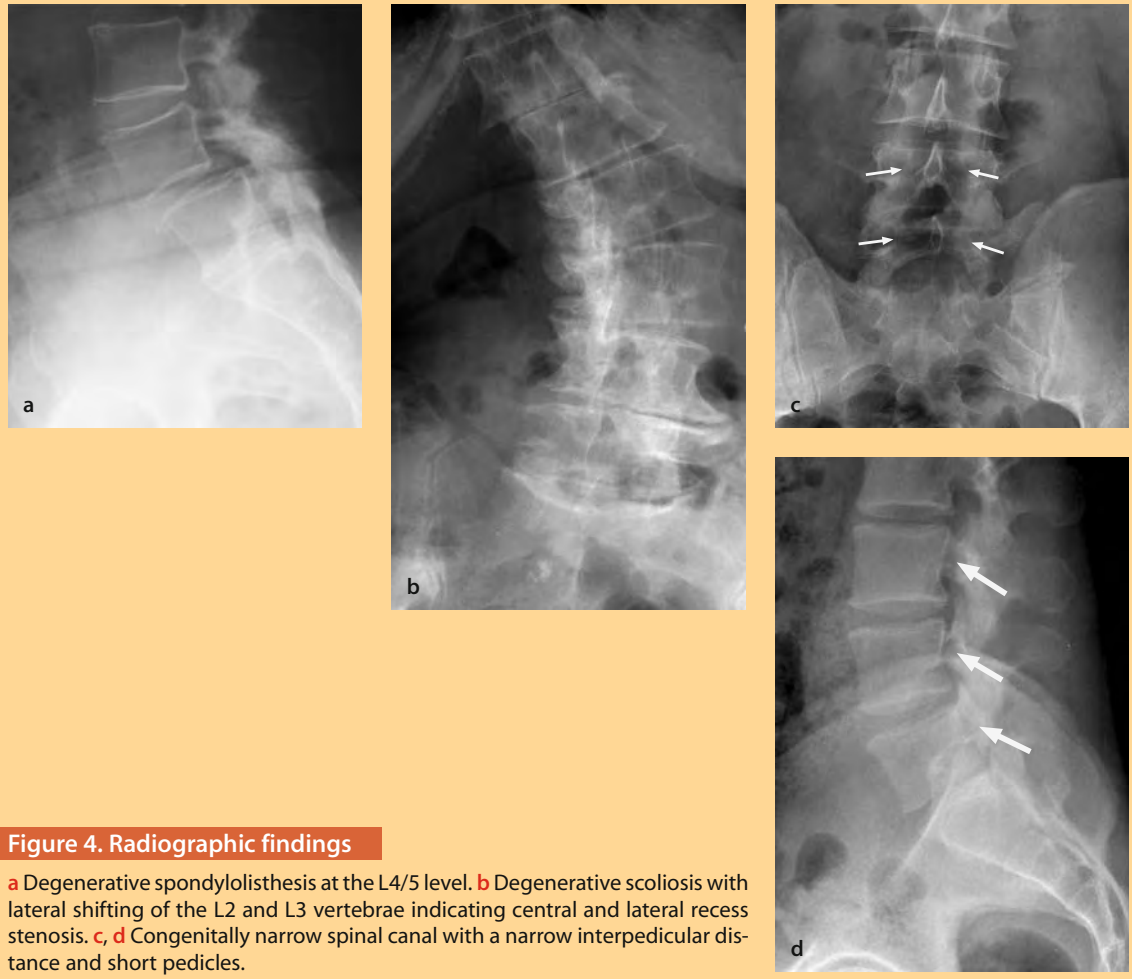


**Figure 4. Radiographic findings**

a Degenerative spondylolisthesis at the L4/5 level. b Degenerative scoliosis with lateral shifting of the L2 and L3 vertebrae indicating central and lateral recess stenosis. c, d Congenitally narrow spinal canal with a narrow interpedicular distance and short pedicles.

The spinous processes and laminae should be identified to diagnose any previous surgical decompressive procedure. Scalloping of the posterior aspect of the vertebral body may suggest a congenital process such as achondroplasia, acromegaly, neurofibromatosis, mucopolysaccharidosis, or a tumor.

### Magnetic Resonance Imaging

MRI is the imaging study of choice

Magnetic resonance imaging (MRI) is excellent in demonstrating potential causes of nerve root compression, including spinal stenosis. Compared to computed tomography (CT), MRI has a significant advantage because of its better soft tissue resolution. Encroachment on the spinal canal with inward bulging of discs and yellow ligaments usually plays a significant role in narrowing of the bony spinal canal and can be depicted excellently by MRI.

MRI studies usually encompass a T1- and T2-weighted sagittal and a T2-weighted axial scan. **Characteristic findings** of spinal stenosis include:

- thickened ligamentum flavum (Fig. 5a)
- facet joint hypertrophy (Fig. 5b)
- hourglass appearance of spinal canal on sagittal images (Fig. 5c)
- facet joint synovial cysts (Fig. 5d, e)
- trefoil appearance of the thecal sac (indicative of spinal lipomatosis)
- obliterated perineural fat in neural foramina (Fig. 5f)
- short pedicles
- vertebral endplate osteophytes

Parasagittal T1-weighted images define the integrity of the foramen. The normal nerve root has a low signal and is surrounded by the higher intensity signal of fat. Obliteration of the fat is indicative of a foraminal stenosis (Fig. 5f).

The extent of stenosis and clinical symptoms are not closely correlated

Stenosis is not a pathological entity per se as it appears in up to 21 % of asymptomatic subjects over 60 years of age on MR images [13]. In addition, a poor correlation between radiological stenosis and symptoms is well established [33].

Debate arises about the value of a **functional examination** of the spinal canal. A simple assessment of the postural influence, e.g. on a degenerative spondylolisthesis, can be made by comparing the standard radiograph with the prone MRI. Often a partial reduction during the prone position is seen which indicates the mobility of the slip. **Upright MRI** has been reported to be helpful in the diagnostic assessment [88, 102], but the chance of detecting a pathology not seen on conventional MRI which would change the therapeutic approach is minimal [101]. So far, no single study has proven the added diagnostic value in terms of treatment decisions.

Functional examinations rarely change treatment strategy

### Computed Tomography and CT Myelography

CT is rarely needed in the presence of an MRI scan. The benefits of CT over plain films are that it can provide greater resolution in terms of an increased ability to appreciate density differences. A second advantage of CT is its ability to image in different planes, either directly or by multiplanar reconstruction. On CT, midsagittal lumbar canal diameters less than 10 mm are regarded as an absolute stenosis and midsagittal lumbar canal diameters less than 13 mm represent a relative stenosis [98].

CT myelography is an alternative in case of MRI contraindications

Compared to MR imaging, the disadvantage of CT is that it does not allow good visualization of the nerve roots and exposes patients to radiation. If MRI is not indicated (e.g. pacemaker, metallic artifacts), CT myelography provides the best alternative to confirm nerve root involvement. However, CT myelography may not display foraminal stenosis because the dural root sheath ends at the entrance of the foramen.

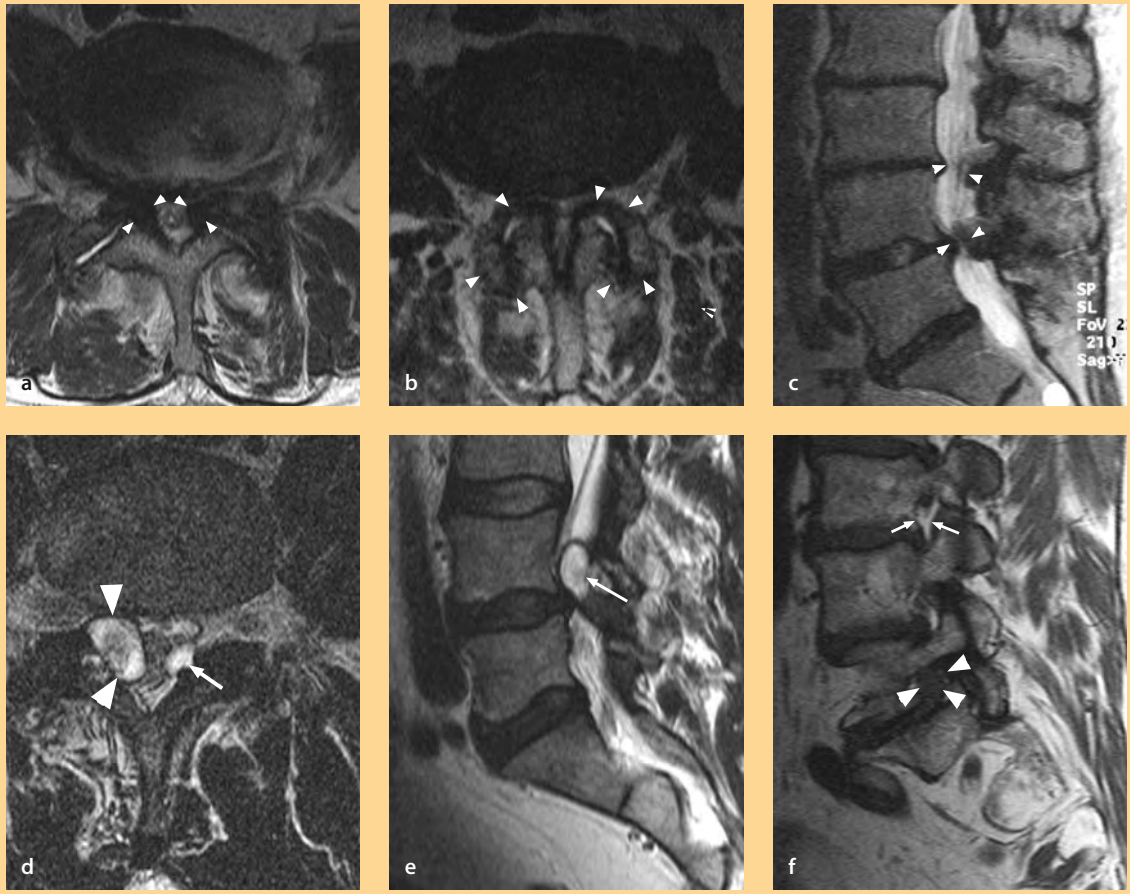


**Figure 5. MRI characteristics of spinal stenosis**

**a** Hypertrophy of the yellow ligament (*arrowheads*) on a T2W axial scan. **b** Facet joint hypertrophy with joint effusion (*arrowheads*) on a T2W axial image. **c** Hourglass appearance of the spinal canal (*arrowheads*) on a sagittal T2W image. **d** Large facet joint synovial cysts on the right side (*arrowheads*) and a small cyst on the left side (*arrow*). **e** A large facet joint cyst is compressing the thecal sac shown on a T2W sagittal image. **f** Fat in the foramen appears with a bright signal on T1W image (*arrows*). Obliterated perineural fat (*arrowheads*) in neural foramina indicating foraminal stenosis which is aggravated by a small disc protrusion.

## Neurophysiologic Studies

Neurophysiologic studies are helpful in the diagnostic work-up of equivocal cases

Neurophysiologic studies are a reasonable supplement to the clinical and radiological assessments. Somatosensory evoked potentials (SSEPs) and motor evoked potentials (MEPs) investigate the central nervous system pathways while EMG and nerve conduction velocity (H-reflex, F-wave) are especially useful for investigating peripheral sensorimotor pathways (see Chapter 12).

Neurophysiologic studies allow the affection of the cauda equina to be confirmed in the majority of patients and provide a **differential diagnosis from peripheral neuropathy**, musculoskeletal and vascular disorders, which are especially frequent in the older population. In a study population of patients undergoing lumbar decompression, the neurological examination was normal in 70% of patients or showed only minor and non-specific motor and/or sensory deficits. However, 87% of patients showed pathological electrophysiological recordings. The tibial SSEP was delayed in 79% and the H-reflex in 56% of patients. A diminished compound motor action potential (CMAP) was found in 39% of patients [20].

**Neurophysiologic assessment** is **indicated:**

- to confirm the clinical relevance of imaging findings in equivocal cases
- to identify a peripheral neuropathy
- to differentiate radiculopathy and mononeuropathy
- to differentiate non-specific neurological complaints

## Differential Diagnosis

The most common differential diagnosis of neurogenic claudication is intermittent ischemic claudication due to peripheral vascular disease (Table 2):

**Table 2.** Differentiation of vascular and neurogenic claudication

| Signs and symptoms | Vascular | Neurogenic |
|---|---|---|
| walking distance | • fixed | • variable |
| type of pain | • cramps, tightness | • dull ache, numbness |
| relief at cessation of activity | • immediate | • delayed |
| back pain | • rarely | • occasionally |
| pain relief | • standing | • flexion and sitting |
| posture provocation | • uncommon | • common |
| walking up hill | • pain | • no pain |
| bicycle riding | • pain | • no pain |
| pulses | • absent | • normal |
| trophic changes | • likely | • absent |
| muscle atrophy | • rarely | • occasionally |

In equivocal cases, ultrasound screening for the presence of pulses and subsequently **angiography** is indicated for differential diagnosis. The **bicycle test** of von Gelderen can be used to distinguish neurogenic from vascular claudication syndromes [19]. Neurogenic claudication has been described as a result of spinal arteriovenous malformations, but such a presentation is extremely rare. Tumors of the cauda equina usually do not produce claudication symptoms. Other differential diagnoses are less frequent. Low-back pain and referred pain associated with non-stenotic lumbar degenerative disease may sometimes mimic neurogenic claudication.

Peripheral neuropathy is a frequent concomitant finding or differential diagnosis

**Peripheral neuropathy** is often found as an independent additional pathology in elderly patients presenting with spinal stenosis. A preoperative diagnosis is important for a proper consultation of the patient about the future treatment result because the neuropathy will remain unaddressed and may result in patient dissatisfaction.

## Non-operative Treatment

The prevailing symptom of patients with lumbar spinal stenosis is neurogenic claudication while back and radicular leg pain is less frequently a predominant complaint. Neurogenic claudication results from a narrowing of the spinal canal, nerve root canals, or intervertebral foramina which cannot be addressed by any form of non-operative treatment. However, it is anecdotally well known that the course of patients with spinal stenosis is sometimes very stable over time and many patients report intermittent improvement.

## Natural History

Natural course of spinal stenosis is generally benign

Little is known about the natural history of spinal stenosis. Some authors reported that the natural course is benign and that the subjective and physical manifestations can be remarkably stable [43]. After a mean follow-up period of 59 months, symptoms were unchanged in 70 %, improved in 15 %, and worsened in 15 % of patients [43]. Since no proof of deterioration was found, it was concluded that expectant observation could be an alternative to surgery [43]. Despite a benign natural history, the long term course is characterized by a slow deterioration because the motion segment degeneration (Fig. 2) progressively leads to a worsening of the stenosis. The end stage of the disease can be described in terms of a completely immobilized patient in whom the stenosis severely impacts on the remaining quality of life.

## Non-operative Options

Conservative measures may be indicated to relieve symptoms in patients with only mild and intermittent symptoms or only minimal interference with lifestyle (Table 3):

**Table 3.** Favorable indications for non-operative treatment

- mild claudication symptoms
- mild to moderate radiculopathy
- absence of motor deficits
- concomitant back pain
- minimal interference with lifestyle

Conservative therapy may be the first choice if surgery is associated with a potentially high perioperative risk for general medical reasons.

**Conservative treatment options** may consist of:

- medication (analgetics, NSAIDs, muscle relaxants)
- administration of calcitonin (nasal spray, subcutaneous, intramuscular)
- postural education
- therapeutic exercise with avoidance of extension
- epidural infiltration of corticosteroids (see Chapter 10)

The scientific evidence for the effectiveness of conservative measures is limited

Various types of oral medication are available to control pain in patients with spinal stenosis and help to control the symptoms. However, there is no evidence in the literature on the clinical effectiveness. The administration of **calcitonin** has been reported to improve the symptoms of neurogenic claudication [22, 75]. However, a recent well-conducted randomized controlled study [73] did not find evidence that nasal application of calcitonin is more effective than placebo treatment. Some patients may improve their function as a result of postural education and instructions for a home exercise program. As extension worsens the symptoms by reducing the size of the spinal canal, it is obvious that extension exercises must be avoided. **Epidural injections** anecdotally have a temporary beneficial effect and may be considered as a treatment in elderly patients in whom surgery would be too risky or who refused surgery. However, the therapeutic value of epidural injections in all lumbar spinal disorders and particularly in spinal stenosis (see Chapter 10) remains controversial [26, 60, 84].

Well conducted studies comparing conservative with surgical treatment are few in number and difficult to compare because of the heterogeneity of the study population. However, studies comparing non-operative and surgical treatment demonstrated better overall results of surgery [4, 7, 8, 44]. Moreover, only one

single randomized study compared short- and long-term results of medical and surgical therapy. Amundsen et al. [4] concluded that an initial conservative approach is advisable for oligosymptomatic patients because those with an unsatisfactory result can be treated surgically later without impairment of the prognosis.

## Operative Treatment

### General Principles

Surgery for lumbar spinal stenosis is generally accepted when conservative treatment has failed or if the stenosis substantially impacts on the patients' lifestyle. The general goals of the operative treatment are to improve quality of life by reducing symptoms such as those in Table 4:

**Table 4.** Indications for surgery

- moderate to severe claudication symptoms
- progressive neurological deficits (rare)
- significant interference with lifestyle
- cauda equina syndrome (very rare)

With the exception of a cauda equina syndrome or progressive neurologic deficits, the indication for surgery remains relative and is dominated by the subjective interference with the patients' quality of life.

### Surgical Techniques

The surgical technique is largely dependent on the type of stenosis (i.e. central, lateral recess, or foraminal) and the presence of concomitant back pain. The **principal surgical options** for decompression of **central and/or lateral spinal stenosis** are:

- decompression (uni-/bilateral laminotomy or laminectomy)
- decompression with non-instrumented fusion
- decompression with instrumented fusion

#### Laminotomy and Laminectomy

Laminectomy may increase or create segmental instability

The objective of decompression is to create more space for the cauda equina and nerve roots by liberating the neural structures from compressing soft tissues (disc herniation, hypertrophied flavum, thickened facet joint capsules) and osseous structures (hypertrophied facet joints, osteophytes). Until the last decade, total laminectomy was the standard method of decompression in central spinal stenosis. However, the recognition that total laminectomy may increase or cause segmental instability [31, 35] has led to a more conservative approach, preserving the lamina and only removing those parts which actually cause the stenosis [91].

**Selective decompression** is the surgical technique of choice in patients presenting with neurogenic claudication without relevant back pain (Case Study 1). **Favorable indications** include:

- central stenosis predominantly due to flavum hypertrophy
- nerve root claudication due to lateral recess stenosis
- absence of degenerative spondylolisthesis and scoliosis
- absence of osseous foraminal stenosis

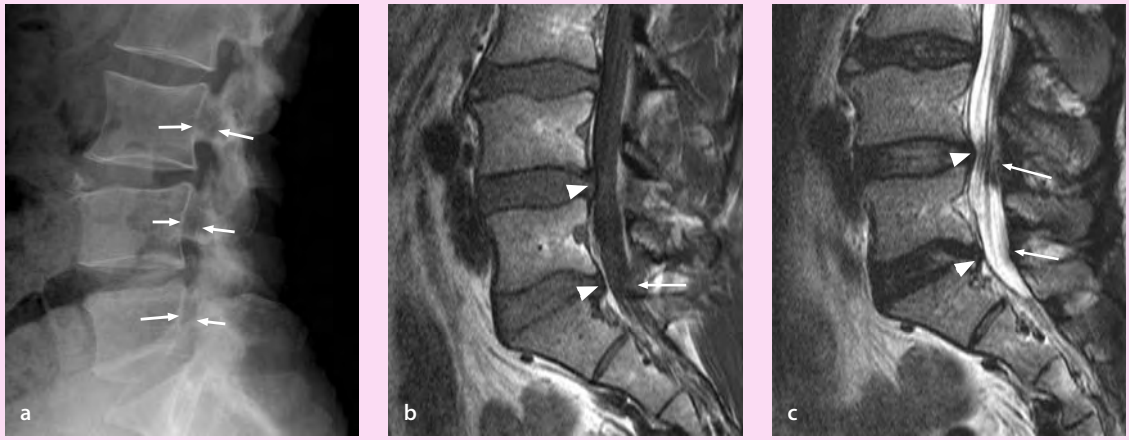


## Case Study 1

A 26-year-old male complained of severe bilateral leg pain which was worse on walking. He did not report any significant back pain. Physiotherapy was not helpful and the patient was severely incapacitated by the pain. NSAIDs had only little effect. A lateral radiograph (a) revealed evidence for a congenitally narrow spinal canal with short pedicles (*arrows*). T1W (b) and T2W (c) sagittal images demonstrated a narrow spinal canal with secondary degenerative changes. Disc protrusions (*arrowheads*) and hypertrophied flavum (*arrows*) at the level of L4/5 and L5/S1 worsened the preexisting narrow spinal canal. The axial T2W image (b) showed a severe stenosis at the level of L4/5. Note the rather advanced degenerative changes of the facet joint (*arrowheads*) already in young age. The patient was treated by a selective bilateral decompression with preservation of the interspinous ligaments and undercutting of the laminae. At 6 weeks postoperatively the patient was completely pain free and resumed normal activities.

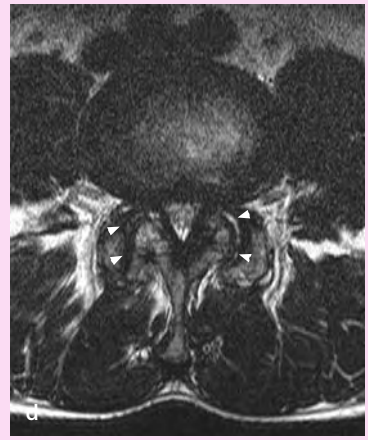


This procedure (Fig. 6) can be performed with the assistance of **loops** or the **microscope** although there is no evidence for the superiority of a microsurgical approach. A technical detail is related to the preservation of the facet joint capsules when an undercutting medial facetectomy is required to decompress the thecal sac.

Decompression alone is indicated in patients without deformity

In selected cases, a unilateral approach suffices to bilaterally decompress the thecal sac (**over-the-top technique**) by undercutting of the laminae, preserving the interspinous ligaments and the contralateral muscles [53].

**Total laminectomy** is still indicated in cases in which the thecal sac cannot be sufficiently decompressed or the access to the foramen is obliterated (foraminal stenosis). In rare cases of cauda equina syndrome, total laminectomy is indicated to ensure adequate neural decompression. Laminectomy alone should be avoided in cases with preexisting instability such as:

- degenerative spondylolisthesis
- isthmic spondylolisthesis with secondary degenerative changes
- degenerative scoliosis

Clinical results of decompressive laminectomy are favorable with appropriate indications accounting for preexisting instability. Patient satisfaction varies from 57 % to 81 % with regard to excellent to good results [1, 38, 39, 41, 45, 46, 48, 49, 78, 79, 83, 89]. While the postoperative outcome of decompressive laminectomy is well maintained for several years after surgery, the condition is known to dete-

Clinical outcomes of laminectomy and laminotomy are similar

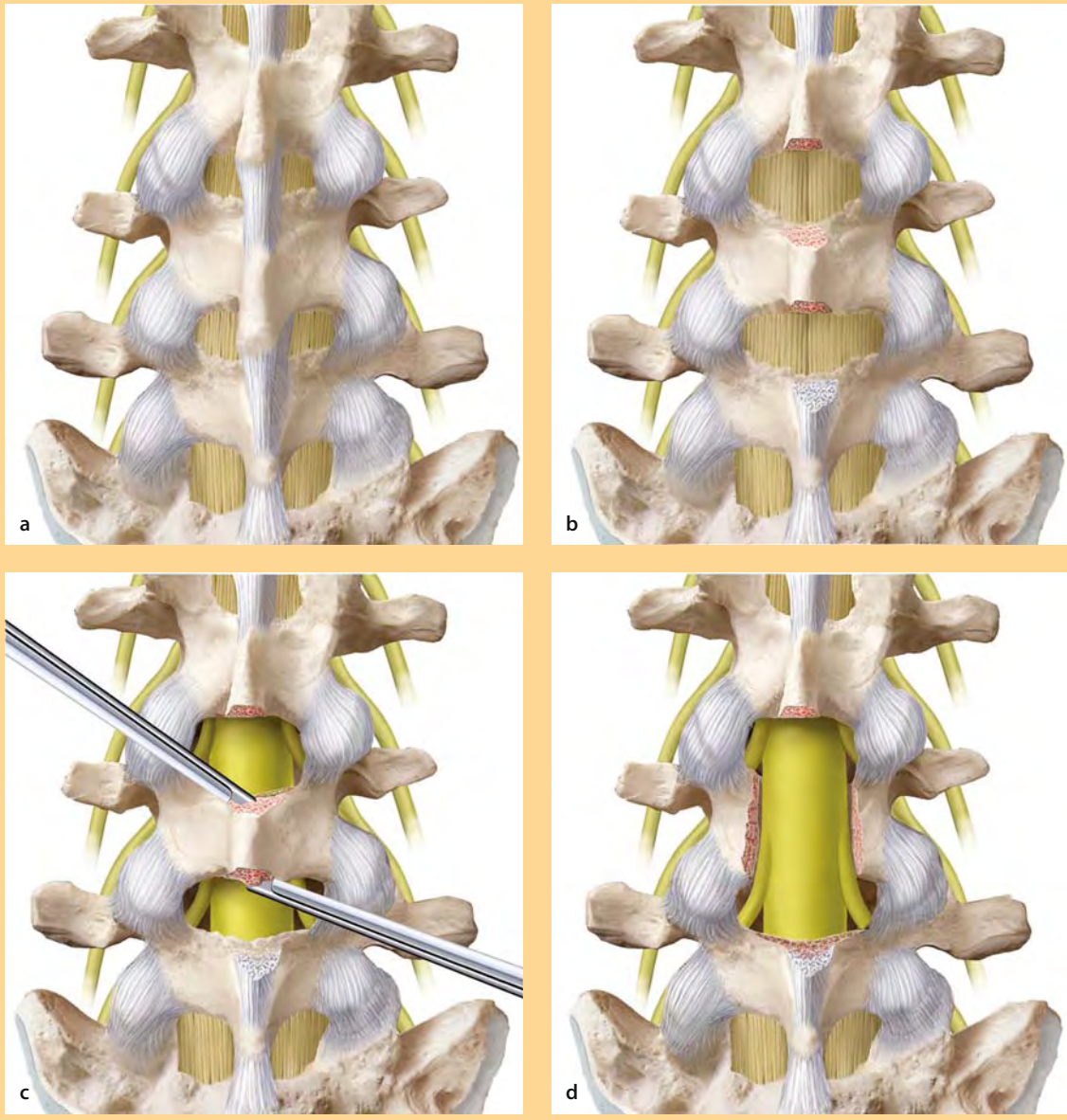


**Figure 6. Surgical decompression of a spinal stenosis**

**a** A midline approach exposes the interlaminar windows L3/4 and L4/5 as well as the facet joints to decompress a spinal stenosis at these levels. **b** The supra- and interspinous ligaments are resected under the preservation of the spinous process. The interlaminar window is opened with a Kerrison rongeur and the compressing bone and hypertrophied flavum are removed. **c** It is important to realize that the narrowest part of the stenosis is always under the lamina. Therefore, the lamina has to be resected (laminotomy) in the caudal third or half. The remaining part needs to be undercut from the superior and inferior sides, respectively. **d** In some cases, the undercutting of the lamina does not suffice for an adequate decompression and the lamina needs to be resected.

riorate in longer follow-up [45, 49, 89]. Clinical results of decompression on open (50–90%) [6, 80, 95] or microsurgical [53, 96] laminotomy are quite similar to those achieved by laminectomy. Although it is generally assumed that laminectomy may increase or cause vertebral instability [31, 35], no difference in clinical outcomes or spondylolisthesis progression between the two treatment methods was seen in two studies [95, 96], especially not when the motion segments were

fully stable preoperatively and were not made unstable by a total laminectomy [29, 80].

### Decompression and Spinal Fusion

The addition of fusion with or without instrumentation to surgical decompression is generally recommended when segmental instability is assumed. However, the radiologic assessment of segmental instability remains a matter of debate. **Decompression and fusion** are considered by many spine surgeons **in case of:**

- segmental instability (degenerative spondylolisthesis and scoliosis)
- concomitant moderate to severe back pain
- necessity for a wide decompression
- recurrent spinal stenosis

Instrumented fusion provides higher fusion rates and better long term outcome

The best fusion technique (Case Introduction, Case Study 2) is still controversial, and the evidence in the literature favoring one technique over the other is still sparse [27, 28, 63]. Most information relates to cases in which degenerative spondylolisthesis is associated with spinal stenosis. Herkowitz et al. [31] prospectively compared decompression alone versus decompression and non-instrumented fusion in 50 patients who had spinal stenosis and degenerative spondylolisthesis. The authors concluded that in the patients who had had a concomitant fusion, the results were significantly better with respect to relief of pain in the back and lower limbs. In a subsequent study, Fishgrund et al. [24] prospectively random-

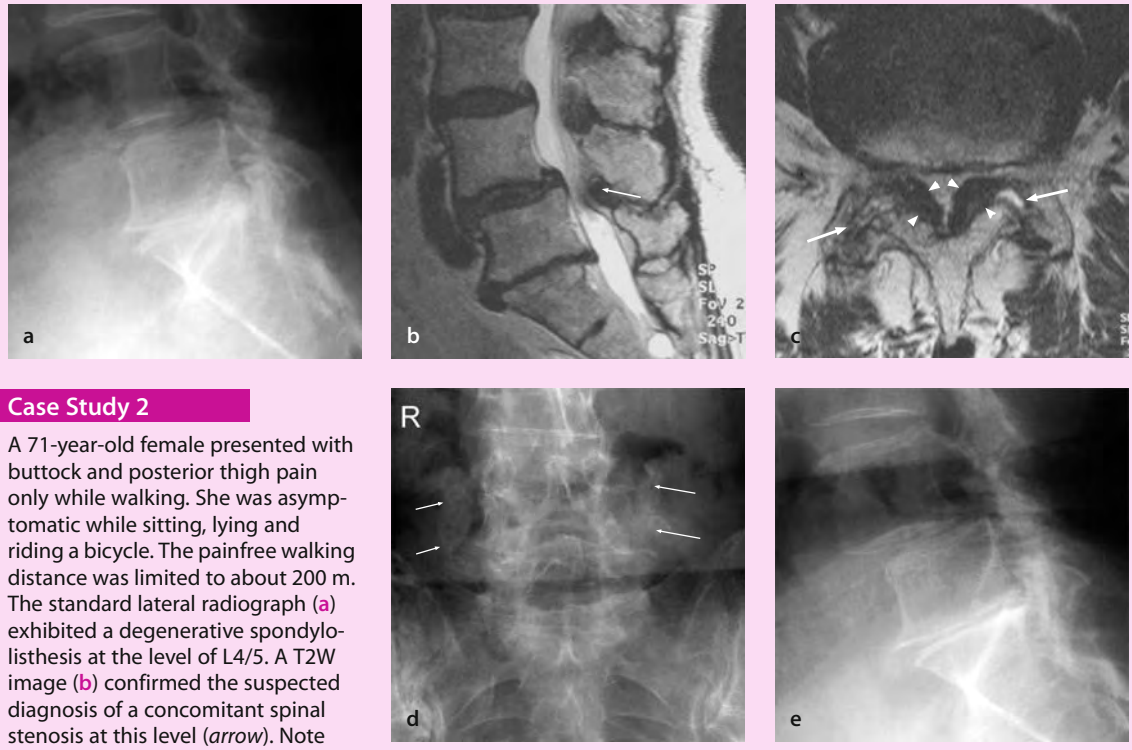


**Case Study 2**

A 71-year-old female presented with buttock and posterior thigh pain only while walking. She was asymptomatic while sitting, lying and riding a bicycle. The painfree walking distance was limited to about 200 m. The standard lateral radiograph (a) exhibited a degenerative spondylolisthesis at the level of L4/5. A T2W image (b) confirmed the suspected diagnosis of a concomitant spinal stenosis at this level (*arrow*). Note the hypertrophied flavum (*arrowheads) and degenerative changes of the facet joints (arrows*) (c). Since the patient did not report any back pain, a lamina preserving decompression was performed. The degenerative spondylolisthesis was addressed by a non-instrumented fusion to improve long term outcome. At 2 years postoperatively the fusion was solid (*arrows*) (d, e). The patient was pain free and able to perform all her desired activities.

ized 67 patients comparing instrumented (pedicle screw fixation) versus non-instrumented fusion. Clinical outcome was excellent or good in 76% of the instrumented and 85% of the non-instrumented cases. This difference was not statistically significant. However, successful fusion was significantly higher in the instrumented group (82 vs. 45%). The authors concluded that the use of pedicle screws may lead to a higher fusion rate, but clinical outcome shows no improvement in pain in the back and lower limbs. However, Kornblum et al. [57] demonstrated the long term (5–14 years) benefits of a successful fusion over non-union with respect to back and lower limb symptoms in patients with degenerative spondylolisthesis and spinal stenosis.

The need for an additional interbody fusion is not supported by the literature

There is no evidence in the literature that an additional **interbody fusion** by an anterior (ALIF) or posterior (PLIF, TLIF) approach improves outcome. Newer techniques such as interspinous spacer stabilization are still evolving and conclusions on clinical effectiveness are premature [105].

## Operative Risks and Complications

Reoperation rates for decompressive laminectomy vary from 7% to 23% [32, 35, 40, 49]. In a cohort study [64], the cumulative incidence of reoperation among patients who underwent surgery for spinal stenosis was slightly higher following initial fusion (19.9%) than decompression alone (16.8%). Reoperation among patients initially presenting with spondylolisthesis was lower with fusion (17.1%) than with decompression alone (28%). These findings are supported by controlled trials indicating better outcome for fusion than decompression alone when spondylolisthesis is present [24, 31]. Interestingly, this data suggests that over 60% of reoperations following fusion are associated with device complications or non-union, rather than new levels of disease or disease progression.

In a population based study of reoperation after back surgery [37], the subgroup spinal stenosis showed a complication rate for laminectomy alone and decompression with fusion of 4.6% and 7.7%, respectively. Reoperation after laminectomy was seen in 10% of the cases, which was equal to the 10.2% after decompression with fusion.

Patients with spinal stenosis often present with significant comorbidities which influence the surgical strategy

The **morbidity** associated with surgical treatment of lumbar stenosis in the elderly is an important aspect as those patients often present with a number of preexisting cardiovascular, pulmonary, or metabolic comorbidities [15, 18, 47, 49]. Advanced age does not increase the morbidity, nor does it decrease patient satisfaction or lengthen the return to activity [25, 81]. An increased complication rate has also been shown to be associated with spinal fusion performed for lumbar stenosis in elderly patients [15, 18, 94]. Therefore less invasive surgical approaches may be of particular interest. Mortality rate has been found to be approximately 0.6–0.8% [18, 92].

## Recapitulation

**Epidemiology.** Spinal stenosis can be found in up to 80% of individuals aged over 70 years. However, about 20% of asymptomatic individuals demonstrate signs of spinal stenosis on MRI indicating that there is no strong correlation with the imaging findings. The **rate of spinal surgery** for spinal stenosis is about 10 per 100000 individuals per year.

**Pathogenesis.** **The pathomechanism of central spinal stenosis** is predominantly related to a **hypertrophy of the yellow ligament** which is a result of a compensatory mechanism to restabilize a segmental hypermobility. Furthermore, bony canal compromise is caused by the occurrence of facet joint enlargement (osteoarthrosis), **osteophyte formation**, and **degenerative spondylolisthesis**. This finally results in a progressive compression of the cauda equina. A congenitally narrow spinal canal is a rare cause of spinal stenosis. Claudication symptoms can be explained by the neurogenic compression and/or the **vascular compression theory**. It is assumed that both mechanisms play a role. **Mechanical nerve root compression** results in decreased nutrition, microvascular changes, edema and fibrosis. The vascular compression theory suggests that spinal stenosis has pathologic effects on the blood supply of the cauda equina. It is assumed that **venous congestion** within the nerve root(s) between the levels of stenosis leads to a compromised nutrition and results in clinical symptoms.

**Clinical presentation.** The prevailing symptom of spinal stenosis is **neurogenic claudication**, which can be described as numbness, weakness and discomfort in the legs while walking or prolonged standing. In contrast to vascular claudication, symptoms improve by forward bending. Objective **neurological deficits are rarely present** during rest. These symptoms may or may not be associated with back pain but usually patients suffer much more from the claudication symptoms while they can live with the back pain. **Radicular claudication** is caused by a lateral recess or foraminal stenosis and results in nerve root pain while walking and prolonged standing.

**Diagnostic work-up.** The imaging modality of choice is MRI, which allows a precise depiction of the pathoanatomy in terms of the central and foraminal stenosis. Standing radiographs are useful to diagnose a concomitant **degenerative spondylolisthesis** or scoliosis. Radiographs may also indicate a congenitally narrow spinal canal. **Neurophysiologic studies** are indicated to confirm the significance of a mild to moderate spinal stenosis with equivocal symptoms. They are also helpful in confirming a radiculopathy in case of a lateral recess or foraminal stenosis. In elderly patients, **peripheral neuropathy** is frequent, which can be detected by electrophysiology. The most important differential diagnosis is peripheral vascular disease, which has to be ruled out by vascular status and in some cases angiography.

**Non-operative treatment.** Conservative measures cannot influence the natural history of spinal stenosis, which is a progressive degenerative disease leading to an increasing immobilization of the patient. However, non-operative treatment may be considered in cases with only mild to moderate stenosis and only minimal interference with lifestyle. Treatment options consist of medication (analgesics, NSAIDs, muscle relaxants), administration of calcitonin, postural education, physical therapy and epidural injections. There is only sparse scientific evidence in support of the clinical effectiveness of any such measures compared to the natural history.

**Operative treatment.** The treatment of choice is spinal decompression. In the early years, **laminectomy** was considered the standard surgical treatment and is still indicated in severe stenosis. However, reports on increasing segmental instability have resulted in a shift to a more conservative approach preserving the posterior elements as much as possible. Today, **laminotomy** is the **preferred treatment** in cases presenting without additional deformity or putative segmental instability. This approach can even be performed by **minimal access surgery** under microscopic guidance. When degenerative spondylolisthesis or scoliosis or significant concomitant back pain due to facet joint osteoarthritis is present, fusion is considered an important adjunct to decompression. **Instrumented fusion** results in a **higher fusion rate** and a **better long term outcome** than non-instrumented fusion. Many spine surgeons therefore favor instrumented fusion although the scientific evidence for this approach is still weak.

## Key Articles

**Verbiest H (1954) A radicular syndrome from developmental narrowing of the lumbar vertebral canal. J Bone Joint Surg Br 36-B:230–7**
Classic article on the clinical presentation of neurogenic claudication as a result of spinal stenosis.

**Amundsen T, Weber H, Nordal HJ, Magnaes B, Abdelnoor M, Lilleas F (2000) Lumbar spinal stenosis: conservative or surgical management? A prospective 10-year study. Spine 25(11):1424–35**
A cohort of 100 patients with symptomatic lumbar spinal stenosis were given surgical or conservative treatment and followed for 10 years. Nineteen patients with severe symptoms were selected for surgical treatment and 50 patients with moderate symptoms for conservative treatment, whereas 31 patients were randomized between the conservative ($n=18$) and surgical ($n=13$) treatment groups. After a period of 4 years, excellent or fair results were found in half of the patients selected for conservative treatment, and in four-fifths of the patients selected for surgery. Patients with an unsatisfactory result from conservative treatment were offered delayed surgery after 3–27 months. The treatment result of delayed surgery was essentially similar to that of the initial group. The treatment result for the patients randomized for surgical treatment was considerably better than for the patients randomized for conservative treatment. Clinically significant deterioration of symptoms during the final 6 years of the follow-up period was not observed. Patients with multilevel afflictions, surgically treated or not, did not have a poorer outcome than those with single-level afflictions. The authors concluded that the outcome was most favorable for surgical treatment. However, an initial conservative approach seems advisable for many patients because those with an unsatisfactory result can be treated surgically later with a good outcome.

**Grob D, Humke T, Dvorak J (1995) Degenerative lumbar spinal stenosis. Decompression with and without arthrodesis. J Bone Joint Surg Am 77:1036–41**
The authors prospectively evaluated the results of decompression of the spine, with and without spinal fusion, for the treatment of lumbar spinal stenosis without instability in 45 patients. The patients were randomly assigned to one of three treatment groups: Group I was treated with decompression with laminotomy and medial facetectomy; Group II, with decompression and arthrodesis of the most stenotic segment; and Group III, with decompression and spinal fusion of all decompressed vertebral segments. After 24–32 months, all three groups had a significant improvement in walking distance. With the numbers available, there were no significant differences in the results among the three groups with regard to the relief of pain. The authors concluded that spinal fusion is not necessary in patients presenting with spinal stenosis in the absence of segmental instability.

**Herkowitz HN, Kurz LT (1991) Degenerative lumbar spondylolisthesis with spinal stenosis. A prospective study comparing decompression with decompression and intertransverse process arthrodesis. J Bone Joint Surg Am 73:802–8**
In a prospective study, 50 patients who had spinal stenosis associated with degenerative lumbar spondylolisthesis were prospectively studied to determine if concomitant intertransverse-process arthrodesis provided better results than decompressive laminectomy alone. After 2–4 years, patients with concomitant fusion had the significantly better results with respect to relief of pain in the back and lower limbs.

**Fischgrund JS, Mackay M, Herkowitz HN, Brower R, Montgomery DM, Kurz LT (1997) Degenerative lumbar spondylolisthesis with spinal stenosis: a prospective, randomized study comparing decompressive laminectomy and arthrodesis with and without spinal instrumentation. Spine 22(24):2807–12**
In this prospective study patients with degenerative spondylolisthesis and spinal stenosis were randomized into groups with and without pedicle screw instrumentation as an adjunct to decompression and posterolateral fusion. After a 2-year follow-up, clinical outcome was excellent or good in 76% of the patients with instrumentation and in 85% without instrumentation. Successful fusion occurred in 82% of the instrumented cases versus 45% of the non-instrumented cases ($p<0.0015$). However, successful fusion did not influence patient outcome ($p=0.435$). The authors concluded that the use of pedicle screws may lead to a higher fusion rate, but clinical outcome shows no improvement regarding pain in the back and lower limbs.

## Key Articles

**Kornblum MB, Fischgrund JS, Herkowitz HN, Abraham DA, Berkower DL, Ditkoff JS (2004) Degenerative lumbar spondylolisthesis with spinal stenosis: a prospective long term study comparing fusion and pseudarthrosis. Spine 29:726–33**
A longer term follow-up (5–14 years) of the previous study indicated that clinical outcome was excellent to good in 86% of patients with a solid fusion and in 56% of patients with a non-union ($p<0.01$). The solid fusion group performed significantly better in the symptom severity and physical function categories on the self-administered questionnaire. The authors concluded that in patients undergoing single-level decompression and posterolateral arthrodesis for spinal stenosis and concurrent spondylolisthesis, a solid fusion improves long-term clinical outcome.

**Weinstein JN, Tosteson TD, Lurie JD, Tosteson AN, Blood E, Hanscom B, Herkowitz H, Cammisa F, Albert T, Boden SD, Hilibrand A, Goldberg H, Berven S, An H (2008) Surgical versus nonsurgical therapy for lumbar spinal stenosis. N Engl J Med 358:794–810**
In this very recent landmark study, study patients with a history of at least 12 weeks of symptoms and spinal stenosis without spondylolisthesis were enrolled in either a randomized cohort ($n=289$) or an observational cohort ($n=365$) at 13 U.S. spine clinics. Treatment consisted either of decompressive surgery or usual non-surgical care. At 2 years, 67% of patients who were randomly assigned to surgery had undergone surgery, whereas 43% of those who were randomly assigned to receive non-surgical care had also undergone surgery. Despite the high level of non-adherence, the intention-to-treat analysis of the randomized cohort showed a significant treatment effect favoring surgery on the SF-36 scale for bodily pain. However, there was no significant difference in scores on physical function or on the Oswestry Disability Index. The as-treated analysis, which combined both cohorts and was adjusted for potential confounders, showed a significant advantage for surgery by 3 and 24 months postoperatively for all primary outcomes. In the combined as-treated analysis, patients who underwent surgery showed significantly more improvement in all primary outcomes than did patients who were treated non-surgically.

## References


1. Airaksinen O, Herno A, Turunen V, Saari T, Suomlainen O (1997) Surgical outcome of 438 patients treated surgically for lumbar spinal stenosis. Spine 22:2278–82
2. Amonoo-Kuofi HS, Patel PJ, Fatani JA (1990) Transverse diameter of the lumbar spinal canal in normal adult Saudis. Acta Anat (Basel) 137:124–8
3. Amundsen T, Weber H, Lilleas F, Nordal HJ, Abdelnoor M, Magnaes B (1995) Lumbar spinal stenosis. Clinical and radiologic features. Spine 20:1178–86
4. Amundsen T, Weber H, Nordal HJ, Magnaes B, Abdelnoor M, Lilleas F (2000) Lumbar spinal stenosis: conservative or surgical management?: A prospective 10-year study. Spine 25:1424–35; discussion 1435–6
5. Arnoldi CC, Brodsky AE, Cauchoix J, Crock HV, Dommisse GF, Edgar MA, Gargano FP, Jacobson RE, Kirkaldy-Willis WH, Kurihara A, Langenskiold A, Macnab I, McIvor GW, Newman PH, Paine KW, Russin LA, Sheldon J, Tile M, Urist MR, Wilson WE, Wiltse LL (1976) Lumbar spinal stenosis and nerve root entrapment syndromes. Definition and classification. Clin Orthop Relat Res:4–5
6. Aryanpur J, Ducker T (1990) Multilevel lumbar laminotomies: an alternative to laminectomy in the treatment of lumbar stenosis. Neurosurgery 26:429–32; discussion 433
7. Atlas SJ, Deyo RA, Keller RB, Chapin AM, Patrick DL, Long JM, Singer DE (1996) The Maine Lumbar Spine Study, Part III. 1-year outcomes of surgical and nonsurgical management of lumbar spinal stenosis. Spine 21:1787–94; discussion 1794–5
8. Atlas SJ, Keller RB, Robson D, Deyo RA, Singer DE (2000) Surgical and nonsurgical management of lumbar spinal stenosis: four-year outcomes from the Maine Lumbar Spine Study. Spine 25:556–62
9. Baker AR, Collins TA, Porter RW, Kidd C (1995) Laser Doppler study of porcine cauda equina blood flow. The effect of electrical stimulation of the rootlets during single and double site, low pressure compression of the cauda equina. Spine 20:660–4
10. Bennett GJ, Xie YK (1988) A peripheral mononeuropathy in rat that produces disorders of pain sensation like those seen in man. Pain 33:87–107
11. Berney J (1994) [Epidemiology of narrow spinal canal]. Neurochirurgie 40:174–8
12. Boden SD (1996) The use of radiographic imaging studies in the evaluation of patients who have degenerative disorders of the lumbar spine. J Bone Joint Surg Am 78:114–24

13. Boden SD, Davis DO, Dina TS, Patronas NJ, Wiesel SW (1990) Abnormal magnetic-resonance scans of the lumbar spine in asymptomatic subjects. A prospective investigation. J Bone Joint Surg Am 72:403 – 8
14. Bolender NF, Schonstrom NS, Spengler DM (1985) Role of computed tomography and myelography in the diagnosis of central spinal stenosis. J Bone Joint Surg Am 67:240 – 6
15. Ciol MA, Deyo RA, Howell E, Kreif S (1996) An assessment of surgery for spinal stenosis: time trends, geographic variations, complications, and reoperations. J Am Geriatr Soc 44:285 – 90
16. De Villiers PD, Booysen EL (1976) Fibrous spinal stenosis. A report on 850 myelograms with a water-soluble contrast medium. Clin Orthop Relat Res:140 – 4
17. Delamarter RB, Bohlman HH, Dodge LD, Biro C (1990) Experimental lumbar spinal stenosis. Analysis of the cortical evoked potentials, microvasculature, and histopathology. J Bone Joint Surg Am 72:110 – 20
18. Deyo RA, Cherkin DC, Loeser JD, Bigos SJ, Ciol MA (1992) Morbidity and mortality in association with operations on the lumbar spine. The influence of age, diagnosis, and procedure. J Bone Joint Surg Am 74:536 – 43
19. Dyck P, Doyle JB, Jr. (1977) "Bicycle test" of van Gelderen in diagnosis of intermittent cauda equina compression syndrome. Case report. J Neurosurg 46:667 – 70
20. Egli D, Hausmann O, Ramseier L, Schmid MR, Boos N, Curt A (2007) Confirmation of cauda equina affection in severe lumbar spinal canal stenosis by electrophysiological recordings. J Neurology (in press)
21. Epstein BS, Epstein JA, Jones MD (1978) Anatomicroradiological correlations in cervical spine discal disease and stenosis. Clin Neurosurg 25:148 – 73
22. Eskola A, Pohjolainen T, Alaranta H, Soini J, Tallroth K, Slatis P (1992) Calcitonin treatment in lumbar spinal stenosis: a randomized, placebo-controlled, double-blind, cross-over study with one-year follow-up. Calcif Tissue Int 50:400 – 3
23. Fanuele JC, Birkmeyer NJ, Abdu WA, Tosteson TD, Weinstein JN (2000) The impact of spinal problems on the health status of patients: have we underestimated the effect? Spine 25:1509 – 14
24. Fischgrund JS, Mackay M, Herkowitz HN, Brower R, Montgomery DM, Kurz LT (1997) 1997 Volvo Award winner in clinical studies. Degenerative lumbar spondylolisthesis with spinal stenosis: a prospective, randomized study comparing decompressive laminectomy and arthrodesis with and without spinal instrumentation. Spine 22:2807 – 12
25. Fredman B, Arinzon Z, Zohar E, Shabat S, Jedeikin R, Fidelman ZG, Gepstein R (2002) Observations on the safety and efficacy of surgical decompression for lumbar spinal stenosis in geriatric patients. Eur Spine J 11:571 – 4
26. Fukusaki M, Kobayashi I, Hara T, Sumikawa K (1998) Symptoms of spinal stenosis do not improve after epidural steroid injection. Clin J Pain 14:148 – 51
27. Gibson JN, Grant IC, Waddell G (1999) The Cochrane review of surgery for lumbar disc prolapse and degenerative lumbar spondylosis. Spine 24:1820 – 32
28. Gibson JN, Waddell G (2005) Surgery for degenerative lumbar spondylosis: updated Cochrane Review. Spine 30:2312 – 20
29. Grob D, Humke T, Dvorak J (1995) Degenerative lumbar spinal stenosis. Decompression with and without arthrodesis. J Bone Joint Surg Am 77:1036 – 41
30. Hart LG, Deyo RA, Cherkin DC (1995) Physician office visits for low back pain. Frequency, clinical evaluation, and treatment patterns from a U.S. national survey. Spine 20:11 – 9
31. Herkowitz HN, Kurz LT (1991) Degenerative lumbar spondylolisthesis with spinal stenosis. A prospective study comparing decompression with decompression and intertransverse process arthrodesis. J Bone Joint Surg Am 73:802 – 8
32. Herno A, Airaksinen O, Saari T (1993) Long-term results of surgical treatment of lumbar spinal stenosis. Spine 18:1471 – 4
33. Herno A, Airaksinen O, Saari T (1994) Computed tomography after laminectomy for lumbar spinal stenosis. Patients' pain patterns, walking capacity, and subjective disability had no correlation with computed tomography findings. Spine 19:1975 – 8
34. Herno A, Saari T, Suomalainen O, Airaksinen O (1999) The degree of decompressive relief and its relation to clinical outcome in patients undergoing surgery for lumbar spinal stenosis. Spine 24:1010 – 4
35. Hopp E, Tsou PM (1988) Postdecompression lumbar instability. Clin Orthop Relat Res 227:143 – 51
36. Howe JF, Loeser JD, Calvin WH (1977) Mechanosensitivity of dorsal root ganglia and chronically injured axons: a physiological basis for the radicular pain of nerve root compression. Pain 3:25 – 41
37. Hu RW, Jaglal S, Axcell T, Anderson G (1997) A population-based study of reoperations after back surgery. Spine 22:2265 – 70; discussion 2271
38. Iguchi T, Kurihara A, Nakayama J, Sato K, Kurosaka M, Yamasaki K (2000) Minimum 10-year outcome of decompressive laminectomy for degenerative lumbar spinal stenosis. Spine 25:1754 – 9

39. Iguchi T, Wakami T, Kurihara A, Kasahara K, Yoshiya S, Nishida K (2002) Lumbar multilevel degenerative spondylolisthesis: radiological evaluation and factors related to anterolisthesis and retrolisthesis. J Spinal Disord Tech 15:93 – 9
40. Jansson KA, Blomqvist P, Granath F, Nemeth G (2003) Spinal stenosis surgery in Sweden 1987 – 1999. Eur Spine J 12:535 – 41
41. Javid MJ, Hadar EJ (1998) Long-term follow-up review of patients who underwent laminectomy for lumbar stenosis: a prospective study. J Neurosurg 89:1 – 7
42. Johnsson KE (1995) Lumbar spinal stenosis. A retrospective study of 163 cases in southern Sweden. Acta Orthop Scand 66:403 – 5
43. Johnsson KE, Rosen I, Uden A (1992) The natural course of lumbar spinal stenosis. Clin Orthop Relat Res:82 – 6
44. Johnsson KE, Uden A, Rosen I (1991) The effect of decompression on the natural course of spinal stenosis. A comparison of surgically treated and untreated patients. Spine 16: 615 – 9
45. Jonsson B, Annertz M, Sjoberg C, Stromqvist B (1997) A prospective and consecutive study of surgically treated lumbar spinal stenosis. Part II: Five-year follow-up by an independent observer. Spine 22:2938 – 44
46. Katz JN, Dalgas M, Stucki G, Katz NP, Bayley J, Fossel AH, Chang LC, Lipson SJ (1995) Degenerative lumbar spinal stenosis. Diagnostic value of the history and physical examination. Arthritis Rheum 38:1236 – 41
47. Katz JN, Lipson SJ, Brick GW, Grobler LJ, Weinstein JN, Fossel AH, Lew RA, Liang MH (1995) Clinical correlates of patient satisfaction after laminectomy for degenerative lumbar spinal stenosis. Spine 20:1155 – 60
48. Katz JN, Lipson SJ, Chang LC, Levine SA, Fossel AH, Liang MH (1996) Seven- to 10-year outcome of decompressive surgery for degenerative lumbar spinal stenosis. Spine 21:92 – 8
49. Katz JN, Lipson SJ, Larson MG, McInnes JM, Fossel AH, Liang MH (1991) The outcome of decompressive laminectomy for degenerative lumbar stenosis. J Bone Joint Surg Am 73: 809 – 16
50. Katz JN, Wright EA, Guadagnoli E, Liang MH, Karlson EW, Cleary PD (1994) Differences between men and women undergoing major orthopedic surgery for degenerative arthritis. Arthritis Rheum 37:687 – 94
51. Kelly DT (1997) 1996 Paul Dudley White International Lecture: Our Future Society: A Global Challenge. Circulation 95:2459 – 2464
52. Kent DL, Haynor DR, Larson EB, Deyo RA (1992) Diagnosis of lumbar spinal stenosis in adults: a metaanalysis of the accuracy of CT, MR, and myelography. AJR Am J Roentgenol 158:1135 – 44
53. Khoo LT, Fessler RG (2002) Microendoscopic decompressive laminotomy for the treatment of lumbar stenosis. Neurosurgery 51:S146 – 54
54. Kirkaldy-Willis WH, Paine KW, Cauchoix J, McIvor G (1974) Lumbar spinal stenosis. Clin Orthop 99:30 – 50
55. Kirkaldy-Willis WH, Wedge JH, Yong-Hing K, Reilly J (1978) Pathology and pathogenesis of lumbar spondylosis and stenosis. Spine 3:319 – 28
56. Kirkaldy-Willis WH, Wedge JH, Yong-Hing K, Tchang S, de Korompay V, Shannon R (1982) Lumbar spinal nerve lateral entrapment. Clin Orthop Relat Res:171 – 8
57. Kornblum MB, Fischgrund JS, Herkowitz HN, Abraham DA, Berkower DL, Ditkoff JS (2004) Degenerative lumbar spondylolisthesis with spinal stenosis: a prospective long-term study comparing fusion and pseudarthrosis. Spine 29:726 – 33; discussion 733 – 4
58. Larsen JL, Smith D (1980) Size of the subarachnoid space in stenosis of the lumbar canal. Acta Radiol Diagn (Stockh) 21:627 – 32
59. Lee HM, Kim NH, Kim HJ, Chung IH (1995) Morphometric study of the lumbar spinal canal in the Korean population. Spine 20:1679 – 84
60. Leonardi M, Pfirrmann CW, Boos N (2006) Injection studies in spinal disorders. Clin Orthop Relat Res 443:168 – 82
61. Long DM, BenDebba M, Torgerson WS, Boyd RJ, Dawson EG, Hardy RW, Robertson JT, Sypert GW, Watts C (1996) Persistent back pain and sciatica in the United States: patient characteristics. J Spinal Disord 9:40 – 58
62. Lundborg G (1975) Structure and function of the intraneural microvessels as related to trauma, edema formation, and nerve function. J Bone Joint Surg Am 57:938 – 48
63. Mardjetko SM, Connolly PJ, Shott S (1994) Degenerative lumbar spondylolisthesis. A meta-analysis of literature 1970 – 1993. Spine 19:2256S–2265S
64. Martin BI, Mirza SK, Comstock BA, Gray DT, Kreuter W, Deyo RA (2007) Reoperation rates following lumbar spine surgery and the influence of spinal fusion procedures. Spine 32:382 – 7
65. Miller JA, Schmatz C, Schultz AB (1988) Lumbar disc degeneration: correlation with age, sex, and spine level in 600 autopsy specimens. Spine 13:173 – 8
66. Niggemeyer O, Strauss JM, Schulitz KP (1997) Comparison of surgical procedures for degenerative lumbar spinal stenosis: a meta-analysis of the literature from 1975 to 1995. Eur Spine J 6:423 – 9

67. Olmarker K, Rydevik B (1992) Single- versus double-level nerve root compression. An experimental study on the porcine cauda equina with analyses of nerve impulse conduction properties. Clin Orthop Relat Res:35 – 9
68. Olmarker K, Rydevik B, Hansson T, Holm S (1990) Compression-induced changes of the nutritional supply to the porcine cauda equina. J Spinal Disord 3:25 – 9
69. Olmarker K, Rydevik B, Holm S (1989) Edema formation in spinal nerve roots induced by experimental, graded compression. An experimental study on the pig cauda equina with special reference to differences in effects between rapid and slow onset of compression. Spine 14:569 – 73
70. Ooi Y, Mita F, Satoh Y (1990) Myeloscopic study on lumbar spinal canal stenosis with special reference to intermittent claudication. Spine 15:544 – 9
71. Panjabi MM, Goel V, Oxland T, Takata K, Duranceau J, Krag M, Price M (1992) Human lumbar vertebrae. Quantitative three-dimensional anatomy. Spine 17:299 – 306
72. Piera V, Rodriguez A, Cobos A, Hernandez R, Cobos P (1988) Morphology of the lumbar vertebral canal. Acta Anat (Basel) 131:35 – 40
73. Podichetty VK, Segal AM, Lieber M, Mazanec DJ (2004) Effectiveness of salmon calcitonin nasal spray in the treatment of lumbar canal stenosis: a double-blind, randomized, placebo-controlled, parallel group trial. Spine 29:2343 – 9
74. Portal A (1802) Cours d'anatomie medicale ou elements de l'anatomie de l'homme, vol 1. Badoin, Paris, pp 299
75. Porter RW, Hibbert C (1983) Calcitonin treatment for neurogenic claudication. Spine 8:585 – 92
76. Porter RW, Ward D (1992) Cauda equina dysfunction. The significance of two-level pathology. Spine 17:9 – 15
77. Postacchini F (1996) Management of lumbar spinal stenosis. J Bone Joint Surg Br 78: 154 – 64
78. Postacchini F (1999) Surgical management of lumbar spinal stenosis. Spine 24:1043 – 7
79. Postacchini F, Cinotti G, Gumina S, Perugia D (1993) Long-term results of surgery in lumbar stenosis. 8-year review of 64 patients. Acta Orthop Scand Suppl 251:78 – 80
80. Postacchini F, Cinotti G, Perugia D, Gumina S (1993) The surgical treatment of central lumbar stenosis. Multiple laminotomy compared with total laminectomy. J Bone Joint Surg Br 75:386 – 92
81. Ragab AA, Fye MA, Bohlman HH (2003) Surgery of the lumbar spine for spinal stenosis in 118 patients 70 years of age or older. Spine 28:348 – 53
82. Rauschning W (1987) Normal and pathologic anatomy of the lumbar root canals. Spine 12:1008 – 19
83. Richter M, Kluger P, Puhl W (1999) [Diagnosis and therapy of spinal stenosis in the elderly]. Z Orthop Ihre Grenzgeb 137:474 – 81
84. Rivest C, Katz JN, Ferrante FM, Jamison RN (1998) Effects of epidural steroid injection on pain due to lumbar spinal stenosis or herniated disks: a prospective study. Arthritis Care Res 11:291 – 7
85. Rydevik B, Holm S, Brown MD, Lundborg G (1990) Diffusion from the cerebrospinal fluid as a nutritional pathway for spinal nerve roots. Acta Physiol Scand 138:247 – 8
86. Rydevik B, Lundborg G, Skalak R (1989) Biomechanics of peripheral nerves. In: Nordin M, Frankel VH (eds) Basic biomechanics of the musculoskeletal system. Lea & Febiger, Philadelphia, pp 75 – 87
87. Sasaki K (1995) Magnetic resonance imaging findings of the lumbar root pathway in patients over 50 years old. Eur Spine J 4:71 – 6
88. Schmid MR, Stucki G, Duewell S, Wildermuth S, Romanowski B, Hodler J (1999) Changes in cross-sectional measurements of the spinal canal and intervertebral foramina as a function of body position: in vivo studies on an open-configuration MR system. AJR Am J Roentgenol 172:1095 – 102
89. Scholz M, Firsching R, Lanksch WR (1998) Long-term follow up in lumbar spinal stenosis. Spinal Cord 36:200 – 4
90. Schonstrom NS, Bolender NF, Spengler DM (1985) The pathomorphology of spinal stenosis as seen on CT scans of the lumbar spine. Spine 10:806 – 11
91. Senegas J, Etchevers JP, Vital JM, Baulny D, Grenier F (1988) Recalibration of the lumbar canal, an alternative to laminectomy in the treatment of lumbar canal stenosis. Rev Chir Orthop Reparatrice Appar Mot 74:15 – 22
92. Silvers HR, Lewis PJ, Asch HL (1993) Decompressive lumbar laminectomy for spinal stenosis. J Neurosurg 78:695 – 701
93. Spratt KF, Keller TS, Szpalski M, Vandeputte K, Gunzburg R (2004) A predictive model for outcome after conservative decompression surgery for lumbar spinal stenosis. Eur Spine J 13:14 – 21
94. Stromqvist B, Jonsson B, Fritzell P, Hagg O, Larsson BE, Lind B (2001) The Swedish National Register for lumbar spine surgery: Swedish Society for Spinal Surgery. Acta Orthop Scand 72:99 – 106
95. Thomas NW, Rea GL, Pikul BK, Mervis LJ, Irsik R, McGregor JM (1997) Quantitative out-

come and radiographic comparisons between laminectomy and laminotomy in the treatment of acquired lumbar stenosis. Neurosurgery 41:567 – 74; discussion 574 – 5
96. Tsai RY, Yang RS, Bray RS, Jr. (1998) Microscopic laminotomies for degenerative lumbar spinal stenosis. J Spinal Disord 11:389 – 94
97. Verbiest H (1954) A radicular syndrome from developmental narrowing of the lumbar vertebral canal. J Bone Joint Surg Br 36-B:230 – 7
98. Verbiest H (1979) The significance and principles of computerized axial tomography in idiopathic developmental stenosis of the bony lumbar vertebral canal. Spine 4:369 – 78
99. Videman T, Nurminen M, Troup JD (1990) 1990 Volvo Award in clinical sciences. Lumbar spinal pathology in cadaveric material in relation to history of back pain, occupation, and physical loading. Spine 15:728 – 40
100. Wang TM, Shih C (1992) Morphometric variations of the lumbar vertebrae between Chinese and Indian adults. Acta Anat (Basel) 144:23 – 9
101. Weishaupt D, Schmid MR, Zanetti M, Boos N, Romanowski B, Kissling RO, Dvorak J, Hodler J (2000) Positional MR imaging of the lumbar spine: does it demonstrate nerve root compromise not visible at conventional MR imaging? Radiology 215:247 – 53
102. Wildermuth S, Zanetti M, Duewell S, Schmid MR, Romanowski B, Benini A, Boni T, Hodler J (1998) Lumbar spine: quantitative and qualitative assessment of positional (upright flexion and extension) MR imaging and myelography. Radiology 207:391 – 8
103. Yoshida M, Shima K, Taniguchi Y, Tamaki T, Tanaka T (1992) Hypertrophied ligamentum flavum in lumbar spinal canal stenosis. Pathogenesis and morphologic and immunohistochemical observation. Spine 17:1353 – 60
104. Yoshizawa H, Kobayashi S, Morita T (1995) Chronic nerve root compression. Pathophysiologic mechanism of nerve root dysfunction. Spine 20:397 – 407
105. Zucherman JF, Hsu KY, Hartjen CA, Mehalic TF, Implicito DA, Martin MJ, Johnson DR, 2nd, Skidmore GA, Vessa PP, Dwyer JW, Puccio S, Cauthen JC, Ozuna RM (2004) A prospective randomized multi-center study for the treatment of lumbar spinal stenosis with the X STOP interspinous implant: 1-year results. Eur Spine J 13:22 – 31

# 20 Degenerative Lumbar Spondylosis

Martin Merkle, Beat Wälchli, Norbert Boos

## Core Messages

- ✔ Morphological abnormalities in the lumbar spine are frequent in asymptomatic individuals, but severe endplate (Modic) changes and severe facet joint osteoarthritis are rare in healthy individuals less than 50 years of age
- ✔ Specific back pain related to degenerative lumbar spondylosis (disc degeneration, facet joint osteoarthritis) is rare (10–15 %)
- ✔ Proinflammatory cytokines seem to play an important role in the generation of discogenic back pain and pain in facet joint osteoarthritis
- ✔ Segmental instability is defined clinically and lacks objective criteria
- ✔ Clinical findings in patients with painful lumbar spondylosis are rare
- ✔ Facet joint blocks and provocative discography in diagnosing specific back pain must be interpreted with care
- ✔ Cognitive behavioral treatment is key for a successful conservative treatment approach
- ✔ Spinal instrumentation with pedicle screw fixation enhances fusion rate but not clinical outcome to an equal extent
- ✔ Combined interbody and posterolateral fusion provides the highest fusion rate
- ✔ Non-union and adjacent level degeneration are frequent problems related to spinal fusion
- ✔ Minimally invasive techniques have so far not been shown to provide better clinical outcome than conventional techniques
- ✔ Total disc arthroplasty is not superior to spinal fusion
- ✔ There is limited scientific evidence to favor spinal fusion over an intensive rehab program including cognitive behavioral treatment

## Epidemiology

Degenerative lumbar spondylosis is a mixed group of lumbar disorders

**Degenerative lumbar spondylosis** refers to a mixed group of pathologies related to the degeneration of the lumbar motion segment and associated pathologies or clinical syndromes of discogenic back pain, facet joint osteoarthritis, and segmental instability [102]. Lumbar spondylosis and degenerative disc disease can be regarded as one entity whether or not they result from aging, are secondary to trauma or "wear and tear", or degenerative disease, and whether or not they involve the intervertebral discs, vertebrae, and/or associated joints [103]. This group of disorders also includes spinal stenosis with or without degenerative spondylolisthesis, degenerative scoliosis and isthmic spondylolisthesis with secondary degenerative changes. The latter pathologies are separately covered in Chapters 19, 26 and 27, respectively.

Specific back pain is relatively rare (10–15 %)

The prevailing symptom of lumbar spondylosis is back pain. However, it is often difficult to reliably relate back pain to specific alterations of the motion segment. In the vast majority of cases (85–90 %), no pathomorphological correlate can be found for the patient's symptoms and the pain remains **non-specific** [66]. We have dedicated a separate chapter to this entity (see Chapter 21). In this chapter, we focus on degenerative alterations **without neural compromise** as spe-

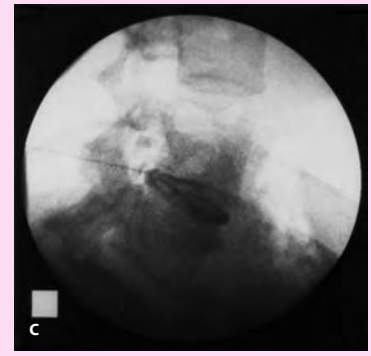


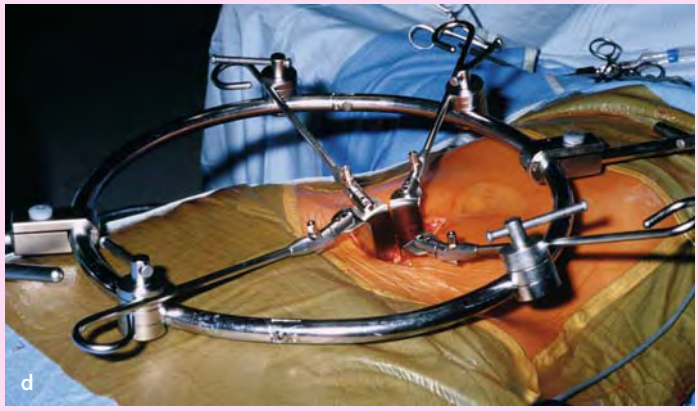

## Case Introduction

A 37-year-old female presented with severe incapacitating back pain when sitting and during the night. The pain was so severe that the patient had to stop her work as a secretary. Pain could be provoked by a sit-up test. The pain was radiating to the anterior thigh but the patient did not have any neurological deficits. Sagittal MRI scans showed disc degeneration at the level of L4/5 with severe Modic Type I changes: decreased signal in the T1W (a) and increased signal in T2W (b) images. The remaining discs were unremarkable. Provocative discography (c) at the target level produced the typical pain worse than ever. Injection at the adjacent MR normal levels only produced a slight pressure. The intervertebral disc was assumed to be the source of the back pain. The patient underwent posterior translaminar screw fixation and posterolateral fusion with autologous bone harvested from the iliac crest. Subsequently, the patient underwent a minimally invasive retroperitoneal approach. A retractor frame facilitates the exposure (d). After disc excision, a femur ring allograft filled with autologous spongiosa (e) was used to replace the disc. The graft was secured with an anti-glide screw with washer (f, g). The patient reported immediate pain relief after surgery, which was still present at 5 year follow-up. The patient returned to work 2 months after surgery and was able to enjoy unlimited physical and leisure activities.

cific sources of back pain (i.e. symptomatic disc degeneration, symptomatic facet joint osteoarthritis and segmental instability).

Morphological abnormalities are frequent in asymptomatic individuals

Cadaveric studies [119, 192, 193, 266] indicated a strong correlation of degenerative changes to age, but correlation to symptoms was problematic for obvious reasons. By the age of 47 years, 97 % of all discs studied already exhibited degenerative changes [193]. For many years, epidemiologic studies on lower back pain (LBP) were hampered by the inability to non-invasively assess the relation of morphological alterations and clinical symptoms. Studies were sparse until the advent of magnetic resonance imaging (MRI). In 1953, Splithoff et al. [243] compared the radiographs of 100 patients with and without back pain. A similar incidence of transitional vertebrae, spondylolisthesis, and retrolisthesis was reported for both groups. There was a slight tendency for a higher incidence of osteoarthritis in the symptomatic group. Comparing 200 individuals with and without low-back pain, Fullenlove and Williams [95] reported that transitional anomalies were equally frequent in symptomatic and asymptomatic individuals. However, disc height loss with spurs showed a much higher incidence in symptomatic patients (25 % vs. 9 %), while no significant difference in the incidence of other degenerative lesions was found. Magora and Schwartz [181] explored the prevalence of degenerative osteoarthritic changes in the lumbar spine of 372 individuals with low-back pain and in 217 matched asymptomatic controls. They found an even higher prevalence of degenerative findings in the asymptomatic (66.4 %) than in the symptomatic group (58.3 %).

Asymptomatic morphological abnormalities frequently occur in MRI

These early findings are corroborated by later MRI studies. The high prevalence of degenerative alterations in asymptomatic individuals demonstrated by MRI underlined the missing link of degenerative alterations of the motion segment and low-back pain [14, 23, 140, 218, 274]. In patients younger than 50 years, however, disc extrusion (18 %) and sequestration (0 %), endplate abnormalities (Modic changes, 3 %), and osteoarthritis of the facet joints (0 %) are rare [274], indicating that these findings may be associated with low-back pain in symptomatic patients [274]. Despite the weak correlation of imaging findings and pain, there is no doubt that degenerative alterations of the motion segment can be a pain source in some patients. Research has recently focused on the **molecular mechanisms**, which may explain why particular degenerative changes are symptomatic in some patients but not in healthy controls despite the identical morphological appearance of the alteration. However, screening tools will not become available in the foreseeable future, which may allow for epidemiologic studies exploring the true incidence of symptomatic alterations of the motion segment.

The natural history of LBP is benign

The **natural history of LBP** related to degenerative lumbar spondylosis is benign and self-limiting. In an RCT, Indahl et al. [133] have even shown that low-back pain has a good prognosis when left untampered.

## Pathogenesis

A prerequisite for normal spinal function is the coordinated interplay of the spinal components, i.e.:

- intervertebral disc
- facet joints and capsules
- spinal ligaments
- spinal muscles (extrinsic, intrinsic)

The three-joint complex is key to understanding the degenerative alterations

Schmorl and Junghanns [236] coined the term **functional spinal unit** (FSU) to describe the smallest anatomical unit, which exhibits the basic functional characteristics of the entire spine. On a macroscopic basis, Kirkaldy-Willis [155, 156]

described the sequences of age-related changes leading to multisegmental spondylosis based on the concept of the "**three-joint complex**" (Chapter 19, Table 1). Basically, this concept implies that disc degeneration will finally lead to facet joint osteoarthritis and vice versa. Both alterations can cause segmental instability but hypermobility may also result in disc degeneration and facet joint osteoarthritis. There is ongoing debate about the **temporal sequences** of these relationships. While there is increasing evidence that the age-related changes start in the intervertebral disc in the vast majority of cases [25, 35, 94, 110, 206], there are patients who predominantly exhibit facet joint osteoarthritis without significant disc degeneration. Anecdotal observations also highlight the existence of a painful segmental "**hypermobility**" without evidence of advanced disc or facet joint degenerations. A detailed overview of the biomechanics of the motion segment and age-related changes is provided in Chapters 2 and 4, respectively.

Disc degeneration will finally lead to facet joint osteoarthritis and vice versa

All structures in the lumbar motion segment, i.e. vertebrae, intervertebral discs, facet joints, muscles, ligaments and muscles, can be **sources of pain** [41]. While there is good scientific evidence that disc-related nerve root compression and spinal stenosis is correlated with pain, the evidence for spondylosis is limited [203]. The evidence for muscle related back pain, myofacial pain and sacroiliac joint syndromes is poor. From a clinical perspective, three additional pathomorphological alterations can be identified which show some correlation to clinical symptoms although the scientific evidence for this relationship is still weak and very controversial [41] (Table 1).

All spinal structures can be a source of pain

**Table 1.** Putative sources of specific back pain

| Pathomorphological correlate | Syndrome |
|---|---|
| • disc degeneration | • discogenic back pain |
| • facet joint osteoarthritis | • facet syndrome |
| • segmental instability | • instability syndrome |

## Disc Degeneration and Discogenic Back Pain

The presence of so-called "discogenic back pain" is critically related to the innervation of the intervertebral disc. While the normal adult intervertebral disc is only innervated at the outer layers of the anulus fibrosus [18, 19, 114, 182], the innervation in the degenerative intervertebral disc is less clear. Some researchers provided data suggesting that there is a neo-innervation and/or nerve ingrowth into deeper layers of the anulus fibrosus and even into the nucleus pulposus during disc degeneration [57, 58, 85–87, 141, 279]. Furthermore, there is some evidence that neo-innervation is preceded by neovascularization of the disc [86, 141]. However, these findings could not be confirmed by studies precisely investigating the temporospatial distribution of blood vessels [204] and neural innervation of the disc (Boos et al., unpublished data).

Discogenic back pain may be caused by proinflammatory cytokines

The **impaired nutritional supply** has been identified as one of the key factors in triggering the changes in the extracellular matrix with aging (see Chapter 4). Nutritional deficits result in an **increase in lactate** and **decreased pH**. The altered metabolism of the disc leads to **cellular changes** and **matrix degradation**. The cleavage of collagenous support structures may result in structural damage macroscopically seen as tear and cleft formation. The phenotypic change of disc cells in conjunction with degradation processes may prompt the initiation of a **proinflammatory cascade** which could become the decisive factor in producing pain. In this context, proinflammatory cytokines have been identified in degenerated intervertebral discs such as [7, 32, 33, 146, 216, 222, 271]:

Cellular changes and matrix breakdown may initiate a proinflammatory cascade

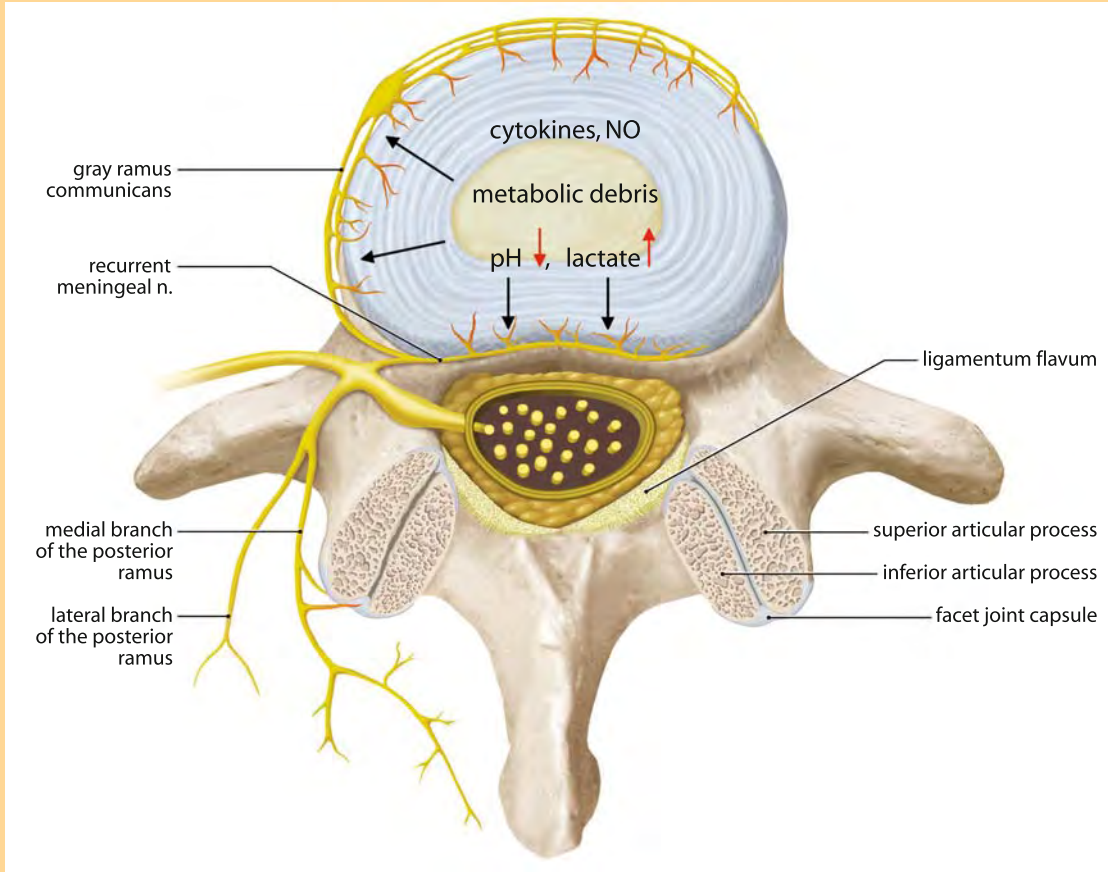


**Figure 1. Current concept of discogenic facet joint pain**

Proinflammatory cytokines, nitric oxide, metabolic debris, low pH or high lactate levels may diffuse out of the disc and cause nociception at the outer annular fibers.

- tumor necrosis factor (TNF)-α
- interleukin (IL)-1β
- interleukin (IL)-6
- prostaglandins (PG)-$E_2$

Discogenic back pain may be caused by proinflammatory cytokines

A current working hypothesis is that these proinflammatory cytokines along with other substances (e.g. nitric oxide, metabolite, waste products) diffuse out of the disc and cause nociception at the outer annular disc fibers which are innervated. The presence of **tear and cleft formations** appears to facilitate proinflammatory cytokine diffusion (Fig. 1).

## Facet Joint Osteoarthritis

Facet joint cartilage is often retained in severe OA

The facet joints are synovial joints with a hyaline cartilage surface, a synovial membrane, and a surrounding fibrous capsule similar to a diarthrodial joint. Bogduk extensively studied the neural innervations of the facet joints [18]. The lumbar facet joints are innervated by nociceptive fibers of the medial branch of the dorsal ramus, whereas the disc, the posterior longitudinal ligament and the dura are innervated by the recurrent meningeal nerve, a branch of the ventral primary ramus (Fig. 1). As is the case for any true synovial joint, the facet joints

Malalignment of the facet joints may predispose to OA

may undergo degenerative changes and develop **osteoarthritis** (OA). Similar to large synovial joints, **malalignment** of the facet joints was suspected to be a predisposing factor for OA. A significant association was found between the sagittal orientation and OA of the lumbar facet joints, even in patients without degenerative spondylolisthesis [94]. Facet joint OA appears to be the pathoanatomic feature that is associated with **sagittal orientation** of the facet joints in patients with degenerative spondylolisthesis [94]. In contrast to OA of large synovial joints (e.g. hip joint), an intact covering of hyaline cartilage is frequently retained by the articular surfaces even when large osteophytes have formed [265].

It can be hypothesized that this preservation of articular cartilage may result from changing joint stresses [265]. However, Swanepoel et al. [250] found that the apophyseal cartilage of the facet joint surfaces exhibits a greater extent and prevalence of cartilage fibrillation than large diarthrodial joints, with significant damage in specimens younger than 30 years. In late stages of OA, the facet joints also demonstrate the **classic features**, i.e. complete loss of articular cartilage, cysts and pseudocysts in the bone, dense bone sclerosis, and large osteophyte formation. Of note, spontaneous fusion of the facet joints is very rare in the absence of ankylosing spondylitis or ankylosing hyperostosis [265]. Recently, inflammatory cytokines in facet joint capsule were observed at high levels in degenerative lumbar spinal disorders [132]. These inflammatory cytokines had a higher concentration rate in lumbar spinal canal stenosis than in lumbar disc herniation. This finding suggests that inflammatory cytokines in degenerated facet joints may play an important role in symptomatic facet joint OA [132].

Spontaneous facet joint ankylosis is rare

Facet joint OA is a veritable source of back pain

Facet joint alterations were first identified as a source of low-back pain by Goldthwait in 1911 [108]. Ghormley coined the term "**facet joint syndrome**" in 1933 [101], but it only gained widespread attention after Mooney's clinical paper in 1976 [197]. Since that time, debate has continued on the relevance of this clinical entity because it was not possible to reliably attribute clinical symptoms to joint abnormalities [134, 135]. Nevertheless, there is no doubt that facet joint OA can be related to severe back pain in some patients.

## Segmental Instability

Excessive segmental motion is a potential pain source

Although there is no serious doubt that excessive mobility within a motion segment can occur which results in pain, a valid definition of segmental instability has not been satisfactorily established and remains somewhat enigmatic [217]. The current working hypothesis is (Table 2):

**Table 2.** Definition of segmental instability

- Segmental instability is a loss of stiffness of a motion segment which causes pain, has the potential to result in progressive deformity, and will place neurogenic structures at risk

According to Pope et al. [217]

No objective definition of segmental instability is available

This definition implies that forces applied to a motion segment produce greater displacement due to decreased stiffness than would be seen in a normal segment [217] and that this effect is related to pain. Various attempts were made to measure segmental instability by imaging studies. Since the diagnostic criteria for segmental instability are unclear, a proper definition of a reference standard is obviously problematic.

The range of normal (painless) lumbar motion is large

Stokes et al. [248] reported on 78 patients who had a clinical diagnosis of putative segmental instability. The authors found that the forward-backward translation movement in intervertebral discs did not differ significantly at the affected

levels from those at unaffected levels. However, the ratio between translation motion and angular motion was somewhat elevated in the affected levels. It was concluded that flexion/extension radiography was not useful in the diagnosis of lumbar instability. Hayes [124] examined the angulatory and translational lumbar spine intervertebral motion using flexion-extension radiographs from 59 asymptomatic individuals. There was 7–14 degrees of angulatory motion present in the lumbar spine with such a large variation that norms of angulatory motion could not be more precisely defined. **Translational motion** was 2–3 mm at each lumbar level. Some of the asymptomatic subjects (20%) had 4 mm or more translational motion at the L4–5 interspace and at least 10% had 3 mm or greater motion at all levels except L5–S1. The diagnostic value of flexion-extension views has also been questioned in conditions where a segmental instability (e.g. spondylolisthesis) is expected [212]. The problem may lie in the inability of functional views to properly depict instability rather than in the fact that there is no instability detected with the applied tests.

Functional views do not differentiate normal and painful motion

So far, radiological criteria for instability (in terms of certain excessive motion) have failed to diagnose instability in a reliable way [214]. Boden and Wiesel [17] have indicated that it is more important to measure the dynamic vertebral translation than a static displacement on a single view. This was corroborated by an experimental animal study [143]. From these results, it was concluded that the maximum range of motion, which must be measured using a dynamic technique, was a more sensitive parameter for identifying changes in segmental kinematics caused by chronic lesions than was the end range of motion. The lumbar musculature was found to be less efficient overall in stabilizing the motion segment, possibly because of altered mechanisms in the neuromuscular feedback system [143]. The hypothesis that the motion per se and not the endpoints are unstable was explored by dynamic lumbar flexion-extension motion using videofluoroscopy [207]. While segmental instability was found to influence the whole lumbar motion in patients with degenerative spondylolisthesis, patients with chronic low-back pain did not show a significant difference when compared with volunteers [207].

Segmental instability appears to be related to the motion itself

Despite refined assessment methods, no substantial progress has so far been achieved in exploring the predisposing pathomorphological or biomechanical factors or reliably diagnosing segmental instability. Therefore, the entity of segmental instability remains a clinical diagnosis without scientific confirmation. The classic clinical entity of a segmental instability is spondylolisthesis, which is covered in Chapter 27.

## Clinical Presentation

In **specific spinal disorders,** a pathomorphological (structural) correlate can be found which is consistent with the clinical presentation, while the diagnosis of **non-specific spinal disorders** is reached by exclusion (see Chapter 8). Typical radicular leg pain and claudication symptoms can be attributed to morphological alterations (i.e. nerve root compromise, spinal stenosis) in the vast majority of patients with leg pain; less than 15% of individuals with isolated or predominant back pain can be given a precise pathoanatomical diagnosis [66].

In this chapter, we focus on clinical syndromes related to specific structural alterations such as disc degeneration, facet joint OA, or segmental instability. Despite the dilemma of unproven efficacy of diagnostic tests for isolated back pain, a practical approach appears to be justifiable until more conclusive data is available from the literature [66, 203]. We acknowledge that this approach is anecdotal rather than solidly based on scientific evidence, but it appears to work in our hands.

## History

Although we focus here on specific syndromes, the patient should undergo a thorough assessment of the whole spine as outlined in Chapter 8.

### Discogenic Pain Syndrome

Discogenic pain originating from the thoracolumbar spine manifests as deep aching pain located in the lower lumbar spine.

The **cardinal symptoms** of discogenic back pain are:

- predominant low-back pain
- pain aggravation in flexion (forward bending, sitting)
- non-radicular pain radiation in the anterior thigh

Discogenic back pain increases during sitting and forward bending

The pain is often increased after **prolonged sitting** or **bending** with the spine in a semi-flexed position. Patients often report that sitting is the worst position (caused by disc compression). The pain increases when the patient tries rising from the supine position with their knees straight (sit-up). In severe cases [often associated with endplate (Modic) changes], the pain intensity resembles the complaints of a low grade infection or a tumor and can hurt during the night (Case Introduction). However, none of these signs has been shown to closely correlate with a positive pain provocation test during discography. Therefore, these findings must be regarded as non-specific and non-sensitive.

### Facet Joint Syndrome

The term "facet joint syndrome" comprises clinical symptoms related to the facet joints such as dysfunction and osteoarthritis.

The **cardinal symptoms** of facet joint pain are:

- predominant low-back pain
- osteoarthritis pain type (improvement during motion)
- pain aggravation in extension and rotation (standing, walking downhill)
- non-radicular pain radiation in the posterior thigh

**Backward bending** and **rotation** compresses the facet joints and may therefore provoke the pain. The pain is often located in the buttocks and groin and infrequently radiates into the posterior thigh. However, it is non-radicular in origin.

Facet joint pain improves during movement (early stages)

The pain usually resembles that of an osteoarthritis (OA) type with **improvement by motion** and aggravation by rest. However, in late stages of OA this alleviation may vanish. Patients often feel stiff in the morning and have a "**walk in**" period. They sometimes complain about pain in the early morning of such intensity that they have to get out of bed. Similarly, patients report that they wake up when turning. Occasionally, they have to get out of bed and move around until they can continue their sleep (Case Study 1).

When comparing the outcome of facet joint injections with clinical symptoms, no reliable clinical signs could be identified which predicted pain relief during injection. Therefore, it is difficult to define a so-called "facet joint syndrome" [134, 135, 197].

### Instability Syndrome

The definition of spinal instability remains enigmatic because a gold standard test is lacking. So far, the definition is purely descriptive (Table 2) and therefore the clinical signs are vague (Case Study 2).

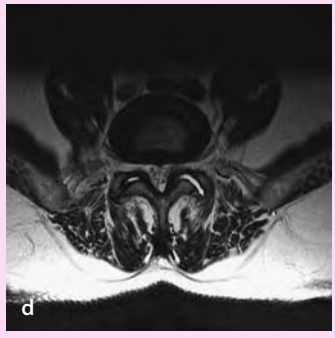


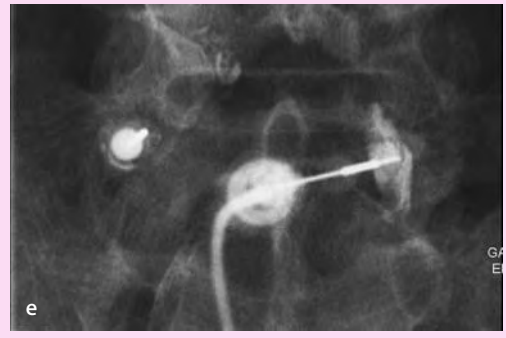

## Case Study 1

A 58-year-old male presented with recurrent episodes of back pain radiating to the posterior thigh. The pain was worse during the morning and on backward bending with rotation. The patient reported that forward bending relieved his pain. Standard radiographs (a, b) showed a lumbosacral transitional anomaly with sacralization of L5. Sagittal T2W MRI scan revealed normal discs at all lumbar levels (c). Axial T2W image (d) revealed a moderate to severe osteoarthritis of the facet joint. A gap is visible between the articular surfaces of the facet joints L4/5 filled with fluid. An intra-articular facet joint block (e) relieved the symptoms completely for 10 weeks but then the symptoms recurred. Two repeated facet joint injections relieved the pain for 6 and 4 weeks, respectively. The patient was diagnosed with a symptomatic facet joint osteoarthritis and underwent pedicle screw fixation and posterolateral fusion (f, g). At 1-year follow-up the patient was symptomfree and fully active.

The **cardinal symptom** of a segmental instability is:

- mechanical low-back pain

Instability pain worsens during motion and improves during rest

Mechanical LBP can be defined as pain which is provoked by motion and improves or disappears during rest. **Vibration** (e.g. driving a car, riding in a train) may aggravate the pain. Pain is also felt when sudden movements are made. The resulting muscle spasm can be so severe that the patients experience a lumbar catch ("**blockade**"). Pain usually does not radiate below the buttocks. Some patients benefit from wearing a brace.

### Non-specific Back Syndromes

Within this group, the **sacroiliac joint (SIJ) syndrome** deserves special attention because the pain can occasionally be attributed to a joint dysfunction or inflammation. Patients with pain originating from the SIJ locate their pain unilaterally deep over the SIJ. Sometimes the pain radiates to the dorsal aspect of the thigh or to the groin. There is no specific provocation pattern.

## Physical Findings

Physical findings rarely help to identify the pain source

The physical assessment of the spine is often hampered by strong muscle spasm and therefore does not allow for a passive examination as for large diarthrodial joints. With the exception of neurological signs, the physical assessment does not permit a reliable pathoanatomic diagnosis to be made in patients with predominant back pain. The physical examination should follow a defined algorithm so as to be as short and effective as possible (see Chapter 8). We focus here on the physical findings, which may at least give a hint as to the source of the back pain.

In patients with **discogenic pain syndrome,** physical findings are:

- pain provocation on repetitive forward bending
- pain provocation during a sit-up test (with legs restrained by the examiner)

In patients with **facet syndrome,** physical findings are:

- pain provocation on repetitive backward bending
- pain provocation on repetitive side rotation
- hyperextension in the prone position

In patients with **instability syndrome,** physical findings are:

- abnormal spinal rhythm (when straightening from a forward bent position)
- hand-on-thigh support

The hand-on-thigh support can be seen when pain is severe on forward bending. The patient needs the support with hands on thighs when straightening out of the forward bent position by supporting the back.

## Diagnostic Work-up

Diagnostic tests differentiate symptomatic and asymptomatic alterations

None of the aspects of the patient's history or physical examination allows the symptoms to be reliably attributed to structural abnormalities in patients with predominant back pain. The imaging studies are hampered by the high prevalence of asymptomatic alterations in the lumbar spine as outlined above. Further diagnostic tests are needed to differentiate between symptomatic and asymptomatic morphological alterations.

## Imaging Studies

Debate continues about the need for standard radiographs for the initial evaluation of patients with predominant back pain. MRI has become the imaging modality of choice in evaluating LBP patients. However, **lumbosacral transitional anomalies** can be missed when only sagittal and axial views are obtained. In our center, we only omit standard radiographs in the presence of recent anteroposterior and lateral radiographs. A detailed description of the imaging modalities for the lumbar spine is included in Chapter 9.

### Standard Radiographs

Standard radiographs are rarely diagnostic

Standard radiographs are helpful in diagnosing lumbosacral transitional anomalies which may be overlooked on MRI in cases without coronal sequences. Standard radiographs are rarely helpful in reliably identifying the pain source. However, **non-specific findings** indicating a painful disc degeneration or facet joint osteoarthritis are:

- disc space narrowing with endplate sclerosis
- severe facet joint osteoarthritis

#### *Flexion/Extension Films*

Flexion/extension views cannot reliably distinguish between normal and symptomatic lumbar motion

Functional views are generally regarded as unreliable for the diagnosis of a segmental instability because of the wide range of normal motion [248]. However, excessive segmental motion (>4 mm) or subluxation of the facet joint that is rare in asymptomatic individuals, and is not even observed in patients who exhibit extreme ranges of motion (e.g. contortionists) [120]. However, the inability to reliably diagnose or attribute segmental instability to a specific level by imaging studies prompts the taking of great care with this diagnostic label (Case Study 2).

### Magnetic Resonance Imaging

Severe Modic changes and facet joint OA are uncommon in asymptomatic individuals

MRI has surpassed computed tomography (CT) because of its tissue contrast and multiplanar capabilities. MRI is a very sensitive but less specific imaging modality because of the vast majority of alterations which can be observed in asymptomatic individuals [22]. There are only very few alterations which are uncommon in asymptomatic individuals younger than 50 years [272], i.e.:

- severe facet joint osteoarthritis
- endplate changes (so-called Modic changes) [195]

On the contrary, **annular tears** can be found in up to 30 % of asymptomatic individuals and are therefore not a good predictor.

In the context of lumbar spondylosis with predominant back pain, MR scans should be graded specifically with regard to:

- disc degeneration [215]
- vertebral endplate changes [195]
- facet joint osteoarthritis [273]

Moderate to severe Modic changes correlate with positive provocative discography

In particular, Type I Modic changes are considered to be related to discogenic LBP [195]. However, Weishaupt et al. [275] have demonstrated that moderate to severe **Type I and II Modic changes** are correlated with discogenic LBP based on provocative discography (Case Introduction). Although CT provides better imaging of bone, MRI does not provide less information regarding facet joint osteoarthritis than CT [273].

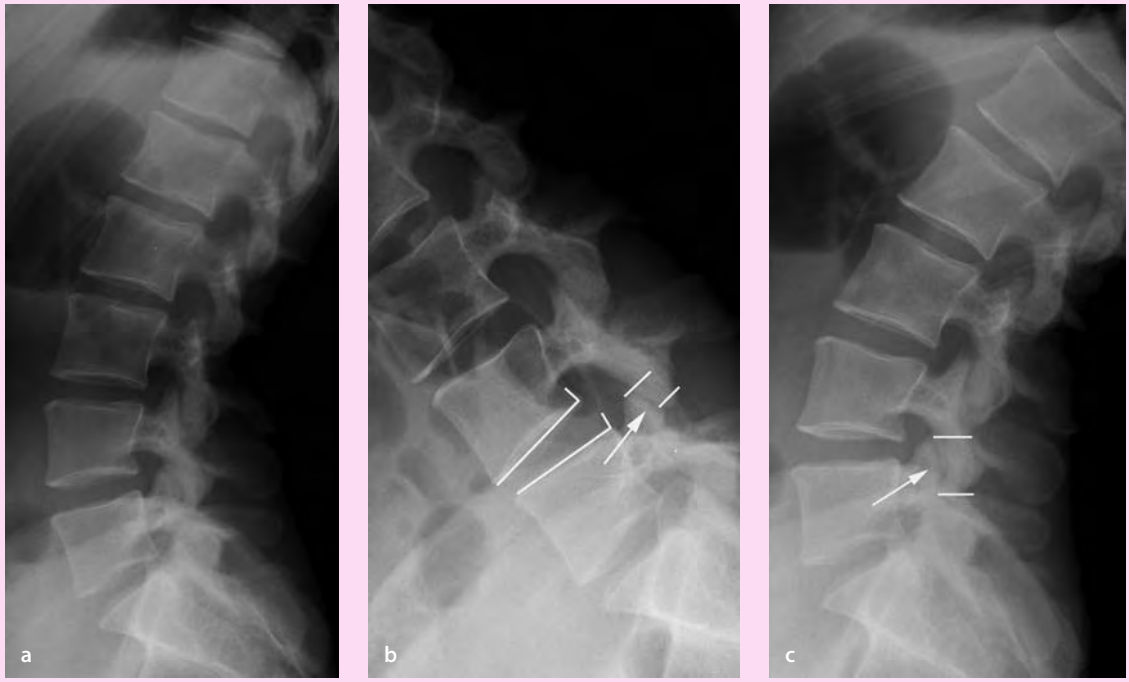


**Case Study 2**

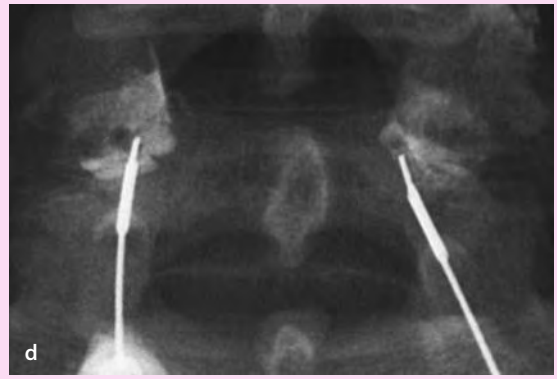


A 28-year-old female presented with severe LBP which had been persistent for 4 months. The pain became worse during the day while moving and was better during rest and at night. In the morning, the patient was symptom-free. The patient reported frequent sensations of sharp pain in her lumbar spine during motion but no pain radiation into the legs. Lateral radiograph showing a normal spine (a). Functional views (b, c) demonstrated increased motion (compared to adjacent levels) at L4/5 with increased segmental kyphosis, slight anterior displacement of L4, and subluxation of the facet joints (*arrow*). The MRI was unremarkable (not shown). A facet joint block (d) at L4/5 resulted in a symptom-free period for several weeks. The patient was diagnosed with mechanical LBP (instability syndrome). Although very suggestive, the increased motion at L4/5 should only tentatively be attributed to the increased mobility at L4/5 because of the large variation in segmental motion in asymptomatic individuals. She was admitted to an intensive rehab program with emphasis on stabilizing exercises which resolved her symptoms. At 1 year follow-up, the patient was completely painfree and unrestricted for all activities.

### Computed Tomography

The current role of CT in the evaluation of patients suffering from lumbar spondylosis is the assessment of fusion status and for patients with contraindications for MRI (e.g. pacemaker). In the latter case, MRI is often combined with myelography (myelo-CT) to provide conclusions on potential neural compression.

CT is the method of choice for the assessment of spinal fusion

Computed tomography (Fig. 2) is the method of choice for the assessment of the fusion status [228]. However, CT in conjunction with 2D coronal and sagittal image reformation is more sensitive in diagnosing lumbar fusions than non-union (Fucentese and Boos, unpublished data).

**Figure 2. Computed tomography**

Computed tomography is the imaging modality of choice for the assessment of spinal fusion. Even in the presence of implants, the bony bridges are well visualized. Bony bridges outside a fusion cage are a more reliable sign of solid fusion than when they appear inside. a Axial view; b sagittal reformation; c coronal reformation

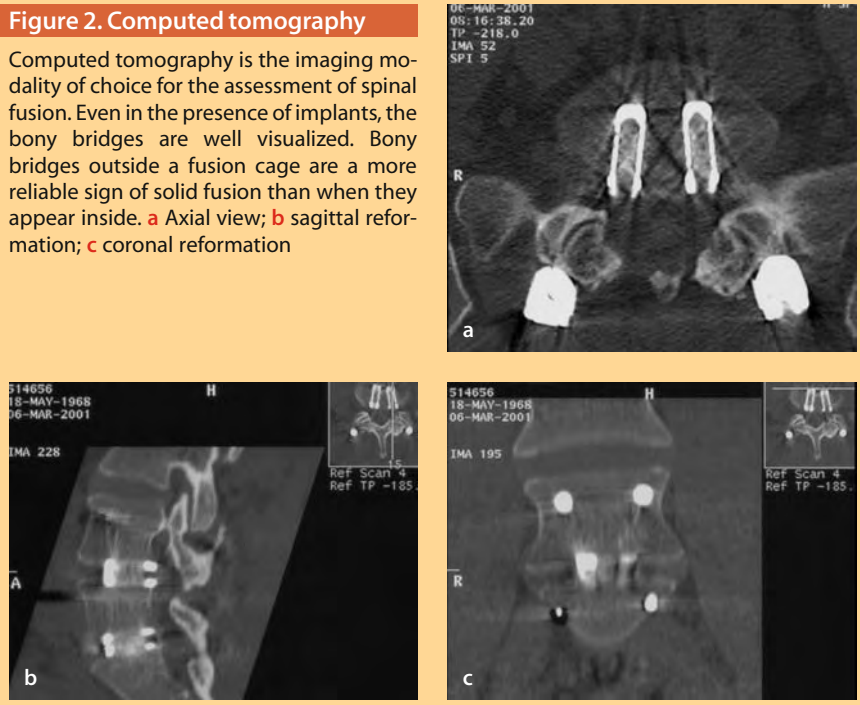


## Injection Studies

Injection studies are helpful in identifying the pain source

The high prevalence of asymptomatic disc alterations prompts the need for further diagnostic tests to confirm that a specific structural abnormality is the source of the pain. Spinal injections play an important role, although the scientific evidence in the literature for their diagnostic efficacy is poor. Furthermore, the predictive power of an injection study to improve patient selection for surgery is poorly explored and documented [169]. A detailed description of the strength and weaknesses of these diagnostic studies is included in Chapter 10.

### Provocative Discography

Discography remains the only method to verify discogenic LBP

Discography was introduced to image intervertebral disc derangement [172]. Currently, discography predominantly serves as a pain provocation test to differentiate symptomatic and asymptomatic disc degeneration. The diagnostic efficacy of this test remains a matter of debate [43, 202, 269] (see Chapter 10). The assessment of the diagnostic accuracy of provocative discography for discogenic LBP is problematic since no gold standard is available [43].

Always include an MR normal level as internal control

A reasonable practical approach is to include an adjacent MR normal disc level as internal control [169, 275]. Accordingly, a positive pain response would include an exact pain reproduction at the target level and no pain provocation or only pressure at the normal disc level (Case Introduction). In our center, patients are only selected for provocative discography if they are potential candidates for surgery, i.e. when the diagnostic test will influence treatment strategy. However, careful interpretation of the findings is still mandatory with reference to the clinical presentation [43]. Furthermore, provocative discography has failed to improve patient selection to obtain better clinical outcome after surgery [177].

### Facet Joint Injections

Diagnosis of painful facet joints by injections must be made cautiously

The differentiation between symptomatic and asymptomatic facet joint osteoarthritis based on imaging studies alone is impossible [169]. So far, facet joint injections have been used for this purpose but are not without shortcomings (see Chapter 10). Some authors suggest that a facet joint syndrome can be diagnosed based on pain relief by an intra-articular anesthetic injection or provocation of the pain by hypertonic saline injection followed by subsequent pain relief after injection of local anesthetics [44, 173, 185, 199]. Interpretation of the pain response is difficult because the facet joints are innervated by two to three segmental posterior branches and the local anesthetic may diffuse to adjacent levels if the injection is done non-selectively (i.e. without prior contrast medium injection) [169]. We recommend using contrast injection to document the correct needle position and filling of the joint capsule (Case Study 1). Uncontrolled diagnostic facet joint blocks exhibit a false-positive rate of 38 % and a positive predictive value of only 31 % [239]. It is therefore mandatory to perform repetitive infiltrations to improve the diagnostic accuracy [239]. However, there are no convincing pathognomonic, non-invasive radiographic, historical, or physical examination findings that allow the reliable identification of lumbar facet joints as a source of low-back pain and referred lower extremity pain [69, 70].

## Temporary Stabilization

Temporary stabilization does not predict fusion outcome

The diagnosis of segmental instability remains a matter of intensive debate. However, it would be unreasonable to assume that abnormal segmental mobility is non-existent or cannot be painful. Imaging studies, particularly functional views, have failed to reliably predict segmental instability because of the wide normal range of motion. The correct identification of the unstable level(s) is challenging. The temporary stabilization with a **pantaloon cast** [223] has the drawback of being unselective and requires further diagnostic testing, e.g. by facet joint blocks. Stabilization of the putative abnormal segments by an **external transpedicular fixator** has been suggested by several authors [74, 237, 254] with mixed results in terms of outcome prediction. Based on an analysis of 103 cases, Bednar [10] could not support using the external spinal skeletal fixation as a predictor of pain relief after lumbar arthrodesis.

## Patient Selection for Treatment

The important role of **non-biological factors** for the outcome of surgical procedures particularly for patients with predominant LBP is well documented. We have therefore dedicated Chapter 7 to this topic. Various domains must be considered, i.e.:

- medical factors
- psychological factors
- sociological factors
- work-related factors

Non-biological factors are important outcome predictors

In clinical practice, however, it is extremely difficult to identify and systematically assess risk factors that can be used to accurately predict the outcome of surgery. So far, there is insufficient evidence to exclude patients from surgery on the grounds of specific risk factors [183]. Nonetheless, in the presence of selected factors (see Chapter 7), surgery should at least be delayed until attempts have been made to modify risk factors that are amenable to change and all possible conservative means of treatment are exhausted.

## Non-operative Treatment

Most patients with predominant low-back pain without radiculopathy or claudication symptoms can be managed successfully by non-operative treatment modalities (Case Study 2). The general objectives of treatment are (Table 3):

**Table 3.** General objectives of treatment

- pain relief
- improvement of health-related quality of life
- improvement of activities of daily living
- improvement of social activities
- improvement of recreational activities
- improvement of work capacity

When the diagnostic assessment has identified a specific source of back pain (Table 1), the conservative treatment option does not differ from those applied to non-specific disorders, which are extensively covered in Chapter 21. The **mainstay of non-operative management** rests on three pillars:

- pain management (medication)
- functional restoration (physical exercises)
- cognitive-behavioral therapy (psychological intervention)

Cognitive behavioral interventions are necessary to address fears and misbeliefs

Pharmacologic pain management is outlined in Chapter 5. Spinal injections (e.g. facet joint blocks) may be a reasonable adjunct in controlling the pain for a short term period [109, 169]. The first important aspect is a multidisciplinary functional restoration program and psychological interventions to influence patient behavior (see Chapter 21). The second important aspect is the **timeliness** of the treatment intervention. The longer pain and functional limitations persist, the less likely is pain relief, functional recovery and return to work (see Chapter 6). Patients presenting with specific degenerative back pain usually experience their pain and functional limitations for more than 3 months. These patients should promptly be included in a multidisciplinary functional work conditioning program. There is increasing evidence that patients with chronic LBP benefit from a **multidisciplinary treatment** with a functional restoration approach when compared with inpatients or outpatient non-multidisciplinary treatments [263]. Two recent high quality randomized controlled trials (RCTs) demonstrated that such a program is equally effective as surgery in treating patients with lumbar spondylosis [31, 77].

It is as simple as it is obvious that the outcome of any treatment is critically dependent on patient selection and this is also valid for non-operative treatment (see Chapter 7). Favorable indications for non-operative treatment include (Table 4):

**Table 4.** Favorable indications for non-operative treatment

- minor to moderate structural alterations
- LBP of variable intensity and location
- intermittent symptoms
- short duration of persistent symptoms (< 6 months)
- absence of risk factor flags
- highly motivated patient

## Operative Treatment

### General Principles

Spinal fusion is thought to eliminate painful motion

Spinal fusion is the most commonly performed surgical treatment for lumbar spondylosis [66]. The **paradigm of spinal fusion** is based on the experience that painful diarthrodial joints or joint deformities can be successfully treated by arthrodesis [66, 121]. Since its introduction in 1911 by Albee [3] and Hibbs [127], spinal fusion was initially only used to treat spinal infections and high-grade spondylolisthesis. Later this method was applied to treat fractures and deformity. Today approximately 75 % of the interventions are done for painful degenerative disorders [66]. Despite its frequent use, spinal fusion for lumbar spondylosis is still not solidly based on scientific evidence in terms of its clinical effectiveness [66, 102, 103, 264]. For a long time it was hoped that outcome of spinal fusions could be significantly improved when the fusion rates come close to 100 %. However, it is now apparently clear that outcome is not closely linked to the fusion status [24, 90, 91, 102, 103, 256].

The **standard concept** advocated in the literature is that surgical treatment is indicated when an adequate trial of non-operative treatment has failed to improve the patient's pain or functional limitations [122, 264]. However, there is no general consensus in the literature on what actually comprises an adequate trial of non-operative care. Based on a meta-analysis, van Tulder et al. [264] concluded that fusion surgery may be considered only in carefully selected patients after active rehabilitation programs for a period of 2 years have failed. The general philosophy that surgery is only indicated if long-term non-operative care has failed is challenged by the finding that the longer pain persists the less likely it is that it will disappear. This notion is supported by recent advances in our understanding of the pathways and molecular biology of persistent (chronic) pain (see Chapter 5). It has also been known for many years that returning to work becomes very unlikely after 2 years [268].

Surgery if needed should be done in a timely manner

We therefore advocate a more **active approach in patient selection** for surgery, i.e. not only offering surgery as the last resort after everything else has failed because of the adverse effects of pain chronification. Patients should be evaluated early (i.e. within 3 months), searching for a pathomorphological abnormality which is likely to cause the symptoms. This evaluation must be based on a thorough clinical assessment, imaging studies and diagnostic tests. If a pathomorphological alteration in concordance with the clinical symptoms can be found, the patient should be selected for potential surgery. Prior to surgery, the patient should then be integrated in a fast track aggressive functional rehabilitation program (not longer than 3 months). If this program fails, the structural correlate should be treated surgically if multilevel (>2 levels) fusion can be avoided. In multilevel degeneration of the lumbar spine requiring more than two-level fusion, the clinical outcome is less satisfactory in our hands and we are more conservative. We acknowledge that this approach is anecdotal and not yet based on scientific evidence, but it seems to be reasonable and works satisfactorily in a large spine referral center.

**Favorable indications for surgery** include (Table 5):

**Table 5.** Favorable indications for operative treatment

- severe structural alterations
- one or two-level disease
- clinical symptoms concordant with the structural correlate
- positive pain provocation and/or pain relief tests
- short duration of persistent symptoms (<6 months)
- absence of risk factor flags
- highly motivated patient
- initial response to a rehab program but frequent recurrent episodes

Only a few morphological imaging abnormalities have been identified which rarely occur in a group of asymptomatic individuals below the age of 50 years [274] and may therefore predict the pain source when occurring in symptomatic patients. Severe structural alterations which may predict a **favorable outcome** of surgery include:

- severe facet joint osteoarthritis
- disc degeneration with severe endplate abnormalities (Modic Types I and II)

These abnormalities represent favorable predictors for surgery, particularly when present at only one or two levels with the rest of the thoracolumbar spine unremarkable, cause concordant symptoms and consistently respond to pain provocation and relief test. As outlined above, the duration of symptoms should be short to avoid the adverse effects of a chronic pain syndrome. It has been our anecdotal observation that patients have a favorable outcome if they had responded successfully to a **multidisciplinary restoration program** but have frequent recurrent episodes.

## Biology of Spinal Fusion

A basic understanding of the general principles of bone development and bone healing as well as the biologic requirements for spinal fusion in the lumbar spine are a prerequisite to choosing the optimal fusion technique [13]. A comprehensive review of this topic is far beyond the scope of this chapter and the reader is referred to some excellent reviews [13, 92, 93, 209, 232, 240].

In contrast to fracture healing, the challenge in spinal fusion is to bridge an anatomic region with bone that is not normally supported by a viable bone [34]. **Spinal arthrodesis** can be generated by a fusion of:

- adjacent laminae and spinous processes
- facet joints
- transverse processes
- intervertebral disc space

Vascular supply to the fusion area is important

An osseous **fusion of the transverse processes** is the most common type of fusion performed in the lumbar spine [16]. MacNab was one of the first to realize that the success of intertransverse fusion over posterior fusion (i.e. bone apposition on the laminae and spinous processes) was based on the blood supply to the fusion bed which allowed for a revascularization and reossification of the graft [176]. The early interbody fusion technique (inserting bone into the intervertebral disc space after discectomy) was hampered by graft subsidence or graft failure because of the heavy loads in the lumbar spine and did not provide favorable results without instrumentation (see below).

The prerequisite of successful spine fusion is **three distinct properties** of the applied graft material, i.e. [164, 259]:

- osteogenesis
- osteoconduction
- osteoinduction

The optimal graft material should be osteogenic, osteoconductive and osteoinductive

**Osteogenicity** is the capacity of the graft material to directly form bone and is dependent on the presence of viable osteogenetic cells. This property is only exhibited by fresh autologous bone and bone marrow. **Osteoconduction** is the process of living tissue to grow onto a surface or into a scaffold, which results in new bone formation and incorporation of that structure [59]. Particularly cancellous bone with its porous and highly interconnected trabecular architecture allows easy ingrowth of surrounding tissues. Osteoconduction is also observed

in fabricated materials that have porosity similar to that of bone structure, e.g. coralline ceramics, hydroxyapatite beads, combinations of hydroxyapatite and collagen, porous metals and biodegradable polymers [59]. **Osteoinduction** indicates that primitive, undifferentiated and pluripotent cells are stimulated to develop into bone-forming cells [4]. Urist [257, 258] coined the term "**bone morphogenetic proteins**" (BMPs) for those factors that stimulate cells to differentiate into osteogenic cells.

### Bone Grafts

Autologous bone is still the gold standard

**Autologous bone** is generally considered the "gold standard" as a graft material for spinal fusion and exhibits osteogenetic, osteoconductive and osteoinductive properties [115]. Autologous bone for spinal fusion is harvested from the anterior or posterior iliac crest as cancellous bone, corticocancellous bone chips or tricortical bone blocks. The drawback of autologous bone is related to the limited quantity and **potential donor site pain** [63, 80, 125].

Allografts potentially transmit infectious disease

These drawbacks have led to the use of **allograft bone** early in the evolution of spinal fusion. Allografts are used in different forms for spinal fusion. They are predominately used as **structural allografts** (e.g. femoral ring allografts) but are available in other forms (e.g. corticocancellous bone chips). Bone allografts exhibit strong osteoconductive, weak osteoinductive but no osteogenetic properties [152, 232]. Fresh allografts elicit both local and systemic immune responses diminishing or destroying the osteoinductive and conductive properties. Freezing or freeze-drying of allografts is therefore used clinically to improve incorporation [107], but mechanical stability of the graft is reduced by freeze drying (about 50 %) [232]. However, the major drawback of those allografts is the potential transmission of infections (particularly hepatitis C, HIV) [64]. **Gamma irradiation** of at least 34 kGy is recommended to substantially reduce the infectivity titer of enveloped and non-enveloped viruses [220]. However, screening procedures remain mandatory. Autologous or allogenic cortical grafts are at least initially weight-bearing but all bone grafts are finally resorbed.

Cancellous allografts are completely replaced by autologous bone or resorbed

Cancellous grafts are completely replaced in time by **creeping substitution**, whereas cortical grafts remain as an admixture of necrotic and viable bone for a prolonged period of time [107]. Bone graft incorporation within the host, whether autogenous or allogeneic, depends on various factors [152]:

- type of graft
- site of transplant
- quality of transplanted bone and host bone
- host bed preparation
- preservation techniques
- systemic and local disease
- mechanical properties of the graft

Although the role of cancellous allograft as a delivery vehicle for other osteoinductive factors is conceptually reasonable, data is lacking to support this application at this time [162]. Femoral ring allografts for anterior interbody fusions have gained increasing popularity because of their capability for an initial structural support [191]. The decreased fusion rate associated with allografts becomes more significant in multilevel surgery and in patients who smoke [65].

### Bone Graft Substitutes

Bone graft substitutes are increasingly being used for spinal fusion because of the minimal but inherent risk of a transmission of infectious disease with allografts

[115]. Among the **characteristics** of an **optimal bone graft substitute** are:

- high degree of biocompatibility
- lack of immunogenicity and toxicity
- ability for biodegradation
- ability to withstand sterilization
- availability in different sizes, shapes and amounts
- reasonable cost

The most **commonly used bone graft substitutes** in spinal fusion are:

- calcium phosphates
- demineralized bone matrix (DBM)

### *Calcium Phosphates*

Calcium phosphate materials can be classified by chemical composition and origin [i.e. natural or synthetic (ceramic) forms] and include:

- hydroxyapatite (HA)
- tricalcium phosphate (TCP)
- natural coralline

This group of materials closely resembles the mineral composition, properties and microarchitecture of human cancellous bone and has a high affinity for binding proteins [162]. **HA** is relatively inert and biodegrades poorly. Due to its brittleness and slow resorption, remodeling may be hindered and the material can become a focus of mechanical stress [232]. In contrast, **TCP** composites exhibit greater solubility than HA and typically undergo biodegradation within approximately 6 weeks, which may be too early for a maturation of the fusion mass [162, 232]. **Coralline HA** (CHA) was developed in 1971 with the aim of providing a more consistent pore size and improved interconnectivity [198]. These natural ceramics are derived from sea corals and are structurally similar to cancellous bone. The coral calcium carbonate undergoes a hydrothermal reaction where calcium carbonates are transformed into HA [162].

Calcium phosphates are of limited effectiveness

These materials are available in various preparations including putty, granular material, powder, pellets or injectable calcium phosphate cement [20]. In contrast to early reports suggesting the capability for osteogenic stimulation, it is now believed that calcium phosphates have only osteoconductive properties [232]. Purely osteoconductive substitutes are less effective in posterolateral spine fusion, but may be suitable for interbody fusion when it is rigidly immobilized [13]. Although selective data both from animal and clinical studies appears promising, there is still only limited evidence for the clinical effectiveness of these materials to generate or at least enhance spinal fusion [232].

### *Demineralized Bone Matrix*

A group of low-molecular-weight glycoproteins contained in the organic phase (particularly BMPs) are responsible for the bone inductive activity [166]. DBM is produced through a mild acid extraction of cortical bone and is processed to reduce risk of infection and immunogenic host response. The mild demineralization removes the mineral content of the bone, leaving behind collagen and noncollagenous proteins including the BMP, which becomes locally available to the cellular environment [166]. DMB is supplied in a variety of forms such as gel, malleable putty, flexible strips or injectable bone paste. Lee et al. [166] have pointed out that the amount of osteoinductive ability may rely on its preparation and the type of carrier with which it is combined.

DBM predominantly is a bone graft extender

Even though DBM is considered osteoinductive, this effect is much weaker as compared with commercially available recombinant BMPs. The use of current available DBMs is primarily as a bone graft extender or enhancers but caution is necessary as bone graft substitutes [5, 13].

### Bone Promoters

Since their discovery by Urist in 1965 [257], BMPs have been the focus of intensive research and clinical testing aiming to develop treatment strategies to enhance bone healing and generate arthrodesis. The role of BMPs in bone formation during development and in fracture healing is now well established [225]. BMPs are members of the transforming growth factor-β supergene family [40] and so far more than 15 BMPs have been identified [225]. BMPs function as a differentiation factor and act on mesenchymal stem cells to induce bone formation [34].

The majority of preclinical and clinical studies for spinal fusion (interbody and posterolateral) have been done using [15, 68, 106, 139, 142, 145, 260, 261]:

- BMP 2
- BMP 7 (osteogenic protein-1, OP-1)

BMPs promote fusion but cost-effectiveness is unclear

The BMPs are delivered to the fusion site on carriers, e.g. HTA/TCP [15] or collagen matrix [145]. When used at an optimized concentration and with an appropriate carrier, BMPs can be successfully used as bone graft replacement [34]. However, only increasing experience and longer term follow-up will show whether these new fusion techniques will surpass the level of safety and clinical feasibility and can be established as a cost-effective treatment.

## Surgical Techniques

For a long time, spinal fusion has been the treatment of choice when addressing symptomatic lumbar spondylosis. Motion preserving implant technologies have emerged which offer theoretical advantages over fusion. The early motion preserving technologies such as **Graf ligamentoplasty** [96, 144, 226] and **Dynesys stabilization** [237, 238] have demonstrated favorable outcomes for selected patients. Similarly, the early outcome was promising for total disc arthroplasty [62, 116, 190, 284] and posterior interspinous spacers [49, 153, 286]. However, the new technologies must pass the test of time, i.e. long-term follow-up in RCTs, before they can be broadly accepted as alternative fusion techniques. So far, no evidence has been reported to demonstrate that these new techniques are superior to spinal fusion.

The scientific literature exhibits a plethora of articles covering the outcome of surgical treatment. The vast majority of these papers cover technical aspects, safety and early clinical results without adequate control groups. Many of the studies incorporated a whole variety of indications, which limits conclusions on degenerative lumbar spondylosis without neurological compromise. However, when the scientific literature is reduced to **Level A evidence** (i.e. consistent evidence in multiple high-quality RCTs), only 31 RCTs can be identified through March 2005 [102, 103]. These facts greatly limit treatment recommendations on degenerative lumbar spondylosis. In this chapter, we therefore attempt to base treatment recommendations on the best available evidence.

The scientific evidence for spinal fusion in lumbar spondylosis is poor

## Non-instrumented Spinal Fusion

Lumbar arthrodesis can be achieved by three approaches. The most commonly used technique is **posterolateral fusion** (PLF), which comprises a bone grafting of the posterior elements. As an alternative, the bone grafting can be performed after disc excision and endplate decancellation (**interbody fusion**) by a posterior approach (posterior lumbar interbody fusion, PLIF) or the anterior approach (anterior lumbar interbody fusion, ALIF). The so-called **combined or 360 degree fusion** is the combination of both techniques.

### *Posterolateral Fusion*

Posterolateral fusion remains the fusion gold standard

Posterolateral fusion was first described by Watkins in 1953 [270] and remains the gold standard for spinal fusion. The technique consisted of a decortication of the transverse spinous processes, pars interarticularis and facet joints with application of a large corticocancellous iliac bone block. This method has been modified by Truchly and Thompson [255], who used multiple thin iliac bone strips as graft material instead of a single corticocancellous bone block because of frequent graft dislocation [255]. In 1972, Stauffer and Coventry [245] presented the technique still used today by most surgeons, which consisted of a single midline approach (Fig. 3). However, the bilateral approach had a revival some years later when Wiltse et al. [278] suggested an anatomic muscle splitting approach which was modified by Fraser [118].

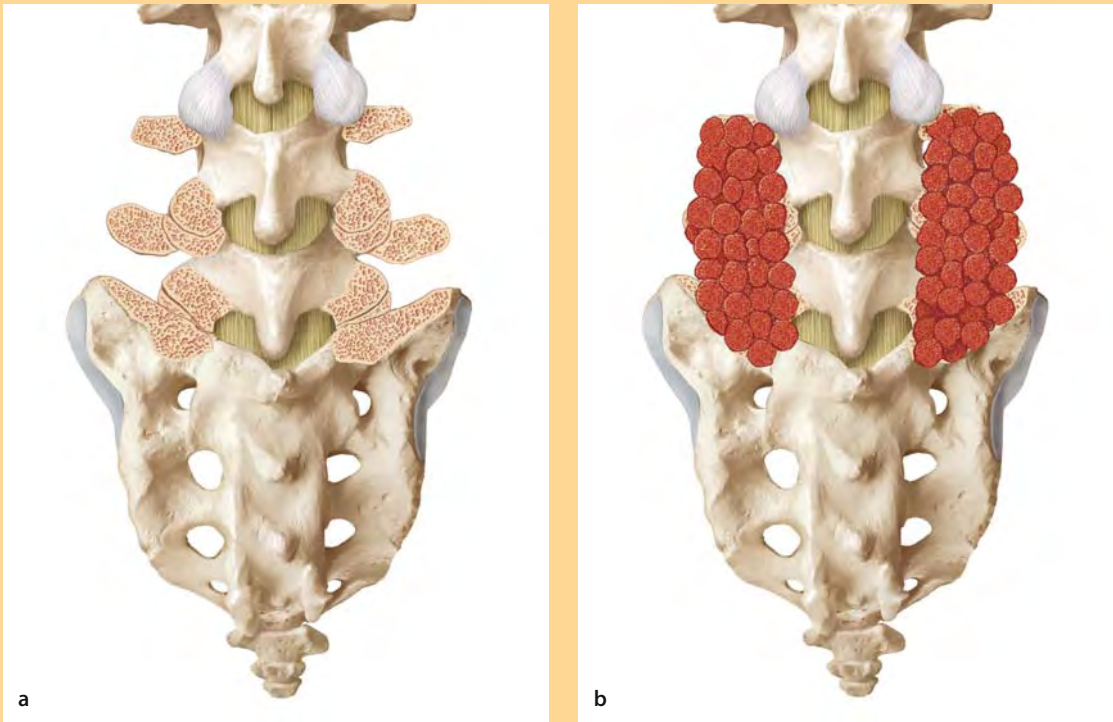


**Figure 3. Surgical technique of posterolateral fusion**

Careful preparation of the fusion bed is important and consists of: a decortication of the transverse process and facet joints and isthmus; b placement of autologous corticocancellous bone chips over the facet joints and transverse processes.

Non-instrumented posterolateral fusion remains the benchmark for comparison of fusion techniques

Boos and Webb [24] reviewed 16 earlier non-randomized studies (1966 – 1995) with a total of 1 264 cases and found a mean fusion rate of 87 % (range, 40 – 96 %) and an average rate of satisfactory outcome of 70 % (range, 52 – 89 %). The results reported in the article by Stauffer and Coventry [245] remain a benchmark for non-instrumented posterolateral fusion. Eighty-nine percent of those whose fusion was done as a primary procedure for degenerative disc disease achieved good clinical results and 95 % were judged to have a solid fusion. These favorable results were not surpassed by many studies which followed.

### *Posterior Lumbar Interbody Fusion*

Posterior disc excision and insertion of bone grafts was first described by Jaslow in 1946 [138] and popularized by Cloward [52, 54] and others as posterior lumbar interbody fusion (**PLIF**) (Fig. 4). The disadvantage of PLIF was the need for an extensive posterior decompression to allow for a graft insertion which destabilized the spine. Furthermore, graft insertion necessitates a substantial retraction of the nerve roots which carries the risk of nerve root injuries and significant postoperative scarring.

PLIF increases fusion rate

PLIF resulted in a somewhat higher fusion rate and better clinical outcome than posterolateral fusion. Based on an analysis of 1 372 cases reported in 8 studies [53, 56, 130, 131, 165, 171, 194, 219], mean fusion rate was 89 % (range, 82 – 94 %) and the average rate of satisfactory outcome was 82 % (range, 78 – 98 %) [24].

### *Anterior Lumbar Interbody Fusion*

Anterior spinal fusion was first described by Capener in 1932 for the treatment of spondylolisthesis [39]. However, Lane and Moore [163] were the first to perform anterior lumbar interbody fusion (ALIF) on a larger scale [163]. Iliac tricortical bone autograft as well as femoral, tibia, or fibula diaphyseal allografts were used for this technique. Particular femoral ring allografts have been recently used as cost-effective alternatives to cages and offer some advantages regarding the biology of the fusion compared to cages [167, 191]. The advantage of ALIF was that the paravertebral muscles and neural structures remained intact. A further technical advantage is that disc excision and graft bed preparation can be done better than with PLIF. On the other hand, the abdominal access is associated with specific approach related problems such as retrograde ejaculation in male patients (range, 0.1 – 17 %) [29, 76, 254] and vascular injuries (range, 0.8 – 3.4 %) [29, 210].

Stand-alone ALIF has not been successful

The results in the literature were largely variable. An analysis of 1 072 cases reported in 10 studies revealed a mean fusion rate of 76 % (range, 56 – 94 %) and an average satisfactory outcome rate of 76 % (range, 36 – 92 %) [24]. Compared to the favorable results Stauffer and Coventry achieved with a posterolateral fusion [245], the ALIF results of the same authors [244] were disappointing (fusion rate 56 %, satisfactory outcome 36 %). Stauffer and Coventry [244] concluded that ALIF should be utilized as a salvage procedure in those infrequent cases in which posterolateral fusion is inadvisable because of infection or unusual extensive scarring [244]. Graft dislocation and subsidence as well as moderate fusion rate caused the “stand-alone” ALIF to fall out of favor for some years.

## Instrumented Spinal Fusion

With the advent of pedicle screw fixation devices in the 1980s and the introduction of fusion cages in the 1990s, spinal instrumentation was widely used with the

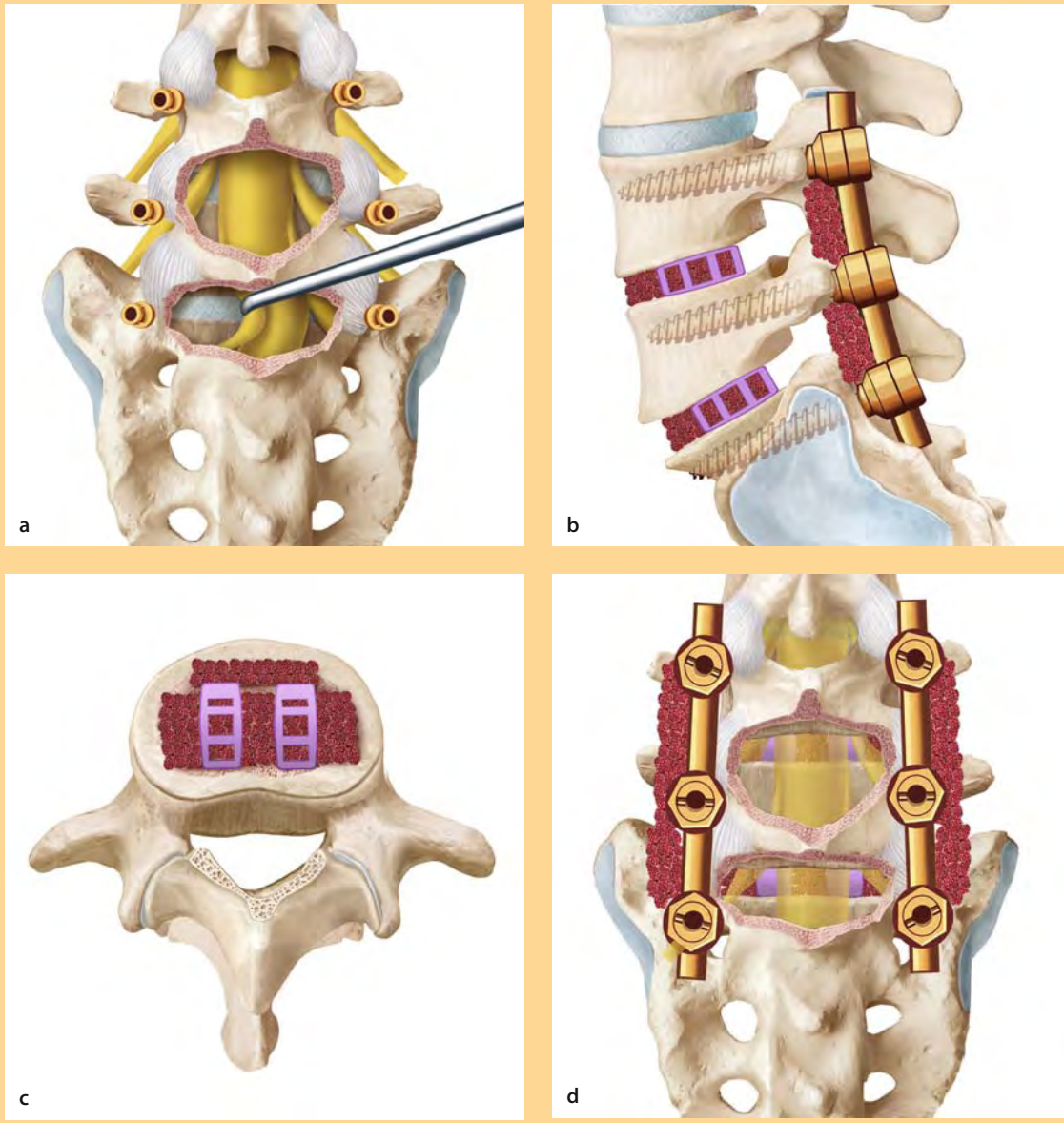


**Figure 4. Surgical technique of posterior lumbar interbody fusion**

a Pedicle screws are inserted at the target levels. A wide decompression is necessary to insert the cages safely through the spinal canal. The intervertebral disc is removed as completely as possible but without jeopardizing the anterior outer anulus (vascular injuries). The cartilage endplates are removed with curettes. Cages are inserted by retracting the nerve root and thecal sac medially. b, c Prior to insertion, the disc space is filled with cancellous bone graft particularly anteriorly. d The rod is inserted and fixed to the screws. A posterolateral fusion is added.

rationale that the improved segmental stability may enhance the fusion rate and simultaneously improve clinical outcome. The biomechanical background of spinal instrumentations is reviewed in Chapter 3.

### *Pedicle Screw Fixation*

Pedicle screw fixation is the gold standard for lumbar stabilization

The pedicle is the strongest part of the vertebra, which predestines it as an anchorage for screw fixation of the vertebral segments. Pedicle screw fixation had

Roy-Camille first used pedicle screws

its origins in France. From 1963, **Raymond Roy-Camille** first used pedicle screws with plates to stabilize the lumbar spine for various disorders [230]. Some years later, **Louis and Maresca** modified Roy-Camille's plate and technique to better adapt to the lumbosacral junction [174, 175]. Based on the pioneering work of **Fritz Magerl** [179], the concept of angle-stable pedicular fixation was introduced, which led to the development of the AO Internal Fixator [1, 67]. Around the same time, Steffee [246] developed the variable screw system (VSP), a plate pedicle screw construct. A further milestone in the development was the introduction of a new screw-rod system by **Cotrel and Dubousset** in 1984 [60]. The versatile Cotrel-Dubousset instrumentation system became widely used for the treatment of degenerative disorders. The current system offers the advantage of polyaxial screw heads which facilitate the rod screw connection. The most frequently used fusion technique today is to combine pedicle screw fixation with posterolateral fusion (Case Study 1).

Pedicle screw fixation is most commonly used in conjunction with posterolateral fusion

The fusion rates with the pedicle screw system average 91 % (range 67 – 100 %) with satisfactory clinical outcome ranging between 43 % and 95 % (mean 68 %) [24]. Many surgeons applied the pedicle screw stabilization system with the rationale that the enhanced fusion rate would also improve outcome. However, at the end of the 1990s it became obvious that pedicle screw fixation may increase the fusion rate but not necessarily clinical outcome [24, 102].

Pedicle screw fixation enhances fusion rate but not clinical outcome

### *Translaminar Screw Fixation*

Translaminar screws are an alternative to pedicle screws

An alternative method of screw fixation in the lumbar spine was first described in 1959 by **Boucher** [26]. These oblique facet screws were used to block the zygapophyseal joints. However, the stability of these screws crossing the facet joints obliquely was unsatisfactory. **Magerl** [180] developed the so-called translaminar screw fixation which crossed the facet more perpendicularly, increasing stability [126]. The initial clinical results were promising [113, 129, 136, 184]. The advantage is that the screws can be used as a minimally invasive posterior stabilization technique and can often be combined with an anterior interbody fusion [191], which can also be done minimally invasively (see below, Case Introduction) [21].

### *Cage Augmented Interbody Fusion*

Cages stabilize the anterior column and increase fusion rate

The application of interbody fusion cages for fusion enhancement is based on the rationale that a strong structural support is needed for the anterior column which does not migrate or collapse [122]. Interbody cages were designed and first used by **Bagby and Kuslich** (BAK cage) in the 1990s and consisted of threaded hollow cylinders filled with bone graft [160, 161]. Today, different designs and materials are available for anterior and posterior use (Table 6):

**Table 6.** Cage materials and design

| Designs | Materials |
|---|---|
| • threaded, cylindrical cages<br>• ring-shaped cages with and without mesh structure<br>• box-shaped cages | • titanium<br>• carbon<br>• polyetheretherketone (PEEK) |

The cages were originally designed as stand-alone anterior or posterior fusion devices. The initial studies in the literature reported promising results [161, 224, 233] and some authors reported satisfactory long term outcome [27]. However, the biomechanical (stability, no cage subsidence) and biologic (load sharing with

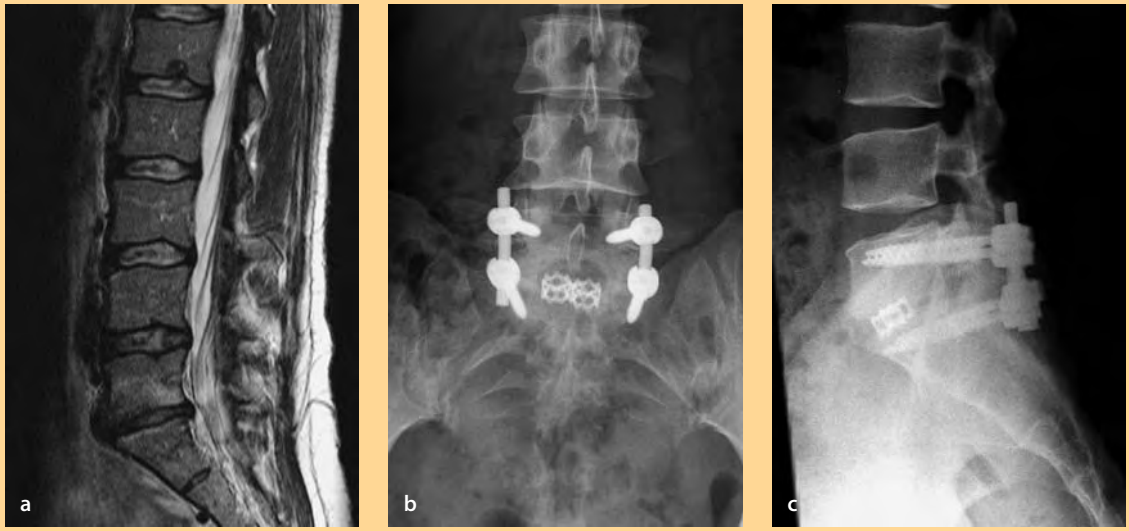


**Figure 5. Circumferential fusion**

a Young (28 years) female patient with endplate changes (Modic Type II) undergoing pedicle screw fixation L5/S1 and posterolateral fusion in combination with a cage augmented anterior lumbar interbody fusion. Postoperative b antero-posterior view and c lateral view.

the graft) requirements for spinal fusion were challenging (see Chapter 3) and resulted in a high failure rate [73, 189]. The problems associated with stand-alone cages led to the recommendation of the use of cages only in conjunction with spinal instrumentation (Fig. 5) [37, 45].

The outcome of stand-alone cages is not favorable

Although a **bilateral cage insertion** is generally recommended for biomechanical reasons, it is not always possible to insert two cages when the disc space is still high and the spinal canal rather narrow. Recently, it has been shown that **unilateral cage insertion** leads to comparable results to bilateral cage placements [82, 196]. The shortcomings of the PLIF technique (i.e. retraction of nerve roots and potential epidural fibrosis) led to a modified technique by a transforaminal route (**transforaminal lumbar interbody fusion, TLIF**). After unilateral resection of the facet joints, the disc is exposed and excised without retraction of the thecal sac and nerve roots before a cage is implanted. TLIF should only be used in conjunction with spinal instrumentations. The reported results with this technique are promising [105, 117, 123, 231, 235].

Unilateral cage insertion may suffice in selected cases

### *Circumferential Fusion*

Circumferential fusion (i.e. interbody and posterolateral fusion) was first used for the treatment of spinal trauma and deformity, then expanded to failed previous spinal fusion operations and is now used also as a primary procedure for chronic low-back pain [122]. Theoretically, this technique should increase the fusion rate by maximizing the stability within the motion segment and enhance outcome because of an elimination of potential pain sources in anterior and posterior spinal structures. Today, circumferential fusion is almost always done **in conjunction with instrumentation**. Interbody fusion can be done by a posterior (PLIF) (Fig. 4) or anterior approach (ALIF) (Figs. 5, 6) depending on the individual pathology and surgeons' preferences. There seems to be no difference between both approaches in terms of clinical outcome [178].

Outcome of PLIF and ALIF appears to be comparable

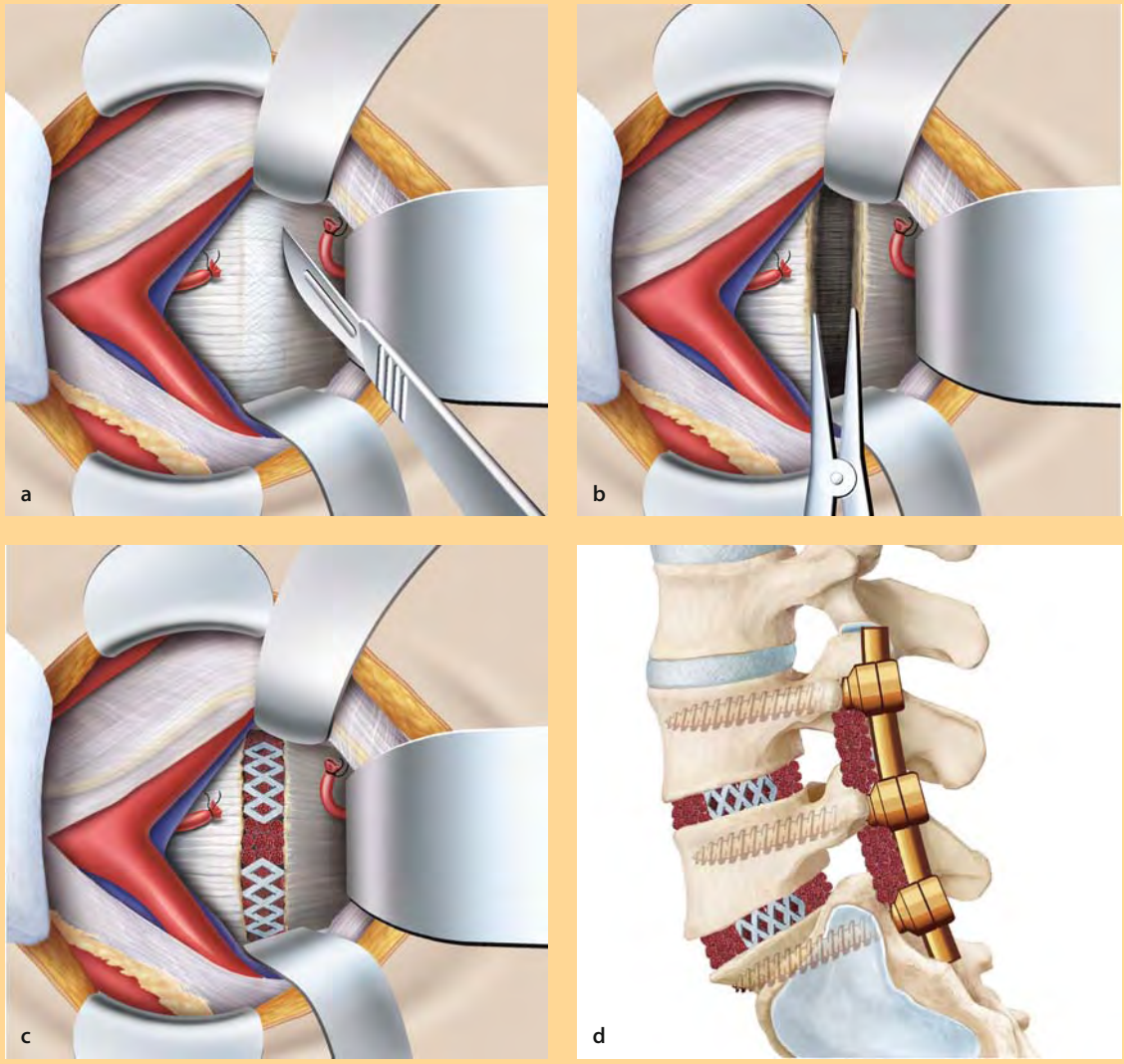


**Figure 6. Surgical technique of anterior lumbar interbody fusion**

The lumbosacral junction is exposed by a minimally invasive retroperitoneal approach. **a** The intervertebral disc is excised; **b** the endplates can be distracted with a spreader and the endplate cartilage is removed with curettes; **c** the disc space is filled with cancellous bone and supported with two cages. Ring-shaped cage design allows sufficient bone graft to be placed around the cages. **d** Pedicle screw fixation is added in conjunction with posterolateral fusion.

Combined interbody and posterolateral fusion has the highest fusion rate

Several studies have consistently demonstrated that circumferential fusion increases the rate of solid fusion [48, 91], with fusion rates ranging from 91 % to 99 % [48, 91, 242, 252]. However, it remains controversial whether circumferential fusion improves clinical outcome [91, 267]. Fritzell et al. [91] did not find a significant difference in outcome when comparing non-instrumented, instrumented posterolateral or circumferential fusion. On the contrary, Videbaek et al. [267] have demonstrated that patients undergoing circumferential fusion have a significantly better long term outcome compared to posterolateral fusion in terms of disability (Oswestry Disability Index) and physical health (SF-36). Some patients continue to have pain after posterolateral spinal fusion despite apparently solid arthrodesis. One potential etiology is pain that arises from a disc within the fused levels and has positive pain provocation on discography. These patients benefit from an ALIF [8].

### Minimally Invasive Approaches for Spinal Fusion

Access technology should decrease collateral muscle damage during fusion surgery

In the last two decades, attempts have been made to minimize approach-related morbidity [98, 154, 247]. Particularly, the posterior approach to the lumbosacral spine necessitates dissection and retraction of the paraspinal muscles. The muscle retraction was shown to cause a significant muscle injury dependent on the traction time [147–150]. The use of **translaminar screw fixation** in conjunction with an ALIF has been suggested to minimize posterior exposure of the lumbar spine [9, 137, 159, 191, 241] (Case Introduction). Newer posterior techniques use a tubular retractor system for pedicle screw insertion and percutaneous rod insertion that avoids the muscle stripping associated with open procedures [71, 83, 98].

**Laparoscopic techniques** for anterior interbody fusion were developed in the 1990s to minimize surgical injury related to the anterior approach [38, 170, 252, 281]. This technique was favored in conjunction with the use of cylindrical cages and may exhibit some immediate postoperative advantages (e.g. less blood loss, shorter postoperative ileus, earlier mobilization) [61, 78]. However, this technique did not prevail because of the tedious steep learning curve, longer operation time, expensive laparoscopic instruments and tools and need for a general surgeon familiar with laparoscopy without providing superior clinical results [50, 200, 281]. Many surgeons today prefer a **mini-open anterior approach** to the lumbar spine using a retraction frame (Case Introduction), which allows a one or two level anterior fusion to be performed through a short incision [2, 186]. It also allows for a rapid extension of the exposure in case of complications such as an injury to a large vessel.

Minimally invasive approaches have not yet demonstrated superior outcomes

Many initial reports have shown similar clinical results in terms of spinal fusion rates for both traditional open and minimally invasive posterior approaches [71, 84]. However, the anterior minimally invasive procedures are often associated with a significantly greater incidence of complications and technical difficulty than their associated open approaches [71].

### Fusion Related Problems

#### *Revision Surgery for Non-union*

Revision surgery for non-union remains costly and difficult. Diagnosis of non-union by radiological assessment is not easy and solid fusion determined from radiographs ranged from 52 % to 92 % depending on the choice of surgical procedure [47].

Functional and clinical results of lumbar fusion are often not in correlation

Similarly to a primary intervention, the single most important factor in achieving a successful clinical outcome is **patient selection** [75]. It is well anticipated that functional and clinical results of lumbar fusion are often not in correlation and the rate of non-union has no significant association with clinical results in the first place [81, 277], which challenges the clinical success of revision surgery for non-union.

The best lumbar fusion rates are achieved by a circumferential fusion

Interbody fusion is advocated to repair non-union because revision surgery by posterolateral fusion has not been overly successful [55, 75]. Circumferential fusion provides the highest fusion rate. It is therefore recommended to perform a 360-degree fusion during a revision operation [47]. However, patients with a non-union after stand-alone cage augmented fusion (PLIF or ALIF) may well benefit from a revision posterolateral fusion and pedicle screw fixation [45].

Despite successful fusion repair, clinical outcome is often disappointing

Although solid fusion after non-union can be achieved in 94–100 % of patients with appropriate techniques [36, 42, 99], there is only a poor correlation of the radiographic and clinical results [42]. After repair of pseudoarthrosis, Car-

penter et al. reported a solid fusion rate of 94% without significant association with clinical outcome, patient's age, obesity and gender [42]. Similar findings were made by Gertzbein et al. [99]. These authors reported a fusion rate of 100% even in the face of factors often placing patients at high risk for developing a pseudarthrosis, i.e. multiple levels of previous spinal surgery, including previous pseudarthrosis, and a habit of heavy smoking. However, the satisfactory outcome rate was only somewhat better than 50%, based on a lack of substantial pain improvement and return to work [99]. It is therefore mandatory to inform surgical candidates that the risk of an unsatisfactory outcome is high despite solid fusion.

#### *Adjacent Segment Degeneration*

Adjacent segment degeneration following lumbar spine fusion remains a well known problem, but there is insufficient knowledge regarding the risk factors that contribute to its occurrence [158]. Biomechanical and radiological investigations have demonstrated increased forces, mobility, and intradiscal pressure in adjacent segments after fusion [72]. Although it is hypothesized that these changes lead to an acceleration of degeneration, the natural history of the adjacent segment remains unaddressed [72]. When discussing the problem of **adjacent segment degeneration** it is important to:

- take the preoperative degeneration grade into account
- differentiate asymptomatic and symptomatic degeneration
- consider the natural history of the adjacent motion segment

Adjacent segment degeneration is a frequent problem

There is no significant correlation between the preoperative arthritic grade and the need for additional surgery [100]. Radiographic segmental degeneration weakly correlates with clinical symptoms [208] and the age of the individual [46, 104, 213]. There are conflicting results on the influence of the length of spinal fusion [46]. Pellise et al. [213] found that radiographic changes suggesting disc degeneration appear homogeneously at several levels cephalad to fusion and seem to be determined by individual characteristics. Ghiselli et al. [100] reported a rate of symptomatic degeneration at an adjacent segment warranting either decompression or arthrodesis to be 16.5% at 5 years and 36.1% at 10 years. It remains to be seen whether disc arthroplasty will alter the rate of adjacent segment degeneration [128].

### Motion Preserving Surgery

Motion preservation surgery is still emerging

With the advent of motion preserving surgical techniques, there is a great excitement among surgeons and patients that the drawbacks of spinal fusion can be overcome. So far, the initial results are equivalent to those obtained with spinal fusion and it is hoped that there is a decrease in the rate of adjacent segment degeneration. The success of the paradigm shift toward motion preservation is still unproven but it makes intuitive and biomechanical sense [6]. A review of the biomechanical background of motion preserving surgery is included in Chapter 3.

#### *Total Disc Arthroplasty*

Attempts to artificially replace the intervertebral discs were already made in the 1950s by **Fernstrom** [79]. However, the ball like intercorporal endoprosthesis was prone to failures (i.e. loosening and migration). The disc prosthesis with the longest history is the **SB-Charité prosthesis**, which dates back to 1982. The prosthesis was developed by Kurt Schellnack and Karin Büttner-Janz at the Charité Hos-

pital in Berlin. The prosthesis has meanwhile undergone several redesigns. The SB-Charité III disc prosthesis (Depuy Spine) was the first to receive FDA approval in 2004. In recent decades various alternative designs have been developed such as the ProDis-L (Synthes, FDA approval 2006), Maverick (MedtronicSofamorDanek), Flexicore (Stryker), Kineflex (SpinalMotion) and ActivL (B. Braun/Aesculap) total disc replacement systems.

**Indications and contraindications** for total disc arthroplasty (TDA) are (Table 7):

**Table 7.** Total disc arthroplasty

| Indications | Contraindications |
|---|---|
| • age 18–60 years<br>• severe back pain<br>• severe disability (ODI > 30–40)<br>• failed non-operative treatment for > 6 months<br>• single or two-level disc degeneration | • osteoporosis<br>• multilevel disc degeneration<br>• facet joint osteoarthritis<br>• spinal deformity or instability<br>• prior lumbar fusion<br>• obesity<br>• consuming illness (tumor, infection, inflammatory disorders)<br>• metabolic disorders<br>• known allergies |

Modified from Zigler et al. [283] and Guyer et al. [116]
*ODI* Oswestry Disability Index

German and Foley [97] have highlighted that particular attention should be paid to the presence of facet joint osteoarthritis, as this has been associated with poor clinical outcomes after arthroplasty [187, 262]. Total disc arthroplasty (Fig. 7) has meanwhile passed the level of technical feasibility and safety [11, 51, 168, 187]. However, major concerns remain regarding revision arthroplasty, which can cause life-threatening complications (e.g. in case of a major vessel injury during reoperation).

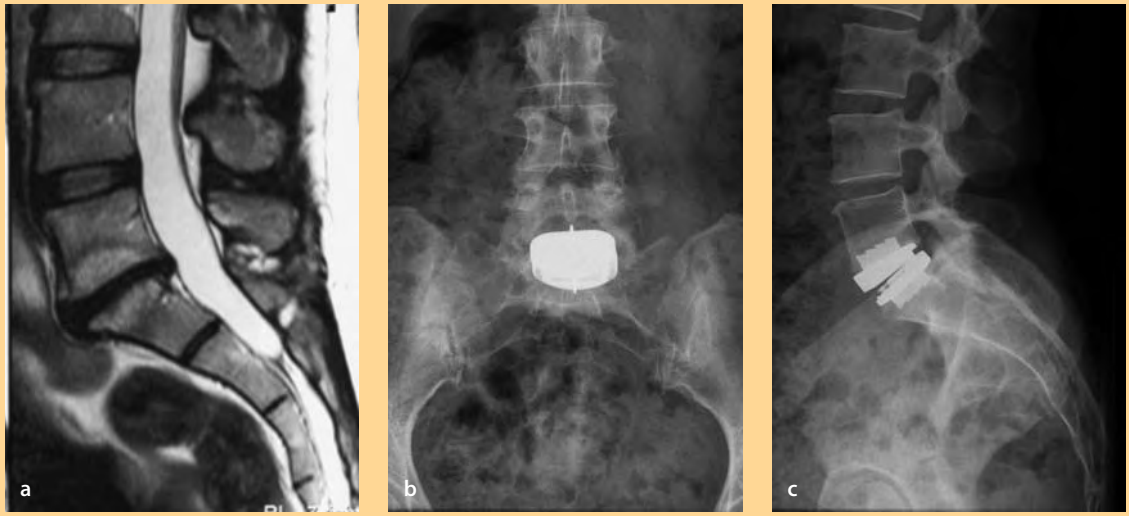


**Figure 7. Total disc arthoplasty**

Female patient (48 years) with endplate (Modic) changes at L5/S1 treated by total disc replacement with Prodisc (Synthes). a Sagittal T2 weighted MRI scan demonstrating Modic Type II changes at L5/S1. Postoperative b anteroposterior view; and c lateral view showing correct positioning of the TDA.

Two randomized controlled FDA IDE trials compared TDA with spinal fusion. In the first trial, the SB-Charité disc prosthesis was compared with stand-alone BAK cages with autograft from the iliac crest for one-level disc disease L4–S1 [12, 188]. The second trial compared the ProDisc-L total disc arthroplasty with circumferential spinal fusion for the treatment of discogenic pain at one vertebral level between L3 and S1 [282]. Both prospective, randomized, multicenter studies demonstrated that quantitative clinical outcome measures following TDA are at least equivalent to clinical outcomes with conventional fusion techniques.

Short-term clinical outcome of TDA is comparable to spinal fusion

Although these results are promising, only longer term follow-up will show whether TDA is superior to spinal fusion and reduce the rate of adjacent segment degeneration [97].

### *Dynamic Stabilization*

Abnormal loading patterns are a cause of pain

Mulholland [201] has hypothesized that abnormal patterns of loading rather than abnormal movement are the reason that disc degeneration causes back pain in some patients. **Abnormal load transmission** is the principal cause of pain in osteoarthritic joints. Both osteotomy and total joint replacement succeed because they alter the load transmission across the joint [201]. In this context, the spine is painful in positions and postures rather than on movement [201]. The rationale for dynamic or **"soft" stabilization** of a painful motion segment is to alter mechanical loading by unloading the disc but preserving lumbar motion in contrast to spinal fusion [205]. The **Graf ligamentoplasty** was the first dynamic stabilization system widely used in Europe [30, 96, 111]. The principle of the Graf system was to stabilize the spine in extension (locking the facet joints) using pedicle screws connected by a non-elastic band. This system increased the load over the posterior anulus, caused lateral recess and foraminal stenosis and was only modestly successful [201].

The dynamic stabilization system may alter abnormal loading and thus be effective

Best indications for dynamic stabilization are not well established

The **Dynesys system** is based on pedicle screws connected with a polyethylene cord and a polyurethane tube reducing movement both in flexion and extension [238, 249]. However, often it also unloads the disc to a degree that is unpredictable [201]. Non-randomized studies reported promising results [221, 249, 276]. However, Grob et al. [112] reported that only half of the patients declared that the operation had helped and had improved their overall quality of life, and less than half reported improvements in functional capacity. The reoperation rate after Dynesys was relatively high. Only long-term follow-up data and controlled prospective randomized studies will reveal whether dynamic stabilization is superior to spinal fusion for selected patients [238].

The clinical effectiveness of interspinous stabilization remains to be proven

Recently, **interspinous implants** have been introduced as minimally invasive dynamic spine stabilization systems, e.g. X-Stop (St. Francis Medical Technologies), Diam (Medtronic), and Wallis (SpineNext). The interspinous implants act to distract the spinous processes and restrict extension. This effect will reduce posterior anulus pressures and theoretically enlarge the neural foramen [49]. These implants are therefore predominantly used for degenerative disc disorders in conjunction with spinal stenosis [157, 251, 285]. Further case-control studies and RCTs still have to identify the appropriate indications and clinical efficacy.

## Comparison of Treatment Modalities

During the last decade, several high quality prospective randomized trials have elucidated the effect of conservative versus operative treatment on clinical outcome for lumbar degenerative disorders.

The **Swedish Lumbar Spine Study** [88–91] investigated whether lumbar fusion could reduce pain and diminish disability more effectively when compared with non-surgical treatment in patients with severe chronic low-back pain (CLBP). The surgical patients had a significantly higher rate of subjective favorable outcome and return to work rate compared to the non-surgical group.

Spinal fusion is superior to non-operative care at 2 years

However, no significant differences between fusion techniques were found among the groups in terms of subjective or objective clinical outcome [91]. The authors concluded from their studies that lumbar fusion in a well-informed and selected group of patients with severe CLBP can diminish pain and decrease disability more efficiently than commonly used non-surgical treatment and that there was no obvious disadvantage in using the least demanding surgical technique of posterolateral fusion without internal fixation [90, 91].

Surgical fusion techniques do not differ in outcome

The results of this study were analyzed in the context of cost-effectiveness. For both the society and the healthcare sectors, the 2-year costs for lumbar fusion were significantly higher compared with non-surgical treatment, but all treatment effects were significantly in favor of surgery [88]. Longer term follow-up, however, revealed that the benefits of surgery diminished over time (P. Fritzell, personal communication). Although this study was highly acclaimed for being the first of its kind, criticism arose with regard to the patient inclusion criteria (e.g. sick leave for at least 1 year) and the non-specified conservative treatment [103].

In a single blinded RCT from Norway [31, 151], the effectiveness of lumbar instrumented fusion was compared with **cognitive intervention and exercises** in patients with chronic low-back pain and disc degeneration. No significant differences were found in terms of subjective outcome or disability. Patients with chronic low-back pain who followed cognitive intervention and exercise programmes improved significantly in muscle strength compared with patients who underwent lumbar fusion [151]. The authors concluded that the main outcome measure showed equal improvement in patients with chronic low-back pain and disc degeneration randomized to cognitive intervention and exercises or lumbar fusion.

Cognitive behavioral treatment and exercises are key elements of non-operative care

The **MRC Spine Stabilization Trial** [77] assessed the clinical effectiveness of surgical stabilization (spinal fusion) compared with an intensive rehabilitation program (including cognitive behavioral treatment) for patients with chronic low-back pain. No clear evidence emerged that primary spinal fusion surgery was any more beneficial than intensive rehabilitation. The drawback of this study was that the surgical group was not well defined and a garden variety of treatment methods were applied. A cost-effectiveness analysis [227] revealed that surgical stabilization of the spine may not be a cost-effective use of scarce healthcare resources. However, sensitivity analyses show that this could change – for example, if the proportion of rehabilitation patients requiring subsequent surgery continues to increase.

Spinal fusion and intensive rehabilitation achieve similar results

The **practical implication** of these three high quality trials is that patients must be informed extensively about the current evidence in the literature prior to surgery. Presently, there is no substantial evidence that spinal fusion is superior to an intensive rehabilitation program including cognitive behavioral intervention.

Scientific evidence for the effectiveness of spinal fusion is limited

## Complications

The complication rate of surgical interventions for lumbar spondylosis is critically dependent on the extent of the intervention [253]. The reintervention rate ranges from 6% (non-instrumented fusion) to 17% (combined anterior/posterior fusion) [89]. However, the complication rate is also dependent on the surgi-

The surgeon skill factor remains widely unaddressed

cal skill of the individual surgeon, which is not well explored so far. The most frequent complications after spinal fusion for degenerative disc disease are:

- infection: 0 – 1.4 % [77, 89, 280]
- non-union: 7 – 55 % [89, 280]
- de novo neurological deficits: 0 – 2.3 % [77, 253, 280]
- bone graft donor site pain: 15 – 39 % [234]

A detailed discussion of complications related to lumbar fusion is included in Chapter 39.

## Recapitulation

**Epidemiology.** Lumbar spondylosis refers to a mixed group of pathologies related to the degeneration of the lumbar motion segment and associated pathologies or clinical syndromes of discogenic back pain, facet joint osteoarthritis (OA), and segmental instability. Morphological abnormalities in the lumbar spine are frequent in asymptomatic individuals. However, severe endplate alterations (**Modic changes**) and **advanced facet joint OA** are rare in young healthy subjects. Specific low-back pain (LBP) due to lumbar spondylosis is infrequent. The natural history of lumbar spondylosis is benign and self-limiting.

**Pathogenesis.** Disc degeneration may lead to the expression of **proinflammatory cytokines**, which are assumed to be responsible for the generation of discogenic LBP. Facet joint degeneration resembles the clinical pathology of **osteoarthritis**. The orientation of the facet joint appears to play a role in premature degeneration. A **wide range of segmental motion** can be found in asymptomatic individuals. It appears that the **kinematics of the motion** is affected by the instability and not so much the range of motion. Objective criteria for the definition of segmental instability are lacking and the diagnosis therefore remains enigmatic.

**Clinical presentation.** The clinical findings for a symptomatic lumbar spondylosis are few. Patients with **discogenic back pain** often complain of pain aggravation during sitting and forward bending. Pain can increase during the night and can radiate into the anterior thigh. A **facet joint syndrome** causes stiffness as well as pain on backward bending and rotation. In the early stages, pain often improves during motion and exhibits a "walk in" period. The pain sometimes radiates into the buttocks and posterior thigh. A **clinical instability syndrome** causes mechanical LBP, which aggravates during motion and disappears with rest.

**Diagnostic work-up.** The imaging modality of choice is **MRI**, which is sensitive but less specific in identifying the sources of back pain. Standard radiographs are helpful in identifying lumbar-sacral transitional anomalies. **Functional views** do not allow the diagnosis of segmental instability. **Computed tomography** is indicated in patients with contraindications for an MRI and for the assessment of the fusion status. **Injection studies** are indispensable for the identification of a morphological alteration as a source of back pain. Provocative discography remains the only diagnostic test for the diagnosis of discogenic back pain. It is recommended to always include an MR normal disc during discography as an internal control. The interpretation of pain relief subsequent to facet joint infiltrations is hampered by the multilevel innervation of the joints, and repeated injections are needed to improve diagnostic accuracy. Injection studies have to be interpreted with great care. The single most important factor for the choice of treatment is **patient selection**. The exclusion of risk flags is mandatory. Psychological, sociological and work-related factors have been shown to affect treatment outcome more than clinical and morphological findings.

**Non-operative treatments.** The **main objectives** of treatment are pain relief as well as improvement of quality of life (e.g. activities of daily living, recreational and social activities) and work capacity. The **mainstay of non-operative management** consists of pain management (medication), functional restoration (physical exercises), and cognitive-behavioural therapy (psychological intervention). Particularly the combination of functional treatment and cognitive behavioral intervention has been shown to be effective for degenerative lumbar spondylosis.

**Operative treatment.** **The paradigm of spinal fusion** is based on the experience that painful diar-

throdial joints or joint deformities can be successfully treated by arthrodesis. The selection for surgery should be timely and based on the identification of structural abnormalities which can be well addressed with surgery. **Favorable indications** for surgery include severe structural alterations: short duration of persistent symptoms (< 6 months), one- or two-level disease, absence of risk factor flags, clinical symptoms concordant with the structural correlate, highly motivated patient, positive pain provocation and/or pain relief tests.

Understanding the **biology of spinal fusion** is necessary to select the appropriate fusion technique. Blood supply to the spinal fusion area and the properties of the bone graft (or substitutes) is important for the maturation of the fusion mass. The optimal graft material for fusion should be **osteogenetic, osteoconductive and osteoinductive**. Autologous bone possesses all three properties and remains the gold standard. **Allografts** (e.g. femoral ring) are used to support the anterior column and have some biologic advantages compared to cages but carry the risk of transmission of infection. **Calcium phosphates** only have osteoconductive properties and are of limited effectiveness. **Demineralized bone matrix** predominately has a role as a bone graft extender. **Bone morphogenetic proteins** promote spinal fusion but their cost effectiveness is so far not determined. **Posterolateral fusion** remains the fusion technique of choice for lumbar degenerative spondylosis. **Combined interbody and posterolateral fusion** yields the highest fusion rates. **Spinal instrumentation** increases the fusion rate but not equally the clinical outcome. **Cages** support the anterior column and are helpful to stabilize the anterior column and enhance fusion rates. **Minimally invasive fusion techniques** have not been shown to provide better outcome when compared to conventional techniques. Non-union and adjacent segment degenerations are frequent fusion related problems. The best fusion technique for a failed arthrodesis is an instrumented combined anterior/posterior fusion. The clinical results are often disappointing despite successful fusion repair. **Dynamic fixation systems** have so far not been shown to protect adjacent segments from premature degeneration. **Total disc arthroplasty** does not provide superior results compared to spinal fusion. Based on three high quality RCTs, there is **no scientific evidence that spinal fusion is superior to an intensive rehabilitation program** including cognitive behavioral intervention, particularly not at mid and long-term follow-up.

## Key Articles

**Stauffer RN, Coventry MB (1972) Posterolateral lumbar-spine fusion. Analysis of Mayo Clinic series. J Bone Joint Surg Am 54:1195 – 204**
Classic article on spinal fusion for back pain. The results of this early analysis have not been surpassed by many other studies which followed.

**Fritzell P, Hagg O, Wessberg P, Nordwall A (2001) 2001 Volvo Award Winner in Clinical Studies: Lumbar fusion versus nonsurgical treatment for chronic low back pain: a multicenter randomized controlled trial from the Swedish Lumbar Spine Study Group. Spine 26:2521 – 32**

**Fritzell P, Hagg O, Wessberg P, Nordwall A (2002) Chronic low back pain and fusion: a comparison of three surgical techniques: a prospective multicenter randomized study from the Swedish Lumbar Spine Study Group. Spine 27:1131 – 41**
The Swedish Lumbar Spine Study compared lumbar fusion with non-surgical treatment in patients with severe chronic low-back pain (CLBP). A total of 294 patients aged 25 – 65 years with CLBP for at least 2 years were randomized blindly into two major treatment groups, i.e. non-operative (different kinds of physical therapy) vs. operative (three different methods of spinal fusion). At the 2-year follow-up, back pain was significantly more reduced in the surgical group by 33 % compared with 7 % in the non-surgical group. Pain improved most during the first 6 months and then gradually deteriorated. The Oswestry Disability Index (ODI) was reduced by 25 % compared with 6 % among non-surgical patients. The surgical patients had a significantly higher rate (63 %) of a subjective favorable outcome ("much better" or "better") compared to the non-surgical group (29 %). The "net back to work rate" was significantly in favor of surgical treatment, or 36 % vs. 13 %. A detailed analysis of the 222 surgical patients after 2 years revealed that fusion rate was dependent on the fusion technique, i.e. non-instrumented posterolateral

fusion (72%), instrumented posterolateral fusion (87%) and instrumented combined anterior/posterior fusion (91%). All surgical techniques substantially decreased pain and disability, but no significant differences were found among the groups in terms of subjective or objective clinical outcome.

**Brox JI, Sorensen R, Friis A, Nygaard O, Indahl A, Keller A, Ingebrigtsen T, Eriksen HR, Holm I, Koller AK, Riise R, Reikeras O (2003) Randomized clinical trial of lumbar instrumented fusion and cognitive intervention and exercises in patients with chronic low back pain and disc degeneration. Spine 28:1913–21**

This single blinded RCT from Norway compared the effectiveness of lumbar instrumented fusion with cognitive intervention and exercises in patients with chronic low-back pain and disc degeneration. Sixty-four patients aged 25–60 years with low-back pain lasting longer than 1 year and evidence of disc degeneration L4–S1 were randomized to either lumbar fusion with posterior transpedicular screws and postoperative physiotherapy, or cognitive intervention and exercises. At the 1-year follow-up (97%), the ODI was significantly reduced in both groups but the group difference did not achieve statistical significance. Improvements in back pain, use of analgesics, emotional distress, life satisfaction, and return to work were not different. Fear-avoidance beliefs and fingertip-floor distance were reduced more after non-operative treatment, and lower limb pain was reduced more after surgery. The success rate was not significantly different between the two groups based on an independent observer assessment (i.e. 70% after surgery and 76% after cognitive intervention and exercises).

**Fairbank J, Frost H, Wilson-MacDonald J, Yu LM, Barker K, Collins R (2005) Randomised controlled trial to compare surgical stabilisation of the lumbar spine with an intensive rehabilitation programme for patients with chronic low back pain: the MRC spine stabilisation trial. BMJ 330:1233**

This RCT compared the clinical effectiveness of surgical stabilization (spinal fusion) with intensive rehabilitation program (including cognitive behavioral treatment) for patients with chronic low-back pain. In this UK multicenter randomized controlled trial, 349 patients aged 18–55 years with chronic low-back pain (>1 year) were randomized into a surgical group ($n=176$) and a rehabilitation group ($n=173$) and followed for 2 years (81%). The mean ODI changed favorably in both groups but with a slight but significant advantage for the surgical group. No significant differences between the treatment groups were observed in any of the other outcome measures. The authors concluded that the statistical difference between treatment groups in one of the two primary outcome measures was marginal and only just reached the predefined minimal clinical difference. No clear evidence emerged that primary spinal fusion surgery was any more beneficial than intensive rehabilitation.

**Christensen FB, Hansen ES, Eiskjaer SP, Hoy K, Helmig P, Neumann P, Niedermann B, Bunger CE (2002) Circumferential lumbar spinal fusion with Brantigan cage versus posterolateral fusion with titanium Cotrel-Dubousset instrumentation: a prospective, randomized clinical study of 146 patients. Spine 27:2674–83**

**Videbaek TS, Christensen FB, Soegaard R, Hansen ES, Hoy K, Helmig P, Niedermann B, Eiskjoer SP, Bunger CE (2006) Circumferential fusion improves outcome in comparison with instrumented posterolateral fusion: long-term results of a randomized clinical trial. Spine 31:2875–80**

This prospective randomized clinical study compared instrumented circumferential fusion (cage based ALIF and pedicle screw fixation) with instrumented posterolateral lumbar fusion. Both groups showed highly significant improvement in all four categories of life quality as well as in the back pain and leg pain index, as compared with preoperative status. There was a clear tendency toward better overall functional outcome for patients with the circumferential procedure, and this patient group also showed significantly less leg pain at the 1-year follow-up evaluation and less peak back pain at 2 years. The circumferential fusion patients showed a significantly higher posterolateral fusion rate (92%) than the posterolateral group (80%). The repeat operation rate including implant removal was significantly lower in the circumferential group (7%) than in the posterolateral group (22%). The superior result of the circumferential fusion group was preserved during a 5–9 years follow-up.

**Blumenthal S, McAfee PC, Guyer RD, Hochschuler SH, Geisler FH, Holt RT, Garcia R, Jr, Regan JJ, Ohnmeiss DD (2005) A prospective, randomized, multicenter Food and Drug**

**Administration investigational device exemptions study of lumbar total disc replacement with the CHARITE artificial disc versus lumbar fusion: part I: evaluation of clinical outcomes. Spine 30:1565 – 75**

**McAfee PC, Cunningham B, Holsapple G, Adams K, Blumenthal S, Guyer RD, Dmietriev A, Maxwell JH, Regan JJ, Isaza J (2005) A prospective, randomized, multicenter Food and Drug Administration investigational device exemption study of lumbar total disc replacement with the CHARITE artificial disc versus lumbar fusion: part II: evaluation of radiographic outcomes and correlation of surgical technique accuracy with clinical outcomes. Spine 30:1576 – 83**
Three hundred and four patients were enrolled in the study at 14 US centers, randomized in a 2:1 ratio (TDA vs. fusion) and followed for 24 months. Patients in both groups improved significantly following surgery. Patients in the Charité group had lower levels of disability at every time interval from 6 weeks to 24 months, compared with the control group, with statistically lower pain and disability scores at all but the 24-month follow-up. At the 24-month follow-up, a significantly greater percentage of patients in the Charité group expressed satisfaction with their treatment and would have had the same treatment again, compared with the fusion group. The hospital stay was significantly shorter in the Charité artificial disc group. The complication rate was similar between both groups. Preoperative range of motion in flexion/extension was restored and maintained in patients receiving a TDA. Clinical outcomes and flexion/extension ROM correlated with surgical technical accuracy of Charité artificial disc placement.

**Zigler J, Delamarter R, Spivak JM, Linovitz RJ, Danielson GO, 3rd, Haider TT, Cammisa F, Zuchermann J, Balderston R, Kitchel S, Foley K, Watkins R, Bradford D, Yue J, Yuan H, Herkowitz H, Geiger D, Bendo J, Peppers T, Sachs B, Girardi F, Kropf M, Goldstein J (2007) Results of the prospective, randomized, multicenter Food and Drug Administration investigational device exemption study of the ProDisc-L total disc replacement versus circumferential fusion for the treatment of 1-level degenerative disc disease. Spine 32:1155 – 62**
Two hundred and eighty-six patients were included in the trial and followed for 24 months. The safety of ProDisc-L implantation was demonstrated with 0 % major complications. At 24 months, 91.8 % of investigational and 84.5 % of control patients reported improvement in the Oswestry Disability Index (ODI) from preoperative levels, and 77.2 % of investigational and 64.8 % of control patients met the improvement target of more than 15 % (ODI). At the 6 weeks and 3 months follow-up time points, the ProDisc-L patients recorded SF-36 Health Survey scores significantly higher than the control group. The visual analog scale pain assessment showed statistically significant improvement from preoperative levels regardless of treatment. Visual analog scale patient satisfaction at 24 months showed a statistically significant difference favoring investigational patients over the control group. Radiographic range of motion was maintained within a normal functional range in 93.7 % of investigational patients and averaged 7.7 degrees. From this trial it was concluded that ProDisc-L implantation is safe, efficacious and in properly chosen patients superior to circumferential fusion.

**Gibson JN, Grant IC, Waddell G (1999) The Cochrane review of surgery for lumbar disc prolapse and degenerative lumbar spondylosis. Spine 24:1820 – 32**

**Gibson JN, Waddell G (2005) Surgery for degenerative lumbar spondylosis: updated Cochrane Review. Spine 30:2312 – 20**
A must read evidence-based analysis of RCTs for degenerative lumbar spondylosis.

## References


1. Aebi M, Etter C, Kehl T, Thalgott J (1988) The internal skeletal fixation system. A new treatment of thoracolumbar fractures and other spinal disorders. Clin Orthop 227:30 – 43
2. Aebi M, Steffen T (2000) Synframe: a preliminary report. Eur Spine J 9 Suppl 1:S44 – 50
3. Albee FH (1911) Transplantation of a portion of the tibia into the spine for Pott's disease. A preliminary report. JAMA 57:885 – 886
4. Albrektsson T, Johansson C (2001) Osteoinduction, osteoconduction and osseointegration. Eur Spine J 10 Suppl 2:S96 – 101
5. An HS, Phillips FM (2005) Editorial: are spine biologics the future in spinal surgery? Spine J 5:207S–208S

6. Andersson GB, Burkus JK, Foley KT, Haid RW, Nockels RP, Polly DW, Jr, Sonntag VK, Traynelis VC, Weinstein JN (2005) Summary statement: treatment of the painful motion segment. Spine 30:S1
7. Bachmeier BE, Nerlich AG, Weiler C, Paesold G, Jochum M, Boos N (2007) Analysis of tissue distribution of TNF-alpha, TNF-alpha-receptors, and the activating TNF-alpha-converting enzyme suggests activation of the TNF-alpha system in the aging intervertebral disc. Ann N Y Acad Sci 1096:44 – 54
8. Barrick WT, Schofferman JA, Reynolds JB, Goldthwaite ND, McKeehen M, Keaney D, White AH (2000) Anterior lumbar fusion improves discogenic pain at levels of prior posterolateral fusion. Spine 25:853 – 7
9. Beaubien BP, Mehbod AA, Kallemeier PM, Lew WD, Buttermann GR, Transfeldt EE, Wood KB (2004) Posterior augmentation of an anterior lumbar interbody fusion: minimally invasive fixation versus pedicle screws in vitro. Spine 29:E406 – 12
10. Bednar DA (2001) Failure of external spinal skeletal fixation to improve predictability of lumbar arthrodesis. J Bone Joint Surg Am 83A:1656 – 9
11. Bertagnoli R, Kumar S (2002) Indications for full prosthetic disc arthroplasty: a correlation of clinical outcome against a variety of indications. Eur Spine J 11 Suppl 2:S131 – 6
12. Blumenthal S, McAfee PC, Guyer RD, Hochschuler SH, Geisler FH, Holt RT, Garcia R, Jr, Regan JJ, Ohnmeiss DD (2005) A prospective, randomized, multicenter Food and Drug Administration investigational device exemptions study of lumbar total disc replacement with the CHARITE artificial disc versus lumbar fusion: part I: evaluation of clinical outcomes. Spine 30:1565 – 75; discussion E387 – 91
13. Boden SD (2002) Overview of the biology of lumbar spine fusion and principles for selecting a bone graft substitute. Spine 27:S26 – 31
14. Boden SD, Davis DO, Dina TS, Patronas NJ, Wiesel SW (1990) Abnormal magnetic-resonance scans of the lumbar spine in asymptomatic subjects. A prospective investigation. J Bone Joint Surg Am 72:403 – 8
15. Boden SD, Kang J, Sandhu H, Heller JG (2002) Use of recombinant human bone morphogenetic protein-2 to achieve posterolateral lumbar spine fusion in humans: a prospective, randomized clinical pilot trial: 2002 Volvo Award in clinical studies. Spine 27:2662 – 73
16. Boden SD, Schimandle JH, Hutton WC, Chen MI (1995) 1995 Volvo Award in basic sciences. The use of an osteoinductive growth factor for lumbar spinal fusion. Part I: Biology of spinal fusion. Spine 20:2626 – 32
17. Boden SD, Wiesel SW (1990) Lumbosacral segmental motion in normal individuals. Have we been measuring instability properly? Spine 15:571 – 576
18. Bogduk N (1983) The innervation of the lumbar spine. Spine 8:286 – 93
19. Bogduk N, Tynan W, Wilson AS (1981) The nerve supply to the human lumbar intervertebral discs. J Anat 132:39 – 56
20. Bohner M (2001) Physical and chemical aspects of calcium phosphates used in spinal surgery. Eur Spine J 10 Suppl 2:S114 – 21
21. Boos N, Kalberer F, Schoeb O (2001) Retroperitoneal endoscopically assisted minilaparotomy for anterior lumbar interbody fusion: technical feasibility and complications. Spine 26:E1
22. Boos N, Lander PH (1996) Clinical efficacy of imaging modalities in the diagnosis of low-back pain disorders. Eur Spine J 5:2 – 22
23. Boos N, Rieder R, Schade V, Spratt KF, Semmer N, Aebi M (1995) 1995 Volvo Award in clinical sciences. The diagnostic accuracy of magnetic resonance imaging, work perception, and psychosocial factors in identifying symptomatic disc herniations. Spine 20:2613 – 25
24. Boos N, Webb JK (1997) Pedicle screw fixation in spinal disorders: a European view. Eur Spine J 6:2 – 18
25. Boos N, Weissbach S, Rohrbach H, Weiler C, Spratt KF, Nerlich AG (2002) Classification of age-related changes in lumbar intervertebral discs: 2002 Volvo Award in basic science. Spine 27:2631 – 44
26. Boucher HH (1959) A method of spinal fusion. J Bone Joint Surg Br 41B:248 – 59
27. Brantigan JW, Neidre A, Toohey JS (2004) The Lumbar I/F Cage for posterior lumbar interbody fusion with the variable screw placement system: 10-year results of a Food and Drug Administration clinical trial. Spine J 4:681 – 8
28. Brantigan JW, Steffee AD (1993) A carbon fiber implant to aid interbody lumbar fusion. Two-year clinical results in the first 26 patients. Spine 18:2106 – 7
29. Brau SA (2002) Mini-open approach to the spine for anterior lumbar interbody fusion: description of the procedure, results and complications. Spine J 2:216 – 23
30. Brechbuhler D, Markwalder TM, Braun M (1998) Surgical results after soft system stabilization of the lumbar spine in degenerative disc disease – long-term results. Acta Neurochir (Wien) 140:521 – 5
31. Brox JI, Sorensen R, Friis A, Nygaard O, Indahl A, Keller A, Ingebrigtsen T, Eriksen HR, Holm I, Koller AK, Riise R, Reikeras O (2003) Randomized clinical trial of lumbar instrumented fusion and cognitive intervention and exercises in patients with chronic low back pain and disc degeneration. Spine 28:1913 – 21

32. Burke JG, RW GW, Conhyea D, McCormack D, Dowling FE, Walsh MG, Fitzpatrick JM (2003) Human nucleus pulposis can respond to a pro-inflammatory stimulus. Spine 28:2685 – 93
33. Burke JG, Watson RW, McCormack D, Dowling FE, Walsh MG, Fitzpatrick JM (2002) Intervertebral discs which cause low back pain secrete high levels of proinflammatory mediators. J Bone Joint Surg Br 84:196 – 201
34. Burkus JK (2005) Surgical treatment of the painful motion segment: matching technology with indications. Spine 30:S7 – 15
35. Butler D, Trafimow JH, Andersson GB, McNeill TW, Huckman MS (1990) Discs degenerate before facets. Spine 15:111 – 3.
36. Buttermann GR, Glazer PA, Hu SS, Bradford DS (1997) Revision of failed lumbar fusions. A comparison of anterior autograft and allograft. Spine 22:2748 – 55
37. Button G, Gupta M, Barrett C, Cammack P, Benson D (2005) Three- to six-year follow-up of stand-alone BAK cages implanted by a single surgeon. Spine J 5:155 – 60
38. Cammisa FP, Jr, Girardi FP, Antonacci A, Sandhu HS, Parvataneni HK (2001) Laparoscopic transperitoneal anterior lumbar interbody fusion with cylindrical threaded cortical allograft bone dowels. Orthopedics 24:235 – 9
39. Capener N (1932) Spondylolisthesis. Br J Surg 19:374 – 386
40. Carlisle E, Fischgrund JS (2005) Bone morphogenetic proteins for spinal fusion. Spine J 5:240S-249S
41. Carlsson CA, Nachemson AL (2000) Neurophysiology of back pain: current knowledge. In: Nachemson AL (ed) Neck and back pain. The scientific evidence of causes, diagnosis and treatment. Lippincott Williams & Wilkins, Philadelphia, pp 149 – 163
42. Carpenter CT, Dietz JW, Leung KY, Hanscom DA, Wagner TA (1996) Repair of a pseudarthrosis of the lumbar spine. A functional outcome study. J Bone Joint Surg Am 78:712 – 20
43. Carragee EJ, Alamin TF (2001) Discography. a review. Spine J 1:364 – 72
44. Carragee EJ, Tanner CM, Yang B, Brito JL, Truong T (1999) False-positive findings on lumbar discography. Reliability of subjective concordance assessment during provocative disc injection. Spine 24:2542 – 7
45. Cassinelli EH, Wallach C, Hanscom B, Vogt M, Kang JD (2006) Prospective clinical outcomes of revision fusion surgery in patients with pseudarthrosis after posterior lumbar interbody fusions using stand-alone metallic cages. Spine J 6:428 – 34
46. Cheh G, Bridwell KH, Lenke LG, Buchowski JM, Daubs MD, Kim Y, Baldus C (2007) Adjacent segment disease following lumbar/thoracolumbar fusion with pedicle screw instrumentation: a minimum 5-year follow-up. Spine 32:2253 – 7
47. Christensen FB (2004) Lumbar spinal fusion. Outcome in relation to surgical methods, choice of implant and postoperative rehabilitation. Acta Orthop Scand Suppl 75:2 – 43
48. Christensen FB, Hansen ES, Eiskjaer SP, Hoy K, Helmig P, Neumann P, Niedermann B, Bunger CE (2002) Circumferential lumbar spinal fusion with Brantigan cage versus posterolateral fusion with titanium Cotrel-Dubousset instrumentation: a prospective, randomized clinical study of 146 patients. Spine 27:2674 – 83
49. Christie SD, Song JK, Fessler RG (2005) Dynamic interspinous process technology. Spine 30:S73 – 8
50. Chung SK, Lee SH, Lim SR, Kim DY, Jang JS, Nam KS, Lee HY (2003) Comparative study of laparoscopic L5-S1 fusion versus open mini-ALIF, with a minimum 2-year follow-up. Eur Spine J 12:613 – 7
51. Cinotti G, David T, Postacchini F (1996) Results of disc prosthesis after a minimum follow-up period of 2 years. Spine 21:995 – 1000
52. Cloward RB (1952) The treatment of ruptured lumbar intervertebral disc by vertebral body fusion. III. Method of use of banked bone. Ann Surg 136:987 – 92
53. Cloward RB (1981) Spondylolisthesis: treatment by laminectomy and posterior interbody fusion. Clin Orthop:74 – 82.
54. Cloward RB (1985) Posterior lumbar interbody fusion updated. Clin Orthop Relat Res:16 – 9
55. Cohen DB, Chotivichit A, Fujita T, Wong TH, Huckell CB, Sieber AN, Kostuik JP, Lawson HC (2000) Pseudarthrosis repair. Autogenous iliac crest versus femoral ring allograft. Clin Orthop Relat Res:46 – 55
56. Collis JS (1985) Total disc replacement: a modified posterior lumbar interbody fusion. Report of 750 cases. Clin Orthop 193:64 – 7
57. Coppes MH, Marani E, Thomeer RT, Groen GJ (1997) Innervation of "painful" lumbar discs. Spine 22:2342 – 9; discussion 2349 – 50
58. Coppes MH, Marani E, Thomeer RT, Oudega M, Groen GJ (1990) Innervation of annulus fibrosis in low back pain. Lancet 336:189 – 90
59. Cornell CN, Lane JM (1998) Current understanding of osteoconduction in bone regeneration. Clin Orthop Relat Res:S267 – 73
60. Cotrel Y, Dubousset J (1984) Nouvelle technique d'ostéosynthèse rachidienne segmentaire par voie postérieure. Rev Chir Orthop 70:489 – 494
61. Cowles RA, Taheri PA, Sweeney JF, Graziano GP (2000) Efficacy of the laparoscopic approach for anterior lumbar spinal fusion. Surgery 128:589 – 96

62. Delamarter RB, Fribourg DM, Kanim LE, Bae H (2003) ProDisc artificial total lumbar disc replacement: introduction and early results from the United States clinical trial. Spine 28:S167 – 75
63. Delawi D, Dhert WJ, Castelein RM, Verbout AJ, Oner FC (2007) The incidence of donor site pain after bone graft harvesting from the posterior iliac crest may be overestimated: a study on spine fracture patients. Spine 32:1865 – 8
64. Delloye C, Cornu O, Druez V, Barbier O (2007) Bone allografts: What they can offer and what they cannot. J Bone Joint Surg Br 89:574 – 9
65. Deutsch H, Haid R, Rodts G, Jr, Mummaneni PV (2007) The decision-making process: allograft versus autograft. Neurosurgery 60:S98 – 102
66. Deyo RA, Weinstein JN (2001) Low back pain. N Engl J Med 344:363 – 70
67. Dick W (1987) The "Fixateur Interne" as a versatile implant for spine surgery. Spine 12: 882 – 900
68. Dimar JR, Glassman SD, Burkus KJ, Carreon LY (2006) Clinical outcomes and fusion success at 2 years of single-level instrumented posterolateral fusions with recombinant human bone morphogenetic protein-2/compression resistant matrix versus iliac crest bone graft. Spine 31:2534 – 9; discussion 2540
69. Dreyfuss PH, Dreyer SJ, Heering SA (1995) Contemporary concept in spine care. Lumbar zygapophyseal (facet) joint injections. Spine 20:2040 – 2047
70. Dreyfuss PH, Dreyer SJ, Herring SA (1995) Lumbar zygapophysial (facet) joint injections. Spine 20:2040 – 7
71. Eck JC, Hodges S, Humphreys SC (2007) Minimally invasive lumbar spinal fusion. J Am Acad Orthop Surg 15:321 – 9
72. Eck JC, Humphreys SC, Hodges SD (1999) Adjacent-segment degeneration after lumbar fusion: a review of clinical, biomechanical, and radiologic studies. Am J Orthop 28:336 – 40
73. Elias WJ, Simmons NE, Kaptain GJ, Chadduck JB, Whitehill R (2000) Complications of posterior lumbar interbody fusion when using a titanium threaded cage device. J Neurosurg 93:45 – 52
74. Esses S, Botsford D, Kostuik J (1989) The role of external spinal skeletal fixation in the assessment of low-back disorders. Spine 14:594 – 601
75. Etminan M, Girardi FP, Khan SN, Cammisa FP, Jr (2002) Revision strategies for lumbar pseudarthrosis. Orthop Clin North Am 33:381 – 92
76. Faciszewski T, Winter RB, Lonstein JE, Denis F, Johnson L (1995) The surgical and medical perioperative complications of anterior spinal fusion surgery in the thoracic and lumbar spine in adults. A review of 1 223 procedures. Spine 20:1592 – 9
77. Fairbank J, Frost H, Wilson-MacDonald J, Yu LM, Barker K, Collins R (2005) Randomised controlled trial to compare surgical stabilisation of the lumbar spine with an intensive rehabilitation programme for patients with chronic low back pain: the MRC spine stabilisation trial. BMJ 330:1233
78. Farooq N, Grevitt MP (2004) "Does size matter?"A comparison of balloon-assisted less-invasive vs conventional retroperitoneal approach for anterior lumbar interbody fusion. Eur Spine J 13:639 – 44
79. Fernstrom U (1966) Arthroplasty with intercorporal endoprothesis in herniated disc and in painful disc. Acta Chir Scand Suppl 357:154 – 9
80. Fernyhough JC, Schimandle JJ, Weigel MC, Edwards CC, Levine AM (1992) Chronic donor site pain complicating bone graft harvesting from the posterior iliac crest for spinal fusion. Spine 17:1474 – 80
81. Flynn JC, Hoque MA (1979) Anterior fusion of the lumbar spine. End-result study with long-term follow-up. J Bone Joint Surg Am 61:1143 – 50
82. Fogel GR, Toohey JS, Neidre A, Brantigan JW (2007) Is one cage enough in posterior lumbar interbody fusion: a comparison of unilateral single cage interbody fusion to bilateral cages. J Spinal Disord Tech 20:60 – 5
83. Foley KT, Holly LT, Schwender JD (2003) Minimally invasive lumbar fusion. Spine 28:S26 – 35
84. Frantzides CT, Zeni TM, Phillips FM, Mathur S, Zografakis JG, Moore RM, Laguna LE (2006) L5-S1 laparoscopic anterior interbody fusion. JSLS 10:488 – 92
85. Freemont AJ, Jeziorska M, Hoyland JA, Rooney P, Kumar S (2002) Mast cells in the pathogenesis of chronic back pain: a hypothesis. J Pathol 197:281 – 5
86. Freemont AJ, Peacock TE, Goupille P, Hoyland JA, O'Brien J, Jayson MI (1997) Nerve ingrowth into diseased intervertebral disc in chronic back pain. Lancet 350:178 – 81
87. Freemont AJ, Watkins A, Le Maitre C, Baird P, Jeziorska M, Knight MT, Ross ER, O'Brien JP, Hoyland JA (2002) Nerve growth factor expression and innervation of the painful intervertebral disc. J Pathol 197:286 – 92
88. Fritzell P, Hagg O, Jonsson D, Nordwall A (2004) Cost-effectiveness of lumbar fusion and nonsurgical treatment for chronic low back pain in the Swedish Lumbar Spine Study: a multicenter, randomized, controlled trial from the Swedish Lumbar Spine Study Group. Spine 29:421 – 34; discussion Z3
89. Fritzell P, Hagg O, Nordwall A (2003) Complications in lumbar fusion surgery for chronic low back pain: comparison of three surgical techniques used in a prospective randomized study. A report from the Swedish Lumbar Spine Study Group. Eur Spine J 12:178 – 89

90. Fritzell P, Hagg O, Wessberg P, Nordwall A (2001) 2001 Volvo Award Winner in Clinical Studies: Lumbar fusion versus nonsurgical treatment for chronic low back pain: a multicenter randomized controlled trial from the Swedish Lumbar Spine Study Group. Spine 26: 2521 – 32; discussion 2532 – 4
91. Fritzell P, Hagg O, Wessberg P, Nordwall A (2002) Chronic low back pain and fusion: a comparison of three surgical techniques: a prospective multicenter randomized study from the Swedish lumbar spine study group. Spine 27:1131 – 41
92. Frost HM (1989) The biology of fracture healing. An overview for clinicians. Part I. Clin Orthop Relat Res:283 – 93
93. Frost HM (1989) The biology of fracture healing. An overview for clinicians. Part II. Clin Orthop Relat Res:294 – 309
94. Fujiwara A, Lim TH, An HS, Tanaka N, Jeon CH, Andersson GB, Haughton VM (2000) The effect of disc degeneration and facet joint osteoarthritis on the segmental flexibility of the lumbar spine. Spine 25:3036 – 44.
95. Fullenlove TM, Williams AJ (1957) Comparative roentgen findings in symptomatic and asymptomatic backs. JAMA 168:572 – 574
96. Gardner A, Pande KC (2002) Graf ligamentoplasty: a 7-year follow-up. Eur Spine J 11 Suppl 2:S157 – 63
97. German JW, Foley KT (2005) Disc arthroplasty in the management of the painful lumbar motion segment. Spine 30:S60 – 7
98. German JW, Foley KT (2005) Minimal access surgical techniques in the management of the painful lumbar motion segment. Spine 30:S52 – 9
99. Gertzbein SD, Hollopeter MR, Hall S (1998) Pseudarthrosis of the lumbar spine. Outcome after circumferential fusion. Spine 23:2352 – 6; discussion 2356 – 7
100. Ghiselli G, Wang JC, Bhatia NN, Hsu WK, Dawson EG (2004) Adjacent segment degeneration in the lumbar spine. J Bone Joint Surg Am 86-A:1497 – 503
101. Ghormley RK (1933) Low back pain. With special reference to the articular facets, with presentation of an operative procedure. JAMA 101:1773 – 1777
102. Gibson JN, Grant IC, Waddell G (1999) The Cochrane review of surgery for lumbar disc prolapse and degenerative lumbar spondylosis. Spine 24:1820 – 32
103. Gibson JN, Waddell G (2005) Surgery for degenerative lumbar spondylosis: updated Cochrane Review. Spine 30:2312 – 20
104. Gillet P (2003) The fate of the adjacent motion segments after lumbar fusion. J Spinal Disord Tech 16:338 – 45
105. Glassman S, Gornet MF, Branch C, Polly D, Jr, Peloza J, Schwender JD, Carreon L (2006) MOS short form 36 and Oswestry Disability Index outcomes in lumbar fusion: a multicenter experience. Spine J 6:21 – 6
106. Glassman SD, Dimar JR, 3rd, Burkus K, Hardacker JW, Pryor PW, Boden SD, Carreon LY (2007) The efficacy of rhBMP-2 for posterolateral lumbar fusion in smokers. Spine 32: 1693 – 8
107. Goldberg VM, Stevenson S (1993) The biology of bone grafts. Semin Arthroplasty 4:58 – 63
108. Goldthwaith JE (1911) The lumbo-sacral articulation: An explanation of many cases of lumbago, sciatica, and paraplegia. Boston Med Surg J 164:365 – 372
109. Gorbach C, Schmid M, Elfering E, Hodler J, Boos N (2006) Therapeutic efficacy of facet joint blocks. AJR Am J Roentgenol 186:1228 – 1233
110. Gotfried Y, Bradford D, Oegema T (1986) Facet joint changes after chemonucleolysis-induced disc space narrowing. Spine 11:944 – 950
111. Grevitt MP, Gardner AD, Spilsbury J, Shackleford IM, Baskerville R, Pursell LM, Hassaan A, Mulholland RC (1995) The Graf stabilisation system: early results in 50 patients. Eur Spine J 4:169 – 75; discussion 135
112. Grob D, Benini A, Junge A, Mannion AF (2005) Clinical experience with the Dynesys semirigid fixation system for the lumbar spine: surgical and patient-oriented outcome in 50 cases after an average of 2 years. Spine 30:324 – 31
113. Grob D, Humke T (1998) Translaminar screw fixation in the lumbar spine: technique, indications, results. Eur Spine J 7:178 – 86
114. Gronblad M, Weinstein JN, Santavirta S (1991) Immunohistochemical observations on spinal tissue innervation. A review of hypothetical mechanisms of back pain. Acta Orthop Scand 62:614 – 22
115. Gunzburg R, Szpalski M, Passuti N, Aebi M (2001) Biomaterials: the new frontiers in spine surgery. Eur Spine J 10 Suppl 2:S85
116. Guyer RD, McAfee PC, Hochschuler SH, Blumenthal SL, Fedder IL, Ohnmeiss DD, Cunningham BW (2004) Prospective randomized study of the Charite artificial disc: data from two investigational centers. Spine J 4:252S–259S
117. Hackenberg L, Halm H, Bullmann V, Vieth V, Schneider M, Liljenqvist U (2005) Transforaminal lumbar interbody fusion: a safe technique with satisfactory three to five year results. Eur Spine J 14:551 – 8
118. Hadlow SV, Fagan AB, Hillier TM, Fraser RD (1998) The Graf ligamentoplasty procedure. Comparison with posterolateral fusion in the management of low back pain. Spine 23: 1172 – 9

119. Haefeli M, Kalberer F, Saegesser D, Nerlich AG, Boos N, Paesold G (2006) The course of macroscopic degeneration in the human lumbar intervertebral disc. Spine 31:1522–31
120. Hahn F, Kissling R, Weishaupt D, Boos N (2006) The extremes of spinal motion: a kinematic study of a contortionist in an open-configuration magnetic resonance scanner: case report. Spine 31:E565–7
121. Hanley EN, Jr (1995) The indications for lumbar spinal fusion with and without instrumentation. Spine 20:143S–153S
122. Hanley EN, Jr, David SM (1999) Lumbar arthrodesis for the treatment of back pain. J Bone Joint Surg Am 81:716–30
123. Harris BM, Hilibrand AS, Savas PE, Pellegrino A, Vaccaro AR, Siegler S, Albert TJ (2004) Transforaminal lumbar interbody fusion: the effect of various instrumentation techniques on the flexibility of the lumbar spine. Spine 29:E65–70
124. Hayes MA, Howard TC, Gruel CR, Kopta JA (1989) Roentgenographic evaluation of lumbar spine flexion-extension in asymptomatic individuals. Spine 14:327–331
125. Heary RF, Schlenk RP, Sacchieri TA, Barone D, Brotea C (2002) Persistent iliac crest donor site pain: independent outcome assessment. Neurosurgery 50:510–6; discussion 516–7
126. Heggeness MH, Esses SI (1991) Translaminar facet joint screw fixation for lumbar and lumbosacral fusion. A clinical and biomechanical study. Spine 16:S266–9
127. Hibbs R (1911) An operation for progressive spinal deformities. N Y Med J 93:1013–1016
128. Hilibrand AS, Robbins M (2004) Adjacent segment degeneration and adjacent segment disease: the consequences of spinal fusion? Spine J 4:190S–194S
129. Humke T, Grob D, Dvorak J, Messikommer A (1998) Translaminar screw fixation of the lumbar and lumbosacral spine. A 5-year follow-up. Spine 23:1180–4
130. Hutter CG (1983) Posterior intervertebral body fusion. A 25-year study. Clin Orthop: 86–96
131. Hutter CG (1985) Spinal stenosis and posterior lumbar interbody fusion. Clin Orthop 193:103–114
132. Igarashi A, Kikuchi S, Konno S, Olmarker K (2004) Inflammatory cytokines released from the facet joint tissue in degenerative lumbar spinal disorders. Spine 29:2091–5
133. Indahl A, Velund L, Reikeraas O (1995) Good prognosis for low back pain when left untampered. A randomized clinical trial. Spine 20:473–7
134. Jackson RP (1992) The facet syndrome. Myth or reality? Clin Orthop 279:110–121
135. Jackson RP, Jacobs RR, Montesano PX (1988) 1988 Volvo Award in Clinical Sciences. Facet joint injection in low-back pain. A prospective statistical study. Spine 13:966–971
136. Jacobs R, Montesano P, Jackson R (1989) Enhancement of lumbar spine fusion by use of translaminar facet joint screws. Spine 14:12–15
137. Jang JS, Lee SH (2005) Clinical analysis of percutaneous facet screw fixation after anterior lumbar interbody fusion. J Neurosurg Spine 3:40–6
138. Jaslow IA (1946) Intercoporal bone graft in spinal fusion after disc removal. Surg Gynec Obstet 82:215–218
139. Jenis LG, Wheeler D, Parazin SJ, Connolly RJ (2002) The effect of osteogenic protein-1 in instrumented and noninstrumented posterolateral fusion in rabbits. Spine J 2:173–8
140. Jensen MC, Brant-Zawadzki MN, Obuchowski N, Modic MT, Malkasian D, Ross JS (1994) Magnetic resonance imaging of the lumbar spine in people without back pain. N Engl J Med 331:69–73
141. Johnson WE, Evans H, Menage J, Eisenstein SM, El Haj A, Roberts S (2001) Immunohistochemical detection of Schwann cells in innervated and vascularized human intervertebral discs. Spine 26:2550–7
142. Johnsson R, Stromqvist B, Aspenberg P (2002) Randomized radiostereometric study comparing osteogenic protein-1 (BMP-7) and autograft bone in human noninstrumented posterolateral lumbar fusion: 2002 Volvo Award in clinical studies. Spine 27:2654–61
143. Kaigle AM, Holm SH, Hansson TH (1997) 1997 Volvo Award winner in biomechanical studies. Kinematic behavior of the porcine lumbar spine: a chronic lesion model. Spine 22:2796–806.
144. Kanayama M, Hashimoto T, Shigenobu K, Togawa D, Oha F (2007) A minimum 10-year follow-up of posterior dynamic stabilization using Graf artificial ligament. Spine 32:1992–6; discussion 1997
145. Kanayama M, Hashimoto T, Shigenobu K, Yamane S, Bauer TW, Togawa D (2006) A prospective randomized study of posterolateral lumbar fusion using osteogenic protein-1 (OP-1) versus local autograft with ceramic bone substitute: emphasis of surgical exploration and histologic assessment. Spine 31:1067–74
146. Kang JD, Stefanovic-Racic M, McIntyre LA, Georgescu HI, Evans CH (1997) Toward a biochemical understanding of human intervertebral disc degeneration and herniation. Contributions of nitric oxide, interleukins, prostaglandin E2, and matrix metalloproteinases. Spine 22:1065–73
147. Kawaguchi Y, Matsui H, Gejo R, Tsuji H (1998) Preventive measures of back muscle injury after posterior lumbar spine surgery in rats. Spine 23:2282–7; discussion 2288

148. Kawaguchi Y, Matsui H, Tsuji H (1994) Back muscle injury after posterior lumbar spine surgery. Part 1: Histologic and histochemical analyses in rats. Spine 19:2590 – 7
149. Kawaguchi Y, Matsui H, Tsuji H (1994) Back muscle injury after posterior lumbar spine surgery. Part 2: Histologic and histochemical analyses in humans. Spine 19:2598 – 602
150. Kawaguchi Y, Matsui H, Tsuji H (1996) Back muscle injury after posterior lumbar spine surgery. A histologic and enzymatic analysis. Spine 21:941 – 4
151. Keller A, Brox JI, Gunderson R, Holm I, Friis A, Reikeras O (2004) Trunk muscle strength, cross-sectional area, and density in patients with chronic low back pain randomized to lumbar fusion or cognitive intervention and exercises. Spine 29:3 – 8
152. Khan SN, Cammisa FP, Jr, Sandhu HS, Diwan AD, Girardi FP, Lane JM (2005) The biology of bone grafting. J Am Acad Orthop Surg 13:77 – 86
153. Kim KA, McDonald M, Pik JH, Khoueir P, Wang MY (2007) Dynamic intraspinous spacer technology for posterior stabilization: case-control study on the safety, sagittal angulation, and pain outcome at 1-year follow-up evaluation. Neurosurg Focus 22:E7
154. Kim KT, Lee SH, Suk KS, Bae SC (2006) The quantitative analysis of tissue injury markers after mini-open lumbar fusion. Spine 31:712 – 6
155. Kirkaldy-Willis WH, Farfan HF (1982) Instability of the lumbar spine. Clin Orthop Relat Res:110 – 23
156. Kirkaldy-Willis WH, Wedge JH, Yong-Hing K, Reilly J (1978) Pathology and pathogenesis of lumbar spondylosis and stenosis. Spine 3:319 – 28
157. Kondrashov DG, Hannibal M, Hsu KY, Zucherman JF (2006) Interspinous process decompression with the X-STOP device for lumbar spinal stenosis: a 4-year follow-up study. J Spinal Disord Tech 19:323 – 7
158. Kumar MN, Baklanov A, Chopin D (2001) Correlation between sagittal plane changes and adjacent segment degeneration following lumbar spine fusion. Eur Spine J 10:314 – 9
159. Kumar N, Wild A, Webb JK, Aebi M (2000) Hybrid computer-guided and minimally open surgery: anterior lumbar interbody fusion and translaminar screw fixation. Eur Spine J 9 Suppl 1:S71 – 7
160. Kuslich SD, Danielson G, Dowdle JD, Sherman J, Fredrickson B, Yuan H, Griffith SL (2000) Four-year follow-up results of lumbar spine arthrodesis using the Bagby and Kuslich lumbar fusion cage. Spine 25:2656 – 62
161. Kuslich SD, Ulstrom CL, Griffith SL, Ahern JW, Dowdle JD (1998) The Bagby and Kuslich method of lumbar interbody fusion. History, techniques, and 2-year follow-up results of a United States prospective, multicenter trial. Spine 23:1267 – 78; discussion 1279
162. Kwon B, Jenis LG (2005) Carrier materials for spinal fusion. Spine J 5:224S–230S
163. Lane JD, Moore ES (1948) Transperitoneal approach to the intervertebral disc in the lumbar area. Ann Surg 127:537 – 551
164. Laurencin C, Khan Y, El-Amin SF (2006) Bone graft substitutes. Expert Rev Med Devices 3:49 – 57
165. Lee CK, Vessa P, Lee JK (1995) Chronic disabling low back pain syndrome caused by internal disc derangements. The results of disc excision and posterior lumbar interbody fusion. Spine 20:356 – 61
166. Lee KJ, Roper JG, Wang JC (2005) Demineralized bone matrix and spinal arthrodesis. Spine J 5:217S–223S
167. Lekovic GP, Han PP, Kenny KJ, Dickman CA (2007) Bone dowels in anterior lumbar interbody fusion. J Spinal Disord Tech 20:374 – 9
168. Lemaire JP, Skalli W, Lavaste F, Templier A, Mendes F, Diop A, Sauty V, Laloux E (1997) Intervertebral disc prosthesis. Results and prospects for the year 2000. Clin Orthop Relat Res:64 – 76
169. Leonardi M, Pfirrmann CW, Boos N (2006) Injection studies in spinal disorders. Clin Orthop Relat Res 443:168 – 82
170. Lieberman IH, Willsher PC, Litwin DE, Salo PT, Kraetschmer BG (2000) Transperitoneal laparoscopic exposure for lumbar interbody fusion. Spine 25:509 – 14; discussion 515
171. Lin PM (1985) Posterior lumbar interbody fusion technique: complications and pitfalls. Clin Orthop Relat Res:90 – 102
172. Lindblom K (1948) Diagnostic puncture of intervertebral disks in sciatica. Acta Orthop Scand 17:231 – 239
173. Lippitt AB (1984) The facet joint and its role in spine pain. Management with facet joint injections. Spine 9:746 – 50
174. Louis R (1986) Fusion of the lumbar and sacral spine by internal fixation with screw plates. Clin Orthop 203:18 – 33
175. Louis R, Maresca C (1976) Les arthrodèse stables de la charnière lombo-sacrée (70 cas). Rev Chir Orthop (Suppl II) 62:70
176. Macnab I, Dall D (1971) The blood supply of the lumbar spine and its application to the technique of intertransverse lumbar fusion. J Bone Joint Surg 53B:628
177. Madan S, Gundanna M, Harley JM, Boeree NR, Sampson M (2002) Does provocative discography screening of discogenic back pain improve surgical outcome? J Spinal Disord Tech 15:245 – 51

178. Madan SS, Boeree NR (2003) Comparison of instrumented anterior interbody fusion with instrumented circumferential lumbar fusion. Eur Spine J 12:567 – 75
179. Magerl F (1982) External skeletal fixation of the lower thoracic and the lumbar spine. In: Uhthoff H (ed) Current concepts of external fixation of fractures. Springer-Verlag, Berlin, pp 353 – 366
180. Magerl FP (1984) Stabilization of the lower thoracic and lumbar spine with external skeletal fixation. Clin Orthop Relat Res:125 – 41
181. Magora A, Schwartz A (1976) Relation between the low back pain syndrome and x-ray findings. I. Degenerative osteoarthritis. Scand J Rehab Med 8:115 – 125
182. Malinsky J (1959) The ontogenetic development of nerve terminations in the intervertebral discs of man. (Histology of intervertebral discs, 11th communication). Acta Anat (Basel) 38:96 – 113
183. Mannion AF, Elfering A (2006) Predictors of surgical outcome and their assessment. Eur Spine J 15 Suppl 1:S93 – 108
184. Marchesi DG, Boos N, Zuber K, Aebi M (1992) Translaminar facet joint screws to enhance segmental fusion of the lumbar spine. Eur Spine J 1:125 – 130
185. Marks RC, Houston T, Thulbourne T (1992) Facet joint injection and facet nerve block: a randomised comparison in 86 patients with chronic low back pain. Pain 49:325 – 8
186. Mayer HM, Wiechert K (2002) Microsurgical anterior approaches to the lumbar spine for interbody fusion and total disc replacement. Neurosurgery 51:S159 – 65
187. Mayer HM, Wiechert K, Korge A, Qose I (2002) Minimally invasive total disc replacement: surgical technique and preliminary clinical results. Eur Spine J 11 Suppl 2:S124 – 30
188. McAfee PC, Cunningham B, Holsapple G, Adams K, Blumenthal S, Guyer RD, Dmietriev A, Maxwell JH, Regan JJ, Isaza J (2005) A prospective, randomized, multicenter Food and Drug Administration investigational device exemption study of lumbar total disc replacement with the CHARITE artificial disc versus lumbar fusion: part II: evaluation of radiographic outcomes and correlation of surgical technique accuracy with clinical outcomes. Spine 30:1576 – 83; discussion E388 – 90
189. McAfee PC, Cunningham BW, Lee GA, Orbegoso CM, Haggerty CJ, Fedder IL, Griffith SL (1999) Revision strategies for salvaging or improving failed cylindrical cages. Spine 24:2147 – 53
190. McAfee PC, Fedder IL, Saiedy S, Shucosky EM, Cunningham BW (2003) SB Charite disc replacement: report of 60 prospective randomized cases in a US center. J Spinal Disord Tech 16:424 – 33
191. McKenna PJ, Freeman BJ, Mulholland RC, Grevitt MP, Webb JK, Mehdian SH (2005) A prospective, randomised controlled trial of femoral ring allograft versus a titanium cage in circumferential lumbar spinal fusion with minimum 2-year clinical results. Eur Spine J 14:727 – 37
192. Milgram JW (1990) Intervertebral disc disease and degenerative arthritis of the spine. In: Milgram JW (ed) Radiologic and histologic pathology of nontumorous diseases of bones and joints. Northbrook Publishing Company, Northbrook, pp 519 – 588
193. Miller JAA, Schmatz C, Schultz AB (1988) Lumbar disc degeneration: Correlation with age, sex, and spine level in 600 autopsy specimens. Spine 13:173 – 178
194. Mitsunaga MM, Chong G, Maes KE (1991) Microscopically assisted posterior lumbar interbody fusion. Clin Orthop 263:121 – 7
195. Modic MT, Steinberg PM, Ross JS, Masaryk TJ, Carter JR (1988) Degenerative disk disease: Assessment of changes in vertebral body marrow with MR imaging. Radiology 166:193 – 199
196. Molinari RW, Sloboda J, Johnstone FL (2003) Are 2 cages needed with instrumented PLIF? A comparison of 1 versus 2 interbody cages in a military population. Am J Orthop 32:337 – 43; discussion 343
197. Mooney V, Robertson J (1976) The facet syndrome. Clin Orthop 115:149 – 156
198. Moore WR, Graves SE, Bain GI (2001) Synthetic bone graft substitutes. ANZ J Surg 71:354 – 61
199. Moran R, O'Connell D, Walsh MG (1988) The diagnostic value of facet joint injections. Spine 13:1407 – 10
200. Mulholland RC (2000) Cages: outcome and complications. Eur Spine J 9 Suppl 1:S110 – 3
201. Mulholland RC, Sengupta DK (2002) Rationale, principles and experimental evaluation of the concept of soft stabilization. Eur Spine J 11 Suppl 2:S198 – 205
202. Nachemson A (1989) Lumbar discography – Where are we today? Spine 14:555 – 556
203. Nachemson AL (1992) Newest knowledge of low back pain. A critical look. Clin Orthop Relat Res:8 – 20
204. Nerlich AG, Schaaf R, Walchli B, Boos N (2007) Temporo-spatial distribution of blood vessels in human lumbar intervertebral discs. Eur Spine J 16:547 – 55
205. Nockels RP (2005) Dynamic stabilization in the surgical management of painful lumbar spinal disorders. Spine 30:S68 – 72
206. Oegema TR, Jr, Bradford DS (1991) The inter-relationship of facet joint osteoarthritis and degenerative disc disease. Br J Rheumatol 30:16 – 20

207. Okawa A, Shinomiya K, Komori H, Muneta T, Arai Y, Nakai O (1998) Dynamic motion study of the whole lumbar spine by videofluoroscopy. Spine 23:1743 – 9
208. Okuda S, Iwasaki M, Miyauchi A, Aono H, Morita M, Yamamoto T (2004) Risk factors for adjacent segment degeneration after PLIF. Spine 29:1535 – 40
209. Olsen BR, Reginato AM, Wang W (2000) Bone development. Annu Rev Cell Dev Biol 16: 191 – 220
210. Oskouian RJ, Jr, Johnson JP (2002) Vascular complications in anterior thoracolumbar spinal reconstruction. J Neurosurg 96:1 – 5
211. Pavlov PW, Meijers H, van Limbeek J, Jacobs WC, Lemmens JA, Obradov-Rajic M, de Kleuver M (2004) Good outcome and restoration of lordosis after anterior lumbar interbody fusion with additional posterior fixation. Spine 29:1893 – 9; discussion 1900
212. Pearcy M, Shepherd J (1985) Is there instability in spondylolisthesis? Spine 10:175 – 7
213. Pellise F, Hernandez A, Vidal X, Minguell J, Martinez C, Villanueva C (2007) Radiologic assessment of all unfused lumbar segments 7.5 years after instrumented posterior spinal fusion. Spine 32:574 – 9
214. Penning L, Wilmik JT, van Woerden HH (1984) Inability to prove instability. A critical appraisal of clinical-radiological flexion-extension studies in lumbar disc degeneration. Diagn Imag Clin Med 53:186 – 192
215. Pfirrmann CWA, Metzdorf A, Zanetti M, Hodler J, Boos N (2001) MR classification of lumbar intervertebral disc degeneration. Spine 26:1873 – 1878
216. Podichetty VK (2007) The aging spine: the role of inflammatory mediators in intervertebral disc degeneration. Cell Mol Biol (Noisy-le-grand) 53:4 – 18
217. Pope MH, Frymoyer JW, Krag MH (1992) Diagnosing instability. Clin Orthop Relat Res:60 – 7
218. Powell MC, Wilson M, Szypryt P, Symonds EM, Worthington BS (1986) Prevalence of lumbar disc degeneration observed by magnetic resonance in symptomless women. Lancet 2:1366 – 7
219. Prolo DJ, Oklund SA, Butcher M (1986) Toward uniformity in evaluating results of lumbar spine operations. A paradigm applied to posterior lumbar interbody fusions. Spine 11:601 – 6
220. Pruss A, Kao M, Gohs U, Koscielny J, von Versen R, Pauli G (2002) Effect of gamma irradiation on human cortical bone transplants contaminated with enveloped and non-enveloped viruses. Biologicals 30:125 – 33
221. Putzier M, Schneider SV, Funk JF, Tohtz SW, Perka C (2005) The surgical treatment of the lumbar disc prolapse: nucleotomy with additional transpedicular dynamic stabilization versus nucleotomy alone. Spine 30:E109 – 14
222. Rannou F, Corvol MT, Hudry C, Anract P, Dumontier MF, Tsagris L, Revel M, Poiraudeau S (2000) Sensitivity of anulus fibrosus cells to interleukin 1 beta. Comparison with articular chondrocytes. Spine 25:17 – 23
223. Rask B, Dall BE (1993) Use of the pantaloon cast for the selection of fusion candidates in the treatment of chronic low back pain. Clin Orthop Relat Res:148 – 57
224. Ray CD (1997) Threaded titanium cages for lumbar interbody fusions. Spine 22:667 – 79; discussion 679 – 80
225. Reddi AH (2001) Bone morphogenetic proteins: from basic science to clinical applications. J Bone Joint Surg Am 83A Suppl 1:S1 – 6
226. Rigby MC, Selmon GP, Foy MA, Fogg AJ (2001) Graf ligament stabilisation: mid- to long-term follow-up. Eur Spine J 10:234 – 6
227. Rivero-Arias O, Campbell H, Gray A, Fairbank J, Frost H, Wilson-MacDonald J (2005) Surgical stabilisation of the spine compared with a programme of intensive rehabilitation for the management of patients with chronic low back pain: cost utility analysis based on a randomised controlled trial. BMJ 330:1239
228. Rothmann SLG, Glenn WV (1985) CT evaluation of interbody fusion. Clin Orthop 193:47 – 56
229. Rousseau MA, Lazennec JY, Saillant G (2007) Circumferential arthrodesis using PEEK cages at the lumbar spine. J Spinal Disord Tech 20:278 – 81
230. Roy-Camille R, Saillant G, Mazel C (1986) Internal fixation of the lumbar spine with pedicle screw plating. Clin Orthop Relat Res:7 – 17
231. Salehi SA, Tawk R, Ganju A, LaMarca F, Liu JC, Ondra SL (2004) Transforaminal lumbar interbody fusion: surgical technique and results in 24 patients. Neurosurgery 54:368 – 74; discussion 374
232. Sandhu HS, Boden SD (1998) Biologic enhancement of spinal fusion. Orthop Clin North Am 29:621 – 31
233. Sasso RC, Kitchel SH, Dawson EG (2004) A prospective, randomized controlled clinical trial of anterior lumbar interbody fusion using a titanium cylindrical threaded fusion device. Spine 29:113 – 22; discussion 121 – 2
234. Sasso RC, LeHuec JC, Shaffrey C, Spine Interbody Research G (2005) Iliac crest bone graft donor site pain after anterior lumbar interbody fusion: a prospective patient satisfaction outcome assessment. J Spinal Disord Techniques 18 Suppl:S77 – 81

235. Scheufler KM, Dohmen H, Vougioukas VI (2007) Percutaneous transforaminal lumbar interbody fusion for the treatment of degenerative lumbar instability. Neurosurgery 60:203 – 12; discussion 212 – 3
236. Schmorl G, Junghanns H (1968) Die gesunde und die kranke Wirbelsäule in Röntgenbild und Klinik. Thieme, Stuttgart
237. Schnake KJ, Schaeren S, Jeanneret B (2006) Dynamic stabilization in addition to decompression for lumbar spinal stenosis with degenerative spondylolisthesis. Spine 31:442 – 9
238. Schwarzenbach O, Berlemann U, Stoll TM, Dubois G (2005) Posterior dynamic stabilization systems: DYNESYS. Orthop Clin North Am 36:363 – 72
239. Schwarzer AC, Aprill CN, Derby R, Fortin J, Kine G, Bogduk N (1994) The false-positive rate of uncontrolled diagnostic blocks of the lumbar zygapophysial joints. Pain 58:195 – 200
240. Shen FH, Samartzis D, An HS (2005) Cell technologies for spinal fusion. Spine J 5:231S–239S
241. Shim CS, Lee SH, Jung B, Sivasabaapathi P, Park SH, Shin SW (2005) Fluoroscopically assisted percutaneous translaminar facet screw fixation following anterior lumbar interbody fusion: technical report. Spine 30:838 – 43
242. Slosar PJ, Reynolds JB, Schofferman J, Goldthwaite N, White AH, Keaney D (2000) Patient satisfaction after circumferential lumbar fusion. Spine 25:722 – 6
243. Splithoff CA (1953) Lumbosacral junction: Roentgenographic comparison of patients with and without backaches. JAMA 152:1610 – 1613
244. Stauffer R, Coventry M (1972) Anterior interbody lumbar spine fusion. J Bone Joint Surg 54 A:756 – 768
245. Stauffer RN, Coventry MB (1972) Posterolateral lumbar-spine fusion. Analysis of Mayo Clinic series. J Bone Joint Surg Am 54:1195 – 204
246. Steffee AD, Biscup RS, Sitkowski DJ (1986) Segmental spine plates with pedicle screw fixation. A new internal fixation device for disorders of the lumbar and thoracolumbar spine. Clin Orthop Relat Res:45 – 53
247. Stevens KJ, Spenciner DB, Griffiths KL, Kim KD, Zwienenberg-Lee M, Alamin T, Bammer R (2006) Comparison of minimally invasive and conventional open posterolateral lumbar fusion using magnetic resonance imaging and retraction pressure studies. J Spinal Disord Tech 19:77 – 86
248. Stokes IAF, Frymoyer JW (1987) Segmental motion and instability. Spine 12:688 – 691
249. Stoll TM, Dubois G, Schwarzenbach O (2002) The dynamic neutralization system for the spine: a multi-center study of a novel non-fusion system. Eur Spine J 11 Suppl 2:S170 – 8
250. Swanepoel MW, Adams LM, Smeathers JE (1995) Human lumbar apophyseal joint damage and intervertebral disc degeneration. Ann Rheum Dis 54:182 – 8
251. Talwar V, Lindsey DP, Fredrick A, Hsu KY, Zucherman JF, Yerby SA (2006) Insertion loads of the X STOP interspinous process distraction system designed to treat neurogenic intermittent claudication. Eur Spine J 15:908 – 12
252. Thalgott JS, Chin AK, Ameriks JA, Jordan FT, Giuffre JM, Fritts K, Timlin M (2000) Minimally invasive 360 degrees instrumented lumbar fusion. Eur Spine J 9 Suppl 1:S51 – 6
253. Thomsen K, Christensen FB, Eiskjaer SP, Hansen ES, Fruensgaard S, Bunger CE (1997) 1997 Volvo Award winner in clinical studies. The effect of pedicle screw instrumentation on functional outcome and fusion rates in posterolateral lumbar spinal fusion: a prospective, randomized clinical study. Spine 22:2813 – 22
254. Tiusanen H, Seitsalo S, Osterman K, Soini J (1995) Retrograde ejaculation after anterior interbody lumbar fusion. Eur Spine J 4:339 – 42
255. Truchly G, Thompson W (1962) Posterolateral fusion of lumbosacral spine. J Bone Joint Surg 44 A:505 – 512
256. Turner JA, Ersek M, Herron L, Deyo R (1992) Surgery for lumbar spinal stenosis. Attempted meta-analysis of the literature. Spine 17:1 – 8
257. Urist MR (1965) Bone: formation by autoinduction. Science 150:893 – 9
258. Urist MR, Strates BS (1971) Bone morphogenetic protein. J Dent Res 50:1392 – 406
259. Vaccaro AR, Chiba K, Heller JG, Patel T, Thalgott JS, Truumees E, Fischgrund JS, Craig MR, Berta SC, Wang JC (2002) Bone grafting alternatives in spinal surgery. Spine J 2:206 – 15
260. Vaccaro AR, Patel T, Fischgrund J, Anderson DG, Truumees E, Herkowitz HN, Phillips F, Hilibrand A, Albert TJ, Wetzel T, McCulloch JA (2004) A pilot study evaluating the safety and efficacy of OP-1 Putty (rhBMP-7) as a replacement for iliac crest autograft in posterolateral lumbar arthrodesis for degenerative spondylolisthesis. Spine 29:1885 – 92
261. Vaccaro AR, Whang PG, Patel T, Phillips FM, Anderson DG, Albert TJ, Hilibrand AS, Brower RS, Kurd MF, Appannagari A, Patel M, Fischgrund JS (2007) The safety and efficacy of OP-1 (rhBMP-7) as a replacement for iliac crest autograft for posterolateral lumbar arthrodesis: minimum 4-year follow-up of a pilot study. Spine J (in press)
262. van Ooij A, Oner FC, Verbout AJ (2003) Complications of artificial disc replacement: a report of 27 patients with the SB Charite disc. J Spinal Disord Tech 16:369 – 83
263. van Tulder MW, Koes B, Malmivaara A (2006) Outcome of non-invasive treatment modalities on back pain: an evidence-based review. Eur Spine J 15 Suppl 1:S64 – 81

264. van Tulder MW, Koes B, Seitsalo S, Malmivaara A (2006) Outcome of invasive treatment modalities on back pain and sciatica: an evidence-based review. Eur Spine J 15 Suppl 1:S82 – 92
265. Vernon-Roberts B (1992) Age-related and degenerative pathology of intervertebral discs and apophyseal joints. In: Jayson MIV (ed) The lumbar spine and back pain. Churchill Livingstone, Edinburgh, pp 17 – 41
266. Vernon-Roberts B, Pirie CJ (1977) Degenerative changes in the intervertebral discs of the lumbar spine and their sequelae. Rheumatol Rehab 16:13 – 21
267. Videbaek TS, Christensen FB, Soegaard R, Hansen ES, Hoy K, Helmig P, Niedermann B, Eiskjoer SP, Bunger CE (2006) Circumferential fusion improves outcome in comparison with instrumented posterolateral fusion: long-term results of a randomized clinical trial. Spine 31:2875 – 80
268. Waddell G (1987) 1987 Volvo award in clinical sciences. A new clinical model for the treatment of low-back pain. Spine 12:632 – 44
269. Walsh TR, Weinstein JN, Spratt KF, Lehmann TR, Aprill C, Sayre H (1990) Lumbar discography in normal subjects. A controlled, prospective study. J Bone Joint Surg Am 72:1081 – 8
270. Watkins M (1953) Posterolateral fusion of the lumbar and lumbosacral spine. J Bone Joint Surg 35 A:1014 – 1019
271. Weiler C, Nerlich AG, Bachmeier BE, Boos N (2005) Expression and distribution of tumor necrosis factor alpha in human lumbar intervertebral discs: a study in surgical specimen and autopsy controls. Spine 30:44 – 53; discussion 54
272. Weishaupt D, Schmid MR, Zanetti M, Boos N, Romanowski B, Kissling RO, Dvorak J, Hodler J (2000) Positional MR imaging of the lumbar spine: does it demonstrate nerve root compromise not visible at conventional MR imaging? Radiology 215:247 – 53
273. Weishaupt D, Zanetti M, Boos N, Hodler J (1999) MR imaging and CT in osteoarthritis of the lumbar facet joints. Skeletal Radiol 28:215 – 9
274. Weishaupt D, Zanetti M, Hodler J, Boos N (1998) MR imaging of the lumbar spine: prevalence of intervertebral disk extrusion and sequestration, nerve root compression, end plate abnormalities, and osteoarthritis of the facet joints in asymptomatic volunteers. Radiology 209:661 – 6
275. Weishaupt D, Zanetti M, Hodler J, Min K, Fuchs B, Pfirrmann CW, Boos N (2001) Painful lumbar disk derangement: relevance of endplate abnormalities at MR imaging. Radiology 218:420 – 7
276. Welch WC, Cheng BC, Awad TE, Davis R, Maxwell JH, Delamarter R, Wingate JK, Sherman J, Macenski MM (2007) Clinical outcomes of the Dynesys dynamic neutralization system: 1-year preliminary results. Neurosurg Focus 22:E8
277. Wetzel FT, LaRocca H (1991) The failed posterior lumbar interbody fusion. Spine 16: 839 – 45
278. Wiltse L, Bateman J, Hutchinson R, Nelson W (1968) The paraspinal sacrospinalis-splitting approach to the lumbar spine. J Bone Joint Surg 50 A:919 – 926
279. Yoshizawa H, O'Brien JP, Smith WT, Trumper M (1980) The neuropathology of intervertebral discs removed for low-back pain. J Pathol 132:95 – 104
280. Zdeblick TA (1993) A prospective, randomized study of lumbar fusion. Preliminary results. Spine 18:983 – 91
281. Zdeblick TA, David SM (2000) A prospective comparison of surgical approach for anterior L4-L5 fusion: laparoscopic versus mini anterior lumbar interbody fusion. Spine 25:2682 – 7
282. Zigler J, Delamarter R, Spivak JM, Linovitz RJ, Danielson GO, 3rd, Haider TT, Cammisa F, Zuchermann J, Balderston R, Kitchel S, Foley K, Watkins R, Bradford D, Yue J, Yuan H, Herkowitz H, Geiger D, Bendo J, Peppers T, Sachs B, Girardi F, Kropf M, Goldstein J (2007) Results of the prospective, randomized, multicenter Food and Drug Administration investigational device exemption study of the ProDisc-L total disc replacement versus circumferential fusion for the treatment of 1-level degenerative disc disease. Spine 32:1155 – 62; discussion 1163
283. Zigler JE (2004) Lumbar spine arthroplasty using the ProDisc II. Spine J 4:260S–267S
284. Zigler JE, Burd TA, Vialle EN, Sachs BL, Rashbaum RF, Ohnmeiss DD (2003) Lumbar spine arthroplasty: early results using the ProDisc II: a prospective randomized trial of arthroplasty versus fusion. J Spinal Disord Tech 16:352 – 61
285. Zucherman JF, Hsu KY, Hartjen CA, Mehalic TF, Implicito DA, Martin MJ, Johnson DR, 2nd, Skidmore GA, Vessa PP, Dwyer JW, Puccio S, Cauthen JC, Ozuna RM (2004) A prospective randomized multi-center study for the treatment of lumbar spinal stenosis with the X STOP interspinous implant: 1-year results. Eur Spine J 13:22 – 31
286. Zucherman JF, Hsu KY, Hartjen CA, Mehalic TF, Implicito DA, Martin MJ, Johnson DR, 2nd, Skidmore GA, Vessa PP, Dwyer JW, Puccio ST, Cauthen JC, Ozuna RM (2005) A multicenter, prospective, randomized trial evaluating the X STOP interspinous process decompression system for the treatment of neurogenic intermittent claudication: two-year follow-up results. Spine 30:1351 – 8

# 21 Non-specific Low Back Pain

Florian Brunner, Sherri Weiser, Annina Schmid, Margareta Nordin

## Core Messages

- ✔ The natural history of non-specific low back pain (NSLBP) indicates that it is a benign, self-limiting condition
- ✔ NSLBP is characterized by the absence of an identifiable morphological correlate for the symptoms
- ✔ Clinical assessment for risk factors for delayed recovery should be conducted early and must include psychosocial and work-related factors
- ✔ The "flag system" (red, yellow, blue, black) identifies serious pathology and obstacles to recovery
- ✔ Return to work as soon as possible is important because the chances of resuming work after one year are minimal
- ✔ Acute NSLBP is best treated with self-care techniques, including over-the-counter medications and early resumption of normal activities as soon as possible
- ✔ In subacute or recurrent NSLBP, treatment should be aggressive to prevent further decline in health status and return patients to optimal health
- ✔ Active physical therapy should be introduced and obstacles for rehabilitation must be assessed early
- ✔ Patients with chronic LBP should receive a multidisciplinary treatment and evaluation approach as soon as possible

## Epidemiology

LBP is a common medical complaint

Estimates of the prevalence of low back pain (LBP) vary considerably, depending on the data source and the definitions used. The lifetime prevalence for LBP ranges from 49 % up to 84 % [22], making it one of the most common medical complaints [76]. The **cumulative lifetime prevalence** of LBP lasting at least 2 weeks was 16 % for individuals aged between 25 and 74 years [67]. Fifty percent of adults have reported experiencing LBP at some point in their life [34]. Approximately 10 % of individuals report having had back pain within the previous year, and 6.8 % report having LBP at any one point in time [5, 28]. The **incidence of LBP** ranges from 28 to 30 episodes/1 000 persons per year [76], being highest in male patients and in patients between 25 and 64 years of age.

Non-specific LBP is the most frequent reason for consultation of a health care provider

Approximately 80 % of patients who consult a health care provider for **non-specific LBP** (NSLBP) (see Chapter 6) can expect to resume normal activities within 4 – 6 weeks. By 12 weeks, the rate of recovery rises to 90 %. Thus, only less than 10 % LBP patients experience chronic pain [38, 60, 81]. However, the recurrence rate is high and has been described as between 25 % and 70 % in different populations [2, 38, 77].

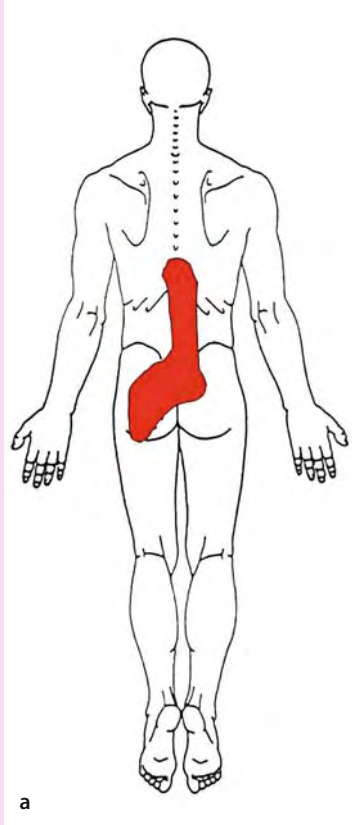

## Case Introduction

A 44-year-old construction worker complained of a history with episodic LBP which he had for several years. Coincidental with a change of workplace his pain was progressively getting worse (**blue flag**). Initially employed as an unskilled worker helping out on different projects, he had to shift to working long shifts as a bricklayer. The new job was associated with working longer hours and under high time pressure (**blue flag**). An acute LBP episode was triggered after lifting several heavy bricks. LBP became aggravating throughout the day and was severe in the evening. The next morning, he could not get out of bed due to severe LBP. His general practitioner (GP) prescribed anti-inflammatory medication and told him to rest for 2 days and then resume normal activities as tolerated (a). After 2 days, he felt extreme LBP, but additionally radiating down the buttocks. Convinced that movement would harm him (**yellow flag**), he remained as inactive as possible while waiting for another consultation with his doctor. The physician decided to perform an MRI (b). The patient stayed at home for 4 weeks until the MRI was done. The MRI did not reveal any structural abnormalities. The patient was referred to a physical therapist who administered heat, massage and electrical stimulation. After a few weeks, he felt a little better regarding his pain but did complain of a burning sensation over his whole leg. Resuming work was still not possible and by this time he had a compensation case pending at work and was required to obtain an independent medical evaluation (**black flag**). After independent medical assessment by the insurance company, he was sent back to work because of the normal MRI scan. However, the patient was upset because he felt accused of simulating and stressed that he was in severe pain (**black flag**).

His family recommended quitting his job to avoid further damage to his back (**yellow flag**). He stayed at home and his wife cared for him. Six weeks later, his GP referred him to a multidisciplinary program. On the first visit, he was depressed, angry, confused and scared (**yellow flags**). The first step was to conduct a medical evaluation and to reassure him that he had NSLBP, and that he indeed would get better. He was immediately relieved but still sceptical as he could not completely understand what was causing his pain (**yellow flag**). During the functional evaluation, pain behavior was observed (**yellow flag**). The physical therapist again gave him the advice that there was no serious damage to justify physical inactivity. Because of his pain behaviors he was evaluated by a psychologist. He began a physical therapy regimen skeptically, but with increasing activity his motivation and compliance improved. The program consisted of general conditioning with an emphasis on tasks he was afraid to perform. Three weeks after the program start he was almost pain free but still unwilling to return to work because he felt discomfort in certain positions and when lifting heavy objects. He still believed that pain indicated damage and returning to work would injure his back (**yellow flag**). Evidence was provided by a psychologist to support the claim that **"pain does not equal harm."** The psychologist and therapist worked to demonstrate to the patient that the physical exercises were just as strenuous as his job and that he was able to fulfill his tasks. During the program, it was discovered that the patient was having conflicts with his new supervisor (**blue flag**) and therefore was afraid to return to work. However, it was recommended to return to work part time (80 %) with minor restrictions for 2 weeks. However, his workplace was not willing to accommodate this request (**blue flag**). The clinical team coordinator negotiated the terms of his return by compromising and insisting on no overtime for 6 months. The patient successfully returned to work and is actively looking for another position in a more supportive organization. This case introduction demonstrates the use of "flags" to identify obstacles to recovery.

## Classification of Back Pain

The term "low back pain" refers to more than 66 diagnoses [24]. As outlined in Chapter 6, LBP can be classified as:

- "specific" (**with** a pathomorphological correlate) [14, 84]
- "non-specific" (**without** a pathomorphological correlate) [43]

**Specific LBP** (SLBP) refers to any diagnosis that can be attributed to a [14, 84]:

- systemic disease
- infection
- injury
- trauma
- structural deformity

The common feature is a causal link between a structural pathology and the expected experience of pain. SLBP diagnoses comprise approximately 15–20% of all back complaints [37].

Specific LBP is based on a causal link between a pathomorphological alteration and pain

**NSLBP** is defined by symptoms occurring primarily in the back that suggest neither nerve root compression nor a serious underlying condition [7, 14, 37, 84]. No causal physical pathology, anatomical lesion, or deformity is identified. NSLBP includes common diagnoses, such as [24]:

- lumbago
- muscle spasm
- back sprain
- back strain
- myofascial syndromes

These vague conditions all include pain in the lumbar region that may radiate to one or both thighs. With regard to the time course, NSLBP can be divided into:

- acute (< 4 weeks)
- subacute (4–12 weeks)
- chronic (> 3–6 months)

Various definitions exist about the point of the beginning of chronic back pain, starting between 3 and 6 months [2, 62]. So far, no consensus has been found on the beginning of **chronic back pain** and a mechanism-based approach is more reasonable (see Chapter 5).

There is also no consensual definition of **recurrent non-specific back pain**. Depending on social system, culture, and type of work, the recurrence rate has been described as between 25% and 70% in different populations [2, 38, 77].

The definition of chronic and recurrent LBP is not well defined

**Delayed recovery** is defined as the period between 4 and 8 weeks after onset of NSLBP during which the patient has not yet returned to normal daily activities [14, 84].

## Pathogenesis of NSLBP

In contrast to SLBP, **no causal pathology** can be found in NSLBP which correlates with pain. Therefore, factors other than anatomic ones must play an important role in generating the pain. Besides the pathoanatomic model for SLBP, the following models are used to diagnose and classify chronic NSLBP [64]:

- peripheral pain generator model
- neurophysiological model

- mechanical loading model
- signs and symptoms model
- motor control model
- biopsychosocial model

The neurophysiological model best explains chronic pain without an obvious path

In the **peripheral pain generator model**, specific injections are used for diagnostic and therapeutic procedures to identify, block or denervate the nociceptive source of pain [16]. The **neurophysiological model** takes into account that, especially in chronic pain, there is a central and a peripheral sensitization induced by biochemical and neuromodulation changes at every level of the nervous system [31, 59]. The **mechanical loading model** includes that sustained end range spinal loading, lifting with flexion and rotation, exposure to vibration and specific sporting activities can have the potential for peripheral sensitization [55]. The **signs and symptoms model** is based on biomechanical and pathoanatomic signs in which the area and nature of pain, impairments in spinal movement and function, changes in segmental spinal mobility, as well as pain responses to mechanical stress and movement play an important role [51, 56]. The **motor control model** implies that in chronic LBP maladaptive movement and motor control impairments appear, resulting in ongoing abnormal tissue loading and mechanically provoked pain (motor control model) [64]. The **biopsychosocial model** has been explained in Chapter 6 and serves as a multidimensional approach for dealing with chronic LBP.

The biopsychosocial model today is well accepted as a conceptual framework

## Patient Assessment and Triage for Non-operative Treatment

The diagnosis of NSLBP is based on the fact that history and clinical examination (Chapter 8) and imaging studies (Chapter 9) as well as spinal injections (Chapter 10) were not able to identify a clear cause of the pain. NSLBP is a diagnosis primarily based on the exclusion of an underlying pathomorphological alteration. This implies at the same time that there is no serious pathology which can hinder the recovery of the patient. Indeed, the natural history of NSLBP indicates that the prognosis is favorable [26]. But 10% of patients with NSLBP still develop chronic pain. Patient assessment must therefore aim to identify obstacles for recovery.

The "flag system" identifies serious spinal pathology and obstacles for recovery

The **goal of triage** for the treatment of LBP is to establish an appropriate rehabilitation plan. The differential diagnosis must first and foremost distinguish between NSLBP and LBP due to neural compression and serious spinal pathologies (e.g., tumors, infections, progressing deformities) [7, 66]. The "**flag system**" is a useful tool (see Chapter 6), which helps to rule out serious spinal pathologies and to identify possible risk factors for delayed recovery associated with poor outcome [3, 38]. Four groups of risk factors or "flags" have been identified (Table 1).

Red flags indicate serious spinal pathology

**Red flags** are symptoms and signs detected by the clinician that may indicate possible spinal pathology and require early referral to a specialist. A standardized physical examination is necessary to exclude possible specific conditions requiring further action. A **history** of trauma, systemic diseases, cancer, infection, or major neurological compromises may indicate serious spinal pathology. In the physical examination, the presence of "red flags," and/or neurological signs and symptoms, such as back pain with radiation to the leg below the knee level or sensory motor dysfunction, classify LBP as specific and may require a referral to a specialist. Comorbidities (such as other joint pain, hypertension, severe stress, diabetes, depression) can also play a major role in recovery of NSLBP [61].

**Table 1.** The flag system [3]

| | Definition | Indicator | Signs and symptoms | Therapeutic approach |
|---|---|---|---|---|
| RED FLAGS | Biomedical factors | Indicate serious spinal pathology | • infections<br>• major trauma<br>• systemic disease<br>• cancer<br>• major neurologic compromise | Early referral to specialist |
| YELLOW FLAGS | Psychosocial or behavioral factors | Predispose to delayed recovery | • patient believes that back pain is harmful or potentially severely disabling<br>• fear avoidance behavior and reduced activity level<br>• tendency to low mood and withdrawal from social interaction<br>• expectations of passive treatment | Add cognitive and behavioral treatment |
| BLUE FLAGS | Socioeconomic/ work factors | Predispose to delayed recovery | • unemployment<br>• fear of losing job<br>• monotony at work<br>• lack of job satisfaction<br>• poor relationships with peers and supervisors | • add ergonomic education<br>• add problem-solving strategies |
| BLACK FLAGS | Occupational and societal factors | Predispose to onset of LBP or disability after acute episode of LBP | • adverse sickness policy<br>• ongoing disability claim<br>• disability compensation<br>• unemployment<br>• type of insurance system | • add problem-solving strategies<br>• solve legal claims |

Yellow flags may indicate psychosocial barriers to recovery and predict poor outcome

**Yellow flags** represent patient's beliefs or behaviors that indicate psychosocial barriers to recovery and predict poor outcomes. Factors which consistently predict poor outcomes are the belief that back pain is harmful or potentially severely disabling, **fear avoidance behavior** (avoiding a movement or activity due to anticipation of pain), reduced activity levels, tendency towards low mood, withdrawal from social interaction, and an expectation of passive treatment rather than a belief that active participation will help to solve the problem [42, 43]. Such **barriers to recovery** should be assessed as soon as possible by the clinician and should be addressed with cognitive and behavioral interventions to avoid long-term problems.

**Six open-ended questions** are useful for eliciting the presence of **yellow flags** [42]:

- Have you had time off work in the past with back pain?
- What do you understand is the cause of your back pain?
- What are you expecting will help you?
- How is your employer responding to your back pain? How are your coworkers or family responding?
- What are you doing to cope with back pain?
- Do you think that you will return to work? If yes, when?

Blue flags represent work related predisposing factors for delayed recovery

**Blue flags** represent work-related predisposing factors for delayed recovery [50] such as fear of losing one's job, **monotony** at work, **lack of job satisfaction**, and poor relationships with peers and supervisors. Though it is difficult to influence work factors in a clinical setting, interventions aimed at strengthening coping skills and problem solving of the patient are part of a cognitive behavioral strategy.

Black flags are related to occupational and societal factors

**Black flags** relate to occupational and societal factors such as **low income** and **low social class** [71]. These factors either lead to the onset of low back pain or promote disability once the acute episode has occurred (see Chapter 6).

## Management of NSLBP

**Various guidelines** supporting the evidence of conservative treatment have been published and they offer treatment recommendations for acute, subacute and chronic LBP [66, 78]. These guidelines were formulated by groups of international experts considering the scientific evidence for physical and non-physical treatment of back pain. Today there are guidelines from many countries and their recommendations are quite consistent [45]. This chapter addresses the treatment of acute, subacute and chronic benign LBP (Fig. 1).

The focus of rehabilitation is on patients with delayed recovery

The chances of a return to work after one year are minimal

The **natural history of NSLBP** shows that most patients return to normal function before the delayed recovery period, whether or not they have any kind of treatment [82]. Therefore, in order to maximize the effectiveness of treatments aimed at disability prevention, the thrust of rehabilitation efforts must be focused on patients who have not resumed normal activities after 4 weeks. **Return to work** as soon as possible is important because the chances of resuming work are minimal after one year [82].

## Management of Acute NSLBP (< 4 weeks)

Acute LBP is often self-limiting and minimal medical intervention is recommended

Self-care techniques put the patient in an active role in the treatment and recovery process

Acute low back pain is defined as the period between onset and 1–4 weeks [32, 62] after onset of pain. Since low back pain is **self-limiting** for the majority of patients, minimal or no medical interventions are recommended for acute non-specific low back pain [2, 84].

In fact, patients can easily rely on **self-care techniques** such as over-the-counter medication and activity as tolerated. This approach is desirable because it requires that the patient plays an active role in the treatment and recovery process [61] (Table 2).

It has been shown that individuals who perceive that they have control over their symptoms and the ability to affect the necessary behaviors have better outcomes than those who do not [63]. In addition self-care techniques reduce the number of health care visits, the associated risk for complications and the treatment costs [63].

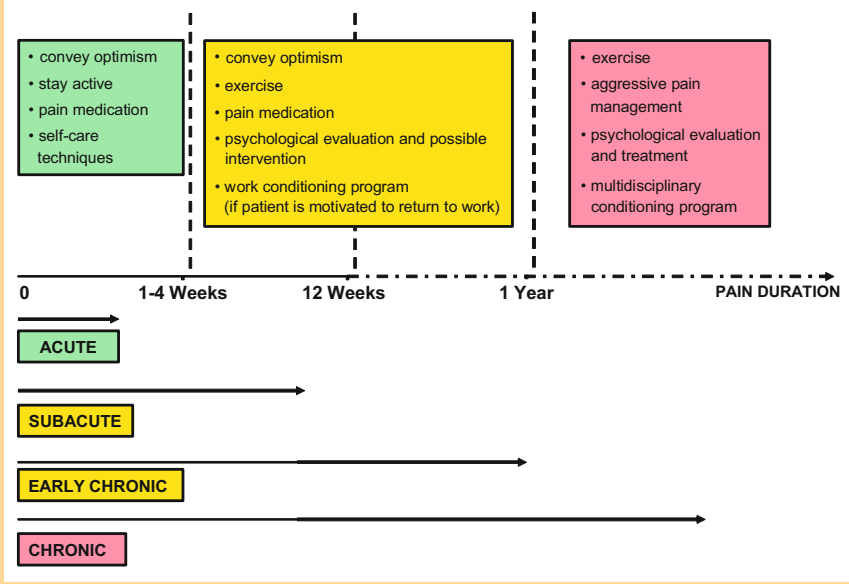


Figure 1. Assessment and interventions in acute, subacute and chronic non-specific low back pain

**Table 2.** Randomized controlled trials of the effectiveness of exercises in the treatment of low back pain

| Author | Subjects | Stage | Intervention/groups | Outcome measures | Conclusions |
|---|---|---|---|---|---|
| Malvimaara et al. 1995 [52] | 186 | Acute | 1. 2 days bed rest<br>2. Extension and lateral flexion exercises<br>3. Control group: return to ADL (asap) | • pain<br>• disability<br>• range of motion | • control group best results at 3 and 12 weeks<br>• recovery slowest for bed rest |
| Lindstrom et al. 1992 [47] | 103 | Sub-acute | 1. Graded activity program with behavioral therapy approach<br>2. Control group: traditional care | • mobility<br>• strength<br>• fitness | • earlier return to work in activity group<br>• mobility, fitness and strength better in activity group |
| Mannion et al 1999 [54] | 148 | Chronic | 1. Active physiotherapy<br>2. Muscle reconditioning on training devices<br>3. Low-impact aerobics | • range of motion<br>• pain<br>• disability<br>• psychosocial factors | • significant reduction in pain, psychological factors and disability in all groups<br>• range of motion improved in 2 and 3 |
| Torstensen et al. 1998 [75] | 208 | Chronic | 1. Medical exercise<br>2. Conventional physiotherapy<br>3. Self-exercise | • pain, functional ability<br>• patient satisfaction<br>• return to work<br>• sick leave, costs | • groups 1 and 2 were significantly better than 3<br>• patient satisfaction highest for 1<br>• no difference between groups for return to work |
| Frost et al. 1995 [33] | 81 | Chronic | 1. Exercise: fitness, stretching, back school<br>2. Back school | • pain<br>• functional status<br>• walking distance | • the exercise group scored significantly higher on most outcomes |
| Hansen et al. 1993 [36] | 150 | Chronic | 1. Intensive dynamic back muscle exercises<br>2. Conventional physiotherapy including isometric exercises<br>3. Placebo: hot packs and light traction | • pain | • physiotherapy was superior in male patients whereas muscle exercises were most efficient for female participants |
| Deyo et al. 1990 [29] | 145 | Chronic | 1. TENS<br>2. Placebo<br>3. TENS and exercise (stretching)<br>4. Placebo and exercise | • pain<br>• range of motion<br>• ADL | • no significant difference between the TENS group and placebo<br>• TENS was equivalent to exercise alone |
| Manniche et al. 1988 [53] | 105 | Chronic | 1. Intensive dynamic back extensor exercises<br>2. Moderate dynamic back extensor exercises<br>3. Thermotherapy, massage and light exercises | • pain<br>• disability<br>• physical impairment | • improvement in all groups<br>• group 1 scored significantly better than 2 and 3 |

If the patient chooses to see a physician during this period it is important for the doctor to convey information about the natural history of LBP. The patient should be encouraged to resume **normal activities** [66] and to stay active. Bed rest should not be prescribed as a treatment. If necessary, over-the-counter medications should be used for pain relief [2, 84].

The patient must be advised to resume normal activities

### Medical Pain Management

Over-the-counter medication should be used for pain relief whenever possible. The first choice of medication should be acetaminophen (paracetamol) because of its low potential side effects [14]. If pain relief is insufficient, non-steroidal anti-inflammatory drugs, such as acetylsalicylic acid, diclofenac or ibuprofen can be prescribed. However, these medications can have serious side effects such as gastrointestinal and renal complications as well as a decreased platelet aggregation. The use of muscle relaxants and opioids has several unpleasant side effects and has not been shown to be more effective than other, safer drugs [14, 84].

For acute NSLBP, acetaminophen is recommended because of its low potential side effects

## Management of Subacute NSLBP (4–12 weeks)

Treatment of subacute NSLBP should proceed in a stepwise fashion

About 60–70 % of the patients with NSLBP seeking care, return to normal function after 4 weeks. If back pain is not resolved after 4 weeks, patients are at increased risk for disability [43, 62, 84]. The risk factors discussed above are associated with delayed recovery and should be identified. Expensive and invasive procedures should be kept to a minimum. Because no guidelines for the management of subacute LBP have been clearly established, treatment should proceed in a stepwise fashion, from least to most invasive treatment [61].

### Exercise

Progressive exercise therapy has been shown to be beneficial for patients with subacute or recurrent episodes of LBP [2]. Although there is sufficient evidence to recommend physical, therapeutic or recreational exercise, it remains unclear whether any specific type of exercise is more effective than any other [2, 77]. The type of exercise prescribed often depends on the training and preferences of the provider and may vary considerably.

Exercise therapy is beneficial in patients with subacute or recurrent episodes of NSLBP

A variety of exercises have been studied including flexion/extension exercises for the trunk, various dynamic exercises, aerobics, stretching, Williams flexion exercise method, McKenzie extension exercises, isometric exercises, and walking and jogging [20, 82]. All seem to be helpful if the patient is committed to performing the exercise. Therefore, an important issue is to encourage exercise and activity preferred by the patient. Less is known about the importance of intensity, duration and frequency of the exercise. However, it is recommended that the exercises are progressive in intensity, duration and frequency [61].

Cardiorespiratory endurance and stretching programs assist recovery

Unless comorbidities contraindicate certain activities, a general progressive fitness program of any type is usually safe [2]. A walking program can increase **cardiorespiratory endurance**. A **stretching program** may achieve flexibility and improve range of motion. Strengthening exercises increase the ability of a muscle or a muscle group to overcome resistance. Strengthening and endurance exercises are a major component in the rehabilitation of patients with LBP. They usually consist of body weight resistance against gravity, machines, free weights, and elastic band resistance and in later stage a recommended sport of the patient's preference [61] (Table 3).

### Modalities and Manual Therapy

Manual therapy may be effective for short-term relief

Commonly used physical modalities for LBP include electrotherapy (TENS), therapeutic heat (superficial heat), therapeutic cold (e.g., cold packs, sprays), and magnetic therapy. Manual therapy includes other passive treatments such as massage and mobilization.

An active approach provides the best outcome

Although there is no evidence that any of these treatments improve the functional outcome of LBP, some of them may be effective for short-term relief and serve as a catalyst for activity resumption [61]. They should only be used to control symptoms in conjunction with an exercise program, as an active approach provides the best outcome [14].

### Spinal Manipulation

Some studies have reported that a few treatments of spinal manipulation in the acute stage of injury can speed recovery [1, 78]. However, these studies are of mixed quality and do not allow definitive statements of efficacy [18]. If a patient is not responsive to two or three treatments, it is unlikely that they will be helped

**Table 3.** Suggestion for a home exercise program for NSLBP

| Exercise | Goal | |
|---|---|---|
| Transverse abdominis muscle activation | To activate the transverse abdominis muscle independently while maintaining diaphragmatic breathing | |
| Adapted leg crunches | To activate the abdominal muscles in a neutral lumbar spine position while moving the lower extremity | |
| Lumbar proprioception | To increase body awareness and stabilize the lumbar spine while bending the hip joints | |
| Lumbar stabilization | To improve lumbar stabilization in forward bending and activate the lumbar extensors | 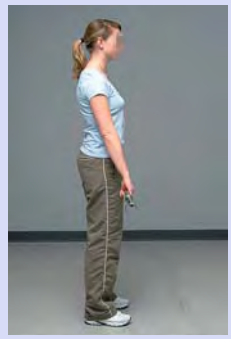  |
| Step up | To maintain lumbar stabilization while strengthening the lower extremity | |

at all and another type of treatment should be introduced. There is no strong support to recommend spinal manipulation after the acute phase of NSLBP, and there is no evidence to support its use in recurrent or chronic NSLBP [78].

Manipulation shows short-term benefit in patients with acute NSLBP

One study questioned the cost-effectiveness of spinal manipulations in low back pain patients as its effect was found to be just slightly better than providing an educational booklet without intervention [23].

### Psychological Intervention

Psychological interventions assist recovery and prevent chronicity

Psychological intervention, predominantly a cognitive-behavioral therapy, is indicated if the patient shows delayed recovery despite aggressive medical and physical therapy management [43, 63, 82, 84]. There is increasingly good evidence that such treatment may assist the rate of recovery and prevent chronicity [48]. All "at risk" patients showing signs of "yellow flags" should be evaluated for psychological intervention.

Psychological interventions include relaxation training, cognitive techniques and coping strategies

Relaxation training may be used to reduce maladaptive long-term stress responses [79]. **Cognitive techniques** are introduced to reduce the negative response associated with pain [79]. These may include pain distraction techniques, reinterpreting symptoms, and the use of healing or calm imagery. Problem focused coping may also be used to assist in overcoming obstacles to recovery and to initiate behavioral change [79]. In some cases, intervention may include psychotherapy or psychopharmacological therapy, or both [61]. Psychological interventions are also indicated in patients with severe distress, those who state that stress plays a significant role in pain or state a desire for an alternative approach to pain, and those patients with recurrent NSLPB [14, 82, 83].

Psychological interventions for best results should usually be done in conjunction with physical therapy exercises. The coordination of care among providers is crucial to provide a consistent and clear message to the patient. Exercise and psychological techniques for pain control reinforce each other: as the patient becomes stronger physically, a sense of psychological control emerges, and vice versa.

### Work Conditioning Programs

The goal of work conditioning programs is to return the patient to gainful employment

Work conditioning programs usually include exercise and fitness, and **cognitive/behavioral and educational components** [20]. Work hardening programs include all the components above as well as work simulation such as digging, driving, and other work tasks [20]. These programs are designed for patients in the subacute or early chronic stage of NSLBP who indicate a willingness to return to work. The programs are distinguished by their aggressive approach to rehabilitation and emphasis on returning the patient to gainful employment [47, 49].

Multidisciplinary programs show best results for patients with subacute LBP

These programs use a behavioral paradigm in which the health care provider, in collaboration with the patient, sets the physical functioning goals, and the accomplishment of goals is rewarded with positive feedback [20]. Additionally, many of these programs simulate actual physical work tasks to prepare the patient to return to work after rehabilitation. Most of these programs are multidisciplinary in nature, including psychological and/or ergonomic components [20]. Most successful programs include aggressive physical therapy, psychological intervention, education, and training to return to the workplace. It has been shown that **multidisciplinary programs** appear to have the best results for patients with subacute LBP [2, 40, 83], although the relative contribution of the different disciplines to the success of treatment and outcomes is unknown.

### Medical Pain Management

Not much evidence is available about the medical pain management in subacute LBP. However, in common clinical practice, analgesics such as acetaminophen and non-steroidal anti-inflammatory drugs have been shown to be effective [76]. In some cases antidepressants and muscle relaxants might be indicated. Facet joints or epidural injections may be subjectively helpful but have not been proven to be effective.

## Management of Chronic Non-specific LBP (> 12 weeks)

Multidisciplinary and work conditioning programs may prevent disability

The natural history of NSLBP predicts that, as time goes on, the chances for recovery become progressively worse [61]. At 6 months after the onset of pain, the likelihood of a patient ever resuming normal activities is 40 – 55 %, at 2 years, it is almost nil [82]. Most studies and reviews imply that any attempts to rehabilitate chronic patients generally are not very successful [61]. However, aggressive multidisciplinary programs have been shown to be successful for some chronic patients [20]. Work-conditioning programs may also help for the early chronic patient (< 1 year) [20]. These types of programs should be considered if the patient has not previously tried aggressive physical therapy (see Table 1).

### Medical Pain Management

In chronic LBP, acetaminophen and non-steroidal anti-inflammatory drugs are likely to be beneficial [81]. The effectiveness of other medications such as antidepressants and muscle relaxants is unknown [81]. However, in common clinical practice these medications can be beneficial in combination with the treatment mentioned above. Facet joint injections have been shown to be ineffective or even

**Table 4.** Outcome of medication on back pain and sciatica

| Medication | Stage | Results | References | Adverse effects |
|---|---|---|---|---|
| NSAIDs | Acute LBP | • conflicting evidence for better pain relief than placebo | [4, 8, 10, 35, 39, 46, 74, 85, 86] | • gastrointestinal complications<br>• cardiovascular risks |
| | | • conflicting evidence that NSAIDs are more effective than paracetamol | [30, 57, 87] | |
| | | • moderate evidence that NSAIDs are not more effective than other drugs | [10, 17, 19, 30, 73, 80] | |
| | Chronic LBP | • naproxen sodium 275 mg decreased pain more than placebo at 14 days | [12] | |
| | | • strong evidence that COX2 inhibitors decrease pain and improve function better than placebo | [15, 25, 41, 65] | |
| Muscle relaxants | Acute LBP | • limited evidence that an intramuscular injection of diazepam followed by oral diazepam is more effective than placebo for short-term pain relief and overall improvement | [58] | • strong evidence for more total adverse effects and central nervous system adverse effects than placebo (drowsiness, dizziness) |
| | | • moderate evidence that orphenadrine injection is more effective than placebo in pain relief and muscle spasm | [44] | |
| | | • strong evidence that oral non-benzodiazepines are more effective than placebo for short-term pain relief and physical outcome | [9, 11, 13] | |
| | | • strong evidence that antispasticity muscle relaxants are more effective than placebo for short-term pain relief and spasm reduction | [21, 27] | |
| | Chronic LBP | • strong evidence that tetrazepam 50 mg is more effective than placebo on short-term pain relief | [6, 70] | |
| | | • moderate evidence that tetrazepam is more effective than placebo on short-term decrease of muscle spasm | [6] | |
| | | • moderate evidence that flupirtine is more effective than placebo on short-term pain relief but not on spasm reduction | [88] | |
| | | • moderate evidence that tolperisone is more effective than placebo on short-term overall improvement but not pain relief and spasm | [68] | |
| Antidepressants | Chronic LBP | • antidepressants significantly reduce pain compared with placebo, no difference in functioning | [69, 72] | • dry mouth, drowsiness, constipation, urinary retention, orthostatic hypotension, mania |

The effect of analgesic pumps is unproven

harmful [81]. Implantation of analgesic pumps, which constantly release analgesics, is becoming more and more popular, but their effectiveness remains to be proven (Table 4).

## Recapitulation

**Epidemiology.** The lifetime prevalence for LBP ranges from 49% up to 84%, making it one of the most common complaints. However, less than 10% experience chronic low back pain.

**Classification.** Low back pain can be divided into specific LBP (with a pathomorphological correlate) and non-specific LBP into acute, subacute and chronic stages. There exist several **models** to explain and classify chronic NSLBP such as the peripheral pain generator model, the neurophysiological model, the mechanical loading model, the signs and symptoms model, the motor control model and the biopsychosocial model.

**Assessment.** NSLBP is a diagnosis primarily based on the exclusion of an underlying pathomorphological alteration. The "**flag system**" is a useful tool which helps to rule out serious pathologies and to identify risk factors for delayed recovery.

**Acute NSLPB.** Acute NSLBP is mostly a self-limiting condition in which no anatomic pathology can be identified which correlates with signs and symptoms. It requires no special medical attention unless red flags indicate a specific diagnosis requiring timely treatment or yellow flags suggest psychological stressors that may delay recovery. During the acute phase (<4 weeks), most patients benefit from **self-care techniques**, including over-the-counter medications and graded physical activity as tolerated. Most patients recover and are able to return to work.

**Subacute NSLPB.** In the later acute phase (2–4 weeks after onset) and the early subacute (4–6 weeks after onset) phase, a variety of **progressive exercise programs** appear equally useful, and therefore the choice is often made based on the preferences of the physical therapist. In patients not responding to these treatments, psychological evaluation and short-term **psychological interventions** may be effective.

**Chronic NSLBP.** Failure to recover from subacute and recurrent back pain should prompt the use of **multidisciplinary work conditioning programs** (within 6–12 weeks of onset). Preliminary evidence suggests that an important part of the success of these programs is the patient's motivation to return to work.

## Key Articles

**Malvimaara A, Hakkinen U, Aro T, Heinrichs ML, Koskenniemi L, Kuosma E, Lappi S, Paloheimo R, Servo C, Vaaranen V, Hernberg S (1995) The treatment of acute low back pain – bed rest, exercises or ordinary activity. N Engl J Med 332:351–355**
Randomized controlled trial investigating the efficacy of bed rest compared to back-extension exercises or continuation of ordinary activities as tolerated in acute low back pain. A more rapid recovery has been demonstrated after continuation of ordinary activities.

**Lindstrom I, Ohlund C, Eek C, Wallin L, Peterson LE, Fordyce WE (1992) The effect of graded activity on patients with subacute low back pain: a randomized prospective clinical study with an operant-conditioning behavioural approach. Physical Therapy 72: 279–293**
High quality trial investigating the effects of a graded activity program with a behavioral therapy approach compared to a control group receiving traditional care in subjects with NSLBP. The graded activity program proved to be a successful method to accelerate the return to work rate and was superior in terms of mobility, strength and fitness in subacute NSLBP.

**Frost H, Klaber Moffett JA, Bergman JA, Spengler D (1995) Randomised controlled trial for evaluation of fitness programme for patients with chronic low back pain. Br Med J 310:152–154**
Randomized controlled trial investigating a fitness program (back school, stretching, exercise) compared to a control group (back school solely) in chronic NSLBP. The fitness program improved pain, disability, self-efficacy and walking distance significantly compared to the control group and is thus suggested to play a role in the management of chronic NSLBP.

**Van Tulder M, Koes B, Malmivaara A (2006) Outcome of non-invasive treatment modalities on back pain: an evidence-based review. Eur Spine J 15:S64–S81**
Comprehensive review of outcome of non-invasive treatment on back pain which recommends NSAID, muscle relaxants and staying active as interventions for acute LBP. Antidepressants, COX2, back school, progressive relaxation, cognitive-respondent treatment, exercise therapy and multidisciplinary treatments are favored in chronic LBP for short term pain relief.

**Abenhaim L, Rossignol M, Valat JP, Nordin M, Avouac B, Blotman F, Charlot J, Dreiser RL, Legrand E, Rozenberg S, Vautravers P (2000) The role of activity in the therapeutic management of back pain. Report of the International Paris Task Force on Back Pain. Spine 25:1S–33S**
Extensive review about the role of activity in the treatment of patients with back pain with comprehensive recommendations from the Paris Task Force.

**Accident Rehabilitation & Compensation Insurance Corporation of New Zealand and National Health Committee (1997) Acute Low Back Pain Guide. Ministry of Health, New Zealand**
The New Zealand task force proposed a flag system to help identify factors associated with poor outcome of low back pain.

**Cherkin DC, Deyo RA, Battie M, et al. (1998) A comparison of physical therapy, chiropractic manipulation, and provision of an educational booklet for the treatment of patients with low back pain. N Engl J Med 339:1021–9**
Trial investigating the cost effectiveness and treatment success of McKenzie treatment compared to chiropractic manipulation or minimal treatment (educational booklet). There was no significant difference between the chiropractic and McKenzie intervention and no differences in absence of work or recurrent back pain among all groups. However, the booklet proved to be the most cost-effective intervention whereas chiropractic and McKenzie therapy had similar costs. The limited benefits of the therapies are questioned when considering their costs.

**Mannion AF, Taimela S, Muntener M, Dvorak J (2001) Active therapy for chronic low back pain: part 1. Effects on back muscle activation, fatigability, and strength. Spine 26:897–908**
Prospective study comparing the effect of three active therapies on back muscle function in chronic low back pain. There were significant muscle performance changes after all three interventions. Those appeared to be mainly due to psychological changes and changes in neural activation.

**Kaser L, Mannion AF, Rhyner A, Weber E, Dvorak J, Muntener M (2001) Active therapy for chronic low back pain: part 2. Effects on paraspinal muscle cross-sectional area, fiber type size, and distribution. Spine 26:909–19**
Prospective study comparing the effects of different active therapies on back muscle structure in chronic LBP. Three-month active therapy was not enough to reverse the glycolytic profile and the back muscle size in the chronic LBP patient and morphological changes can thus not explain the improvement in muscle performance.

**Mannion AF, Junge A, Taimela S, Muntener M, Lorenzo K, Dvorak J (2001) Active therapy for chronic low back pain: part 3. Factors influencing self-rated disability and its change following therapy. Spine 26:920–9**
Cross sectional analysis of the factors influencing self-rated disability associated with chronic LBP. Prospective study investigating the changes of these factors following active therapy. A combination of pain and psychological and physiological factors was most

suited to predict baseline disability. The active treatment program demonstrated to improve physical function and psychological factors.

**Cost B13: European guidelines for the management of low back pain (2006) Eur Spine J 15 Suppl 2:S125 – 300**
Excellent supplement with a state of the art review of the literature providing practical guidelines for the treatment of LBP.

**Waddell G (2004) The back pain revolution. 2nd Edition. Churchill Livingstone, Edinburgh**
Landmark book with a comprehensive view on back pain.

## References


1. Abenhaim L, Bergeron AM (1992) Twenty years of randomized clinical trials of manipulative therapy for back pain: a review. Clin Invest Med 15:527 – 535
2. Abenhaim L, Rossignol M, Valat JP, Nordin M, Avouac B, Blotman F, Charlot J, Dreiser RL, Legrand E, Rozenberg S, Vautravers P (2000) The role of activity in the therapeutic management of back pain. Report of the International Paris Task Force on Back Pain. Spine 25:1S–33S
3. Accident Rehabilitation & Compensation Insurance Corporation of New Zealand and National Health Committee MoH (1997) New Zealand Acute Low Back Pain Guide
4. Amlie E, Weber H, Holme I (1987) Treatment of acute low-back pain with piroxicam: results of a double-blind placebo-controlled trial. Spine 12:473 – 476
5. Andersson G (1997) The epidemiology of spinal disorders. In: Frymoyer JW (ed) The adult spine: Principles and practice. Lippincott-Raven, Philadelphia
6. Arbus L, Fajadet B, Aubert D, Morre M, Goldfinger E (1990) Activity of tetrazepam in low back pain. Clin Trials J 27:258 – 267
7. Atlas SJ, Deyo RA, Patrick DL, Convery K, Keller RB, Singer DE (1996) The Quebec Task Force Classification for Spinal Disorders and the severity, treatment, and outcomes of sciatica and lumbar spinal stenosis. Spine 21:2885 – 2892
8. Babej-Dolle R, Freytag S, Eckmeyer J, Zerle G, Schinzel S, Schmeider G, Stankov G (1994) Parenteral dipyrone versus diclofenac and placebo in patients with acute lumbago or sciatic pain: randomized observer-blind multicenter study. Int J Clin Pharmacol Ther 32:204 – 209
9. Barrata R (1982) A double-blind study of cyclobenzaprine and placebo in the treatment of acute musculoskeletal conditions of the low back. Curr Ther Res 32:646 – 652
10. Basmajian JV (1989) Acute back pain and spasm. A controlled multicenter trial of combined analgesic and antispasm agents. Spine 14:438 – 439
11. Bendix AF, Bendix T, Vaegter K, Lund C, Frolund L, Holm L (1996) Multidisciplinary intensive treatment for chronic low back pain: a randomized, prospective study. Cleve Clin J Med 63:62 – 69
12. Berry H, Bloom B, Hamilton EB, Swinson DR (1982) Naproxen sodium, diflunisal, and placebo in the treatment of chronic back pain. Ann Rheum Dis 41:129 – 132
13. Berry H, Hutchinson A (1988) A multicentre placebo-controlled study in general practice to evaluate the efficacy and safety of tizanidine in acute low-back pain. J Int Med Res 16:75 – 82
14. Bigos S, Bowyer O, Braen G (1994) Acute low back problems in adults. Clin Practice Guidelines 14:1 – 116
15. Birbara CA, Puopolo AD, Munoz DR, Sheldon EA, Mangione A, Bohidar NR, Geba GP (2003) Treatment of chronic low back pain with etoricoxib, a new cyclo-oxygenase-2 selective inhibitor: improvement in pain and disability – a randomized, placebo-controlled, 3-month trial. J Pain 4:307 – 315
16. Bogduk N (2004) Management of chronic low back pain. Med J Aust 180:79 – 83
17. Braun H, Huberty R (1982) [Therapy of lumbar sciatica. A comparative clinical study of a corticoid-free monosubstance and a corticoid-containing combination drug]. Med Welt 33:490 – 491
18. Bronfort G (1999) Spinal manipulation: current state of research and its indications. Neurol Clin 17:91 – 111
19. Brown FL, Jr., Bodison S, Dixon J, Davis W, Nowoslawski J (1986) Comparison of diflunisal and acetaminophen with codeine in the treatment of initial or recurrent acute low back strain. Clin Ther 9 Suppl C:52 – 58
20. Campello M, Weiser S, van Doorn JW, Nordin M (1998) Approaches to improve the outcome of patients with delayed recovery. Baillieres Clin Rheumatol 12:93 – 113
21. Casale R (1988) Acute low back pain: symptomatic treatment with a muscle relaxant drug. Clin J Pain 4:81 – 88

22. Cassidy JD, Carroll LJ, Cote P (1998) The Saskatchewan health and back pain survey. The prevalence of low back pain and related disability in Saskatchewan adults. Spine 23: 1860 – 1866; discussion 1867
23. Cherkin DC, Deyo RA, Battie M, Street J, Barlow W (1998) A comparison of physical therapy, chiropractic manipulation, and provision of an educational booklet for the treatment of patients with low back pain. N Engl J Med 339:1021 – 1029
24. Cherkin DC, Deyo RA, Volinn E, Loeser JD (1992) Use of the International Classification of Diseases (ICD-9-CM) to identify hospitalizations for mechanical low back problems in administrative databases. Spine 17:817 – 825
25. Coats TL, Borenstein DG, Nangia NK, Brown MT (2004) Effects of valdecoxib in the treatment of chronic low back pain: results of a randomized, placebo-controlled trial. Clin Ther 26:1249 – 1260
26. Croft PR, Macfarlane GJ, Papageorgiou AC, Thomas E, Silman AJ (1998) Outcome of low back pain in general practice: a prospective study. BMJ 316:1356 – 1359
27. Dapas F, Hartman SF, Martinez L, Northrup BE, Nussdorf RT, Silberman HM, Gross H (1985) Baclofen for the treatment of acute low-back syndrome. A double-blind comparison with placebo. Spine 10:345 – 349
28. Deyo RA, Tsui-Wu YJ (1987) Descriptive epidemiology of low-back pain and its related medical care in the United States. Spine 12:264 – 268
29. Deyo RA, Walsh NE, Martin DC, Schoenfeld LS, Ramamurthy S (1990) A controlled trial of transcutaneous electrical nerve stimulation (TENS) and exercise for chronic low back pain. N Engl J Med 322:1627 – 1634
30. Evans DP, Burke MS, Newcombe RG (1980) Medicines of choice in low back pain. Curr Med Res Opin 6:540 – 547
31. Flor H, Braun C, Elbert T, Birbaumer N (1997) Extensive reorganization of primary somatosensory cortex in chronic back pain patients. Neurosci Lett 224:5 – 8
32. Force QT (1987) Scientific approach to the assessment and management of activity-related spinal disorders. A monograph for clinicians. Report of the Quebec Task Force on Spinal Disorders. Spine 12:S1 – 59
33. Frost H, Klaber Moffett JA, Moser JS, Fairbank JC (1995) Randomised controlled trial for evaluation of fitness programme for patients with chronic low back pain. BMJ 310:151 – 154
34. Frymoyer JW, Pope MH, Costanza MC, Rosen JC, Goggin JE, Wilder DG (1980) Epidemiologic studies of low-back pain. Spine 5:419 – 423
35. Goldie I (1968) A clinical trial with indomethacin (indomee(R)) in low back pain and sciatica. Acta Orthop Scand 39:117 – 128
36. Hansen FR, Bendix T, Skov P, Jensen CV, Kristensen JH, Krohn L, Schioeler H (1993) Intensive, dynamic back-muscle exercises, conventional physiotherapy, or placebo-control treatment of low-back pain. A randomized, observer-blind trial. Spine 18:98 – 108
37. Hart LG, Deyo RA, Cherkin DC (1995) Physician office visits for low back pain. Frequency, clinical evaluation, and treatment patterns from a U.S. national survey. Spine 20:11 – 19
38. Hashemi L, Webster BS, Clancy EA, Courtney TK (1998) Length of disability and cost of work-related musculoskeletal disorders of the upper extremity. J Occup Environ Med 40: 261 – 269
39. Jacobs JH, Grayson MF (1968) Trial of an anti-inflammatory agent (indomethacin) in low back pain with and without radicular involvement. Br Med J 3:158 – 160
40. Karjalainen K, Malmivaara A, van Tulder M, Roine R, Jauhiainen M, Hurri H, Koes B (2000) Multidisciplinary biopsychosocial rehabilitation for subacute low back pain among working age adults. Cochrane Database Syst Rev:CD002193
41. Katz N, Ju WD, Krupa DA, Sperling RS, Bozalis Rodgers D, Gertz BJ, Gimbel J, Coleman S, Fisher C, Nabizadeh S, Borenstein D (2003) Efficacy and safety of rofecoxib in patients with chronic low back pain: results from two 4-week, randomized, placebo-controlled, parallel-group, double-blind trials. Spine 28:851 – 858; discussion 859
42. Kendall NA (1999) Psychosocial approaches to the prevention of chronic pain: the low back paradigm. Baillieres Best Pract Res Clin Rheumatol 13:545 – 554
43. Kendall NA, Linton SJ, Main CJ (1997) Guide to Assessing Psychosocial Yellow Flags in Acute Low Back Pain: Risk Factors for Long-term Disability and Work Loss. Accident Rehabilitation and Compensation Insurance Corporation of New Zealand and the National Health Committee, Wellington
44. Klinger N, Wilson R, Kanniainen C, Wagenknecht K, Re O, Gold R (1988) Intravenous orphenadrine for the treatment of lumbar paravertebral muscle strain. Curr Ther Res 43: 247 – 254
45. Koes BW, van Tulder MW, Ostelo R, Kim Burton A, Waddell G (2001) Clinical guidelines for the management of low back pain in primary care: an international comparison. Spine 26:2504 – 2513; discussion 2513 – 2504
46. Lacey PH, Dodd GD, Shannon DJ (1984) A double blind, placebo controlled study of piroxicam in the management of acute musculoskeletal disorders. Eur J Rheumatol Inflamm 7:95 – 104

47. Lindstrom I, Ohlund C, Eek C, Wallin L, Peterson LE, Nachemson A (1992) Mobility, strength, and fitness after a graded activity program for patients with subacute low back pain. A randomized prospective clinical study with a behavioral therapy approach. Spine 17:641 – 652
48. Linton SJ, Andersson T (2000) Can chronic disability be prevented? A randomized trial of a cognitive-behavior intervention and two forms of information for patients with spinal pain. Spine 25:2825 – 2831; discussion 2824
49. Loisel P, Abenhaim L, Durand P, Esdaile JM, Suissa S, Gosselin L, Simard R, Turcotte J, Lemaire J (1997) A population-based, randomized clinical trial on back pain management. Spine 22:2911 – 2918
50. Main CJ, Williams AC (2002) Musculoskeletal pain. BMJ 325:534 – 537
51. Maitland G (2005) Vertebral manipulation. Butterworth, London
52. Malmivaara A, Hakkinen U, Aro T, Heinrichs ML, Koskenniemi L, Kuosma E, Lappi S, Paloheimo R, Servo C, Vaaranen V, et al. (1995) The treatment of acute low back pain – bed rest, exercises, or ordinary activity? N Engl J Med 332:351 – 355
53. Manniche C, Hesselsoe G, Bentzen L, Christensen I, Lundberg E (1988) Clinical trial of intensive muscle training for chronic low back pain. Lancet 2:1473 – 1476
54. Mannion AF, Muntener M, Taimela S, Dvorak J (1999) A randomized clinical trial of three active therapies for chronic low back pain. Spine 24:2435 – 2448
55. McGill SM (2004) Linking latest knowledge of injury mechanisms and spine function to the prevention of low back disorders. J Electromyogr Kinesiol 14:43 – 47
56. McKenzie R (1981) In: The lumbar spine, mechanical diagnosis and treatment. Spinal Publications, Waikanae, New Zealand
57. Milgrom C, Finestone A, Lev B, Wiener M, Floman Y (1993) Overexertional lumbar and thoracic back pain among recruits: a prospective study of risk factors and treatment regimens. J Spinal Disord 6:187 – 193
58. Moll W (1973) [Therapy of acute lumbovertebral syndromes through optimal muscle relaxation using diazepam. Results of a double-blind study on 68 cases]. Med Welt 24:1747 – 1751
59. Moseley GL (2003) A pain neuromatrix approach to patients with chronic pain. Man Ther 8:130 – 140
60. Murphy PL, Courtney TK (2000) Low back pain disability: relative costs by antecedent and industry group. Am J Ind Med 37:558 – 571
61. Nordin M, Lis A, Weiser S, Halpern M, Campello M (2004) Non-specific low back pain: Current issues in treatment. In: Frymoyer J, Wiesel S (eds) The Adult & Pediatric Spine. Lippincott Williams & Wilkins, Philadelphia, pp 307 – 321
62. Nordin M, Weiser S, Van Doorn JW (1998) Non-specific low back pain. In: Rom W (ed) Environmental and occupational medicine. Lippincott-Raven Publishers, Philadelphia, pp 947 – 956
63. Nordin M, Welser S, Campello MA, Pietrek M (2002) Self-care techniques for acute episodes of low back pain. Best Pract Res Clin Rheumatol 16:89 – 104
64. O'Sullivan P (2005) Diagnosis and classification of chronic low back pain disorders: maladaptive movement and motor control impairments as underlying mechanism. Man Ther 10:242 – 255
65. Pallay RM, Seger W, Adler JL, Ettlinger RE, Quaidoo EA, Lipetz R, O'Brien K, Mucciola L, Skalky CS, Petruschke RA, Bohidar NR, Geba GP (2004) Etoricoxib reduced pain and disability and improved quality of life in patients with chronic low back pain: a 3 month, randomized, controlled trial. Scand J Rheumatol 33:257 – 266
66. Royal College of General Practitioners (2001) Clinical guidelines for the management of acute low back pain. Royal College of General Practitioners, London
67. Praemer A, Furner S, Rice D (1992) In: Musculoskeletal conditions in the United States. American Academy of Orthopaedic Surgeons (AAOS). Parkridge Illinois, pp 3 – 19
68. Pratzel HG, Alken RG, Ramm S (1996) Efficacy and tolerance of repeated oral doses of tolperisone hydrochloride in the treatment of painful reflex muscle spasm: results of a prospective placebo-controlled double-blind trial. Pain 67:417 – 425
69. Salerno SM, Browning R, Jackson JL (2002) The effect of antidepressant treatment on chronic back pain: a meta-analysis. Arch Intern Med 162:19 – 24
70. Salzmann E, Pforringer W, Paal G, Gierend M (1992) Treatment of chronic low-back syndrome with tetrazepam in a placebo controlled double-blind trial. J Drug Dev 4:219 – 228
71. Schmidt CO, Kohlmann T (2005) [What do we know about the symptoms of back pain? Epidemiological results on prevalence, incidence, progression and risk factors]. Z Orthop Ihre Grenzgeb 143:292 – 298
72. Staiger TO, Gaster B, Sullivan MD, Deyo RA (2003) Systematic review of antidepressants in the treatment of chronic low back pain. Spine 28:2540 – 2545
73. Sweetman BJ, Baig A, Parsons DL (1987) Mefenamic acid, chlormezanone-paracetamol, ethoheptazine-aspirin-meprobamate: a comparative study in acute low back pain. Br J Clin Pract 41:619 – 624
74. Szpalski M, Hayez JP (1994) Objective functional assessment of the efficacy of tenoxicam in

the treatment of acute low back pain. A double-blind placebo-controlled study. Br J Rheumatol 33:74 – 78
75. Torstensen TA, Ljunggren AE, Meen HD, Odland E, Mowinckel P, Geijerstam S (1998) Efficiency and costs of medical exercise therapy, conventional physiotherapy, and self-exercise in patients with chronic low back pain. A pragmatic, randomized, single-blinded, controlled trial with 1-year follow-up. Spine 23:2616 – 2624
76. van Tulder M, Koes B, Bombardier C (2002) Low back pain. Best Pract Res Clin Rheumatol 16:761 – 775
77. van Tulder M, Malmivaara A, Esmail R, Koes B (2000) Exercise therapy for low back pain: a systematic review within the framework of the Cochrane Collaboration Back Review Group. Spine 25:2784 – 2796
78. van Tulder MW, Koes BW, Bouter LM (1997) Conservative treatment of acute and chronic nonspecific low back pain. A systematic review of randomized controlled trials of the most common interventions. Spine 22:2128 – 2156
79. van Tulder MW, Ostelo R, Vlaeyen JW, Linton SJ, Morley SJ, Assendelft WJ (2001) Behavioral treatment for chronic low back pain: a systematic review within the framework of the Cochrane Back Review Group. Spine 26:270 – 281
80. Videman T, Heikkila J, Partanen T (1984) Double-blind parallel study of meptazinol versus diflunisal in the treatment of lumbago. Curr Med Res Opin 9:246 – 252
81. Volinn E, Van Koevering D, Loeser JD (1991) Back sprain in industry. The role of socioeconomic factors in chronicity. Spine 16:542 – 548
82. Waddell G (2004) The Back Pain Revolution. Elsevier
83. Waddell G, Gibson A, Gran I (2000) Surgical treatment of lumbar disc prolapse and degenerative lumbar disc disease. In: Nachemson A, Jonsson E (eds) Neck and back pain. Lippincott Williams & Wilkins, Philadelphia, pp 305 – 325
84. Waddell G, McIntosh A, Hutchinson A (1999) Low back pain evidence review. Royal College of Practitioners, London
85. Weber H, Aasand G (1980) The effect of phenylbutazone on patients with acute lumbago-sciatica. A double blind trial. J Oslo City Hosp 30:69 – 72
86. Weber H, Holme I, Amlie E (1993) The natural course of acute sciatica with nerve root symptoms in a double-blind placebo-controlled trial evaluating the effect of piroxicam. Spine 18:1433 – 1438
87. Wiesel SW, Cuckler JM, Deluca F, Jones F, Zeide MS, Rothman RH (1980) Acute low-back pain. An objective analysis of conservative therapy. Spine 5:324 – 330
88. Wörz R, Bolten W, Heller J, Krainick U, Pergande G (1996) Flupirtin im Vergleich zu Chlormezanon und Placebo bei chronischen muskuloskelettalen Rückenschmerzen. Fortschritte der Therapie 114:500 – 504

# 22 Postoperative Rehabilitation

Florian Brunner, Shira Schecter-Weiner, Annina Schmid, Rudolf Kissling

## Core Messages

- ✔ The goal of rehabilitation is to restore optimal patient function in all spheres of life, including the medical, social, emotional, and vocational dimensions
- ✔ The key to successful rehabilitation management is understanding the relationship between selected target problems including impaired bodily functions and structures, as well as psychosocial and environmental factors
- ✔ The primary goal of postoperative rehabilitation is to decrease pain and to restore optimal function in activities of daily living, including household and community skills
- ✔ To promote and maximize the individual's recovery, rehabilitation interventions must be planned with regard for the three stages of wound healing (inflammation, proliferation, remodeling/adaptation)
- ✔ A careful preoperative assessment is essential in order to establish realistic and attainable postoperative goals
- ✔ The goal of rehabilitation during the first week after surgery is to achieve the best possible independence in activities of daily living (ADL) prior to discharge from the hospital
- ✔ During the first 4–6 weeks postoperatively, no supervised rehabilitation is usually needed. After biological healing, stretching and strengthening exercises can be progressed as tolerated by the patient and according to the surgeon's protocol
- ✔ Four to 6 months postoperatively, the patient should return to optimal function and work status and continued physical activity should be encouraged for ideal long-term outcome

## Epidemiology

The epidemiology of postoperative rehabilitation after spinal surgery is not well explored. This lack of evidence includes not only the epidemiology but also the efficacy of postoperative rehabilitation after spinal surgery. So far, no comprehensive guidelines about this topic have been published. There is some evidence for the efficacy of postoperative rehabilitation after disc surgery [4, 6, 8, 10, 17, 21, 25].

The scientific evidence for postoperative rehabilitation is sparse

In this setting, it is important to emphasize that the contents of this chapter are based on experience in common clinical practice rather than results from randomized controlled trials. Where appropriate, our recommendations are enhanced by evidence from the literature. We do not imply that the recommendations given in this chapter are universally applicable. However, they have been shown anecdotally to be efficient in a third level spine referral center.

## Conceptional Background

### Theoretical Considerations

Rehabilitation medicine may be defined as the multi- and interdisciplinary approach to optimizing a patient's function and health subsequent to medical treatment [28]. The goal of rehabilitation is to restore optimal patient function in all spheres of life, including:

- medical dimensions
- social dimensions
- emotional dimensions
- vocational dimensions

The **objectives of rehabilitation** can be centered around three strategies, i.e.

- treatment strategy
- rehabilitative strategy
- preventive strategy

Rehabilitation encompasses treatment of impaired body structures and functions (treatment strategy); aims to overcome impaired bodily functions, activity limitations and participation restrictions (rehabilitative strategy); and aims to prevent further symptoms and disability (preventive strategy) [28].

The goal is to restore optimal patient function in all spheres of life

Although an underlying condition may not be cured or prevented, rehabilitation can minimize symptoms, disability and related health care costs, a benefit for both the individual and society [29].

In 1980 the World Health Organization published the International Classification of Impairments, Disabilities, and Handicaps (ICIDH) as a scheme for the consequences of disease [38]. This classification was revised in 2001, and renamed the International Classification of Functioning, Disability and Health (ICF) [39]. The ICF classification describes situations with regard to human functioning and its restrictions, and serves as a framework to organize this information in two parts: the first part deals with functioning and disability; the second part covers contextual factors.

According to the ICF classification, the disability of a patient can be conceptualized within **three related system domains**:

- organ domain or biological system
- person domain
- social domain

Limitations or deficits within these domains lie in three respective dimensions (Table 1):

- impairment
- activity
- participation

**Table 1.** Summary of rehabilitation targets and domains

| Target | Domain | Description |
|---|---|---|
| Impairment | organ domain | implies any loss or abnormal function of an organ or a system (biological or psychological) |
| Activity | person domain | performance of individual tasks or activities by the person, including activities of daily living (dressing, driving, cooking) |
| Participation | social domain | person's involvement in life situations, during leisure activities or at work |

Any restriction of a person's ability to perform a task or activity within a range considered normal for an individual of a particular age results in disability.

Environmental and personal contextual factors influence a person's health condition

According to the ICF Classification, a person's health condition is also influenced by contextual factors, which represent the complete background of an individual's life and living situation. Within the **contextual factors**, environmental factors make up the physical, social and attitudinal environment in which people live and conduct their lives (e.g., natural environments, relationships, attitudes, values and beliefs). **Personal factors** reflect the particular background of an individual's life and living situation and comprise features that are not a physical component of a health condition (e.g., gender, age, race, fitness and lifestyle). These factors can have a positive or a negative influence on the patient.

It has been shown that participation in a **rehabilitation program** after disc surgery has a considerable positive impact on outcome and is an important supplement to surgery [20, 24]. The benefit of a rehabilitation program after fusion surgery has not been studied in the past.

The benefits of postoperative rehabilitation programs are not well explored

There is persistent controversy about the duration and necessity for postoperative restriction of activities after spinal surgery, as well as specific rehabilitation protocols [5]. The individual preferences and protocols of the surgeons as well as the fear of reinjury after the intervention are possible explanations for this controversy.

## Anatomical and Surgical Considerations

A rehabilitation program has to be planned with respect for the postoperative phase of wound healing. **Wound healing** is a physiological response of the body to the surgery and can be divided into **three stages**:

- inflammation (0 – 2 days)
- proliferation (3 – 21 days)
- remodeling/adaptation (21 – 300 days) [32]

Rehabilitation must respect postoperative soft-tissue healing

Throughout the postoperative rehabilitation process it is crucial to plan and implement interventions which consider these different stages. In spinal surgery, it is especially important to respect these stages since there is a greater degree of muscle detachment than in other orthopedic fields.

Especially **posterior surgery** of the spine exposes and traumatizes the paravertebral muscles. Deep paravertebral muscles such as the mm. rotatores and mm. multifidi serve as important stabilizers, especially in the lumbar spine. In contrast to other orthopedic fields such as hip and knee surgery, there is no way to avoid extensive muscle detachment and retraction in posterior spine surgery. Posterior dissection carries the potential risk of denervation of the paraspinal musculature leading to weakness and **muscle dysfunction** [11]. As a direct consequence, a decrease in trunk strength after posterior lumbar surgery was shown [11, 22]. Prolonged retraction of the paraspinal muscle during spinal surgery may produce ischemic damage. This ischemic damage may be the underlying cause of electrophysiological [16] and magnetic resonance changes [12]. However, there is no correlation with pain or other clinical symptoms after a posterior surgical approach to the spine [37].

Muscle detachment in posterior spine surgery limits early rehabilitation

If instrumentation has been performed, care must be taken to protect the operation site until solid fusion has occurred. This takes approximately 3 – 4 months, depending on the bone quality and the type of instrumentation. Torsional stability requires solid fusion, which may need some more time.

## Individual and Societal Considerations

Several factors must be considered when identifying the postoperative goals for this patient population:

- preoperative status
- patient expectations
- comorbidities
- work situation
- societal factors

The task of the surgeon is to inform the patient about realistic surgical goals

For the individual patient, function can have a variety of meanings. The entire health care team interacting with the patient must be aware of what optimal function means to a particular patient, and to establish common realistic goals based on physician and patient expectations.

Surgery is successful if the patient's expectations are met

Preoperatively, the physician is obliged to explain to the patient what to expect in the postoperative period and how realistically the patients' expectations can be met by the intervention [19, 27]. The functional status of the patient will greatly influence the intensity of rehabilitation necessary to reach the postoperative goals. Patients who are able to maintain a high level of preoperative functioning, including work status, are expected to regain function more easily [2]. The underlying condition and comorbidities will negatively impact the postoperative process, and consequently the rate and intensity of rehabilitation. **Clinical factors** shown to be associated with unexpected critical care management and prolonged hospitalization include preexisting myelopathy, extent of decompression, presence of pulmonary disease, hypertension, cardiovascular disease and diabetes mellitus [15]. Preoperative sick leave [14], compensation payments and litigation [30] are important predictors of poor outcomes after low back surgery.

## Indications for Postoperative Spinal Rehabilitation

Rehabilitation addresses the causes and secondary effects of injury and illness

Care must be taken to distinguish between postoperative follow-up treatment and rehabilitation. Functional status and health are different when viewed from the medical versus the rehabilitation perspective. According to the biomedical model, a treatment is directed at the cause of disease without considering the secondary effects of illness. Rehabilitation complies with the **biopsychosocial model** and produces multiple simultaneous interventions addressing both the cause and secondary effects of injury and illness.

Rehabilitation is indicated if a persistent, complex and multimodal malfunction exists

Rehabilitation is clearly indicated if a persistent, complex and multimodal malfunction exists, which may require a multidisciplinary treatment plan and is likely to be successful. A complex problem (impairment) that impacts on function, activity or participation may benefit from rehabilitation.

To clarify the need and to set the goals for an intervention in rehabilitation, the following prerequisites must be assessed and fulfilled in a cumulative manner. A **rehabilitation treatment plan** can be prescribed after considering:

- need for rehabilitation
- capacity for rehabilitation
- rehabilitation potential/prognosis

Rehabilitation is needed if a health impairment and activity/participation interference exist simultaneously. A patient is considered capable of achieving good results if their somatic and psychological status allows participation in an appropriate rehabilitation program. Important factors to identify are the motivation,

**compliance** and capacity of the individual. An evaluation of the rehabilitation potential is based on the prognosis of the success of the rehabilitation intervention and on its durability. This implies that the goals are attainable and the effects sustainable.

### General Goals

The primary goal of postoperative rehabilitation after spinal surgery is to decrease pain and to achieve optimal independence in all activities of daily living, leading to a reintegration into work and social life. Patients typically suffer from a number of problems postoperatively including pain, fatigue, and difficulties with the activities of daily living (personal, household and social). **Prerequisites for successful rehabilitation** management are:

- the understanding of the relationship between selected target problems and impaired structure, i.e., bodily functions
- the presence of confounding psychosocial and environmental factors

The primary goal is to decrease pain and to optimize independence in all daily activities

### Specific Goals

Not all impaired bodily functions, structures and contextual factors may be relevant to the target problem. Furthermore, not all bodily functions, structures and contextual factors relevant to the problem are modifiable or of equal importance. When planning the rehabilitation intervention, it is thus necessary to identify and address those factors with the greatest potential for improvement and of importance to the patient, and to set priorities by selecting target problems, and to define realistic goals and a realistic time frame for achieving them.

Successful rehabilitation identifies and addresses factors with the greatest potential for improvement

## Principles of Postoperative Rehabilitation

### Preoperative Assessment

A thorough preoperative assessment forms the basis for an effective postoperative rehabilitation. It is essential to establish realistic and attainable postoperative goals (Table 2):

A careful physical assessment helps to identify realistic functional goals

**Table 2.** Checklist for preoperative assessment

| Questions to be considered by the surgeon |
|---|
| • Is the surgical procedure appropriate considering the patient's physical and functional status? |
| • Are all comorbidities optimally controlled? |
| • Can I expect this patient to progress to a level of household independence within several postoperative days? |
| • Is there a realistic support system in place to support the patient through the recovery process? |
| • Will inpatient rehabilitation or home health assistance likely be needed? |
| • Might the patient need equipment and/or household modifications due to physical deconditioning such as a rolling walker, elevated commode, etc.? |
| • Does the diagnosis correlate with the reported symptoms and functional status? If not, a cognitive assessment might be beneficial |
| • Are there any anticipated obstacles to recovery? |

In order to plan **postoperative rehabilitation**, several aspects must be considered:

- specific needs of the patient
- comorbidity

- rehabilitation potential
- goals of rehabilitation

The rehabilitation protocol, including the necessary interventions as well as their intensity and duration, is established through the synoptic assessment of the aforementioned aspects. A careful physical assessment can aid in deciding on the need and type of postoperative rehabilitation, i.e., home-exercise program, assisted physiotherapy, in-hospital aftertreatment, or support at home.

An effective rehabilitation begins preoperatively

Once the patient's physical capabilities have been assessed, an attempt should be made to correlate these findings with their functional status. Physical limitations and functional capacity are not always in proportion. In cases where they are out of proportion, an attempt must be made to overcome obstacles for rehabilitation as soon as the preoperative period.

Other variables that should be considered during the preoperative assessment extend beyond physical findings and include:

- secondary gains
- financial incentives
- patient's expectations

Although not directly related to the underlying condition, **secondary gains** provide some indirect benefit to the individual and may represent an obstacle to recovery.

Pending litigation or workers' compensation benefits have the potential to interfere with the postoperative result and have been linked to a poor postoperative outcome [13, 30]. These financial incentives must be identified preoperatively and should be solved prior to an indication for surgery.

The expectations of the patient and physician must be synchronized preoperatively

Another significant matter to assess preoperatively is that of **expectation**. This includes both the expectations of the patient and the surgeon. Synchronizing both dimensions is critical for an optimal outcome and satisfaction of the patient and physician.

## Postoperative Rehabilitation

As indicated above, effective rehabilitation has to **begin preoperatively**. Based on the time elapsed after surgery, the postoperative rehabilitation can be differentiated into **three phases** (Table 3):

**Table 3.** Synopsis of postoperative rehabilitation

| Period | Goals | Assessment and tools |
|---|---|---|
| Preoperative assessment | establish realistic and attainable postoperative goals | • needs of the patient<br>• rehabilitation potential<br>• goals of rehabilitation<br>• type of intervention<br>• intensity and duration of required rehabilitation |
| Immediate aftercare | achieve optimal independence in activities of daily living prior to discharge | • early mobilization<br>• bone and soft tissue healing<br>• activities of daily living (questionnaire)<br>• home exercise program |
| Rehabilitation | promote tissue healing and progress to more strenuous exercises (3 months postoperatively) | • home exercise program (gradually increasing activity)<br>• after tissue healing: stretching/strengthening exercises as tolerated |
| Aftercare | minimize persistent deficits in activities of daily living and return to work | • home exercise program<br>• restart of recreational activities<br>• instruction of preventive measures |

The progression of each of these periods depends on the individual needs of the patient, goals of rehabilitation, interventions performed, duration of the treatment and response to treatment.

### Immediate Aftercare

This period starts at surgery and ends with the discharge from hospital. Besides routine postoperative medical and wound care, the period includes physical therapy and possibly occupational therapy. The primary objective of rehabilitation during the immediate care stage is independent ambulation and a regaining of the **activities of daily living**. The aim of early mobilization is to avoid a deconditioning of various body systems following surgery. Possible obstacles to achieving successful early mobilization are patient fear avoidance beliefs, postoperative pain, low postoperative levels of hemoglobin, vasovagal reactions and hypotonic blood pressure.

The primary goal of rehabilitation is to regain activities of daily living

Physical therapy starts on the first postoperative day with a neurological check and an evaluation of the current status of the patient. Prior to initiating treatment, patients should be questioned regarding the effectiveness of their pain management and if necessary the pain medication must be modified to allow for a painless initial mobilization. The patient should also be reassured about the safety of postoperative movement. Common immediate care rehabilitation procedures include:

- deep diaphragmatic breathing
- ankle range of motion

The goal of **diaphragmatic breathing** is to promote full lung and chest expansion, and to clear the airways of secretions secondary to anesthesia, thus avoiding atelectasis. Furthermore, oxygen saturation in the blood is maximized prior to progressing from a reclining to an upright position and relaxation can be achieved. Exercises for ankle range of motion are to promote good circulation and to avoid the development of blood clots secondary to inactivity.

Early mobilization is important

#### *Activities of Daily Living*

The term "activities of daily living" (ADL) refers to the basic tasks of everyday life, such as eating, bathing, dressing, toileting, and transferring. A distinction is made between upper and lower body management, especially for bathing and dressing. After spinal surgery, optimizing independence in ADL prior to discharge from the hospital is an important goal. Few studies exist that support or describe an optimal immediate postoperative rehabilitation protocol and therefore recommendations are based on clinical practice. Throughout the rehabilitation process care must be taken to protect the wound and any instrumentation of the spine (Tables 4, 5).

Regaining the activities of daily living is mandatory prior to discharge

### Rehabilitation

Depending on the type of surgery, the rehabilitation period lasts from discharge until approximately 3–6 months. Common clinical practice shows that besides the **home exercise program**, no specific rehabilitative intervention is needed for the first 4–6 weeks after surgery. However, the patient should perform the home exercise program on a regular basis.

A home exercise program suffices for the first 4–6 weeks

The aim of this home program is to place the patient in an **active role of self-care**, and to promote self-confidence and body awareness. It usually consists of a few stabilizing and stretching exercises that can be readily incorporated into the

**Table 4.** Activities of daily living tasks

| Task | Goal | |
|---|---|---|
| Bed mobility including log rolling | To limit rotation and enable the patient to use their arms as a support for independent transfer from supine to sitting position. A side grab bar may be added to the bed in the hospital or at home | |
| Transfers | To promote independence in all sit to stand transfers. In situations where the patient is weak in their arms or quadriceps muscle, the addition of grab bars, firm cushions on a chair or an elevated commode may be helpful | |
| Ambulation on level and uneven surfaces | To promote independence in all ambulation on level surfaces, stairs and inclines. If balance is a problem, the addition of a rolling walker or cane might be necessary. Avoid heavy ambulation devices that require repetitive lifting as this may place unnecessary strain on the low back. The patients are encouraged to increase the walking distance at home continuously |  |

**Table 5.** ADL tasks as instructed in group training

| Task | Goal | |
|---|---|---|
| Basic lifting and postural guidelines | To educate the patient about basic body mechanics and postural awareness. If specific restrictions are advised by the surgeon, the patient should be provided with clear and concise instructions. During the first 6 weeks after surgery, lifting more than 5 kg is not encouraged |  |

**Table 5.** (*Cont.*)

| Task | Goal | |
|---|---|---|
| Getting dressed | To instruct the patient about getting dressed with minimal loading of the spine | |
| Sitting | To inform the patient about the optimal sitting posture and duration. If necessary, a supportive pillow is recommended | |
| Driving | To instruct a patient on how to get in and out of a car. The position of the seat should be discussed as well as the importance of short breaks when driving over a longer period of time | |
| Taking a shower or bath | To evaluate self-care at home | |

patient's daily routine. To ensure good compliance and motivation, it is of great importance that the exercises are simple and of short duration. Finally, the home exercise program must be customized in conjunction with the surgeon, based on the surgical procedure, the associated contraindications, and the current functional status of the patient (Tables 6, 7).

**Table 6.** Home exercise program after lumbar surgery

| Exercise | Goal | |
|---|---|---|
| Activation of m. transversus abdominis | To increase the ability of selective transverse abdominis activation | |
| Coordination of m. transversus abdominis while moving the lower extremity | To increase independency between active lumbar spine stabilization and movement of the extremity | |
| Stabilization of the trunk muscles and strengthening of the lower extremity muscles | Exercise with regard to activities of daily living (sit to stand) and body awareness | |
| Stretching of the gluteal muscles | To increase flexibility of the gluteal muscles and gentle mobilization of the lower lumbar spine into flexion | |

However, the therapist may provide patients with educational information regarding back care, basic body mechanics and practical tips for self-care. This can be in the form of group education, brochures and accurate internet web sites.

After soft tissue healing, stretching and strengthening exercises can be intensified

Approximately 3 months after surgery, biological healing is complete and exercises can be progressed as tolerated by the patient and according to the surgeon's protocol. Stretching and strengthening exercises can be intensified and should be performed two to three times a week [23]. In addition, it has been shown that an aerobic exercise program can be beneficial for successful rehabilitation [3].

Depending on the intervention and pain tolerance, the patient should be as active and independent as possible, returning to most of their daily activities.

If the postoperative reassessment by the surgeon at 4–6 weeks postoperatively reveals any difficulties or irregularities, the patient is referred to physical therapy. Depending on the patient's presentation, the physical therapist will provide an individual treatment and management plan aiming to restore normal func-

**Table 7.** Home exercise program after cervical surgery

| Exercise | Goal | |
|---|---|---|
| Activation of the deep neck flexors | To increase the ability of selective deep neck flexor activation | |
| Stabilization of the cervical spine | To facilitate body awareness and improve cervical posture |  |
| Stabilization of the cervical spine during movement | To facilitate optimal cervical posture in activities of daily living (sit to stand) |  |

tion, activity and participation. The intervention is planned with regard for the surgical procedure and is based on:

- loading disorder: symptoms in sustained positions
- movement disorder
- motor control disorder

If the patient's complaints are of a loading disorder, the treatment of choice would be mobilization of possible hypomobile segments in order to restore optimal posture. Moreover, advice on posture, strengthening of impaired muscles and pain-relieving positions and ergonomics is given to the patient.

Treatment of a **movement disorder** focuses on improving hypomobile movement segments and restoring optimal muscle extensibility. Stabilizing exercises with individual focus on the impaired muscle function and postural advice are the main management strategies for a motor control disorder.

In case of a rehabilitation deficit, individual treatment and management is provided after 4–6 weeks

### Aftercare/Prevention

The aim of aftercare is to maximize the individual's resumption of all ADL

The aftercare period starts at around 3 months after surgery, when biological healing is complete and exercises can be progressed as tolerated by the patient and depending on the intervention. The aim of aftercare is to maximize the individual's resumption of all functional activities of daily living including personal, social, and occupational domains. The rehabilitation program should follow the current guidelines of back and neck pain management in which physical, therapeutic, and recreational exercises are recommended [1]. The continuation of a back- or neck-related home exercise program should be encouraged, with an emphasis on neck and trunk flexibility and strength. **Aerobic conditioning** should also be encouraged as the benefits to the entire body are evident [1]. Extensive evidence exists legitimizing the need for activity as compared to rest, although to date it remains unclear whether any specific type of exercise is more effective than any other [31].

#### *Physical Rehabilitation Training*

If a patient still has deficits in function, activity or participation at 3 months postoperatively, a physical rehabilitation program can be started. This rehabilitation program should be performed two to three times a week and continuously intensified [23]. In addition, it has been shown that an aerobic exercise program can be beneficial for successful rehabilitation [3]. Rehabilitation after spinal surgery will be based on the PRT system (**physical rehabilitation training**) [32]. Upon the first appointment, the patient's need for their ADL and their loading ability will be analyzed in order to compose an individual program to eliminate the remaining dysfunctions specifically.

The **standard program** progresses according to the following stages:

- proprioception
- strength endurance
- acceleration/deceleration training

Physical rehabilitation consists of coordination, strength endurance and acceleration/deceleration training

**Proprioception** is trained first in a motor learning approach to improve muscle coordination. This stage of the training will last 3–6 weeks on average and is underloaded, which means the patient can perform the training without fatigue in the target muscles. The **strength endurance** stage is then reached and the patient will progress until they can perform 8–14 repetitions under load while provoking fatigue in the target muscles. Once the patient can perform the exercises with the required weight for two to three consecutive trainings, the program is progressed to the next stage. **Acceleration and deceleration** training, which differ from strength endurance training in the rhythm of the performance, is the next stage of the training. The same exercises are implemented at an increased speed than before. This promotes further adaptation and remodeling of the connective tissues.

### Return to Work

Return to work is key in postoperative rehabilitation

The return to work is not closely correlated with the extent of the intervention. On the contrary, confounding factors seem to play an even more important role [9, 26]. The rate of resumption of heavy work is difficult to determine and will be dictated by the surgeon with consideration of the operative procedure and the degree of postoperative soft tissue and bony alterations. This decision will often be anecdotal and will vary from surgeon to surgeon. We recommend that the patient resumes work as soon as possible.

**Table 8.** Home exercise program after lumbar surgery

| Exercise | Goal | |
|---|---|---|
| Dead lift | To stabilize the trunk during bending activities |  |
| | Progression: dead lift in extension |  |
| Front press | To stabilize the trunk during upper extremity movements | |
| Bent over barbell row | To stabilize the trunk in an inclined position |  |

**Table 8.** (*Cont.*)

| Exercise | Goal | |
|---|---|---|
| Bent over barbell row | Progression: bent over dumbbell rotation | |
| Barbell rotation | To stabilize the trunk during rotational activities | 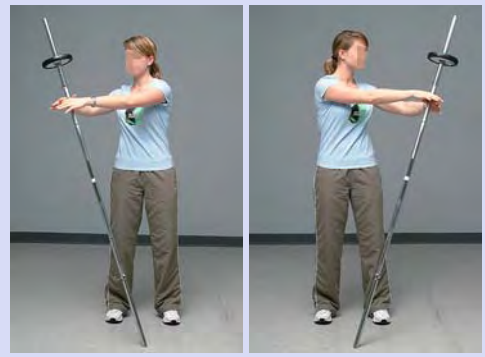 |

### Recreational Activities

Activity resumption should be as soon as possible

Most studies investigating **return to sports** and recreational activities were performed on athletes [7, 36, 40]. It has been found that different factors may influence the time to return to recreational activities. Among them are the patient's preoperative health condition, age, and quality of surgery. It is suggested that patient motivation influences recovery from spinal surgery and return to recreational activities [36]. Limited data assist with decision-making for return to sport after (thoraco-) lumbar fusion [40]. Some of the criteria used to determine return to play included a solid fusion based on clinical assessment and imaging studies and full recovery as determined by near normal range of motion and normal muscular strength. Return to sport decisions must be made on an individual basis, and various factors, such as the number of levels fused, must be taken into account.

## Obstacles for Rehabilitation

### Morphological Obstacles and General Medical Obstacles

Care must be taken to distinguish between procedure-specific morphological obstacles and general medical obstacles. Morphological obstacles for rehabilitation can occur immediately postoperatively or after a latency of a few days. It is important to emphasize the difference between persistent and new symptoms. Possible immediate postoperative complications include:

- neural injury (de novo)
- neural compression (persistent or de novo, e.g., epidural bleeding)
- early infection

Late postoperative morphological obstacles for rehabilitation include:

- non-union
- late infection
- persistent neurological dysfunction
- instability (de novo or persistent)
- medical complications (e.g., myocardial infarction, stroke, pulmonary embolus)
- other comorbidities

Comorbidities are frequent obstacles for recovery

During the physical assessment a patient's medical history is critical in order to identify comorbidities such as hypertension, diabetes mellitus, and pulmonary and cardiovascular diseases. These comorbidities have been linked to the need for postoperative critical care and increased hospitalization [15].

## Psychosocial Obstacles

**Psychosocial obstacles** for rehabilitation include:

- psychosocial factors (psychological, behavioral, social factors) [35] (see Chapter 11)
- fear-avoidance behavior [34]
- kinesiophobia [18]

A clinical assessment of risk factors for delayed recovery is required and must include attention to psychosocial factors (Chapter 21). The **fear avoidance model** describes how patients avoid normal activities if they believe these activities will provoke pain. Fear of movement or (re)injury, also called kinesiophobia, is associated with avoidance behaviors that increase functional disability in chronic low back pain. **Kinesiophobia** is an excessive, irrational and debilitating fear of physical movement and activity resulting from a feeling of vulnerability to painful injury or reinjury [33]. Treatment to reduce this fear must include cognitive behavioral techniques that address the perceived threat of movement or pain, in conjunction with progressive exercise and function.

## Work-Related Obstacles

As outlined in Chapter 21, **job satisfaction** has been associated with low back pain disability. Similarly, psychological aspects of work such as:

- occupational mental stress
- general job satisfaction
- job related resignation

were shown to be related to postoperative relief of disability [26].

### Recapitulation

**Epidemiology.** The literature is sparse on postoperative rehabilitation after spinal surgery. This lack of evidence includes not only the epidemiology but also the efficacy of postoperative rehabilitation after spinal surgery.

**Conceptional background.** Ideally, the rehabilitation process is initiated prior to surgery through a precise and thorough **preoperative assessment**. Initially an accurate diagnosis is imperative so that the physician can identify an optimal surgical intervention. A thorough physical examination and medical history is useful for **identifying comorbidities**, since these have the potential to impede the rate of postoperative rehabilitation. The patient's **functional status** must also be carefully scrutinized.

An international classification system, ICF, has been established for determining the impact of a condition or illness with regard to human functioning and its restrictions. This system takes into account function and **disability** (impairment) with consideration of contextual factors (participation in the activities of daily living, and work and leisure pursuits). Based on the physical and functional assessments, postoperative rehabilitation plans are initiated. The physician and patient must have an unambiguous understanding of the other's expectations and the role of each of them in the postoperative recovery. After surgery, an ongoing reassessment of the patient's status is indicated and the rehabilitation plans are modified accordingly.

**Principles of postoperative rehabilitation.** The postoperative period can be divided into three phases: Immediate aftercare, rehabilitation and aftercare. **Immediate aftercare** begins with an evaluation by the therapist to determine the individual's current physical capacity and to anticipate special needs. Pain management must be carefully addressed as preoperative pain is often the driving factor leading to surgery and can impede the patient's performance due to the physical and psychological implications. Treatment will include transfer and gait training, exercise instruction and education on basic back care. This will continue throughout the inpatient period or until independence is achieved.

The **rehabilitation phase** continues until 6 months postoperatively. During this phase patients gradually increase their activities of daily living, the home exercise program continues and all progresses under the guidance of the treating physician. Any inconsistencies between function and physical status must be addressed. During the **aftercare phase**, patients are expected to progress further in their functional level both personally and within the occupational and social spheres. Continued exercise is encouraged, both low back stretching and strengthening as well as general aerobic conditioning.

To date the existing scientific literature supports exercise after spinal surgery, although no particular form of exercise has been proven optimal. Little exists in the literature describing the ideal postoperative rehabilitation protocol, and common clinical practice is the point of reference. All involved in spinal surgery rehabilitation must strive to fill these voids.

## Key Articles

**WHO (2001) International Classification of Functioning, Disability and Health. ICF, Geneva**
The International Classification of Functioning, Disability and Health was published by the World Health Organization. It describes situations with regard to human functioning and its restrictions from a biological, individual and social perspective.

**Ostelo RW, de Vet HC, Waddell G, Kerckhoffs MR, Leffers P, van Tulder M (2003) Rehabilitation following first-time lumbar disc surgery: a systematic review within the framework of the Cochrane collaboration. Spine 28:209–218**
Systematic review of randomized controlled trials about rehabilitation following first-time lumbar disc surgery. No evidence exists for restriction of activity after lumbar surgery. Strong evidence is found for intensive exercise programs.

**Manniche C, Skall HF, Braendholt L, Christensen BH, Christophersen L, Ellegaard B, Heilbuth A, Ingerslev M, Jorgensen OE, Larsen E (1993) Clinical trial of postoperative dynamic back exercises after first lumbar discectomy. Spine 18:92–97**
Randomized controlled trial investigating a high intensity compared to a mild physical rehabilitation program after discectomy. An intensive exercise program appears to increase patient behavioural support and results in work capacity improvements and patient self-rated disability levels.

**Kjellby-Wendt G, Styf J (1998) Early active training after lumbar discectomy. A prospective, randomized, and controlled study. Acta Orthop Scand Suppl 23:2345–2351**
A randomized controlled trial demonstrating the advantages of an early active treatment program beginning immediately after lumbar discectomy compared to a less active program.

## References


1. Abenhaim L, Rossignol M, Valat JP, Nordin M, Avouac B, Blotman F, Charlot J, Dreiser RL, Legrand E, Rozenberg S, Vautravers P (2000) The role of activity in the therapeutic management of back pain. Report of the International Paris Task Force on Back Pain. Spine 25:1S–33S
2. Alaranta H, Hurme M, Einola S, Kallio V, Knuts LR, Torma T (1986) Rehabilitation after surgery for lumbar disc herniation: results of a randomized clinical trial. Int J Rehabil Res 9:247 – 257
3. Brennan GP, Shultz BB, Hood RS, Zahniser JC, Johnson SC, Gerber AH (1994) The effects of aerobic exercise after lumbar microdiscectomy. Spine 19:735 – 739
4. Burke SA, Harms-Constas CK, Aden PS (1994) Return to work/work retention outcomes of a functional restoration program. A multi-center, prospective study with a comparison group. Spine 19:1880 – 1885
5. Carragee EJ, Helms E, O'Sullivan GS (1996) Are postoperative activity restrictions necessary after posterior lumbar discectomy? A prospective study of outcomes in 50 consecutive cases. Spine 21:1893 – 1897
6. Danielsen JM, Johnsen R, Kibsgaard SK, Hellevik E (2000) Early aggressive exercise for postoperative rehabilitation after discectomy. Spine 25:1015 – 1020
7. Debnath UK, Freeman BJ, Gregory P, de la Harpe D, Kerslake RW, Webb JK (2003) Clinical outcome and return to sport after the surgical treatment of spondylolysis in young athletes. J Bone Joint Surg Br 85:244 – 249
8. Dolan P, Greenfield K, Nelson RJ, Nelson IW (2000) Can exercise therapy improve the outcome of microdiscectomy? Spine 25:1523 – 1532
9. Donceel P, Du BM (1998) Fitness for work after surgery for lumbar disc herniation: a retrospective study. Eur Spine J 7:29 – 35
10. Donceel P, Du BM, Lahaye D (1999) Return to work after surgery for lumbar disc herniation. A rehabilitation-oriented approach in insurance medicine. Spine 24:872 – 876
11. Gejo R, Kawaguchi Y, Kondoh T, Tabuchi E, Matsui H, Torii K, Ono T, Kimura T (2000) Magnetic resonance imaging and histologic evidence of postoperative back muscle injury in rats. Spine 25:941 – 946
12. Gejo R, Matsui H, Kawaguchi Y, Ishihara H, Tsuji H (1999) Serial changes in trunk muscle performance after posterior lumbar surgery. Spine 24:1023 – 1028
13. Greenough CG, Peterson MD, Hadlow S, Fraser RD (1998) Instrumented posterolateral lumbar fusion. Results and comparison with anterior interbody fusion. Spine 23:479 – 486
14. Hagg O, Fritzell P, Ekselius L, Nordwall A (2003) Predictors of outcome in fusion surgery for chronic low back pain. A report from the Swedish Lumbar Spine Study. Eur Spine J 12:22 – 33
15. Harris OA, Runnels JB, Matz PG (2001) Clinical factors associated with unexpected critical care management and prolonged hospitalization after elective cervical spine surgery. Critical Care Medicine 29:1898 – 1902
16. Johnson EW, Burkhart JA, Earl WC (1972) Electromyography in postlaminectomy patients. Archiv Phys Med Rehabil 53:407 – 409
17. Kjellby-Wendt G, Styf J (1998) Early active training after lumbar discectomy. A prospective, randomized, and controlled study. Acta Orthopaedica Scandinavica Suppl 23:2345 – 2351
18. Kori SH, Miller RP, Todd DD (1990) Kinesiophobia: a new view of chronic pain behaviour. Pain Management 3:35 – 43
19. Mahomed NN, Liang MH, Cook EF, Daltroy LH, Fortin PR, Fossel AH, Katz JN (2002) The importance of patient expectations in predicting functional outcomes after total joint arthroplasty. J Rheumatol 29:1273 – 1279
20. Manniche C, Asmussen K, Lauritsen B, Vinterberg H, Karbo H, Abildstrup S, Fischer-Nielsen K, Krebs R, Ibsen K (1993) Intensive dynamic back exercises with or without hyperextension in chronic back pain after surgery for lumbar disc protrusion. A clinical trial. Spine 18:560 – 567
21. Manniche C, Skall HF, Braendholt L, Christensen BH, Christophersen L, Ellegaard B, Heilbuth A, Ingerslev M, Jorgensen OE, Larsen E (1993) Clinical trial of postoperative dynamic back exercises after first lumbar discectomy. Spine 18:92 – 97
22. Mayer TG, Kondraske G, Mooney V, Carmichael TW, Butsch R (1989) Lumbar myoelectric spectral analysis for endurance assessment. A comparison of normals with deconditioned patients. Spine 14:986 – 991
23. Medicine ACoS (1991) Guidelines for Exercise Testing and Prescription. Lea & Febiger, Philadelphia
24. Ostelo RW, de Vet HC, Waddell G, Kerckhoffs MR, Leffers P, van Tulder M (2003) Rehabilitation following first-time lumbar disc surgery: a systematic review within the framework of the Cochrane collaboration. Spine 28:209 – 218
25. Ostelo RW, de Vet HC, Waddell G, Kerckhoffs MR, Leffers P, van Tulder MW (2002) Rehabilitation after lumbar disc surgery. Cochrane Database Syst Rev: CD003007

26. Schade V, Semmer N, Main CJ, Hora J, Boos N (1999) The impact of clinical, morphological, psychosocial and work-related factors on the outcome of lumbar discectomy. Pain 80: 239 – 249
27. Stambough JL (2001) Matching patient and physician expectations in spine surgery leads to improved outcomes. Spine J 1:234
28. Stucki G, Ewert T, Cieza A (2003) Value and application of the ICF in rehabilitation medicine. Disabil Rehabil 25:628 – 634
29. Stucki G, Sangha O (1997) Principles of rehabilitation. In: Klippel JH, Dieppe PA (eds) Rheumatology. Mosby, London
30. Taylor VM, Deyo RA, Ciol M, Farrar EL, Lawrence MS, Shonnard NH, Leek KM, McNeney B, Goldberg HI (2000) Patient-oriented outcomes from low back surgery: a community-based study. Spine 25:2445 – 2452
31. van Tulder MW, Malmivaara A, Esmail R, Koes BW (2000) Exercise therapy for low back pain. Cochrane Database Syst Rev:CD000335
32. Van Wingerden BAM (1995) Connective tissue in rehabilitation. Scipro Verlag, Vaduz
33. Vlaeyen JW, Kole-Snijders AM, Boeren RG, van Eek H (1995) Fear of movement/(re)injury in chronic low back pain and its relation to behavioral performance. Pain 62:363 – 372
34. Waddell G (2004) Beliefs about back pain. In: Back pain revolution. Churchill Livingstone, Edinburgh, pp 221 – 240
35. Waddell G, Bircher M, Finlayson D, Main CJ (1984) Symptoms and signs: physical disease or illness behaviour? British Medical Journal (Clinical Research Edition) 289:739 – 741
36. Watkins RGt, Williams LA, Watkins RG, 3rd (2003) Microscopic lumbar discectomy results for 60 cases in professional and Olympic athletes. Spine J 3:100 – 105
37. Weber BR, Grob D, Dvorak J, Muntener M (1997) Posterior surgical approach to the lumbar spine and its effect on the multifidus muscle. Spine 22:1765 – 1772
38. WHO (1980) ICIDH. International Classification of Impairments, Disabilities and Handicaps. WHO, Geneva
39. WHO (2001) International Classification of Functioning, Disability and Health: ICF. WHO, Geneva
40. Wright A, Ferree B, Tromanhauser S (1993) Spinal fusion in the athlete. Clinics Sports Medicine 12:599 – 602

# 23 Idiopathic Scoliosis

Mathias Haefeli, Kan Min

## Core Messages

- ✔ Idiopathic scoliosis is the most common structural spinal deformity in children and adolescents and affects about 2–3% of the adolescent population
- ✔ An asymmetrical vertebral growth of the anterior column with tethering of the posterior structures may be the cause of the deformity, but the exact underlying etiology is unknown
- ✔ Scoliosis is defined as a lateral curvature of the spine of at least 10° with vertebral rotation
- ✔ The most common adolescent idiopathic scoliosis is a thoracic curve to the right side
- ✔ Idiopathic scoliosis is usually accidentally detected as a trunk asymmetry and a rib hump
- ✔ Initial assessment of scoliosis patients includes a physical examination including a thorough neurological examination and anteroposterior/lateral radiographs of the whole spine
- ✔ Neurological abnormalities should prompt further investigations (MRI, neurophysiology)
- ✔ Risk factors for curve progression are young age, pre-menarchal, and large curve size at first presentation
- ✔ During growth, curves up to 25° usually do not require specific therapy except observation.
- ✔ Curves between 25° and 40° are usually treated with bracing whereas larger curves often are addressed surgically
- ✔ When not treated surgically thoracic curves between 50° and 70° are most likely to progress in adult life
- ✔ Long-term health related quality of life is comparable with non-affected controls but restrictive pulmonary disease may become a serious health problem in thoracic curves larger than 70°
- ✔ The goal of surgery is to prevent curve progression and correct the spinal deformity
- ✔ Surgery usually consists of curve correction and spinal fusion
- ✔ When spinal instrumentation and fusion is indicated, surgical procedures which spare motion segments are favorable
- ✔ The lower lumbar motion segments should be left unfused if possible
- ✔ The reconstruction or preservation of spinal balance is more important than the extent of the curve correction

## Epidemiology

Idiopathic scoliosis is the most common structural spinal deformity in children and adolescents. Scoliosis is defined as a coronal spinal curvature of at least 10° [37] with **rotation** of the vertebral bodies of unknown origin [36].

Scoliosis is defined as a coronal curve of at least 10° with vertebral rotation

About 80–90% of all idiopathic scoliosis cases develop during adolescence whereas about 10–20% develop between the age of 3 and 10 years and only about 1% affect younger patients [179, 184]. The **overall prevalence** of adolescent idiopathic scoliosis accounts for about 2–3% in the general population of this age group [97, 204]. The prevalence decreases to about 0.1–0.3% for curves larger than 30° [97, 228]. Large screening studies of adolescent idiopathic scoliosis revealed incidences of 1.2–13.6% depending on the criteria defining true scoliosis [6, 22, 23, 124, 162, 188].

Idiopathic scoliosis affects about 2–3% of the adolescent population

## Case Introduction

A 13-year-old girl was referred to her family practitioner for an asymmetry of her back which her mother realized was present. The patient was referred to an orthopedic surgeon, who diagnosed a thoracolumbar curve of 30 degrees with a minor thoracic curve. Due to the young age of the patient, a brace treatment was started. However, the curve rapidly progressed despite the fact that the girl had regularly worn her brace. At the time of referral, the girl was fully active but had some occasional backpain during intensive sports activities. The patient had only recently had her menarche and had been growing rapidly for the last couple of months. Standard radiographs (a) revealed a major thoracolumbar curve of 58 degrees with a minor thoracic curve of 42 degrees in a skeletally immature patient (Risser IV). The lateral view revealed a flattening of the sagittal profile with a decrease of thoracic kyphosis and lumbar lordosis (b). Surgery was indicated because of a rapidly progressing curve in a patient with a persistent potential for growth. Supine bending films demonstrated a correction of the thoracolumbar curve to 15 degrees (c) and of the thoracic curve to 20 degrees (d). We opted for a short selective anterior fusion by a thoracoabdominal approach because of the still flexible thoracic curve. Six years after surgery, the patient presented with a balanced spine and was symptom free (e). The radiographs demonstrate an excellent curve correction with fusion of only two intervertebral discs (f, g).

In patients with small curves, males and females are about equally affected, but with increasing curve magnitude the female-to-male ratio changes to the disadvantage of female adolescents [6, 22, 23, 97]. The infantile form (0–3 years) is more frequent in males (3:2), and may be associated with pathologic findings of the heart, skull, hip, or mental development. Between 3 and 6 years, the female-to-male ratio is 1:1, between 3 and less than 10 years it is 2:1 to 4:1 [95] and at 10 years of age the ratio is about 8:1 [172].

## Pathogenesis

Asymmetrical anterior column growth with posterior tethering may lead to scoliosis

Despite intensive research, the etiology remains unknown, i.e., idiopathic [129]. However, some factors that seem to play a role in the etiology and pathogenesis of this spinal deformity have been detected. There is some evidence that an asymmetrical vertebral growth of the anterior column with tethering of the posterior structures leads to the deformity. Guo et al. [76] found a disproportional longitudinal growth by endochondral ossification of the vertebral bodies assessed by MRI in patients with adolescent idiopathic scoliosis compared with age-matched controls. On the contrary, the circumferential growth of the vertebral bodies and pedicles by membranous ossification was found to be slower than in controls. The reasons for this **imbalance of anterior and posterior growth** are unknown.

### Genetic Factors

Several studies have shown that idiopathic scoliosis develops within affected families with a higher incidence than in the general population [44, 233]. In one study, 27 % of the daughters of women with scoliosis (curves > 15°) were found to have scoliosis as well [84]. Larger population studies in the 1960s and 1970s found incidences of 11 %, 2.4 % and 1.4 % for first-, second- and third-degree relatives, respectively. Studies with monozygous twins exhibited a concordance of almost three-quarters for the development of scoliosis whereas the concordance in heterozygous twins was found to be about one-third, which is still higher than in first-degree relatives [100].

There is a genetic predisposition for idiopathic scoliosis

Beside these observational approaches several attempts were made to statistically analyze a potential linkage of genes to the disorder. Complex segregation analyses indicate that there is a major gene controlling scoliosis [8]. However, such a gene has not been detected yet and the aforementioned studies with monozygous twins suggest that variable gene expression and environmental factors also influence the development of scoliosis.

### Connective Tissue and Skeletal Muscle Abnormalities

Connective tissue disorders appear to play a role in scoliosis

Scoliosis is linked to several **connective tissue diseases** such as Marfan syndrome. Therefore, alterations in the extracellular matrix of connective tissue were the subject of investigations on the etiology of scoliosis. Some authors found a different collagen composition of the nucleus in scoliosis patients [171] while others did not [164, 186]. Differences in the elastic fibers were also found [58, 78]. Changes in the paraspinal musculature were also discussed as possible etiologic factors. Several studies found a muscle fiber distribution (slow-twitch and fast-twitch) between the convex and the concave side of the curve [27, 189, 199, 201, 235]. However, it can only be speculated whether these alterations are the result or the cause of the disease [129].

### Thrombocyte Abnormalities, Calmodulin and Melatonin

The myosin/actin contractile systems of thrombocytes and skeletal muscle are quite similar. It was therefore suggested that if there is an abnormality in the contractile apparatus of the skeletal muscle leading to scoliosis, abnormalities should also be apparent in platelets. As thrombocytes are independent of the axial skeleton, changes must be independent of secondary effects caused by the deformity itself. Muhlrad et al. [147] detected a decreased activity of the intracellular contractile apparatus of platelets and a decreased platelet aggregation with adenosine triphosphate and epinephrine in scoliosis patients. Yarom et al. [234] electron microscopically identified three different types of platelets after metal impregnation: reticular, metallophilic and pale platelets. Patients with larger idiopathic curves exhibited more metallophilic thrombocytes, whereas the reticular type was mainly found in the controls. This difference was thought to be due to different membrane permeability indicating a membrane defect.

Progressive scoliosis may be associated with abnormal platelets and calmodulin or melatonin levels

Calmodulin interacts with actin and myosin and regulates the calcium influx from the sarcoplasmatic reticulum. It therefore regulates the contractile properties of muscles and platelets and has also been investigated as a potential etiologic factor. Elevated calmodulin concentrations in thrombocytes were found to be associated with progressive adolescent scoliosis while the levels in patients with non-progressive curves and controls were similar [102]. Melatonin is decreased in patients with progressive curves whereas it is normal in stable curves [133]. As melatonin binds to calmodulin and acts as an antagonist to it, it may also play an important role in the regulation of the aforementioned platelet changes. In conclusion, these reports suggest a defect in the contractile system of platelets associated with scoliosis.

## Classification

### Age-Related Classification

The **Scoliosis Research Society** (SRS) suggested differentiating [36] idiopathic scoliosis according to its age of onset as:

- infantile (0 – 3 years; IIS)
- juvenile (3 – 10 years; JIS)
- adolescent (10 – 18 years; AIS)
- adult (> 18 years) onset

Idiopathic scoliosis is classified according to age of onset

Dickson, however, proposed a division into early onset (0 – 5 years) and late onset (after 5 years of age [47]). The rationale behind this classification is that growth of the spine in the juvenile age (3 – 10 years) is rather steady [172] and that the pulmonary maturity reached after 5 years of age exhibits fewer cardiopulmonary risks [208].

The **adult idiopathic scoliosis** has to be differentiated from:

- primary degenerative or "de novo" scoliosis (see Chapter 26)

The adult idiopathic type is an idiopathic scoliosis which already existed at the end of growth and can exhibit progressive secondary degenerative changes [1].

## Radiological Classification

The King classification system classifies thoracic curves

According to the SRS guideline, a curve is **thoracic** if its apex is at the T2 to T11/12 disc, **thoracolumbar** if its apex is at T12 or L1 and **lumbar** if its apex is at the L1/2 to L4 disc [36]. King et al. [103] presented a classification system in 1983 which is still broadly used. This system is based on the location of the structural and non-structural (secondary) curves, their relation to the center sacral vertical line (CSVL) and on their flexibility in side-bending radiographs, leading to five curve types (Table 1):

**Table 1.** King classification of thoracic curves [103]

| Type | Major curve | Secondary curve | Side-bending |
|---|---|---|---|
| I | • lumbar, crossing midline | • thoracic, crossing midline | • lumbar curve larger or less flexible |
| II | • thoracic, crossing midline | • lumbar, crossing midline | • thoracic equal to or larger than lumbar and less flexible |
| III | • thoracic | • lumbar, not cross midline | – |
| IV | • long thoracic | • L5 centered over the sacrum, L4 tilts into long thoracic curve | – |
| V | • double thoracic<br>• T1 tilts into convexity of upper curve | –<br>– | –<br>– |

The Lenke classification considers all anatomical curve types and the sagittal thoracic profile

The lack of a classification system for single thoracolumbar, lumbar or double/triple major curve types and recent reports of poor to fair validity, reliability and reproducibility of the King classification [41, 110] have led to the development of a new and more comprehensive classification system. In 2001, Lenke et al. [113] introduced a new system which should help to determine the extent of spinal instrumentation in adolescent idiopathic scoliosis (Fig. 1). The classification is based on **six different curve patterns**, **three lumbar spine modifiers** and a **sagittal thoracic modifier**. The curves in the scoliotic spine are differentiated into structural and non-structural curves. The relationship of the CSVL to the apex of the lumbar curve determines the lumbar spine modifier (A – C). The sagittal thoracic modifier (STM) is negative when the thoracic kyphosis (T5–T12) is smaller than 10°, neutral when it is 10 – 40°, and positive when more than 40°. This system allows for a distinction of six principal curve types (MT, DT, DM, TM, TL/L, TL/L-MT) and therefore for a much differentiated characterization. Two recent studies have investigated validity and reliability comparing the King and Lenke classifications [155, 182]. Richards et al. found slightly higher kappa values for the inter- and intraobserver reliability in the King classification [182]. Niemeyer et al. [155] found that the reliability of both grading systems is dependent on the level of experience of the rater.

## Clinical Presentation

### History

AIS is usually not painful and is discovered accidentally

Patients presenting with idiopathic scoliosis before adulthood usually present without severe clinical signs and symptoms. Frequently, the scoliosis is accidentally discovered by family members, teachers, friends, school nurse or family physicians because of the back or shoulder asymmetry. Teenagers sometimes realize the scoliosis is present when they have problems finding perfectly fitting clothes (waistline asymmetry). To rule out secondary forms of scoliosis and to

## Curve Type

| Type | Proximal Thoracic | Main Thoracic | Thoracolumbar / Lumbar | Curve Type |
|---|---|---|---|---|
| 1 | non-structural | structural (major*) | non-structural | main thoracic (MT) |
| 2 | structural | structural (major*) | non-structural | double thoracic (DT) |
| 3 | non-structural | structural (major*) | structural | double major (DM) |
| 4 | structural | structural (major*) | structural | triple major (TM) |
| 5 | non-structural | non-structural | structural (major*) | thoracolumbar / lumbar (TL/L) |
| 6 | non-structural | structural | structural (major*) | thoracolumbar / lumbar - main thoracic (TL / L - MT) |

*major = largest Cobb measurement, always structural

minor = all other curves with structural criteria applied

**Structural Criteria** (minor curves)

**proximal thoracic:** - side bending Cobb ≥ 25°
- T2 - T5 kyphosis ≥ +20°

**main thoracic:** - side bending Cobb ≥ 25°
- T10 - L2 kyphosis ≥ +20°

**thoracolumbar / lumbar:** - side bending Cobb ≥ 25°
- T10 - L2 kyphosis ≥ +20°

**Location of Apex** (Scoliosis Research Society Definition)

**Curve:** - thoracic
- thoracolumbar
- lumbar

**Apex:** - T2 - T11-12 disc
- T12 - L1
- L1-2 disc - L4

## Modifiers

| Lumbal Spine Modifier | | Thoracic Sagittal Profile T6 - T12 | | |
|---|---|---|---|---|
| | **CSVL to lumbar apex** | | | |
| A | **CSVL** between pedicles | – | hypo | < 19° |
| B | **CSVL** touches apical body(ies) | N | normal | 10° - 40° |
| C | **CSVL** completely medial | + | hyper | > 40° |

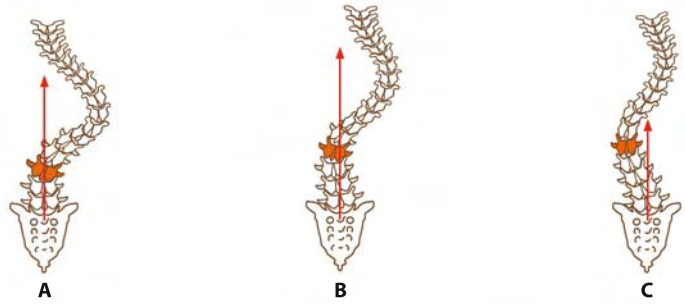


Center Sacral Vertical Line (CSVL)

Curve Type (**1 - 6**) + Lumbar Spine Modifier (**A, B, or C**) + Thoracic Sagittal Modifier (**-, N. or +**)

**Classification (e.g. 1B+):** _____

**Figure 1. Classification for adolescent idiopathic scoliosis**

According to Lenke et al. [113], reprinted with permission from JBJS, Inc.).

assess the risk of progression, **specific information** should be obtained from the patient and their parents:

- history related to spinal deformities
- course of pregnancy
- course of delivery
- developmental milestones (onset of walking, speaking, etc.)

- fine motor skills
- tendency to fall (clumsiness)
- evidence for metabolic or neuromuscular disorders
- back pain/leg pain
- functional disability

Assess risk factors for curve progression

Information on **pre- and perinatal complications** or retardation of general development of the child may raise suspicion about other than idiopathic etiologies (e.g., mild forms of cerebral palsy, metabolic or neuromuscular disorders or intraspinal malformations). Severe pain, functional disability and neurological deficits are rarely present in adolescent idiopathic scoliosis and should prompt suspicion about, e.g., intraspinal tumors [34] or syringomyelia [237]. However, mild back pain is not infrequent in AIS due to the curve-related muscle imbalance. Several factors are helpful in assessing the **risk of progression** [25, 125]:

- menarchal status
- breaking of the voice
- beard growth
- growth spurt

Investigations have shown that all girls have the menarche before the end of the growth spurt and that no menstrual bleeding occurs before peak growth velocity. In boys, it was found that the growth spurt is in its most intensive phase when voice breaking begins [80].

**Adult idiopathic scoliosis** usually presents with pain and/or disability due to:

- secondary degenerative changes
- sagittal or coronal imbalance

Adult scoliosis can cause significant pain and disability

Progression of adult scoliosis [1] may lead to increasing waistline asymmetry and hip prominence and cause symptoms. The most common complaint is **back pain** due to facet joint arthritis, disc degeneration or imbalance [93, 194]. Secondary degenerative changes in the adult scoliosis can produce [198, 230]:

- radiculopathy
- claudication symptoms (patients > 50 years)

The importance of cosmesis should not be underestimated either in adolescents or in adults.

## Physical Examination

### General Assessment

Perform a comprehensive musculoskeletal exam

Height (sitting and standing) and weight should be noted at every examination to monitor growth and identify a growth spurt. A full musculoskeletal assessment is indispensable to identify associated pathology.

Rule out secondary scoliosis by means of a thorough history and physical exam

Leg length discrepancies, limb asymmetries, arachnodactyly, foot deformities, foot size discrepancies (tethered cord) or general laxity of the joints may indicate secondary scoliosis. The skin must be searched for:

- hairy patches/dimples (spinal dysraphism)
- café-au-lait spots (neurofibromatosis)

### Curve Assessment

Bending forward is the most reliable scoliosis screening test

In small curves not much may be seen when inspecting the back in the upright position. However, asymmetries such as an S-shaped line of the spinal processes, a slightly more prominent scapula or asymmetric lumbar triangles may indicate the presence of scoliosis (Fig. 2a). The most reliable and subtle sign is the rib hump when the patient bends forward (Fig. 2b, c). When the curve is larger, the deformity is clearly visible in the upright standing position (Fig. 2d). The **coronal balance** should be assessed (Fig. 2e). Side bending is important to evaluate the flexibility of the curves and detect structural curves (Fig. 2f, g).

Assess coronal balance

Clinical **curve assessment** should include:

- curve location (thoracic, thoracolumbar, lumbar)
- convexity (right, left)
- flexibility of the curves
- extent of rib hump/lumbar bulge
- shoulder level
- pelvic obliquity
- sagittal profile
- sagittal balance
- coronal balance

The convexity of adolescent thoracic curves is mostly on the right side. If there is a left convex thoracic major curve, other causes of scoliosis should be considered (see below, Fig. 5). Assessing the curve flexibility by passive side bending is indicative of the curve rigidity. The **sagittal profile** usually presents rather with a hypo-kyphosis/lordosis than with hyper-kyphosis/lordosis. **Spinal balance** in the coronal and sagittal plane as well as pelvic and shoulder obliquity are assessed allowing for an interpretation of the global spine balance.

### Neurological Assessment

A neurological examination (see Chapter 11) should include:

- exam of sensory and motor system
- reflex status (abdominal wall reflex, deep tendon reflexes, Babinski test)
- gait (ataxia)

Absent abdominal wall reflexes may indicate an intramedullary pathology

Testing the **abdominal wall reflexes** may give an important hint to an undiscovered intramedullar pathology [237].

### Assessment of Physical Maturity

Adolescent idiopathic scoliosis most rapidly progresses during the growth spurt. This rapid growth usually occurs in the age range of 10–13 years in girls and 12–15 years in boys. This period of rapid growth is indicated by aspects obtained during history taking (i.e., menarchal status, breaking of the voice) and the progress of genital development. **Tanner** staged the **pubertal development** according to the development of pubic hair, breast development in girls and penile and testicular growth in boys [211]. Girls usually reach their time of most rapid growth between Stages 2 and 3 for pubic hair and breast development whereas in boys this occurs between Stages 3 and 5 for penile and testicular growth [24, 211].

**Figure 2. Clinical assessment**

a Minor scoliosis indicated by a prominent right scapula and a waistline asymmetry. b Forward bending test revealing a rib hump. c Measurement of the rib humb with a scoliometer. d Severe scoliosis with trunk imbalance. e Assessment of coronal balance and shoulder level. f, g Side bending tests demonstrating a structural right convex curve without correction when bending to the right (*arrows*).

## Diagnostic Work-up

### Imaging Studies

The imaging modality of choice for the diagnostic evaluation of idiopathic scoliosis remains standard radiography. Magnetic resonance imaging (MRI) and computed tomography (CT) are only necessary in selected cases or perioperative planning.

#### Standard Radiographs

Whole spine standing (anteroposterior, lateral) radiographs are standard

Standard assessment consists of standing radiographs of the whole spine including occiput and pelvis in the anteroposterior and lateral views (Fig. 3). This allows the assessment of all curves, vertebral rotation, spinal balance, and Risser stage. These standard radiographs should be taken at the first visit as a baseline documentation of the deformity. During follow-up examinations, an anteroposterior view of the spine is sufficient as long as there are no clinical signs of a sagittal imbalance of the spine.

##### *Radiographic Curve Assessment*

Radiological assessment in the **anteroposterior** view includes the determination of the following parameters [36]:

- localization (thoracic, thoracolumbar, lumbar)
- magnitude of the deformity (Cobb angle, Fig. 4)
- differentiation of major and minor/compensatory curves
- upper and lower end vertebrae of the curve
- apical vertebra
- coronal spinal balance
- pelvic obliquity
- sacral obliquity
- skeletal maturity
- vertebral rotation
- rib-vertebral angle difference (RVAD) [137]

Angular deformity is assessed by the Cobb angle

The magnitude of the deformity is measured by the method of Cobb [37] (Fig. 4a). The **Cobb angle** is defined by the angle of the two end vertebrae. The upper and lower end vertebrae are those vertebrae most tilted into the curve and which do not exhibit a rotation (**neutral vertebrae**).

The major curve is the one with the largest Cobb angle on the anteroposterior view. If two curves are of the same size, the most rigid curve is considered major. If both curves are similarly rigid, they are called **double-major curves**. According to the SRS guidelines, a minor curve is any curve that is not a major curve. Minor curves may be compensatory curves, i.e., a curve above or below a major curve and it may or may not be structural [36]. Lateral translation is determined in relation to the **central vertical sacral line** (CVSL). The **apical vertebra** is the vertebra that is most laterally deviated from the CVSL. If the most lateral point is a disc, this is called the apical disc. **Coronal balance** (Fig. 2e) is assessed as the lateral translation of the radiographic plumbline falling from the center of the C7 vertebral body in relation to the mid-point of the sacrum. Pelvic obliquity is determined by the connecting line of the iliac spines in relation to a true horizontal line. Sacral obliquity is assessed by the connecting line of the upper border of the sacrum in relation to a line connecting the femoral heads. Skeletal maturity is determined by the method of **Risser** (Figs. 3c, 4b), which is based on the calcifi-

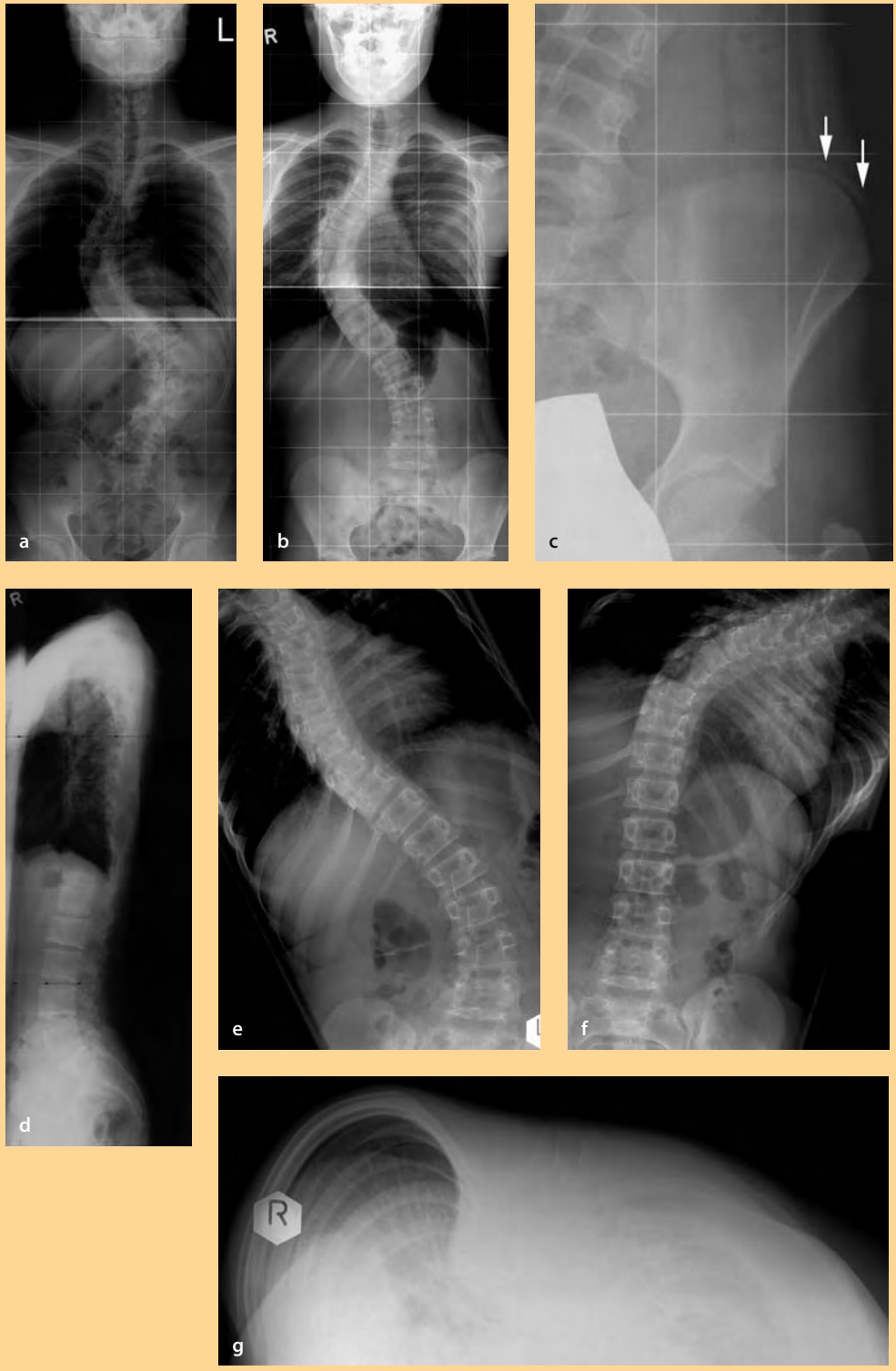


**Figure 3. Standard radiography**

a Compensated double major curve. b Decompensated thoracic curve. c Risser sign I–II (*arrows*). d Sagittal profile with a flat back. e, f Thoracic and lumbar side bending views. g Silhouette radiograph demonstrating a rib cage deformity.

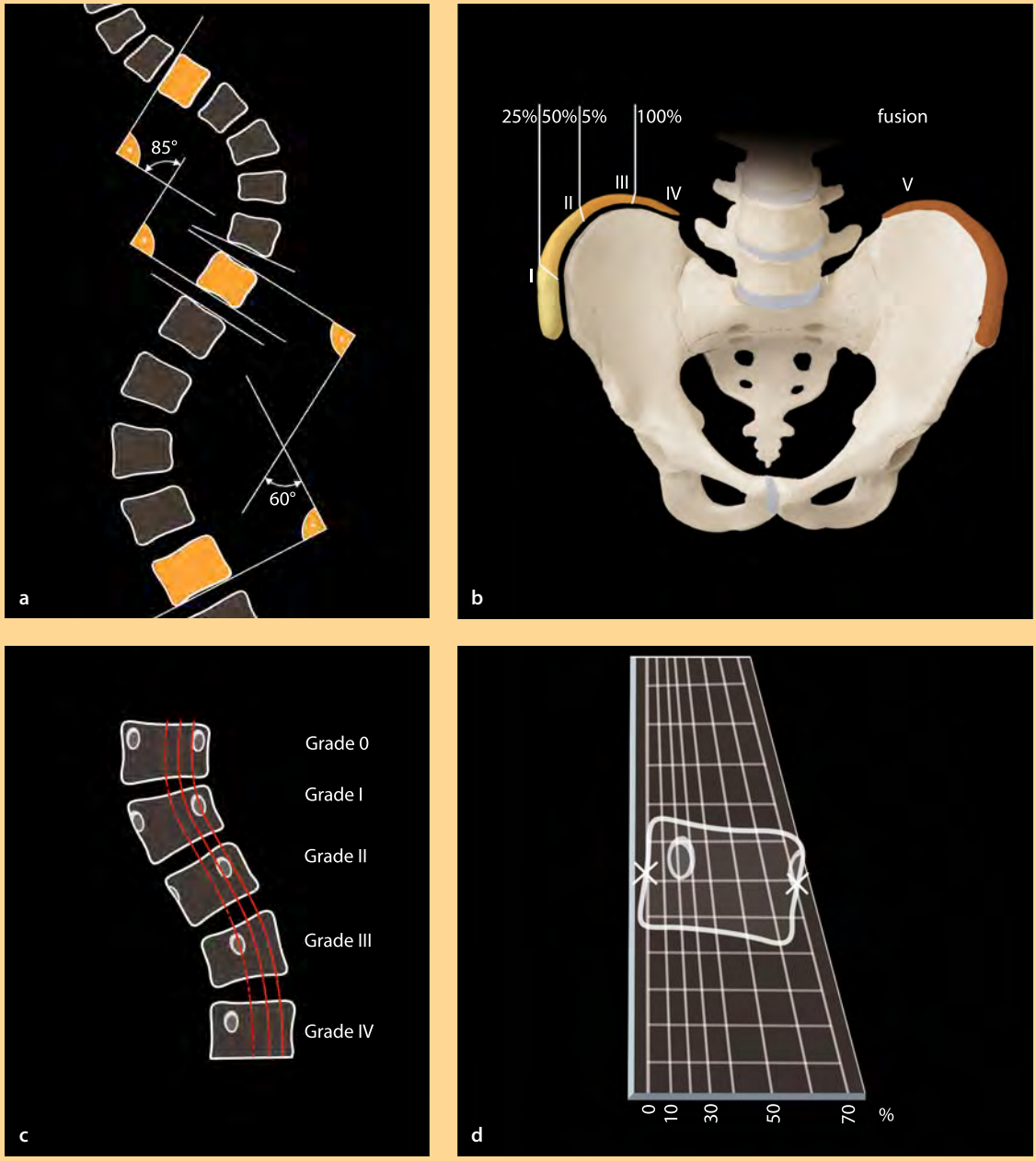


**Figure 4. Radiographic assessments**

a Cobb measurement. b Risser sign. c Vertebral rotation according to **Nash/Moe**: the more rotated the vertebra, the more the pedicle at the convexity passes towards and beyond the midline and the pedicle at the concavity disappears. d Vertebral rotation according to **Perdriolle**: the radiograph of the target vertebra is superimposed by a torsionometer. The intersection of the pedicle at the convexity with the respective line of the torsionometer determines the rotation.

cation of the apophysis of the iliac crest [185]. This apophysis first appears anterosuperiorly of the iliac crest and progresses towards posterior before it fuses with the iliac spine. According to Risser, the iliac crest is divided into four quarters in the anteroposterior radiograph. If none of the quarters is calcified, Risser stage is 0; if one quarter is calcified Risser stage is 1 and so on. If the complete apophysis is fused with the iliac crest, Risser stage is 5.

Two methods are commonly used to assess **vertebral rotation** on standard anteroposterior radiographs:

- Nash/Moe method
- Perdriolle method

The technique by **Nash and Moe** determines vertebral rotation according to the pedicles into five grades [150] (Fig. 4c). In grade 0 (neutral) both pedicles show a symmetric distance from the lateral borders of the vertebral bodies. In grade I and II the pedicle on the convex side translates towards the middle line of the vertebral body whereas the one on the concave side begins to disappear. In grade III the pedicle of the convex side lies in the midline of the vertebral body and in grade IV and V it passes the midline towards the concave half of the vertebral body. In these two grades the pedicle of the concave side is no longer visible.

Vertebral rotation is measured by the method of Nash and Moe or Perdriolle

The method of **Perdriolle** (Fig. 4d) allows the angle of rotation to be estimated by using a specific transparent torsionometer which is laid on the radiograph [175, 176]. The angle of rotation can then be read off the torsionometer according to the projection of the pedicle on the convex side.

The **rib-vertebral angle (RVA)** is construed by a midvertebral vertical line and a line centered through the rib head. Progression or resolution of infantile idiopathic scoliosis may be predicted by the RVA difference. Mehta described this method which combines the difference of the rib-vertebra angles of the convex and the concave curve side as the so-called "phase of the rib head" [137]. Two phases may be distinguished. In Phase 1 the rib head of the convex rib of the apical vertebra shows no overlap with the apical vertebra. In Phase 2 there is an overlap to be found.

Radiographic curve assessments in the **lateral view** (Fig. 3d) include the determination of the following parameters [36]:

- thoracic and lumbar profile (angle of kyphosis/lordosis)
- sagittal spinal balance
- other abnormalities: spondylolysis/-listhesis

The intraobserver error in Cobb measurements ranges between 3° and 10°

For the assessment of the sagittal thoracic profile, the upper endplate of T1 and the lower endplate of T12 are used to determine the Cobb angle of kyphosis or lordosis, respectively. If T1 is not distinguishable on the radiograph due to overprojection of the shoulder, the upper endplate of T4 or T5 is usually used. For the assessment of the sagittal lumbar profile, the upper endplates of L1 and S1 are used.

According to inter- and intraobserver reliability studies of the Cobb method in juvenile and adolescent idiopathic scoliosis, a change of between 5° and 10° [30, 62, 94, 121, 122, 180] between two measurements is considered to be a true change of curvature. In congenital scoliosis, the variability in measurement of the Cobb angle is largely due to skeletal immaturity and incomplete ossification. However, it is important always to compare the actual with the baseline radiographs.

Side bending supine images are necessary to determine curve rigidity

When a surgical correction of the deformity is considered, additional anteroposterior supine **side-bending views** are necessary (Fig. 3e, f) to assess the rigidity of the curves (i.e., extent of curve correction). The films are taken with the patient supine on the X-ray table with maximal passive side bending. The rib hump can be radiologically assessed by a **silhouette radiograph** taken from posterior with the patient inclined horizontally (Fig. 3g) [94].

### Magnetic Resonance Imaging

The purpose of preoperative MRI is to detect intraspinal pathologies. Possible pathologies include syringomyelia, Arnold-Chiari malformation, tethered spinal cord (Fig. 5a–c) or intraspinal tumors. Several studies have documented the risk

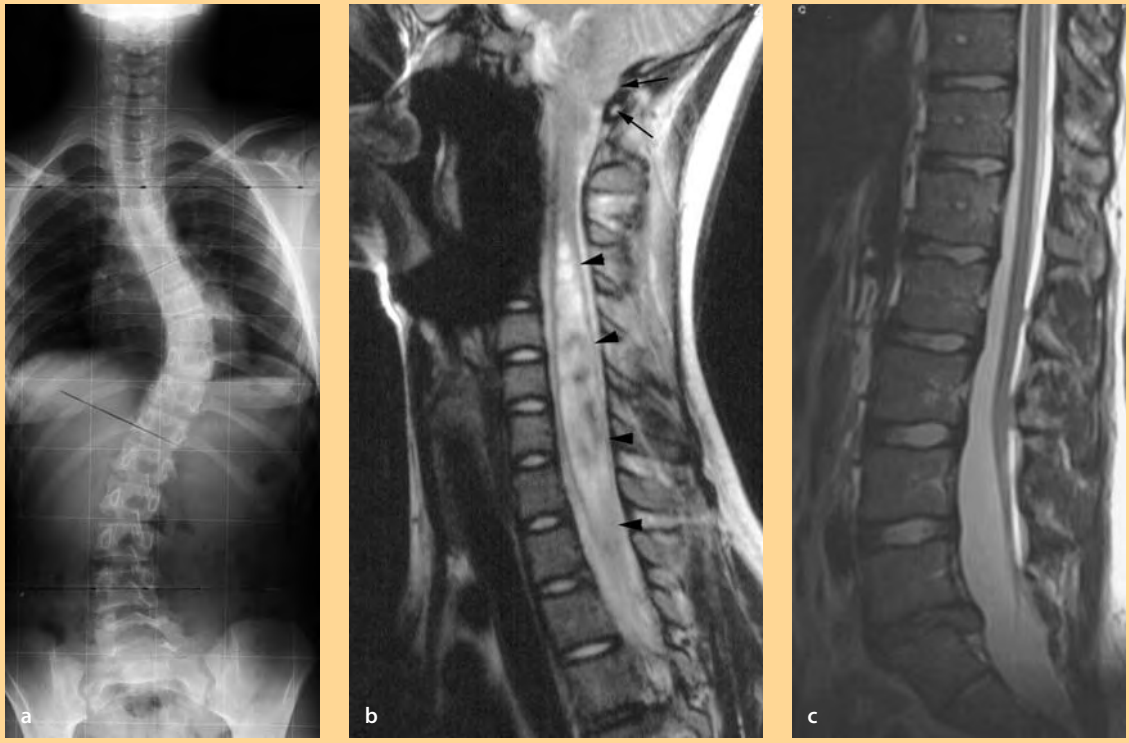


**Figure 5. Magnetic resonance imaging**

a Standard radiograph showing an atypical left thoracic curve. b MRI of this patient reveals an Arnold-Chiari malformation Type I (*arrows*) and a syrinx (*arrowheads*). c MRI of the thoracolumbar spine with a tethered cord demonstrated by a low conus at the level of L4.

of neurological complications in scoliosis correction surgery with concomitant syringomyelia [91, 159, 160, 167].

There is a broad consensus on performing preoperative MRI of the complete spine in patients presenting with **atypical idiopathic scoliosis**, i.e.:

- infantile and juvenile onset [61, 119]
- painful scoliosis [9, 192]
- left convex thoracic curves [9, 231]
- neurological abnormalities (e.g., absent abdominal reflexes) [192, 237]

Preoperative MRI is mandatory in atypical scoliosis

There is an ongoing controversy in the literature whether to routinely perform preoperative MRI in adolescent idiopathic scoliosis [49, 68, 86, 163]. Some authors only recommend performing MRI in the aforementioned cases [49, 92, 195, 231]. We prefer routine MRI in all patients scheduled for operative scoliosis treatment [68, 86].

### Computed Tomography

For severe curves, CT may be helpful for surgical planning

Computed tomography is not routinely used in the preoperative assessment of idiopathic scoliosis. In selected cases, however, preoperative CT scans may be of value to precisely assess vertebral deformation and rotation. CT may be used to assess pedicle size and shape before using spinal instrumentation. In juvenile idiopathic scoliosis, it may be necessary to assess pedicle size before performing surgery because the pedicle diameter may be too small for a pedicle screw insertion affording alternative instrumentation methods [71].

### Injection Studies

In **adult** idiopathic scoliosis, injection studies are helpful in identifying the source of the pain (see Chapter 10). **Provocative discography** may be used to identify symptomatic disc degeneration. This test is only helpful if the typical pain can be provoked at the target level without pain provocation at adjacent MR normal levels [118, 191]. **Selective nerve root blocks** or **facet joint blocks** may be useful in identifying nerve root compromise and symptomatic facet joint arthritis, respectively [73, 118].

## Neurophysiologic Evaluation

Neurophysiologic evaluation is recommended to detect a subclinical pathology

A thorough neurophysiologic evaluation is necessary in clinically suspicious patients. In a study on 100 patients with typical right convex idiopathic adolescent curve and normal neurologically, 56 % showed alterations in the neurophysiologic evaluation of somatosensory evoked potentials (SSEPs) [86]. Preoperative pathologic differences between left and right were found in 17 % of the cases although no clinical signs could be detected. This indicates that by neurophysiologic evaluation subclinical pathologies may be detected and that this method may be used for preoperative screening. It was also found that in uneventful scoliosis surgery pre- and postoperative SSEPs were found to be similar and that the influence of anesthesia on intraoperative SSEPs becomes quite predictable when using a standardized anesthesia protocol [205].

# Treatment

## General Considerations

Idiopathic scoliosis does not usually present with severe symptoms (i.e., no pain or neurological deficits) before adulthood. In this age group, the general objectives of treatment are (Table 2):

**Table 2.** General objectives of treatment

- arrest progression
- maintain or restore sagittal and coronal balance
- preserve function of lower lumbar motion segments

- correct spinal deformity
- maintain or restore sagittal and coronal balance
- allow for further growth of the spine (**only** infantile and juvenile scoliosis)

When deciding on the most appropriate therapy, the key questions are whether the individual curve exhibits the potential of progression and with what consequences. The fact that patients with idiopathic scoliosis usually present early in life and adverse consequences may only occur decades later makes patient selection a challenge. The knowledge of the natural history is therefore a prerequisite for a counselling of an appropriate treatment.

## Natural History

### Infantile Idiopathic Scoliosis

Only few cases of infantile scoliosis progress rapidly to severe deformities

Infantile scoliosis was found to usually develop in the first months of life affecting more males than females (ratio 3:2) [95, 96, 120, 193]. The majority of structural curves in this age group resolved partly or completely and remained stable thereafter. However, a minority of patients exhibited rapid progression and developed

severe curves when left untreated. Especially girls with right sided curves were found to be at a high risk of deterioration [215].

A feature that may help to predict progression or resolution of infantile idiopathic scoliosis is the **RVAD** as described by Mehta [137]. In **Phase 1**, an RVAD of more than 20° is associated with progression of the curve in 84 % whereas an RVAD of less than 20° is associated with resolving of the curve in 83 %. In **Phase 2**, all curves progressed independently of the RVAD [137]. These findings were supported by Ferreira and James [64]. The appearance of a double curve was found to be correlated with progression by Ceballos et al. [32]. These curves must therefore be followed closely.

Double major curves are likely to progress

### Juvenile Idiopathic Scoliosis

Spinal growth during the age between 3 and 10 years is rather steady [172]. Regression of the curve may occur [136] but usually curves in this group are characterized by slow to moderate progression [65, 95, 106, 179]. Early onset curves are at higher risk for severe progression. The reported necessity for surgery varies between 30 % [136, 216] and 56 % [65]. Right thoracic and double major curves are the predominant curve patterns. In approximately 20 % of patients in this age group, scoliosis is associated with an intraspinal abnormality and it is strongly recommended that curves larger than 20° should be evaluated by MRI [77, 119].

### Adolescent Idiopathic Scoliosis

Several studies postulated that less than 10 % of individuals exhibiting curves larger than 10° require treatment [23, 125, 188, 228]. Several studies have explored the natural history of progression in idiopathic scoliosis during adolescence. **Risk factors** for curve progression are:

- young age at onset [187]
- premenarchal status [25, 125]
- physical immaturity (Risser sign, Tanner stages) [185, 211]
- larger curves [25, 125, 220]
- female gender [25]

Thoracic curves (> 50°) tend to progress even after skeletal maturity

Progression is influenced by the **curve type** with double major curves being at highest progression risk [25, 125]. Larger curves generally have a higher progression risk than smaller ones [25, 125, 220] and progression is more frequent in female patients [5, 25, 56, 221, 222]. Curve progression has also been found to occur after skeletal maturity, especially in thoracic curves larger than 50° [5, 179, 222]. Curves that were smaller than 30° at skeletal maturity did not tend to progress during adulthood.

Health related quality of life in patients with AIS is comparable to healthy controls

Early studies on the natural history of scoliosis included mixed types of scoliosis and reported higher mortality rates, more back pain and psychosocial adverse effects such as a lower rate in married women or a reduced ability to work [148, 156]. More recent selective studies on adolescent idiopathic scoliosis did not show such unsatisfactory outcomes. Collis and Ponsetti [39] found that most of their 215 investigated patients with non-operated AIS led normal and active lives, were productive, worked, married and showed similar activities compared to the normal population. They did not find a higher mortality rate in scoliosis patients. However, they found back pain to occur more frequently than in the normal population. Similar findings were reported by Weinstein et al. [222]. Danielsson et al. [43] found that health-related quality of life in patients with adolescent idiopathic scoliosis was about the same as in the general population after more than

20 years of follow-up. However, the scoliosis patients exhibited slightly reduced physical function (SF-36) and more disability (Oswestry Score) compared to healthy controls.

Similar findings were found by Haefeli et al. [79] in a 10- to 60-year follow-up of conservatively treated patients who exhibited a similar quality of life compared to healthy controls according to the WHOQOL-Bref. assessment. Whereas Danielsson et al. [43] and Weinstein et al. [220] found no correlation between Cobb angle and disability or pain, Haefeli et al. [79] detected slightly but significantly higher pain levels in patients with curves of more than 45°.

The prevalence of back pain and physical disability seems higher in scoliosis patients than in healthy controls

In contrast to the earlier studies mentioned above, Danielsson et al. [42] and Weinstein [220] did not find differences regarding rates of marriages, childbearing and sexual function in women 22–50 years of age regardless of treatment.

This data suggests adolescent idiopathic scoliosis to be a rather benign spinal disorder especially in cases of small to moderate curve sizes. On the other hand, it has been shown that thoracic curves bigger than 70° exhibit an increased risk of chronic respiratory or cardiac failure [11].

Respiratory and cardiac failure may occur in large (>70°) thoracic curves

## Non-operative Options

Considering the relatively benign natural history of idiopathic scoliosis, surgical treatment is reserved for progressive large curves. The vast majority of remaining cases can be treated non-operatively. **Conservative measures consist of:**

- physiotherapy
- bracing
- electrotherapy

So far, there is no evidence for the efficacy of electrotherapy [117].

### Physiotherapy

Non-operative treatment generally consists of observation and physiotherapy in curves smaller than 25° [123]. A recent review of the effectiveness of physiotherapy in the treatment of scoliosis has identified 11 studies [151]. The methodological quality of the retrieved studies was found to be very poor. Therefore, the literature fails to provide solid evidence that physical exercises influence the natural history. Nevertheless, physiotherapy is a helpful adjunct to reduce symptoms related to muscle imbalance and to improve or preserve back function [224, 225]. The limitations of physiotherapy with regard to curve progression have to be clearly communicated to the patient and their parents prior to treatment. Patients having physiotherapy remain under surveillance with regard to curve progression.

Physiotherapy does not arrest curve progression

### Casts and Bracing

#### *Infantile and Juvenile Idiopathic Scoliosis*

In early onset (<6 years), scoliosis therapy is dominated by the progression risk. Curves that are expected to resolve may be simply observed every 4–6 months. Active treatment should be initiated at a progression of 10°. Patients whose curves resolve should be followed until maturity to rule out any progression during the growth spurt [2]. In resolving curves plaster-bed treatment showed no advantage over physiotherapy with regard to the time of resolution or functional outcome after 25 years [48]. When progression is documented treatment should be started. Initial therapy consists of serial molded body casts that have to be

Progression risk is high in early onset scoliosis

changed every 6–12 weeks until maximum correction is achieved. Then, full-time bracing is started for at least 2 years and until there is no further progression to be observed [2]. Prognosis is good if total correction is achieved before the prepubertal growth spurt [138]. If no full correction may be achieved, progression may occur, possibly necessitating surgery.

### *Adolescent Idiopathic Scoliosis*

The choice of therapy depends on the severity of the curve and the potential for progression

In adolescent idiopathic scoliosis with curves between 25° and 40° in a skeletally immature (<Risser 3) patient, bracing is indicated [123]. However, it must be borne in mind that the primary goal is to prevent curve progression through bracing (Fig. 6). The treatment is considered successful if the initial curve size at treatment entry can be preserved at the end of bracing. Often an improvement occurs during therapy but is lost after brace cessation [31, 139, 227]. In the presence of a true thoracic lordosis (>5° to 10°), bracing may be impossible as any positioning of the thoracic pad will increase thoracic lordosis and thus make correction impossible. The possible psychological distress of a long-term therapy such as bracing and the efficacy of the treatment must carefully be considered [63, 135, 157, 165, 219].

There is limited evidence for the effectiveness of bracing

The effectiveness of conservative treatment modalities has been the subject of several studies [117]. The only study that found a significant difference in favor of bracing compared to observation and overnight electrical stimulation was presented by Nachemson and Peterson for curves ranging from 25° to 35° in female patients [149]. In the same study, no difference was found between bracing and physiotherapy. Other studies found no significant differences for bracing versus natural history [158]. A recent survey among members of the Scoliosis Research Society and of the Pediatric Orthopaedic Society of North America revealed a high degree of variability with regard to the opinion of the effectiveness of brace treatment [52]. Based on the current literature, there seems to exist only **limited evidence** for the effectiveness of bracing.

**Figure 6. Thoracolumbar brace**

a, b Thoracolumbar brace. c, d Patients should wear the brace for a minimum of 23 h daily to achieve a treatment effect.

## Operative Treatment

The risks and benefits of surgery must be carefully weighed against the natural history when the scoliosis is left untreated. Intensive counselling of the patients and their parents is necessary to explain the pros and cons of the intervention, risks and potential outcome. The **indications for surgery** for idiopathic scoliosis depend on:

- risk for progression
- skeletal maturity
- curve type
- curve magnitude
- cosmetic appearance
- failure of conservative treatment

Intraoperative neuromonitoring is the standard of care

Surgery has to be well planned in advance and requires a dedicated team taking care of children and adolescents. **Intraoperative neuromonitoring** has become the standard of care to control spinal cord function during correcting surgery [67, 131, 168, 173] (see Chapters 12, 15). The use of intraoperative somatosensory evoked potential (SSEP) recording has been found to reduce the incidence of postoperative neurological deficits [161, 166]. Combined monitoring of motor and somatosensory potentials has even been found to be superior compared to single mode monitoring by increased sensitivity [174].

## Indications for Surgery

Indications for surgery are somewhat different for the specific age group and are discussed under each type of scoliosis accordingly.

### Infantile and Juvenile Idiopathic Scoliosis

Spinal instrumentation without fusion is the surgical treatment of choice for infantile and juvenile curves

In these young patients, surgery is preserved for those curves that are severe and progressing despite conservative treatment. Lungs, thorax and spine are still incompletely developed and usually prohibit multisegmental spinal fusion in patients younger than 5–6 years. Spinal instrumentation without fusion may be indicated in large progressive curves **allowing the spine still to grow**. Different systems are in use but all have a high risk of complications that may necessitate several revision operations [66, 105, 183]. If the curve deteriorates despite instrumentation, definitive fusion of the spine should be considered. In this age group, the surgical treatment of scoliosis is usually difficult, prone to complications and requires multiple surgeries.

### Adolescent Idiopathic Scoliosis

Progressive adolescent curves (>40–50°) are considered surgical candidates

Progressive curves (>40–50°) in skeletally immature patients (Risser Grade 3 or less) are usually considered candidates for surgery. It should be taken into account that large curves may progress even after skeletal maturity [5, 179, 222]. Cosmetic aspects may also play a role in the indication of surgery, especially in the presence of a substantial rib hump or shoulder asymmetry [81].

### Adult Idiopathic Scoliosis

Indications for surgery in adult idiopathic scoliosis depend on the predominant problem [1, 15], i.e.

- back and/or leg pain
- radiculopathy
- claudication symptoms
- curve progression
- spinal imbalance

The surgical indication in adult curves is determined by the secondary degeneration

A thorough diagnostic work-up must be done to reveal the specific problem and potential pain sources. In cases of adult scoliosis with predominant degenerative alterations, similar principles apply as for **de novo scoliosis** (see Chapter 26). Accordingly, selective decompression of neural structures and/or spinal fusion with or without deformity correction is indicated [16].

## General Principles

### Approach

The choice of the surgical approach, i.e., posterior, anterior or combined anterior and posterior, depends on:

- curve type and size
- curve rigidity
- skeletal maturity
- spinal instrumentation
- surgical skills

#### *Posterior Approach*

The posterior approach addresses the deformity by fixing rods to the posterior structures of the spine, i.e., the pedicles, the transverse processes, or the laminae (Fig. 7). This approach necessitates detachment of the posterior paraspinal muscles. Only little is known about the extent of muscle detachment in scoliosis surgery but it does not seem to interfere significantly with the spinal muscle function after 3–6 months [53]. **Harrington** introduced the first instrumentation for posterior scoliosis correction in the 1960s [85]. In general, long term outcome in terms of quality of life, disability and patient satisfaction were found to be quite satisfactory after the Harrington operation [38, 74, 154, 169, 170].

In the 1970s, **Luque** introduced segmental spinal fixation using sublaminar wires [132].

The so-called **third generation instrumentations** were introduced in the 1980s. These modern implant systems allowed for a segmental instrumentation by the use of contourable rods that are fixed to the spine by lamina hooks, pedicle hooks, transverse process hooks, and pedicle screws. The instrumentation systems of **Cotrel Dubousset** [40], the **Texas Scottish Rite Hospital** (TSRH) and the **ISOLA** were the most frequently used implants at that time which allowed for more correction and preservation of lower lumbar motion segments compared to the Harrington system [114]. Despite the advances of the third generation instrumentations, correction of vertebral rotation is limited even with the use of pedicle screws. In young patients with a large growth potential there is a risk of continuing anterior growth of the spine despite a solid posterior fusion, which leads to the so-called crankshaft phenomenon (see below).

Correction of vertebral rotation remains a challenge

#### *Anterior Approach*

Anterior scoliosis correction allows for a better derotation and shorter fusion

Dwyer introduced the anterior approach for scoliosis correction in 1969 [57]. Ten years later, Zielke first introduced the concept of anterior derotation spondylodesis using vertebral body screws connected by a rod [238]. He reported on

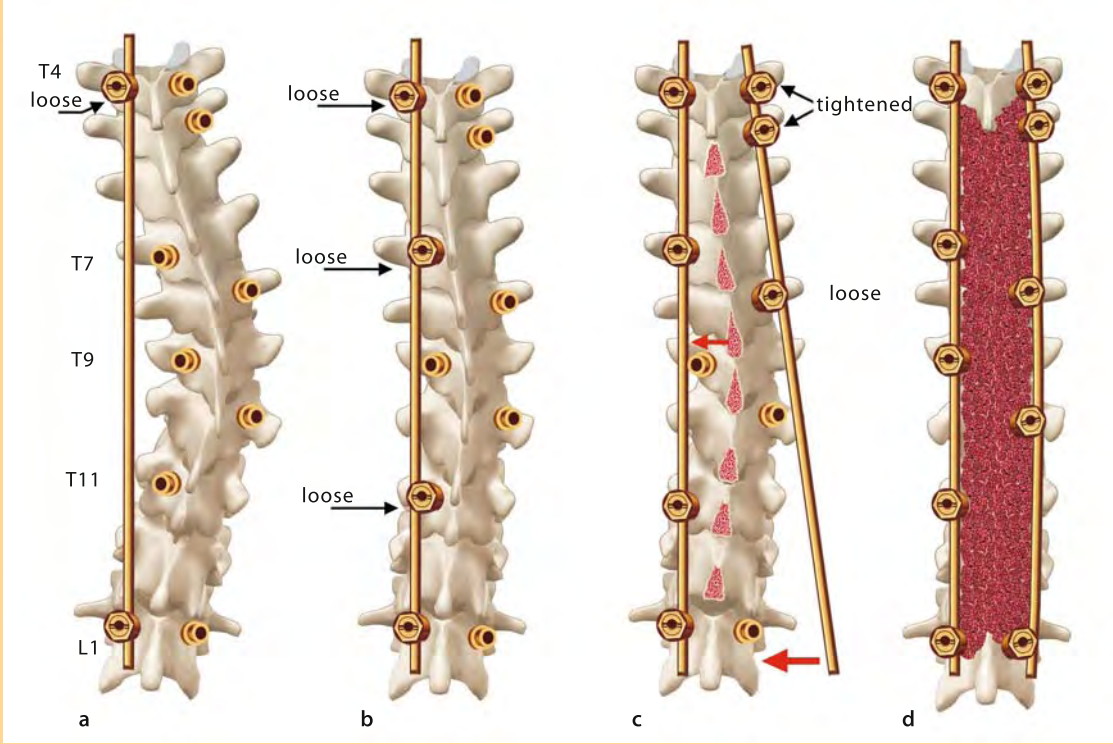


**Figure 7. Technique of posterior scoliosis correction**

The technique of posterior scoliosis correction is exemplified using the Universal Spine System. a, b Pedicle screws are inserted in the target vertebra and a rod is first inserted on the concave side of the curve and connected to the screws, c, d Insertion of the convex rod and levering it to the lower screws allows the concave apex screw to be narrowed to the rod achieving a good correction. A posterior fusion is added.

shorter fusion lengths and better vertebral derotation compared to posterior procedures.

The fusion usually incorporates all segments between upper and lower end vertebrae [10, 112, 128, 209, 218]. The spine is exposed by a thoracotomy, lumbotomy or a **thoraco-lumbotomy** depending on the anatomical location of the curve. The intervertebral discs are completely removed at the levels selected for fusion. Correction in the coronal, sagittal and axial planes is achieved by proper placement of the screws into the vertebral bodies and connection to a **pre-bent single** or **double rod** (Fig. 8, Case Introduction). The disc space can be filled with bone (e.g., resected rib) to enhance interbody fusion. These approaches are obviously technically more demanding than a posterior approach and are restricted to the mid thoracic to upper lumbar levels. The morbidity caused by a thoracotomy is not negligible but can be kept very low in experienced hands. Recently, **thoracoscopic procedures** have been introduced which are even more demanding [134, 152, 177, 178, 181, 206, 232]. Newton et al. [152, 153] reported on comparable results after thoracoscopic correction of thoracic curves compared with open techniques. Similar findings were reported by Grewal et al. [75] even though they reported a higher intraoperative blood loss in the thoracoscopic group. During the first year, the thoracoscopic approach was found to cause fewer declines in the vital capacity compared to the open anterior approach.

The rod needs to be pre-bent, creating a lordosis

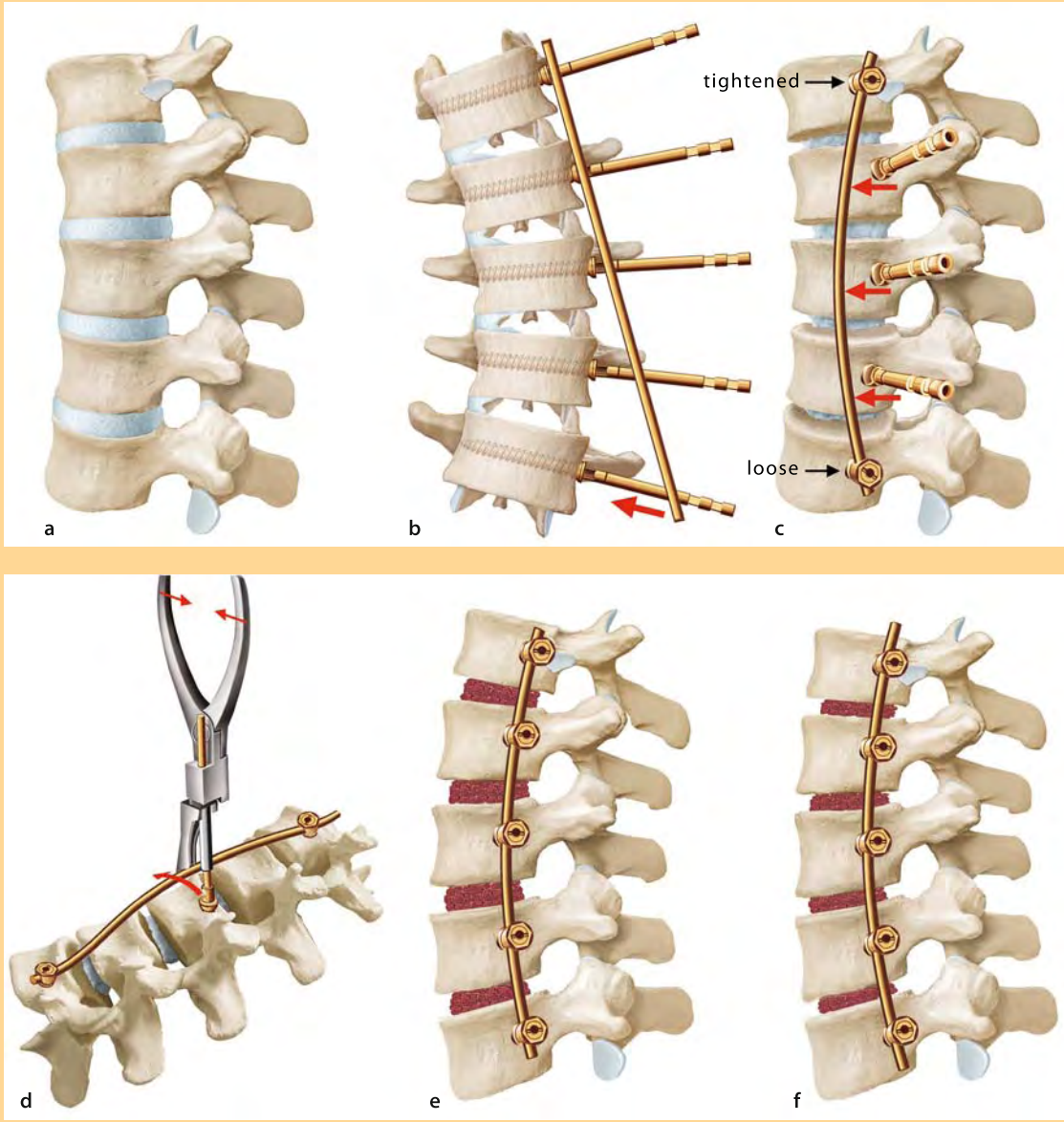


**Figure 8. Technique of anterior scoliosis correction**

The instrumentation is exemplified using the Universal Spine System. Prior to instrumentation the intervertebral discs are completely excised. a The insertion of the vertebral screws is anterior to the base of the pedicles. b, c Pedicle screws are inserted in the vertebral body and a pre-bent rod is connected to the screws in the upper and lower vertebrae. d A complex reduction forceps is used to narrow the remaining screws to the rod derotating the spine. e, f Disc spaces are compressed on the convex side after filling the disc spaces with bone. Full correction of the deformity is achieved.

### *Combined Anterior and Posterior Approach*

Anterior fusion avoids the crankshaft phenomenon in immature patients

Further growth of the anterior spinal column after posterior fusion before the pubertal growth spurt may lead to a loss of correction. The so-called **crankshaft phenomenon** leads to an increasing angulation and rotation of the spine [55], i.e., the spine is crankshafting around the posterior fusion mass. Dubousset, who first described this phenomenon, concluded that young patients with a high remaining growth potential should be fused anteriorly and posteriorly to prevent

crankshafting. Shufflebarger et al. [196] and Dohin et al. [51] provided evidence that this procedure was successful. Open tri-radiate cartilage and surgery before or during the peak growth velocity are strong positive predictors for the crankshaft phenomenon whereas later surgery is a strong negative predictor [190].

Curve rigidity may require a combined surgery

Another indication for using a combined anterior and posterior approach may be given by the **rigidity of a curve**. If the deformity is too rigid to prevent a satisfactory correction, an anterior release can be done prior to posterior fusion (Case Study 1). By performing a thoracotomy or thoracoscopy, the intervertebral discs in the apex region are removed. In a second step the correction and fusion of the spine is done from posteriorly. While a few studies doubt the need for anterior release even in severe adolescent idiopathic scoliosis [4, 26, 88, 130, 207], Cheung et al. found it to effectively improve spinal flexibility [33]. Severe deformities of adult idiopathic scoliosis may also require anterior release and posterior fusion [1].

### Fusion Levels

Pedicle screw fixation allows for better curve correction and shorter fusion

One of the most challenging issues in scoliosis surgery is to define the correct fusion levels. First, all structural curves must be determined [103, 113]. In a second step, the neutral (no rotation) vertebrae at the upper and lower end of the curve are determined for each curve. Thirdly, the central sacral vertical line is drawn. The stable lower end vertebra is then defined as the one being closest to the curve's lower neutral end-vertebra and most nearly bisected by the central sacral vertical line. Usually a fusion to the **stable end vertebra** defined by the central sacral vertical line results in a good correction with a balanced spine. However, the decision whether the fusion may exclude one segment or include one additional segment is also dependent on the individual curve and the surgeon's experience. Bernstein and Hall reported on the selection of fusion levels for anterior fusion of lumbar and thoracolumbar curves [12]. They showed that by including one vertebra above and below the apex vertebra, good results can be achieved if a slight overcorrection is performed. Only in severe curves (>60°) and if the apex was an intervertebral disc did they include two vertebrae above and below. Recently, it has been shown that the posterior segmental instrumentation with pedicle screws allows for a shorter fusion than with Harrington rods [114] or hooks alone [101].

Lumbar levels should be preserved whenever possible

Halm et al. [82] showed that anterior instrumentation of lumbar curves allows one caudad segment to be spared compared to a segmental posterior pedicle instrumentation. However, Hee et al. [87] found comparable fusion lengths. Bitan et al. [13] and Min et al. [142] reported shorter fusion lengths by using the anterior approach compared with a posterior approach.

### Spinal Profile and Spinal Balance

A slight hypokyphosis is common in right thoracic curves

A thoracic kyphosis of 20°–40° and a lumbar lordosis of 40°–60° can be considered normal [70, 146, 202]. In AIS a slight thoracic hypokyphosis is common. However, especially left convex idiopathic curves may be associated with thoracic hyperkyphosis as well. By using a modern instrumentation system through an isolated posterior approach, thoracic hypokyphosis can be corrected about 5°–10° [20]. Even though anterior correction was reported to allow for a better correction of hypokyphosis [89, 98], severe thoracic hypokyphosis or even thoracic lordosis may necessitate a combined anterior and posterior approach [18]. In thoracolumbar and lumbar curves usually a hypolordosis or even a slight kyphosis is present in AIS patients. It has been reported that an anterior instrumentation allows for a good segmental restoration of the lordosis [89, 99]. Despite the

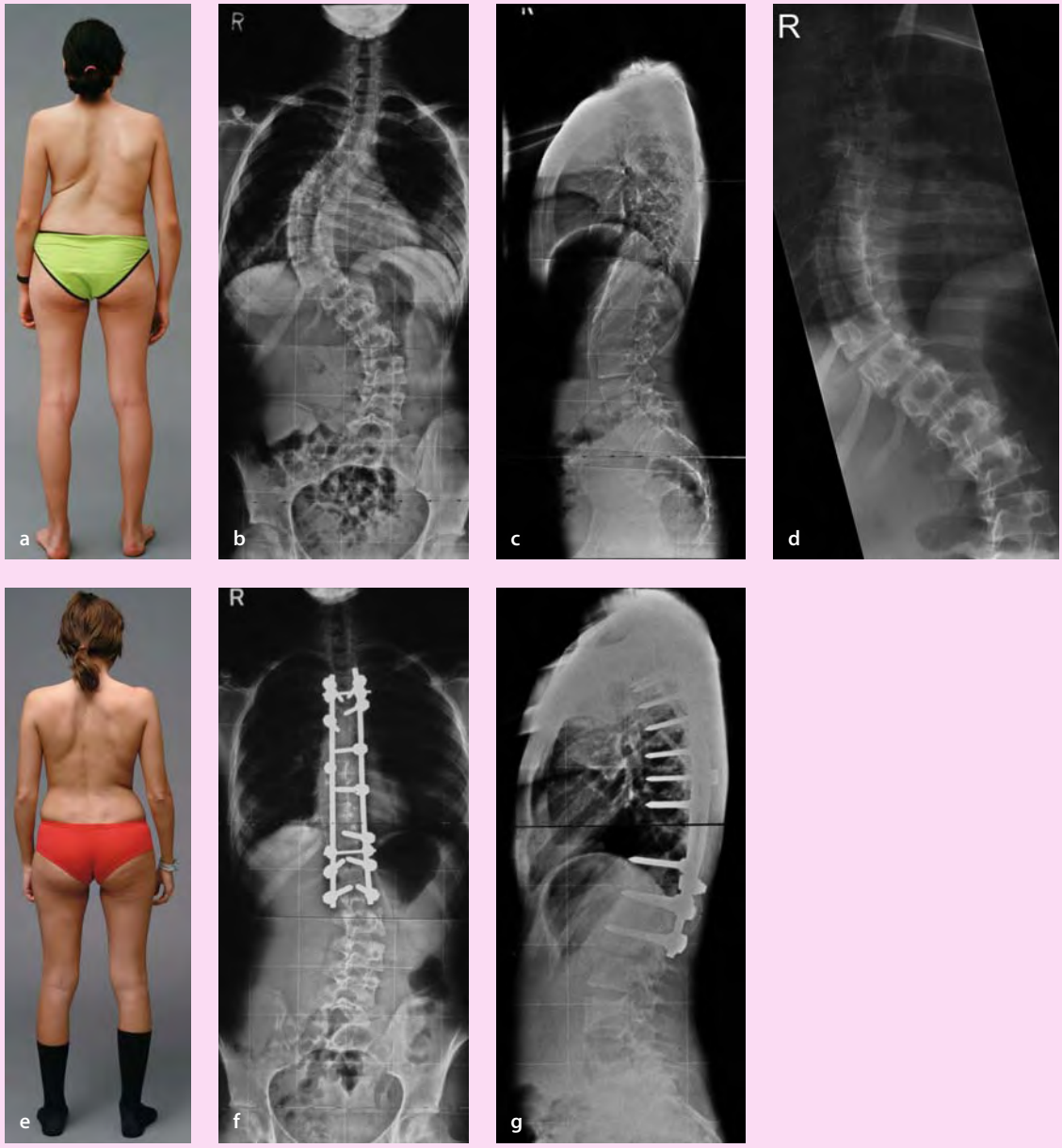


## Case Study 1

A 16-year-old patient presented with a severe thoracic idiopathic scoliosis (a). Although a back asymmetry had been noted for 2 years, the patient did not consult a physician because she was pain free. At the time of presentation, standard radiographs (b, c) showed a thoracic curve (T5–T12) of 75 degrees which corrected to 45 degrees on supine bending (d). Although the anteroposterior radiograph demonstrated Risser Type IV indicating only a minimal remaining growth potential, surgery was suggested because of the curve magnitude. In a first step, an anterior release was done to allow for a better curve correction, followed by a posterior instrumentation with pedicle screws and curve correction during the same intervention. Ten years after the operation, the patient was pain free and working full time as a mechanic (e). The follow-up radiographs demonstrate a curve correction to 20 degrees and a balanced spine (f, g).

kyphogenic character of the anterior instrumentation, a good correction can be achieved even without structural intervertebral support [127]. Severe hypolordosis or kyphosis in middle-aged adults with degenerative changes often requires combined anterior and posterior surgery and longer fusion length to restore sagittal profile and spinal balance [1, 18].

A complication of the early scoliosis correction with Harrington distraction rods was a proneness to result in a so-called iatrogenic **flat back syndrome**, i.e., a loss of the normal sagittal profile (decreased lumbar lordosis and thoracic kyphosis). In cases in which the whole lumbosacral spine is flattened, patients have problems standing upright and need to bend their knees to rebalance the spine because the trunk is inclined anteriorly. This problem is infrequent today because the modern instrumentation systems also allow sagittal balance and profile to be addressed [226].

A special issue of concern after scoliosis surgery is the development of iatrogenic **coronal imbalance**. This problem occurs when correcting the major curve beyond the compensatory potential of the minor curves. The rigidity of the minor curves has to be taken into account prior to fully correcting the major curve.

### Thoracoplasty

The rib hump in thoracic scoliosis results from vertebral rotation and concomitant deformation of the rib cage. Therefore, the rib hump can only partially be corrected by vertebral derotation. In cases in which this deformity should be addressed for cosmetic reasons, a **thoracoplasty** can be done by a removal of parts of the most prominent ribs [69, 203]. It is generally accepted that thoracoplasty in addition to scoliosis correction should be considered when the rib hump measures more than 15° [143]. Disadvantages to be considered are a possible temporary decrease of pulmonary function and the potential risk for complications such as pneumothorax and intercostal pain [115]. Impaired vascular supply to the spinal cord by coagulation of the segmental vessels can occur when performing an internal (transthoracic) thoracoplasty [197].

## Surgical Decision-Making

A detailed description of treatment guidelines and surgical procedures is far beyond the scope of this chapter. However, we want to provide here a short overview of surgical decision-making (Table 3).

### Infantile and Juvenile Idiopathic Scoliosis

In cases of severe scoliosis in young children, the application of serial orthotic casts or braces may not be sufficient to stop curve progression. On the other hand, fusion in a young child should be avoided to prevent growth arrest or crankshafting resulting in a short trunk with consecutive disproportionate body habitus or impaired lung function. Therefore, fusion should be postponed as long as possible and spinal instrumentation without fusion is performed if conservative therapy fails to control the curve. The main objective of using **expandable spinal instrumentation** is to stop progression of the curve, maintain spinal balance and allow spinal growth. Definitive fusion surgery is delayed as long as possible. In 1984, Moe et al. [145] described a technique using a Harrington distraction rod which was continuously lengthened with growth or, if necessary, replaced by a longer one. Even though progression may be stopped in most patients by this procedure, there is the drawback of repeated interventions and

Expandable spinal instrumentation is indicated when spinal growth should be preserved

**Table 3.** Surgical indications and techniques

| | Age of onset | | | |
|---|---|---|---|---|
| | Infant (0–2 yrs) | Juvenile (3–9 yrs) | Adolescent (10–17 yrs) | Adult (>17 yrs) |
| **General considerations** | • large age span affords variable indications<br>• loss of spinal height, chest wall growth and lung growth in case of fusion are a major concern | | • arrest of curve progression, deformity correction and solid spinal fusion is the main objective | • indication guided by the predominant symptoms |
| **Age** | • >6 yrs if possible (maturation of the lungs) [208] | | • crankshaft phenomenon must be avoided | • higher risk of surgery related morbidity >40 yrs [17, 46, 210] |
| **Cobb angle** | • progressive curves >45–60° despite former orthotic treatment [50, 116] | | • progressive curves >40° in skeletally immature patients<br>• curves >45–50° even in skeletally mature patients [5, 179, 222] | • progressive and/or symptomatic curves |
| **Techniques** | | | | |
| **Growing rod** | • young children | | – | – |
| **Anterior and posterior fusion** | • older children (8–10 yrs) at risk of crankshaft phenomenon [51, 190, 196] | | • skeletally immature patients at risk of crankshaft phenomenon [51, 190, 196] | • severe cases with spinal imbalance or flat back syndrome [1, 46] |
| **Anterior release and posterior fusion** | – | – | • indicated in patients with severe rigid deformity [4, 26, 33, 88, 130, 207] | – |
| **Anterior or posterior fusion** | – | – | • depending on the curve type | • usually only posterior or combined fusion |

complications such as rod fracture or hook displacement [144]. More recent methods with single or dual growing rod techniques are used [14, 144]. Dual rods were reported to be stronger than single rods and provide a better correction and maintenance of correction as well as fewer complications [3, 214]. Despite the improvements obtained by these newer methods, complications and reinterventions remain unavoidable.

A special instrumentation system, the so-called vertical **expandable prosthetic titanium rib** (VEPTR), allows for an indirect correction of the scoliosis by lengthening of the deformed thorax on the concave side of the curve [28, 29]. Preliminary data indicate that this technique is particularly effective in the treatment of congenital scoliosis with rib cage deformities [213]. It remains unclear whether this technique is also effective for juvenile scoliosis.

## Adolescent Idiopathic Scoliosis

The main objectives are arrest of curve progression and fusion

The main objective of surgical treatment is correction of the deformity and maintaining the correction by spinal fusion. When surgically addressing AIS, one would therefore want to improve the coronal deformity (Cobb angle), try to reduce the most visible deformity, i.e., rib hump, restore a normal sagittal profile and achieve or preserve sagittal and coronal spinal balance.

### *Thoracic Curves*

A single thoracic curve may be treated by **anterior or posterior** fusion, the latter being the classic approach. The posterior approach usually includes fusion of the entire curve. Using pedicle screws instead of hooks offers a better curve correc-

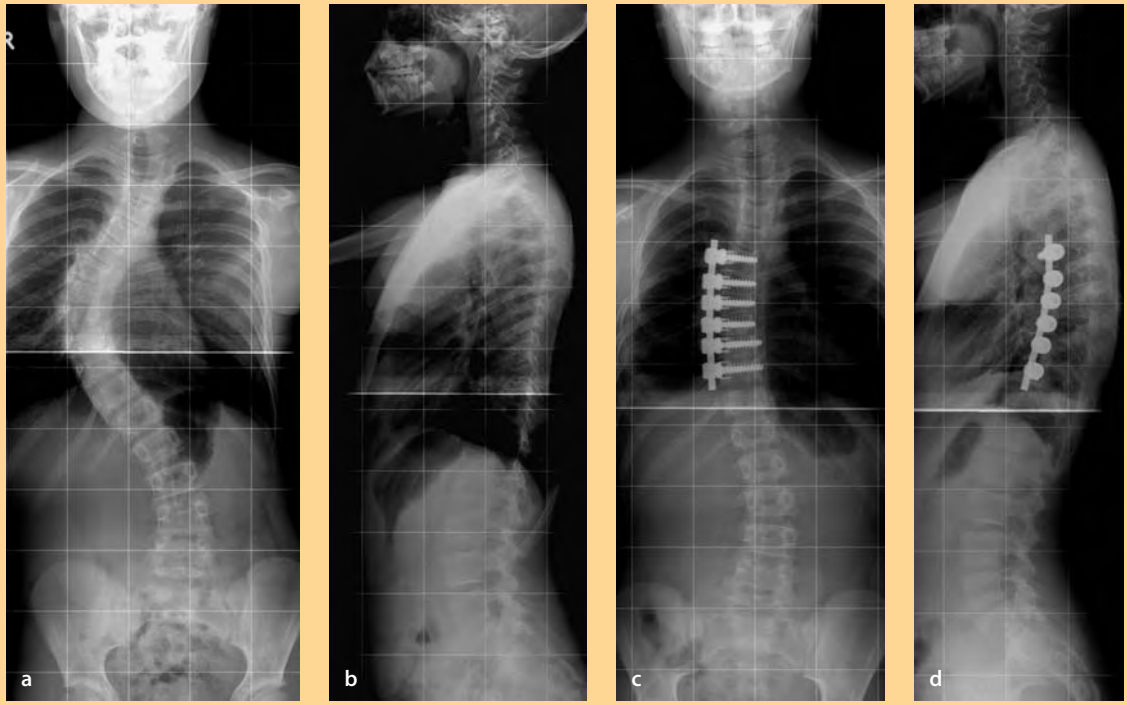


**Figure 9. Anterior thoracic scoliosis correction**

a, b Preoperative radiographs showing a decompensated King type III curve (same patient as Fig. 2c). c, d Postoperative radiographs showing excellent curve correction and restoration of the coronal balance.

tion and enables a slightly shorter fusion length than with the use of hooks [101]. The use of pedicle screws allows for a better rotational and coronal correction [109]. In the hands of an experienced surgeon, neurological problems were not found to be higher with the use of pedicle screws [101]. The advantage of an anterior correction is the shorter fusion length and better derotation (Fig. 9). The anterior approach has a cosmetic advantage if the operation is performed by means of a **mini-thoracotomy** or **thoracoscopy** leaving only small scars. Although spontaneous lumbar curve correction occurs after both selective posterior and anterior thoracic fusion, the correction was found to be better in the latter approach [111]. When planning surgery for **double-thoracic curves**, preoperative shoulder balance (T1-tilt) and size (Cobb angle) and rigidity of the proximal thoracic curve must be considered to achieve a good outcome [108]. If the shoulder is elevated on the convex side of the major thoracic curve (i.e., on the right side) and the proximal thoracic curve corrects to less than 25° in the side bending view, spontaneous correction of the proximal thoracic curve with level shoulders can be expected after isolated selective anterior fusion of the major curve [108]. If both thoracic curves need fusion, the operation must be done from posteriorly.

Pedicle screws allow for a better scoliosis correction

In double thoracic curves attention must be paid to shoulder balance, curve size and rigidity

### *Thoracolumbar and Lumbar Curves*

An isolated fusion of these curve types without addressing the thoracic curve (if present) is possible if the thoracic curve reduces to less than 25° in the bending radiograph [142]. These curves benefit most from a short anterior scoliosis correction (Case Introduction), preserving more mobile motion segments com-

Thoracolumbar curves are best treated from anteriorly

pared to posterior fusion [60, 142]. If the thoracic curve remains larger than 25° in the bending radiograph, it should probably be addressed surgically in order to avoid decompensation of spine and shoulder balance.

### *Double Major Curves*

These curve patterns with a thoracic and a thoracolumbar or lumbar structural curve are usually operated on from posteriorly indicating that a big part of the spine has to be fused. Attempts to fuse the lumbar curve anteriorly and only the thoracic curve posteriorly have recently been suggested. It was reported that an anterior release with instrumented fusion of the lumbar curve was superior to an anterior release followed by posterior instrumented fusion [236]. Only preliminary data is available on the short selective anterior fusion of both the thoracic and the lumbar curve with the potential advantage of preserving motion segments in double major curves [141].

Motion segment preservation is an important goal

## Adult Idiopathic Scoliosis

The general state of health, age and bone quality play important roles in the surgical decision-making. Morbidity for surgery is lower in younger patients (< 40 years) and the chance of a better outcome will also be higher than in older patients (> 40 years) [17, 46, 210]. **Surgical decision-making** in adult idiopathic scoliosis strongly depends on the underlying causes of pain, which have to be explored thoroughly. With predominant irradiating pain or claudication without relevant back pain, selective spinal decompression may be performed as a standalone procedure [1]. In younger patients a partial correction of the deformity may already lead to a sufficient decompression without a formal decompression being performed (Case Study 2). If additional segmental instability, extensive degenerative changes and progressive deformity lead to back pain, posterior and/or anterior fusion and stabilization with/without decompression and correction may be required [194]. To achieve a **balanced spine** and prevent a postoperative collapse of the adjacent segment, the fusion usually has to extend beyond the major curve. Stopping the fusion of a lumbar curve below the thoracolumbar junction usually bears a high risk of sagittal decompensation of the spine cranially [83]. It is still controversial whether or not the lumbosacral junction should be included in the fusion [17, 19, 45, 90]. If unfused, the L5/S1 segment has to take all the movements and loads of the fused lumbar spine [107, 194]. Furthermore, a fusion to the sacrum leads to higher stress for the sacroiliac and hip joints.

Surgical treatment is strongly influenced by the pain sources

On the other hand, it is difficult to achieve a solid fusion at this level. Nonunion rates of up to 30 % are reported if the fusion is not done circumferentially [19, 59].

It has to be borne in mind that the spine may be in a fragile balance before surgery and that a decompression and/or a partial fusion may lead to a deterioration of this balance leading to progressive deformity and disability. If spinal balance is preserved, fusion in situ will often be the method of choice as an adjunct to decompression [1]. If there is a derangement either in the coronal and/or sagittal plane (e.g., flat back syndrome), additional correction of the deformity is necessary [1]. An imbalanced spine with secondary degenerative changes requires extensive release of the posterior structures and in some cases multiple spinal osteotomies (see Chapter 26). Frequently, a combined anterior and posterior approach may be necessary [46].

The goal is to achieve a balanced spine without pain and normal neurology

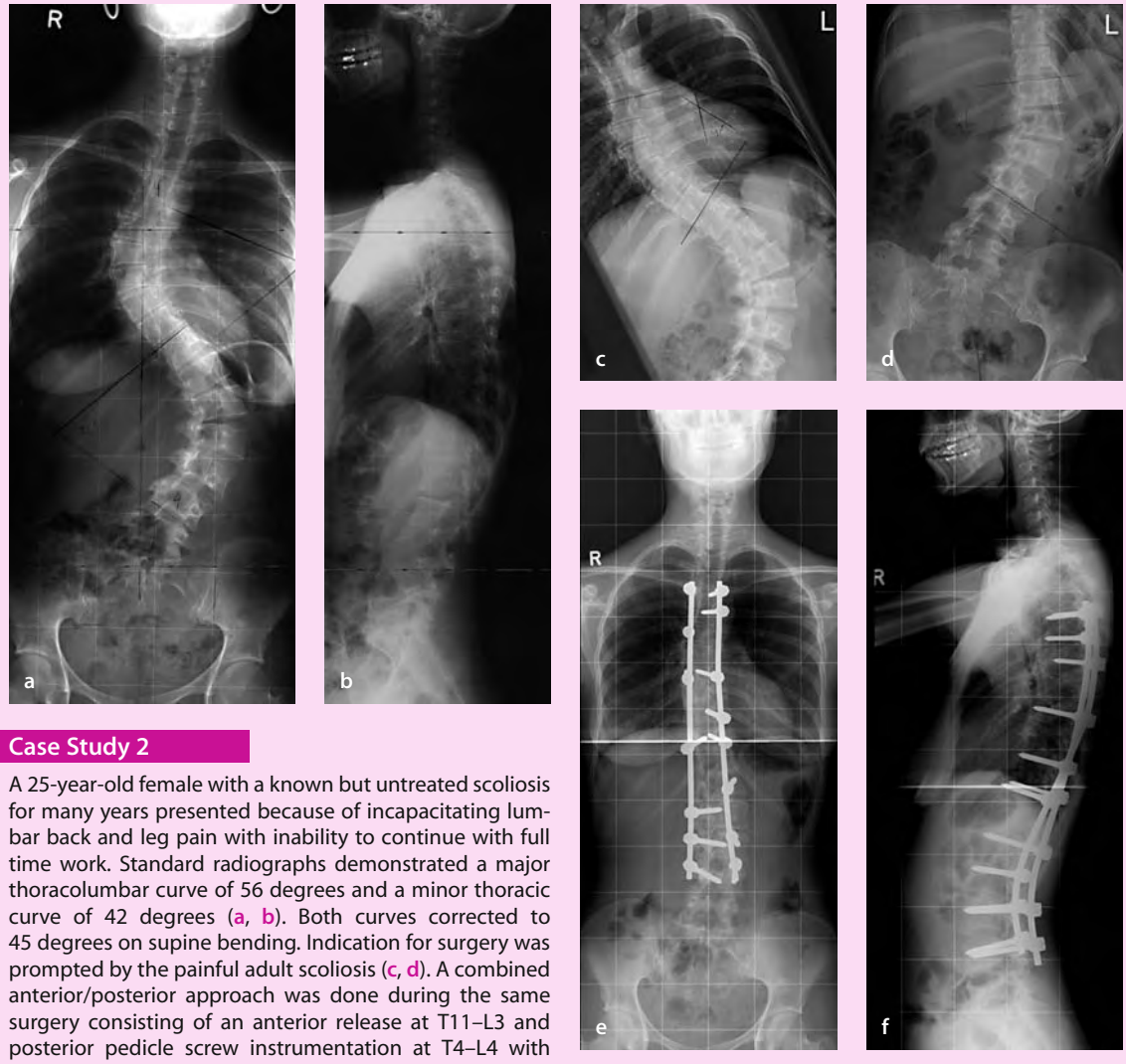


**Case Study 2**

A 25-year-old female with a known but untreated scoliosis for many years presented because of incapacitating lumbar back and leg pain with inability to continue with full time work. Standard radiographs demonstrated a major thoracolumbar curve of 56 degrees and a minor thoracic curve of 42 degrees (a, b). Both curves corrected to 45 degrees on supine bending. Indication for surgery was prompted by the painful adult scoliosis (c, d). A combined anterior/posterior approach was done during the same surgery consisting of an anterior release at T11–L3 and posterior pedicle screw instrumentation at T4–L4 with scoliosis correction. At 5 years follow-up the patient was very satisfied with the result. The radiographs revealed a balanced spine with excellent curve correction (e, f).

## Complications

The most deleterious complication of scoliosis surgery is a neurological compromise particularly in AIS (Table 4). Complications of scoliosis surgery are discussed in more detail in Chapter 39.

**Neurological injury** can result from either direct contusion or an ischemic insult. Generally, resolution of the deficits is more likely to occur after contusion.

In experienced hands, spinal cord injury is rare

**Table 4.** Complications in scoliosis surgery

| Complication | Incidence | References |
|---|---|---|
| spinal cord injury | 0.5–3% | [54, 126] |
| nerve root injury | 0.5% | [126] |
| early wound infection | 0.1–5% | [72, 140, 212, 217] |
| delayed wound infection | 0.6–1.7% | [7, 35, 229] |
| non-union | 0–2.2% | [7, 200, 223] |

Ischemia of the spinal cord can result from stretching of the blood vessels feeding the spinal cord or by prolonged hypotension. Therefore, a reduction of the correction and restoration of a sufficient perfusion should be achieved if neurological injury is noticed intraoperatively. Ligation of anterior segmental arteries has also been suggested to increase the likelihood of ischemia of the cord [21].

**Early wound infections** occur within 12 weeks of the initial intervention. Malnourished and immunocompromised patients are at substantially higher risk for infections [104]. To minimize intraoperative infection, antibiotic prophylaxes are routinely used. If an early wound infection is diagnosed, wound revision and antibiotic treatment after isolation of the germ is indicated. The wound is thoroughly debrided and loose bone graft is removed. Titanium implants can be left in place to avoid loss of correction and non-union [212].

Delayed wound infections are caused by low-virulent germs

**Delayed wound infections** occur 20 weeks or longer after the initial intervention. Usually patients become symptomatic only after 2–3 years [35]. If the diagnosis is confirmed, surgical intervention is indicated removing all implants. If the fusion is solid, usually no further measures are necessary besides implant removal.

**Non-union** may be associated with hardware loosening, dislodgement or breakage requiring revision surgery.

## Recapitulation

**Epidemiology.** Idiopathic scoliosis is the most common structural spinal deformity in the child and adolescent. The overall **prevalence** of adolescent idiopathic scoliosis is about 2–3% in the adolescent population. The prevalence decreases to about 0.1–0.3% for curves larger than 30°. Adolescent idiopathic scoliosis is the most frequent type (80%). Only about 1% of idiopathic scoliosis affects children younger than 3 years. Considering AIS requiring therapy, girls are three times more often affected than boys.

**Pathogenesis.** There is some evidence that an **asymmetrical vertebral growth** of the anterior column with tethering of the posterior structures leads to the deformity. Genetic aspects, platelet defects, cell membrane defects, abnormalities of calmodulin and melatonin levels have been suspected to play a role in scoliosis development.

**Classification.** According to the **age of onset**, the disease is divided into infantile (0–3 years), juvenile (3–10 years), adolescent (10–18 years) and adult (>18 years) idiopathic scoliosis. King has proposed a classification of the thoracic curve into five types. The Lenke classification includes not only thoracic but also thoracolumbar and lumbar curve types as well as the sagittal profile. The curve types are helpful when selecting fusion levels.

**Clinical presentation.** Most often scoliosis is discovered accidentally. **Pain** or functional disability is rare in adolescent scoliosis. If present, pain should raise suspicion about a secondary etiology (i.e., non-idiopathic), prompting further diagnostic investigations into the etiology. Family and **developmental medical history** must be assessed with emphasis on growth spurt and menarche. Small asymmetries such as an S-shaped line of the spinal processes, a slightly more prominent scapula or asymmetric lumbar triangles may indicate the presence of scoliosis and the location on physical examination. The most reliable clinical sign for scoliosis is the presence of a rib hump on the convex side of the curve best seen in forward bending. Convexity and flexibility of all curves must be assessed.

**Diagnostic work-up.** **Standard radiography** of the entire spine with the patient in standing position is still the hallmark of the imaging studies. The radiological assessment considers curve size and location, spinal balance in the coronal and sagittal plane, pelvic and shoulder level, as well as the sagittal profile (i.e., hypo-/hyper-kyphosis/lordosis). Supine bending radiographs are necessary to determine curve rigidity and are necessary for surgical planning. **Atypical curve pattern** (left thoracic curve) and neurological deficits such as absent abdominal wall reflexes may indicate intramedullary pathologies and require further investigation with MRI.

**Treatment.** Treatment of **infantile and juvenile scoliosis** remains a therapeutic challenge because of the adverse effects of multisegmental fusion in a growing spine. If conservative treatment (cast, braces) has failed to control the curve, spinal instrumentation without fusion becomes necessary. Surgery for these curve types is very demanding and prone to complications often requiring revision surgery.

The **natural history** of **adolescent idiopathic scoliosis** is benign without significant differences to an asymptomatic control group regarding physical functioning and quality of life in adulthood. The treatment depends on the severity of the curve and the risk of progression. Conservative treatment is intended to control progression of smaller curves. It consists of observation and physiotherapy in curves less than 10°–25° in skeletally immature patients. Curves of 25°–40° are usually treated by **bracing**. Braces are only effective before skeletal maturity is reached. Surgery is indicated in curves larger than 40°–50° or rapidly progressing curves despite conservative treatment. The objective of scoliosis surgery is to stop the progression and to correct the deformity. **Posterior instrumentation and fusion** remains the gold standard and allows for a correction of the coronal deformity with restoration of the coronal and sagittal balance and profile. Today, pedicle screws are frequently used as they allow a better correction and shorter fusion length than systems only using hooks and wires. In skeletally immature patients an anterior release and fusion is necessary to avoid further anterior growth after posterior fusion with a deterioration of the deformity (**crankshaft phenomenon**). The more demanding **anterior scoliosis surgery** often allows motion segments to be spared and vertebral rotation to be better addressed.

In contrast to adolescent scoliosis, **adult idiopathic scoliosis** patients often present with symptoms (pain, neurological deficits) due to secondary degenerative changes. Surgical decision-making in adult idiopathic scoliosis strongly depends on the underlying causes of the pain or neurological deficits. The goal in adult scoliosis is to achieve a balanced spine without pain or neurological deficits. Decompression of a nerve root compression or secondary central stenosis is possible in selected patients with a balanced spine. Fusion in situ (w/o short-segmental instrumentation) should be added when extensive decompression is needed to avoid curve deterioration. The treatment of an imbalanced spine with secondary degenerative changes often requires extensive posterior release and in some cases necessitates multiple spinal osteotomies.

## Key Articles

**Nachemson A (1968) A long term follow-up study of non-treated scoliosis. Acta Orthop Scand 39:466–476**
This is one of the first long-term follow-up studies on the natural course of scoliosis. Different types of scoliosis are included. For congenital, thoracogenic and neurogenic scoliosis prognosis was found to be worse than for idiopathic, rachitogenic and poliomyelitic scoliosis.

**Weinstein SL, Zavala DC, Ponseti IV (1981) Idiopathic scoliosis: long-term follow-up and prognosis in untreated patients. J Bone Joint Surg Am 63:702–712**
Thoracic curves of 50°–80° were found to be at a high risk of progressing even after skeletal maturity was reached. Curves smaller than 30° did not progress regardless of the curve pattern. In thoracic curves, the Cobb angle and vertebral rotation were found to be important risk factors for curve progression.

**Lonstein JE, Carlson JM (1984) The prediction of curve progression in untreated idiopathic scoliosis during growth. J Bone Joint Surg Am 66:1061–1071**
In this study of patients with mild idiopathic scoliosis, pattern and magnitude of the curve, the patient's age at first diagnosis, menarchal status and the Risser sign were found to be related to curve progression during growth.

**Harrington PR (1962) Treatment of scoliosis. Correction and internal fixation by spine instrumentation. J Bone Joint Surg 44A:591–610**
Historical paper on spinal instrumentation for scoliosis describing the technique of scoliosis correction by distraction.

**Cotrel Y, Dubousset J (1984) A new technique for segmental spinal osteosynthesis using the posterior approach. Rev Chir Orthop Reparatrice Appar Mot 70:489 – 494**
Cotrel and Dubousset describe their technique for the posterior segmental derotation technique of scoliosis correction.

**Dubousset J, Herring JA, Shufflebarger H (1989) The crankshaft phenomenon. J Pediatr Orthopedics 9:541 – 550**
This article first describes the progression of the anterior column deformity despite posterior instrumentation and solid fusion, the so-called crankshaft phenomenon.

**King HA, Moe JH, Bradford DS, Winter RB (1983) The selection of fusion levels in thoracic idiopathic scoliosis. J Bone Joint Surg Am 65:1302 – 1313**
Landmark paper on the classification of thoracic curves into five types.

**Lenke LG, Betz RR, Harms J, Bridwell KH, Clements DH, Lowe TG, Blanke K (2001) Adolescent idiopathic scoliosis: a new classification to determine extent of spinal arthrodesis. J Bone Joint Surg 83A:1169 – 1181**
The King classification only included thoracic curves. Lenke et al. therefore developed a new more comprehensive classification system. It allows the classification of 42 different curve patterns including all curve types and the thoracic sagittal profile. This classification is helpful for the selection of fusion levels.

## References


1. Aebi M (2005) The adult scoliosis. Eur Spine J 14:925 – 948
2. Akbarnia BA (2007) Management themes in early onset scoliosis. J Bone Joint Surg Am 89 Suppl 1:42 – 54
3. Akbarnia BA, Marks DS, Boachie-Adjei O, Thompson AG, Asher MA (2005) Dual growing rod technique for the treatment of progressive early-onset scoliosis: a multicenter study. Spine 30:S46 – 57
4. Arlet V, Jiang L, Ouellet J (2004) Is there a need for anterior release for 70 – 90 degrees masculine thoracic curves in adolescent scoliosis? Eur Spine J 13:740 – 745
5. Ascani E, Bartolozzi P, Logroscino CA, Marchetti PG, Ponte A, Savini R, Travaglini F, Binazzi R, Di Silvestre M (1986) Natural history of untreated idiopathic scoliosis after skeletal maturity. Spine 11:784 – 789
6. Ascani E, Giglio G, Salsano V (1980) Scoliosis screening in Rome. In: Zorab P, Siegler D (eds) Scoliosis. Academic Press, London
7. Asher M, Lai SM, Burton D, Manna B, Cooper A (2004) Safety and efficacy of Isola instrumentation and arthrodesis for adolescent idiopathic scoliosis: two- to 12-year follow-up. Spine 29:2013 – 2023
8. Axenovich TI, Zaidman AM, Zorkoltseva IV, Tregubova IL, Borodin PM (1999) Segregation analysis of idiopathic scoliosis: demonstration of a major gene effect. Am J Med Genet 86:389 – 394
9. Barnes PD, Brody JD, Jaramillo D, Akbar JU, Emans JB (1993) Atypical idiopathic scoliosis: MR imaging evaluation. Radiology 186:247 – 253
10. Benli IT, Akalin S, Kis M, Citak M, Kurtulus B, Duman E (2000) The results of anterior fusion and Cotrel-Dubousset-Hopf instrumentation in idiopathic scoliosis. Eur Spine J 9:505 – 515
11. Bergofsky EH (1979) Respiratory failure in disorders of the thoracic cage. Am Rev Respir Dis 119:643 – 669
12. Bernstein RM, Hall JE (1998) Solid rod short segment anterior fusion in thoracolumbar scoliosis. J Pediatr Orthop B 7:124 – 131
13. Bitan FD, Neuwirth MG, Kuflik PL, Casden A, Bloom N, Siddiqui S (2002) The use of short and rigid anterior instrumentation in the treatment of idiopathic thoracolumbar scoliosis: a retrospective review of 24 cases. Spine 27:1553 – 1557
14. Blakemore LC, Scoles PV, Poe-Kochert C, Thompson GH (2001) Submuscular Isola rod with or without limited apical fusion in the management of severe spinal deformities in young children: preliminary report. Spine 26:2044 – 2048
15. Boachie-Adjei O, Gupta MC (1999) Adult scoliosis and deformity. AAOS Instructional Course Lectures 48:377 – 391
16. Bradford DS (1988) Adult scoliosis. Current concepts of treatment. Clin Orthop Related Res 229:70 – 87
17. Bradford DS, Tay BK, Hu SS (1999) Adult scoliosis: surgical indications, operative management, complications, and outcomes. Spine 24:2617 – 2629

18. Bridwell KH (1998) Normalization of the coronal and sagittal profile in idiopathic scoliosis: options of treatment. J Orthop Sci 3:125 – 134
19. Bridwell KH (1996) Where to stop the fusion distally in adult scoliosis: L4, L5, or the sacrum? Instr Course Lect 45:101 – 107
20. Bridwell KH, Betz R, Capelli AM, Huss G, Harvey C (1990) Sagittal plane analysis in idiopathic scoliosis patients treated with Cotrel-Dubousset instrumentation. Spine 15:921 – 926
21. Bridwell KH, Lenke LG, Baldus C, Blanke K (1998) Major intraoperative neurologic deficits in pediatric and adult spinal deformity patients. Incidence and etiology at one institution. Spine 23:324 – 331
22. Brooks H (1980) Current incidence of scoliosis in California. In: Zorab P, Siegler D (eds) Scoliosis. Academic Press, London, pp 7 – 12
23. Brooks HL, Azen SP, Gerberg E, Brooks R, Chan L (1975) Scoliosis: A prospective epidemiological study. J Bone Joint Surg 57:968 – 972
24. Buckler J (1990) A longitudinal study of adolescent growth. Springer-Verlag, New York
25. Bunnell WP (1986) The natural history of idiopathic scoliosis before skeletal maturity. Spine 11:773 – 776
26. Burton DC, Sama AA, Asher MA, Burke SW, Boachie-Adjei O, Huang RC, Green DW, Rawlins BA (2005) The treatment of large (> 70 degrees) thoracic idiopathic scoliosis curves with posterior instrumentation and arthrodesis: when is anterior release indicated? Spine 30:1979 – 1984
27. Bylund P, Jansson E, Dahlberg E, Eriksson E (1987) Muscle fiber types in thoracic erector spinae muscles. Fiber types in idiopathic and other forms of scoliosis. Clin Orthop Related Res 214:222 – 228
28. Campbell RM, Jr (2005) The treatment of thoracic insufficiency syndrome associated with progressive early onset scoliosis by opening wedge thoracostomy. In: Annual Meeting of the Scoliosis Research Society, Miami
29. Campbell RM, Jr, Smith MD, Hell-Vocke AK (2004) Expansion thoracoplasty: the surgical technique of opening-wedge thoracostomy. Surgical technique. J Bone Joint Surg Am 86A Suppl 1:51 – 64
30. Carman DL, Browne RH, Birch JG (1990) Measurement of scoliosis and kyphosis radiographs. Intraobserver and interobserver variation. J Bone Joint Surg 72:328 – 333
31. Carr WA, Moe JH, Winter RB, Lonstein JE (1980) Treatment of idiopathic scoliosis in the Milwaukee brace. J Bone Joint Surg Am 62:599 – 612
32. Ceballos T, Ferrer-Torrelles M, Castillo F, Fernandez-Paredes E (1980) Prognosis in infantile idiopathic scoliosis. J Bone Joint Surg Am 62:863 – 875
33. Cheung KM, Lu DS, Zhang H, Luk KD (2006) In-vivo demonstration of the effectiveness of thoracoscopic anterior release using the fulcrum-bending radiograph: a report of five cases. Eur Spine J 15 Suppl 17:578 – 582
34. Citron N, Edgar MA, Sheehy J, Thomas DG (1984) Intramedullary spinal cord tumours presenting as scoliosis. J Bone Joint Surg Br 66:513 – 517
35. Clark CE, Shufflebarger HL (1999) Late-developing infection in instrumented idiopathic scoliosis. Spine 24:1909 – 1912
36. Classification WGo-D, Committee T (2000) SRS Terminology Committee and Working Group on Spinal Classification Revised Glossary of Terms.
37. Cobb J (1948) Outline for the study of scoliosis. AOS Instructional Course Lecture 5:261 – 275
38. Cochran T, Irstam L, Nachemson A (1983) Long-term anatomic and functional changes in patients with adolescent idiopathic scoliosis treated by Harrington rod fusion. Spine 8:576 – 584
39. Collis DK, Ponseti IV (1969) Long-term follow-up of patients with idiopathic scoliosis not treated surgically. J Bone Joint Surg 51:425 – 445
40. Cotrel Y, Dubousset J (1984) [A new technic for segmental spinal osteosynthesis using the posterior approach]. Rev Chir Orthop Reparatrice Appar Mot 70:489 – 494
41. Cummings RJ, Loveless EA, Campbell J, Samelson S, Mazur JM (1998) Interobserver reliability and intraobserver reproducibility of the system of King et al. for the classification of adolescent idiopathic scoliosis. J Bone Joint Surg 80:1107 – 1111
42. Danielsson AJ, Nachemson AL (2001) Childbearing, curve progression, and sexual function in women 22 years after treatment for adolescent idiopathic scoliosis: a case-control study. Spine 26:1449 – 1456
43. Danielsson AJ, Wiklund I, Pehrsson K, Nachemson AL (2001) Health-related quality of life in patients with adolescent idiopathic scoliosis: a matched follow-up at least 20 years after treatment with brace or surgery. Eur Spine J 10:278 – 288
44. De George FV, Fisher RL (1967) Idiopathic scoliosis: genetic and environmental aspects. J Med Genet 4:251 – 257
45. Deyo RA, Cherkin DC, Loeser JD, Bigos SJ, Ciol MA (1992) Morbidity and mortality in association with operations on the lumbar spine. The influence of age, diagnosis, and procedure. J Bone Joint Surg Am 74:536 – 543

46. Dick J, Boachie-Adjei O, Wilson M (1992) One-stage versus two-stage anterior and posterior spinal reconstruction in adults. Comparison of outcomes including nutritional status, complication rates, hospital costs, and other factors. Spine 17:S310 – 316
47. Dickson RA (1994) Early-onset idiopathic scoliosis. In: Weinstein SL (ed) The pediatric spine: Principles and practice. Raven Press, New York
48. Diedrich O, von Strempel A, Schloz M, Schmitt O, Kraft CN (2002) Long-term observation and management of resolving infantile idiopathic scoliosis a 25-year follow-up. J Bone Joint Surg Br 84:1030 – 1035
49. Do T, Fras C, Burke S, Widmann RF, Rawlins B, Boachie-Adjei O (2001) Clinical value of routine preoperative magnetic resonance imaging in adolescent idiopathic scoliosis. A prospective study of three hundred and twenty-seven patients. J Bone Joint Surg 83A:577 – 579
50. Dobbs MB, Weinstein SL (1999) Infantile and juvenile scoliosis. Orthop Clin North Am 30:331 – 341, vii
51. Dohin B, Dubousset JF (1994) Prevention of the crankshaft phenomenon with anterior spinal epiphysiodesis in surgical treatment of severe scoliosis of the younger patient. Eur Spine J 3:165 – 168
52. Dolan LA, Donnelly MJ, Spratt KF, Weinstein SL (2007) Professional opinion concerning the effectiveness of bracing relative to observation in adolescent idiopathic scoliosis. J Pediatr Orthop 27:270 – 276
53. Donovan WH, Dwyer AP, Bedbrook GM (1980) Electromyographic activity in paraspinal musculature in patients with idiopathic scoliosis before and after Harrington instrumentation. Arch Phys Med Rehabil 61:413 – 417
54. Dove J (1985) British Scoliosis Society: morbidity study. In: Proceedings of the British Scoliosis Society, San Diego
55. Dubousset J, Herring JA, Shufflebarger H (1989) The crankshaft phenomenon. J Pediatr Orthopedics 9:541 – 550
56. Duriez J (1967) Evolution de la scoliose idiopathique chez l'adulte. Acta Orthop Belg 33:547 – 550
57. Dwyer AF, Newton NC, Sherwood AA (1969) An anterior approach to scoliosis. A preliminary report. Clin Orthop Related Res 62:192 – 202
58. Echenne B, Barneon G, Pages M, Caillens JP, Guibal C, Jarrousse Y, Dimeglio A, Pous JG (1988) Skin elastic fiber pathology and idiopathic scoliosis. J Pediatr Orthop 8:522 – 528
59. Edwards CC, 2nd, Bridwell KH, Patel A, Rinella AS, Jung Kim Y, Berra AB, Della Rocca GJ, Lenke LG (2003) Thoracolumbar deformity arthrodesis to L5 in adults: the fate of the L5–S1 disc. Spine 28:2122 – 2131
60. Engsberg JR, Lenke LG, Uhrich ML, Ross SA, Bridwell KH (2003) Prospective comparison of gait and trunk range of motion in adolescents with idiopathic thoracic scoliosis undergoing anterior or posterior spinal fusion. Spine 28:1993 – 2000
61. Evans SC, Edgar MA, Hall-Craggs MA, Powell MP, Taylor BA, Noordeen HH (1996) MRI of 'idiopathic' juvenile scoliosis. A prospective study. J Bone Joint Surg Br 78:314 – 317
62. Facanha-Filho FA, Winter RB, Lonstein JE, Koop S, Novacheck T, L'Heureux EA, Jr, Noren CA (2001) Measurement accuracy in congenital scoliosis. J Bone Joint Surg 83A:42 – 45
63. Fallstrom K, Cochran T, Nachemson A (1986) Long-term effects on personality development in patients with adolescent idiopathic scoliosis. Influence of type of treatment. Spine 11:756 – 758
64. Ferreira JH, de Janeiro R, James JI (1972) Progressive and resolving infantile idiopathic scoliosis. The differential diagnosis. J Bone Joint Surg Br 54:648 – 655
65. Figueiredo UM, James JI (1981) Juvenile idiopathic scoliosis. J Bone Joint Surg Br 63B:61 – 66
66. Fisk JR, Peterson HA, Laughlin R, Lutz R (1995) Spontaneous fusion in scoliosis after instrumentation without arthrodesis. J Pediatr Orthop 15:182 – 186
67. Forbes HJ, Allen PW, Waller CS, Jones SJ, Edgar MA, Webb PJ, Ransford AO (1991) Spinal cord monitoring in scoliosis surgery. Experience with 1168 cases. J Bone Joint Surg Br 73:487 – 491
68. Freund M, Hahnel S, Thomsen M, Sartor K (2001) Treatment planning in severe scoliosis: the role of MRI. Neuroradiology 43:481 – 484
69. Geissele AE, Ogilvie JW, Cohen M, Bradford DS (1994) Thoracoplasty for the treatment of rib prominence in thoracic scoliosis. Spine 19:1636 – 1642
70. Gelb DE, Lenke LG, Bridwell KH, Blanke K, McEnery KW (1995) An analysis of sagittal spinal alignment in 100 asymptomatic middle and older aged volunteers. Spine 20:1351 – 1358
71. Gilbert TJ, Jr, Winter RB (2005) Pedicle anatomy in a patient with severe early-onset scoliosis: can pedicle screws be safely inserted? J Spinal Disord Tech 18:360 – 363
72. Glazer PA, Hu SS (1996) Pediatric spinal infections. Orthop Clin North Am 27:111 – 123
73. Gorbach C, Schmid MR, Elfering A, Hodler J, Boos N (2006) Therapeutic efficacy of facet joint blocks. AJR Am J Roentgenol 186:1228 – 1233
74. Gotze C, Slomka A, Gotze HG, Potzl W, Liljenqvist U, Steinbeck J (2002) [Long-term results of quality of life in patients with idiopathic scoliosis after Harrington instrumentation and their relevance for expert evidence]. Z Orthop Ihre Grenzgeb 140:492 – 498

75. Grewal H, Betz RR, D'Andrea LP, Clements DH, Porter ST (2005) A prospective comparison of thoracoscopic vs open anterior instrumentation and spinal fusion for idiopathic thoracic scoliosis in children. J Pediatr Surg 40:153 – 156; discussion 156 – 157
76. Guo X, Chau WW, Chan YL, Cheng JC (2003) Relative anterior spinal overgrowth in adolescent idiopathic scoliosis. Results of disproportionate endochondral-membranous bone growth. J Bone Joint Surg Br 85:1026 – 1031
77. Gupta P, Lenke LG, Bridwell KH (1998) Incidence of neural axis abnormalities in infantile and juvenile patients with spinal deformity. Is a magnetic resonance image screening necessary? Spine 23:206 – 210
78. Hadley-Miller N, Mims B, Milewicz DM (1994) The potential role of the elastic fiber system in adolescent idiopathic scoliosis. J Bone Joint Surg Am 76:1193 – 1206
79. Haefeli M, Elfering A, Kilian R, Min K, Boos N (2006) Nonoperative treatment for adolescent idiopathic scoliosis: a 10- to 60-year follow-up with special reference to health-related quality of life. Spine 31:355 – 366; discussion 367
80. Hagg U, Taranger J (1980) Menarche and voice change as indicators of the pubertal growth spurt. Acta Odontol Scand 38:179 – 186
81. Haher TR, Merola A, Zipnick RI, Gorup J, Mannor D, Orchowski J (1995) Meta-analysis of surgical outcome in adolescent idiopathic scoliosis. A 35-year English literature review of 11 000 patients. Spine 20:1575 – 1584
82. Halm H, Liljenqvist U, Castro WH, Jerosch J (1995) [Surgical treatment of idiopathic thoracolumbar scoliosis: Contrell-Dubousset instrumentation versus ventral derotation spondylodesis]. Z Orthop Ihre Grenzgeb 133:282 – 288
83. Hanley EN, Jr (1996) Indications for fusion in the lumbar spine. Bull Hosp Jt Dis 55:154 – 157
84. Harrington PR (1977) The etiology of idiopathic scoliosis. Clin Orthop Related Res:17 – 25
85. Harrington PR (1962) Treatment of scoliosis. Correction and internal fixation by spine instrumentation. J Bone Joint Surg 44A:591 – 610
86. Hausmann ON, Boni T, Pfirrmann CW, Curt A, Min K (2003) Preoperative radiological and electrophysiological evaluation in 100 adolescent idiopathic scoliosis patients. Eur Spine J 12:501 – 506
87. Hee HT, Yu ZR, Wong HK (2007) Comparison of segmental pedicle screw instrumentation versus anterior instrumentation in adolescent idiopathic thoracolumbar and lumbar scoliosis. Spine 32:1533 – 1542
88. Hempfing A, Ferraris L, Koller H, Rump J, Metz-Stavenhagen P (2007) Is anterior release effective to increase flexibility in idiopathic thoracic scoliosis? Assessment by traction films. Eur Spine J 16:515 – 520
89. Hopf CG, Eysel P, Dubousset J (1997) Operative treatment of scoliosis with Cotrel-Dubousset-Hopf instrumentation. New anterior spinal device. Spine 22:618 – 627; discussion 627 – 618
90. Horton WC, Holt RT, Muldowny DS (1996) Controversy. Fusion of L5–S1 in adult scoliosis. Spine 21:2520 – 2522
91. Huebert HT, MacKinnon WB (1969) Syringomyelia and scoliosis. J Bone Joint Surg Br 51:338 – 343
92. Inoue M, Minami S, Nakata Y, Otsuka Y, Takaso M, Kitahara H, Tokunaga M, Isobe K, Moriya H (2005) Preoperative MRI analysis of patients with idiopathic scoliosis: a prospective study. Spine 30:108 – 114
93. Jackson RP, Simmons EH, Stripinis D (1983) Incidence and severity of back pain in adult idiopathic scoliosis. Spine 8:749 – 756
94. James J (1967) Scoliosis. E & S Livingstone, Edinburgh
95. James JI (1954) Idiopathic scoliosis; the prognosis, diagnosis, and operative indications related to curve patterns and the age at onset. J Bone Joint Surg Br 36B:36 – 49
96. James JI, Lloyd-Roberts GC, Pilcher MF (1959) Infantile structural scoliosis. J Bone Joint Surg Br 41B:719 – 735
97. Kane WJ, Moe JH (1970) A scoliosis-prevalence survey in Minnesota. Clin Orthop Related Res 69:216 – 218
98. Kaneda K, Shono Y, Satoh S, Abumi K (1997) Anterior correction of thoracic scoliosis with Kaneda anterior spinal system. A preliminary report. Spine 22:1358 – 1368
99. Kaneda K, Shono Y, Satoh S, Abumi K (1996) New anterior instrumentation for the management of thoracolumbar and lumbar scoliosis. Application of the Kaneda two-rod system. Spine 21:1250 – 1261; discussion 1261 – 1252
100. Kesling KL, Reinker KA (1997) Scoliosis in twins. A meta-analysis of the literature and report of six cases. Spine 22:2009 – 2014; discussion 2015
101. Kim YJ, Lenke LG, Cho SK, Bridwell KH, Sides B, Blanke K (2004) Comparative analysis of pedicle screw versus hook instrumentation in posterior spinal fusion of adolescent idiopathic scoliosis. Spine 29:2040 – 2048
102. Kindsfater K, Lowe T, Lawellin D, Weinstein D, Akmakjian J (1994) Levels of platelet calmodulin for the prediction of progression and severity of adolescent idiopathic scoliosis. J Bone Joint Surg Am 76:1186 – 1192

103. King HA, Moe JH, Bradford DS, Winter RB (1983) The selection of fusion levels in thoracic idiopathic scoliosis. J Bone Joint Surg 65:1302 – 1313
104. Klein JD, Hey LA, Yu CS, Klein BB, Coufal FJ, Young EP, Marshall LF, Garfin SR (1996) Perioperative nutrition and postoperative complications in patients undergoing spinal surgery. Spine 21:2676 – 2682
105. Klemme WR, Denis F, Winter RB, Lonstein JW, Koop SE (1997) Spinal instrumentation without fusion for progressive scoliosis in young children. J Pediatr Orthop 17:734 – 742
106. Koop SE (1988) Infantile and juvenile idiopathic scoliosis. Orthop Clin North Am 19:331 – 337
107. Kostuik JP, Hall BB (1983) Spinal fusions to the sacrum in adults with scoliosis. Spine 8:489 – 500
108. Kuklo TR, Lenke LG, Won DS, Graham EJ, Sweet FA, Betz RR, Bridwell KH, Blanke KM (2001) Spontaneous proximal thoracic curve correction after isolated fusion of the main thoracic curve in adolescent idiopathic scoliosis. Spine 26:1966 – 1975
109. Lee SM, Suk SI, Chung ER (2004) Direct vertebral rotation: a new technique of three-dimensional deformity correction with segmental pedicle screw fixation in adolescent idiopathic scoliosis. Spine 29:343 – 349
110. Lenke LG, Betz RR, Bridwell KH, Clements DH, Harms J, Lowe TG, Shufflebarger HL (1998) Intraobserver and interobserver reliability of the classification of thoracic adolescent idiopathic scoliosis. J Bone Joint Surg 80:1097 – 1106
111. Lenke LG, Betz RR, Bridwell KH, Harms J, Clements DH, Lowe TG (1999) Spontaneous lumbar curve coronal correction after selective anterior or posterior thoracic fusion in adolescent idiopathic scoliosis. Spine 24:1663 – 1671; discussion 1672
112. Lenke LG, Betz RR, Haher TR, Lapp MA, Merola AA, Harms J, Shufflebarger HL (2001) Multisurgeon assessment of surgical decision-making in adolescent idiopathic scoliosis: curve classification, operative approach, and fusion levels. Spine 26:2347 – 2353
113. Lenke LG, Betz RR, Harms J, Bridwell KH, Clements DH, Lowe TG, Blanke K (2001) Adolescent idiopathic scoliosis: a new classification to determine extent of spinal arthrodesis. J Bone Joint Surg 83A:1169 – 1181
114. Lenke LG, Bridwell KH, Baldus C, Blanke K, Schoenecker PL (1993) Ability of Cotrel-Dubousset instrumentation to preserve distal lumbar motion segments in adolescent idiopathic scoliosis. J Spinal Disorders 6:339 – 350
115. Lenke LG, Bridwell KH, Blanke K, Baldus C (1995) Analysis of pulmonary function and chest cage dimension changes after thoracoplasty in idiopathic scoliosis. Spine 20:1343 – 1350
116. Lenke LG, Dobbs MB (2004) Idiopathic scoliosis. In: Frymoyer JW, Wiesel SW (eds) The adult and pediatric spine. Lippincott Williams and Wilkins, Philadelphia, pp 337 – 360
117. Lenssinck ML, Frijlink AC, Berger MY, Bierman-Zeinstra SM, Verkerk K, Verhagen AP (2005) Effect of bracing and other conservative interventions in the treatment of idiopathic scoliosis in adolescents: a systematic review of clinical trials. Phys Ther 85:1329 – 1339
118. Leonardi M, Pfirrmann CW, Boos N (2006) Injection studies in spinal disorders. Clin Orthop Related Res 443:168 – 182
119. Lewonowski K, King JD, Nelson MD (1992) Routine use of magnetic resonance imaging in idiopathic scoliosis patients less than eleven years of age. Spine 17:S109 – 116
120. Lloyd-Roberts GC, Pilcher MF (1965) Structural idiopathic scoliosis in infancy: a study of the natural history of 100 patients. J Bone Joint Surg Br 47:520 – 523
121. Loder RT, Spiegel D, Gutknecht S, Kleist K, Ly T, Mehbod A (2004) The assessment of intraobserver and interobserver error in the measurement of noncongenital scoliosis in children < or = 10 years of age. Spine 29:2548 – 2553
122. Loder RT, Urquhart A, Steen H, Graziano G, Hensinger RN, Schlesinger A, Schork MA, Shyr Y (1995) Variability in Cobb angle measurements in children with congenital scoliosis. J Bone Joint Surg Br 77:768 – 770
123. Lonstein JE (2006) Scoliosis: surgical versus nonsurgical treatment. Clin Orthop Related Res 443:248 – 259
124. Lonstein JE, Bjorklund S, Wanninger MH, Nelson RP (1982) Voluntary school screening for scoliosis in Minnesota. J Bone Joint Surg 64:481 – 488
125. Lonstein JE, Carlson JM (1984) The prediction of curve progression in untreated idiopathic scoliosis during growth. J Bone Joint Surg 66:1061 – 1071
126. Lowe T (1987) Morbidity and mortality report. In: Proceedings of the Scoliosis Research Society, San Diego
127. Lowe TG, Alongi PR, Smith DA, O'Brien MF, Mitchell SL, Pinteric RJ (2003) Anterior single rod instrumentation for thoracolumbar adolescent idiopathic scoliosis with and without the use of structural interbody support. Spine 28:2232 – 2241; discussion 2241 – 2232
128. Lowe TG, Betz R, Lenke L, Clements D, Harms J, Newton P, Haher T, Merola A, Wenger D (2003) Anterior single-rod instrumentation of the thoracic and lumbar spine: saving levels. Spine 28:S208 – 216
129. Lowe TG, Edgar M, Margulies JY, Miller NH, Raso VJ, Reinker KA, Rivard CH (2000) Etiology of idiopathic scoliosis: current trends in research. J Bone Joint Surg 82A:1157 – 1168

130. Luhmann SJ, Lenke LG, Kim YJ, Bridwell KH, Schootman M (2005) Thoracic adolescent idiopathic scoliosis curves between 70 degrees and 100 degrees: is anterior release necessary? Spine 30:2061 – 2067
131. Luk KD, Hu Y, Wong YW, Leong JC (1999) Variability of somatosensory-evoked potentials in different stages of scoliosis surgery. Spine 24:1799 – 1804
132. Luque ER (1982) Segmental spinal instrumentation for correction of scoliosis. Clin Orthop Related Res 163:192 – 198
133. Machida M, Dubousset J, Imamura Y, Miyashita Y, Yamada T, Kimura J (1996) Melatonin. A possible role in pathogenesis of adolescent idiopathic scoliosis. Spine 21:1147 – 1152
134. Mack MJ, Regan JJ, McAfee PC, Picetti G, Ben-Yishay A, Acuff TE (1995) Video-assisted thoracic surgery for the anterior approach to the thoracic spine. Ann Thorac Surg 59: 1100 – 1106
135. MacLean WE, Jr, Green NE, Pierre CB, Ray DC (1989) Stress and coping with scoliosis: psychological effects on adolescents and their families. J Pediatr Orthopedics 9:257 – 261
136. Mannherz RE, Betz RR, Clancy M, Steel HH (1988) Juvenile idiopathic scoliosis followed to skeletal maturity. Spine 13:1087 – 1090
137. Mehta MH (1972) The rib-vertebra angle in the early diagnosis between resolving and progressive infantile scoliosis. J Bone Joint Surg Br 54:230 – 243
138. Mehta MH, Morel G (1979) The non-operative treatment of infantile idiopathic scoliosis. In: Zorab PA, Siegler D (eds) Scoliosis. Academic Press, London, pp 71 – 84
139. Mellencamp DD, Blount WP, Anderson AJ (1977) Milwaukee brace treatment of idiopathic scoliosis: late results. Clin Orthop Related Res 126:47 – 57
140. Mielke CH, Lonstein JE, Denis F, Vandenbrink K, Winter RB (1989) Surgical treatment of adolescent idiopathic scoliosis. A comparative analysis. J Bone Joint Surg Am 71:1170 – 1177
141. Min K, Hahn F, Haefeli M (2007) Anterior short correction of double major adolescent idiopathic scoliosis: A new approach. In: IMAST 2007, Bahamas
142. Min K, Hahn F, Ziebarth K (2007) Short anterior correction of the thoracolumbar/lumbar curve in King 1 idiopathic scoliosis: the behaviour of the instrumented and non-instrumented curves and the trunk balance. Eur Spine J 16:65 – 72
143. Min K, Waelchli B, Hahn F (2005) Primary thoracoplasty and pedicle screw instrumentation in thoracic idiopathic scoliosis. Eur Spine J 14:777 – 782
144. Mineiro J, Weinstein SL (2002) Subcutaneous rodding for progressive spinal curvatures: early results. J Pediatr Orthopedics 22:290 – 295
145. Moe JH, Kharrat K, Winter RB, Cummine JL (1984) Harrington instrumentation without fusion plus external orthotic support for the treatment of difficult curvature problems in young children. Clin Orthop Related Res 185:35 – 45
146. Moe JH, Winter RB, Bradford DS (1978) Kyphosis-lordosis: general principles. Scoliosis and other spinal deformities. WB Saunders Co, Philadelphia, pp 325 – 330
147. Muhlrad A, Yarom R (1982) Contractile protein studies on platelets from patients with idiopathic scoliosis. Haemostasis 11:154 – 160
148. Nachemson A (1968) A long term follow-up study of non-treated scoliosis. Acta Orthop Scand 39:466 – 476
149. Nachemson AL, Peterson LE (1995) Effectiveness of treatment with a brace in girls who have adolescent idiopathic scoliosis. A prospective, controlled study based on data from the Brace Study of the Scoliosis Research Society. J Bone Joint Surg 77:815 – 822
150. Nash CL, Jr, Moe JH (1969) A study of vertebral rotation. J Bone Joint Surg 51:223 – 229
151. Negrini S, Antonini G, Carabalona R, Minozzi S (2003) Physical exercises as a treatment for adolescent idiopathic scoliosis. A systematic review. Pediatr Rehabil 6:227 – 235
152. Newton PO, Marks M, Faro F, Betz R, Clements D, Haher T, Lenke L, Lowe T, Merola A, Wenger D (2003) Use of video-assisted thoracoscopic surgery to reduce perioperative morbidity in scoliosis surgery. Spine 28:S249 – 254
153. Newton PO, Parent S, Marks M, Pawelek J (2005) Prospective evaluation of 50 consecutive scoliosis patients surgically treated with thoracoscopic anterior instrumentation. Spine 30:S100 – 109
154. Niemeyer T, Bovingloh AS, Grieb S, Schaefer J, Halm H, Kluba T (2005) Low back pain after spinal fusion and Harrington instrumentation for idiopathic scoliosis. Int Orthop 29:47 – 50
155. Niemeyer T, Wolf A, Kluba S, Halm HF, Dietz K, Kluba T (2006) Interobserver and intraobserver agreement of Lenke and King classifications for idiopathic scoliosis and the influence of level of professional training. Spine 31:2103 – 2107; discussion 2108
156. Nilsonne U, Lundgren KD (1968) Long-term prognosis in idiopathic scoliosis. Acta Orthop Scand 39:456 – 465
157. Noonan KJ, Dolan LA, Jacobson WC, Weinstein SL (1997) Long-term psychosocial characteristics of patients treated for idiopathic scoliosis. J Pediatr Orthop 17:712 – 717
158. Noonan KJ, Weinstein SL, Jacobson WC, Dolan LA (1996) Use of the Milwaukee brace for progressive idiopathic scoliosis. J Bone Joint Surg 78:557 – 567

159. Noordeen MH, Taylor BA, Edgar MA (1994) Syringomyelia. A potential risk factor in scoliosis surgery. Spine 19:1406 – 1409
160. Nordwall A, Wikkelso C (1979) A late neurologic complication of scoliosis surgery in connection with syringomyelia. Acta Orthop Scand 50:407 – 410
161. Nuwer MR (1999) Spinal cord monitoring. Muscle Nerve 22:1620 – 1630
162. O'Brien J (1980) The incidence of scoliosis in Oswestry. In: Zorab P, Siegler D (eds) Scoliosis. Academic Press, London, pp 39 – 44
163. O'Brien MF, Lenke LG, Bridwell KH, Blanke K, Baldus C (1994) Preoperative spinal canal investigation in adolescent idiopathic scoliosis curves > or = 70 degrees. Spine 19:1606 – 1610
164. Oegema TR, Jr, Bradford DS, Cooper KM, Hunter RE (1983) Comparison of the biochemistry of proteoglycans isolated from normal, idiopathic scoliotic and cerebral palsy spines. Spine 8:378 – 384
165. Olafsson Y, Saraste H, Ahlgren RM (1999) Does bracing affect self-image? A prospective study on 54 patients with adolescent idiopathic scoliosis. Eur Spine J 8:402 – 405
166. Owen JH (1999) The application of intraoperative monitoring during surgery for spinal deformity. Spine 24:2649 – 2662
167. Ozerdemoglu RA, Transfeldt EE, Denis F (2003) Value of treating primary causes of syrinx in scoliosis associated with syringomyelia. Spine 28:806 – 814
168. Padberg AM, Wilson-Holden TJ, Lenke LG, Bridwell KH (1998) Somatosensory- and motor-evoked potential monitoring without a wake-up test during idiopathic scoliosis surgery. An accepted standard of care. Spine 23:1392 – 1400
169. Padua R, Padua L, Ceccarelli E, Romanini E, Bondi R, Zanoli G, Campi A (2001) Cross-cultural adaptation of the lumbar North American Spine Society questionnaire for Italian-speaking patients with lumbar spinal disease. Spine 26:E344 – 347
170. Padua R, Padua S, Aulisa L, Ceccarelli E, Padua L, Romanini E, Zanoli G, Campi A (2001) Patient outcomes after Harrington instrumentation for idiopathic scoliosis: a 15- to 28-year evaluation. Spine 26:1268 – 1273
171. Pedrini VA, Ponseti IV, Dohrman SC (1973) Glycosaminoglycans of intervertebral disc in idiopathic scoliosis. J Lab Clin Med 82:938 – 950
172. Pehrsson K, Larsson S, Oden A, Nachemson A (1992) Long-term follow-up of patients with untreated scoliosis. A study of mortality, causes of death, and symptoms. Spine 17:1091 – 1096
173. Pelosi L, Jardine A, Webb JK (1999) Neurological complications of anterior spinal surgery for kyphosis with normal somatosensory evoked potentials (SEPs). J Neurol Neurosurg Psychiatry 66:662 – 664
174. Pelosi L, Lamb J, Grevitt M, Mehdian SM, Webb JK, Blumhardt LD (2002) Combined monitoring of motor and somatosensory evoked potentials in orthopaedic spinal surgery. Clin Neurophysiol 113:1082 – 1091
175. Perdriolle R (1979) La scoliose: son étude tridimensionelle. Maloche, Paris
176. Perdriolle R, Vidal J (1981) [A study of scoliotic curve. The importance of extension and vertebral rotation (author's transl)]. Revue de chirurgie orthopedique et reparatrice de l'appareil moteur 67:25 – 34
177. Picetti GD, 3rd, Ertl JP, Bueff HU (2001) Endoscopic instrumentation, correction, and fusion of idiopathic scoliosis. Spine J 1:190 – 197
178. Picetti GD, 3rd, Pang D, Bueff HU (2002) Thoracoscopic techniques for the treatment of scoliosis: early results in procedure development. Neurosurgery 51:978 – 984; discussion 984
179. Ponseti IV, Friedman B (1950) Prognosis in idiopathic scoliosis. J Bone Joint Surg 32A: 381 – 395
180. Propst-Proctor SL, Bleck EE (1983) Radiographic determination of lordosis and kyphosis in normal and scoliotic children. J Pediatr Orthop 3:344 – 346
181. Regan JJ, Mack MJ, Picetti GD, 3rd (1995) A technical report on video-assisted thoracoscopy in thoracic spinal surgery. Preliminary description. Spine 20:831 – 837
182. Richards BS, Sucato DJ, Konigsberg DE, Ouellet JA (2003) Comparison of reliability between the Lenke and King classification systems for adolescent idiopathic scoliosis using radiographs that were not premeasured. Spine 28:1148 – 1156; discussion 1156 – 1147
183. Rinsky LA, Gamble JG, Bleck EE (1985) Segmental instrumentation without fusion in children with progressive scoliosis. J Pediatr Orthop 5:687 – 690
184. Riseborough EJ, Wynne-Davies R (1973) A genetic survey of idiopathic scoliosis in Boston, Massachusetts. J Bone Joint Surg Am 55:974 – 982
185. Risser JC (1958) The iliac apophysis; an invaluable sign in the management of scoliosis. Clin Orthop 11:111 – 119
186. Roberts S, Menage J, Eisenstein SM (1993) The cartilage end-plate and intervertebral disc in scoliosis: calcification and other sequelae. J Orthop Res 11:747 – 757
187. Robinson CM, McMaster MJ (1996) Juvenile idiopathic scoliosis. Curve patterns and prognosis in one hundred and nine patients. J Bone Joint Surg Am 78:1140 – 1148

188. Rogala EJ, Drummond DS, Gurr J (1978) Scoliosis: incidence and natural history. A prospective epidemiological study. J Bone Joint Surg 60:173 – 176
189. Sahgal V, Shah A, Flanagan N, Schaffer M, Kane W, Subramani V, Singh H (1983) Morphologic and morphometric studies of muscle in idiopathic scoliosis. Acta Orthop Scand 54: 242 – 251
190. Sanders JO, Little DG, Richards BS (1997) Prediction of the crankshaft phenomenon by peak height velocity. Spine 22:1352 – 1356; discussion 1356 – 1357
191. Schellhas KP, Pollei SR (1994) The role of discography in the evaluation of patients with spinal deformity. Orthop Clin North Am 25:265 – 273
192. Schwend RM, Hennrikus W, Hall JE, Emans JB (1995) Childhood scoliosis: clinical indications for magnetic resonance imaging. J Bone Joint Surg 77:46 – 53
193. Scott JC, Morgan TH (1955) The natural history and prognosis of infantile idiopathic scoliosis. J Bone Joint Surg Br 37B:400 – 413
194. Shapiro GS, Taira G, Boachie-Adjei O (2003) Results of surgical treatment of adult idiopathic scoliosis with low back pain and spinal stenosis: a study of long-term clinical radiographic outcomes. Spine 28:358 – 363
195. Shen WJ, McDowell GS, Burke SW, Levine DB, Chutorian AM (1996) Routine preoperative MRI and SEP studies in adolescent idiopathic scoliosis. J Pediatr Orthopedics 16:350 – 353
196. Shufflebarger HL, Clark CE (1991) Prevention of the crankshaft phenomenon. Spine 16:S409 – 411
197. Shufflebarger HL, Smiley K, Roth HJ (1994) Internal thoracoplasty. A new procedure. Spine 19:840 – 842
198. Simmons EH, Jackson RP (1979) The management of nerve root entrapment syndromes associated with the collapsing scoliosis of idiopathic lumbar and thoracolumbar curves. Spine 4:533 – 541
199. Slager UT, Hsu JD (1986) Morphometry and pathology of the paraspinous muscles in idiopathic scoliosis. Dev Med Child Neurol 28:749 – 756
200. Smith JA, Deviren V, Berven S, Bradford DS (2002) Does instrumented anterior scoliosis surgery lead to kyphosis, pseudarthrosis, or inadequate correction in adults? Spine 27:529 – 534
201. Spencer GS, Eccles MJ (1976) Spinal muscle in scoliosis. Part 2. The proportion and size of type 1 and type 2 skeletal muscle fibres measured using a computer-controlled microscope. J Neurol Sci 30:143 – 154
202. Stagnara P, De Mauroy JC, Dran G, Gonon GP, Costanzo G, Dimnet J, Pasquet A (1982) Reciprocal angulation of vertebral bodies in a sagittal plane: approach to references for the evaluation of kyphosis and lordosis. Spine 7:335 – 342
203. Steel HH (1983) Rib resection and spine fusion in correction of convex deformity in scoliosis. J Bone Joint Surg Am 65:920 – 925
204. Stirling AJ, Howel D, Millner PA, Sadiq S, Sharples D, Dickson RA (1996) Late-onset idiopathic scoliosis in children six to fourteen years old. A cross-sectional prevalence study. J Bone Joint Surg Am 78:1330 – 1336
205. Strahm C, Min K, Boos N, Ruetsch Y, Curt A (2003) Reliability of perioperative SSEP recordings in spine surgery. Spinal Cord 41:483 – 489
206. Sucato DJ (2003) Thoracoscopic anterior instrumentation and fusion for idiopathic scoliosis. J Am Acad Orthop Surg 11:221 – 227
207. Suk SI, Kim JH, Cho KJ, Kim SS, Lee JJ, Han YT (2007) Is anterior release necessary in severe scoliosis treated by posterior segmental pedicle screw fixation? Eur Spine J 16:1359 – 1365
208. Swank SM, Winter RB, Moe JH (1982) Scoliosis and cor pulmonale. Spine 7:343 – 354
209. Sweet FA, Lenke LG, Bridwell KH, Blanke KM (1999) Maintaining lumbar lordosis with anterior single solid-rod instrumentation in thoracolumbar and lumbar adolescent idiopathic scoliosis. Spine 24:1655 – 1662
210. Takahashi S, Delecrin J, Passuti N (2002) Surgical treatment of idiopathic scoliosis in adults: an age-related analysis of outcome. Spine 27:1742 – 1748
211. Tanner JM, Whitehouse RH (1976) Clinical longitudinal standards for height, weight, height velocity, weight velocity, and stages of puberty. Arch Dis Child 51:170 – 179
212. Theiss SM, Lonstein JE, Winter RB (1996) Wound infections in reconstructive spine surgery. Orthop Clin North Am 27:105 – 110
213. Thompson GH, Akbarnia BA, Campbell RM, Jr (2007) Growing rod techniques in early-onset scoliosis. J Pediatr Orthop 27:354 – 361
214. Thompson GH, Akbarnia BA, Kostial P, Poe-Kochert C, Armstrong DG, Roh J, Lowe R, Asher MA, Marks DS (2005) Comparison of single and dual growing rod techniques followed through definitive surgery: a preliminary study. Spine 30:2039 – 2044
215. Thompson SK, Bentley G (1980) Prognosis in infantile idiopathic scoliosis. J Bone Joint Surg Br 62B:151 – 154
216. Tolo VT, Gillespie R (1978) The characteristics of juvenile idiopathic scoliosis and results of its treatment. J Bone Joint Surg Br 60B:181 – 188

217. Transfeldt EE, Lonstein JE, Winter RB (1985) Wound infections in reconstructive spinal surgery. Orthop Trans 9:128
218. Turi M, Johnston CE, 2nd, Richards BS (1993) Anterior correction of idiopathic scoliosis using TSRH instrumentation. Spine 18:417 – 422
219. Ugwonali OF, Lomas G, Choe JC, Hyman JE, Lee FY, Vitale MG, Roye DP, Jr (2004) Effect of bracing on the quality of life of adolescents with idiopathic scoliosis. Spine J 4:254 – 260
220. Weinstein SL, Dolan LA, Spratt KF, Peterson KK, Spoonamore MJ, Ponseti IV (2003) Health and function of patients with untreated idiopathic scoliosis: a 50-year natural history study. JAMA 289:559 – 567
221. Weinstein SL, Ponseti IV (1983) Curve progression in idiopathic scoliosis. J Bone Joint Surg 65:447 – 455
222. Weinstein SL, Zavala DC, Ponseti IV (1981) Idiopathic scoliosis: long-term follow-up and prognosis in untreated patients. J Bone Joint Surg 63:702 – 712
223. Weis JC, Betz RR, Clements DH, 3rd, Balsara RK (1997) Prevalence of perioperative complications after anterior spinal fusion for patients with idiopathic scoliosis. J Spinal Disord 10:371 – 375
224. Weiss HR, Negrini S, Hawes MC, Rigo M, Kotwicki T, Grivas TB, Maruyama T (2006) Physical exercises in the treatment of idiopathic scoliosis at risk of brace treatment – SOSORT consensus paper 2005. Scoliosis 1:6
225. Weiss HR, Negrini S, Rigo M, Kotwicki T, Hawes MC, Grivas TB, Maruyama T, Landauer F (2006) Indications for conservative management of scoliosis (guidelines). Scoliosis 1:5
226. Wiggins GC, Ondra SL, Shaffrey CI (2003) Management of iatrogenic flat-back syndrome. Neurosurg Focus 15:E8
227. Willers U, Normelli H, Aaro S, Svensson O, Hedlund R (1993) Long-term results of Boston brace treatment on vertebral rotation in idiopathic scoliosis. Spine 18:432 – 435
228. Willner S, Uden A (1982) A prospective prevalence study of scoliosis in Southern Sweden. Acta Orthop Scand 53:233 – 237
229. Wimmer C, Nogler M, Frischhut B (1998) Influence of antibiotics on infection in spinal surgery: a prospective study of 110 patients. J Spinal Disord 11:498 – 500
230. Winter RB, Lonstein JE, Denis F (1988) Pain patterns in adult scoliosis. Orthop Clin North Am 19:339 – 345
231. Winter RB, Lonstein JE, Heithoff KB, Kirkham JA (1997) Magnetic resonance imaging evaluation of the adolescent patient with idiopathic scoliosis before spinal instrumentation and fusion. A prospective, double-blinded study of 140 patients. Spine 22:855 – 858
232. Wong HK, Hee HT, Yu Z, Wong D (2004) Results of thoracoscopic instrumented fusion versus conventional posterior instrumented fusion in adolescent idiopathic scoliosis undergoing selective thoracic fusion. Spine 29:2031 – 2038; discussion 2039
233. Wynne-Davies R (1968) Familial (idiopathic) scoliosis. A family survey. J Bone Joint Surg Br 50:24 – 30
234. Yarom R, Meyer S, More R, Robin GC (1982) Metal impregnation abnormalities in platelets of patients with idiopathic scoliosis. Haemostasis 12:282 – 288
235. Yarom R, Robin GC (1979) Studies on spinal and peripheral muscles from patients with scoliosis. Spine 4:12 – 21
236. Yeon HB, Weinberg J, Arlet V, Ouelett JA, Wood KB (2007) Anterior lumbar instrumentation improves correction of severe lumbar Lenke C curves in double major idiopathic scoliosis. Eur Spine J 16:1379 – 1385
237. Zadeh HG, Sakka SA, Powell MP, Mehta MH (1995) Absent superficial abdominal reflexes in children with scoliosis. An early indicator of syringomyelia. J Bone Joint Surg Br 77:762 – 767
238. Zielke K, Berthet A (1978) [VDS – ventral derotation spondylodesis – preliminary report on 58 cases]. Beitr Orthop Traumatol 25:85 – 103.

# 24 Neuromuscular Scoliosis

Jean A. Ouellet, Vincent Arlet

## Core Messages

- ✔ Kyphoscoliosis is a synonym for neuromuscular scoliosis, in contrast to lordoscoliosis, which is a synonym for idiopathic scoliosis
- ✔ Hyperlordosis is also seen in neuromuscular scoliosis
- ✔ Pelvic obliquity is pathognomonic for neuromuscular scoliosis
- ✔ Spinal deformities in neuromuscular patients tend to be severe and progressive in both coronal and sagittal planes
- ✔ Surgical management of patients with neuromuscular scoliosis is associated with greater morbidity as they can have severe comorbid medical problems
- ✔ Duchenne muscular dystrophy and Friedreich's ataxia should always have a preoperative cardiac assessment
- ✔ Preoperative pulmonary function of less than 35 % of the predicted value indicates postoperative ventilatory support and dependency, which may put the surgical indications in question
- ✔ Maximizing hemostasis with adjuvant controlled hypotension, cell savers, hemostatic agents and excellent vascular access is imperative since intraoperative bleeding can be significant (up to two times blood volume)
- ✔ Spinal fixation may be complicated and prone to failure since bone is weakened by disuse, osteopenia and antiepileptic drugs
- ✔ Achieving spinal balance in both the coronal and sagittal planes is even more critical as patients with neuromuscular scoliosis typically do not have the innate ability to compensate and balance themselves postoperatively
- ✔ Fusion often extends to the pelvis; thus a good understanding of different pelvic-lumbosacral fixations is mandatory
- ✔ Never extend a fusion down to the pelvis in a patient relying on a mobile lumbosacral junction for his or her ambulation, even in the presence of pelvic obliquity
- ✔ If the curve < 40° and the pelvic obliquity < 10°, one can stop the fusion at L5; if these are greater then the fusion should be extended to the pelvis

## Epidemiology

Neuromuscular scoliosis embodies a heterogeneous group of patients

Scoliosis in the presence of a **neuromuscular disorder** (NMD) behaves entirely differently from the more predictable idiopathic scoliosis. Depending on the underlying NMD, the prevalence of scoliosis is also different. Having a better understanding of these disorders facilitates the management of their associated spinal deformities (Table 1).

Treatment must be individualized for each underlying diagnosis

One must appreciate that the heading of neuromuscular scoliosis encompasses a large variety of different NMD pathologies. These disorders can present either early or later in life. They can be acquired by means of postinfectious or post-traumatic events, or they can be genetic disorders affecting genes that code for the proteins in nerve cells or in muscle cells, leading to malfunction of the neurological or muscular systems. They can also be secondary to brain or spinal cord insults or disease. The majority of these disorders present in different sever-

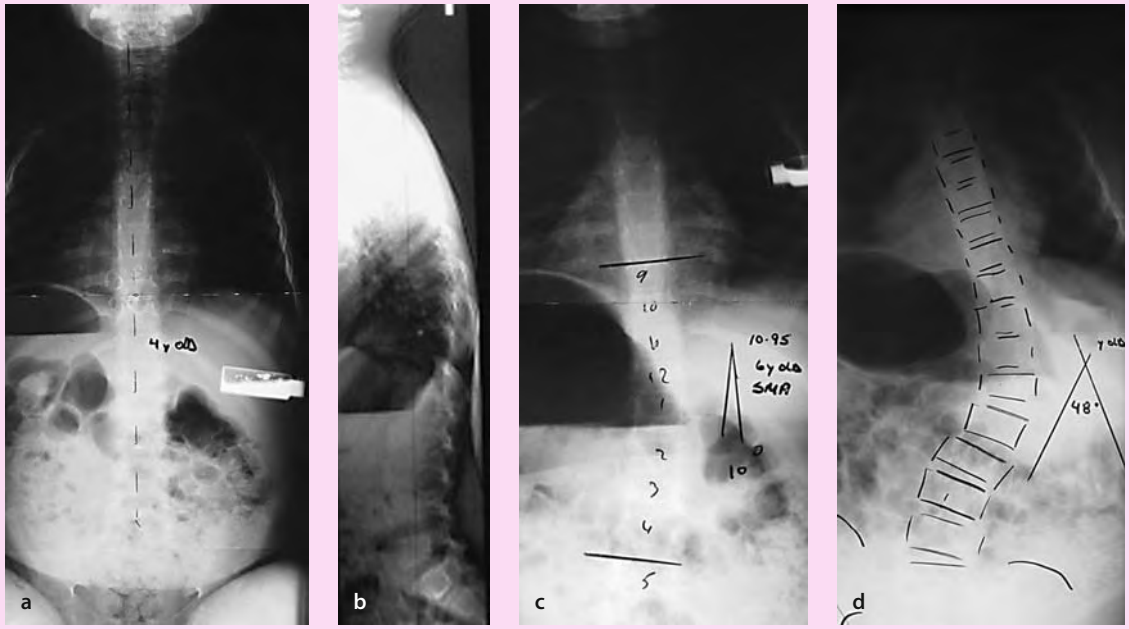


## Case Introduction

A 4-year-old boy with Duchenne muscular dystrophy had been followed at the neuromuscular clinic at regular intervals to monitor respiratory status and general development. On initial screening, spine X-ray did not demonstrate any spinal deformity (a, b). At the age of 6, spinal asymmetry was noted and a 10° scoliosis documented. By the age of 10, the curve had progressed to 48° (c). Respiratory functions were 35% of expected and deemed amenable to spinal surgery with moderate perioperative risk. The patient had a classic segmental posterior spinal fusion using sublaminar wiring from T2 to L5 (d). A decision was made to fuse to L5 and not fuse to the pelvis considering that his pelvic obliquity was minimal < 10° and flexible (e, f). By doing so the risk of pseudoarthrosis across the lumbosacral junction was minimized. Being a male and non-ambulator the fusion could have been extended to the pelvis to prevent the possibility of progressive pelvic obliquity. In girls that perform self-catherization, fusing to the pelvis often leads to loss of independence of self-care. The second contentious decision was that no anterior spinal fusion was done due to the fear that he would not tolerate the extended surgery. Fusing the spine at such a young age poses a risk of the patient developing a crankshaft deformity; however, considering that he had passed his peak growth velocity, this risk was minimal. Furthermore any decisions must take into account his truncated life expectancy. Of note is that the rods were inappropriately contoured lacking lumbar lordosis to achieve an adequate sagittal balance.

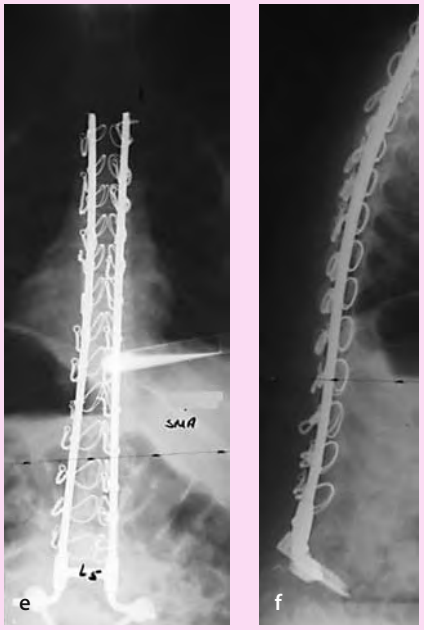


**Table 1.** Characteristics of neuromuscular disorders associated with scoliosis [15, 34, 47]

| Disease (incidence) | Onset (years) | Inheritance | Life expectancy (years) | Presentation | Progression of weakness | Loss of ambulation (years) |
|---|---|---|---|---|---|---|
| **Muscular dystrophies** | | | | | | |
| Duchenne (1:4000 male births) | 1.5–4 | XR | 20±4 | Proximal muscle weakness, lower weaker than upper limbs, extensor weaker than flexor, muscles of heart and respiratory system | Rapid decline from 5 to 13 years, slower after 14 | 10±2.5 |
| Becker (4:100000 male births) | 8.5±8.5 | XR | 23–89 | Distribution similar to Duchenne | Slow decline | 25–58 |

**Table 1.** (*Cont.*)

| Disease (incidence) | Onset (years) | Inheritance | Life expectancy (years) | Presentation | Progression of weakness | Loss of ambulation (years) |
|---|---|---|---|---|---|---|
| **Muscular dystrophies** | | | | | | |
| Limb girdle (incidence cannot be estimated) | 9±4 | AR (expAD) | variable | distribution similar to Duchenne and Becker except no difference of extensor and flexor | rapid loss | 75% by age 20 |
| Myotonic (AKA Steinert's) (1:20000 births) | 23±13 | AD | variable (dependent on arrhythmias) | facial weakness notice first, ptosis, generalized weakness of voluntary muscles of limbs, distal muscle weakness, and the neck, facial, and diaphragm muscles, and intercostals. Develops heart blocks, unable to release grasp | slow loss | late in life if ever |
| Congenital myotonic | at birth | AR | variable (% neonatal death) | severe weakness, floppy baby, require ventilation and nutrition supplement as infant, moderate mental retardation | | may never reach ambulation |
| **Arthrogryposis** (1:3000 births) | at birth | non-genetic fetal akinesia, 30% AR | normal (50% neonatal death when CNS) | focal weakness in presence of severe joint contractures: classic hands, wrists, elbows, shoulders, hips, feet and knees. Severe cases, all joints including jaw and spine | static; may progress with disuse, atrophy may be present, and muscles or muscle groups may be absent | variable |
| **spinal muscular atrophy** (1:6000 births) | | | | | | |
| Type I (acute infantile, acute Werdnig-Hoffmann disease) | 0–0.5 | AR | 1.5 (50% die before 2 years) | severe generalized muscle weakness leading to feeding and breathing failures, unable to sit | | never ambulate |
| Type II (chronic Werdnig-Hoffmann diseases) | 2 | | 30–40 | proximal muscle weakness, lower weaker than upper limbs, extensor weaker than flexor, sits but difficulty walking if able | progression variable | early loss |
| Type III (Kugelberg-Welander diseases) | 23±19 | | normal | proximal muscle weakness, no difference between lower and upper or flexor and extensor | slow loss | very late if any |
| **Poliomyelitis** (prevalence in 2003: 623 cases worldwide) | variable | acquired (Nigeria, India, Pakistan, Afghanistan, Egypt) | normal (may require respiratory support) | prodrome: fever 5–7 days before headache, stiff neck, paraspinal muscle weakness, asymmetrical peripheral weakness (only on one side or worse on one side), distribution depends on level of cord involvement, abnormal sensations with hypersensitivity | rapid onset progresses to paralysis, permanent or transient with possible mild delayed regression | variable dependent on severity, subclinical, non-paralytic, paralytic |
| **Hereditary motor sensory neuropathy** | | | | | | |
| Charcot-Marie-Tooth (1:2500 births) | 13±14 | AD | relatively normal | distal muscle weakness, no difference upper vs lower, nor flexor vs extensors | slow loss | later if any |
| **Cerebral palsy** (2:1000 births) | at birth | acquired brain insult in utero/perinatally, post-infectious | variable (dependent on mobility; non-sitter: 30; sitter: 46; ambulator: 62) | spastic (50%): stiff, difficult movement<br>dyskinetic/athetoid (20%): involuntary uncontrolled movement<br>ataxic (rare): poor coordination and balance<br>mixed (30%): combination of these types | hypotonia may develop into spasticity | variable |
| **Spinocerebellar dysfunction** | | | | | | |
| Friedreich's ataxia (1:22000 births) | 10±5 | AR | early adulthood 38±14 (cardiac) | initially difficulty walking, ataxia, then spreading to arms then trunk, muscle weakness, muscle wasting: feet, leg, hands, loss of sensation over time, nystagmus, cardiomyopathy, myocardial fibrosis | slow progressive | 15–20 years after diagnosis |

ities: from mild, to moderate, to severe forms. They may result in minimal clinical manifestation or they can result in lethal disease in early infancy. An overview of these disorders with their clinical presentations, their incidence and their functional impact is given in Table 1.

## Disease Specific Spinal Deformity

Spinal deformity is frequent and severe in rapidly progressive NMD

As part of a review of 547 individuals with different NMDs, the Rehabilitation Research and Training Center (RRTC/NMD) found that the overall incidence of **spinal deformity** was elevated (60–80%) in patients with rapidly progressive NMD who presented before skeletal maturity [41], while in slowly progressive NMD the incidence of scoliosis was relatively low (only 32%). In the patients with rapidly progressive NMD, the incidence and severity of the scoliosis increased with disease duration and years of wheelchair dependency, with a high incidence of **pulmonary complications** and decreased pulmonary function. In contrast, in patients with slowly progressive NMD, the presence of spinal deformity showed no relationship between disease duration and length of wheelchair dependency. The scoliosis of these patients was often mild to moderate and usually non-progressive. There was, however, a significant association between the number of pulmonary complications and disease duration in those patients with spinal deformity who also had significantly lower vital capacities. One must keep in mind that these are general guidelines and do not imply a cause to effect relationship between specific disease and the development of scoliosis.

Duchenne patients are likely to develop scoliosis

For example, in **Duchenne muscular dystrophy** (DMD), there is a progressive increase in incidence of scoliosis up to the age of 20 years (Case Introduction). The incidence increases significantly once patients are wheelchair dependent, especially after 3 years, when the incidence is close to 60%. Thirty-five percent of patients have spinal deformity before the age of 8 years, and 90% do so by the age of 20 years [15]. The incidence increases greatly between the ages of 13 and 15 years, which correspond closely with the adolescent growth spurt in boys.

In contrast, in patients with **Becker's muscular dystrophy**, only 13% had scoliosis with mild non-progressive curves. Patients with hereditary motor sensory neuropathy (HMSN, Charcot-Marie-Tooth disease) had a 25% incidence of spinal deformity, of whom 15% had scoliosis and 10% had kyphoscoliosis. In patients with Friedreich's ataxia, the incidence of scoliosis was almost 100%, compared to only 32% in those with other types of hereditary spinal cerebellar ataxia (HSCA). Patients with infantile onset **spinal muscular atrophy** (SMA) had a 78% incidence of scoliosis while juveniles and adults with SMA onset had only 8% incidence. Spinal deformity in the congenital myopathies occurred primarily in the individuals with congenital muscular dystrophy (36%). Thirty-five percent of patients with facioscapulohumeral dystrophy had spinal deformity, of whom 15% had scoliosis alone. The incidence of spinal deformity in limb girdle syndrome also depended on the type. Individuals with the childhood onset type had a 44% incidence while those with the late onset and pelvofemoral types had only a 6% incidence. There was a marked difference in the incidence of spinal deformity between congenital myotonic muscular dystrophy (MMD) and non-congenital MMD. Forty-seven percent of the former had scoliosis as compared to 15% of the latter.

Ninety percent of myelodysplasia patients with a T10 level will develop a spinal deformity

With respect to patients with myelodysplasia, the prevalence will vary depending on their functional level: 90% of patients with a complete T10 level will develop a coronal or sagittal spinal deformity, while only 5% of patients with an L5 level will develop a spinal deformity [20].

The overall incidence of spinal deformity varies depending on the underlying NMD, but it also varies according to the severity of the underlying NMD

**Table 2.** Prevalence of spinal deformities in neuromuscular diseases

| Diagnosis | Percentage[a] |
|---|---|
| Cerebral palsy | 25 |
| Poliomyelitis | 17–80 |
| Myelodysplasia | 60 |
| Spinal muscular atrophy | 67 |
| Friedreich's ataxia | 80 |
| Duchenne muscular dystrophy | 90 |
| Spinal cord injury (traumatic before 10 years of age) | 100 |

[a] Based on data by J.E. Lonstein, Department of Orthopedics, University of Minnesota, Twin Cities Spine Center, Minneapolis

(Table 2). In general, the greater the neuromuscular involvement, the greater the likelihood of having a spinal deformity and the greater the deformity will be.

## Pathogenesis

The pathophysiology of neurogenic spinal deformities remains unclear. It seems logical to assume that the "collapsing kyphoscoliosis" is secondary to muscle weakness and yet the same deformity is seen in patients with spasticity. The **classical spinal deformities** encountered in NMD consist of:

- scoliosis
- kyphosis
- kyphoscoliosis
- lumbar hyperlordosis
- pelvic obliquity

Pelvic obliquity is an associated spinal deformity

**Pelvic obliquity** should be considered as an associated "spinal" neurogenic deformity. All of these deformities can be present with any of the different NMDs, making it difficult to draw any conclusion about the pathogenesis of neuromuscular scoliosis. Furthermore there is no association between etiology, pattern of weakness, and curve pattern. There are factors that influence the development of certain deformities. For example, the development of scoliosis is **influenced by** the following factors:

- age of onset of NMD
- ambulation status
- severity and rapidity of the progression of the weakness

This is particularly true for patients with Duchenne muscular dystrophy. Close to 90% of them will develop scoliosis as their weakness progresses quickly, and it occurs prior to cessation of growth coupled with loss of ambulation at an early age. However, these factors do not always lead to a deformity, such as in patients with amyotrophic lateral sclerosis, which is a very rapid progressive NMD and yet only 1% develop scoliosis.

## Classification

The classic patient we think of having neuromuscular scoliosis has either **cerebral palsy** (upper motor neuron lesions) or **Duchenne muscular dystrophy** (peripheral muscular disease) [4]. These two etiologies are representative of the two main types of neuromuscular scoliosis. The Scoliosis Research Society has classified neuromuscular scoliosis into neuropathic types and myopathic types (Table 3).

**Table 3.** Classification of neuromuscular scoliosis

| Neuropathic conditions | Myopathic conditions |
|---|---|
| **Upper motor neuron**<br>• cerebral palsy<br>• syringomyelia<br>• spinal cord injury | **Muscular dystrophy**<br>• Duchenne and Becker<br>• limb girdle<br>• facioscapulohumeral<br>• myotonic dystrophy |
| **Lower motor neuron**<br>• poliomyelitis<br>• spinal muscular atrophy | **Arthrogryposis** |
| **Mixed upper and lower motor neuron**<br>• myelodysplasia (spina bifida)<br>• spinal trauma | **Congenital myopathies**<br>• nemaline<br>• central core disease |
| **Spinocerebellar dysfunction**<br>• Friedreich's ataxia | |
| **Hereditary motor sensory neuropathy**<br>• Charcot-Marie-Tooth | |

Lonstein et al. [22] classified the curve patterns of neuromuscular scoliosis in patients with cerebral palsy and mental retardations into two large groups each subdivided into two subgroups (Fig. 1). The difference between the groups is the presence (G-II) or absence (G-I) of pelvic obliquity, which has a clinical bearing as to whether to include the pelvis in the spinal fusion.

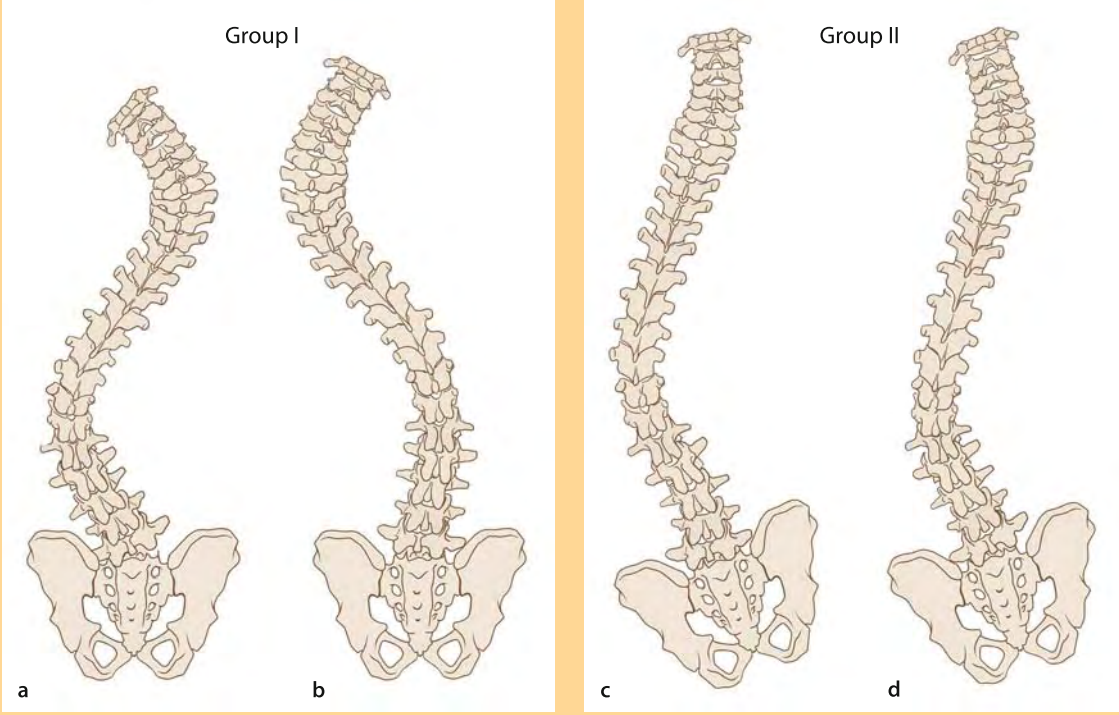


**Figure 1. Neuromuscular curve classification**

**Group I:** double thoracic and lumbar curves, little pelvic obliquity, patient in balance. a Thoracic lumbar curve in balance; b thoracic greater than lumbar curve, unbalanced. **Group II:** large lumbar or thoracolumbar curves, severe pelvic obliquity, patient out of balance. c Short fractional curve above sacrum; d extension of lumbar curve in sacrum (According to Lonstein et al. [22]).

## Clinical Presentation

### History

As in any ailment, obtaining a detailed history is fundamental in the establishment of the correct diagnosis of scoliosis. A thorough history should include:

- perinatal history
- development history
- family history

A **family history** is required to assess the risk of a known etiology for the patient's spinal deformity. **Clues** suggestive for neuromuscular scoliosis are:

- birth anoxia
- delayed developmental milestone
- acquired or familial neuropathies and/or myopathies
- early onset (less than 7 years old)
- painful scoliosis

The patient should be asked about maternal diabetes, specific bowel and bladder functions, and muscle endurance since these insignificant details can lead to a diagnosis of sacral agenesis or then again to that of a tethered cord. Subjective complaints of patchy numbness and weakness must be elicited as well as symptoms consistent with radiculopathy, myelopathy, or recurrent headaches, which may all be symptoms of a syringomyelia (Table 4).

Detailed perinatal history and family history is warranted if neuromuscular scoliosis is suspected

**Table 4.** Red flags for neuromuscular scoliosis

| | |
|---|---|
| **History:** | |
| | • early onset scoliosis: early, less than 7 years of age<br>• painful scoliosis<br>• headache<br>• sensory or motor disturbances<br>• bowel and bladder dysfunction<br>• developmental delay, mental retardation |
| **Physical examination:** | |
| Head & neck: | • flaccid facies<br>• poor head control |
| Skin: | • neuroectodermal lesions: café au lait spots<br>• spinal dysraphism: hairy patch, sacral dimples, midline birthmark |
| Spine: | • long collapsing scoliosis<br>• pelvic obliquity<br>• kyphoscoliosis<br>• lack of rotation |
| Neurology: | • spasticity<br>• muscle weakness, proximal girdle + Gower<br>• peroneal muscular weakness<br>• long track signs: clonus, Babinsky's, hyperreflexia<br>• hypotonia, hyporeflexia<br>• patchy paresthesia |
| Musculoskeletal: | • limb atrophy, different feet size<br>• cavus feet<br>• upper extremity posturing during running<br>• loss of sitting balance<br>• Charcot joints<br>• non-ambulators |

## Physical Examination

### Skin

The dermis must be inspected for skin lesions such as **café au lait spots** or **axillary freckles** as these are associated with neurofibromatosis, which can have intradural neuromas. Other neurocutaneous skin markings such as hairy patches (Fig. 2) or midline nevi (or vascular lesion) can also be superficial clues to intradural pathologies.

### Spine

Coronal imbalance is frequent in neuromuscular scoliosis

Neuromuscular scoliosis resembles a kyphoscoliotic deformity, in contrast to the lordoscoliosis found in adolescent idiopathic scoliosis. **Kyphosis** is frequently found as an associated spinal deformity in the neuromuscular patient as the majority of them have "collapsing spine" secondary to muscular weakness or deficient trunk control (Case Study 1). Patients must be examined for both deformities in the sitting and supine positions, giving us an immediate insight into the overall rigidity of both deformities. Of note, hyperlordosis can also be seen in neuromuscular scoliosis, leading to inability to sit properly.

Sagittal imbalance with apical kyphosis is also frequent

The combination of pelvic obliquity and scoliosis tends to lead to spinal imbalance, resulting in abnormal pressure points. Patients with neuromuscular scoliosis can develop pressure sores on the sacrum, the ischia, and the greater trochanter and these should be looked for.

**Figure 2. Clinical clues to neuromuscular scoliosis**

a Eleven-year-old boy, idiopathic-like curve pattern, asymptomatic. On examination unilateral cavus foot with calf atrophy is noted. b The patient presents with a myopathic scoliosis due to Charcot-Marie-Tooth disease. c Seven-year-old girl, right thoracic curve, with overt neuroectodermal marker – hairy patch. d The patient is diagnosed with diastematomyelia and tethered cord.

## Case Study 1

A 12-year-old boy with congenital myopathy (a) presented at our neuromuscular clinic with his older brother (b), who was also diagnosed with neuromuscular scoliosis. His brother had undergone a selective thoracic posterior spinal fusion with Harrington rod 15 years earlier (c). Over time the brother developed additional deformity above and below and crankshaft deformity across the instrumented segment. The main concern of the younger brother was not to end up like his older brother. The patient has severe coronal imbalance with a significant pelvic obliquity (d, e). Surgical management must address both the long classic C-shape neuromuscular scoliosis and the pelvic obliquity. The primary goal is to achieve coronal and sagittal balance. Despite the relatively rigid upper thoracic deformity, correction was achieved by posterior alone spinal surgery with a solid pelvic fixation comprising MW construct, pedicle screws above and below and apical sublaminar wire to maximize apical translation (f, g). The MW "segmental pelvic fixation" (see Fig. 5) allows (if needed) for further pelvic correction by levering on the iliosacral screws in the up or down hemipelvis depending on residual obliquity even after the cantilever maneuver has been done.

### Pelvis and Hips

Hip contractures will influence treatment

From a musculoskeletal examination point of view, one must assess the skeletal appendages as well as the spine. A detailed examination of the hips particularly looking for **hip contracture** is crucial as they influence sitting balance and in particular can induce pelvic obliquity (Case Study 1). As there are many patients with neuromuscular scoliosis who are wheelchair dependent, one must pay particular attention to the pelvis and its orientation in both the coronal (obliquity) and sagittal plane (anteversion/retroversion).

If **pelvic obliquity** is present, one should assess whether its origin is:

- suprapelvic
- intrapelvic
- infrapelvic [13]

Pelvic obliquity is pathognomonic for neuromuscular scoliosis

**Suprapelvic obliquity** is secondary to the spinal deformity itself. The scoliosis drives the pelvis in its obliquity. Dubousset saw the pelvis as the 6th lumbar vertebra and the pelvis being a simple extension of the scoliotic deformity resulting in pelvic obliquity. In contrast, **infrapelvic obliquity** is secondary to hip contractures which result in pelvic obliquity. The contractures which drive the pelvic obliquity tend to be abduction or adduction hip contractures. When both are present in opposite hips one talks of **windswept deformity** of the hips, which typically results in significant pelvic obliquity.

NMD patients often develop hip flexion contractures

In addition, as the majority of these patients are wheelchair dependent, they develop **hip flexion contractures**. These may induce fixed or flexible sagittal spinal deformity in the form of lumbar hyperlordosis. Orientation of the pelvis and lumbar lordosis needs to be assessed as an anteverted pelvis or compensatory hyperlordosis can indicate severe hip flexion contracture. These postoperatively may become much more apparent as the patients are no longer able to compensate with their flexible lumbar spine.

To differentiate between supra- and infrapelvic obliquity, the patient is placed prone at the end of an examining table with the hips flexed over the edge of the table (negating the flexion hip contractures). Then by abducting or adducting the hips, the pelvis can be leveled in the infrapelvic obliquity, while for the suprapelvic obliquity the pelvis cannot be leveled by changing the position of the hips.

An understanding of pelvic obliquity is a key to treatment

**Intrapelvic obliquity** is secondary to morphological changes of the hemipelvises. This can be seen in asymmetrical myelomeningocele as the weaker side develops less, resulting in bony architectural changes leading to ischial and ilium hypoplasia. Pelvic X-rays are the only way to identify such pelvic obliquity.

### Ambulatory Status and Mode of Ambulation

It is not enough to know if the patient is a:

- walker
- sitter (wheelchair bound)
- non-sitter

Mode of ambulation determines the extent of instrumented fusion

In the **walker**, one must determine gait pattern and mode of ambulation. Certain patients (myelodysplasia) need a mobile lumbosacral junction to ambulate as they rely on pelvic thrust to propel their lower extremities to ambulate. Extending the fusion to the pelvis in this subpopulation would take away their ability to ambulate. Even in the **wheelchair-bound patient**, a mobile lumbosacral junction may be needed to perform self-catheterization. Thus, the decision to extend the fusion to the pelvis must be done with careful consideration.

### Neurological Examination

The treating surgeon must complete a thorough physical examination not limited to the musculoskeletal examination. Literally, a head to toe examination is required to search for NMD. **Missing abdominal reflexes** can be a subtle sign of neurogenic scoliosis. Flaccid faces can be suggestive of subtle myopathies while asymmetrical shoe size can be a subtle sign of syringomyelia. Having the patient walk and run while looking for gait pattern and upper extremity posturing can elucidate a **subtle spastic diplegia**. Lower extremity morphological asymmetry such as a unilateral cavus must alert the surgeon that there may be underlying spinal cord pathology warranting further investigation. A detailed neurological examination must be carried out to assess for both sensory and motor deficits. Testing reflexes and looking for long tract signs such as Babinski's and Hoffman's signs, clonus, and spasticity are all part of a first visit examination of a newly diagnosed scoliosis. If weakness is present, differentiating proximal from distal distribution may help in differentiating neuropathies from myopathies. Looking for proximal girdle strength should also be tested by asking the child to stand unassisted from a sitting position. If the child is unable to do so or uses their hands to push themselves up by adapting a wide base gait and locks the knees in extension with the hands and uses the hands to push themselves along on their legs, then this is considered a positive Gower test. Romberg's test should also be performed to test **cerebellar function** (testing balance with eyes closed, feet side by side and arm forward flexed). Signs of calf hypotrophy are also documented as a diagnosis of Charcot-Marie-Tooth disease can be made.

Always check abdominal reflexes

## Diagnostic Work-up

### Medical Assessment

Confirming the diagnosis of neuromuscular scoliosis is best done in a multidisciplinary fashion by including the neurologist and geneticist. To achieve a final diagnosis, nerve and muscle biopsy may be warranted. Managing spinopelvic deformity in the neuromuscular patient remains a challenging task. These patients tend not only to have severe deformities, but they also have associated pathologies that are directly or indirectly related to their spinal deformity that puts them at higher risk of morbidity and mortality (Case Study 2). This multidisciplinary team should include a pulmonologist, a cardiologist, dieticians, a physiotherapist, and an occupational therapist. Particular attention must be paid to pulmonary functions as many patients have severe restrictive pulmonary disease. Pulmonary function of less than 35 % predicted is associated with a protracted postoperative course with an increased risk of ventilation dependency. **Cardiac arrhythmias** secondary to conduction abnormalities and even possible ventricular hypokinesis can be seen in dystrophy patients, in particular those with Duchenne muscular dystrophy. A large proportion of patients with neuromuscular scoliosis have concomitant dietary problems leading to malnutrition (low total protein and a low leukocyte count). As **nutritional status** [51] has a direct impact on the risk of deep wound infections, perioperative nutritional optimization in the form of continuous feeds via a nasogastric tube or total parenteral nutrition (intravenous caloric and protein supplements) during hospitalization is recommended.

Pulmonary function less than 35 % of predicted is associated with increased risk of ventilation dependency

Check for the nutritional status

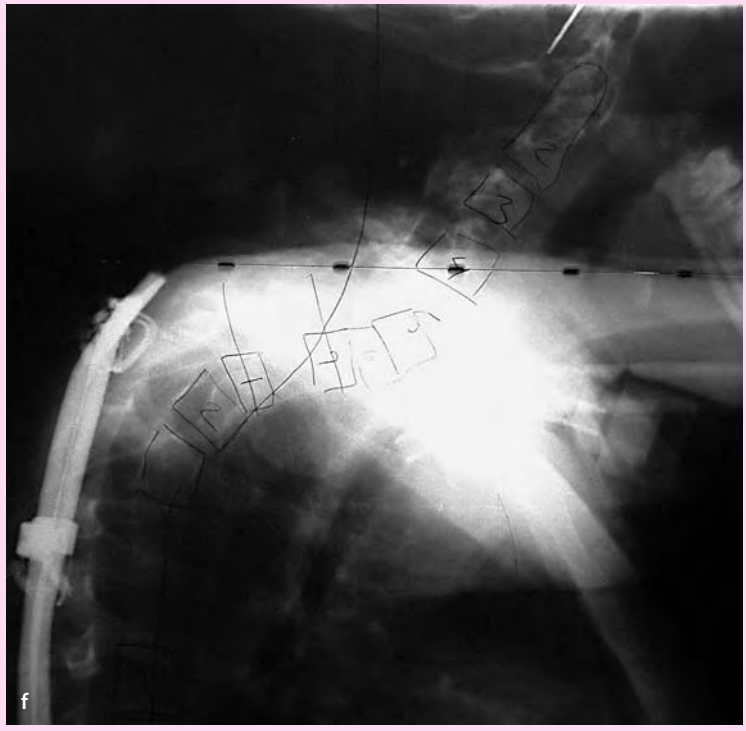


## Case Study 2

An 11-year-old girl with a mid-thoracic functional myelomeningocele presented with progressive neurogenic kyphosis (a, b). The patient had had a tracheotomy for central apnea since the age of 6 years. Sitting and wheelchair adaptation had become progressively more difficult. The thoracolumbar kyphosis was compounding her already compromised respiratory status due to loss of spinal height. The pathophysiology of myelomeningocele kyphotic progressive

**Case Study 2** (*Cont.*)

deformities is secondary to the following "mechanical" considerations: loss of posterior tension band, erector spinal musculature becoming a "flexion" vector as it subluxes anterior laterally, and anterior column deficiency. A hyperextension X-ray shows the kyphosis to have corrected but only partially (c). Surgical treatment included first stage posterior spinal instrumentation and correction with a pedicle subtraction osteotomy at L2. Distal fixation was achieved by using a Donn McCarthy presacral ala rod supplemented with a far lateral pedicle screw preventing distal fixation pull-out. Proximal pedicle screws were used flanking the osteotomy while proximally the fusion and instrumentation was extended to T2 to avoid junctional kyphosis (d, e). The patient had 2nd stage anterior interbody fusion across the kyphotic segment as posterior bone mass was inadequate for solid fusion. In the span of 5 months, the patient developed severe junctional kyphosis (f) with required extension of the instrumentation to the first lordotic cervical segment. Junctional kyphosis was assessed and noted to be relatively flexible on extension film; thus no anterior release was done prior to final surgery (g, h). Inferior facettes were resected, providing adequate correction and sagittal balance.



## Imaging Studies

### Plain Radiographs

Standard radiographs (standing or sitting) remain the imaging modality of choice

Obtaining reliable spine X-rays is a challenge in this patient population as some are unable to stand, to sit or even to lie still for the X-rays. Taking this into consideration, standard **unassisted upright standing or sitting** AP and lateral X-rays have an added variability, thus making curve monitoring more difficult. In some cases supine X-rays are the only X-rays feasible. As part of the preoperative imaging, supine bending films and/or traction films should be obtained to guide surgical planning. The **bending films** and even the **traction films** will provide some insight into the spinal muscular atrophy patient; however, in the spastic quad little will be gained as the patient will not relax for the surgeon to see the residual rigid deformity. Obtaining an intraoperative X-ray with the patient under general anesthesia can provide added information to decide whether the patient needs an anterior release. More important is an intraoperative physical examination to assess curve and pelvis flexibility. An absolute Cobb measurement must not be taken without clinical correlation.

NMD curve typically presents with a long collapsing C-shaped curve

A long **collapsing C-shaped curve** pattern is the classic spinal deformity found in the neuromuscular patient (Case Study 1). Granted that this is the classic curve

But NMD can present with any other curve pattern

pattern, any curve pattern can be found. Left-sided curves, particularly in males, have been associated with syringomyelia. The absence of Dickson's apical lordosis [9] on the lateral X-ray should raise the suspicion of neuromuscular scoliosis [39]. Stagnara described that as the spine rotates 90° the lateral deviation (scoliosis) of the spine is then oriented in the sagittal plan, resulting in apparent kyphosis [46] (Fig. 3). The other type of **kyphotic deformity** in neuromuscular scoliosis is secondary to loss of the posterior tension band such as in myelomeningocele [20] (Case Study 2) or in myopathy scoliosis. This kyphosis can result in significant loss of spinal height, resulting in internal organ crowding and skin breakdown over the gibbus.

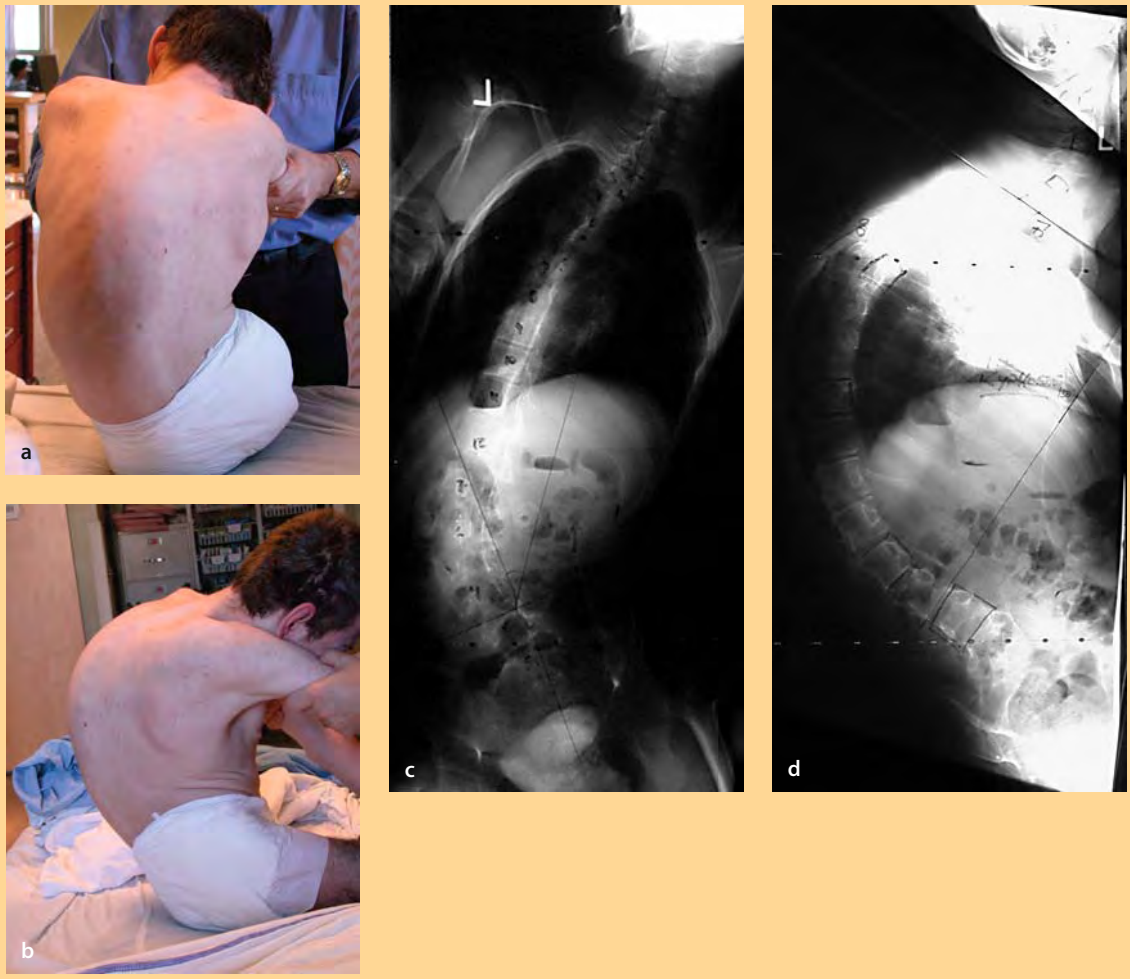


**Figure 3. Neurogenic kyphoscoliosis**

The rotational deformity of scoliosis causes an apparent kyphosis. a, b The clinical coronal deformity appears moderate. However, due to the severe rotational deformity compounded by severe pelvic obliquity, the PA X-ray is actually more of a lateral of the spine. c, d The apparent severe sagittal kyphotic deformity is in fact the coronal scoliotic deformity. This is apparent as one notes the lumbar vertebrae are oriented in a PA orientation. This case illustrates the true three-dimensional nature of spinal deformities.

### Magnetic Resonance Imaging

Any scoliotic patients with a hint of neurological signs or symptoms [8, 49] or with neuroectodermal skin lesions must have MRI performed of the entire spine (occiput to sacrum) to assess the presence of any intradural lesions: syringomyelia, tethered cord, and spinal tumor. Malignant curve progression warrants MRI as it may also be a sign of intradural pathology.

Rule out intradural pathology by MRI

## Non-operative Treatment

When consulting patients for the type of treatment, a thorough knowledge of the natural history is mandatory. The natural history in neuromuscular scoliosis is closely linked to the underlying disease.

### Natural History

In general, patients with neuromuscular scoliosis have a **diminished life expectancy** compared with the general population which is mainly secondary to their underlying neuromuscular diagnosis. Spinal deformity if severe can negatively impact their life expectancy, particularly scoliotic deformities leading to cardiopulmonary compromise [18] (Table 1).

The life expectancy of NMD patients is diminished

The natural history of neuromuscular spinal deformity is one of **curve progression** irrespective of etiology. Granted that there are many different factors influencing curve progression, there are some neuromuscular curves which do not progress; however, the majority will.

**Factors influencing curve progression** are as follows:

- age of onset of NMD
- severity and rapidity of weakness
- evolving or static neuromuscular disease
- skeletal maturity
- ambulation status
- severity of curves

Few papers have specifically looked at the natural history and curve progression of patients with neuromuscular scoliosis [15, 20, 25]. Their curve progression has been reported to be from 7° to 40° per year. The **severe progression** occurs mainly during patients' peak growth compounded with loss of an autoregulatory spinal alignment process which their underlying neuromuscular condition impedes.

Severe curve progression occurs mainly during peak growth

For example, in Duchenne muscular dystrophy, the rate of curve progression in untreated boys overall averages 7° per year. Oda et al. [36], after reviewing the natural history of scoliosis in DMD, found that there were **three courses of curve progression**:

- **Type I** curves comprise progressive collapsing kyphoscoliosis with significant rotatory deformity extending into the pelvis which always reach 30° before the age of 15 years, with a rapid progression of 15°–20° per year thereafter.
- **Type II** curves are characterized by hyperlordosis with a progressive scoliotic deformity. The patients with double major curves tend not to have pelvic obliquity and have stable curves, while patients with lumbar or thoracolumbar curves tend to have pelvic obliquity and progress as type I curves.
- **Type III** curves have straight sagittal spines and have non-progressive scoliotic curves that never reach 30°.

Patients with cerebral palsy have a highly variable onset of puberty

In Becker's muscular dystrophy, curves tend not to be severe and non-progressive [29], as the patients tend to be older. In contrast, in patients with cerebral palsy, because their onset of puberty is highly variable (8–20 years), it is difficult to quantify the risk of curve progression.

Scoliosis in cerebral palsy can progress into adulthood

It has also been shown that scoliosis in patients with cerebral palsy continues to progress even into adulthood [16, 25].

## Non-operative Treatment Options

Non-operative treatment must be individualized

The non-operative management of neuromuscular spinal deformities must be adapted to each patient's specific requirements. When patients are still able to be upright, then initial treatment consists of encouraging prolongation of an upright position while maintaining standing/ambulation status.

Once a patient is **wheelchair dependent**, then seating modifications are warranted to provide lateral trunk support, as well as accommodation of sagittal deformities such as hyperlordosis or kyphosis. The **seating surface** must also be carefully chosen to minimize skin breakdown while providing enough support to minimize pelvic obliquity. Controlling and compensating hip contractures must also be taken into consideration to favorably influence the pelvis to minimize an oblique take-off of the spine.

Bracing is usually not helpful in neuromuscular scoliosis

**Bracing** in neuromuscular scoliosis should not be seen in the same light as bracing for idiopathic scoliosis. Bracing has not been shown to prevent curve progression in neuromuscular scoliosis [37]; thus its usage is not oriented towards the treatment of these curves [6, 32].

The bracing used for neuromuscular scoliosis is **functional bracing**. It provides external support to the spine, allowing some patients to be more functional. Its goal is to maximize functional positioning by controlling some of the spinal collapse, improving posture, and facilitating seating in some cases. One must realize that in some patients with neuromuscular scoliosis bracing is contraindicated since it may result in compromising what is left of their respiratory reserve. Bracing can seriously limit gastric motility, worsening the nutritional status of these patients. Some will simply not tolerate the braces, with uncontrollable behavioral problems. Obviously in any of these situations, bracing should be discontinued, since it is counterproductive to a functional bracing. Early recognition of neuromuscular spinal deformity is important, since treatment plans must be instituted as soon as possible.

## Operative Treatment

### Surgical Indications

The decision to proceed with major spine surgery for neuromuscular scoliosis remains somewhat controversial, particularly when looking at the elevated morbidity and mortality of this type of surgery. Yet a consensus is emerging that with adequate pre- and perioperative multidisciplinary management and with a successful outcome, most patients and caregivers feel the surgery is beneficial to their overall well-being [3].

The indication for scoliosis correction in NMD patients remains controversial

Absolute surgical indications remain controversial [22] for globally disabled children. The classic surgical indications of idiopathic scoliosis, i.e., curves > 50° or **curve progression** in the immature patient, also apply to the management of neurogenic scoliosis. However, these tend not to be the main factors influencing the decision to operate. **Loss of function** is the more common indication to proceed with surgical management of neurogenic scoliosis. As their spinal deformity progresses, the ensuing spinal deformity and trunk shifts result in **decreased pul-**

**monary function** and increased respiratory disease, deterioration of comfort and loss of the activities of daily living, inability to walk or sit independently, as well as a decrease in quality of life. Sitting patients end up supporting themselves with one of their hands, resulting in a functional triplegia. Such functional losses are surgical indications. The development of **pressure sores** and the inability to use further adapted wheelchairs to compensate for their spinal deformity are also surgical indications since the spinal deformity has a real impact on the activities of daily living. In contrast to idiopathic scoliosis, where it is rare that the deformity negatively impacts on the child's well-being, neurogenic scoliosis compounds an already fragile individual (Table 5):

**Table 5.** Indications for surgery

- severe (> 50 degrees) progressive curves
- curve progression in Duchenne muscle dystrophy
- loss of sitting balance
- cardiopulmonary compromise
- deteriorating general well-being

One must not forget that indications will vary depending on the underlying etiology of the scoliosis. For example, in Duchenne muscular dystrophy, knowing that 90 % of patients with DMD will have a progressive spinal deformity as well as a declining pulmonary function [33], one tends to intervene at a lower Cobb angle and/or when the curve is progressive. In fact a loss of pulmonary function is more influential than a rise in Cobb angle. As patients get older, their curves increase while their pulmonary functions decrease. Due to this reverse relationship there is a window in which surgery is recommended, and if it is missed morbidity rises to unacceptable levels. When treating patients with cerebral palsy who are skeletally immature with a progressive curve between 40° and 50°, or skeletally mature cerebral palsy patients with curves greater than 50°, it is recommended to proceed with a spinal arthrodesis [48].

In Duchenne patients surgery is indicated early

## General Principles

The first principle, and probably the only steadfast rule when managing neuromuscular deformities, is not to blindly apply the **classic principles** of surgical management of idiopathic scoliosis. The second principle in managing neuromuscular scoliosis, which is the cornerstone of all surgical management of any spinal deformity, is to achieve perfect **spinal balance** in both the coronal and sagittal planes [42]. Classically these patients do not have compensatory mechanisms (muscle tone, intact proprioception) to rebalance themselves.

Do not blindly apply the classic principles of idiopathic scoliosis management

Aim for coronal and sagittal balance

Patients' curves tend to be long and they often have associated pelvic obliquity, necessitating long fusions to the pelvis. Therefore, the coronal and sagittal balance must be perfect when performing spinal fusions for neuromuscular scoliosis. Thirdly, a word of caution: a thorough preoperative and perioperative medical management is mandatory in managing patients with neuromuscular scoliosis. These patients tend to have **cardiac pathology**, **severe pulmonary disease**, and **malnutrition** [51] to name a few associated conditions. If these medical problems are left unattended or are ignored, they will lead to catastrophic complications.

Consider the comorbidities

## Surgical Techniques

### Levels of Fusion

The Harrington principle, fuse the Cobb angle, also holds true for neuromuscular scoliosis. However, in contrast to idiopathic scoliosis, it is usual to actually span beyond the Cobb for two reasons:

- associated kyphosis
- associated pelvic obliquity

Selective fusion should not be done for NMS

In contrast to idiopathic scoliosis, selective spinal fusion should not be done since the underlying neuromuscular condition will continue to exert its force on the non-fused segment and new deformities will present themselves. The fusion is often extended proximally to address the sagittal kyphotic deformity.

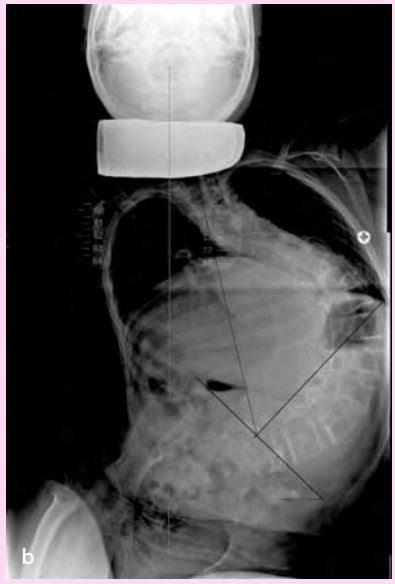

### Case Study 3

A 14-year-old boy with cerebral palsy was referred for a severe and particularly rigid spinal deformity with a rigid pelvic obliquity (a, b). His wheelchair could no longer be adapted to provide comfortable positioning. The patient had developed a pressure sore on his left ischium. Preoperative X-ray confirmed both sagittal and coronal imbalance with little correction on supine bending (c, d).

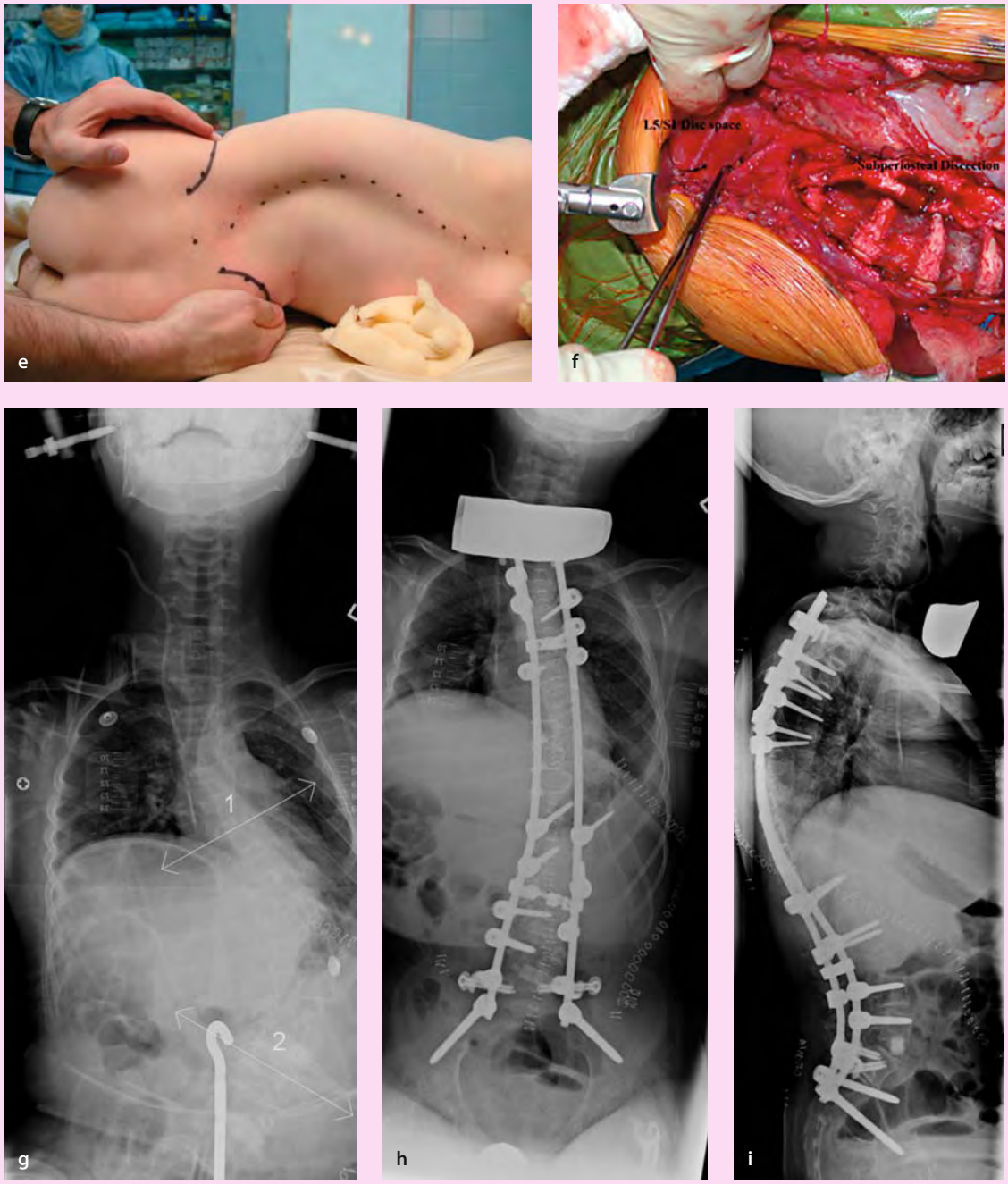


**Case Study 3** (*Cont.*)

Furthermore even under GA with manual traction it was not possible to level the patient's pelvis (e). Hence an anterior release was performed as well as an apical corpectomy (f). Subsequently the patient was placed in gravity halo traction (g). One week later the patient had completion of apical vertobrectomy and posterior instrumentation and fusion with restoration of sagittal and coronal correction (h, i).

Sagittal kyphotic deformities must be addressed and fused

Therefore, it is critical not only to choose your fusion levels with coronal and bending films but to closely scrutinize the lateral X-ray to avoid stopping the fusion at the apex of the kyphotic deformity (Case Study 3). The fusion must extend out of the kyphosis to the first lordotic segment; this holds true both prox-

imally and distally [19]. Fusing long will avoid problematic revision surgery for junctional kyphosis.

Selective spinal fusion must be avoided

In general, T2 is the proximal fusion level for neuromuscular scoliosis. Fusing too short or excessive kyphotic correction leads to junctional kyphosis as patients with neuromuscular kyphoscoliosis want to drift back to their initial sagittal alignment, placing tremendous forces at the distal end of fixation.

Fixation to the sacrum is a major challenge

More often than not, if the distal level of the fusion exceeds the Cobb angle, it is to address the associated **pelvic obliquity**. In general, L5 or the sacrum is the distal fusion level for neuromuscular spinal deformities. There remains some debate as to whether the pelvis should be included or not in the fusion. Patients with pelvis obliquity of less than 10° can have their fusion down to L5 to avoid the complications associated with fixation to the pelvis. Trying to fuse across the lumbosacral junction is associated with a high rate of non-union. Secondly, as there is one level left of mobility, overall spinal alignment can be forgiving, and spinal balance may be achieved by patient volition. The downside of stopping the fusion short of the pelvis is that there is a possibility that the patient decompensates out of balance as the pelvis tilts, thus leading to further spine surgery in already frail patients.

## Spinal Fixation

Sublaminar wires have been the gold standard treatment

The classic spinal implant for neuromuscular curves comprises sublaminar wires with Luque rods [24]. The advantages of this classic segmental spinal fixation are that one achieves a gradual reduction of each segment (mainly by spinal translation), thus minimizing the risk of fracturing the spinal anchorage points.

Poor bone quality challenges the instrumentation

This is of particular concern when treating non-ambulatory patients with an osteoporotic spine either from disuse and/or induced by long-term antiepileptic medication. The disadvantages of wires are the potential risk of injuring the spinal cord during insertion and the risk of considerable epidural bleeding.

Consider the risk of spinal anchorage point fracture and pull out

The alternative construct is a combination of multiple sublaminar hooks, pedicle hooks and/or pedicle screws at each level, distributing the forces across the entire spine. The use of multiple pedicle screws can provide enough corrective forces for the anterior release to be avoided, and to allow for single stage posterior spinal fusion and instrumentation [30]. The liberal use of pedicle screws (lumbar and thoracic) rather than sublaminar wires serves two purposes. Firstly, they allow for a much more thorough decortication, which obviously helps to achieve a better fusion. Secondly, pedicle screws allow for much more radical bilateral facetectomies, which facilitates greater correction. Both of these can be done without fear of weakening the spinal fixation points.

## Sacral and Pelvic Fixation

Sacral and pelvic fixation remain a major challenge in NMD

The classic spinal implant for the management of pelvic obliquity associated with neuromuscular scoliosis is the **Luque-Galveston construct** [11]. This fixation from T2 to pelvis spans the lumbosacral junction by inserting the distal rods into the **posterior superior iliac spine** (PSIS) between the inner and outer tables just above the sciatic notch (Fig. 4). Adding an S1 pedicle screw to the base of the construct and a cross-link proximally adds significant stability to the construct [26]. The unit rod [35] has been shown to be a more effective means of addressing the pelvic obliquity and the spinal deformity [7]. The reduction maneuver for correcting pelvic obliquity consists of a **cantilever maneuver**. This entails fixing the rods distally to the pelvis at a 90-degree orientation to the ischial tuberosities. Then the rods are levered across and attached to the proximal spine, thus leveling the pelvis perpendicular to the balance of the spine. The entry points in the PSIS

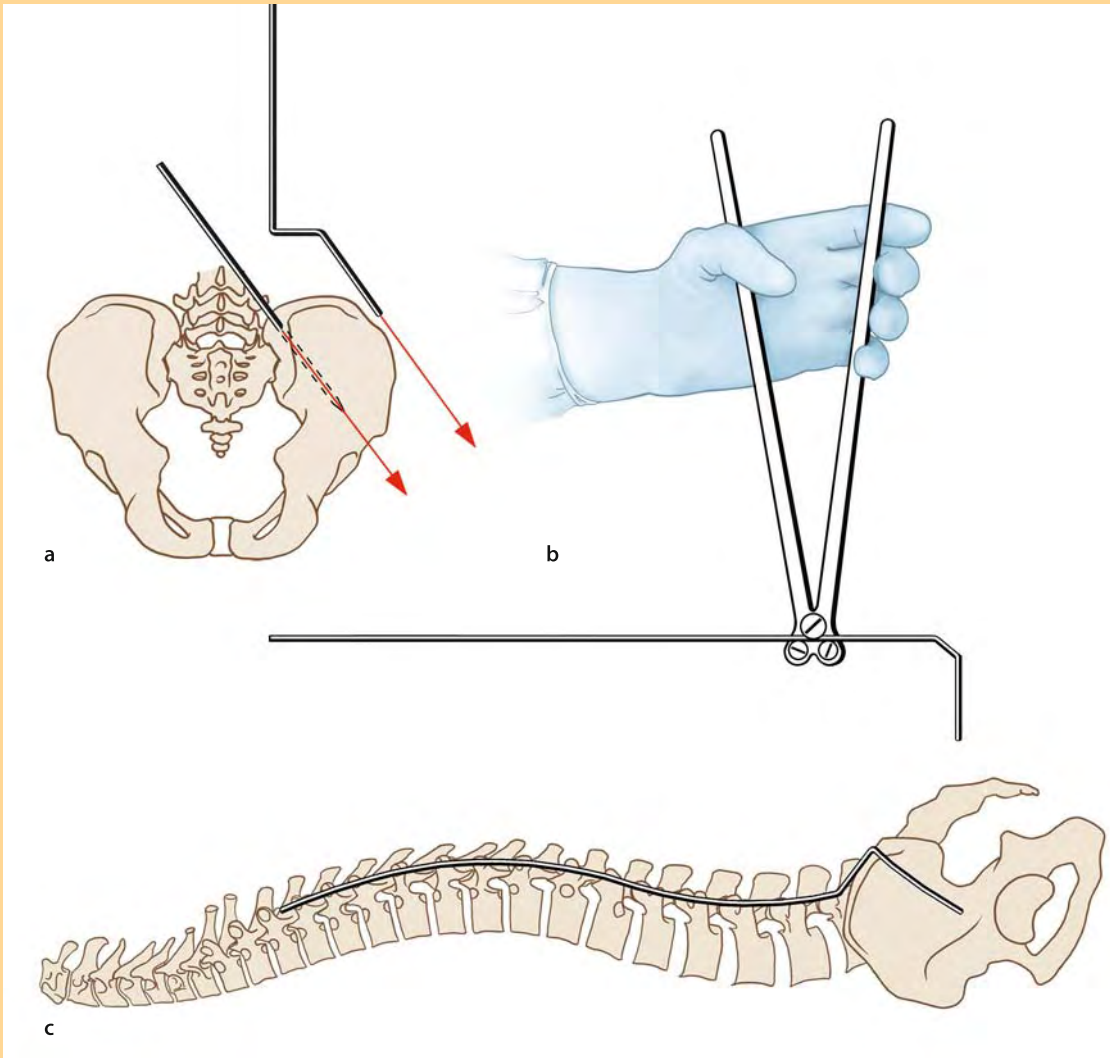


**Figure 4. Luque-Galveston fixation**

a Entry point of iliac fixation at the posterior superior iliac spine (PSIS). b Bending rod for Galveston fixation comprises two bends, one 90° and one 45° in two different planes. c Contouring of the rod to adapt to the sagittal profile. d Luque-Galveston fixation for neuromuscular scoliosis.

are crucial for the unit rod and Galveston techniques as this will determine if the pelvis will be leveled after the reduction maneuver. For severe pelvic obliquity a maximal width (MW) segmental pelvic fixation has also been described and shown to be effective [2]. MW pelvic fixation comprises a pedicle screw inserted in a Galveston fashion down the iliac wing 1 cm above the sciatic notch. As an added lever arm to correct the pelvis, a sublaminar hook pushes or pulls on an iliosacral screw, as described by Dubousset [31]. The construct has a maximal width fixation across the lumbosacral junction and on the AP and axial imaging has an "**M&W**" configuration; hence the eponym **MW fixation** (Fig. 5). The hook placement obviously is dependent on the obliquity of the pelvis; hence the hook facing down is on the iliosacral screw of the elevated hemipelvis side while the hook going up is on the iliosacral screw on the lower hemipelvis. Great forces can be exerted across these iliosacral screws, thus allowing significant correction

The MW fixation allows for a very stable sacropelvic fixation

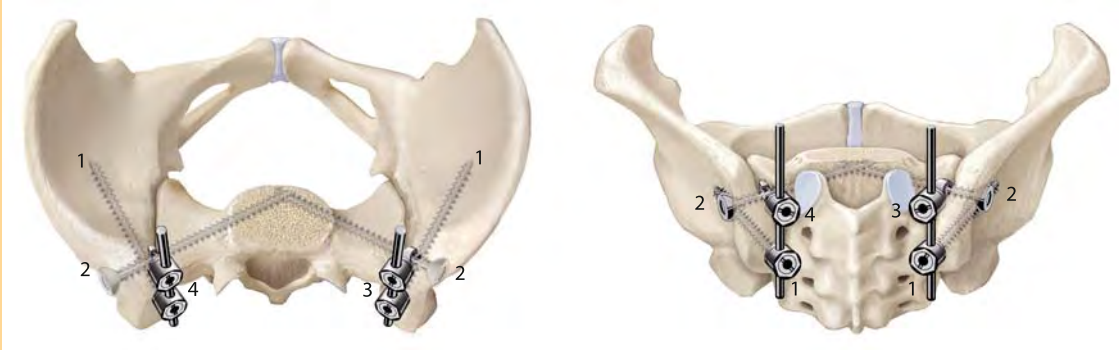


**Figure 5. MW fixation**

The drawings illustrate the placement and appearance of MW fixation. The pelvis anchorage points comprise an iliac screw (*1*) and iliosacral screws (*2*) which have downgoing (*3*) and upgoing hooks (*4*) to provide leverage in opposite directions to level the pelvis. *Inset view* of pelvis illustrates placement of screws. Note the iliosacral screws end in the promontory of S1. Note the location of the hooks harnessing the added lever arm of the iliosacral screws.

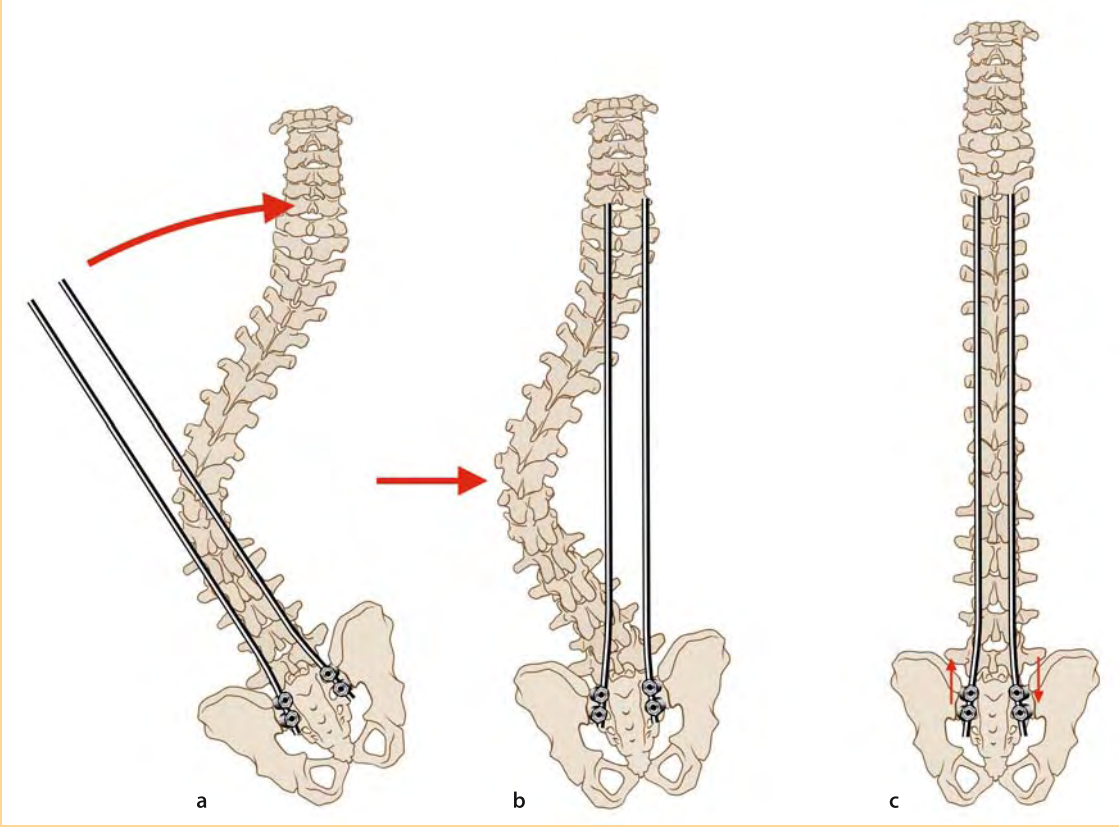


**Figure 6. Cantilever correction with MW sacropelvic fixation**

a The initial step of reduction is to achieve solid distal pelvic fixation. In this illustration MW pelvic fixation is achieved. Rods must be as perpendicular as possible to the pelvis. b The second step is to cantilever the proximal rod to the spine, thus achieving initial correction of the pelvic obliquity. c The third step consists of correcting if needed the residual pelvis obliquity by distracting down via the hook resting on the iliosacral screw on the higher hemipelvis. In contrast, on the lower hemipelvis, the hook will pull up (compressing) the iliosacral screw proximally to level the pelvis.

of oblique pelvis (Fig. 6). From a technical point of view, to improve our accuracy of the insertion of the iliosacral screws we identify and delineate the medial wall of the pedicle of S1 via a small laminotomy. We then identify our entry point on the outer table of the iliac bone, aiming just above the sacral ala and down the S1 pedicle, entering the vertebral body of S1. As one establishes their entry point on the iliac bone one must ensure that the screw will be superficial to the sacral ala, thus allowing some room for the laminar hook to pass underneath it and catch the iliosacral screw (Case Study 1).

### Bone Grafting

Allograft fusion is well accepted for fusion of neuromuscular scoliosis

The general consensus is that an allograft is a well-accepted bone grafting substitute for spinal fusion in neuromuscular scoliosis [52]. Many factors have led to this consensus. In part the pelvises of neuromuscular patients tend to be small, never providing enough bone. Furthermore they are often used as a fixation point. It is therefore standard treatment to supplement a local bone graft (spinous process, facets and lamina) with an allograft.

### Anterior vs Posterior Surgery vs Combined Surgery

The classic surgical management of neuromuscular scoliosis comprises a single posterior spinal fusion. Undertaking anterior spinal surgery has been associated with an increased morbidity especially in NMD patients [12]. **Indications for anterior spinal surgery** are threefold:

- skeletal immaturity
- rigidity of the deformity
- risk of non-union

The literature remains unclear on the absolute indications because of the added morbidity.

Patients at risk of crankshafting should undergo additional anterior fusion

The general principle is that patients who are at risk of a **crankshaft phenomenon** (i.e., progressive rotation of the anterior column around the fused posterior elements) after posterior fusion should undergo an anterior growth arrest and fusion. Keeping in mind that patients with neuromuscular disorders have altered growth patterns [16, 25], patients younger than 10 years of age, Risser 0, with open triradiate cartilage, and who have not yet reached their peak growth velocity are at risk of crankshaft. It is recommended for these patients to proceed with an anterior spinal fusion if they can tolerate the surgical insult.

Anterior release may be necessary for the correction of rigid deformity

The second indication for anterior surgery is the need for an **anterior release** to allow the pelvis to be leveled. If one is unable to correct the pelvis manually by bringing it within 10° of the perpendicular of the trunk by applying external forces over the iliac crests and the trunk with the patient in a prone position with the legs hanging free in flexion, then it is recommended that an anterior release should be done or even an apical vertebrectomy considered. Curve flexibility can be assessed with traction films and supine bending films. However, in some cases of severe spasticity, only intraoperative examination and imaging with the patient under general anesthetic will provide curve flexibility (Case Study 4).

Patients at risk of non-union (e.g. myelodysplasia) should undergo interbody fusion

Thirdly, anterior spinal fusion should be also considered when the **risk of non-union** is elevated. The typical example is that patients with myelomeningocele with deficient posterior spinal elements should systematically have an anterior interbody fusion [45]. The biology of posterior grafting remains in tension mode, while anterior grafting is in compression mode, which favors a solid fusion. Achieving solid anterior fusion can be crucial, as about half of myelomeningocele patients with posterior spinal fusion [20] will develop a deep posterior

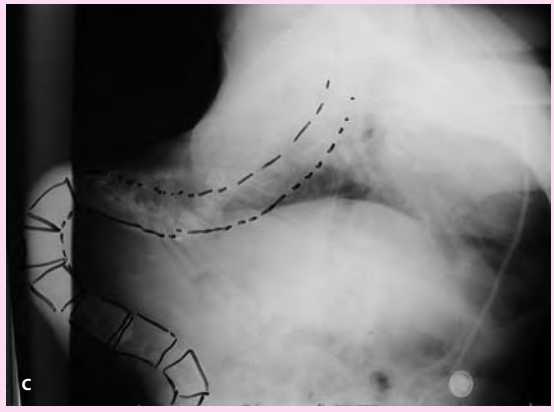


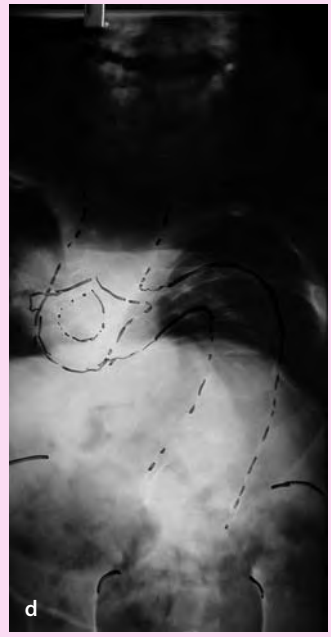

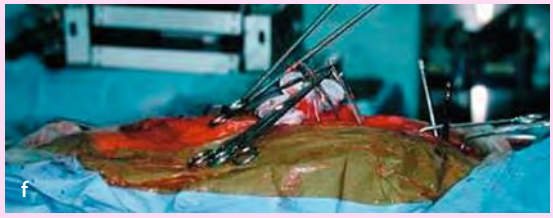


## Case Study 4

This is a 16-year-old boy with a T10 myelomeningocele with a progressive severe coronal and sagittal spinal deformity (a–d). His deformity led him to have recurrent pressure sores over the gibbus, constant GI problems secondary to the increased abdominal pressure, as well as severe pulmonary restrictive disease. Surgical management required preoperative gravity halo traction and aggressive chest physiotherapy to minimize perioperative respiratory collapse. The patient then underwent a **kyphectomy** with a retroperitoneal extraperiosteal resection of the proximal kyphotic segment (e) allowing a maximal distal fixation point. To minimize distal instrumentation, pull-out Dunn-McCarthy presacral rods were used supplemented with far lateral pedicle screws almost behaving as anterior vertebral screws. Once the proximal bone was excised (*yellow shadow*), the deformity was corrected in a cantilever maneuver closing the gap (f) and correcting the deformity.

**Case Study 4** (*Cont.*)

The patient then had an anterior structural tibial graft inserted via a thoraco-abdominal approach to ensure solid anterior spinal fusion across the residual kyphosis (g, h).

spinal infection with the possible necessity of hardware removal [27, 30, 38]. Finally, patients with severe kyphotic deformities requiring significant corrections should also have anterior structural bone grafting (tibia or ribs) to prevent the deformity from recurring. It is preferable to achieve sagittal balance with normalization of the sagittal alignment but moderating the urge to overcorrect the kyphosis.

Single anterior only surgery is indicated only in minor curves without the need for sacropelvic fixation

**Single anterior only spine surgery** can be done for specific curve patterns and patients with specific contraindications to posterior surgery, i.e., chronic infected wounds. The surgical indications that Sponseller recommends for anterior spinal fusion in myelomeningocele are: a relatively small supple curve of less than 70 degrees with no need to extend the fusions down to the pelvis [44].

If combined anterior and posterior surgery is required, the ideal timing of the anterior surgery is still controversial [10]. Anterior surgery can be done on the same day or staged with a period of halo traction, achieving some gradual correction over time. **Gravity halo traction** [5] and **intraoperative halo femoral traction** [17] are options. Irrespective of the type of traction, close neurological examination including cranial nerve testing, muscle strength in the upper and lower extremities, sensory examination and long tract signs is mandatory to avoid injury to the spinal cord. Complications in staged surgery have been found to be higher and some advocate same day front and back surgery [10].

### Severe Rigid Spinal Deformities

Some of the neuromuscular spinal deformities can be severe, and particularly rigid spinal osteotomies, vertebrectomies, or even kyphectomies may be required to rebalance patients. When one needs to proceed to a kyphectomy, the neuromuscular kyphoscoliosis has reached its end stage disease and is an exam-

ple of what can happen with neuromuscular curves. The severe spinal deformity can lead has led to significant loss of spinal column height, resulting in significant disability and morbidity. This child's kyphotic deformity was not addressed at an early age, as there was a false perception that delaying surgical management would allow for better pulmonary function. The problem is that kyphosis will always progress in this population and that the complexity of the case will only increase. There are two types of kyphosis in myelomeningocele. The more **classic collapsing C shape type kyphosis** that can be addressed by pedicle subtraction type osteotomies [27] is classically performed in the newborn and young infant by removing the ossific nuclei. The second type is described as a so-called **rigid S shape kyphosis** [21] due to the associated thoracic lordosis above the lumbar kyphosis. To address such a deformity a spinal column resection is required.

Rigid S shape kyphosis requires spinal column resection

When planning a spinal resection, one must achieve solid fixation above and below the resection. Distal fixation can be problematic if distal vertebrae have been resected, thus keeping as many distal spinal vertebrae as possible, to maximize distal spinal anchorage points. Pelvic/sacral fixation is best achieved with a modified **Dunn-McCarthy presacral rod** [28] augmented with pedicle screws in the most distal vertebral bodies. The entry points for these screws tend to be much more lateral (in the remnant pedicle) and must converge much more than the usual pedicle screws. As the Dunn-McCarthy rods are anterior to the sacrum and sacral alae, one is able to exert a significant corrective force across an osteoporotic pelvis and sacrum. With such a construction one is able to flex in a cantilever fashion the distal spine and pelvis, thus correcting the deformity. Proximal fixation can be performed with sublaminar wire, hooks or pedicle screws. Sharrard first described this as **apical vertebral resection** [43]. We tend to identify and isolate the dural sac [40]. If it poses a physical barrier to our dissection, we ligate the sac and transect the cord; however, we prefer to spare it by mobilizing it and then transecting the roots. We then proceed in an extraperiosteal dissection just as one would do a classic anterior approach. We identify the disc levels, then, by using a blunt dissection we reflect the great vessel and the peritoneum off of the spine from either side. We then ligate the segmental vessels, and reflect anteriorly the peritoneum and the abdominal contents. This is facilitated by the prone position as the abdominal contents fall forward. Once the vertebrae identified have been circumferentially dissected, we place blunt retractors around the spine and proceed to cut the vertebra at a bony surface with an oscillating saw above and below the planned resected spine, thus providing bony apposition. As one does this, significant blood loss is encountered, and it persists until the two ends of the vertebrectomy are reapproximated. Therefore the spinal anchorage points must already be in place and the actual kyphectomy is done last (Case Study 4).

Apical vertebral resection is technically very demanding and associated with significant blood loss

## Spinal Cord Monitoring

Spinal cord monitoring remains mandatory though not always feasible

In patients with neuromuscular scoliosis, one sometimes cannot have any form of intraoperative spinal monitoring due to inadequate somatosensory evoked potential (SSEP) or even motor evoked potential (MEP) and one must rely on the Stagnara wake-up [14, 50]. Sometimes, the wake-up test is also not feasible if patients are uncooperative.

The wake-up test is often unreliable

In such situations we tend to keep all our instruments sterile on the back table until well after the surgery has ended and until the patient has moved all limbs. If there is a problem then we do not need to wait for the resterilization of the instruments and proceed to immediate hardware removal or decrease the amount of correction.

## Recapitulation

**Epidemiology.** Scoliosis, in the presence of a neuromuscular disorder (NMD), behaves entirely differently than the more predictable idiopathic scoliosis. The overall incidence of spinal deformity varies between underlying NMDs but it also varies according to the severity of the underlying NMD. In general, **the greater the neuromuscular involvement, the greater the likelihood of having a spinal deformity** and the greater the deformity will be.

**Pathogenesis.** The pathophysiology of neurogenic spinal deformities remains unclear.

**Clinical presentation.** The **classical spinal deformities** encountered in NMD consist of **kyphoscoliosis**, scoliosis, kyphosis, lumbar hyperlordosis and **pelvic obliquity**. On taking the history one needs to find clues, which may confirm the presence of neuromuscular scoliosis. **Clues suggestive of neuromuscular scoliosis** are birth anoxia, delayed developmental milestone, acquired or familial neuropathies and/or myopathies, spinal deformity before the age of 7 years, or a painful scoliosis. A systemic examination is mandatory of head to toes and further clues can be found confirming the presence of neuromuscular spinal deformity. Neurocutaneous skin markings such as hairy patches or midline nevi (or vascular lesion) can be superficial clues to intradural pathologies. If **pelvic obliquity** is present, one should assess whether its origin is: **suprapelvic, intrapelvic, or infrapelvic**. Dubousset saw the pelvis as the 6th lumbar vertebra and the pelvis being a simple extension of the scoliotic deformity resulting in pelvic obliquity. In contrast, infrapelvic obliquity is secondary to hip contractures, which result in pelvic obliquity. The contractures, which drive the pelvic obliquity, tend to be abduction or adduction hip contractures. It is crucial to know if the patient is a walker, sitter (wheelchair bound) or non-sitter. In the **walker**, one must determine gait pattern and mode of ambulation, as it determines the extent of instrumented fusion (whether or not to include the pelvis). The neurological examination needs to be thorough: Flaccid faces can be suggestive of subtle myopathies while asymmetrical shoe size can be a subtle sign of syringomyelia.

**Diagnostic work-up.** Confirming the diagnosis of neuromuscular scoliosis is best done in multidisciplinary fashion by including the neurologist and geneticist. Patients with neuromuscular scoliosis tend to have severe deformities with associated pathologies that are directly or indirectly related to their spinal deformity that puts them at higher risk of morbidity and mortality. The **onus is on the treating surgeon to exclude hidden pathologies** that can worsen the deformities as well as harm the general health of the patient. **Pulmonary function** less than 35 % of predicted is associated with a protracted postoperative course with an increased risk of ventilation dependency. **Cardiac dysfunctions** can be seen in the muscular dystrophic patients. A large proportion of patients with neuromuscular scoliosis have concomitant dietary problems leading to **malnutrition** which may require supplementation. Part of the preoperative imaging, supine bending films and/or traction films should be obtained to guide surgical planning. Any scoliotic patients with a hint of neurological signs or symptoms or with neuroectodermal skin lesions must have an **MRI scan of the entire spine** taken (occiput to sacrum) to assess any presence of intradural lesions: syringomyelia, tethered cord, or spinal tumor.

**Non-operative treatment.** The **natural history** of neuromuscular spinal deformity is one of **curve progression** irrespective of etiology. **Factors influencing curve progression** are as follows: age of onset of NMD, severity and rapidity of weakness, evolving or static neuromuscular disease, skeletal maturity, ambulation status, and severity of curves. Their curve progression has been reported to be from 7° to 40° per year. In patients with cerebral palsy, because their onset of puberty is highly variable (8–20 years), it is difficult to quantify the risk of curve progression and it has been shown that their scoliosis does progress into adulthood. Bracing for neuromuscular scoliosis is **"functional bracing".** It provides an external support to the spine, allowing some patients to be more functional. Bracing has not been shown to prevent curve progression in the neuromuscular scoliosis.

**Operative treatment.** In contrast to idiopathic scoliosis, neuromuscular deformities tend to **alter the patient's functional status** by interfering with their ability to sit, stand, and walk. This loss of function is the more common indication to proceed with surgical management as all of these curves progress. One must prepare for and expect longer surgical times with greater blood loss. **Surgical planning is crucial** not to miss the associated sagittal deformities. The majority of these patients will need the postoperative intensive care unit mainly to monitor

for fluid shift and respiratory status. The cornerstone of the surgical management of these types of curve is to achieve perfect **spinal balance both in the coronal and sagittal planes**. Classically these patients do not have compensatory mechanisms (muscle tone, intact proprioception) to rebalance themselves. Their curves tend to be long and they often have associated **pelvic obliquity necessitating long fusions to the pelvis**. Treating neuromuscular-spinal deformity requires a vast knowledge of pelvic and spinal fixation techniques such as the **Luque-Galveston techniques**, unit rods, and **MW pelvic fixation**. One should apply all the modern principles of spinal deformity correction to these cases in order to minimize the extent of the approach, to maximize their postoperative function (walking capacity or sitting balance) and to achieve a successful outcome with no postoperative immobilization.

## Key Articles

**Mazur J, Melelaus MB, Dicksen DR, et al. (1986) Efficacy of surgical management for scoliosis in myelomeningocele: correction of deformity and alteration of functional status. J Pediatr Orthop 6:568**
Paper summarizing the impact of spinal surgery on the myelomeningocele patient.

**Askin G, Hallett R, Hare N, Webb JK (1997) The outcome of scoliosis surgery in the severely physically handicapped child: An objective and subjective assessment. Spine 22(1):44 – 50**
A broad summary of the subjective impact of spinal surgery on patients with neuromuscular scoliosis.

**Lonstein J, Akbarnia B (1983) Operative treatment of spinal deformities in patients with cerebral palsy or mental retardation. J Bone Joint Surg Am 65:43 – 55**
Landmark paper providing insight into management of neuromuscular scoliosis.

**Winter S (1994) Preoperative assessment of the child with neuromuscular scoliosis. Orthop Clin North Am 25:239 – 245**
Thorough review and clear recommendations for preoperative work-up of patients with neuromuscular scoliosis going for surgery.

The following papers describe surgical techniques for pelvic fixation, which are required for management of spinal surgery in this patient population:

**Allen BL, Ferguson RL (1984) The Galveston technique of pelvic fixation with L-rod instrumentation of the spine. Spine 9(4):388 – 94**
This article describes the classic sacral fixation technique in neuromuscular scoliosis.

**Bulman W, Dormans J, Ecker M, et al. (1996) Posterior spinal fusion for scoliosis in patients with cerebral palsy: a comparison of Luque rod and unit rod instrumentation. J Pediatr Orthop 16:314 – 323**
In this study the results of 15 patients who underwent arthrodesis with dual Luque rod instrumentation are compared with the results of 15 patients in whom unit rod instrumentation was used. The unit rod instrumentation allowed a significantly greater correction of both the major curve and pelvic obliquity.

**McCarthy RE, Bruffett WL, McCullough FL (1999) S rod fixation to the sacrum in patients with neuromuscular spinal deformities. Clin Orthop Relat Res 364:26 – 31**
This article describes a new form of pelvic fixation for use in patients with neuromuscular spinal deformities to overcome the problems imposed by the Galveston technique. One end of a Luque rod is prebent into an S-shaped configuration and placed over the sacral ala, supplying firm fixation across the lumbosacral junction without crossing the sacroiliac joint. It fixes firmly against the sacral ala by distracting against a hook or screw in the lumbar spine

**Arlet V, Marchesi D, Papin P, Aebi M (1999) The 'MW' sacropelvic construct: an enhanced fixation of the lumbosacral junction in neuromuscular pelvic obliquity. Eur Spine J 8(3):229 – 31**
The authors introduce a new fixation system, in which iliosacral screws are combined with iliac screws. This is made possible by using the AO Universal Spine System with side opening hooks above and below the iliosacral screws and iliac screws below it. The whole sacropelvis is thus encompassed by a maximum width (MW) fixation, which gives an 'M' appearance on the pelvic radiographs and a 'W' appearance in the axial plane.

## References


1. Allen BL, Ferguson RL (1984) The Galveston technique of pelvic fixation with L-Rod instrumentation of the spine. Spine 9(4):388 – 94
2. Arlet V, Marchesi D, Papin P, Aebi M (1999) The 'MW' sacropelvic construct: an enhanced fixation of the lumbosacral junction in neuromuscular pelvic obliquity. Eur Spine J 8(3):229 – 31
3. Askin G, Hallett R, Hare N, Webb JK (1997) The outcome of scoliosis surgery in the severely physically handicapped child: An objective and subjective assessment. Spine 22(1):44 – 50
4. Berven S, Bradford DS (2002) Neuromuscular scoliosis: causes of deformity and principles for evaluation and management. Semin Neurol 22(2):167 – 78. Review
5. Bridwell KH (2001) Adolescent idiopathic scoliosis: surgery. In: Weinstein SL (ed) The pediatric spine: Principles and management, 2nd edn. Chap. 21. Philadelphia: Lippincott Williams & Wilkins, pp 385 – 411
6. Brooke M, Fenichel G, Griggs R, et al. (1989) Duchenne muscular dystrophy, patterns of clinical progression and effects of supportive therapy. Neurology 39:475 – 481
7. Bulman W, Dormans J, Ecker M, et al. (1996) Posterior spinal fusion for scoliosis in patients with cerebral palsy: a comparison of Luque rod and Unit Rod instrumentation. J Pediatr Orthop 16:314 – 323
8. Charry O, Koop S, Winter RB, Lonstein JE, Denis F, Bailey W (1992) Syringomyelia and scoliosis: A review of twenty-five pediatric patients. Proceedings of the Scoliosis Research Society Meeting. Orthopaedic Transactions 16:167
9. Deacon P, Archer IA, Dickson RA (1987) The anatomy of spinal deformity: a biomechanical analysis. Orthopedics 10(6):897 – 903
10. Ferguson RL, Hansen MM, Nicholas DA, Allen BL Jr (1996) Same-day versus staged anterior-posterior spinal surgery in a neuromuscular scoliosis population: the evaluation of medical complications. J Pediatr Orthop 16(3):293 – 303
11. Gau Y, Lonstein J, Winter R, et al. (1991) Luque-Galveston procedure for correction and stabilization of neuromuscular scoliosis and pelvic obliquity: a review of 68 patients. J Spinal Disord 4:399 – 410
12. Grossfeld S, Winter B, et al. (1997) Complications of anterior spinal surgery in children. J Pediatr Orthop 17(1):89 – 95
13. Haas S (1942) Spastic scoliosis and obliquity of the pelvis. J Bone Joint Surg 24:775
14. Hall JE, Levine CR, Sudhir KG (1978) Intraoperative awakening to monitor spinal cord function during Harrington instrumentation and fusion: description of procedure and report of three cases. J Bone Joint Surg Am 60:533 – 536
15. Hart D, McDonald C (1998) Spinal deformity in progressive neuromuscular disease. Phys Med Rehab Clin North Am 9(1)
16. Horstman H, Boyer B (1984) Progression of scoliosis in cerebral palsy patients after skeletal maturity. Dev Med Child Neurol 26:261
17. Huang MJ, Lenke LG (2001) Scoliosis and severe pelvic obliquity in a patient with cerebral palsy: surgical treatment utilizing halo-femoral traction. Spine 26(19):2168 – 70
18. Koman A, Paterson B, Shilt J (2004) Cerebral palsy – Seminar; Lancet 363
19. Lee GA, Betz RR Clements DH 3rd, Huss GK (1999) Proximal kyphosis after posterior spinal fusion in patients with idiopathic scoliosis. Spine 24(8):795 – 9
20. Lindseth RE (1991) Spine deformity in myelomeningocele. Instr Course Lect 40:276
21. Lindseth RE (2001) Myelomeningocele spine. In: Weinstein SL (ed) The pediatric spine: Principles and practice, 2nd edn, Chap 49, pp 859 – 60
22. Lonstein J, Akbarnia B (1983) Operative treatment of spinal deformities in patients with cerebral palsy or mental retardation. J Bone Joint Surg Am 65:43 – 55
23. Luhmann SJ, Lenke LG, Kim YJ, Bridwell KH, Schootman M (2005) Thoracic adolescent idiopathic scoliosis curves between 70 degrees and 100 degrees: is anterior release necessary? Spine 30(18):2061 – 7
24. Luque E (1982) Segmental spinal instrumentation in correction of scoliosis. Clin Orthop 163:192 – 198
25. Majd ME, Muldowny DS, Holt RT (1997) Natural history of scoliosis in the institutionalized adult cerebral palsy population. Spine 22:1416 – 1466
26. Marchesi D, Arlet V, Stricker, Aebi M (1997) Modification of the original Luque technique in the treatment of Duchenne's neuromuscular scoliosis. J Pediatr Orthop 17(6):743 – 9
27. Mazur J, Melelaus MB, Dicksen DR, et al. (1986) Efficacy of surgical management for scoliosis in myelomeningocele: correction of deformity and alteration of functional status. J Pediatr Orthop 6:568
28. McCarthy RE, Bruffett WL, McCullough FL (1999) S rod fixation to the sacrum in patients with neuromuscular spinal deformities. Clin Orthop Relat Res 364:26 – 31
29. McDonald C, Abresch T, Carter G, et al. (1995) Profiles of neuromuscular diseases: Becker muscular dystrophy, Am J Phys Med Rehabil 74: S93 – 103

30. McMaster MJ (1987) Anterior and posterior instrumentation and fusion of thoracolumbar scoliosis due to myelomeningocele. J Bone Joint Surg Br 69:20
31. Miladi LT, Ghanem IB, Draoui MM, Zeller RD, Dubousset JF (1997) Iliosacral screw fixation for pelvic obliquity in neuromuscular scoliosis. A long-term follow-up study. Spine 22(15): 1722 – 9
32. Miller A, Temple T, Miller F (1996) Impact of orthoses on the rate of scoliosis progression in children with cerebral palsy. J Pediatr Orthop 16(3):332 – 335
33. Miller RG, Chalmers AC, Dao H, et al. (1991) The effect of spine fusion on respiratory function in Duchenne muscular dystrophy. Neurology 41:38 – 40
34. Global Polio Eradication Initiative Strategic Plan (2004) Centers for disease. MMWR Morb Mortal Wkly Rep 53(5):107 – 8
35. Moseley CF, Musca V, Laden L, et al. (1985) Improved stability in segmental instrumentation of neuromuscular scoliosis. Presented at the Annual Meeting of Pediatric Orthopedic Society of North America, San Antonio, Texas 1985
36. Oda T, Shimizu N, Yonenobu K, et al. (1993) Longitudinal study of spinal deformity in Duchenne muscular dystrophy. J Pediatr Orthop 13:478 – 188
37. Olafsson Y, Sarast H, et al. (1999) Brace treatment in neuromuscular spine deformity. J Pediatr Orthop 19(3):376 – 9
38. Osebold WR, Mayfield JK, Winter RB, et al. (1982) Surgical treatment of the paralytic scoliosis associated with myelomeningocele. J Bone Joint Surg Am 64:841
39. Ouellet JA, LaPlaza J, Erickson MA, Birch JG, Burke S, Browne R (2003) Sagittal plane deformity in the thoracic spine: a clue to the presence of syringomyelia as a cause of scoliosis. Spine 28(18):2147 – 51
40. Pontari MA, Bauer SB, Hall JE, et al. (1998) Adverse urologic consequence of spinal cord resection at the time of kyphectomy: value of preoperative urodynamic evaluation. J Pediatr Orthop 18:820 – 823
41. RRTC/NMD Roundtable Conference 2001
42. Shapiro GS, Taira G, Boachie-Adjei O (2003) Results of surgical treatment of adult idiopathic scoliosis with low back pain and spinal stenosis: a study of long-term clinical radiographic outcomes. Spine 2003 28(4):358 – 63
43. Sharrard WJW (1968) Spinal osteotomy for congenital kyphosis in myelomeningocele. J Bone Joint Surg Br 50:466
44. Sponseller PD, Young AT et al. (1999) Anterior only fusion for scoliosis in patients with myelomeningocele. Clin Orthop 364:117 – 24
45. Sriram K, Bobrtchko WT, Hall JE (1972) Surgical management of spinal deformities in spina bifida. J Bone Joint Surg Br 54:666
46. Stagnara P (1974) Déviations latérales du rachis: scoliotic. In: Encyclopédie médicochirurgicale. Paris: Appareil Locomoteur
47. Strauss DJ, Shavelle RM (1998) Life expectancy of adults with cerebral palsy. Dev Med Child Neurol 40:369 – 375
48. Thomson JD, Banta JV (2001) Scoliosis in cerebral palsy: an overview and recent results. J Pediatr Orthop B 10:6 – 9
49. Williams B (1979) Orthopaedic features in the presentation of syringomyelia. J Bone Joint Surg Br 61:314 – 23
50. Wilson-Holden TJ, Padberg AM, Lenke LG, Larson BJ, Bridwell KH, Bassett GS (1999) Efficacy of intraoperative monitoring for pediatric patients with spinal cord pathology undergoing spinal deformity surgery. Spine 24(16):1685 – 92
51. Winter S (1994) Preoperative assessment of the child with neuromuscular scoliosis. Orthop Clin North Am 25:239 – 245
52. Yazici M, Asher M (1997) Freeze-dried allograft for posterior spinal fusion in patients with neuromuscular spinal deformities. Spine 22:1467 – 1471

# 25 Congenital Scoliosis

Francis H. Shen, Vincent Arlet

## Core Messages

- ✔ Most cases of congenital scoliosis are sporadic and therefore are non-hereditary
- ✔ Up to 60 % of patients with congenital scoliosis may have malformations of other organ systems, particularly the genitourinary, cardiovascular, and nervous systems
- ✔ The classification system is based on either failure of formation, failure of segmentation, or mixed (failure of both formation and segmentation)
- ✔ Curve progression in congenital scoliosis is based on both the type and location of vertebral anomaly
- ✔ MRI searching for associated neurologic malformations is mandatory
- ✔ The treatment of congenital scoliosis is primarily surgical
- ✔ The goal of prophylactic surgery is to prevent curve progression or attempt a slow progressive correction over time through fusions in situ and/or hemiepiphysiodeses
- ✔ The principle of corrective surgery focuses on attempting to correct the spinal deformity at the time of spinal fusion through either osteotomies or spinal resections
- ✔ Neurologic monitoring is essential during correction of congenital curves

## Epidemiology

Most cases of congenital scoliosis are sporadic and therefore non-hereditary

The presence of a **coronal plane curvature** secondary to an anomalous congenital vertebral defect that is present at birth is known as congenital scoliosis. This can be distinguished from infantile idiopathic scoliosis by the presence of a structural vertebral abnormality. If the vertebral anomaly results in a **sagittal plane deformity** it will result in **congenital kyphosis** or **lordosis**. Frequently, the resulting deformity is a combination of both planes, with congenital kyphoscoliosis being more common than congenital lordoscoliosis. The true incidence of congenital scoliosis is unknown. Among the large studies reported there do not appear to be any significant ethnic or geographic differences, although there is a greater female to male ratio (1.4 – 2.5 to 1). Most cases of congenital scoliosis are **non-hereditary** and pose little risk to subsequent siblings or offspring [3, 45, 47]. In a review of 1 250 congenital deformities at a single institution, Winter found that approximately 1 % of patients with congenital spinal deformities had a known relative with the problem [43]. In fact, the majority of identical twin studies have shown the congenital defect to exist in one of the siblings, but not in the other [15, 29, 40]. Rare reports of both twins having congenital spinal anomalies do exist [1]. Cases with a syndromic association (Jarcho-Levine, spondylothoracic dysplasia, spondylocostal dysplasia) can have a hereditary component, and are typically associated with multiple levels of bilateral failures of segmentation, multiple fused ribs, and missing segments [11, 27, 30]. In these cases, where multiple complex anomalies exist, the related risk is up to 10 % for similar lesions in siblings or subsequent generations [22]. The incidence of associated malformation has been reported to be as high as 25 % for urologic conditions [25], 10 % for cardiac conditions [4], and 28 – 40 % for neuroaxis anomalies [4, 8, 33, 34, 46].

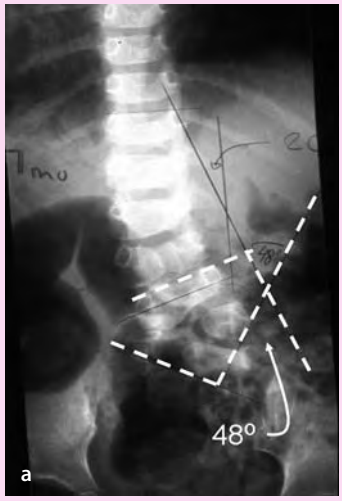

## Case Introduction

Technique for surgical excision of a hemivertebra through a posterior only approach. A 7-month-old girl was diagnosed with a congenital hemivertebra. An MRI was obtained revealing a tethered cord which was subsequently released. She was otherwise healthy and the remaining work-up did not reveal any other associated genitourinary, cardiac, or neurologic malformations. Radiographs (a) demonstrate a fully segmented hemivertebra located at the lumbosacral junction. Due to the magnitude of the curve, location of the anomaly resulting in an oblique take-off of the spine, and associated pelvic obliquity. The patient developed a substantial clinical deformity (b) with coronal imbalance. These cases are perhaps the best indication for early surgical intervention. As a result, at 7 years of age the patient underwent an excision of the hemivertebra through a posterior approach only (Fig. 4). Intraoperative images (c) and postoperative radiographs (d) confirm the position of the instrumentation and correction of the deformity. Clinically, the patient has immediate improvement in her coronal balance (e).

## Pathogenesis

Up to 60% of patients may have malformations of other organ systems

The etiology in sporadic cases is believed to be related to an insult to the fetus during the 4th–6th week of gestation during spine embryological development [24]. It is also during this gestational period that other organ systems are developing in the fetus. As a result, up to 60% of children with congenital scoliosis have malformations in other organ systems, particularly the genitourinary, cardiovascular, and nervous systems [4]. Therefore, a careful search for associated anomalies should be conducted in these patients.

## Classification

The congenital anomalies are classified as either failure of formation, failure of segmentation, or mixed (failure of both formation and segmentation) [27, 44]. Examples of failure of formation are hemivertebra and wedge vertebra, while unilateral unsegmented bars and block vertebra are examples of failure of segmentation (Fig. 1).

Congenital spinal anomalies can be classified as failure of formation, failure of segmentation or mixed

A **wedge vertebra** represents a partial failure of formation on one side of the vertebra. A complete unilateral failure of vertebral formation is known as a **hemivertebra**, and depending on the presence, or absence, of the disc space(s) is further described as:

- fully segmented
- partially segmented, or
- non-segmented

**Fully segmented hemivertebrae** have a normal disc space both superior and inferior to the vertebral anomaly, while a partially segmented hemivertebra has only one normal disc space and is fused to the adjoining vertebra on the remaining side. A non-segmented hemivertebra has no intervening disc space at all and is fused to both the superior and inferior vertebrae. Furthermore, depending on its relationship to the spine, a hemivertebra can be further described as:

- incarcerated or
- non-incarcerted

Wedge vertebra and hemivertebra are examples of failure of formation

An **incarcerated** hemivertebra appears to be "tucked into" the spine with its pedicle falling in-line with the adjacent pedicles, while a **non-incarcerated** hemiverte-

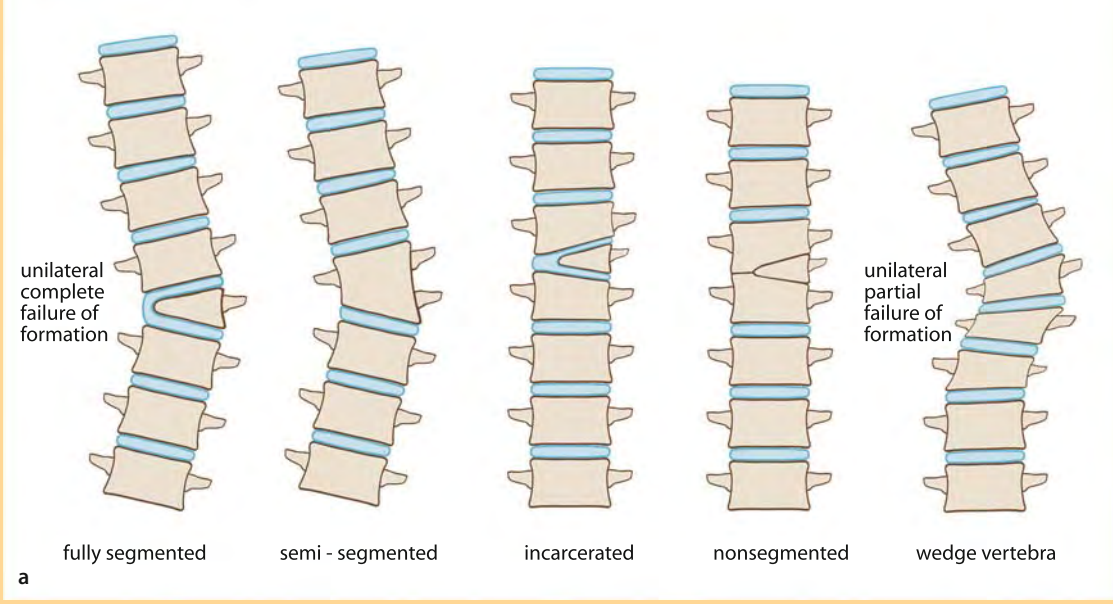


**Figure 1. Classification of congenital scoliosis**

Congenital anomalies of the spine can be classified either as failure of formation or failure of segmentation. a Hemivertebra and wedge vertebra are two common examples of failure of formation. Notice that hemivertebra can be further subclassified as fully segmented, semi- (or partially) segmented, non-segmented, incarcerated and non-incarcerated.

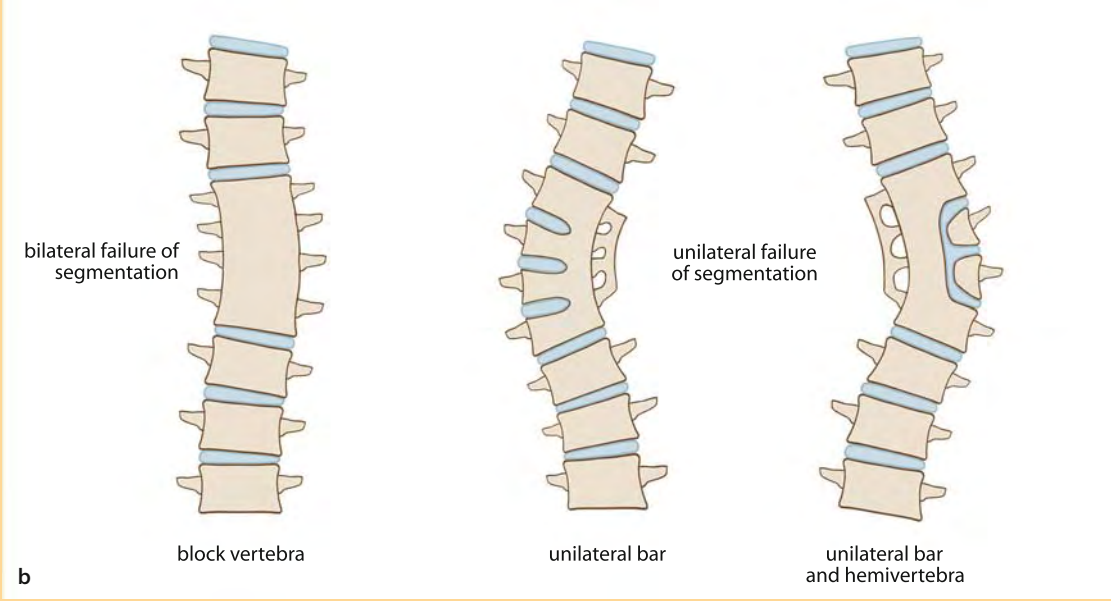


**Figure 1.** (*Cont.*)

**b** Block vertebra is an example of a bilateral failure of segmentation while unilateral bars are examples of unilateral failure of segmentation. A unilateral bar with a contralateral hemivertebra has the worst prognosis for progression and is an example of a mixed anomaly (both failure of formation and failure of segmentation).

bra protrudes out of the spine with its pedicle lying outside the line of the adjacent pedicles [26]. In general, a **non-incarcerated vertebra has a worse prognosis** for progression when compared to an incarcerated vertebra.

Unilateral unsegmented bars and block vertebra are examples of failure of segmentation

A **unilateral unsegmented bar** is a vertebral bar fusing the discs and facets on one side of the vertebral column, while a block vertebra is the result of bilateral failure of segmentation with complete fusion of the disc between the involved vertebrae. In some cases, fused ribs may also be present, typically on the same side as the unsegmented bar. Mixed anomalies are combinations of both failure of formation and failure of segmentation and can occur in any combination.

## Clinical Presentation

### History

Congenital spinal anomaly may be found incidentally

Patients with congenital scoliosis can present at any time. Often the diagnosis of the spinal deformity is made in utero at the time of the **prenatal ultrasound** [5]. Although in most cases the exact anomaly cannot be diagnosed at that time, it is essential that the ultrasonographer also look for other **associated conditions** such as spina bifida, and cardiovascular, urogenital or other syndromic malformations. Prenatal counseling and awareness of the overall prognosis of these kinds of deformities is essential to provide appropriate information to the parents. The congenital curve may also be discovered incidentally on routine radiographs performed for any other reason, such as a chest X-ray for respiratory problems or congenital heart disease, or abdominal films for belly pain. The importance of these images should not be overlooked, because later they can provide essential information in assessing progression of the deformity.

Congenital scoliosis is often associated with other non-spinal anomalies

**Figure 2. Physical findings suggestive of congenital spinal anomaly**

A careful physical examination of the whole body is mandatory. Findings may be as obvious as a gross coronal imbalance; however, often the signs are more subtle. Evidence of a spinal asymmetry, b a hairy patch, c calf or d foot asymmetry is suggestive of an underlying congenital malformation.

Otherwise, the child will be referred for the evaluation of a spinal deformity that was picked up by the family, school nurse, or their physician. Findings that should raise the suspicion of an underlying congenital malformation are:

- a hairy patch
- midline skin hemangioma
- a sacral dimple
- a foot malformation
- leg asymmetry
- urinary symptoms
- an unusual or rigid curve (Fig. 2)

In extreme cases, congenital scoliosis is only discovered at the time of the surgical procedure (of what was thought to be an idiopathic scoliosis), as it may not have been visible on the radiographs due to the rotation of the vertebrae.

Skin stigmata or musculoskeletal anomalies may indicate congenital anomaly

## Physical Findings

The evaluation of the patient follows the same rules as for any spinal deformity examination. An assessment is made of:

- balance of the trunk (plumb line dropped from C7 and the skull)
- balance of the shoulders

- rigidity of the curve
- the rib hump
- associated malformations

The **physical examination** should include:

- whole spine
- skin
- a complete musculoskeletal status
- a thorough neurologic examination

The evaluation must follow the same rules as for any spinal deformity examination

The **clinical assessment** should also search for:

- craniofacial malformations
- Klippel-Feil web neck
- cardiac malformation
- urinary malformations

Serial clinical photographs are helpful for monitoring progression

**Clinical digitalized photographs** should be obtained because they best reflect the patient's clinical presentation. It is important to note that sometimes, although the Cobb angle does not change, the clinical deformity may worsen and may be picked up as an increased shoulder imbalance, trunk shift or a worsening of the compensatory curve requiring early surgical intervention.

## Diagnostic Work-up

The high frequency of associated malformations necessitates a thorough diagnostic work-up of the patient and it is mandatory to not only concentrate on the spinal deformity.

### Imaging Studies

#### Standard Radiographs

Standard radiographs are still the method of choice for an **initial screening** and assessment. The appropriate initial work-up of patients with congenital scoliosis should include:

- whole spine radiographs
- functional views
- cervical spine radiographs
- spot views of the malformation
- chest radiographs

**Whole spine** posteroanterior (PA) and lateral radiographs are essential to assess the deformity comprehensively. The best X-rays are usually ones taken at birth, and one should track them down if they are available. After 1 year of age, radiographs should be taken as upright standing films, with the legs in extension and the pelvis level, to compensate for any leg length discrepancy. The Cobb angle should be measured from endplate to endplate or, if not feasible, one should use the **pedicle lines**. It is essential that the same landmarks be used during subsequent follow-up measurements. Several Cobb angles may have to be calculated and recorded, including the Cobb angle measuring the congenital deformity and one of the overall curve.

The same landmarks should be used during each follow-up radiographic measurement

**Functional views** (flexion/extension, side bending, or traction views) can be used to provide information about instability, flexibility, and rigidity of the deformity. It is accepted that in congenital scoliosis a worsening of the Cobb angle of at least 10° is sufficiently significant to be termed as progression [23].

The **diagnosis of progression** is based on serial clinical and radiographic examinations (every 6–9 months from birth to 5 years of age, every year from 5 to 10, and every 6 months from puberty to the end of skeletal maturity). **Serial radiographs** should always be compared with the initial radiographs, and measurements should include:

Always compare the measurements with the first assessment

- Cobb angle of the whole curve
- Cobb angle of the deformity
- Cobb angle of any compensatory curves
- assessment of vertebral rotation
- rib vertebral angle (ribs becoming more vertical)

Additional cervical spine X-rays are indicated to rule out a Klippel-Feil syndrome or a cervical hemivertebra. The association between congenital scoliosis and Klippel-Feil syndrome has been well described and may present with the classic clinical triad of short neck and low posterior hairline, with a limited neck range of motion. These malformations are often not very well visualized in whole spine radiographs, and spot views of the malformation and flexion-extension lateral radiographs may also be necessary. Recently, studies have noted that the increased **anterior atlantoaxial interval** (ADI) frequently seen in these patients may not necessarily be related to clinical symptoms and that the presence of occipitalization and decreased posterior ADI may provide additional information for identifying patients at risk for developing subsequent neurologic sequelae [34, 36]. In addition, chest cage X-rays will be required in the case of a thoracic curve to look for **rib synostoses**, which may behave as a bar if they are close to the spine.

Search for rib synostoses

### Magnetic Resonance Imaging

When a further assessment is needed or in the process of surgical planning, MRI can provide valuable anatomic detail. MRI with cartilage sequences provides the best quality pictures of the cartilage endplates, possibly giving the best information on growth potential and contact with the intramedullary elements. In addition to better defining the congenital anomaly, MRI has become the modality of choice for the diagnosis of commonly associated **intramedullary disorders** such as syrinx, tethered cord, or Chiari malformations (Fig. 3a–c).

Obtaining an MRI scan to search for associated neurologic malformations is mandatory

The patient with a **tethered cord** may be asymptomatic or present with a range of neurologic symptoms ranging from increased spasticity or gait disturbances, to progressive loss of motor or bowel and bladder function. MRI findings may include the presence of a low lying conus or thickened filum terminale. If present, surgical untethering is typically warranted to avoid incurring further neurologic deficits. Another association frequently identified on MRI includes the Chiari malformation. Although the clinical presentation in these patients is extremely variable, the common MRI finding is characterized by caudal displacement of the cerebellar vermis, tonsils, and cervicomedullary junction into the spinal canal (Fig. 3c).

### Computed Tomography

CT can help define the congenital anomaly better

Tomographs are classic for showing a bony bar, but have lost their role in the diagnostic assessment with the advent of thin-slice high resolution computed tomography (CT). CT with thin slices and with reconstruction is useful in very complex deformities and to facilitate surgical planning.

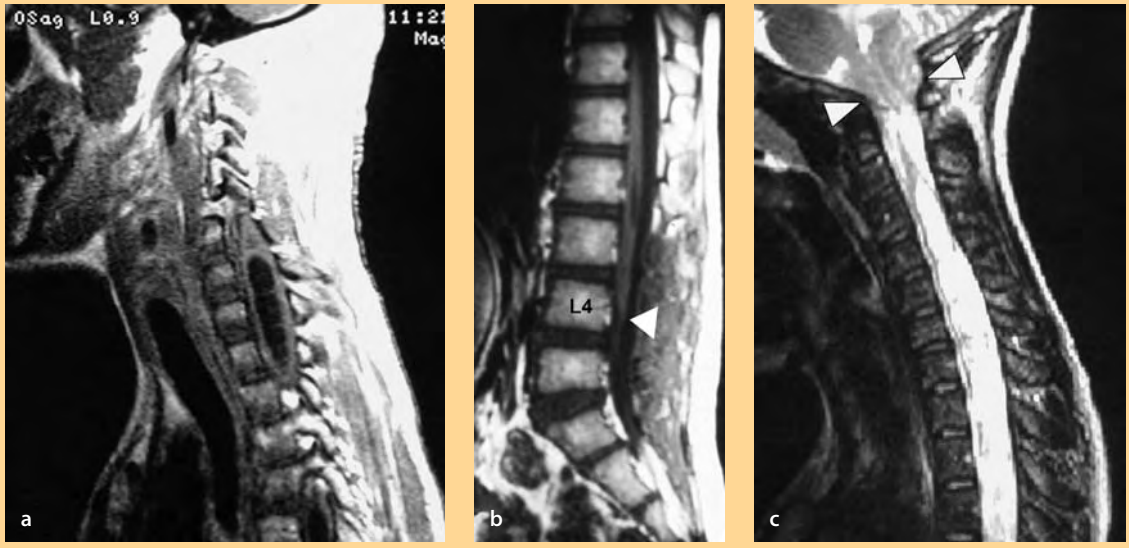


**Figure 3. MRI identifies common associated intramedullary disorders**

Spinal cord anomalies can occur in up to 40% of patients with congenital spinal scoliosis. Common associated findings include **a** syrinx, **b** tethered cord with low lying conus, or **c** Chiari malformation.

### Specific Investigations

**Renal and bladder ultrasound** imaging is recommended for all patients on their initial presentation and further genitourinary imaging is obtained as indicated. A cardiac assessment is also required by the cardiologist, as congenital scoliosis has a 12% incidence of associated cardiac malformation. **Echocardiography** is therefore often indicated to rule out an underlying cardiac problem.

## Non-operative Treatment

Bracing usually is ineffective in congenital scoliosis

Non-operative treatment of congenital scoliosis will consist in either observation of the curve or bracing. Observation should be applied only for non-progressive balanced curves. In most instances bracing is ineffective in congenital scoliosis. It may be indicated for long flexible curves, controlling compensatory lumbar curves, helping to rebalance the spine, or postoperative use until the fusion is solid.

A prerequisite for counseling patients on the choice of treatment is a thorough knowledge of the natural history particularly when surgery is considered. In congenital scoliosis, natural history is predominately influenced by the risk of curve progression.

### Natural History and Progression

Curve progression in congenital scoliosis is related to the type and location

Because of the wide range of deformities that can occur in congenital scoliosis, predicting the risk of curve progression can be difficult. As a general rule, the **rate of progression** is directly related to:

- the potential for asymmetric growth, and therefore related to the presence or absence of an intervening disc(s)
- the location of the vertebral anomaly (Case Introduction)

Therefore, it follows that a fully segmented vertebra, with the presence of two disc spaces (and therefore two sites of growth potential), has a greater risk for curve progression than a non-segmented hemivertebra that is completely fused to the two adjoining vertebrae and has no available disc spaces. Similarly, block vertebrae have no growth potential and therefore remain stable. Table 1 provides guidelines for the risks of progression for each type of anomaly and average degree of progression per year.

**Table 1.** Risk of progression for common vertebral anomalies

| |
|---|
| **Greatest risk of progression** |
| unilateral unsegmented bar with contralateral hemivertebra (5–10 degrees/year) |
| unilateral unsegmented bar (3–9 degrees/year) |
| two unilateral fully segmented hemivertebrae (2–5 degrees/year) |
| one fully segmented hemivertebra (1–3 degrees/year) |
| wedge vertebra (minimal to no growth potential) |
| block vertebra (stable) |
| **Lowest risk of progression** |

While these examples are fairly straightforward, the anatomy in many mixed anomalies can be unclear, with a prognosis that is unknown. In these instances, the patient must be followed closely for evidence of curve progression. In general, the overall average progression per patient is 5 degrees per year [44].

Location of the congenital anomaly can affect both curve progression and overall appearance of the patient. Upper thoracic curves tend to progress less than thoracolumbar and lumbar curves. However, although these upper thoracic curves seldom reach 30°, they can cause significant shoulder imbalance that may require early surgical intervention. Similarly, low lumbar curves can induce an oblique take-off from the spine resulting in pelvic obliquity and truncal imbalance. Mid-thoracic curves, with the apex centered at T5–T7, can induce a progressive compensatory low thoracic or lumbar curve that may need to be included in the fusion if they become bigger and structural. In these instances it may be important to consider early surgical intervention before these changes occur [3].

Early surgical intervention may be required to address curves that result in significant shoulder, pelvic, or trunk imbalance

## Operative Treatment

### General Principles

The treatment of congenital scoliosis is primarily surgical [14, 46]. The goal is to achieve a solid fusion and prevent further progression, and if possible decrease the deformity to achieve as straight a spine as possible at the end of growth. However, the curves are often rigid and correction difficult to achieve; therefore the best approach is **early recognition** and **careful monitoring** [22]. In this manner, early "prophylactic" surgery is possible by anticipating and halting progression before significant deformity occurs [3]. It is even possible in some cases to achieve partial correction over time. However, in many cases some degree of immediate correction is desired. In these cases, the surgical procedures are designed to correct the curve through the use of spinal instrumentation, osteotomies, and spinal column and vertebral resections.

The treatment of congenital scoliosis is primarily surgical

## Surgical Techniques

### "Prophylactic" Surgical Procedures

These procedures are predominantly referred to as "**in situ fusions and hemiepiphysiodesis**." The general principle is to balance the growth by slowing or stopping the convex side growth while allowing the remaining concave growth potential to catch up.

In situ fusion can be done with a single posterior fusion with or without instrumentation, or with an anterior fusion, or as an anterior-posterior fusion. These operations can be performed if the three-dimensional aspects of the deformity have been fully understood. However, the compensatory curve above or below the fused segment may still progress after such procedures. Some correction of the so-called fusions can be achieved if one uses a corrective cast postoperatively.

Asymmetric growth is balanced by arresting growth on the convex side

**Hemiepiphysiodesis** tends to achieve progressive correction over time, taking advantage of the intact growth plates on the concave side of the deformity (Case Study 1). In most cases it requires an anterior and posterior approach to the spine. Anteriorly, one-third of the disc space and corresponding endplates on the convexity of the curve are removed and fused. The hemiepiphysiodesis can be performed through a mini-thoracotomy, thoracoscopically, or even transpedicularly [17, 31]. Posteriorly only the convex side is approached and fused. The patient is then immobilized in a cast in the position of maximum correction to take advantage of the flexibility of the curve. The results are, however, somewhat **unpredictable** [13, 18, 42], and these procedures are typically limited to young patients (under 5 years of age) and to curves of less than 50°. They should not be carried out if there is a kyphosis component to the deformity. A very careful follow-up is necessary, as progression of the deformity can still occur during the adolescent growth spurt.

The outcome of hemiepiphysiodesis is not easily predictable

## Corrective Surgery Procedures

### Posterior Curve Corrections

Neurologic monitoring is essential during correction of congenital curves

Posterior spine fusion without instrumentation and correction with a cast is an option in young children, but the lack of anterior fusion exposes the spine to the crankshaft phenomenon if the anterior growth plates overcome the posterior fusion. Posterior spine fusion with instrumentation is indicated in older patients, where there is no risk of crankshafting [46]. Anterior and posterior spine fusion with discectomies and instrumentation can achieve a significant correction in the mobile segments of the spine. The danger with all corrective procedures is overcorrection and distraction of the curve with subsequent neurologic complications. In such cases the distraction should not be done first. The compression rod should be inserted first and then only minimal distraction applied on the concave rod. The use of spinal cord monitoring and/or a wake-up test after correction is mandatory. Neurologic monitoring can never be emphasized enough during such corrections (Case Study 2). Anterior stabilization of the spine with a strut graft done through a convex, or for biomechanical reasons from a concave, approach should be considered if there is a significant kyphotic component to the deformity.

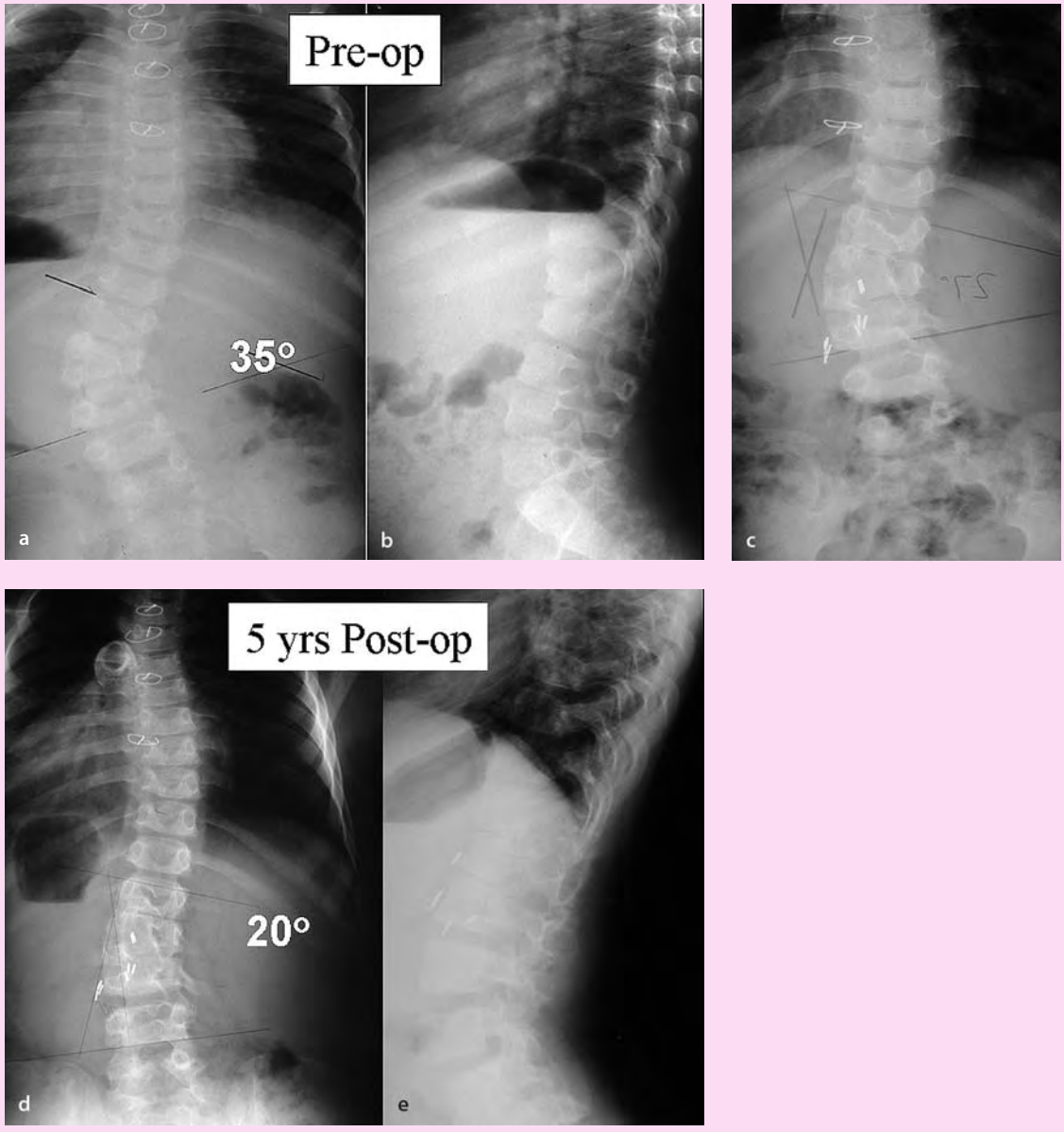


## Case Study 1

A 3-year-old boy presented for evaluation and management of a progressive congenital scoliosis. He was diagnosed with a cardiac murmur at birth and subsequent echocardiogram revealed severe congenital cardiomyopathy and pulmonary hypertension that eventually required surgical intervention. AP and lateral radiographs (a, b) of the spine reveal a partially segmented, incarcerated hemivertebra at the thoracolumbar junction. Cobb angle, measured from endplate to endplate, was 37 degrees at the time of surgery. Physical examination and MRI revealed no other neurologic findings. The patient underwent an anterior hemiepiphysiodesis and posterior hemiarthrodesis on the convex side of the curve (c). Segmental vessels were ligated with surgical clips. The intervertebral disc, and therefore the growth potential on the concave side of the curve, were left intact. The patient tolerated the procedure well and achieved a solid arthrodesis on the convexity of the curve. The remaining growth potential produced unilateral growth and progressive correction of the curve. At latest follow-up (d, e) the congenital curve had been reduced to 20 degrees over a 5-year period.

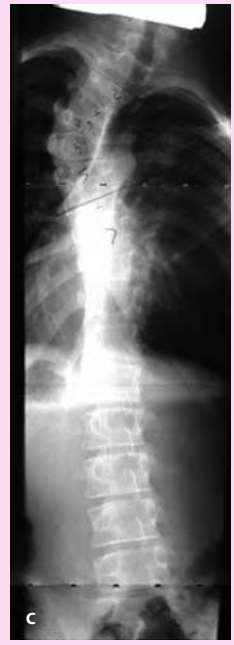

## Case Study 2

A 14-year-old male with congenital scoliosis presented with a 55-degree upper left thoracic curve. He was otherwise neurologically intact. There were no other members in his family with scoliosis. The remaining medical work-up and MRI was negative for associated cardiac, genitourinary, or neurologic malformations. Because of the location of the congenital anomaly in the high thoracic spine, the patient developed a fairly dramatic clinical deformity with an elevated left shoulder (a, b) and coronal imbalance (c). As a result, he underwent an instrumented posterior spinal fusion. Intraoperatively, the left convex rod was inserted first and a **compression maneuver** performed. The second concave rod was placed in situ with minimal distraction. A progressive loss of neuromonitoring signals prompted a Stagnara wake-up test which revealed that the patient had no voluntary motion of the lower extremities. The patient was placed back under anesthesia and both rods were loosened returning the curve to its original position. The patient was able to move all four extremities on the repeat wake-up test. The rods were locked in situ **without any correction**. Postoperatively, the patient was neurologically intact and demonstrated a mild improvement in his clinical (d) and radiographic appearance (e, f). This case emphasizes the dangers associated with curve correction in the surgical treatment of the congenital curve.

### Spinal Osteotomies

Most spinal osteotomies are based on a combination of two traditional osteotomies: the **Smith-Peterson** and the **pedicle subtraction** osteotomies. Both techniques were originally described for the management of flexion deformities that occurred in rheumatoid and ankylosing spondylitis patients and have since been extensively modified [35, 39, 41]. Frequently, as in patients with unsegmented bars, an asymmetric osteotomy aimed at addressing the specific vertebral anomaly should be designed as necessary. A thin-slice or spiral CT scan is essential for preoperative surgical planning, which can be performed through either a single posterior approach or a combined approach. The inherent neurologic risks of such techniques must be well understood before undertaking such a procedure. Placement of segmental instrumentation for provisional stabilization prior to completing the osteotomy can help to reduce the risk of uncontrolled translation of the spine with corresponding neurologic injury.

The selective use of asymmetric spinal osteotomies can help correct deformities in multiple planes, but must be planned carefully

### Hemivertebra Resection

This procedure is done either through a posterior approach only (Fig. 4), or through a sequential or simultaneous anterior and posterior approach [7, 9, 16, 19, 20, 21, 28, 32, 33, 37]. The ultimate surgical approach selected depends on the location of the hemivertebra, its type, whether it is segmented or not, and familiarity of the surgeon with the technique. These procedures usually provide an average of 25°–30° of correction, with some correction of the associated kyphosis. Perhaps the best indications are a fully segmented hemivertebra located at the lumbosacral junction associated with an oblique take-off and pelvic obliquity (Case Introduction). Recent publications tend to show that hemivertebra resection is safe even in the thoracic spine; however, they are clearly more dangerous to perform and should only be carried out by experienced spine surgeons [16].

After hemivertebra excision, the correction can be achieved and maintained by a variety of methods. Depending on the size of the patient, 4.5-mm AO screws inserted into the pedicles with a tension band system can be used, and supra- or infralaminar hooks with cast or brace treatment are also options [3]. In older patients a classic pedicle screw rod system is indicated. Depending on the size and location of the vertebra, anterior instrumentation is also an option [33].

Hemivertebra at the lumbosacral junction causing an oblique take-off may be best treated with hemivertebra resection

### Spinal Column Resection

In very complex spinal deformities the only way to rebalance the spine may be through a **spinal column resection** with shortening of the spinal column. This was described by Bradford and Tribus, and consists of an anterior approach where one or several vertebrae are removed after a decorticated osteoperiosteal flap has been elevated [6]. The involved vertebral bodies are removed down to the dura, the convex pedicles are removed, and as much as possible of the concave pedicles is removed. The posterior surgery, done in the same sitting or a few days later, consists of removing the corresponding posterior laminae and the rest of the concave pedicles. The spinal deformity is then corrected at the same time as the shortening is carried out. Careful monitoring of the neurologic function is mandatory during these exceptional procedures [6]. This procedure should be undertaken by only the most experienced spine surgeons, and only after careful preoperative planning and discussion with the patient and family.

Spinal column resection may be the only way to rebalance the spine in patients with complex deformities

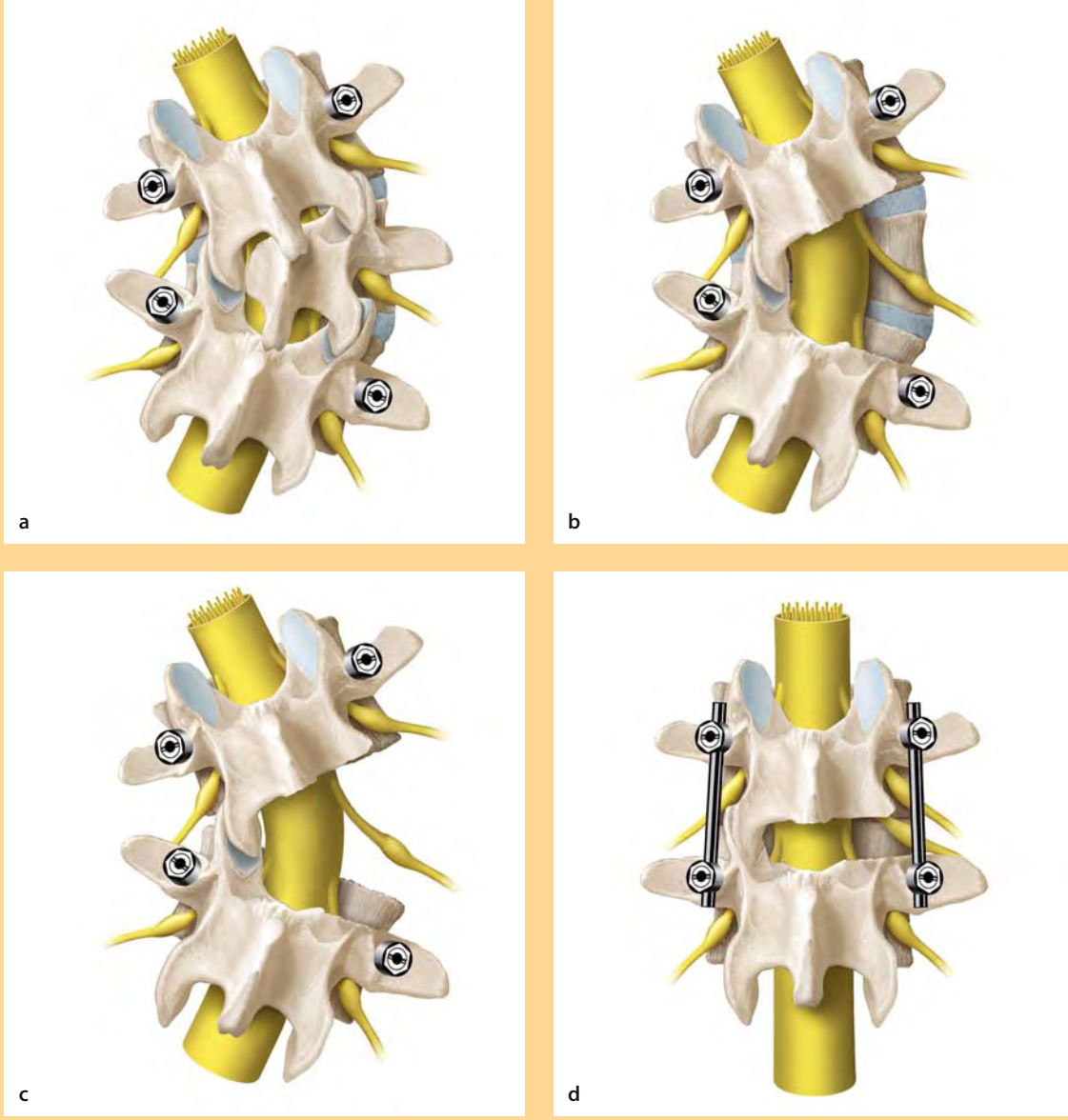


**Figure 4. Techniques of hemivertebra resection (posterior only)**

a During the posterior excision of the hemivertebra, the appropriate level is identified and pedicle screws are inserted above and below the malformation. b Next the inferior facets of the hemivertebra and the vertebra above are removed and a complete laminectomy is performed at the level of the hemivertebra exposing the neural structure. c Decancellation of the vertebral body of the hemivertebra is performed with a curette. The exiting nerve root is protected during this stage of the procedure by the medial pedicle wall. Discectomies above and below the hemivertebra are performed. The hemivertebral excision is completed after removal of the pedicle and the remnant of the vertebral body. This is performed with minimal retraction of the neural elements. d Compression with the pedicle screw rod system results in immediate correction of the deformity. Notice that after the hemivertebra is excised, two nerve roots exit through a single foramen and should be checked for possible nerve root compression.

## Miscellaneous Surgical Techniques

### Halo Traction

The use of halo traction should be exceptional in congenital scoliosis, and it may be dangerous for neurologic function. Its use is formally contraindicated if there is a rigid acute component of kyphosis associated with the scoliosis. However, in selected cases it may be a helpful adjunct, especially in order to prepare the patient for surgery, in cases of severe respiratory compromise, or in between staged surgery [2, 38, 46].

### The Rib Expander

The rib expander (Fig. 5) – the titanium rib expansion project developed in San Antonio by **Campbell** – will allow some spine growth as well as chest and lung expansion if carried out before the age of 8 years, to recruit more pulmonary alveoli [10]. Its best indications are in cases of congenital scoliosis associated with fused ribs and/or patients with thoracic insufficiency syndrome and/or chest hypoplasia.

In the appropriate patient, the use of halo traction, the titanium rib expander, and the subcutaneous growing rod are acceptable surgical options

### Subcutaneous Rods

Subcutaneous rods without fusion and subsequent lengthening may play a role in maintaining the growth of the spine in very young children, but these procedures do not address the area where the malformation of the spine is. They may be combined with convex growth arrest [12]. They expose the patient to multiple lengthening operations and carry a significant risk of complications, mostly infections or instrument complications.

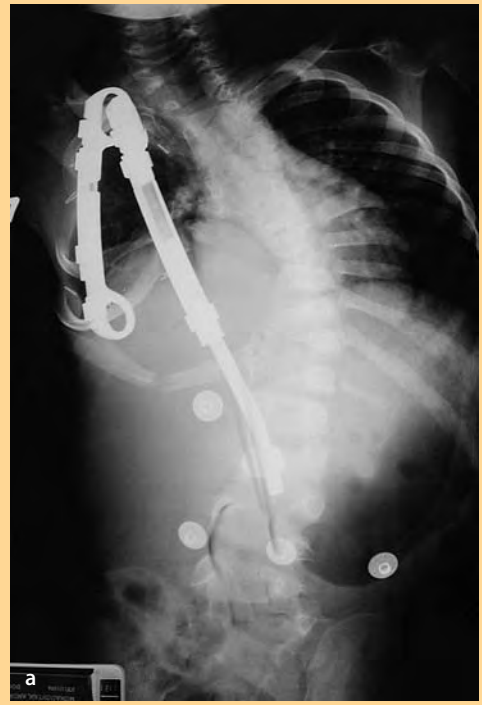


**Figure 5. Alternative treatment options for congenital scoliosis**

In carefully selected cases the use of a the titanium rib expander or

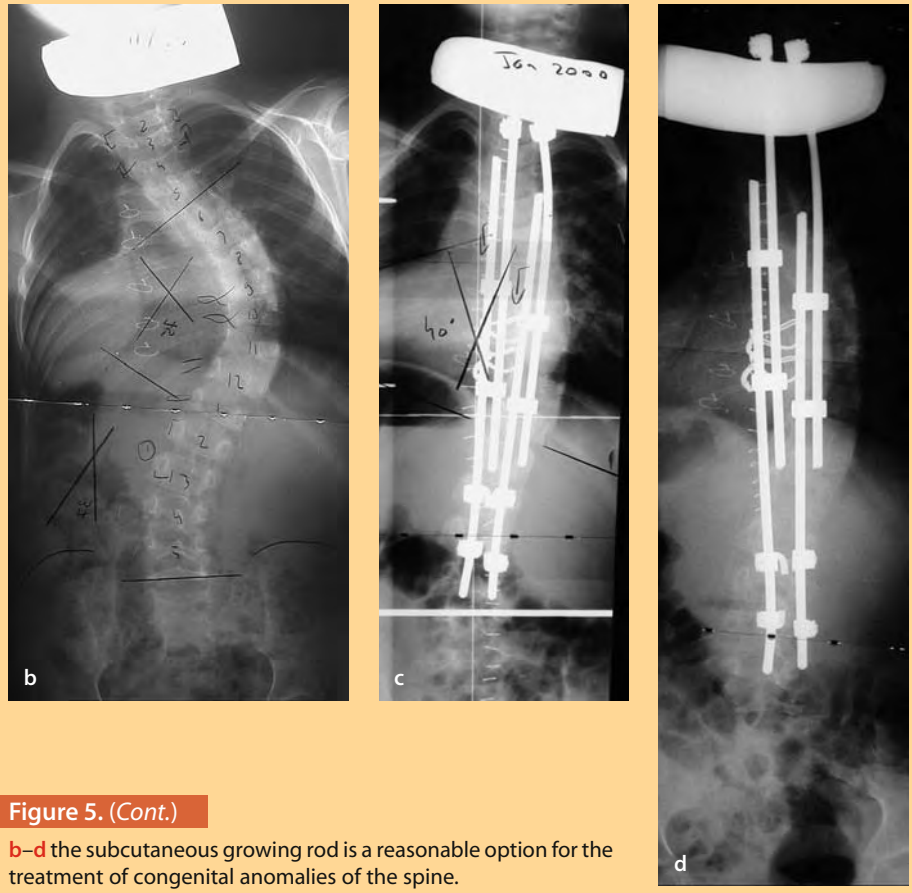


**Figure 5.** (*Cont.*)
b–d the subcutaneous growing rod is a reasonable option for the treatment of congenital anomalies of the spine.

## Recapitulation

**Epidemiology.** The true incidence of congenital scoliosis is unknown. There do not appear to be any significant ethnic or geographic differences, although there is a greater female to male ratio (1.4–2.5 to 1). **Most cases are non-hereditary.** Cases with a syndromic association can have a hereditary component with a 10% risk to siblings and subsequent generations.

**Pathogenesis.** In sporadic cases, the etiology is believed to be an insult to the fetus during the 4th–6th week of gestation. As a result, up to **60%** of patients with congenital scoliosis may **have malformations** in other organ systems.

**Classification.** The congenital anomalies are classified as either **failure of formation**, **failure of segmentation**, or **mixed**. Examples of failure of formation are hemivertebra and wedge vertebra, while unilateral unsegmented bars and block vertebra are examples of failure of segmentation. In addition, hemivertebra is further classified as fully, partially, or non-segmented and as incarcerated or non-incarcerated. In general, a non-incarcerated fully segmental hemivertebra has a worse prognosis for progression compared to an incarcerated non-segmented vertebra.

**Clinical presentation.** Often the diagnosis of the spinal deformity is made at the time of the prenatal ultrasound examination or is discovered incidentally. Otherwise, the child will be referred for the evaluation of a spinal deformity.

**Physical findings.** Examination should include the skin and spine, but one should also look for any foot or leg asymmetry, craniofacial malformations, Klippel-Feil web neck, and cardiac and urinary malfor-

mations. A thorough neurologic examination is required.

**Diagnostic work-up.** The best X-rays are usually ones taken at birth. Several Cobb angles should be calculated, one within the deformity and one over the whole curve. The same landmarks should be used during subsequent measurements. A 10-degree increase in the Cobb angle is considered as progression. Occasionally, although the Cobb angle does not change, the clinical deformity may worsen requiring early surgical intervention. When further detail is needed, cone down views and CT reconstructions can provide additional detail. MRI evaluation of the spinal column is mandatory. Furthermore an ultrasound examination of the genitourinary and cardiac system should be performed as indicated.

**Non-operative treatment.** Observation may be considered for non-progressive balanced curves. Bracing in most instances is ineffective in congenital scoliosis.

**Natural history and progression.** The rate of **progression** in congenital scoliosis is directly related to: (1) the **potential** for asymmetric growth and (2) the **location** of the vertebral anomaly. Depending on the location, early surgical intervention may be required to address congenital curves that result in significant shoulder, pelvic, or trunk imbalance.

**Operative treatment.** The goal is to achieve a solid fusion and prevent further progression, to achieve as straight a spine as possible at the end of growth. **Prophylactic surgical procedures** refer predominantly to in situ fusions and hemiepiphysiodesis. The general principle is to balance the growth by slowing or stopping the convex side growth while allowing the remaining concave growth potential to catch up. **Posterior spine fusion without instrumentation and correction** with a cast is an option in young children, but exposes the spine to the crankshaft phenomenon. Posterior spine fusion with instrumentation is indicated in older patients. Anterior and posterior spine fusion with instrumentation can achieve a significant correction; however, neurologic complications are a concern. The use of spinal cord monitoring and/or a wake-up test is strongly recommended. In selected cases an **osteotomy with subsequent corrective instrumentation** is an option; however, the inherent neurologic risks of such techniques must be well understood before undertaking such a procedure. **Hemivertebra resection** is done either through a posterior approach only or through a sequential or simultaneous anterior and posterior approach, and provide an average of 25°–30° of correction. Fully segmented hemivertebra at the lumbosacral junction may be the best indication for resection. In very complex deformities the only way to rebalance the spine may be through a spinal column resection. In the appropriate patient, the use of halo traction, the **titanium rib expander**, and the **subcutaneous growing rod** are acceptable surgical options.

## Key Articles

**Wynne-Davies R (1975) Congenital vertebral anomalies: etiology and relationship to spina bifida cystica. J Med Genet 12:280–88**
In a study of 337 patients with congenital spinal anomalies, the author found that an isolated hemivertebra or similar localizing defect was sporadic with no risk to subsequent siblings or offspring. Patients with multiple anomalies, however, carry a 5–10% risk to subsequent siblings.

**McMaster MJ, Ohtsuka K (1982) The natural history of congenital scoliosis. A study of two hundred and fifty-one patients. J Bone Joint Surg Am 64(8):1128**
This paper provides a review of over 200 patients who were observed past the age of 10 without treatment. They found that final severity depended on the type of vertebral anomaly, the location of the anomaly, and the age of the patient at diagnosis.

**Bradford DS, Heithoff KB, Cohen M (1991) Intraspinal abnormalities and congenital spine deformities: a radiographic and MRI study. J Pediatr Orthop 11:36–41**
Forty-two patients with congenital spinal deformity were studied by MRI. Sixteen patients (38%) had an associated intraspinal abnormality. The authors recommend MRI in patients with congenital spinal deformities undergoing spinal stabilization.

## Key Articles

**Roaf R (1963) The treatment of progressive scoliosis by unilateral growth arrest. J Bone Joint Surg Br 45:637**
One of the earliest descriptions of the use of convex growth arrest for addressing congenital scoliosis. Convex growth arrest is achieved by anterior and posterior convex fusions resulting in continued concave growth with potential curve correction.

**Bradford DS, Tribus CB (1997) Vertebral column resection for the treatment of rigid coronal decompensation. Spine 22:1590 – 9**
Twenty-four patients with rigid coronal decompensation underwent anterior-posterior vertebral column resection, spinal shortening, with posterior spinal instrumentation and fusion. Average correction of coronal and sagittal plane deformity was 82 % and 87 % respectively. Although the complication rate was nearly 60 % (14 patients), all patients rated their results as either good or excellent.

**Lazar RD, Hall JE (1999) Simultaneous anterior and posterior hemivertebra excision. Clin Orthop Rel Res 364:76 – 84**
Eleven patients underwent simultaneous anterior and posterior resection of a congenital hemivertebra with deformity correction using posterior instrumentation. Preoperative curves measuring an average of 47 degrees corrected to an average of 14 degrees at 28 months follow-up. There was one transient leg weakness which resolved. No long term complications were noted.

## References


1. Akbarnia BA, Heydarian K, Ganjavian MS (1983) Concordant congenital spine deformity in monozygotic twins. J Pediatr Orthop 3:502
2. Arlet V, Papin P, Marchesi D (1999) Halo femoral traction and sliding rods in the treatment of a neurologically compromised congenital scoliosis: technique. Eur Spine J 8:329 – 31
3. Arlet V, Odent T, Aebi M (2003) Congenital scoliosis. Eur Spine J 12:456 – 63
4. Beals RK, Robbins JR, Rolfe B (1993) Anomalies associated with vertebral malformations. Spine 18:1329 – 1332
5. Benacerraf BR, Greene MF, Barss VA (1986) Prenatal sonographic diagnosis of congenital hemivertebra. J Ultrasound Med 5:257 – 9
6. Bradford DS, Tribus CB (1997) Vertebral column resection for the treatment of rigid coronal decompensation. Spine 22:1590 – 9
7. Bradford DS, Boachie-Adjei O (1990) One-stage anterior and posterior hemivertebral resection and arthrodesis for congenital scoliosis. J Bone Joint Surg Am 72:536 – 40
8. Bradford DS, Heithoff KB, Cohen M (1991) Intraspinal abnormalities and congenital spine deformities: a radiographic and MRI study. J Pediatr Orthop 11:36 – 41
9. Callahan BC, Georgopoulus G, Eilert RE (1997) Hemivertebral excision for congenital scoliosis. J Pediatr Orthop 17:96 – 9
10. Campbell RM, Vocke AK (2003) Growth of the thoracic spine in congenital scoliosis after expansion thoracoplasty. J Bone Joint Surg Am 85:409 – 20
11. Cantu JM, Urrusti J, Rosales G, et al. (1971) Evidence for autosomal recessive inheritance of costovertebral dysplasia. Clin Genet 2:149
12. Cheung KM, Zhang JG, Lu DS, et al. (2002) Ten-year follow-up study of lower thoracic hemivertebrae treated by convex fusion and concave distraction. Spine 27:748 – 53
13. Chirpaz-Cerbat JM, Michel F, Berard J, et al. (1993) Early and semi-early surgery for scoliosis caused by hemivertebrae – indications and results. Eur J Pediatr Surg 3:144 – 53
14. Hall JE, Herndon WA, Levine CR (1981) Surgical treatment of congenital scoliosis with or without Harrington instrumentation. J Bone Joint Surg Am 63:608 – 619
15. Hattaway GL (1977) Congenital scoliosis in one of monozygotic twins: a case report. J Bone Joint Surg Am 59:837
16. Holte DC, Winter RB, Lonstein JE, et al. (1995) Excision of hemivertebrae and wedge resection in the treatment of congenital scoliosis. J Bone Joint Surg Am 77:159 – 171
17. Keller PM, Lindseth RE, DeRosa GP (1994) Progressive congenital scoliosis treatment using a transpedicular anterior and posterior convex hemiepiphysiodesis and hemiarthrodesis. A preliminary report. Spine 19:1933 – 9
18. Kieffer J, Dubousset J (1994) Combined anterior and posterior convex epiphysiodesis for progressive congenital scoliosis in children aged < or = 5 years. Eur Spine J 3:120 – 5

19. Klemme WR, Polly DWJ, Orchowski JR (2001) Hemivertebral excision for congenital scoliosis in very young children. J Pediatr Orthop 21:761 – 4
20. Lazar RD, Hall JE (1999) Simultaneous anterior and posterior hemivertebra excision. Clin Orthop 364:76 – 84
21. Leatherman KD, Dickson RA (1978) Two stage corrective surgery for congenital deformity of the spine. J Bone Joint Surg Br 61:324 – 328
22. Loder RT (2003) Congenital scoliosis and kyphosis. In: DeWald RL, Arlet V, Carl AL, et al. (eds) Congenital scoliosis and kyphosis. New York: Thieme, pp 684 – 693
23. Loder RT, Urquhart A, Steen H, et al. (1995) Variability in Cobb angle measurements in children with congenital scoliosis. J Bone Joint Surg Br 77:768 – 70
24. Loder RT, Hernandez MJ, Lerner AL, et al. (2000) The induction of congenital spinal deformities in mice by maternal carbon monoxide exposure. J Pediatr Orthop 20:662 – 666
25. MacEwen GD, Winter RB, Hardy JH (1972) Evaluation of kidney anomalies in congenital scoliosis. J Bone Joint Surg Am 54:1451 – 54
26. McMaster MJ, David CJ (1986) Hemivertebra as a cause of scoliosis: a study of 104 patients. J Bone Joint Surg Br 68:588 – 95
27. McMaster MJ, Ohtsuka K (1982) The natural history of congenital scoliosis: a study of two hundred and fifty one patients. J Bone Joint Surg Am 64:1128 – 47
28. Nakamura H, Matsuda H, Konishi S, et al. (2002) Single-stage excision of hemivertebrae in the posterior approach alone for congenital spine deformity: follow-up period longer than ten years. Spine 27:110 – 5
29. Peterson HA, Peterson LF (1967) Hemivertebrae in identical twins with dissimilar spinal columns. J Bone Joint Surg Am 49:938
30. Rimoin DL, Fletcher BD, McKusick VA (1968) Spondylocostal dysplasia. A dominantly inherited form of short trunked dwarfism. Am J Med 45:948
31. Rothenberg S, Erickson M, Eilert R, et al. (1998) Thoracoscopic anterior spinal procedures in children. J Pediatr Orthop 33:1168 – 70
32. Ruf M, Harms J (2002) Hemivertebra resection by a posterior approach: innovative operative technique and first results. Spine 27:1116 – 23
33. Shen FH, Lubicky JP (2004) Surgical excision of the hemivertebra in congenital scoliosis. J Am Coll Surg 199:652 – 3
34. Shen FH, Herman J, Lubicky JP (2003) A radiographic classification for identifying Klippel-Feil patients at increased risk for developing clinically significant cervical symptoms. In: 31st Annual Meeting of the Cervical Spine Research Society. Scottsdale, Arizona
35. Shen FH, Samartzis D, Jenis L, et al. (2004) Evaluation and surgical management of the rheumatoid neck. Spine J 4:689 – 700
36. Shen FH, Samartzis D, Herman J, et al. (2006) Radiographic assessment of segmental motion at the atlantoaxial junction in the Klippel-Feil patient. Spine 31:171 – 177
37. Shono Y, Abumi K, Kaneda K (2001) One-stage posterior hemivertebra resection and correction using segmental posterior instrumentation. Spine 26:752 – 7
38. Sink EL, Karol LA, Sanders J, et al. (2001) Efficacy of perioperative halo-gravity traction in the treatment of severe scoliosis in children. J Pediatr Orthop 21:519 – 24
39. Smith-Peterson MN, Larson CB, Aufranc OE (1945) Osteotomy of the spine for correction of flexion deformity in rheumatoid arthritis. J Bone Joint Surg Am 27:1 – 11
40. Sturm PF, Chung R, Bomze SR (2001) Hemivertebra in monozygotic twins. Spine 26:1389 – 91
41. Thomasen E (1985) Vertebral osteotomy for correction of kyphosis in ankylosing spondylitis. Clin Orthop 194:142 – 152
42. Thompson AG, Marks DS, Sayampanathan SR, et al. (1995) Long-term results of combined anterior and posterior convex epiphysiodesis for congenital scoliosis due to hemivertebrae. Spine 20:1380 – 5
43. Winter RB (1983) Congenital deformities of the spine. New York: Thieme-Stratton
44. Winter RB, Moe JH, Eilers VE (1968) Congenital scoliosis: a study of 234 patients treated and untreated. Part I: natural history. J Bone Joint Surg Am 64:1128 – 47
45. Winter RB, Moe JH, Lonstein JE (1983) A review of family histories in patients with congenital spine deformities. Orthop Trans 7:32
46. Winter RB, Moe JH, Lonstein JE (1984) Posterior arthrodesis for congenital scoliosis. An analysis of the cases of two hundred and ninety patients five to nineteen years old. J Bone Joint Surg Am 66:1188 – 97
47. Wynne-Davies R (1975) Congenital vertebral anomalies: etiology and relationship to spina bifida cystica. J Med Genet 12:280 – 88

# 26 Degenerative Scoliosis

Max Aebi

## Core Messages

- ✔ The average age of patients with degenerative scoliosis is in the sixties
- ✔ Degenerative scoliosis is a form of adult scoliosis (= scoliosis after bony maturity)
- ✔ Degenerative scoliosis can be distinguished into primary (de novo) degenerative scoliosis and secondary degenerative idiopathic scoliosis (primary curve or compensatory curves)
- ✔ Degenerative scoliosis can progress with time
- ✔ The cardinal symptoms are back pain, claudication symptoms, neurological deficit and curve progression
- ✔ Cosmesis does not play an important role
- ✔ Patients with back pain in degenerative scoliosis need to be individually evaluated for surgery
- ✔ Clinical signs and symptoms as well as comorbidities determine the extent of surgery
- ✔ The primary goal of the treatment is not curve correction but the control of back pain and claudication symptoms
- ✔ A decompression at the apex of the curve needs to be stabilized and fixed in order to prevent curve progression
- ✔ The loss of lordosis is often the main reason for back pain, and sagittal realignment is crucial
- ✔ The fixation of the lumbosacral junction in the stabilization of a deformed lumbar spine remains controversial

## Epidemiology

Degenerative scoliosis can be differentiated into two major groups, i.e., primary degenerative scoliosis or **de novo scoliosis** (after skeletal maturity) and **secondary degeneration** of adult idiopathic scoliosis or scoliosis of other etiology [1, 7].

Slow progression of degenerative scoliosis is common

The prevalence of scoliosis in patients older than 50 years is about 6 %, including patients with secondary degeneration of adult idiopathic scoliosis as well as patients with degenerative or de novo scoliosis [6, 7, 14, 17], and the average age of those seeking medical care with degenerative scoliosis is in the sixties. There is a potential for curve progression with an average of 3.3° a year (Case Introduction). Degenerative scoliosis, which occurs on the basis of idiopathic scoliosis of less than 30°, usually does not tend to progress; however, curves greater than 50° have a tendency to progress an average of 1 – 2° a year.

Nevertheless, for primary degenerative scoliosis, there is no scientific evidence which really documents the full complexity and extent of the natural history. For instance, degenerative scoliosis occurs more frequently in male patients than adult idiopathic scoliosis, which is more frequent in females. There are several aggravating factors in patients with degenerative scoliosis, mostly due to the advanced age of patients, who have several comorbidities such as diabetes, heart disease, pulmonary disease, and osteoporosis, factors which play a significant role in the assessment and decision-making for treatment [3, 8, 11, 18, 25].

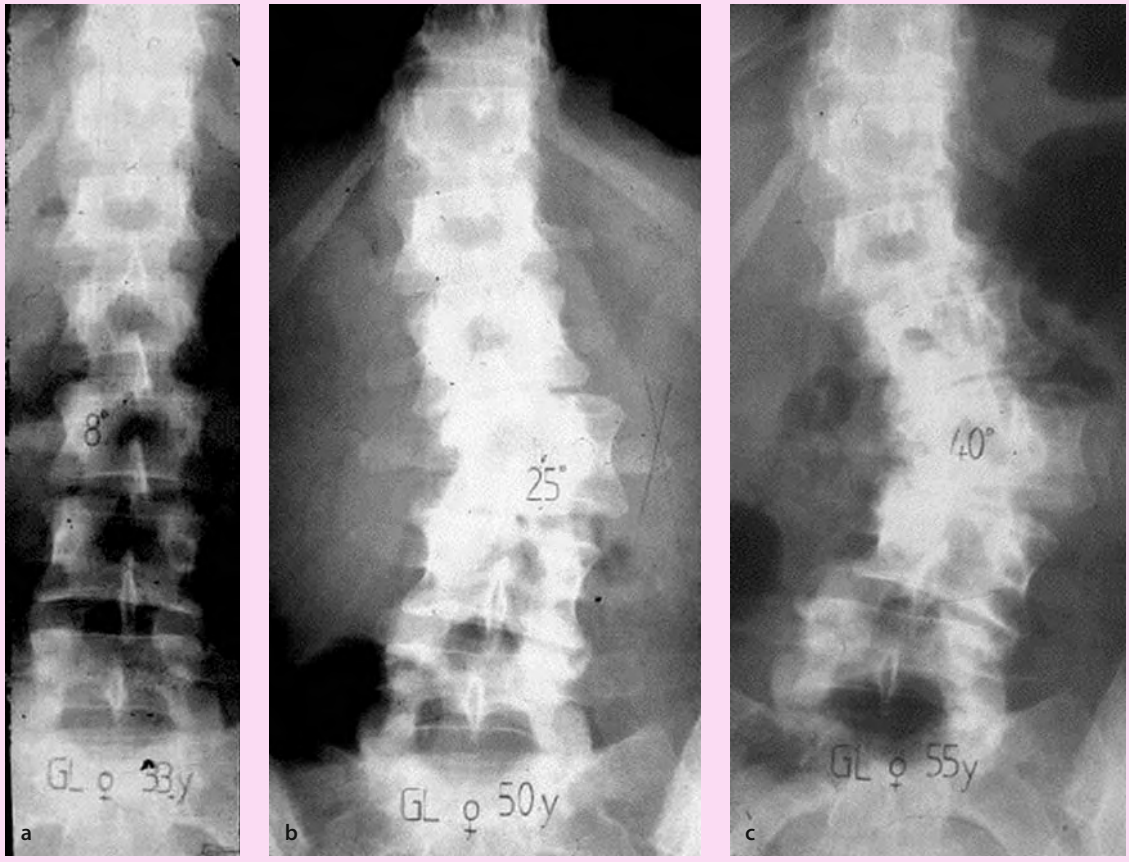


## Case Introduction

Female patient with a 22-year history of low back pain and a de novo scoliosis (primary degenerative scoliosis) exemplifying the natural history of this scoliosis type. The patient first sought medical help for low back pain at the age of 33 years. The radiograph exhibited a short left-convex lumbar scoliosis (8°), which in retrospect can be attributed to a disc degeneration of L3/4 (disc space narrowing) and an asymmetry at the L2/3 level (a). At that time, the patient was treated with NSAIDs and physiotherapy with some improvement. However, she was never really pain-free. When she was 50 years old, she had increasing back pain with radiating pain mostly into the right anterior thigh. In the meantime, the patient entered menopause, and the curve now measured a Cobb angle of 25° with a lateral translation and rotation of L3 toward the left side (b). Five years later the curve measured 40°, an average 3° curve increase per year. The curve was now clearly identifiable as a short, left-convex curve from L2–L4 (end vertebrae) (c). The overall frontal balance was still more or less in equilibrium. However, the sagittal profile converted toward a lumbar kyphosis. The patient now complained not only about difficulty of controlling back pain, but also about classical claudication symptoms when walking 400–500 m. The pain disappeared when resting. The back pain was much less when resting in bed, but increased when standing up in the vertical position. The translation/rotation of the apical vertebra L3 had also increased compared to 5 years previously. This curve demonstrates a truly progressive degenerative de novo adult scoliosis, which ended with the complete set of symptoms and signs which finally necessitate surgery. This process involves a mechanical deterioration of the lumbar spine, which expresses itself in clinical signs and symptoms related to instability, mostly axial-vertical instability with some translational component, central canal and/or foraminal neurocompression, fatigue of unbalanced paravertebral muscles and finally curve progression. The understanding of the natural history and behavior of such a primary degenerative scoliotic curve may help to make a decision for or against relatively early surgery. In the case of early surgery, the intervention may be more limited and simple, both for the patient and the surgeon.

The prevalence of degenerative scoliosis is increasing

Degenerative scoliosis seems to be becoming more frequent in an increasingly aging society for several reasons, which may include the more aggressive and precise diagnosis than was possible 20 years ago, a different perception of pain in a modern urbanized society, and the desire of a large component of our society to be active in sports and to pursue leisure activities also after retirement. It seems, how-

ever, that degenerative scoliosis is not a characteristic disease of industrialized society, since the same pathology can be observed in other, less developed societies [7].

## Pathogenesis

Primary degenerative adult scoliosis, specifically in the lumbar spine, is characterized by a quite uniform pathomorphology and pathomechanism [1]. The **asymmetric degeneration** of the disc and/or the facet joint leads to an asymmetric loading of the spinal segment and consequently of a whole spinal area. This again leads to an asymmetric deformity, for example scoliosis and/or kyphosis [6, 14]. Such a deformity again triggers asymmetric degeneration and induces **asymmetric loading**, creating a **vicious circle** (Fig. 1a). The destruction of discs, facet joints and joint capsules usually ends in some form of uni- or multisegmental sagittal and/or frontal latent or obvious instability. There may not only be a spondylolisthesis, meaning a slip in the sagittal plane, but also translational dislocations in the frontal plane or rather three-dimensionally when the instability expresses itself in a rotational dislocation [15].

Primary (de novo) degenerative scoliosis results from segmental degeneration

The biological reaction to an unstable joint or, in the case of the spine, an unstable segment, is the **formation of osteophytes** at the facet joint (spondylarthritis), and at the vertebral endplates (**spondylosis**), both contributing to the increasing narrowing of the spinal canal together with the hypertrophy and calcification of the ligamentum flavum and joint capsules, creating central and recessal spinal stenosis (Fig. 2). The pathomorphological and pathomechanical relationship directly relates to the clinical presentation of an adult degenerative scoliosis (Fig. 1b). The osteophytes of the facet joints and the spondylotic osteophytes, however, may not sufficiently stabilize a diseased spinal segment. Such a condition leads to a **dynamic**, mostly **foraminal stenosis** with radicular pain or claudication type pain, specifically when the spine is loaded vertically.

The progressive degeneration and deformity often leads to central and foraminal stenosis

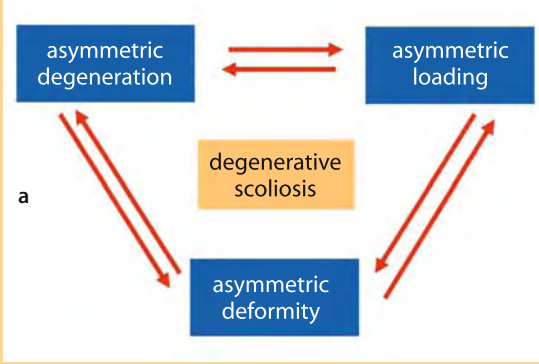


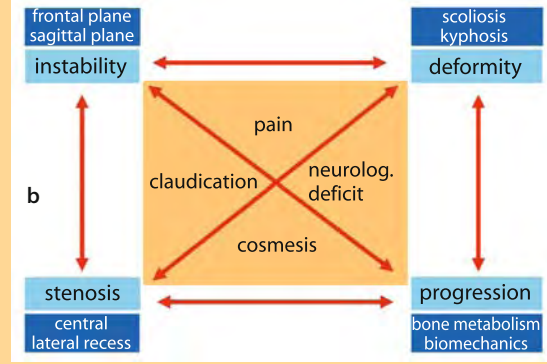


**Figure 1. Pathogenesis of degenerative scoliosis**

a Degenerative scoliosis results from a close interaction of asymmetric loading, degeneration and deformity. b The clinical symptoms are closely related to the pathomorphology.

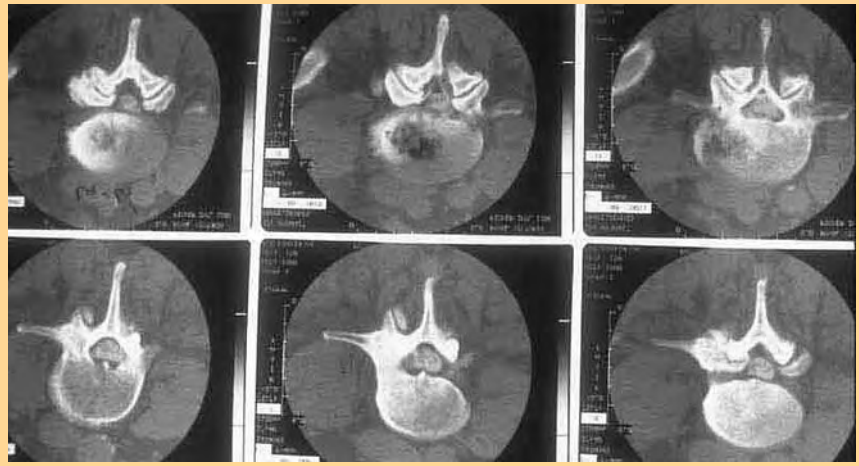

**Figure 2. Degenerative changes**

Deformity and spinal imbalance lead to secondary degeneration, i.e., facet joint arthrosis (hypertrophy), disc degeneration, spondylosis spurs and osteophytes, and calcified ligaments as a biological reaction with the goal of stabilizing the spine. As a consequence spinal stenosis develops. When decompression is performed destabilization results.

## Classification

Degenerative scoliosis forms a major part of the adult scoliosis group. This group comprises a wide spectrum of different pathologies, which may look very similar at the end-stage, when many patients are seeking help from a spine surgeon for the first time [15]. These patients usually have a long history of back pain and spinal discomfort and have undergone all the possible symptomatic treatment modalities such as exercise, acupuncture, braces and other complementary medical measures as well as pain medication.

There is no established classification system for degenerative scoliosis [1, 7]. However, the most important distinction is between primary degenerative scoliosis and secondary degenerative scoliosis (Table 1).

**Table 1. Classification of degenerative scoliosis**

| Primary (de novo) degenerative scoliosis | Secondary degenerative scoliosis |
|---|---|
| • develops de novo after skeletal maturity | • results from degenerative alterations of curves existing prior to skeletal maturity |

Classification systems or degenerative idiopathic scoliosis is inadequate to describe de novo scoliosis

Several attempts have been made to elucidate some systematic structure in this kind of pathology. A classification on the basis of the curve type, very much as in the idiopathic scoliosis classification by Lenke [21], has been proposed. This classification may be able to cover the adult idiopathic scoliosis group with secondary degeneration but is not necessarily adequate for the primary degenerative scoliosis type. Another attempt at classification has recently been presented by Schwab et al. [13, 27], who distinguished three groups based on measurements of the endplate obliquity of L3 in the frontal plane, and of the lumbar lordosis measured between the L1 and S1 superior endplates in the sagittal plane of a standard X-ray.

This is obviously a classification which can be applied solely to primary degenerative lumbar scoliosis. The **three distinct types** with increasing severity from Type 1 to Type 3 are:

- Type 1 – lordosis > 55°, L3 obliquity < 15°
- Type 2 – lordosis 35 – 55°, L3 obliquity 15 – 25°
- Type 3 – lordosis < 35°, L3 obliquity > 25°

The interesting characteristic of this classification is the attempt to correlate the objective radiological findings with the self-reported pain and disability.

We have recently proposed an etiological classification which basically distinguishes **three types**, Type 3 being subdivided into two subtypes [1]:

- **Type 1** – primary degenerative scoliosis ("de novo" form), mostly located in the lumbar or thoracolumbar spine.
- **Type 2** – progressive idiopathic scoliosis in adult life of the thoracic, thoracolumbar and/or lumbar spine. A rough distinction can be made between adult idiopathic scoliosis in patients less than 40 years of age and those aged over 40 years.
- **Type 3** – secondary degenerative scoliosis comprising:
  Subtype 3a: degeneration of secondary curves following idiopathic or other forms of scoliosis or occurring in the context of a pelvic obliquity due to a leg length discrepancy, hip pathology or a lumbosacral transitional anomaly, mostly located in the thoracolumbar, lumbar or lumbosacral spine.
  Subtype 3b: scoliosis secondary to metabolic disease (mostly osteoporosis) [18] combined with asymmetric arthritic disease and/or vertebral fractures.

There is no classification gold standard

The clinical entity of an adult degenerative scoliosis can indeed be present since childhood or adolescence and can become progressive and/or symptomatic only in adult life [5, 24], or a scoliosis may appear de novo in adult life only without any precedence in early life. In this chapter we deal predominantly with Type 1 scoliosis, partially with Type 3a and only marginally with Type 2. The chapter is not closed over the classification issue, since an ideal classification must be simple, easy to apply and imply treatment options that are designed to correlate well with the clinical picture and outcome.

## Clinical Presentation

### History

Patients with adult degenerative scoliosis seek medical help for four major reasons [1, 6, 7, 16, 23], which also present as **cardinal symptoms**:

- back pain
- claudication symptoms and/or radicular pain
- neurological deficits
- increasing deformity (curve progression)

**Cosmesis** does not have the same significance as in adolescent scoliosis; nevertheless recent studies show that the self-perception of scoliotic adult patients plays an important role in a health assessment analysis [13]. The clinical picture as outlined above can be substantially aggravated by **concomitant osteoporosis** [18].

Patients have a long history of back pain before they complain of claudication symptoms

Usually these patients have a long history of back pain and only in a second stage do they complain about leg pain, claudication symptoms and difficulty, for instance, climbing or descending stairs. Most of these patients experience pain

when in an upright position under an axial load and are more or less pain free when lying down. Most of them report loss of height over time and some patients have increased pain when turning in bed or twisting during physical activity, which relates to a certain instability of the deformed and mechanically weakened spine.

### Back Pain

Back pain is often related to instability

Back pain is the **most frequent clinical problem** of adult scoliosis, and presents itself with a multiform mosaic of symptoms. Back pain at the site of the curve can be localized either at the apex or in its concavity, and facet joint pain can be localized in the counter curve from below the curve to above the curve [32, 33]. Back pain can be combined with radicular leg pain, and can be the expression of muscular fatigue or of a real mechanical instability. Unbalanced, overloaded and stressed paravertebral back muscles may become very sore and in return will not contribute to balance the muscle play, consequently becoming part of a vicious circle. This is especially true when the lumbar curve is accompanied by the loss of lumbar lordosis [10, 15, 20]. This muscular pain is rather diffuse, is distributed over the lower back and is often permanent at the insertion of the muscle tendons at the iliac crest, sacrum, os coccyx and bony process of the spine. The back pain can be constant and non-specific, which is a bad prognostic sign regarding the treatment outcome. The pain, however, can be present only when the patient is upright, especially when standing and sitting, presenting itself as a so-called **axial pain** or only during certain movements or physical activities, pointing rather to a mechanical unstable segment or a whole spinal region. Patients often indicate that they can control their pain well when lying down flat or on their side and when the axial load is taken off the spine.

Patients often complain of axial back pain due to segmental instability

### Spinal Claudication

Claudication is the **second most important symptom** of adult degenerative scoliosis and may express itself as:

- radicular claudication
- central claudication

Central, lateral and recess stenosis are frequent

The symptoms become worse when standing or walking. The patient can have a true radicular pain due to a localized compression or root traction. The roots are compressed not necessarily on the concave side due to a narrow foramen, but **often on the convex side**, rather expressing a dynamic overstretch of the root [20, 32, 33]. There may, however, be a single or multilevel spinal stenosis which can be central or more in the lateral recess creating claudication symptoms. Root compressions can occur at the bottom of the curve or at the transition to the sacrum and can be linked to a hypermobility of an overloaded bottom segment, especially in cases of stiff curves. Short lumbosacral or lumbar curves as counter curves to long fused thoracolumbar scoliosis often show a severe spinal stenosis at the transition from the stiff upper spinal area to the lower lumbosacral area.

### Neurological Compromise

Neurological deficits occur late

Neurological deficit is the third most important clinical presentation and may include individual roots, several roots or the whole cauda equina with apparent bladder and rectal sphincter problems. An objective neurological deficit, however, is rare and when present is due to a significantly compressed space in the spinal canal with a relatively acute aggravation and decompensation. A seques-

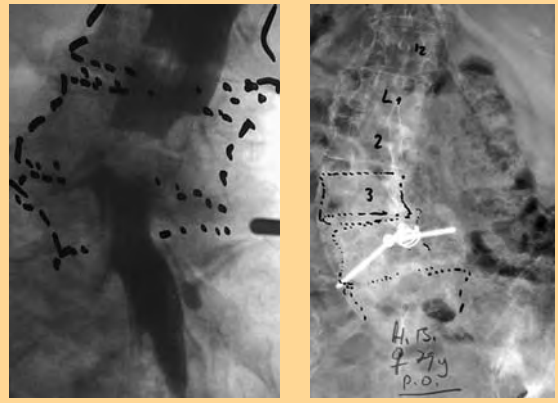

**Figure 3. Neurological compromise**

Sequestrated disc with neurological radicular deficit in a severely degenerated lumbar scoliosis in a 79-year-old frail female patient at the concave side of level L4/5. Since the decompression needed to be done within the curve close to the apex, an additional stabilization of the L4/5 joint has been done in order to avoid a possible progression of the curve and the deterioration of the neurological findings.

tered or calcified disc within the curve may be the cause of such an acute neurological deficit. It can be accentuated or only become clinically relevant due to a latent or obvious segmental instability (Fig. 3).

### Increasing Deformity

Osteoporosis accelerates curve progression

Finally, increasing deformity due to curve progression is a relevant sign of degenerative scoliosis [23, 24]. Curve progression may be an issue from the moment the curve occurs in younger age. It may, however, only become relevant when the curve has reached a certain size and/or when **osteoporotic asymmetric collapse** may contribute significantly to the curve [18]. Once a curve has reached a certain extent of curve degrees, the progression will automatically follow due to the **axial mechanical overload** of individual facet joints and/or osteoporotic vertebral bodies. The progression of the curve may well be an indication for surgical treatment. Surgeons need to be aware of the amount of aggravation which may occur when no surgery is done. The increasing age of patients should be borne in mind along with all the medical consequences which automatically increase the risk of a surgical intervention [25, 26, 29, 31]. Therefore, a surgical intervention may occasionally be indicated in order to avoid further progression and degeneration in a patient with potential medical risks.

Larger curves tend to progress faster than small curves for biomechanical reasons

## Physical Findings

The clinical examination usually easily demonstrates a patient with a deformed back or trunk once the curve has progressed beyond about 35°. **Examination** with the patient in the standing position **may reveal**:

- an oblique pelvis
- a lumbar or thoracic hump
- an unequal shoulder level
- an asymmetric lumbar triangle
- loss of lordosis (flatback)
- loss of sagittal and coronal balance

The **hump** is often already visible in the standing position but more so when the patient is bending forward. A counter rib hump is an expression of a primary or compensatory thoracic or thoracolumbar scoliosis. Severely deformed patients may stand with flexed knees to shift their anterior trunk in balance back into a position over the center of the pelvis. This out-of-balance position in the sagittal

Note sagittal and coronal imbalance

plane is due to the lumbar flat back or kyphosis. Usually, patients are still quite mobile in spite of a radiologically relatively stiff curve. The lumbar triangle is usually accentuated on the concave side and flat on the convex side. The side bending as well as flexion and extension of the lumbar curve is usually very limited in progressed curves. Neurological deficits are rare and can vary from some sensory radicular signs to paraparesis due to a complete stenosis of the spinal canal or rarely a multilevel radicular syndrome. Reflex anomalies may occur in isolation or in combination with other neurological deficits. Sometimes the distinct neurological deficit has to be correlated with the target muscles of the specific lumbar roots.

## Diagnostic Work-up

The relevant diagnostic measures in patients with degenerative scoliosis consist of both imaging studies and interventional radiological studies. Laboratory tests are only necessary as a preoperative evaluation for patients planned to undergo surgery.

### Imaging Studies

Very often the whole armentarium of imaging studies is necessary to understand the complexity of a curve and specifically, if present, the concomitant neurological signs or deficits.

#### Standard Radiographs

Full body standing radiographs are indispensable

**Whole spine X-rays** where the center of the skull and the pelvis are visible are necessary in both the frontal and the lateral planes. **Spot views** predominantly of the lumbar spine are necessary to analyze the affection by the scoliosis in the different segments. **Oblique radiographs** are helpful in exploring facet joint alterations and foramina. **Functional views** including **side bending** as well as **flexion/extension films** are necessary. Functional radiographs are better performed with the patient in the supine position than under axial load. If performed with the patient in the supine position, there is a need for the physician to attend the X-ray capture of the patient. On standard radiographs there may be clues [14, 15] as to whether a scoliosis is truly a primary degenerative scoliosis or rather a secondary degenerative scoliosis (Fig. 4). It is important to look at earlier radiographs to understand the natural history and therefore the etiology of the curve. The **sagittal contour** of the lumbar spine is important in terms of pain and outcome since curves with a loss of lordosis < 25° are usually painful and have a more complex treatment requirement [13].

Radiographs sometimes exhibit clues to the etiology of the curve (primary vs. secondary)

#### Magnetic Resonance Imaging

Magnetic resonance imaging is the imaging modality of choice to explore neural compromise and disc degeneration. **Coronal views** are very helpful in assessing neural compromise in relation to the curve. However, degenerative scoliosis is often very polymorphic with MRI due to the complex pathology, parts of which may still be difficult to understand and may leave us uncertain as to what the leading pathology is. For example, deformity may be interpreted on one of the MRI cuts as spinal stenosis since the whole deformity is not in the same plane; however, the patient has no signs of spinal stenosis at all.

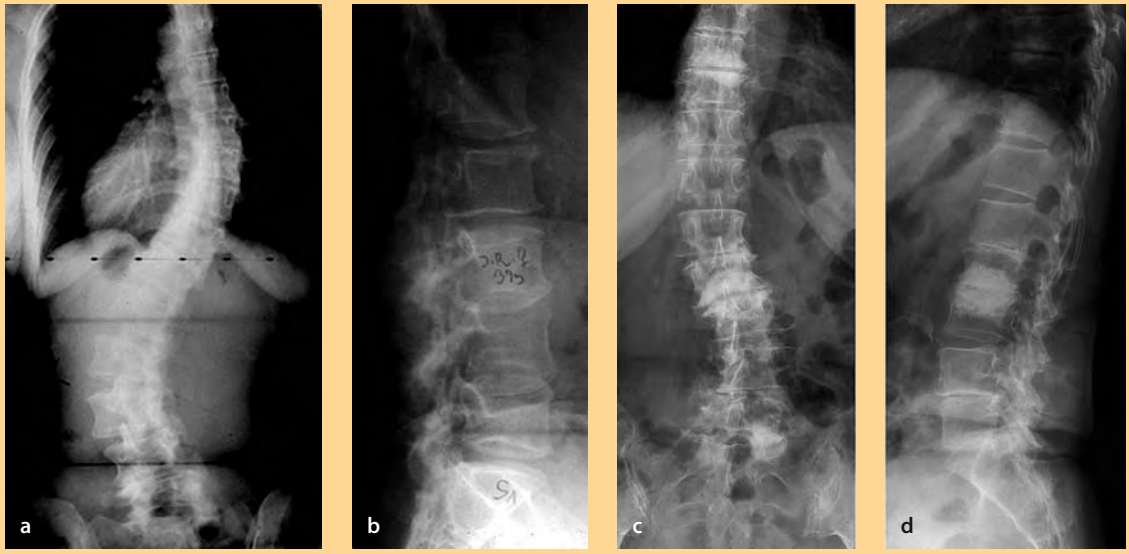


**Figure 4. Primary and secondary degenerative scoliosis**

a, b Secondary degenerative scoliosis on the basis of an idiopathic scoliosis is usually more strongly expressed, c, d less osteoporotic and longer than a primary degenerative scoliosis . In both end stages there are translational and rotational dislocations of individual vertebrae.

### Computed Tomography

**Computed tomography** with or without a **myelogram** is the diagnostic imaging method of choice in the case of diagnostic uncertainties related to the three-dimensional curve pattern, precise localization of root compressions and their correlation with clinical findings.

## Interventional Radiological Procedure

In the context of the evaluation of the pain source, **spinal injection studies** (see Chapter 10 ) are especially helpful since their findings may change the therapeutic approach [1, 20, 33]. Helpful **interventional studies** are:

- provocative discography
- facet joint blocks
- nerve root blocks
- epidural blocks

Injection studies are sometimes helpful in identifying the pain source

It is important, for instance in lumbar curves, to find out whether the pain occurs within the curve or below the main curve, or whether it usually involves L4/5 and L5/S1, or rarely whether it is above the curve at the thoracolumbar junction. Since the pain can be generated in one or several segments, it is recommended to perform the discograms or the **facet blocks** sequentially in order to isolate the really painful segment. In addition, discography can be used as a pain provocation test as well as a pain elimination test (i.e., injecting local anesthetic possibly with some steroids). The test is double positive when pain is first elicited during injection and disappears shortly after the injection. The selective use of **epidural blocks** at stenotic levels or **selective nerve root blocks** is another helpful tool to identify the level clinically relevant to the symptomatology on the one hand and as a therapeutic tool on the other hand in case surgery is not feasible or is decided to be delayed.

## Additional Diagnostic Tools

A temporary immobilization cast can reveal mechanical back pain

If, despite all of these tests, the pain remains unexplained, it may in rare cases be helpful to put on a **temporary immobilization cast** in the form of a thoracolumbar orthosis (TLO) or thoracolumbosacral orthosis (TLSO) to see whether an overall stabilization and fusion of the whole scoliotic spinal area could be beneficial for the patient, specifically in cases of an overall tendency of the spine to statically collapse.

In elderly people with degenerative scoliosis, with plain predominant symptoms of claudication, leg pain and multilevel stenotic segments in the imaging studies, **neurophysiologic studies** (see Chapter 12) may be helpful to identify the level responsible for the clinical presentation. A clear topographic diagnosis would certainly help to minimize the surgery in these patients.

**Osteodensitometry** (DEXA) is indicated whenever there is a suspicion of osteoporosis because of the implications with regard to curve progression and potential spinal fixation.

## Non-operative Treatment

The indication for or against surgery and, more specifically, the type of surgery to be performed involves complex decision-making [1]. Certainly, surgery is only an option when the non-surgical measures have no effect or do not have the prospect of any relevant long-term help.

The general objectives of treatment derive from the cardinal symptoms of degenerative scoliosis (Table 2):

**Table 2. General objectives of treatment**

| | |
|---|---|
| • relieve pain | • reverse neurological deficit |
| • eliminate spinal claudication | • prevent curve progression |

The **non-surgical treatment options** basically consist of:

- non-steroid anti-inflammatory drugs (NSAIDs)
- muscular relaxation
- pain medication
- muscle exercises

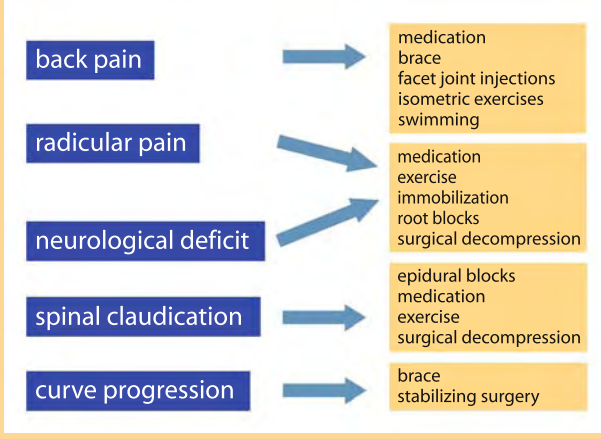


**Figure 5. Therapeutic options**

- gentle traction (in selected cases)
- spinal injection studies
- orthosis

Manipulations and physical activation should be avoided because they may increase the pain. Therapeutic epidural and selective nerve root blocks as well as facet joint blocks may help to control the pain temporarily. Sometimes, a well-fitted brace to support the painful spine area may be necessary [23].

Manipulations should be avoided

In order to plan the most promising therapeutic approach for each patient, a clear understanding of the prominent symptoms or clinical signs is mandatory. The symptoms and clinical signs can be addressed by various therapeutic treatment modalities (Fig. 5).

## Operative Treatment

A surgical approach to degenerative adult scoliosis is obviously complex in terms of decision-making, e.g., ascertaining the surgical indication and choosing the patient and the procedure appropriately.

The decision about treatment approach and type of surgery is complex

The technical difficulties, however, are equally relevant. The aggravating factors and difficulties with this type of surgery are manifold. **Curve magnitude** and **age** of the patient are, for instance, significant predictors of curve flexibility [2, 4, 29, 31]. The understanding of this association allows the treatment options over time to be better addressed. The **possible surgical technique** can be divided into:

- posterior procedures
- anterior procedures
- combined procedures

In all these procedures, a simple decompression or stabilization with pedicle screws [2, 4, 8, 22, 28] can be done alone or in combination. In some cases, additional correction may be considered, either by clearly defined osteotomies or by sequential segmental corrections through instrumentation. This is particularly of interest in combined sagittal/frontal rigid deformities.

The goals of the various treatments **depending on curve type** are summarized in Table 3.

**Table 3. Surgical treatment options**

| Scoliosis type | Decompression | Correction | Posterior stabilization and fusion | Anterior stabilization and fusion |
|---|---|---|---|---|
| Primary (de novo) degenerative scoliosis (lumbar, thoracolumbar) | • rarely laminectomy, often necessary by laminotomy, enlargement of lateral recess and foramen | • not a primary objective (depends on pain pattern and spinal balance) | • usually posterior stabilization and posterolateral fusion sufficient. Occasionally selectively combined with PLIF in younger patients. | • usually not necessary |
| Secondary lumbar or thoracolumbar degenerative scoliosis (idiopathic curves) | • often necessary in elderly patients with a long-lasting history, not so much in younger patients | • in younger patients correction possible cave thoracic curve: overall balance mandatory | • usually posterior stabilization and posterolateral fusion sufficient. Occasionally PLIF in younger patients | • usually not necessary. As stand alone procedure possible in younger patients |
| Progressing idiopathic curve in patients younger than 40 years (thoracolumbar curves) | • rarely necessary | • younger patients: correction and balanced spine desired. Combined anterior/posterior release often necessary | • posterior pedicle fixation posterolateral fusion, pedicle based | • anterior stand alone surgery at the thoracolumbar junction possible |

## Decompression Procedure

Decompression alone may result in curve compression

The type of decompression used depends on the extent of necessary decompression. There is the option to decompress microsurgically the lateral recess and/or the foramen or to perform a more extensive canal enlargement by laminotomy, hemilaminectomy, or laminectomy to address the crucial compressive lesion. If two adjacent segments need to be decompressed, a laminectomy can be considered, specifically when a surgical stabilization is foreseen. Whether maintenance of the integrity of the vertebral arches is necessary in a stabilized and fused spine is not clear, but it may prevent scarring of the dural sac.

Besides the direct decompression as mentioned above, there is the possibility of **indirect decompression** occurring on correction of deformity and realignment of the spine. The older the patient and the longer lasting the degenerative scoliosis is, the more carefully this concept has to be applied. Adhesion of the dural sac due to scarring between the dura and the hypertrophied ligamentum flavum and facet joint capsules, and sometimes directly to the bone, may induce traction and/or compression of neural elements with consecutive neurological deficit. The benefits of correction of the curve therefore have to be carefully weighed against the direct decompression. The idea that osteophytes and bony spurs may disappear over time in a stabilized and fused segment may leave the patient with sometimes persistent symptoms for quite a long time. The recommendation is to explore the crucial roots after a corrective measure by small fenestration of the spinal canal in order not to miss a possible persistent compression or traction of a neural element.

The pros and cons of direct of indirect decompressions must be carefully weighed

## Correction Procedures

Sagittal balance is most important

Whether or not a degenerative scoliosis should be corrected remains a crucial and complex question. The treatment of a degenerative scoliosis has different goals than the treatment of adolescent scoliosis. While in the latter the goal is prevention of curve progression and cosmetic improvement, degenerative scoliosis requires the relief of back and leg as well as claudication symptoms. Correction has to address spinal imbalance, which is mainly in the sagittal plane [1].

Whether a degenerative scoliosis should be corrected or not, **depends on several factors**:

- age
- cardinal symptoms
- coronal balance
- sagittal alignment
- curve rigidity
- rigidity of the adjacent spine

### Age

The need for curve correction decreases with age

The older the patient, the less necessity there is to correct the deformity. Correction may induce diffuse back pain in elderly patients, which may be due to the age-related inability to adapt to a new muscle balance. A correction may be necessary if there is a clear frontal imbalance. The correction may, however, rather consist in a localized osteotomy than in an overall correction of the curve. An additional sagittal imbalance needs to be corrected in most cases of chronic back pain in the context of a degenerative deformity [13, 20]. The correction has to reach the plumb line falling from the projection of the outer auricular canal onto the femoral head.

### Cardinal Symptoms and Imbalance

A curve correction is indicated in patients with chronic back pain without a localized pathomorphology (e.g., painful facet joints) and a clear coronally and sagittally unbalanced spine. In younger patients, treatment consists of an overall curve correction. A **localized osteotomy** is more appropriate in elderly patients.

Curve correction is indicated in the presence of significant coronal or sagittal imbalance

### Curve Rigidity

In a completely rigid curve, specifically in elderly patients, a correction usually is not necessary except if the back pain is related to the imbalance of the curve. The correction of a rigid curve may be achieved either by a localized corrective osteotomy (transpedicular reduction osteotomy) preferentially in elderly patients, or alternatively by a multilevel release and mobilization of the facet joints with osteotomies in the joints and an overall correction through reduction of the mobilized spine to a pre-contoured rod. A rigid thoracolumbar curve >70° usually needs a combined approach [19, 20] (Case Study 1).

Rigid severe curves require anterior release

### Rigidity of the Adjacent Spine

In the case of a lumbar or thoracolumbar degenerative curve which is adjacent to a rigid (fused or ankylosed) idiopathic thoracic curve, any correction of the lumbar spine has to be well thought through. Because of the rigid thoracic curve, the spine may fall completely out of balance following a lumbar correction. In younger patients rarely it may be necessary to add a mobilizing osteotomy to the upper curve to effect a necessary lumbar correction.

Postoperative coronal imbalance is a risk

## Surgical Techniques

The armentarium of surgical techniques for the correction of degenerative scoliosis consists of:

- posterior release
- anterior release
- wedge osteotomies
- transpedicular reduction osteotomies

**Posterior release** can be achieved through mobilization and osteotomies of the facet joints. This procedure may be accompanied by an **anterior release** when significant osteophytes and intervertebral disc calcifications exist. If posterior release and facet joint osteotomies are not sufficient, **wedge osteotomies** of the arches (Fig. 6) may provide further correction. For a significant localized correction, a bilateral or unilateral **transpedicular reduction osteotomy** (Fig. 7) may be necessary at one, two or three levels. The correction of the lordosis in severe flat back syndrome can best be achieved by a pedicular reduction osteotomy when an anterior and posterior release is not sufficient.

In all the above-mentioned methods a posterior **pedicle-based instrumentation** is necessary [2, 8, 12, 22, 32]. The correction is done by contouring the rod in the desired shape and by pulling and/or pushing the pedicle anchorage toward the rod. One possibility is to adapt the rod to the curve – in the lumbar spine on the convex side – and to rotate the rod, which is inserted in the pedicle anchorage (screws or pedicle-based hook screws) into the lordosis. An alternative is to bend and adapt the rod in situ to the best possible contour.

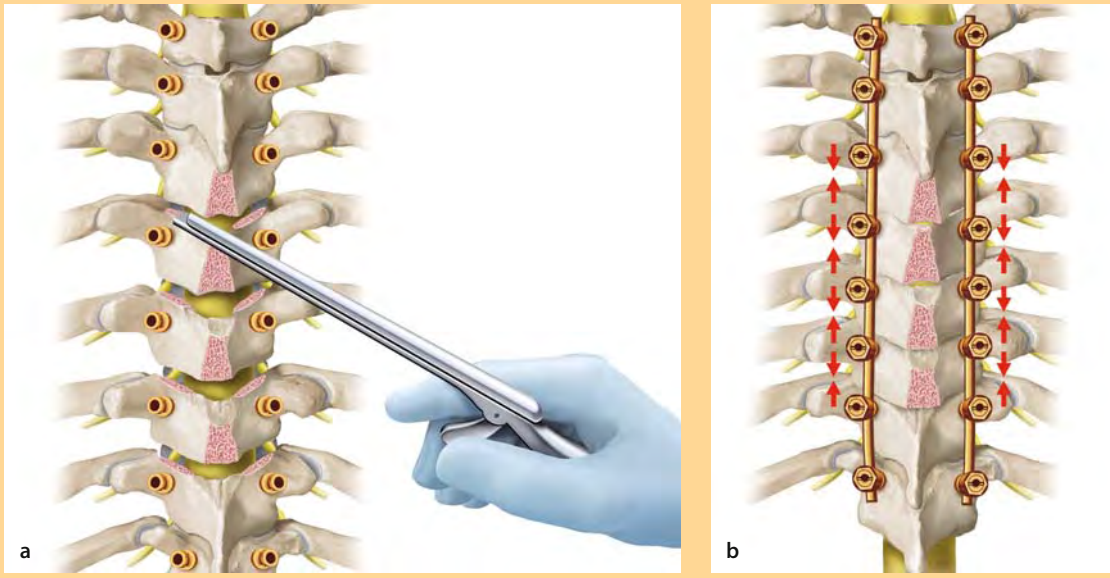


**Figure 6. Smith-Peterson arch osteotomy**

This technique creates lordosis and is usually applied to one or multiple levels. a The interspinous ligament and the adjoining spinous process are resected with a rongeur and the interlaminar ligamentum flavum is removed in the midline, from where lateral osteotomies are carried out bilaterally, through the facet joints in the direction of the interspinal foramina. b These osteotomies are directed laterocranially, at an angle of 30–40 degrees to the horizontal. The desired slot width of 5–7 mm is obtained by using a suitably wide rongeur. If there is a lateral overhang, the osteotomies are made slightly larger on the convex side. The osteotomy gap is closed by a tension banding pedicular fixation one or two levels above or below. With one single osteotomy approximately 10 degrees of correction can be achieved.

Unilateral cage insertion facilitates segmental correction

A further methodology to achieve specifically short distance correction in the lumbar spine without performing osteotomies consists of complete mobilization of a deformed segment with complete removal of the disc through either an anterior or a posterior approach and using a **unilateral cage** or **tricortical bone graft** by either an anterior lumbar interbody fusion (**ALIF**) or a posterior lumbar interbody fusion (**PLIF**) procedure.

In the case of a uniquely posterior procedure, a posterolateral intertransverse fusion is done by autologous bone graft, either collected from laminar bone during the decompression procedure and/or the iliac crest, or by an allogeneic bone graft from a bone bank or a combination of autologous/allogeneic bone, which can still be augmented by, e.g., granular tricalciumphosphate.

An isolated anterior release and stabilization is seldom applicable and may work in younger patients at the thoracolumbar junction by sparing segments from inclusion into the fusion. In cases where anterior surgery is done, it is mostly a combined front and back procedure [19].

Avoid fusion to the sacrum in young patients

Debate continues on the indications for a **lumbosacral fusion**. Only general recommendations can be given [9, 12, 30]. In young patients with secondary degenerative scoliosis, it is better to omit L5/S1 from fusion whenever possible in order to prevent iliosacral joint degeneration or an early hip problem. It is also usually preferable to stop at L4 in a lumbar curve whenever possible. However, a fusion to the L5 vertebra is necessary when the condition of the L4/5 facet joint is poor (Case Study 1). This obviously leads to an overload of the L5/S1 segment. However, it is difficult to predict the time when the secondary facet arthritis will occur, and possibly a good sagittal alignment will delay this substantially. The

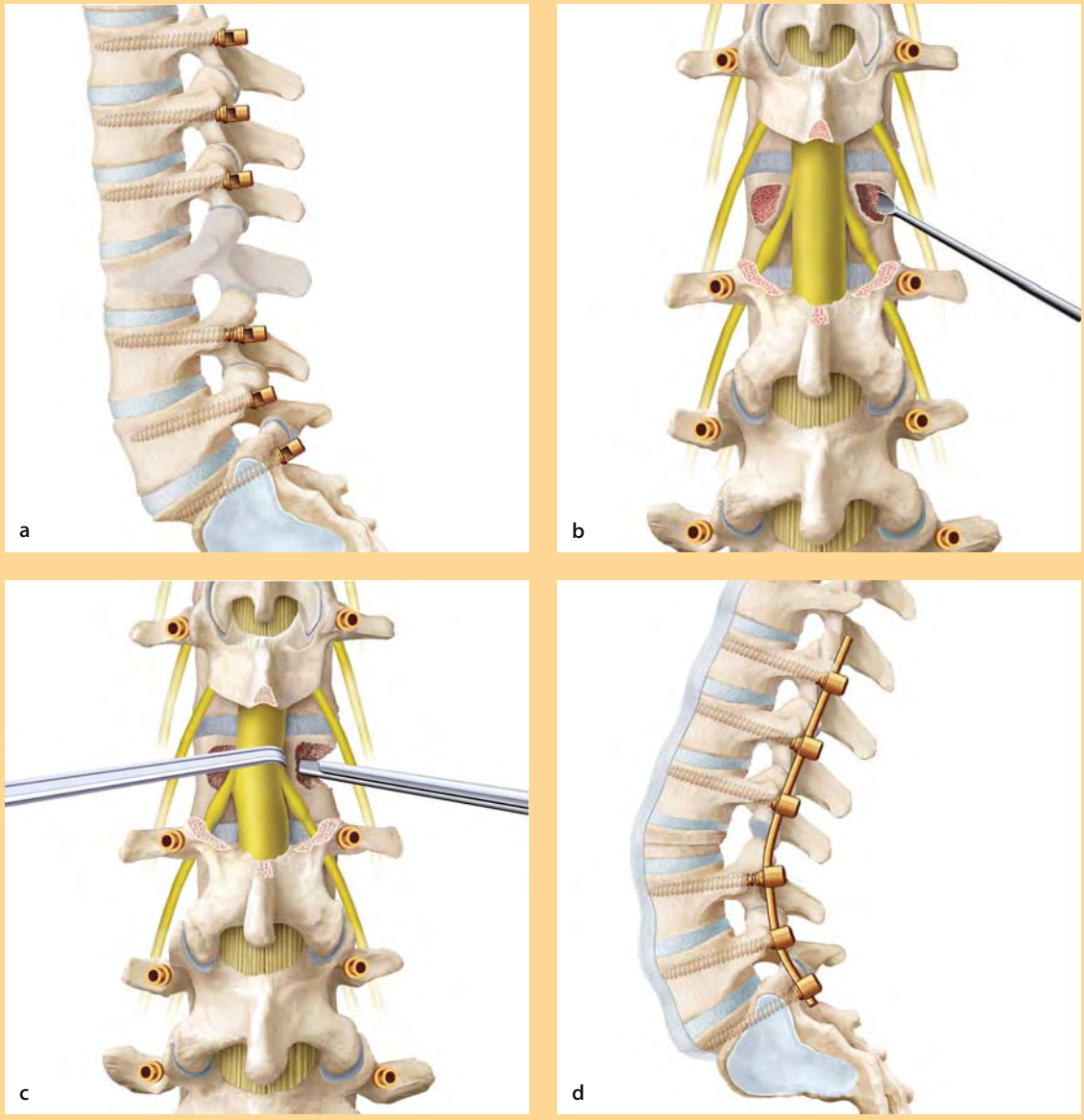


**Figure 7. Pedicle reduction osteotomy**

a The osteotomy is started by removing the posterior arch including the facet joints until only the pedicle stump at the transition to the posterior wall of the vertebral body is left with also the transverse process removed. b The pedicle stump is then excavated continuously into the vertebral body, which is emptied by means of an "eggshell" procedure. c The remaining posterior bridge between the two wholes of the pedicle stumps is then resected by a large Kerrison rongeur. d The created "empty" wedge is then closed under compression by means of a posterior pedicle-based tension banding system.

patient, however, needs to be informed that secondary surgery may become necessary later [9, 12, 30]. When **fusion to the sacrum** cannot be avoided, it is important to add an **interbody fusion** to decrease the risk of a non-union. This can either be done by an anterior (ALIF) or a posterior (PLIF) approach (Case Study 2).

Add an interbody fusion when fusion to the sacrum is intended

a

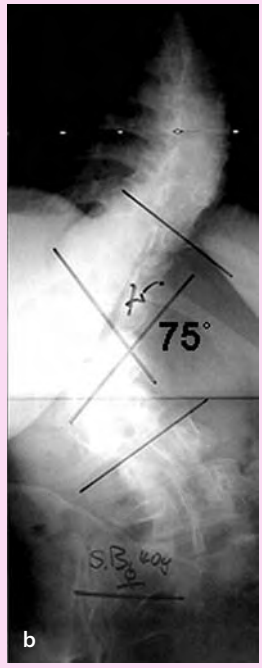


b

c

d

## Case Study 1

A young female teacher presented with progressive idiopathic scoliosis. At the age of 35 years the curve measured 62° (a). Three years later the curve had progressed to 75° (b). With curve progression, the patient developed incapacitating back and leg pain and was unable to work. The major curve progression occurred during pregnancy. All conservative treatment failed and the patient decided to undergo surgery. A left bending functional radiograph shows only some correction of the curve (c). The patient presented with lumbar kyphosis which needed to be addressed (d). Combined anterior/posterior surgery was performed. First, an anterior release through a minimally invasive thoracophrenicolumbotomy from the left side was done and the intervertebral disc spaces of T12/L1, L1/L2, L2/L3 and L3/L4 were released and filled with a hybrid of corticocancellous bone combined with beta-tricalciumphosphate (β-TCP) for an anterior fusion. Second, for posterior release and facet joint osteotomies, correction was done in conjunction with reconstruction of the lumbar lordosis and a posterolateral fusion from T9 to L5. Radiographs at 18 months follow-up show restoration of lumbar lordosis and coronal balance (e, f).

e

f

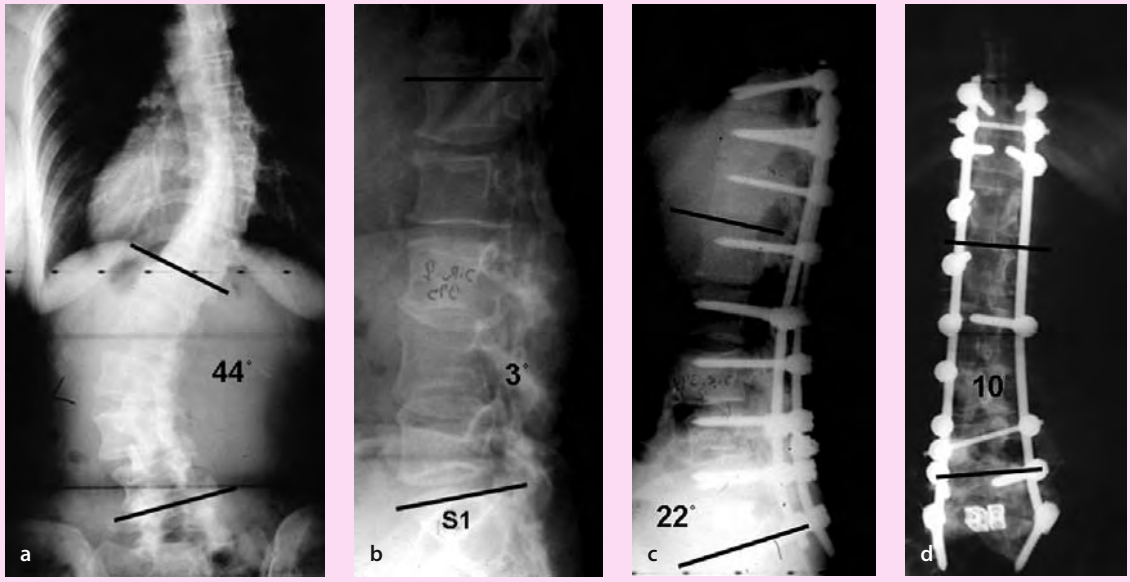


## Case Study 2

A 39-year-old female patient presented with incapacitating back pain due to a progression of adult idiopathic scoliosis (Type 2) (a). There was no evidence of claudication symptoms or radicular pain. Non-operative treatment did not result in persistent pain relief. The preoperative lateral radiograph shows a significant loss of lumbar lordosis (3°) (b). The postoperative radiographs show a restoration of lordosis to 22° and circumferential fusion with PLIF at the lumbosacral junction in order to avoid non-union. Frontal correction of the scoliosis was satisfactory (c, d).

## Recapitulation

**Epidemiology.** Primary degenerative scoliosis develops **de novo** after skeletal maturity and needs to be distinguished from the **secondary degenerative changes** of a curve already present at the end of growth. The **prevalence** of scoliosis in patients older than 50 years is **about 6 %** including both types. Degenerative scoliosis is more prevalent in males than in females. The overall prevalence is increasing due to the aging population.

**Pathogenesis.** Primary degenerative scoliosis results from **segmental instability** and degeneration of intervertebral discs and facet joints, often resulting in anterior and lateral displacement. The body counteracts the instability by a thickening of the ligaments, lumbar spondylosis and facet joint hypertrophy causing central and foraminal stenosis. The clinical symptoms closely relate to the pathomorphological alterations. **Secondary degenerative scoliosis** results from **asymmetric loading and dysbalance** of the spine.

**Clinical presentation.** The cardinal symptoms are **back pain, claudication symptoms, radicular pain,** neurological deficits and increasing deformity. Back pain is often related to spinal instability. Cosmetic aspects are not a predominant complaint in contrast to adolescent scoliosis. Claudication symptoms are very frequent but neurological deficits appear late. The clinical assessment must focus on the **sagittal and coronal balance** as well as on the sagittal profile (flat back, thoracolumbar or lumbar kyphosis). Concomitant osteoporosis must be assessed.

**Diagnostic work-up.** Standing whole body anterior and posterior radiographs are indispensable for a clear understanding of the curve and the etiology. A differentiation of primary and secondary degenerative scoliosis is difficult in advanced stages because spinal rotation and lateral displacement can be present in both types. MRI is the imaging modality of choice to show disc degeneration and neural compromise. CT and combination with myelography are sometimes necessary to better demonstrate the three-dimensional character of the curve and neural impingement. Provocative discography

as well as facet joints, nerve root and epidural blocks often allow the identification of the source of the pain. Neurophysiologic studies and osteodensitometry are helpful in selected cases.

**Treatment.** Non-operative treatment consists of NSAIDs, physiotherapy, spinal injection studies and orthosis. However, conservative treatment cannot prevent progression of the curve. The **general goals of surgery** derive from the cardinal symptoms: resolution of back pain and claudication symptoms, reversal of neurological deficits, and correction of deformity or prevention of curve progression. In elderly patients, decompression may suffice if the main symptom is spinal stenosis. Care must be taken **not to further destabilize** the spine. The correction procedures consist of anterior, posterior or combined interventions. The choice of the technique depends on age, cardinal symptoms, coronal balance, sagittal alignment, curve rigidity, and rigidity of the adjacent spine. In elderly patients, posterior release is sufficient to realign the spine. A **severely rigid curve** in young individuals usually requires a combined anterior/posterior release. When anterior and/or posterior release is insufficient, **wedge osteotomies or transpedicular reduction osteotomies** are indicated to rebalance the spine. Posterior pedicle screw fixation is the standard fixation technique. Posterolateral fusion with autograft, allograft or bone substitutes accompanies spinal instrumentation in almost all cases. Only in young individuals with short segmental curves is anterior release and instrumented fusion advisable. **Sagittal and coronal rebalancing** as well as reshaping the sagittal contours (flat back) are crucial for a good outcome. Fusion to the sacrum should be avoided whenever possible in young individuals. However, if **fusion to the sacrum** cannot be avoided, an **interbody fusion** is mandatory to reduce the risk of non-union.

## Key Articles

**Aebi M (2005) The adult scoliosis. Eur Spine J 14(10):925–948**
A recent review article which allows for further reading.

**Bridwell KH (1996) Where to stop the fusion distally in adult scoliosis: L4, L5, or the sacrum? Instr Course Lect 45:101–7**
This articles highlights the many aspects which must be weighed and discussed with the patient before deciding on a long fusion down to the middle or distal lumbar spine. Outcome of surgery is crucially dependent on how well the different aspects are addressed by surgery.

**Grubb SA, Lipscomb HJ, Coonrad RW (1988) Degenerative adult onset scoliosis. Spine 13:241–245**
The authors reviewed 21 patients with the diagnosis of degenerative scoliosis. This review shows that patients can de novo develop progressive scoliosis and loss of lumbar lordosis with a resulting flat back deformity. These patients commonly present in the 6th decade of life with predominant claudication symptoms but often lack the classic feature of relief in a sitting posture. The number of male and female patients was approximately equal. Roentgenogram findings show a high angle deformity over a short number of spinal segments and an absence of bony features associated with idiopathic scoliosis such as lateral vertebral wedging and alterations of the lamina.

**Grubb SA, Lipscomb HJ (1992) Diagnostic findings in painful adult scoliosis. Spine 17(5):518–527**
Fifty-five adults with painful scoliosis were evaluated with regard to diagnostic findings. The curves were 49% adult degenerative onset and 44% idiopathic. The older degenerative patients had myelographic defects most commonly within the primary curve and multiple abnormal, not necessarily painful, discs throughout the lumbar spine on discography. The idiopathic group had myelographic defects most commonly in a compensatory lumbar or lumbosacral curve. On discography, all idiopathic patients had at least one abnormal, painful disc, and 88% had their pain reproduced. Pain-producing pathology was frequently identified in areas that would not have been included in the fusion area according to accepted rules for treatment of idiopathic scoliosis.

## Key Articles

**Swank S, Lonstein JE, Moe JH, Winter RB, Bradford DS (1981) Surgical treatment of adult scoliosis. A review of two hundred and twenty-two cases. J Bone Joint Surg Am 63:268 – 87**
Classical case series which predominantly deals with secondary degenerative scoliosis.

**Ponseti IV (1968) The pathogenesis of adult scoliosis. In: Zorab PA (ed) Proceedings of Second Symposium on Scoliosis Causation. E & S Livingstone, Edinburgh**
A comprehensive treatise on the pathogenesis of adult scoliosis by one of the pioneers of scoliosis surgery.

## References


1. Aebi M (2005) The adult scoliosis. Eur Spine J 14(10):925 – 948
2. Aebi M (1988) Correction of degenerative scoliosis of the lumbar spine. A preliminary report. Clin Orthop Related Res 232:80 – 86
3. Albert TJ, Purtill J, Mesa J, McIntosh T, Balderston RA (1995) Study design: Health outcome assessment before and after adult deformity surgery. A prospective study. Spine 20: 2002 – 2004; discussion p. 2005
4. Ali RM, Boachie-Adjei O, Rawlins BA (2003) Functional and radiographic outcomes after surgery for adult scoliosis using third-generation instrumentation techniques. Spine 28(11): 1163 – 1169
5. Ascani E, Bartolozzi P, Logroscino CA, Marchetti PG, Ponte A, Savini R, Travaglini F, Binazzi R, Di Silvestre M (1986) Natural history of untreated idiopathic scoliosis after skeletal maturity. Spine 11(8):784 – 789
6. Benner B, Ehni G (1979) Degenerative lumbar scoliosis. Spine 4:548
7. Boachie-Adjei O, Gupta MC (1999) Adult scoliosis + deformity. AAOS Instructional Course Lectures 48(39):377 – 391
8. Bradford DS, Tay BK, Hu SS (1999) Adult scoliosis: surgical indications, operative management, complications and outcome. Spine 24:2617 – 2629
9. Bridwell KH (1996) Where to stop the fusion distally in adult scoliosis: L4, L5, or the sacrum? AAOS Instructional Course Lectures 45:101 – 107
10. Deviren V, Berven S, Kleinstueck F, Antinnes J, Smith JA, Hu SS (2002) Predictors of flexibility and pain patterns in thoracolumbar and lumbar idiopathic scoliosis. Spine 27(21): 2346 – 2349
11. Deyo RA, Cherkin DC, Loeser JD, Bigos SJ, Ciol MA (1992) Morbidity and mortality in association with operations on the lumbar spine. The influence of age, diagnosis, and procedure. J Bone Joint Surg Am 74(4):536 – 543
12. Edwards CC, Bridwell KH, Patel A, Rinella AS, Jung Kim Y, Berra A, Della Rocca GJ, Lenke LG (2003) Thoracolumbar deformity arthrodesis to L5 in adults: The fate of the L5–S1 disc. Spine 28(18):2122 – 2131
13. Glassman SD, Bridwell K, Dimar JR, Horton W, Berven S, Schwab F (2005) The impact of positive sagittal balance in adult spinal deformity. Spine 30(18):2024 – 2029
14. Grubb SA, Lipscomb HJ, Coonrad RW (1988) Degenerative adult onset scoliosis. Spine 13: 241 – 245
15. Grubb SA, Lipscomb HJ (1992) Diagnostic findings in painful adult scoliosis. Spine 17(5): 518 – 527
16. Grubb SA, Lipscomb HJ, Suh PB (1994) Results of surgical treatment of painful adult scoliosis. Spine 19:1619 – 1627
17. Guillaumat M (1993) Les scolioses lombaires de l'adulte. In: SOFCOT, Chirurgie du Rachis de l'Adulte. Expansion Scientifique Française, Paris, pp 199 – 222
18. Healy J, Lane J (1985) Structural scoliosis in osteoporotic women. Clin Orthop 195:216
19. Johnson JR, Holt RT (1988) Combined use of anterior and posterior surgery for adult scoliosis. Orthop Clin North Am 19:361 – 370
20. Kostuik JP (1980) Recent advances in the treatment of painful adult scoliosis. Clin Orthop 147:238 – 252
21. Lenke LG, Edwards CC, Bridwell KH (2003) The Lenke classification of adolescent idiopathic scoliosis: How it organizes curve patterns as a template to perform selective fusions of the spine. Spine 28(20S):S199–S207
22. Marchesi DG, Aebi M (1992) Pedicle fixation devices in the treatment of adult lumbar scoliosis. Spine 17:S304 – 309
23. Ogilvie JW (1992) Adult scoliosis: evaluation and nonsurgical treatment. Instructional Course Lectures 41:251 – 255

24. Ponseti IV (1968) The pathogenesis of adult scoliosis. In: Zorab PA (eds) Proceedings of second symposium on scoliosis causation. E & Livingstone, Edinburgh
25. Reindl R, Steffen T, Cohen L, Aebi M (2003) Elective lumbar spinal decompression in the elderly: is it a high-risk operation? Can J Surg 46(1):43 – 46
26. Rinella A, Bridwell K, Kim Y, Rudzki J, Edwards C, Roh M, Lenke L, Berra A (2004) Late complications of adult idiopathic scoliosis primary fusions to L4 and above: The effect of age and distal fusion level. Spine 29(3):318 – 325
27. Schwab F, el-Fegoun AB, Gamez L, Goodman H, Farcy JP (2005) A lumbar classification of scoliosis in the adult patient: preliminary approach. Spine 30 (14):1670 – 1673
28. Simmons ED Jr, Kowalski JM, Simmons EH (1993) The results of surgical treatment for adult scoliosis. Spine 18:718 – 724
29. Sponseller PD, Cohen MS, Nachemson AL, Hall JE, Wohl ME (1987) Results of surgical treatment of adults with idiopathic scoliosis. J Bone Joint Surg Am 69(5):667 – 675
30. Swank S, Lonstein JE, Moe JH, Winter RB, Bradford DS (1981) Surgical treatment of adult scoliosis. A review of two hundred and twenty-two cases. J Bone Joint Surg 63A:268 – 287
31. Takahashi S, Delécrin J, Passuti N (2002) Surgical treatment of idiopathic scoliosis in adults: An age-related analysis of outcome. Spine 27(16):1742 – 1748
32. Tribus CB (2003) Degenerative lumbar scoliosis: evaluation and management. J Am Acad Orthop Surg 11(3):174 – 183
33. Winter RB, Lonstein JE, Denis F (1988) Pain patterns in adult scoliosis. Orthop Clin North Am 19:339 – 345

# 27 Spondylolisthesis

Clayton N. Kraft, Rüdiger Krauspe

## Core Messages

- ✔ Spondylolisthesis is the end result of various distinct causes
- ✔ Spondylolisthesis is a disorder of the entire lumbosacral junction and spondylolysis is a result of a stress fracture
- ✔ Not every radiographically evident slippage causes clinical symptoms
- ✔ Standard radiographs are the imaging modality of choice for a first assessment
- ✔ Oblique radiographs may demonstrate a pars defect not visible on the lateral view
- ✔ In the presence of neurologic deficit, MRI is the imaging modality of choice
- ✔ Multi-slice CT with image reformation detects pars defects not visible on standard radiographs
- ✔ Treatment rationale is based on the etiology of the disorder, degree of slippage, intensity of pain, and neurologic symptoms
- ✔ The vast majority of patients with spondylolisthesis can be treated non-operatively
- ✔ The primary aim of all surgical options is to achieve stability, prevent progression and decompress neurologic structures
- ✔ The surgical technique (posterolateral fusion in situ, instrumentation and posterolateral fusion with or without interbody fusion) depends on the surgeon's familiarity with the approach as well as on the deformity
- ✔ Reduction of low-grade spondylolisthesis is not the primary aim of surgery but may be necessary to decompress foraminal stenosis
- ✔ There is continuing debate on the subject of reduction of high-grade spondylolisthesis
- ✔ The L5 nerve root is at high risk when reducing high-grade spondylolisthesis because of a tethering effect
- ✔ Anterior buttressing (interbody fusion) is needed when a slipped vertebra is reduced and/or distracted
- ✔ Frequent complications after spondylolisthesis surgery are non-union and postoperative nerve root compromise

## Epidemiology

**Spondylolysis** is not the only cause of spondylolisthesis, only the most intensively studied one. Lumbar spondylolysis occurs in the general population at the rate of around 5% [36, 49]. Based on data published by Fredrickson et al. [24], the rate of spondylolysis is less than 4.4% for children under the age of 6 years and approximately 6% for adults. According to Grobler and Wiltse [27], Caucasian males are significantly more frequently affected than black females, indicating that there is a gender as well as an ethnic factor underlying the condition. This presumption is underlined by a recent study by Whitesides et al. [115], who were able to demonstrate that in different ethnic groups there is a genetically determined difference in the upper sacral tilt, which again is associated with the occurrence of pars defects.

There is a gender and ethnic factor to spondylolysis and spondylolisthesis

Numerous studies have shown that young athletes engaged in strenuous training in sports that incorporate intensive hyperextension and rotation of the lumbar spine have a predisposition to spondylolysis and subsequent spondylolis-

Sports with intensive hyperextension and rotation of the spine may cause pars defects

**Case Introduction**

Thirty-six-year-old patient with developmental spondylolisthesis L5/S1 Meyerding Grade IV. The patient initially consulted a GP with low-back pain and was treated with a brace and further conservative measures moderately successfully over a period of 2 years. Sciatica, the beginning of neurologic deficit in the form of numbness in the left leg as well as mild vesical incontinence on sneezing and coughing led to presentation in our clinic. Neurologic assessment, conventional radiographs (a), and MRI (b) led to the diagnosis. Posterior lumbar interbody fusion (PLIF) with placement of two PEEK cages filled with autologous spongiosa was subsequently performed as a one-step procedure. An improvement of spinal realignment from Meyerding Grade IV to Meyerding Grade I–II (c) was achieved. Postoperatively the patient had a transitory L5 weakness, which quickly improved and subsided completely after 10 days without revision surgery. One year after surgery, realignment is still held and there is bony bridging between L5 and S1 (d).

thesis. In comparison to their age group, female adolescent gymnasts have a nearly four times increased probability of stress fractures of the pars interarticularis [40]. A further example is professional bowlers and cricket players who show stress lesions of the pars on the non-dominant side [84].

Even high-grade spondylolisthesis can remain asymptomatic

Because even severe forms of spondylolisthesis can clinically remain completely asymptomatic, the true incidence of the condition in the general population remains a matter of speculation. For **developmental spondylolisthesis**, most studies report rates of around 3 %, though depending on the ethnic group assessed significantly higher incidences of up to 50 % have been reported [9, 36, 42, 49, 90]. The **incidence of spondylolisthesis** in adult white males is reported to be 5 – 6 % and in females 2 – 3 % [86]. According to Roche and Rowe [86], the most frequent localization is L5 – S1 in 82 %, followed by L4 – L5 in 11.3 %, L3 – L4 in 0.5 % and L2 – L3 in less than 0.5 %. Of the acquired slippages, the degenerative type is the most frequent one. **Degenerative spondylolisthesis** is common in individuals older than 50 years [85]. In a radiographic study, Valkenburg and Haanen [112] showed that approximately 10 % of females over 60 years of age had degenerative spondylolisthesis. Based on autopsy data, Farfan [23] found a 4.1 % incidence for the condition. Previous studies have indicated that the condition occurs four times more frequently in women and is most commonly seen at L4 – L5 [58].

The incidence is 5 – 6 % in males and 2 – 3 % in females

## Pathogenesis

For a better understanding, it is worthwhile very briefly summarizing the morphology and biomechanics of the lumbar spine and lumbosacral joint. Put simply, the spine is a two-column structure, with the anterior column consisting of vertebral bodies and discs and the posterior column composed of bony and ligamentous structures. The sacrum acts like a bony shelf and thereby supports the proximal spinal column. The **orientation of the sacrum** plays a pivotal role in the development of spondylolisthesis and is influenced by pelvic rotation, hip extension and lordosis [95]. Normal sacral inclination varies between 40° and 60° and the relationships between sacral slope, pelvic inclination and lumbar lordosis are dependent on the pelvic incidence, a parameter which is unique to every individual [22]. A **high pelvic incidence** results in high shear forces at the lumbosacral junction and has been shown to be associated with an increased degree of slippage [17, 39, 95]. Without the osteoligamentous complex of the posterior column, with the pars interarticularis acting as a bolt uniting the superior and inferior facets and the pedicle acting as a bridge to the ventral column, spinal stability would be severely compromised. To ensure that spinal stability is maintained during gait or other complex dynamic functions, an intricate interaction between the neuromuscular system, the bony and ligamentous structures as well as the viscoelastic discs is needed [30].

High-grade isthmic spondylolisthesis is a kyphotic disorder of the lumbosacral junction

Motion is passively restricted by the ligaments and posterior facets and, depending on their orientation and size, the flexion-extension, axial rotation and lateral bending of each individual spinal segment is defined. Resistance to torsion depends on the integrity of facet joints and resistance to lateral bending is dependent on the integrity of the disc and the iliolumbar ligaments. Resistance to flexion is primarily dependent on the capsular ligaments of the facet joints. The disc, interspinous ligaments as well as the ligamentum flavum are only secondary flexion restraints [1]. Loads applied to the lumbosacral spine are shared between the disc and the posterior articulations [2]. While compression is resisted by the disc, shear is resisted by the disc and posterior elements as well as the stabilizing muscles [18, 110]. The effective distribution of loads shared by the posterior elements and the intervertebral disc varies with posture [75]. When failure of the pars interarticularis occurs, which is usually due to a stress induced fatigue fracture in adolescence [120], the disc is confronted with excessive shear, flexional and rotational forces and this dissociation of the ventral from the dorsal column may subsequently result in slippage, since the anulus fibrosus cannot resist the shear forces.

Spondylolysis is a result of a stress fracture of the pars interarticularis

With this very simplified morphological and biomechanical model, an attempt has been made to communicate that pathologies of the pelvis, the sacral plateau or the vertebrae themselves may be the cause of localized or even global spinal imbalance which can ultimately result in the entity of spondylolisthesis.

Spondylolisthesis is a biomechanical disorder of the entire lumbosacral junction

## Classification

Due to the complex underlying pathologies which may lead to spondylolisthesis, numerous classifications have been propagated over the years [54, 56, 77, 78, 118, 119]. Of these, the two classification systems that have remained relevant are those of Wiltse and Rothman [118] and Marchetti and Bartolozzi [56] as they are applicable to all forms of lumbar spondylolisthesis and are simultaneously clinically relevant in terms of treatment decision [30]. While the former is an anatomic classification (Table 1), the latter is etiology based (Table 2) with two main

Common classification systems are those of Wiltse/Rothmann and Marchetti/Bartolozzi

**Table 1.** Anatomic classification (according to Wiltse and Rothman [118])

| Types | Description |
|---|---|
| **I. Dysplastic** | In this type congenital abnormalities of the upper sacrum or the arch of L5 permit the olisthesis to occur |
| **II. Isthmic** | The lesion is in the pars interarticularis. Three subtypes can be recognized:<br>**A.** Lytic failure<br>**B.** Elongated but intact pars<br>**C.** Acute fracture |
| **III. Degenerative** | Due to long-standing intersegmental instability |
| **IV. Traumatic** | Due to fracture in other areas of the bony hook than the pars |
| **V. Pathological** | There is generalized or localized bone disease |

**Table 2.** Etiology-based classification (according to Marchetti and Bartolozzi [56])

| Developmental | Acquired | |
|---|---|---|
| High dysplastic<br>• with lysis<br>• with elongation | Traumatic<br>• acute fracture<br>• stress fracture | Pathologic<br>• local<br>• systemic |
| Low dysplastic<br>• with lysis<br>• with elongation | Postsurgical<br>• direct<br>• indirect | Degenerative<br>• primary<br>• secondary |

categories differentiating between primary developmental deficiencies and secondary acquired spondylolisthesis. The Marchetti classification is almost self-explanatory and due to the avoidance of confusing terminology in our opinion seems to be more up to date.

In contrast to **Wiltse's**, the **Marchetti classification** avoids the term "isthmic" and does not differentiate between developmental and acquired forms of slippage. Both types may have defects of the pars interarticularis, yet they present different pathologic processes [30]. Also, the term "congenital" is incorrectly used for some subtypes which develop at a later age and are not present at birth. Despite these shortcomings, the Wiltse categorization is without doubt the most frequently used and surgeons treating spinal deformities should be familiar with it. It was modified in 1989 by Wiltse and Rothmann [119] to include an extra subtype of spondylolisthesis resulting from prior surgery.

## Clinical Presentation

Patients with spondylolysis or spondylolisthesis may be clinically asymptomatic

Patients with spondylolysis or spondylolisthesis may be asymptomatic and never present for medical evaluation. Those that seek medical advice do so with a variety of symptoms. By carefully scrutinizing the information yielded by the patient, an experienced physician can draw conclusions about the underlying pathophysiologic mechanisms.

### History

A thorough history should be taken with regard to the **pain history**:

- onset
- intensity
- quality of back pain

The severity of the deformity does not always correlate with the magnitude of pain. Generally, high-grade spondylolisthesis is rarely diagnosed in adults, as many become apparent in adolescence and are then surgically managed. Patients presenting with Grade IV spondylolisthesis may be asymptomatic even though their posture is markedly distorted. There are reports of almost asymptomatic massive slippages with good sagittal balance in adults and evidence of bony stabilization by spontaneous fusion [33].

Severity of spondylolisthesis does not correlate with symptoms

Occasionally, an asymptomatic adult may develop back or radicular pain as a result of proximal lumbar disc pathology, bringing the spondylolisthesis to light for the first time. Particularly in these cases, care must be taken to ensure that the correct diagnosis is made as the spine surgeon's attention is easily distracted by the obvious deformity present.

Make sure that the radiographically obvious pathology is the pain source

The **cardinal symptoms** are [70]:

- mechanical low back pain (worse on motion, better on rest)
- leg pain (sciatica)

Mechanical back pain is thought to be due to **abnormal distribution of load** across the vertebral endplate following disc degeneration [63, 64]. Despite conventional beliefs, the hypothesis that degenerative spondylolisthesis is associated with increased motion remains to be proven. Some studies even suggest the contrary [61, 97]. The bandwidth and intensity of pain is variable and may be of sudden onset, chronic or intermittent. Patients may note aggravation with position transition such as changing from sitting to standing [88] and are often completely pain free on rest. The **leg pain** can be distinguished as:

Mechanical LBP may result from abnormal load distribution

- referred
- radicular

This depends on the presence of a true neural (mostly foraminal) compromise.

Additional but **less frequent symptoms** are:

- discogenic back pain (worse on sitting and forward bending)
- facet joint pain (worse on standing and backward bending)
- numbness and tingling
- motor weakness
- claudication symptoms

**Discogenic back pain** can result from secondary disc degeneration in the olisthetic or adjacent segment [37, 98]. Subsequent degenerative changes of the bone and ligamentous complex lead to spur formation, hypertrophy, subchondral sclerosis and destruction of the facet joints causing **facet joint pain** [98]. **Neurogenic claudication** is produced by spinal stenosis secondary to slippage and hypertrophy of the ligamentum flavum and facet joints encroaching into the spinal canal. Pain along the buttocks and both legs may occur with standing or walking and is frequently associated with dysesthesia, numbness or weakness of the legs.

Discogenic, facet-joint and neurogenic, referred pain may coexist in spondylolisthesis

In **children,** the findings are very variable. In a large collective of 415 patients, Lafond [45] found that only approximately one-quarter of patients with spondylolysis or spondylolisthesis experienced complaints before 20 years of age, but only 9 % sought medical attention during childhood or adolescence. In children, most high-grade developmental spondylolisthesis develops significant slippage during the adolescent growth period [33, 51], and this is usually when symptoms occur [36].

Most high-grade spondylolistheses become apparent during adolescence

Several risk factors for this **progression** such as age, sex, spina bifida and dysplasia have been identified [12]. Back pain in young children and adolescents always raises suspicion of an underlying spondylolysis. Adolescents with symp-

tomatic high-grade spondylolisthesis often have sciatic pain that can develop into a sciatic crisis known as:

- **Phalen-Dixon sign**

Young patients may present with a sciatic crisis known as the "Phalen-Dixon sign"

This includes sciatic pain, vertical sacrum and pelvis, lumbosacral kyphosis, tight hamstrings, and an unusual pelvic waddling gait [33, 51]. This is caused by compression of the cauda equina and subsequent spasm of the ischiocrural muscle group. Irritation of the L5 and S1 nerve root explains sciatica.

## Physical Findings

Patients should very carefully be neurologically assessed

Physical examination should be performed to distinguish referred from radicular symptoms, to document spinal sagittal alignment and spinal mobility and to establish the presence of any neurologic deficits. Particularly, the sensory and motor function needs to be checked. In the light of medicolegal issues, it seems prudent to document these findings very precisely or even refer the patient to a neurologist to document the findings.

Depending on the extent of slippage, **children and adolescents** may present with:

- hyperlordosis of the lumbar spine
- sagittal malalignment (lumbosacral step-off)
- trunk deviation (Case Study 2)
- flexed knee position
- tight hamstrings
- paraspinal muscle spasm
- gait disturbance (in high-grade spondylolisthesis)
- Lasègue's sign
- sensorimotor deficits
- bowel and bladder dysfunction (very rare)

Since scoliosis can be observed in conjunction with spondylolisthesis, trunk deviation and back asymmetry must be searched for.

In **adults and elderly patients**, the physical findings often vary from those of children and rather depend on secondary segmental degeneration. Physical examination may even be unremarkable. However, **frequent findings** are:

- tight hamstrings
- sensorimotor deficits
- pain on backward bending and rotation (often facet joint pain)
- pain on forward bending (often discogenic pain)
- pain on extension from the forward bent position
- limitation of walking distance

Pain in adults with spondylolisthesis is frequently due to secondary segmental degeneration

Pain provocation on specific movements can indicate the source of the pain (e.g. facet joint or discogenic pain). However, these findings are variable and the actual prediction of the pain source is not very reliable. Yet, these signs provide a hint as to which structures should be further explored with spinal injections.

## Differential Diagnosis

Patient radiographs and clinical presentation need to be closely correlated

Degenerative spondylolisthesis may be an asymptomatic roentgenographic finding [98]. Belfi et al. [7] demonstrated a 5.7 % prevalence of spondylolysis and a 3.1 % prevalence of spondylolisthesis in asymptomatic patients. Radiographs should therefore not be overinterpreted, as numerous spinal pathologies can give rise to back and/or leg pain. Similar symptoms as found in spondylolisthesis can

also be induced by spinal stenosis, central disc herniations or scoliotic deformities. Osteoarthritis of the hip is found in about 15 % of patients with degenerative spondylolisthesis and commonly radiates to the anterior thigh and thus mimics an L3 or L4 radiculopathy [5]. Peripheral vascular disease is common in the elderly and may cause very similar symptoms to spinal claudication. Diabetic neuropathy can usually be clinically differentiated from a painful radiculopathy. As with all spinal pathologies, radiographs should be scrutinized for signs of spondylodiscitis or primary/metastatic tumor disease.

Degenerative spondylolisthesis and hip joint OA coincide in about 15 % of cases

**Syndromes** which are **associated with spondylolisthesis** are:

- neurofibromatosis I [16]
- Marfan syndrome [99, 122]
- Tricho-rhino-phalangeal syndrome [103]
- Ehlers-Danlos syndrome [76]
- myelomeningocele [101]

Spondylolisthesis associated with abnormal bone and/or soft tissue constraints is rare and reports on these remain mostly anecdotal. Despite this, they should be pointed out because they can occur at unusual anatomic sites and, depending on the pathogenesis, may cause neurogenic injury as they can be high grade even with an intact neural arch [53]. Metastatic and primary bone tumors involving the spine are usually located in the vertebral body, and may of course cause significant structural weakening of the bone or supporting soft tissue of the dorsal column, with subsequent slippage of varying degrees. Less obvious are pathophysiological mechanisms based on a systemic bone disease. Several studies have shown that spondylolisthesis is seen in a significant number of women with osteoporosis [107, 113, 114]. Interestingly, approximately 1/3 of the slips they identified were posterior. Appropriate treatment of these patients, who more often than not have concomitant massive degenerative changes, will depend on the amount of slippage and symptomatology as well as the neurologic findings. The usual methods of decompression, stabilization and fusion will be indicated [53]. A further, though far rarer, example is osteogenesis imperfecta, which may lead to an elongation of pedicles or pars, and due to static moments and gravity severe slippage can occur [32, 52].

## Diagnostic Work-up

### Imaging

#### Standard Radiographs

**Conventional** anteroposterior and lateral radiographs should be performed as an initial assessment. In high-grade spondylolisthesis, the slipped vertebra contours a shape on the anteroposterior radiograph similar to an "inverted Napoleon's hat" (Fig. 1a). Very often the pars defect is already visible on the lateral view (Fig. 1b). If a slippage or pars defect is not clearly visible, oblique (45° angled) radiographs are helpful (Fig. 1c). In case of a pars defect, the "Scottie dog" wears a collar (Fig. 1d).

Search for "Scottie dog" with a collar on oblique radiographs

**Functional radiographs** may give valuable information concerning spontaneous repositioning of a slip, which may be useful in planning surgery. However, functional views have failed to reliably demonstrate an instability [25] and the motion within an olisthetic segment can even be less than in a normal segment.

A simple and easily applicable grading of the spondylolisthesis is the grading system according to **Meyerding** [65]. The original grading included four grades. However, it has become international convention that completely slipped vertebrae (spondyloptosis) are defined as Grade V (Fig. 2).

Meyerding's grading of slippage is widely used

**Figure 1. Radiographic findings**

a On the anteroposterior radiograph it appears that there are only four lumbar vertebrae, but L5 has slipped in front of S1 (spondyloptosis) and its contour resembles an "inverted Napoleon's hat". b Standard lateral radiograph showing a developmental (isthmic) spondylolisthesis L5/S1 Meyerding Grade II with a clearly visible pars defect. c Oblique radiograph showing a pars defect at the level of L4 (*arrows*). d Schematic drawing of the so-called "Scottie dog". The pars defect shows up as a "collar".

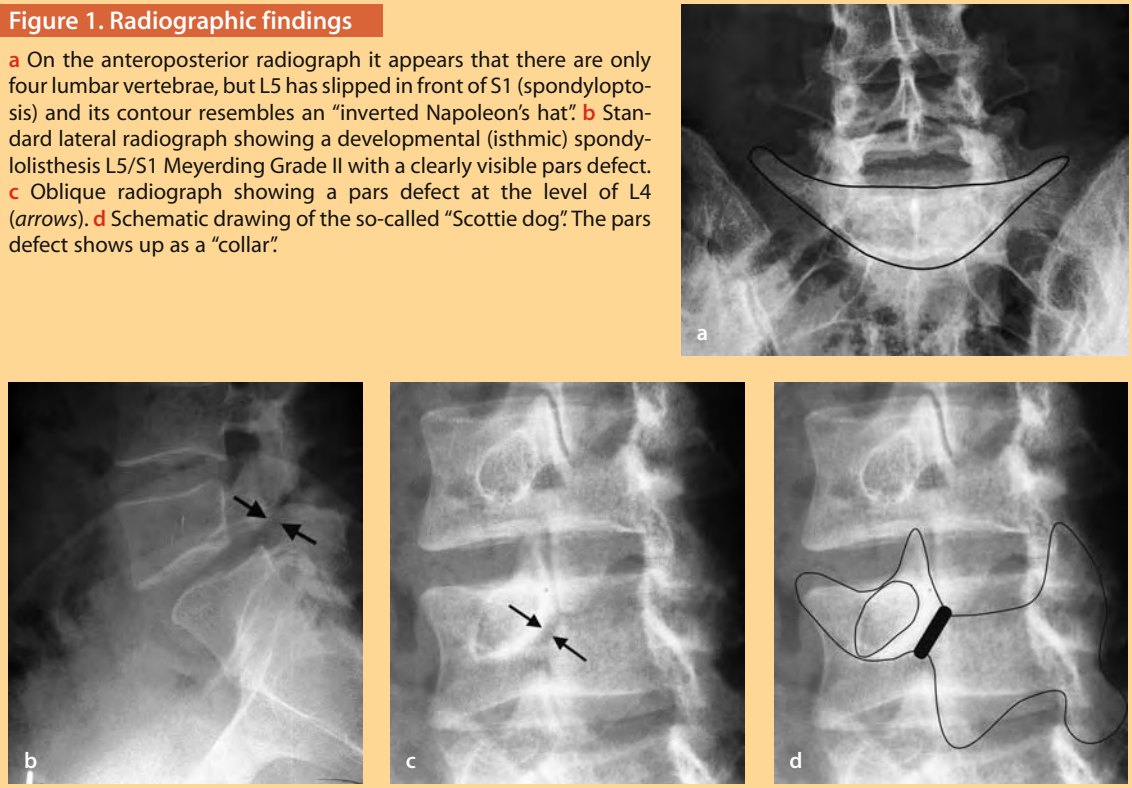


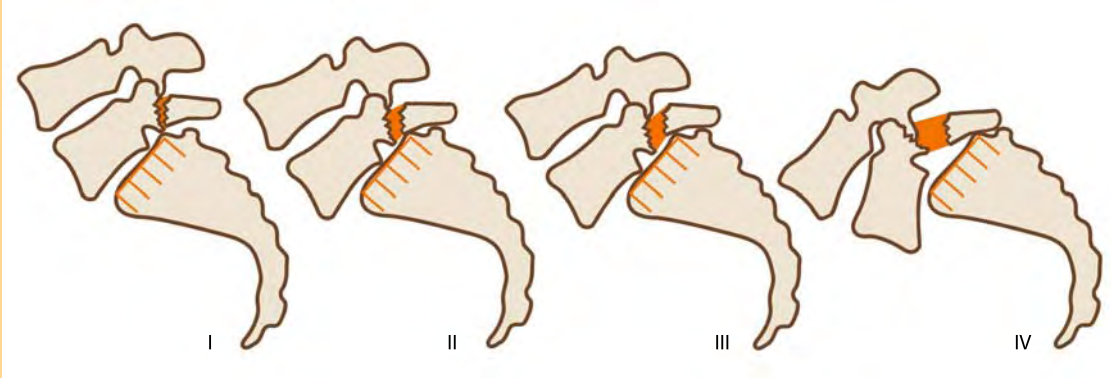


**Figure 2. Meyerding grading of spondylolisthesis**

The anteroposterior diameter of the sacrum is separated into quartiles. Slippage within the first quartile is graded as Grade I, etc., up to the fourth quartile, where it is Grade IV. Spondyloptosis is classified as Grade V.

Various measurements have been advocated to closely describe the normal anatomy of the lumbosacral junction (Fig. 3a) [12, 44, 121]. The most **important measurements** are:

- percent of anterior displacement (Fig. 3b) according to Taillard [108]
- slip angle (Fig. 3c) according to Boxall et al. [12]
- percent of rounding of top of sacrum (Fig. 3d)

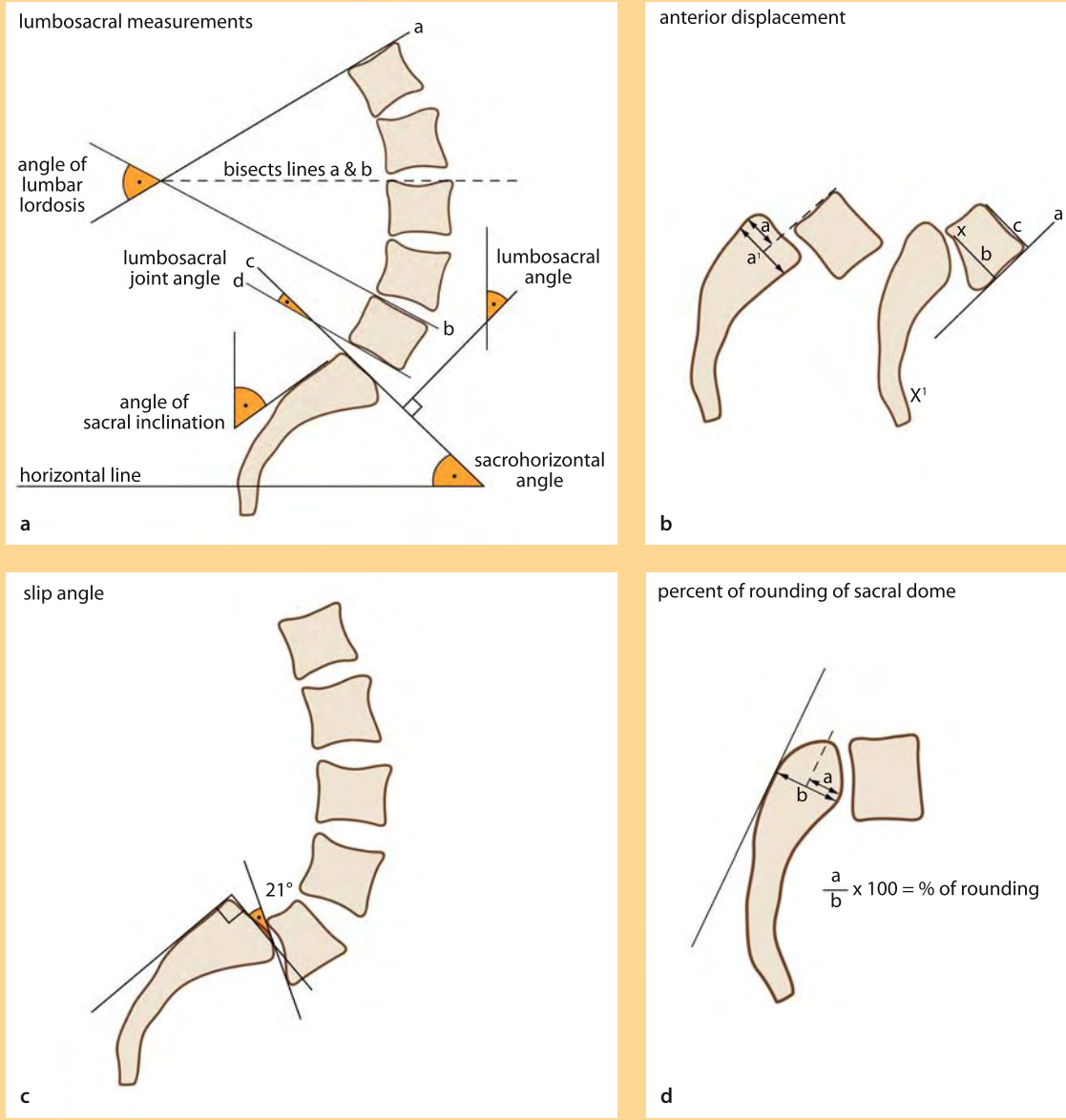


**Figure 3. Measurements of spondylolisthesis**

a The angle between a line across the cranial border of S1 and the horizontal plane comprises the sacrohorizontal angle. The lumbosacral angle is found by first defining the longitudinal axis of the lumbar spine, i.e. the perpendicular line to the bisector of the lumbosacral angle. The sacrohorizontal angle is formed by this line and the longitudinal axis of S1 (perpendicular line to the cranial border of S1). b The percent anterior slippage is defined as a percentage of the anteroposterior diameter of S1 according to Taillard. c The slip angle is defined by a line along the inferior border of S1 and a line perpendicular to the longitudinal axis of the sacrum. d The rounding of the sacral dome is expressed as the relation of the maximum anteroposterior diameter of the sacrum to the sacral dome [12, 121].

The latter three measurements allow an estimation of the risk of slip progression. A high slip angle in conjunction with a rounded sacrum increases the risk of a slip progression in children.

A high slip angle indicates progression risk

### Bone Scans

Bone scans are particularly useful in children and adolescents

According to Willburger [116], bone scans are particularly valuable in children and adolescents as they allow the differentiation between acute (fresh fracture) and chronic pars defects. This has clinical implications insofar that there is a good chance of successful conservative management of a fresh pars defect or imminent stress fracture, while older lesions usually do not heal with non-operative management. In adults, where acute lesions are rarely found, the sensitivity of a bone scan is poor [81].

### Computed Tomography

CT is of particular value if surgery is planned

By means of CT, an excellent assessment of bony anatomy can be made and with evaluation of the pars interarticularis imperative information concerning the type of spondylolisthesis can be gathered. Normally, the usual gantry is angled perpendicularly to the pars defect increasing the risk of overlooking a pars defect. It is therefore recommended to angle the gantry parallel to the pars interarticularis, i.e. perform a so-called reversed gantry CT (Case Study 1) or use multi-slice CT with image reformation. However, this technique is not necessary with multi-slice CT, which allows reformation of the images in the desired plane. CT scans can demonstrate a pars defect as well as facet hypertrophy and the pedicle anatomy (size, trajectory), which is of importance if surgery is planned.

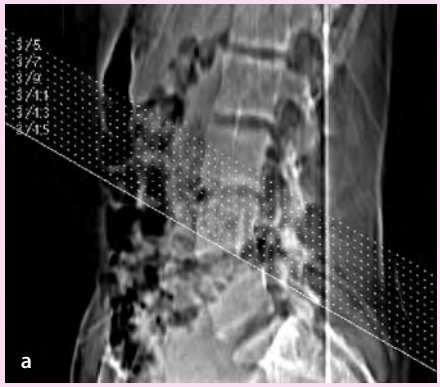


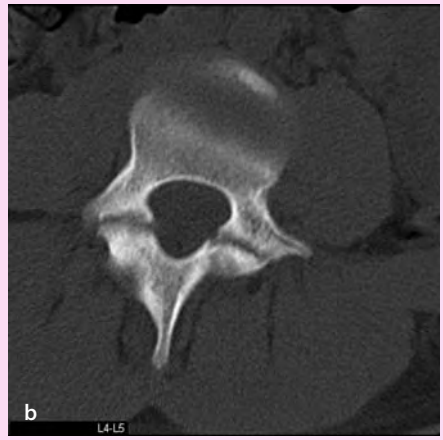





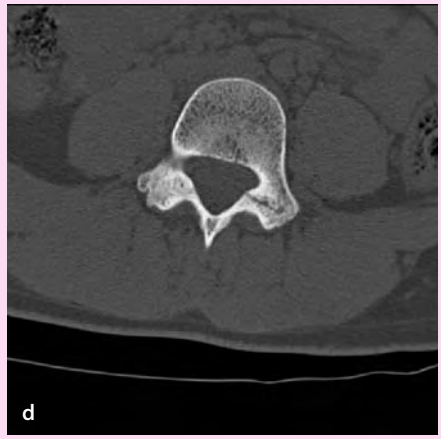


**Case Study 1**

A 14-year-old female presented with acute severe back pain worse on motion with tight hamstrings. Bilateral spondylolysis L4/5 was diagnosed only after a CT scan using the reversed gantry technique (a, b) was performed. A bone scan demonstrated an uptake at the location of the lysis on both sides indicating an acute fracture (not shown). Conservative treatment with a lumbar brace treatment including the right thigh for 8 weeks was started (c). Pain subsided very rapidly. At 4 months, the patient was symptom free. A control CT scan at 1 year postoperatively demonstrated healing of the acute pars fracture (d). The patient was symptom free and regained all desired activities. (Courtesy of University Hospital Balgrist).

**Figure 4. MRI characteristics of spondylolisthesis**

Isthmic spondylolisthesis Grade II at the level of L5/S1. **a** The T2-weighted image demonstrates the pseudo disc herniation (*black arrow*), endplate (Modic) changes Type II (*arrowheads*) and a hyperintense zone (annular tear) in the L4/5 disc (*white arrow*). **b** The parasagittal T1-weighted image demonstrates the severe foraminal stenosis with compression of the exiting L5 nerve root (*arrow*). **c** The T2-weighted axial image demonstrates mild to moderate facet joint osteoarthritis at the L4/5 level

Placement of pedicle screws can be difficult when **pedicles are dysplastic** and CT is therefore helpful for preoperative planning. CT scans may also be useful in determining which cases warrant decompression in addition to fusion [59]. Sagittal reconstructions are helpful for exploring the adaptive changes within the olisthetic vertebrae and their subadjacent vertebrae such as the erosion and rounding off of the sacral dome in lumbosacral spondylolisthesis [44].

CT is helpful for preoperative planning

### Magnetic Resonance Imaging

MRI easily allows the depiction of a spondylolisthesis but it is sometimes difficult to exactly localize the lysis. For the further diagnostic assessment, MRI is the method of choice. **Characteristic findings** in patients with spondylolisthesis are (Fig. 4):

If neurologic structures are compromised, MRI is the imaging modality of choice

- olisthetic vertebra (Fig. 4a)
- foraminal stenosis (Fig. 4b)
- pseudo disc herniation (Fig. 4a)
- cauda compression
- disc degeneration in the olisthetic and superior segment (Fig. 4a)
- hyperintense zone (HIZ) in the anulus (annular tears) (Fig. 4a)
- endplate abnormalities (Modic changes) (Fig. 4a)
- facet joint osteoarthritis (upper adjacent level) (Fig. 4c)
- tethered cord (very rare)

## Invasive Imaging Studies

### Provocative Discography

This invasive method is in our opinion only justified if surgery is planned. The slipped vertebra often causes a secondary degeneration of the upper adjacent intervertebral disc. In cases with mild disc degeneration, the question arises whether the upper level should be included. In this case, provocative discography (see Chapter 10) can be helpful in deciding whether the upper disc level is painful and should therefore be included in the fusion.

### Nerve Root Block

A nerve root block can be helpful in deciding equivocal cases of neural compression and radiculopathy (see Chapter 10). Particularly in degenerative spondylolisthesis, a nerve root block can be also used to support non-operative treatment.

### Functional Myelography

CT myelography has been surpassed by MRI for the vast majority of indications. However, it is helpful in cases with:

- contraindications for MRI (e.g. pacemaker)
- functional stenosis
- postoperative (iatrogenic) spondylolisthesis

Particularly in postoperative spondylolisthesis, myelography and postmyelo-CT are valuable

Myelography alone is of limited use. Because a complete block of contrast fluid is occasionally found, the degree of pathology, especially of nerve root compression, is not adequately visualized. Without doubt there is the advantage of envisaging the implications of lumbar flexion/extension for the spinal canal (Fig. 5), yet in our opinion the invasive method only has true value if a consecutive CT myelography is performed. In cases where a postoperative spondylolisthesis is suspected (Wiltse Type IV), we routinely perform myelography and myelo-CT. This enables us to determine the degree of instability as well as the amount of postoperative scarring, which is important for planning surgery.

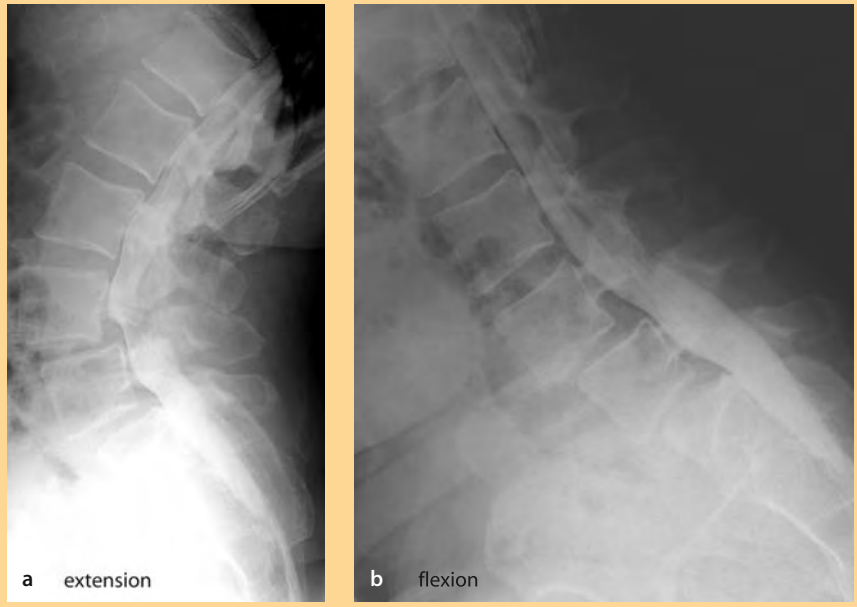


**Figure 5. Functional myelography**

a, b Functional myelography of an unstable spondylolisthesis demonstrating a narrowing of the spinal canal in extension at the level of L4/5 compared to flexion.

## Non-operative Treatment

In the management of spondylolisthesis, the spine specialist needs to take into account various important aspects which will crucially influence the treatment decision and modality (Table 3):

**Table 3.** Factors influencing treatment

- natural history
- grade of slippage
- lumbosacral anatomy
- age
- neurologic deficit
- severity of complaints
- duration of symptoms
- comorbidities

## Natural History

Some spondylolistheses progress to severe deformities yet are associated with no or only mild pain and no neurologic deficit and are uncovered only incidentally. Other slips progress very little but produce significant symptoms [30]. While natural history is benign in low-grade adult spondylolisthesis, there is a high tendency for slip progression in children. High-grade slips almost always necessitate surgical treatment; yet low-grade slips can be managed non-operatively in the majority of cases. The **risk of slip progression** is very high in the presence of a lumbosacral deformity and a rounded sacrum dome, which often leads to a high-grade slip and a lumbosacral kyphotic deformity. In adults with low-grade spondylolytic, degenerative or postsurgical spondylolisthesis (Meyerding I and II), the natural history of the condition is usually benign [4, 24]. While progressive deformity might well occur due to increase in degeneration at the slipped segment, the incidence and magnitude of such progression is small [44]. Often, independently of slippage, back pain improves when the disc space has completely collapsed. In only 30% of these cases does slippage progress, and about 75% of the patients who are initially neurologically intact do not deteriorate over time [58]. These are the patients who will respond to a conservative treatment. Conversely, most patients (about 80%) with a history of neurogenic claudication or vesicorectal symptoms deteriorate with poor final outcome [98]. In view of these results, the indications for surgery should without doubt be stringently met and individualized.

Low-grade spondylolisthesis in adults is usually a benign condition with little progression

A rounded sacral dome predisposes to slip progression

In view of this, treatment is dependent on the presence of a neurologic deficit either caused by a foraminal or a central stenosis. Treatment should therefore also take into account severity and duration of symptoms and comorbidities.

With regard to the aforementioned aspects an etiology-based recommendation of treatment modality can be given (Table 4).

## Conservative Treatment Options

In general, the vast majority of patients with spondylolisthesis can be treated non-operatively (Table 5).

The vast majority of spondylolisthesis patients can be treated non-operatively

In patients with favorable indications for non-operative treatment, **acute pain** should be controlled with:

- activity modification (bedrest < 3 days)
- pain medication
- anti-inflammatory drugs
- muscle relaxing drugs

**Table 4.** Guidelines for treatment

| Etiology | Age | Low grade (Meyerding I–II) | | High grade (Meyerding III–IV) | | |
|---|---|---|---|---|---|---|
| | | Asymptomatic | Back pain only | Back and neuro-logic symptoms | Back pain only | Back and neuro-logic symptoms |
| Developmental | children | no treatment | mostly non-operative | surgical | surgical | surgical |
| | adults | no treatment | mostly non-operative | mostly surgical | non-operative or surgical | surgical |
| Degenerative | adults | no treatment | non-operative or surgical | usually surgical | non-operative or surgical | usually surgical |
| Postsurgical | children | no treatment | attempt non-operative | surgical | surgical | surgical |
| | adults | no treatment | attempt non-operative | surgical | surgical | surgical |
| Pathologic | children | depending on etiology depending on etiology | depending on etiology depending on etiology | depending on etiology depending on etiology | | |
| Trauma | children | depending on slippage | surgical | surgical | | |
| | adults | surgical | surgical | surgical | | |

**Table 5.** Favorable indications for non-operative treatment

- no neurologic deficit
- tolerable pain threshold
- short duration of symptoms
- high patient comorbidity
- improvement by exercise program
- improvement by brace treatment

In patients without neurologic deficit, a sufficient conservative management program is a prerequisite before surgery is contemplated

This is followed by a therapeutic exercise program with paraspinal and abdominal strengthening to improve muscle strength, flexibility, endurance and balance (see Chapter 21). If pain does not subside sufficiently, the use of a brace or orthoses may be beneficial.

Radicular symptoms in spondylolisthesis are a result of a herniated disc or a foraminal stenosis. In these cases, non-operative management is not equally successful when compared to mechanical low back pain. However, this does not mean that conservative care is inefficient. However, leg pain may require a longer trail of non-operative care to evaluate the efficacy [5]. The non-operative treatment can be supported by spinal injections (see Chapter 10) to reduce inflammation and thus temporarily or even permanently eliminate leg pain:

- epidural blocks
- spondylolysis block
- nerve root blocks

In patients with chronic recurrent back and leg pain a sufficient period of conservative management should be performed before operative options are seriously contemplated. It is essential that the surgeon is certain that the symptoms are in fact a result of the slippage. Non-spinal causes of leg pain need to be contemplated and excluded.

Children and adolescents with a low-grade spondylolisthesis are usually treated conservatively

**Children and adolescents** with a low-grade spondylolisthesis (Meyerding I and II) are mostly treated non-operatively; yet particularly in adolescence these need to be closely observed, as it is then that they are most likely to progress [12, 33, 51]. One of the most important measures for dealing with pain is the **stretching of the hamstrings**. These exercises will improve the clinical condition in the vast majority of the cases.

In young patients with an acute pars defect, a **lumbar brace treatment** including one thigh is a valuable treatment option. The rationale is that by minimizing flexion-extension movements of the lumbar spine, the brace will stabilize the acute fracture allowing the lysis to heal by bony bridging [72]. Furthermore the brace usually diminishes the pain significantly. This treatment is performed for 6–12 weeks, depending on the age and the symptoms of the patient (Case Study 1).

An acute pars defect can be treated conservatively with a pantaloon cast

There are no given rules as to how long non-operative treatment should be continued. Generally speaking, if there is no neurologic deficit, intensive conservative management should be tried over a period of at least 3–6 months. However, surgery should not be postponed in patients when clinical symptoms are concordant with the morphological alterations and an adequate trial of non-operative therapy has failed.

## Operative Treatment

### General Principles

The choice of surgical treatment greatly depends on the etiology as well as the degree of slippage as outlined above. **General objectives of surgical treatment** are to:

- prevent further slip progression
- stabilize the segment
- correct lumbosacral kyphosis
- relieve back and leg pain
- reverse neurologic deficits

Both patient age and degree of slippage differentiate absolute and relative indications (Table 6):

**Table 6.** Indications for surgery

| Absolute indications | Relative indications |
|---|---|
| • progressive neurologic defits<br>• slip progression in children/adolescents<br>• high-grade spondylolisthesis in children<br>• severe lumbosacral kyphosis with gait disturbance | • minor, non-progressive neurologic deficits<br>• radicular and claudication symptoms<br>• mechanical low-back pain non-responsive to non-operative care |

High-grade developmental spondylolisthesis in adolescents should almost always be treated operatively. Those presenting with a sciatic crisis known as the **Phalen-Dixon sign** need immediate medical attention in the form of intravenous analgesics, bedrest and close neurologic monitoring. If the severe pain does not subside quickly or neurologic deficit is observed, early surgical management should be strived for. It must be pointed out that high-grade spondylolisthesis with either lysis or elongation of the pars constitutes a treatment challenge for even the most careful surgeon [94]. **High-grade spondylolisthesis** (Meyerding III and IV) in adults is treated according to the symptoms and biological age of the patient. While the young, otherwise healthy adult will biomechanically benefit from correction of deformity parameters and realignment of the spine with the sacrum, the elderly patient with comorbidity may only need decompression. Although Möller and Hedlund [69] were able to show that surgical management of adult spondylolisthesis can provide favorable clinical outcomes compared to a supervised exercise program, there is no general consensus as to what constitutes the optimal non-operative or operative treatment regime. The decision to recom-

Progressive slips in children should be treated operatively

There is no general consensus on the optimal treatment regime for adult spondylolisthesis

mend surgery to an adult patient with spondylolisthesis must therefore be individualized very carefully. Almost all cases of traumatic spondylolisthesis in the adult will need surgical management.

## Surgical Techniques

### Spondylolysis Repair

An acute pars defect can be directly repaired by osteosynthesis

In symptomatic cases with a very slight slippage and a verified fresh pars defect, an osteosynthesis using the **Morscher screw and hook** [35, 73] or direct repair by screw fixation (**Buck's fusion** [6, 14]) (Fig. 6) or figure of eight wiring (**Scott's technique** [19, 96]) may be justified.

Each fixation technique significantly increases stiffness and returns the intervertebral rotational stiffness to nearly intact levels. Importantly the displacement across the defect is significantly suppressed by all these instrumentation techniques; yet the least motion is allowed with the screw-rod-hook fixation or Buck's technique [19], making these the method of choice. The prognosis for these techniques is primarily determined by the time of surgery and whether displacement has already taken place. Overall direct osteosynthesis seems to be a comparatively safe and effective treatment method, independent of which method is utilized in cases with spondylolysis and fresh pars defects [19, 124].

### Decompression

When decompression with laminectomy is performed, fusion is compulsory

While a symptomatic disc herniation in the segment L4/5 with coexistent slip at L5/S1 can be treated by selective microsurgical decompression at L4/5 alone, a discectomy in the olisthetic segment should be avoided due to a high risk of additional destabilization. Due to the nature of the slippage, foraminal stenosis cannot be addressed selectively without causing added instability. If neurologic symptoms necessitate decompression and a complete laminectomy (**Gill's procedure** [80]) is done, fusion is mandatory because of the destabilization.

Care should be taken that all proliferative pseudarthrosis tissue is removed after the nerve roots have been identified. While neurologic deficit is a definite indication for decompression, there is an ongoing discussion as to whether in the face of radicular symptoms decompression is always necessary [44]. The argument against decompression relates to the loss of the tension-band strength and subsequent potential instability that the removal of posterior elements may exacerbate [44]. Long-term follow-up studies have shown that especially in children repositioning of the slippage by instrumentation can improve leg pain very soon after surgery [46].

### Instrumented Versus Uninstrumented Fusion

For many years, **uninstrumented fusion in situ** has been the gold standard for the treatment of isthmic spondylolisthesis in children and adolescents [117] and still has strong advocates [91]. However, with the advent of pedicular fixation devices, many spine surgeons have now changed to an instrumented fusion because it facilitates aftertreatment [11, 13, 43, 47, 92, 105].

Outcome of instrumented fusion is not shown to be superior to non-instrumented fusion

While the surgeon may well have the impression that instrumentation gives good primary stability and allows for a more precise realignment of the spinal column, studies randomizing isthmic spondylolisthesis patients with and without pedicle screws have not shown an improved fusion rate or improved clinical outcome with reduction and instrumentation [8, 62, 69]. The argument that a better realignment may be achieved with pedicle screws may be true but remains unproven.

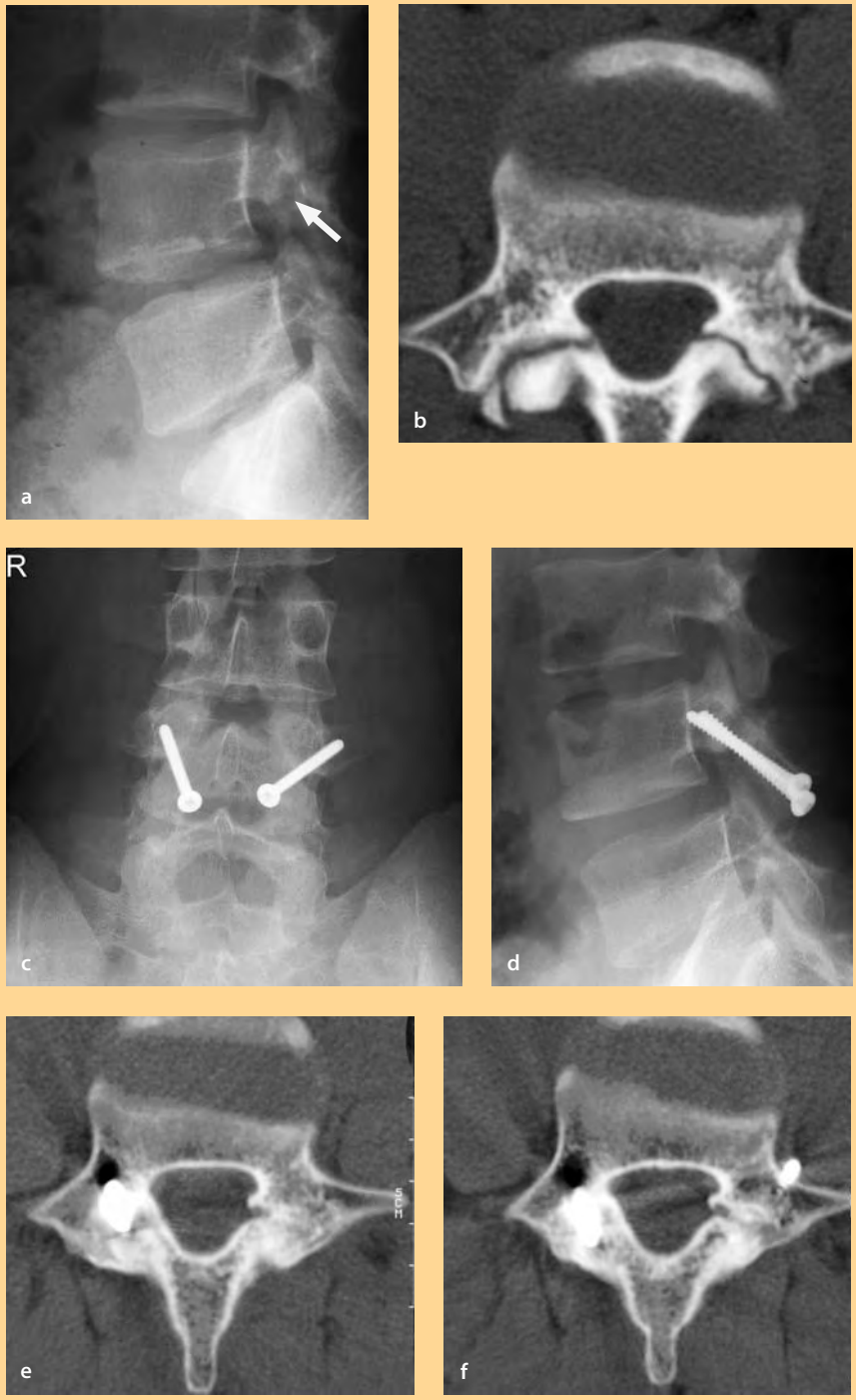


**Figure 6. Direct spondylolysis repair**

a Isthmic spondylolisthesis at the level of L4/5 (*arrow*). b Reversed gantry CT demonstrating the bilateral spondylolysis. c, d Direct screw fixation and bone grafting of the defect. e, f Solid fusion of the defect at 1 year follow-up with complete resolution of pain. (Courtesy of University Hospital Balgrist).

For the posterolateral fusion, the spine can be approached either by a midline skin incision or alternatively by bilateral muscle-splitting (**Wiltse approach** [117]). The transverse processes should be thoroughly denuded and decorticated, along with the lateral aspect of the facet joint and pedicle (see Chapter 20). Especially at the upper margin of the fusion, destruction of the facet joint should be avoided to avoid damage to the adjacent motion segment. Autologous cancellous bone should be packed over the transverse processes, the lateral facet joints and, if a mid line incision has been performed, along the decorticated spinous processes of the slipped motion segment. Bone is usually obtained from the iliac crest, though this may of course increase morbidity.

The mainstay of surgery in children is spinal realignment and in the elderly patient spinal stabilization and decompression

In contrast to treatment of adolescents and young adults where a primary aim of surgical treatment is correction of deformity and spinal realignment, the mainstay of surgery in the adult and elderly patient is decompression, whereby the aim is to relieve radicular and claudication symptoms (see Chapter 19). There is no general consensus about the indications for fusion surgery, the goals being to relieve back pain from a degenerated disc and facet joint by elimination of the instability. Indications for instrumentation are even more controversial [99], due to the higher complication rate.

### *Slip Reduction*

The treatment of high-grade spondylolisthesis differs between children and adults, as does that of low- and high-grade slips in adults. In low-grade slips it remains uncertain whether an attempt to reduce the anterior slip is actually necessary or desirable. Often some degree of reduction is already achieved by the prone position and subsequent exposure of the spine [71].

In adult spondylolisthesis in situ fixation is a proven surgical method

In **high-grade slips** in the **adult**, in situ fixation with or without decompression, depending on the neurologic status, is a proven surgical method [20], especially when intervertebral body space has markedly diminished. Reduction of the slipped vertebra remains controversial in this patient group [13, 33]. Consensus exists on the fact that partial reduction of the slip angle should be attempted if significant malalignment and foraminal stenosis is present. The aim is to decompress neural structures, decrease the lumbosacral kyphosis and facilitate fusion. In cases where partial reduction has been achieved, anterior structural support should be contemplated to hold the reduction in place [20].

In children the aim of surgery is to correct sagittal alignment and lumbosacral kyphosis

Especially in **high-grade slips** (Grade III–IV) **in children**, the aim of surgery is to correct sagittal alignment and lumbosacral kyphosis. By improving the biomechanics, the chances of solid fusion are significantly increased (Case Study 2). Nonetheless the procedure remains a surgical challenge especially in view of the high complication rates ranging from 10 % to 60 % [11, 13, 21]. This has led some surgeons to perform in situ posterolateral spine arthrodesis for high-grade slips in children [12, 28] with satisfactory clinical results.

### *Interbody Fusion*

Interbody fusion is recommended when reduction and/or distraction is performed

Spondylolisthesis is per se a spinal instability and as with all forms of osteosynthesis good postoperative stability is needed to avoid non-union or implant breakage. Especially when repositioning and/or distraction is performed, an interbody structural support of the anterior column is crucial [11]. In cases where the anterior column has not been addressed biomechanically, fusion rates for posterolateral fusions vary from 100 % [11, 29, 92] to as low as 33 % [41, 50, 111]. Even in cases where fusion has been verified, authors report on patients who continue to suffer from what is presumed to be “discogenic back pain” [3, 47].

## Case Study 2

A 10-year-old patient presented with hyperlordosis of the lumbar spine, sagittal malalignment (lumbosacral step-off), flexed knee position, tight hamstrings and paraspinal muscle spasm (a). The patient was neurologically intact. CT and MRI of the lumbar spine demonstrated a spondyloptosis (b). Note the dome shaped sacrum (b, c). The patient did not exhibit a spondylolysis but an elongated pars (c). Surgery was performed to realign the spine by means of sacral dome osteotomy (for technique see Fig. 7), pedicular instrumentation at L4–S1, posterolateral fusion at L4/5 and interbody fusion at L5/S1 with correct sagittal realignment (e, f). At the latest follow-up, the patient was symptom free and had substantially improved her sagittal balance. (Courtesy of University Hospital Balgrist).

**Table 7.** Results of surgical treatment of high-grade spondylolisthesis with and without instrumentation

| Author | Cases | Type of spondylolisthesis | Patient age | Follow-up | Technique | Complications/ outcome | Conclusions |
|---|---|---|---|---|---|---|---|
| Schufflebarger et al. (2005) [85] | 18 | adolescent high-grade developmental | 14 (10–16) years | 3.3 (2.3–5) years | Gill decompression, monosegmental PLIF with Harm's cages and autogenous iliac graft | 2 structural complications<br>0 neurologic complications<br>0 infections<br>0 pseudarthrosis<br>0 reoperations | Retrospective study<br>PLIF procedure provides near-anatomic correction of high-grade spondylolisthesis without significant complications. Anterior column support and posterior compressive instrumentation help restore biomechanics and allow fusion |
| Grzegorzewski et al. (2000) [23] | 21 | adolescent high-grade developmental | 14.9 (9.4–19.3) years | 12.8 (6–24.8) years | PLF + iliac bone graft + immobilization in pantaloon cast 4 months | 0 neurologic complications<br>0 pseudarthrosis<br>5 patients showed progression of slip 1 year postop. | Retrospective study<br>In situ posterolateral arthrodesis with large amount of bone graft followed by immobilization provides satisfactory results |
| Molinari et al. (2002) [62] | 37 | adolescent high-grade developmental | 13.5 (9–20) years | 3.1 (2–10.1) years | PLF ($n=18$) vs. circumferential ($n=19$) fusion | 39% pseudarthrosis for posterolateral procedure vs. 0% in circumferential fusion | Retrospective study<br>All patients who had pseudarthrosis achieved solid fusion with a second procedure involving 360° fusion with anterior column structural grafting |
| Möller et al. (2000) [64] | 77 | adult low grade | 39 (18–55) years | 2 years | PLF with ($n=37$) vs. without ($n=40$) transpedicular fixation | no significant difference in fusion rate level of pain as well as functional disability were very similar | This prospective randomized trial suggests that the use of supplementary transpedicular instrumentation does not add to the fusion rate or improve clinical outcome |
| Bjarke et al. (2002) [7] | 129 | adult low grade | 46 and 43.5 (20–67) years | 5 years | PLF with ($n=63$) vs. without ($n=66$) transpedicular fixation | instrumented group had 25% reoperation rate vs. 14% for non-instrumented functional outcome similar in both groups | This prospective randomized trial showed that long-term functional outcome improved in both groups. Isthmic spondylolisthesis profited from non-instrumentation while degenerative spondylolisthesis fared better with transpedicular fixation |
| Suk et al. (2001) [94] | 56 | adult low grade | 45.9 and 51.3 (23–70) years | 2 years | PLF with instrumentation ($n=35$) vs. ALIF with pedicle screw fixation ($n=21$) | no difference in complication rate clinical outcome identical<br>PLF led to significant loss of reduction | Prospective study<br>ALIF with pedicle screw instrumentation was superior to PLF with instrumentation in terms of preventing reduction loss for spondylolytic spondylolisthesis |
| Kim et al. (1999) [40] | 40 | adult low grade | ±42 (21–62) years | 2.3–3.6 years | ALIF ($n=20$) vs. PLF with instrumentation ($n=20$) | fusion rate after 12 months over 90% for both methods satisfactory clinical results in 85% for ALIF and 90% for PLF + instrumentation | Retrospective study<br>There was no statistically significant difference in clinical results between the two methods |
| Bradford et al. (1990) [12] | 22 | adult high grade | | 5 (2–7.5) years | First posterior decompression + PLF + halo-traction, then in second procedure ALIF | percentage of slippage pre- vs. postop. did not change substantially<br>4 patients had non-union<br>postop. 1 cauda equina syndrome and 2 nerve root neuropathy, yet persisting neurologic deficit in only 1 patient at follow-up | Retrospective study<br>Alignment of the sagittal plane was restored in 17 patients. Back pain and radicular symptoms were relieved in all but one patient |

**Table 7.** *(Cont.)*

| Author | Cases | Type of spondylolisthesis | Patient age | Follow-up | Technique | Complications/ outcome | Conclusions |
|---|---|---|---|---|---|---|---|
| Boos et al. (1993) [10] | 10 | adult high grade | | 4.7 (3.6–6.3) years | PLIF and PLF ($n=6$) vs. PLF ($n=4$) | 5/6 patients with sole PLF had loss of reduction, non-union and implant failure<br>all patients with PLF + PLIF had fusion and no loss of reduction | Retrospective study<br>PLF + PLIF for spondyloptosis is a technically demanding procedure. Permanent reduction and fusion is only obtained with combined interbody and posterolateral fusion |
| Roca et al. (1999) [77] | 14 | adult high grade | 21 years | 2.5 years | Lumbosacral decompression + PLF + interbody fusion | 6 patients with transient motor deficit<br>2 pseudarthrosis<br>13 excellent clinical results | Retrospective study<br>Circumferential arthrodesis through a posterior approach is a safe and effective technique for managing severe spondylolisthesis |

The fusion techniques available for this deformity can conceptually be divided into those that achieve posterior column stability, those that achieve anterior column stability and combined approaches that achieve both. In cases where the spinal canal has to be decompressed and instrumentation is planned, it makes sense to perform a posterior lumbar interbody fusion (PLIF); yet this is certainly not mandatory (Case Introduction). The choice of which approach to take will heavily depend on personal preference and familiarity with the approach, resources and infrastructure as well as back-up expertise in case of complications.

Fusion techniques can achieve posterior column stability, anterior column stability or both

**Anterior techniques** in spine fusion allow for a complete discectomy and very precise placement of an interbody implant or graft. Particularly the latter aspect is an advantage of the method, as larger structural grafts can be placed without the danger of dural sheath damage or nerve root injury. While disc height may thereby be restored and kyphosis diminished, there is ongoing discussion as to whether an adequate repositioning and thus improvement of sagittal alignment of the spine can be achieved by a single anterior procedure, with or without instrumentation. Also, because nerve root and dural sac are not decompressed before the repositioning maneuver, there is a high likelihood of neurologic injury. The method should therefore only be contemplated in low-grade olisthesis, where the primary aim is in situ stabilization and fusion without decompression or repositioning in neurologically asymptomatic patients.

Anterior interbody fusion allows better disc removal and fusion

In the lumbar spine the anterior technique usually involves a retroperitoneal approach, with its attendant complications such as possibility of vascular injury, damage of the sympathetic plexus with subsequent retrograde ejaculation in males, as well as damage to retro- and intraperitoneal structures. Spine surgeons performing this approach should therefore either be able to manage possible complications themselves or have very fast access to expertise.

Circumferential stability offers all the advantages of both the aforementioned techniques, yet obviously also incorporates the possible complications. **Combined approaches** can be either posterior or transforaminal interbody fusion (PLIF or TLIF) or anterior lumbar interbody fusion (ALIF) with posterolateral intertransverse fusion (PLF). Due to the high degree of primary stability achieved with the 360° treatment of the spine, fusion rates are highly reliable with numerous reports claiming rates of 100 % [34, 100, 104, 123]. Also, an excellent spinal realignment can be achieved. Despite these good results, the technique of 360° instrumentation is technically more demanding than ALIF or PLF alone.

Circumferential arthrodesis offers the highest fusion rate

Operation times are longer and complication rates are higher (Table 7) than with the other two approaches. Kwon and Albert [44] point out that solid fusion does not always correlate with clinical success in other degenerative disorders of the spine. While comparative objective radiographic measurements of the spine after PLIF vs. PLF for lytic spondylolisthesis in adults show better results for PLIF, clinical outcomes were not reported to be markedly different [47, 55, 105]. It is therefore valid to at least critically question whether the benefits engendered by performing a combined approach stand in correlation to the longer, technically more demanding and, from a hardware standpoint, usually more expensive procedure with a higher risk for complications.

### *Fusion to L4*

Reduction is facilitated by instrumenting to L4

In children with severe developmental spondylolisthesis at L5/S1 (Meyerding Grades III–V), reduction can be extremely tedious and may be facilitated by instrumentation to L4 (Case Study 2, Fig. 7). This technique allows to distract between L4 and S1, which facilitates the reduction. In selected cases, the L4 screws can be removed at the end of the operation or alternatively 12 weeks later, which leaves the motion segment L4/5 intact [87]. However, the lateral process of L5 is often dysplastic in children and does not allow for a reliable fusion. Therefore a fusion to L4 is recommended. This is particularly valid if no interbody fusion is added.

In adults the L4/5 disc is often degenerated and requires inclusion in the fusion

In **adults with marked slips of L5/S1**, the adjacent L4/5 segment frequently exhibits significant degenerative changes. In these cases, a fusion of L4 to S1 is indicated because the L4/5 segment often rapidly decompensates after the L5/S1 fusion.

### *Vertebrectomy*

To achieve good spine realignment, surgical treatment of spondyloptosis, which almost only affects L5/S1, may necessitate vertebrectomy of L5 (**Gaines' procedure** [26]). This is a two-stage procedure, first incorporating an anterior approach with resection of the entire body of L5 back to the base of the pedicles, as well as the intervertebral discs L4/5 and L5/S1. In a second stage, the posterior approach allows realignment of the spine after L5 pedicles, facets and laminar arch have been removed bilaterally. After transpedicular instrumentation from L4 to S1 and sagittal realignment, nerve roots L5 and S1 exit the spinal canal together over a reconstructed intervertebral foramen. Gaines, who originally described this method in 1985, more recently reported on 30 patients treated with this procedure [26]. Despite the fact that Gaines had a low complication rate and good success, over two-thirds of the patients had neurapraxic injury to one or both L5 roots and in two this remained permanent. This procedure, which requires a large amount of surgical experience, should only be performed at specifically equipped centers. Complication rates remain very high even in experienced hands.

Vertebrectomy for a high-grade slip is prone to complications

### *Sacral Dome Osteotomy*

The main risk of reducing high-grade spondylolisthesis and spondyloptosis is related to the stretching of the L5 nerve roots, which often results in neuropraxia. The **sacral dome osteotomy** helps to avoid this nerve root injury by shortening of the sacrum. This technique consists of a bilateral osteotomy of the sacral dome, which allows the reduction of the slip without distraction (Fig. 7). The operation is carried out in a single stage. This demanding procedure should be carried out

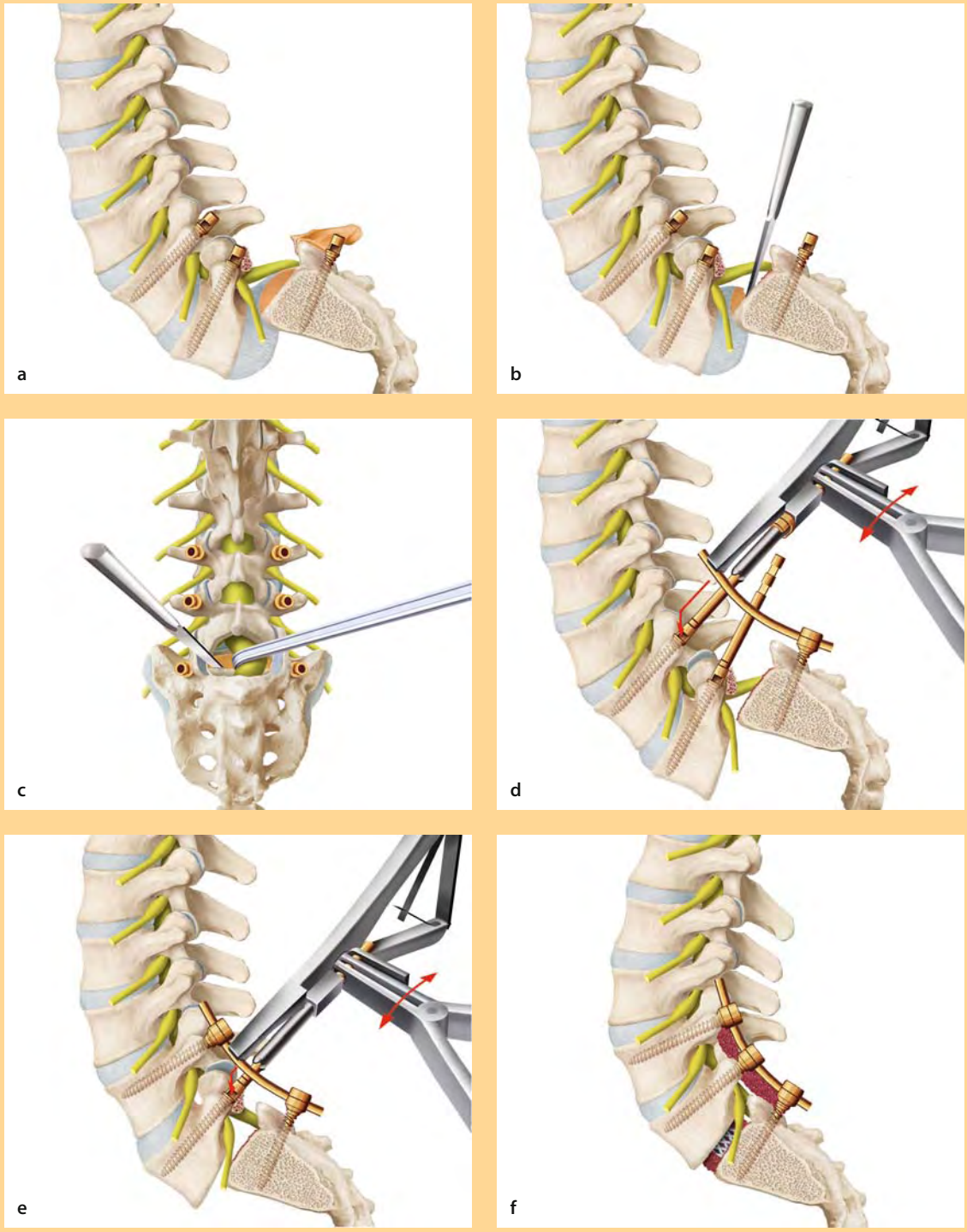


**Figure 7. Reduction of high-grade spondylolisthesis with sacrum dome osteotomy**

a The pedicles of L4, L5 and S1 are instrumented with pedicle screws. b, c The loose posterior arc of L5 is resected and the L5 and S1 nerve root as well as the intervertebral discs are exposed. The dome of the sacrum is osteotomized with a chisel and resected. d A rod is inserted on both sides first connecting the S1 screws with the rods. L4 is then reduced to the rod with a reduction forceps. L4–S1 are slightly distracted. e L5 is pulled back and connected to the rod with a reduction forceps. f An interbody fusion is added to L5/S1 and a posterolateral fusion to L4–S1.

only with neuromonitoring of the L5 nerve roots. It is important to note that neuromonitoring is not absolutely reliable, because paresis of the nerve root can occur even hours after the surgery. It is therefore recommended to reduce the slip only far enough to allow for a good sagittal realignment and an interbody buttressing by a graft or cage (Case Study 2).

## Complications

Typical complications encountered are neurologic injuries and non-union

As with all surgical procedures, patients surgically managed for spondylolisthesis must receive the best outcome with low exposure to problems and complications. It is therefore important to appreciate which complications can occur so as to minimize the occurrence and appreciate the psychologic impact these may have on the patient [79]. Depending on the etiology of the condition and the procedure performed, complication rates differ significantly. In situ fixation for degenerative low-grade slippage in the adult will have a markedly lower risk of attaining neurologic impairment than complex reconstructive surgery of the adolescent spine in spondyloptosis. **Common complications** after spondylolisthesis surgery are:

- neurologic injury (0.3 – 9.1 %) [74, 79, 89, 93]
- persistent nerve root deficits (2 – 3 %) [15, 38, 74, 89, 102]
- non-unions (0 – 39 %) [20, 31, 38, 48, 55, 60, 67, 74, 89, 106]
- progressive slippage (4 – 11 %) [28, 82, 89, 102]
- revision surgery (7.6 %) [48, 67, 89]

L5 nerve root is at high risk in high-grade spondylolisthesis surgery

The list of these potential complications indicates that surgery of (high-grade) spondylolisthesis is demanding and very careful preoperative planning is necessary before the procedure is performed. As with all neurologic complications, these need to be accurately assessed and diagnostic imaging should occur rapidly. If there is obvious compression of neural structures, be it from hematoma or misplacement of spinal instrumentation, immediate revision surgery should be the consequence.

More complex are the cases where there is no radiographic evidence of compression of neural structures. In cases of only minor deficit, an attentive yet merely observational approach may be warranted. The question whether reduction was too ambitious should critically be asked. In general for any surgeon, the decision for or against revision surgery is among the most difficult to make. It is therefore prudent to involve a further, less biased surgeon to assess the patient as well as the radiographic parameters and decide for or against revision together.

**Adjacent segment instability** after instrumentation may be due to excessive iatrogenic destabilization of the overlying facet joint and capsule, due to excessive thinning or complete removal of the overlying lamina or due to degenerative changes to the adjacent motion segment. While the iatrogenic destabilization of a segment certainly will lead to slippage adjacent to a stabilized segment [109], data concerning adjacent segment degeneration are inconsistent. Incidences are reported to range between less than 3 % and 35 %. The discussion remains open as to whether these observed degenerative changes reflect the natural history of disc disease or stand in context to the adjacent fusion [66, 83]. As Ogilvie [79] points out, both are probably a factor and therefore as many lumbar levels should be left unfused as are consistent with the goals of surgery.

## Recapitulation

**Epidemiology.** Lumbar spondylolisthesis can be **developmental or acquired**. As most slippages are asymptomatic, the true incidence of the condition remains speculative. For developmental spondylolisthesis, rates of around **3 %** in the general population have been estimated, but depending on the ethnic group, the incidence may be significantly higher. Among the acquired slippages, the degenerative type is the most frequent one.

**Pathogenesis.** Spondylolysis, which is a defect of the pars interarticularis, is the main cause of developmental spondylolisthesis and results from a stress fracture. This causes failure of the posterior stabilizing elements and the disc is confronted with excessive shear. The **dissociation of the anterior and posterior column** therefore ultimately results in slippage, since the disc cannot withstand the shear forces. Acquired spondylolisthesis mostly occurs on the basis of degenerative lumbar disease. Further causes may be iatrogenic destabilization of a motion segment, trauma, tumors, and rare syndromes or systemic bone disease.

**Classification.** Only those classifications are of true value that are based on anatomy or distinguish between developmental and acquired forms of the deformity. The two systems which are clinically relevant are those of **Wiltse/Rothmann** and **Marchetti/Bartolozzi**. The Marchetti classification is self-explanatory and, as it avoids complex terminology, easier to understand.

**Clinical presentation.** **Patients seeking medical attention do so with a variety of symptoms. Back and/or leg pain** may range from merely harassing to severe. Depending on the degree of slippage and onset, **neurologic symptoms** may occur. In rare cases, spinal canal compromise may be so severe that patients present with a cauda equina syndrome. Adolescents with symptomatic high-grade spondylolisthesis may develop a **sciatic crisis** known as the Phalen-Dixon sign. Tight hamstrings and posture abnormalities accompany the presentation in the adolescent patient. In the adult patient, mechanical low-back pain (worse on motion, better on rest) and radiculopathy are the prevailing symptoms. Physical examination may show hyperlordosis of the lumbar spine, and in high-grade slippages a **step-off between spinous processes**. Patients should be assessed for sensory or motor deficits of nerve roots.

**Diagnostic work-up.** **Standard anteroposterior and lateral radiographs** are the mainstay for the initial assessment. Oblique X-rays may visualize a pars defect not already visible on a lateral view. Slippage is quantified by either using the method as described by **Meyerding (Grade I–V)** or of **Taillard (%)**. Assessment of the sagittal deformity (lumbosacral kyphosis) is crucial in high-grade spondylolisthesis. A large slip angle in conjunction with a rounded sacrum increases the risk of slip progression in children. In case of neurologic deficit or if surgery is planned, a CT scan or MRI should always be performed.

**Non-operative treatment.** Treatment decision will ultimately be based on the age of the patient, symptoms, etiology as well as the degree of slippage. **General objectives of treatment** are to relieve pain, reverse neurologic deficit and, in cases of severe slippage, to realign the spine. The vast majority of spondylolisthesis can be treated non-operatively. Acute pain should be controlled with initial rest, anti-inflammatory and/or pain-modulating medication as well as administration of a muscle relaxant. This is followed by a therapeutic exercise program with paraspinal and abdominal muscle strengthening. If pain does not sufficiently subside, the use of a brace or orthoses may be beneficial. **Cast treatment** may result in a healing of an acute spondylolysis in selected cases.

**Operative treatment.** Surgery is justified in cases of persistent or recurrent back and/or radicular pain, neurologic deficit/neurogenic claudication as well as bladder and/or bowel syndromes. Aim of all surgical techniques is to **decompress neural structures**, **prevent progression** and **achieve stability** with subsequent fusion. Generally there are three methods to achieve this goal, i.e. **uninstrumented posterolateral fusion** (PLF), and **instrumented posterolateral fusion** with or without anterior or posterior **interbody fusion** (ALIF/PLIF). Due to technical innovations and improvement in implants, there is an increasing trend to manage spondylolisthesis by combined approaches. The **surgical approach** will depend on familiarity with the approach, resources and infrastructure as well as back-up expertise in case of complications. Particularly the management of high-grade spondylolisthesis is a surgical challenge and technically demanding. In children with **high-grade spondylolisthesis**, fusion to L4 is often required. Reduction of high-grade spondylo-

listhesis is still a matter of debate because of the high complication rates associated with these procedures. Particularly, the L5 nerve root is at risk. The primary goal in **adult low-grade spondylolisthesis** is not to reduce the slip but this may be necessary in cases with foraminal stenosis. In the latter indication, solid fusion and neural decompression are more important. In cases where reduction and/or distraction of the slipped vertebra was performed, anterior buttressing by an interbody fusion is necessary. **Frequent complications** encountered are non-union and neural compromise.

## Key Articles

**Boxall DW, Bradford DS, Winter RB, Moe JH (1979) Management of severe spondylolisthesis (grade III and IV) in children and adolescents. J Bone Joint Surg (Am) 61:479 – 495**
Patients with an L5/S1 spondylolisthesis of 50 % or greater were reviewed. Four had been treated non-operatively; 11, by spondylodesis; 18, by decompression and spondylodesis; and 10, by reduction and spondylodesis. The angle of slippage was found to be as important a measurement as the percentage of slippage in measuring instability and progression. Spondylodesis alone, even in the presence of minor neural deficits, tight hamstrings, or both, gave relief of pain and resolution of neural deficits and tight hamstrings. The study suggests that management by postoperative extension casts may achieve a significant reduction in percentage and in angle of slippage. Progression of the spondylolisthesis may occur following a solid spondylodesis.

**Bradford DS, Boachie-Adjei O (1990) Treatment of severe spondylolisthesis by anterior and posterior reduction and stabilisation. A long-term follow-up study. J Bone Joint Surg (Am) 72:1060 – 1066**
Unselected patients ($n = 22$) who had severe spondylolisthesis were treated by a first-stage posterior decompression (Gill procedure) and a posterolateral arthrodesis, followed by haloskeletal traction, and then by a second-stage anterior interbody arthrodesis, followed by immobilization in a cast. At an average 5-year follow-up the corrected slip angle remained much the same. A pseudarthrosis developed in four patients, all of whom had a reoperation. The neurologic deficits that had been present in ten patients preoperatively had completely resolved in all but one at follow-up. Alignment in the sagittal plane was restored in most patients, and the back pain and radicular symptoms were resolved in all patients but one.

**Lenke LG, Bridwell KH, Bullis D, Betz RR, Baldus C, Schoenecker PL (1992) Results of in situ fusion for isthmic spondylolisthesis. J Spinal Disord 5:433 – 442**
Patients treated with in situ bilateral transverse process fusions utilizing autogenous iliac bone graft yet without decompression or instrumentation are assessed. A surprisingly low fusion rate was found; yet despite this overall clinical improvement was noted in > 80 % of patients with preoperative symptoms of back pain, leg pain, or hamstring tightness.

**Boos N, Marchesi D, Zuber K, Aebi M (1993) Treatment of severe spondylolisthesis by reduction and pedicular fixation. A 4 – 6-year follow-up study. Spine 18:1655 – 1661**
This paper compares the surgical treatment of severe spondylolisthesis by posterolateral fusion with and without interbody fusion. The majority of patients with single posterolateral fusion demonstrated loss of reduction, non-union and implant failure. The authors suggest that pedicular fixation systems only allow permanent reduction and stabilization of high-grade spondylolisthesis in conjunction with a combined interbody and posterolateral fusion.

**Moller H, Hedlund R (2000) Instrumented and noninstrumented posterolateral fusion in adult spondylolisthesis: a prospective randomized study: part 2. Spine 25:1716 – 1721**
This prospective randomized study assesses whether posterolateral fusion in patients with adult isthmic spondylolisthesis results in an improved outcome compared with an exercise program. Pain and functional disability were quantified before treatment and at 1- and 2-year follow-up assessments by visual analog scales (VAS). The data shows that surgical management of adult isthmic spondylolisthesis improves function and relieves pain more efficiently than an exercise program. The results suggest that the use of supple-

mentary transpedicular instrumentation does not add to the fusion rate or improve clinical outcome.

**Molinari RW, Bridwell KH, Lenke LG, Baldus C (2002) Anterior column support in surgery for high-grade, isthmic spondylolisthesis. Clin Orthop Rel Res 394:109–120**
This study compares the outcome of two techniques of surgical management of high-grade isthmic spondylolisthesis. While reduction and circumferential fusion including anterior structural support had no pseudarthrosis, the incidence of non-union in patients treated with in-situ fusion or decompression and reduction with sole posterior instrumentation was 39%. Outcomes regarding pain after treatment, function, and satisfaction were high in those patients who achieved solid fusion regardless of the method.

**Gaines RW (2005) L5 vertebrectomy for the surgical treatment of spondyloptosis. Thirty cases in 25 years. Spine 30:66–70**
Thirty cases of vertebrectomy are reviewed over a significant time span. Complication review showed that 23 patients had some temporary clinical deficit in the L5 root for 6 weeks up to 3 years after reconstruction. All but two recovered fully. One patient had retrograde ejaculation, and two patients needed revision surgery for screw breakage due to non-union. No patient had junctional problems and overall patients were clinically satisfied with the procedure.

**McAfee PC, DeVine JG, Chaput CD, Prybis BG, Fedder IL, Cunningham BW, Farrell DJ, Hess SJ, Vigna FE (2005) The indications for interbody fusion cages in the treatment of spondylolisthesis: analysis of 120 cases. Spine 30:60–5**
The authors review 120 cases of patients with spondylolisthesis of varying etiologies surgically managed by 360° instrumentation in respect to their radiographic outcome. Also, complications are assessed. Seven incidental durotomies and three infections were recorded. There was an excellent rate of fusion at 98% and the authors conclude that an important part of the success was regaining neuroforaminal height due to distraction and the interbody spacer.

**Schlenzka D, Remes V, Helenius I, Lamberg T, Tervahartiala P, Yrjonen T, Tallroth K, Osterman K, Seitsalo S, Poussa M (2006) Direct repair for treatment of symptomatic spondylolysis and low-grade isthmic spondylolisthesis in young patients: no benefit in comparison to segmental fusion after a mean follow-up of 14.8 years. Eur Spine J 15:1437–47**
Clinical, radiographic and MRI assessment of the long-term clinical, functional, and radiographic outcome of direct repair of spondylolysis using cerclage wire fixation according to Scott in young patients with symptomatic spondylolysis or low-grade isthmic spondylolisthesis ($n=25$) as compared to the outcome after uninstrumented posterolateral in situ fusion ($n=23$). In conclusion, the results of direct repair of the spondylolysis according to Scott were very satisfactory in 76%. After direct repair, the Oswestry Disability Index (ODI) deteriorated with time leading to a clinically moderate but statistically significant difference in favor of segmental fusion. Lumbar spine mobility was decreased after direct repair. Secondary segmental instability above the spinal fusion was not detected. The procedure does not seem to be capable of preventing the olisthetic disc from degeneration. The theoretical benefits of direct repair could not be proven.

## References


1. Adams MA, Hutton WC (1983) The mechanical function of the lumbar apophyseal joints. Spine 8:327–330
2. Andersson GBJ (1983) The biomechanics of the posterior elements of the lumbar spine. Spine 8:326–331
3. Barrick WT, Schoffermann JA, Reynolds JB, et al. (2000) Anterior lumbar fusion improves discogenic pain at levels of prior posterolateral fusion. Spine 25:853–857
4. Beutler WJ, Fredrickson BE, Nurtland A et al. (2003) The natural history of spondylolysis and spondylolisthesis: 45 year follow-up evaluation. Spine 28:1027–1035
5. Balderston RA, Vaccaro AR (1989) Surgical treatment of adult degenerative spondylolisthesis. In: Wiesel SW, Weinstein JN, Herkowitz H, Dvorak J, Bell G (eds) The lumbar spine, vol. 2, 2nd edn. Saunders, Philadelphia, pp 700–710

6. Beckers L (1986) Buck's operation for treatment of spondylolysis and spondylolisthesis. Acta Orthop Belg 52:819 – 23
7. Belfi LM, Ortiz AO, Katz DS (2006) Computed tomography evaluation of spondylolysis and spondylolisthesis in asymptomatic patients. Spine 31:907 – E910
8. Bjarke CF, Stender HE, Laurson M, et al. (2002) Long-term functional outcome of pedicle screw instrumentation as a support for posterolateral spinal fusion: randomized clinical study with a 5-year follow-up. Spine 27:1269 – 1277
9. Blackburne JS, Velikas EP (1977) Spondylolisthesis in children and adolescents. J Bone Joint Surg (Br) 59:490 – 494
10. Boos N, Marchesi D, Aebi M (1991) Treatment of spondylolysis and spondylolisthesis with Coutrel-Dubousset instrumentation: a preliminary report. J Spinal Disord 4.472 – 479
11. Boos N, Marchesi D, Zuber K, Aebi M (1993) Treatment of severe spondylolisthesis by reduction and pedicular fixation. A 4 – 6-year follow-up study. Spine 18:1655 – 1661
12. Boxall DW, Bradford DS, Winter RB, Moe JH (1979) Management of severe spondylolisthesis (grade III and IV) in children and adolescents. J Bone Joint Surg (Am) 61:479 – 495
13. Bradford DS, Boachie-Adjei O (1990) Treatment of severe spondylolisthesis by anterior and posterior reduction and stabilisation. A long-term follow-up study. J Bone Joint Surg (Am) 72:1060 – 1066
14. Buck JE (1970) Direct repair of the defect in spondylolisthesis. Preliminary report. J Bone Joint Surg 52:432 – 7
15. Chen L, Tang T, Yang H (2003) Complications associated with posterior lumbar interbody fusion using Bagby and Kuslich method for treatment of spondylolisthesis. Chin Med J (Engl) 116:99 – 103
16. Crawford AH (2001) Neurofibromatosis. In: Weinstein SL (ed) The pediatric spine. Principles and practice, 2nd edn. Lippincott Williams and Wilkins, Philadelphia
17. Curylo LJ, Edwards C, DeWald RL (2002) Radiographic markers in spondyloptosis: implications for spondylolisthesis progression. Spine 27:1021 – 2025
18. Cyron BM, Hitton WC, Troup JDG (1976) Spondylolytic fractures. J Bone Joint Surg (Br) 58:462 – 466
19. Deguchi M, Rapoff AJ, Zdeblick TA (1999) Biomechanical comparison of spondylolysis fixation techniques. Spine 24:328 – 33
20. DeWald CJ, Vartabedian JE, Rodts MF, Hammerberg KW (2005) Evaluation and management of high-grade spondylolisthesis in adults. Spine 30:S49 – 59
21. Dick WT, Schnebel B (1988) Severe spondylolisthesis. Reduction and internal fixation. Clin Orthop Relat Res 232:70 – 9
22. Duval-Beaupere G, Boisaubert B, Hecquet J, et al. Sagittal profile of normal spine changes in spondylolisthesis. In: Harms J, Sturz H (eds) Severe spondylolisthesis. Steinkopff-Verlag, Darmstadt, pp 21 – 32
23. Farfan HF (1980) The pathological anatomy of degenerative spondylolisthesis: a cadaver study. Spine 5:412 – 418
24. Fredrickson BE, Baker D, McHolick WJ, Yuan HA, Lubicky JP (1984) The natural history of spondylolysis and spondylolisthesis. J Bone Joint Surg (Am) 66:699 – 707
25. Friberg O (1989) Functional radiography of the lumbar spine. Ann Med 21:341 – 346
26. Gaines RW (2005) L5 vertebrectomy for the surgical treatment of spondyloptosis. Thirty cases in 25 years. Spine 30:S66 – S70
27. Grobler LJ, Wiltse LL (1991) Classification, non-operative, and operative treatment of spondylolisthesis. In: Frymoyer JW, Ducker TB, Hadler NM, Kostuik JP, Weinstein JN, Whitecloud TS (eds) The adult spine, vol. 2. Raven Press, New York, pp 1655 – 1704
28. Grzegorzewski A, Kumar SJ (2000) In situ posterolateral spine arthrodesis for grades III, IV and V spondylolisthesis in children and adolescents. J Pediatr Orthop 20:506 – 511
29. Hambly M, Lee CK, Gutteling E, et al. (1989) Tension band wiring-bone grafting for spondylolysis and spondylolisthesis: a clinical and biomechanical study. Spine 14:455 – 460
30. Hammerberg KW (2005) New concepts on the pathogenesis and classification of spondylolisthesis. Spine 30:S4 – S11
31. Hanley EN Jr, Levy JA (1989) Surgical treatment of isthmic lumbosacral spondylolisthesis: analysis of variables influencing results. Spine 14:48 – 50
32. Hanscom DA, Bloom BA (1988) The spine in osteogenesis imperfecta. Orthop Clin North Am 192:449 – 454
33. Harris IE, Weinstein SL (1987) Long-term follow-up of patients with grade III and IV spondylolisthesis: treatment with and without posterior fusion. J Bone Joint Surg (Am) 69: 960 – 969
34. Hashimoto T, Shigenobu K, Kanayama M, et al. (2002) Clinical results of single level posterior lumbar interbody fusion using Brantigan I/F carbon cage filled with a mixture of local morselized bone and bioactive ceramic granules. Spine 27:258 – 262
35. Hefti F, Seelig W, Morscher E (1992) Repair of lumbar spondylolysis with a hook screw. Int Orthop 16:81 – 85
36. Hensinger RN (1989) Spondylolysis and spondylolisthesis in children and adolescents. J Bone Joint Surg (Am) 71:1098 – 1107

37. Herkowitz HN (1995) Spine update: degenerative lumbar spondylolisthesis. Spine 20: 1084 – 1090
38. Hu SS, Bradford DS, Transfeldt EE, et al. (1996) Reduction of high-grade spondylolisthesis using Edwards instrumentation. Spine 21:367 – 371
39. Jackson RP, Phipps T, Hales C, et al. (2003) Pelvic lordosis and alignment in spondylolisthesis. Spine 28:151 – 160
40. Jackson DW, Wiltse LL, Cirincione RJ (1976) Spondylolisthesis in the female gymnast. Clin Orthop 117:68 – 73
41. Johnsson R, Stromqvist B, Axelsson P, et al. (1992) Influence of spinal immobilization on consolidation of posterolateral lumbosacral fusion: a roentgen stereophotogrammetric and radiographic analysis. Spine 17:16 – 21
42. Kettelkamp DB, Wright GD (1971) Spondylolysis in the Alaskan Eskimo. J Bone Joint Surg (Am) 53:563 – 566
43. Kim NH, Lee JW (1999) Anterior interbody fusion versus posterolateral fusion with transpedicular fixation for isthmic spondylolisthesis in adults. A comparison of clinical results. Spine 24.812 – 816
44. Kwon BK, Albert TJ (2005) Adult low-grade acquired spondylitic spondylolisthesis. Evaluation and management. Spine 30:S35 – S41
45. Lafond G (1962) Surgical treatment of spondylolisthesis. Clin Orthop 22:175 – 179
46. Lamberg TS, Remes VM, Helenius IJ, Schlenzka DK, Yrjonen TA, Osterman KE, Tervahartiala PO, Seitsalo SK, Poussa MS (2005) Long-term clinical, functional and radiological outcome 21 years after posterior or posterolateral fusion in childhood and adolescence isthmic spondylolisthesis. Eur Spine J 14:639 – 44
47. La Rosa G, Conti A, Cacciola F, et al. (2003) Pedicle screw fixation for isthmic spondylolisthesis: does posterior lumbar interbody fusion improve outcome over posterolateral fusion? J Neurosurg 99:143 – 150
48. Lauber S, Schulte TL, Lilienquist U, Halm H, Hackenberg L (2006) Clinical and radiologic 2 – 4-year results of transforaminal lumbar interbody fusion in degenerative and isthmic spondylolisthesis grades 1 and 2. Spine 31:1693 – 8
49. Laurent LE, Einola S (1961) Spondylolisthesis in children and adolescents. Acta Orthop Scand 31:45 – 64
50. Lenke LG, Bridwell KH, Bullis D, et al. (1992) Results of in situ fusion for isthmic spondylolisthesis. J Spinal Disord 5.433 – 442
51. Lonstein JE (1999) Spondylolisthesis in children: cause, natural history, and management. Spine 24:2640 – 2652
52. Lubicky JP (1997) The spine in osteogenesis imperfecta. In: Bridwell KH, DeWald RL (eds) The textbook of spinal surgery, 2nd edn. Lippincott-Raven, Philadelphia, p 321
53. Lubicky JP (2005) Unusual spondylolisthesis. Spine 30:S82 – S87
54. Macnab I (1950) Spondylolisthesis with an intact neural arch: the so called pseudospondylolisthesis. J Bone Joint Surg 32:325
55. Madan S, Boeree NR (2002) Outcome of posterior lumbar interbody fusion versus posterolateral fusion for spondylolytic spondylolisthesis. Spine 27:1536 – 1542
56. Marchettei PG, Bartolozzi P (1997) Spondylolisthesis: classification of spondylolisthesis as a guideline for treatment. In: The textbook of spinal surgery, 2nd edn. Lippincott-Raven, Philadelphia, pp 1211 – 1254
57. Matsunaga S, Ijiri K, Hayashi K (2000) Nonsurgically managed patients with degenerative spondylolisthesis: a 10- to 18-year follow-up study. J Neurosurg 93:194 – 198
58. Matsunaga S, Sakou T, Morizono Y, et al. (1990) Natural history of degenerative spondylolisthesis: pathogenesis and natural course of the slippage. Spine 15:1204 – 1210
59. McAfee PC, Yuan HA (1982) Computed tomography in spondylolisthesis. Clin Orthop Rel Res 166:62 – 71
60. McAfee PC, DeVine JG, Chaput CD, Prybis BG, Fedder IL, Cunningham BW, Farrell DJ, Hess SJ, Vigna FE (2005) The indications for interbody fusion cages in the treatment of spondylolisthesis: analysis of 120 cases. Spine 30:S60 – 5
61. McGregor AH, Anderton L, Gedroye WM, et al. (2002) The use of interventional open MRI to assess the kinematics of the lumbar spine in patients with spondylolisthesis. Spine 27: 1582 – 1586
62. McGuire RA, Amundson GM (1993) The use of primary internal fixation in spondylolisthesis. Spine 18:1662 – 1672
63. McNally DS, Adams MA (1992) Internal intervertebral disc mechanics as revealed by stress profilometry. Spine 17:66 – 73
64. McNally DS, Shackleford IM, Goodship AE, et al. (1996) In vivo stress measurement can predict pain on discography. Spine 21:2580 – 2587
65. Meyerding HW (1932) Spondylolisthesis. Surg Gynecol Obstet 54:371 – 380
66. Miyakoshi N, Abe E, Shimada Y, et al. (2000) Outcome of one-level posterior lumbar interbody fusion for spondylolisthesis and postoperative intervertebral disc degeneration adjacent to the fusion. Spine 25:1837 – 1842

67. Molinari RW, Bridwell KH, Lenke LG, Baldus C (2002) Anterior column support in surgery for high-grade, isthmic spondylolisthesis. Clin Orthop Rel Res 394:109 – 120
68. Moller H, Hedlund R (2000) Surgery versus conservative management in adult isthmic spondylolisthesis: a prospective randomized study: part 1. Spine 25:1711 – 1715
69. Moller H, Hedlund R (2000) Instrumented and noninstrumented posterolateral fusion in adult spondylolisthesis: a prospective randomized study: part 2. Spine 25:1716 – 1721
70. Moller H, Sundin A, Hedlund R (2000) Symptoms, signs, and functional disability in adult spondylolisthesis. Spine 25:683 – 689
71. Montgomery DM, Fischgrund JS (1994) Passive reduction of spondylolisthesis on the operating room table: a prospective study. J Spinal Disord 7:167 – 172
72. Morita T, Ikata T, Katoh S, Mirake R (1995) Lumbar spondylolysis in children and adolescents. J Bone Joint Surg 77:620 – 625
73. Morscher E, Gerber B, et al. (1984) Surgical treatment of spondylolisthesis by bone grafting and direct stabilization of spondylolysis by means of a hook screw. Arch Orthop Trauma Surg 103:175 – 178
74. Muschik M, Zippel H, Perka C (1997) Surgical management of severe spondylolisthesis in children and adolescents: anterior fusion in situ versus anterior spondylodesis with posterior transpedicular instrumentation and reduction. Spine 22:2036 – 2042
75. Nachemson AL, Schultz AB, Berkson MH (1979) Mechanical properties of human lumbar spine motion segments. Spine 4:1 – 8
76. Nematbakhsh A, Crawford AH (2004) Non-adjacent spondylolisthesis in Ehlers-Danlos syndrome. J Pediatr Orthop (B) 13:336 – 339
77. Neuwirth M (1981) Dysplastic and isthmic spondylolisthesis. Bull Hosp Joint Dis Orthop Int 41:94 – 104
78. Newman PH (1963) The etiology of spondylolisthesis. J Bone Joint Surg 45(Br):39 – 43
79. Ogilvie JW (2005) Complications in spondylolisthesis surgery. Spine 30:97 – 101
80. Osterman K, Lindholm TS, Laurent LE (1976) Late results of removal of the loose posterior element (Gill's operation) in the treatment of lytic lumbar spondylolisthesis. Clin Orthop Relat Res 117:121 – 8
81. Pennell RG, Maurer AH, Bonakdarpour A (1985) Stress injuries of the pars interarticularis: a radiological classification and indications for scintigraphy. Am J Rad 145:763 – 766
82. Pizzutillo PD, Mirenda W, MacEwan GD (1986) Posterolateral fusion for spondylolisthesis in adolescence. J Pediatr Orthop 6:311 – 316
83. Rahm M, Hall B (1996) Adjacent-segment degeneration after lumbar fusion with instrumentation: a retrospective study. J Spinal Disord 9:392 – 400
84. Ranson CA, Kerslake RW, Burnett AF, Batt ME, Abdi S (2005) Magnetic resonance imaging of the lumbar spine in asymptomatic professional fast bowlers in cricket. J Bone Joint Surg 87:1111 – 1116
85. Rosenberg NJ (1975) Degenerative spondylolisthesis: predisposing factors. J Bone Joint Surg (Am) 57:467 – 474
86. Rowe GG, Roche MB (1953) The etiology of separate neural arch. J Bone Joint Surg (Am) 35:102 – 110
87. Ruf M, Melcher R, Merk H, Harms J (2006) Anatomic reduction and monosegmental fusion for high-grade developmental spondylolisthesis L5/S1. Z Orthop Ihre Grenzgeb 144:33 – 9
88. Saal JA (1989) Comprehensive nonoperative care of lytic spondylolisthesis: principles and practice. In: Wiesel SW, Weinstein JN, Herkowitz H, Dvorak J, Bell G (eds) The lumbar spine, vol. 2, 2nd edn. Saunders, Philadelphia, pp 654 – 669
89. Sailhan F, Gollogly S, Roussouly P (2006) The radiographic results and neurologic complications of instrumented reduction and fusion of high-grade spondylolisthesis without decompression of the neural elements: a retrospective review of 44 patients. Spine 31: 161 – 9
90. Saraste H (1987) Long term clinical and radiological follow-up of spondylolysis and spondylolisthesis. J Pediatr Orthop 7:631 – 638
91. Schlenzka D, Remes V, Helenius I, Lamberg T, Tervahartiala P, Yrjonen T, Tallroth K, Osterman K, Seitsalo S, Poussa M (2006) Direct repair for treatment of symptomatic spondylolysis and low-grade isthmic spondylolisthesis in young patients: no benefit in comparison to segmental fusion after a mean follow-up of 14.8 years. Eur Spine J 15:1437 – 47
92. Schnee CL, Freese A, Ansell LV (1997) Outcome analysis for adults with spondylolisthesis treated with posterolateral fusion and transpedicular screw fixation. J Neurosurg 86:56 – 63
93. Schoenecker PL, Cole HO, Herring JA (1990) Cauda equina syndrome after in situ arthrodesis for severe spondylolisthesis at the lumbosacral junction. J Bone Joint Surg (Am) 72:369 – 377
94. Schufflebarger HL, Geck MJ (2005) High-grade isthmic dysplastic spondylolisthesis. Monosegmental surgical treatment. Spine 30:42 – 48
95. Schwab FJ, Farcy JPC, Roye DP Jr (1997) The sagittal pelvic tilt index as a criterion in the evaluation of spondylolisthesis. Spine 22:1661 – 1667
96. Scott JC (1953) Spinal fusion. J Bone Joint Surg 35-B:169 – 71
97. Sengupta DK (2004) Dynamic stabilization devices in the treatment of low back pain. Orthop Clin North Am 35:43 – 56

98. Sengupta DK, Herkowitz HN (2005) Degenerative spondylolisthesis. Review of current trends and controversies. Spine 6:71 – 81
99. Sponseller PD, Hobbs W, Riley LH, et al. (1995) The thoracolumbar spine in Marfan's syndrome. J Bone Joint Surg (Am) 77:867 – 876
100. Spruit M, Pavlov PW, Leitao J, et al. (2002) Posterior reduction and anterior lumbar interbody fusion in symptomatic low-grade adult isthmic spondylolisthesis: short-term radiological and functional outcome. Eur Spine J 11:428 – 433
101. Stanitski CL, Stanitski DF, LaMant RL (1994) Spondylolisthesis in myelomeningocele. J Pediatr Orthop 14:586 – 591
102. Stanton RP, Meehan P, Lovell WW (1985) Surgical fusion in childhood spondylolisthesis. J Pediatr Orthop 5:411 – 415
103. Sugiura Y (1978) Tricho-rhino-phalangeal syndrome associated with Perthes disease-like bone changes and spondylolisthesis. J Hum Genet 23:23
104. Suk KS, Jeon CH, Park MS, et al. (2001) Comparison between posterolateral fusion with pedicle screw fixation and anterior interbody fusion with pedicle screw fixation in adult spondylolytic spondylolisthesis. Yonsei Med J 42:316 – 323
105. Suk SI, Lee CK, Kim WJ, et al. (1997) Adding posterior lumbar interbody fusion to pedicle screw fixation and posterolateral fusion after decompression in spondylolytic spondylolisthesis. Spine 22:210 – 219
106. Swan J, Hurwitz E, Malek F, van den Haak E, Cheng I, Alamin T, Carragee E (2006) Surgical treatment for unstable low-grade isthmic spondylolisthesis in adults: a prospective controlled study of posterior instrumented fusion compared with combined anterior-posterior fusion. Spine J 6:606 – 14
107. Tabrizi P, Bouchard JA (2001) Osteoporotic spondylolisthesis. Spine 26:1482
108. Taillard W (1954) Les spondylolisthesis chez enfant l'adolescent. Acta Orthop Scand 24:115 – 144
109. Throckmorton T, Hilibrand A, Mencio A, et al. (2003) The impact of adjacent level disc degeneration on health status outcomes following lumbar fusion. Spine 28:2546 – 2550
110. Troup JDG (1976) Mechanical factors in spondylolisthesis and spondylolysis. Clin Orthop 117:59 – 67
111. Vaccaro AR, Ring D, Scuderi G, et al. (1997) Predictors of outcome in patients with chronic back pain and low-grade spondylolisthesis. Spine 22:2030 – 2034
112. Valkenburg HA, Haanen HCM (1982) The epidemiology of low back pain. In: White AA, Gordon SL (1982) Proc Am Assoc Orthop Surg Symposium on Low Back Pain:9 – 22
113. Vogt MT, Rubin DA, Valentin RS, et al. (1998) Lumbar olisthesis and lower back symptoms in elderly white women: the study of osteoporotic fractures. Spine 23:2640 – 2647
114. Vogt MT, Rubin DA, Valentin RS, et al. (1999) Degenerative lumbar listhesis and bone mineral density in elderly women. Spine 24:2536 – 2541
115. Whitesides TE, Horton WC, Hutton WC, Hodges L (2005) Spondylolytic spondylolisthesis. A study of pelvic and lumbosacral parameters of possible etiologic effect in two genetically and geographically distinct groups with high occurrence. Spine 30:S12 – S21
116. Willburger RE (2004) Spondylolyse und Spondylolisthese. In: Wirth CJ, Zichner L. Orthopädie und Orthopädische Chirurgie – Wirbelsäule und Thorax. Ed. Crämer J., 1st ed. Georg Thieme Verlag, Stuttgart New York, pp 191 – 202
117. Wiltse LL, Jackson DW (1976) Treatment of spondylolisthesis and spondylolysis in children. Clin Orthop Relat Res 117:92 – 100
118. Wiltse LL, Newman P, MacNab I (1976) Classification of spondylolysis and spondylolisthesis. Clin Orthop 117:23 – 29
119. Wiltse LL, Rothmann LG (1989) Spondylolisthesis: Classification, diagnosis, and natural history. Semin Spine Surg 1:78 – 94
120. Wiltse LL, Widell EH, Jackson DW (1975) Fatigue fracture: the basic lesion is isthmic spondylolisthesis. J Bone Joint Surg 57:17 – 22
121. Wiltse LL, Winter R (1983) Terminology and measurement of spondylolisthesis. J Bone Joint Surg 65A:768 – 772
122. Winter RB (1982) Severe spondylolisthesis in Marfan's syndrome: report of 2 cases. J Pediatr Orthop 2:51 – 53
123. Zhao J, Hou T, Wang X, et al. (2003) Posterior lumbar interbody fusion using one diagonal fusion cage with transpedicular/rod fixation. Eur Spine J 12:173 – 177
124. Zhao J, Liu F, Shi HG, et al. (2006) Biomechanical and clinical study on screw hook fixation after direct repair of lumbar spondylolysis. Chin J Traumatol 9:288 – 92

# 28 Juvenile Kyphosis (Scheuermann's Disease)

Dietrich Schlenzka, Vincent Arlet

## Core Messages

- ✔ Scheuermann's disease (Type I, "classic" Scheuermann's) is a thoracic or thoracolumbar hyperkyphosis due to wedged vertebrae developing during adolescence
- ✔ Atypical Scheuermann's disease (Type II, "lumbar" Scheuermann's) affects the lumbar spine and/or the thoracolumbar junction. It is a growth disturbance of the vertebral bodies **without** significant wedging causing loss of lumbar lordosis or mild kyphosis
- ✔ The natural history of the deformity is benign in the majority of cases
- ✔ Back pain is common but usually mild and rarely interferes with daily activities or professional career
- ✔ Lung function is impaired only in very severe deformities (> 100 degrees)
- ✔ Diagnosis is based on the clinical picture and typical changes in plain lateral radiographs
- ✔ During growth, brace treatment is recommended in mobile deformities of between 45 and 60 degrees
- ✔ Rare spinal cord compression is the only absolute indication for operation
- ✔ Relative indications for operation are kyphosis greater than 70 degrees, pain, and cosmetic impairment
- ✔ The results of operative treatment are satisfactory in the majority of cases regarding pain and cosmesis
- ✔ The risk of severe intra- and postoperative complications should be weighed carefully against the benefits

## Epidemiology

Scheuermann's disease is a **thoracic** or **thoracolumbar hyperkyphosis** due to wedged vertebrae developing during adolescence. Ancient presentations of hyperkyphosis usually depict extreme gibbus formations as seen due to infection (tuberculosis) or congenital vertebral anomalies. Michelangelo's ceiling fresco in the Sistine Chapel at the Vatican shows an ignudo with a kyphosis resembling a thoracolumbar juvenile kyphosis (Fig. 1). It was painted in 1511 and is possibly the earliest pictorial representation of the disease [30]. Following Schanz, Haglund named the deformity "*Lehrlingskyphose*" (**apprentice's kyphosis**) as it was detected mainly in youngsters involved in heavy labor [27, 61]. He saw the cause as muscular insufficiency and mechanical overloading during growth. Credit is due to **Holger Werfel Scheuermann** from Denmark for first describing it in 1920 as being different from mobile postural kyphosis [62–64]. He recognized from radiographs that the wedge vertebrae formation in the thoracic spine was the underlying reason for the deformity. Scheuermann was the first to describe its typical radiographic features and named it "**osteochondritis deformans juvenilis dorsi**". The true incidence of juvenile kyphosis is not known. It ranges from 1% to 8%, being more common in boys than in girls (ratio 2/1 to 7/1).

Scheuermann's disease is a thoracic or thoracolumbar hyperkyphosis due to wedged vertebrae

The incidence of juvenile kyphosis ranges between 1% and 8%, being more common in boys

## Case Introduction

A 14-year-old boy was referred by the school doctor. The boy was otherwise healthy and played hockey and soccer regularly. Four years previously, posture changes were detected for the first time. The boy had pain in the thoracolumbar area since then during the day and especially after playing sports. Sometimes night pain in the back also occurred. No radiating pain to the lower extremity was present. There were no back problems in the family. Clinically, the boy appears to be healthy. Height is 153 cm, sitting height 77.5 cm. The spine is balanced in the frontal as well as in the sagittal plane. Shoulders and pelvis are leveled. The thoracic kyphosis is pronounced especially in the mid-thoracic area (a). Kyphosis corrects partially during spine extension in the prone position. The left scapula is slightly elevated. A mild left convex thoracic scoliosis with 3 degrees of rib hump is present (b). Lumbar lordosis appears normal. Lumbar range of motion is free. On palpation, the spine is free of pain. Hamstring tightness of 70 degrees is present bilaterally. No neurological abnormalities are found in the lower extremity. Abdominal skin reflexes are symmetrical. On the standing lateral radiograph, thoracic kyphosis measures 56 degrees, lumbar lordosis 55 degrees (c). There are Scheuermann's changes in the T6–T10 vertebral bodies. On supine extension radiographs, thoracic kyphosis has corrected to 30 degrees. The skeletal age is 13.5 years, i.e. 6 months behind the chronological age (d). As the kyphosis is mobile, a sufficient amount of growth is left, and the boy seems to be well motivated, brace treatment is initiated (e, f). The correction in the brace is very acceptable. The thoracic kyphosis decreases from 56 to 42 degrees (g). The brace is worn full-time (23 h/day). It may, however, be removed for sports training hours. Daily exercises including pectoralis stretching, hamstring stretching, and back and abdominal muscle strengthening are advocated.



**Figure 1. Michelangelo's Ignudo**

This painting (1511) exhibits a Scheuermann's kyphosis at the thoracolumbar junction.

## Pathogenesis

The exact causes are unknown

The exact etiology of Scheuermann's kyphosis is unknown. Genetic, hormonal, and mechanical factors have been discussed. An autosomal dominant pattern of inheritance has been described [21, 28]. Scheuermann considered it a **growth disturbance in the vertebral epiphysis** resembling Calvé-Perthes disease. He therefore named it osteochondritis deformans juvenilis dorsi [64]. Aufdermaur reported a developmental error in collagen aggregation leading to a disturbance of the enchondral ossification of the vertebral endplates [3]. Ippolito and Ponsetti detected a mosaic-like pattern of alterations in the growth cartilage and vertebral endplates. The collagen fibers in the matrix are thinner and their number is diminished. The proteoglycan content of the matrix is increased. The growth process is slowed down or even absent in the altered areas. The process should be interpreted as an "**absence of growth**" rather than a destruction [2]. In the normal areas growth is accelerated. This causes wedge-shaped deformation of vertebrae and an increase in kyphosis [2, 32, 33]. For biomechanical reasons, increased kyphosis causes increased pressure to the vertebral bodies which the pathologic bone cannot withstand. This creates a **vicious circle** of increased wedging and increased kyphosis leading to increased load on the vertebral bodies. There are no data available on the rate of progression after cessation of growth.

Juvenile kyphosis has a genetic background and develops due to an ossification disturbance of the vertebral bodies

The sources of pain are not very well defined. **Pain** symptoms in the adolescent can arise from the posture changes. The musculature is insufficient to counteract the increasing kyphosis during the growth spurt. This causes **fatigue** in the paravertebral muscles. Pain in the neck region and in the lumbar spine is caused by **compensatory hyperlordosis** above or below the primary deformity. It develops when the degree of the primary deformity exceeds the capacity of the adjacent segments to adapt to it. In the adult patient, disc degeneration and facet joint osteoarthritis may be the reason for pain in the kyphotic vertebral segment as well as in the segments above and below.

## Normal Sagittal Profile

The sagittal profile develops during growth and changes throughout adult life

Classic **Scheuermann's disease** is a thoracic or thoracolumbar hyperkyphosis, which implies that kyphosis deviates from the normal sagittal curvature of the spine. Therefore, a thorough knowledge of the normal sagittal profile is required for the understanding of this clinical entity. The **sagittal profile** of the spine in humans varies greatly between individuals. It is not established at birth but develops and changes during life [5, 46, 68, 69, 72, 75].

The sagittal profile of the spine is largely variable

There is no scientifically based definition of the degree of normal sagittal spinal curvatures. At birth, the whole spine is kyphotic from the occiput to the coccyx. As the child starts in the upright position, first lumbar lordosis develops and later thoracic kyphosis. It is only when the child becomes a young adult that the definitive sagittal curves are acquired. Confusingly, different methods for measurement of the sagittal curvatures of the spine are used in the literature. Measured from the back surface using spinal pantography, at the age of 14 years thoracic kyphosis in healthy children ranges from 7 to 57 degrees (mean 29 degrees) in girls and from 6 to 69 degrees (mean 30 degrees) in boys, being between 20 and 40 degrees in more than two-thirds of children [46]. In a mixed population with an age range from 4.6 to 29.8 (mean 12.8) years, Bernhart et al. found **thoracic kyphosis** ranging from 9 to 53 (mean 36) degrees measured from standing lateral radiographs between the top of T3 and the bottom of T12. They proposed a normal range from 20 to 50 degrees [5]. In healthy adults, Stagnara et al. measured from standing radiographs thoracic kyphosis from 7 to 63 (mean 37) degrees between the top of T4 and the bottom of the intermediate vertebra (mainly L1, T12, or L2), with the majority being between 30 and 50 degrees [69]. They did not find, however, any hint that those individuals outside the 30–50 degree range were functionally inferior. Vaz et al. reported a global thoracic kyphosis ranging from 25 to 72 (mean 47) degrees [73]. Boulay et al. [9] used true Cobb angle measurements, i.e. they measured thoracic kyphosis from the upper endplate of the most tilted vertebra cranially to the lower endplate of the most tilted vertebra caudally. In 149 healthy adults, they found a range from 33.2 to 83.5 (mean 53.8) degrees. The **Scoliosis Research Society** proposes to regard **10–40 degrees** as the range for normal kyphosis between the upper endplate of T5 and the lower endplate of T12 [51]. Thoracic kyphosis increases in the elderly due to degenerative changes.

Normal kyphosis is in the range of 10° to 60°

Thoracic kyphosis is more prominent in males

There are significant differences between the genders. Thoracic kyphosis is **more prominent in males**. There is a steady increase from adolescence to adulthood. In females, thoracic kyphosis increases during the adolescent growth spurt but decreases during the descending phase of peak growth, i.e. until young adulthood. Thoracic hyperkyphosis (≥45 degrees) is equally prevalent in both genders at the age of 14 years, but more prevalent in males (9.6%) than in females at the age of 22 years [57]. Left-handedness was identified as a risk factor for thoracic hyperkyphosis but no significant correlation between hyperkyphosis and low-back pain during adolescence could be established [47, 48].

There is no scientifically based definition of the threshold for "normal" kyphosis. So-called normal ranges in the literature are derived from cohort measurements using statistical methods. These figures, however, should not be used as such for deciding what is pathologic in the individual. Thoracic kyphosis should always be judged in view of the balance of the entire spine, not as an isolated part of it. The thoracolumbar junction from T10 to L2 is slightly kyphotic [5]. The **upper thoracolumbar junction** (T10–T12) varies from 3 degrees of lordosis to 20 degrees of kyphosis (mean 5.5 degrees of kyphosis). The **lower thoracolumbar junction** (T12–L2) ranges from 23 degrees of lordosis to 13 degrees

of kyphosis (mean 3 degrees of kyphosis). The segment T12–L1 is on average in 1 degree of kyphosis [5]. **Lumbar lordosis** is normally somewhat greater than thoracic kyphosis. On average, lumbar lordosis is more pronounced in females. It is relatively constant during growth from adolescence to young adulthood [57]. In girls, lumbar lordosis measured from the back surface using the spinal pantograph ranges from 18 to 55 (mean 33.4) degrees at the age of 14 years and from 18 to 72 (mean 37.8) degrees at the age of 22 years. In boys, the corresponding figures are 15 – 56 (mean 33) degrees and 11 – 58 (mean 34.6) degrees [57]. According to Bernhart and Bridwell, the range of lumbar lordosis measured from standing radiographs between the bottom of T12 and the bottom of L5 is 14 – 69 (mean 44) degrees. They propose a normal range of from 20 to 60 degrees [5]. Stagnara et al. reported a range for lumbar lordosis of from 32 to 84 degrees. The higher values may be explained by the fact that these authors measured the lumbar lordosis from the upper border of the intermediate vertebra down to the upper endplate of S1 [69]. Bouley et al. [9] reported in adults a lordosis ranging from 44.8 to 87.2 (mean 36.4) degrees measured according to Cobb between the most tilted vertebrae. Vaz et al. measured in adults a global lumbar lordosis ranging from 26 to 76 (mean 46.5) degrees [73]. The Scoliosis Research Society proposes to regard 40 – 60 degrees as a normal range of lumbar lordosis for the adult measured between the upper endplate of T12 and the upper endplate of S1 [51]. Lumbar lordosis decreases in the elderly due to degenerative changes.

Lumbar lordosis is more pronounced in females

A range of 20° to 60° is regarded as normal lordosis

According to Stagnara et al., every person has her or his "unique spinal physiognomy" [69]. Average values are only indicative not normative [5, 69]. There is no indication that persons with a degree of thoracic kyphosis not fitting into the postulated "normal range" are handicapped in any respect.

The threshold for "normal" thoracic kyphosis is not defined

**Sagittal balance** is of the utmost importance for an ergonomic upright posture. The spine is sagittally balanced if a plumb line dropped from the odontoid process crosses the thoracolumbar junction and through the posterior edge of S1. For practical purposes on radiographs, the plumb line is often drawn from the center of the vertebral body C7 [51] (Fig. 2a–c). Normal sagittal balance is essential for the ability of the individual to stand in the upright position with minimal effort. Abnormal sagittal balance will be observed when the spinal column cannot compensate to keep the gravity line between the femoral heads and the sacrum. **Spinal imbalance** is positive when the gravity line falls in front of the femoral heads. It is negative when the gravity line falls posterior to the sacrum.

This is important to consider. A negative sagittal balance may be observed in neuromuscular conditions with weak hip extensors. A positive sagittal balance may be observed in patients with developmental delay, loss of lumbar lordosis (flat back), or rigid kyphotic lumbar spine. Most Scheuermann patients fall into the category of negative sagittal balance [31, 40, 41].

Normal sagittal spinal balance is the prerequisite for an economic upright posture in the standing position

When judging the importance of a thoracic hyperkyphosis, one not only has to take into account the absolute measure of the deformity in degrees, but one must also assess it in relation to the location of the apex of the kyphosis. The lower the apex of the hyperkyphosis the greater its impact on spinal balance and on the adjacent spinal segments below (compensatory lumbar hyperlordosis). For instance, a thoracolumbar kyphotic deformity of 20 degrees between T10 and L3 has a much higher impact on the sagittal balance than a thoracic hyperkyphosis of 55 degrees between T2 and T12, which may be clinically unimportant.

The **concept of pelvic incidence** has recently been introduced by Duval Beaupere [36]. Pelvic incidence is defined as the angle between the perpendicular to the top of S1 and the line joining the middle of S1 to the femoral heads (Fig. 3). It was found that the pelvic incidence was the only morphometric character that is constant throughout life. A strong correlation between the pelvic incidence and the lumbar lordosis has been defined. Pelvic incidence regulates the sagittal

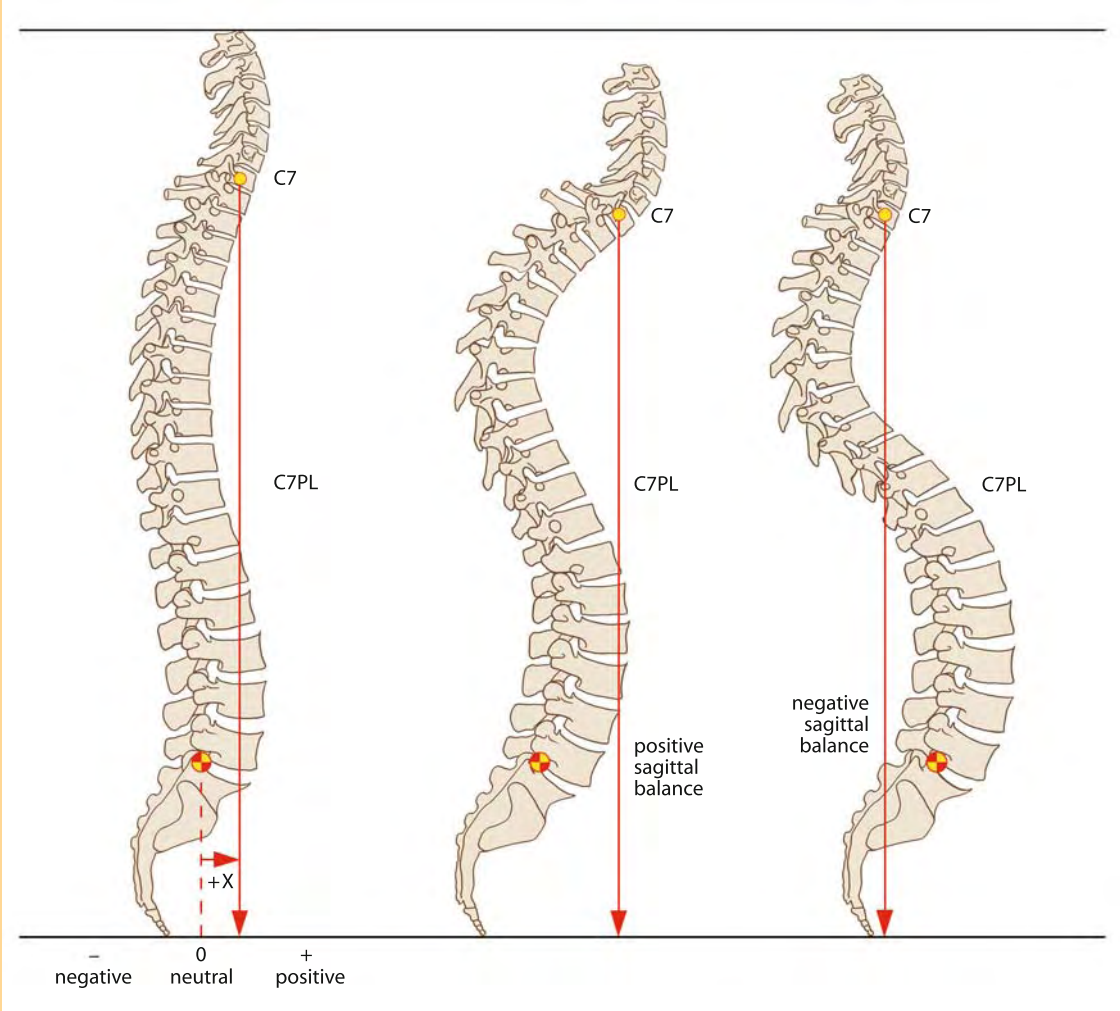


**Figure 2. Sagittal balance**

a The spine is sagittally balanced when the plumb line from C7 touches the posterior edge of S1. b Spinal imbalance is positive when the line falls in front of this point. c It is negative when the plumb line falls behind this point.

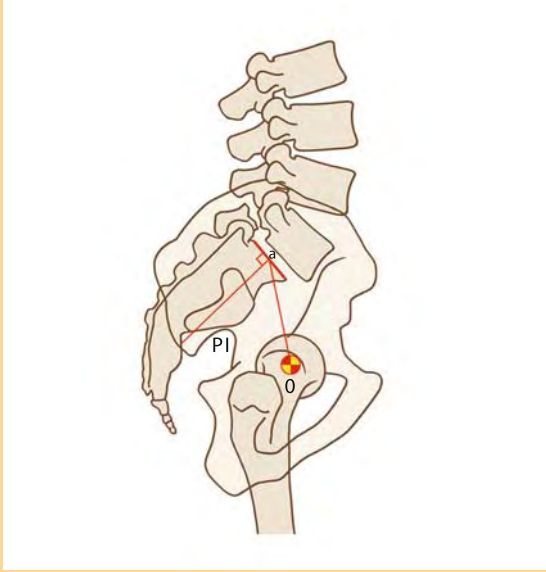


**Figure 3. Pelvic incidence (PI)**

*a* = midpoint of the sacral endplate, *0* = center of the femoral head.

alignment of the spine and pelvis [9, 36, 73]. As a rule of thumb, lumbar lordosis is approximately 10 degrees greater than the pelvic incidence in normal individuals. However, no study has focused yet on any possible relationship between pelvic incidence and Scheuermann's kyphosis.

## Definition and Classification

According to Sörensen [65], the diagnostic criteria are wedging of more than 5 degrees in three consecutive vertebrae with typical endplate irregularities on a lateral radiograph. A **widely accepted definition** is based on Bradford [11]:

- irregular vertebral endplates
- narrowing of the intervertebral disc space
- one or more vertebrae wedged 5 degrees or more
- an increase of normal kyphosis beyond 40 degrees

Both Sörensen's and Bradford's definitions do have their shortcomings since they are arbitrary. Sörensen's criteria exclude deformities with less than three deformed vertebrae. Bradford's 40 degrees of thoracic kyphosis as the borderline between normal and pathologic has its origin in an unpublished X-ray study by Boseker, who found a range of 25–42 degrees in 121 normal children [8, 10]. This is extremely low in comparison to the ranges for thoracic kyphosis in healthy individuals reported later by other investigators (see above). Besides, it cannot be generalized for the different regions of the spine. In the authors' opinion, the diagnosis should be based mainly on the typical pathologic vertebral and disc changes. Bearing in mind the immense variability of the sagittal profile in healthy persons, it seems inappropriate to base the diagnosis on a certain amount of (hyper-)kyphosis measured in degrees (Table 1) (Fig. 4a):

**Table 1. Diagnostic criteria for juvenile kyphosis (Type I)**

- wedging of more than 5 degrees in one or more vertebrae in the thoracic or thoracolumbar region
- endplate irregularities
- disc space narrowing
- increased thoracic or thoracolumbar kyphosis

Schmorl's nodes are not pathognomonic

**Schmorl's nodes** are often associated with juvenile kyphosis but are not a pathognomonic sign.

The classification of Scheuermann's disease concerning its localization in the spine is inconsistent in the literature. In the classic sense, it is a deformity of the thoracic spine. Lindemann reported in 1933 four cases with affection of the lumbar spine and called the condition the "**lumbar form of adolescent kyphosis**" [37]. Lumbar Scheuermann's disease as a separate entity was described in more detail by Edgren and Vaino [19]. Out of 900 radiographs of Scheuermann's patients, they found 30 cases with distinct radiographic features in the lumbar spine. During the growth period (initial stage), they recognized a typical local defect in the spongiosa in the ventral part of the endplates of one or several vertebral bodies (Fig. 4c). After the end of growth (final stage), the contours of the vertebral endplates were uneven. Schmorl's nodes and disc prolapses dislocating the border of the vertebra were seen. Intervertebral disc spaces were narrowed. A slight angular kyphosis was present, and the sagittal diameter of the vertebral bodies was increased. Clinically, the patients showed flattening of the lumbar lordosis or a slight kyphosis, stiffness, and tenderness of the lumbar spine. No root symptoms were seen. They coined the term "**osteochondrosis juvenilis lumbalis**" (atypical juvenile kyphosis) (Table 2).

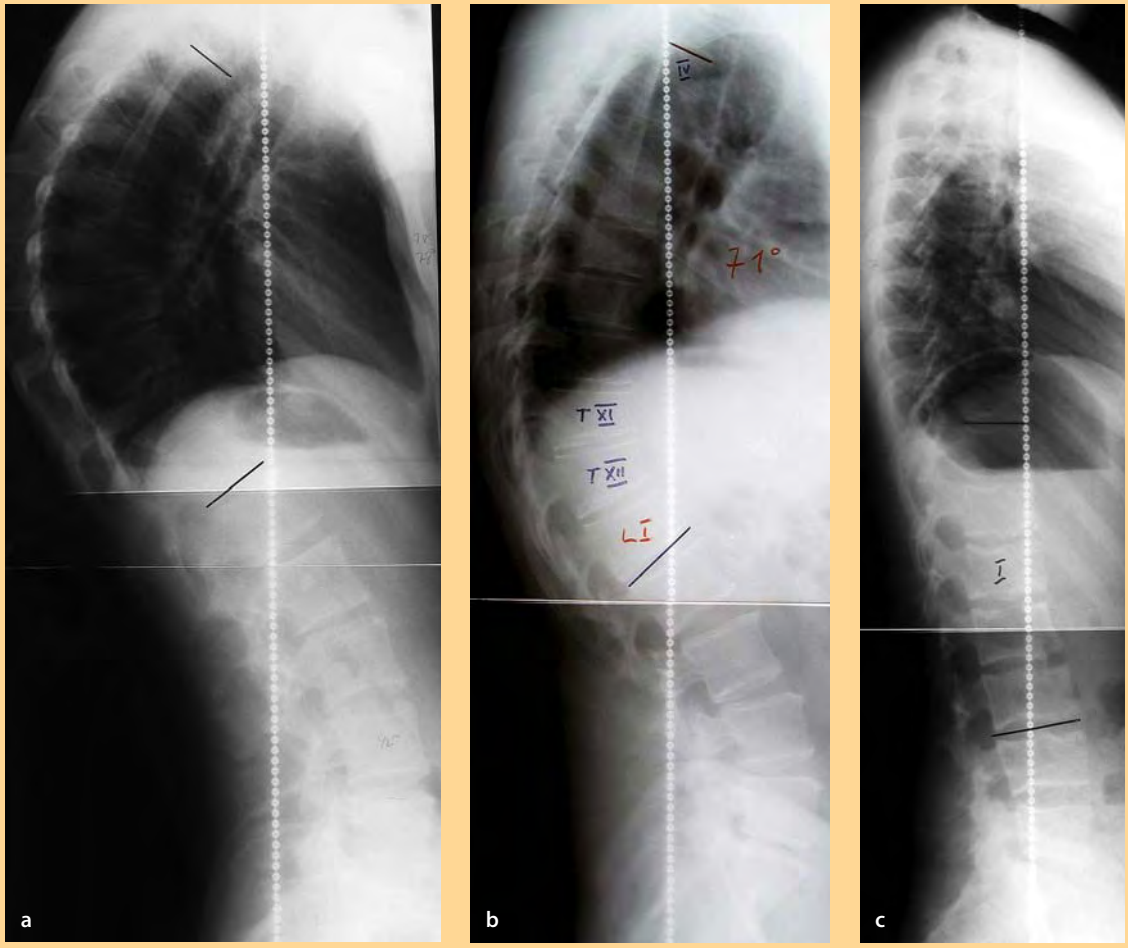


**Figure 4. Types of juvenile kyphosis**

a Standing lateral radiographs of juvenile kyphosis Type I changes in the thoracic spine in an 18-year-old male and b thoracolumbar area in a 52-year-old male. Scheuermann's Type II changes from L1 to L4 in an 18-year-old female gymnast. The thoracolumbar junction is slightly kyphotic. c Note the decrease in thoracic kyphosis.

**Table 2. Diagnostic criteria for juvenile kyphosis (Type II, "lumbar")**

| Obligatory | Facultative |
|---|---|
| • endplate irregularities in one or several vertebral bodies of the lumbar or thoracolumbar area | • apophyseal separation |
| • increased sagittal diameter of vertebral bodies | • loss of lumbar lordosis or slight kyphosis |
| • disc space narrowing | • Schmorl's node |

Blumenthal et al. defined cases with involvement from T10 to L4 as lumbar juvenile kyphosis. They proposed **three different types:**

- I: "classic" juvenile kyphosis (three or more consecutive vertebrae each wedged over 5 degrees)
- IIa: "atypical" juvenile kyphosis (endplate irregularities, anterior Schmorl's nodes, disc space narrowing)
- IIb: acute traumatic intraosseous disc herniation (after acute vertical compression injury) [7]

Wenger proposes a distinction between Type I (thoracic, with wedging), being the most common form, and Type II (thoracolumbar, lumbar), developing at a slightly later age and being more commonly painful. A mechanical overloading is thought to be its basis. Murray et al., in their natural history study, divided the patients according to the apex level of the kyphosis into "cephalad" (apex at T1–T8) and "caudad" (apex at T9–T12) [44].

The confusion arising from these different classifications seems to be mainly due to the fact that localization and pathoanatomical picture are mingled. Typical wedging (classical juvenile kyphosis, Type I) occurs usually in the thoracic spine but it may also cross the thoracolumbar junction and reach into the upper lumbar spine (Fig. 4b). Endplate impressions, disc narrowing, and increased sagittal diameter of the vertebral bodies **without significant wedging** (**lumbar "atypical" juvenile kyphosis**, **Type II**), as described by Edgren and Vainio, seem to occur only in the lumbar spine up to the thoracolumbar junction (Table 2). Possibly both types are expressions of the same pathology. Severe wedging does not develop in the primarily lordotic lumbar spine due to the fact that the loading conditions are different from those in the primarily kyphotic thoracic spine [37]. Type II Scheuermann's disease is commonly attributed to mechanical overloading [23, 40, 74]. However, in the reports of Edgren and Vainio as well as Blumenthal et al., the majority of patients had not been involved in heavy physical activity [7, 19]. Obviously, there is an idiopathic form due to an "intrinsic" factor and a secondary form caused by mechanical overloading and endplate damage as seen in certain sports disciplines (weight lifting, gymnastics, motocross).

Severe wedging does not develop in the lordotic lumbar spine

For the purposes of clear communication, we propose to define the condition primarily according to the vertebral changes as Type I or Type II, respectively. If deemed necessary, one can then add the vertebral level(s) for specification.

## Clinical Presentation

### History

In the initial phase of the disease posture changes are not visible yet but back pain may be present.

The **cardinal symptoms** of juvenile kyphosis are:

- back pain
- cosmetic disturbance

Usually, juvenile kyphosis is detected first by caretakers or the school nurse or doctor (Case Introduction) when a visible deformity has already developed. During adolescence, pain in the region of the kyphosis may occur during **exercise or prolonged sitting**. In later adulthood, secondary cervical and lumbar hyperlordosis may cause pain symptoms also in the cervical and/or lumbar region. Segmental thoracic pain or lower extremity root pain has not been described. Back pain symptoms occur mainly during the day and under loading. They are more common in Type II as compared to Type I [7, 19, 23, 40, 74]. Murray et al. found in Type I that pain interfered significantly more with life if the kyphosis was more severe and the apex more cephalad (T1–T8). But **job activity level** and **pain intensity** were not dependent on the level of the apex of the kyphosis [44]. Patients with Type II Scheuermann's disease are prone to develop lumbar spinal stenosis [70]. As these patients often have a **genetic predisposition**, one should focus on the existence of a family history of a deformity. Previous fractures, infections and neurological disorders should be ruled out.

Back pain is activity dependent

Back pain is related to curve size and location

**Figure 5. Clinical appearance of juvenile kyphosis**

a Normal harmonic kyphosis of the spine in flexion. b, c A 16-year-old female with a thoracic hyperkyphosis of 88 degrees, apex T8. d, e A 20-year-old male with a low thoracic hyperkyphosis of 79 degrees, apex T10. f A 19-year-old male with Scheuermann's Type II; the upper lumbar spine is slightly kyphotic.

## Physical Findings

Rigid thoracic hyperkyphosis is the cardinal physical finding

When an adolescent patient presents with a thoracic or thoracolumbar hyperkyphosis, the diagnosis can be suspected at first glance. The **hyperkyphosis** is frequently accompanied by **compensatory hyperlordosis** of the cervical and/or lumbar spine (Fig. 5). The spine is balanced in the coronal plane but usually in a negative balance in the sagittal plane. The clinical examination aims to assess the **rigidity of the curve**. Asking the patient to lift the head and extend the spine in the prone position best assesses this aspect. Mild secondary scoliosis with minimal or no rotation may be present. The muscles in the region of the kyphosis or in hyperlordotic areas above (shoulder-neck region) or below (low back) the main deformity may be painful on palpation. **Hamstring tightness** is common. Neurology should be assessed carefully. Pathologic neurological findings, however, are very rare.

Distinguish juvenile kyphosis from idiopathic roundback

Usually it is easy to distinguish Scheuermann's kyphosis (Type I) from **idiopathic roundback**. In the latter, the hyperkyphosis is harmonic also in flexion. Moreover, it corrects well in extension.

In Type II Scheuermann's kyphosis, the typical clinical features are diminished lumbar lordosis (flat back) (Fig. 5f) or a very mild lumbar kyphosis, stiffness of the lumbar spine, and local pain.

## Diagnostic Work-up

### Imaging Studies

The definitive diagnosis of juvenile kyphosis can often be made by conventional radiographs alone. However, MRI best shows endplate abnormalities, premature disc degeneration, and vertebral wedging.

Computed tomography very seldom provides additional information and is rarely indicated.

#### Standard Radiographs

Juvenile kyphosis is diagnosed on standard radiographs

Plain lateral and posteroanterior radiographs of the whole spine with the patient in the standing position are the primary radiological investigations. In the lateral projection a more or less sharp hyperkyphosis of the thoracic spine with compensatory lumbar hyperlordosis is seen (Fig. 4b). If necessary, close-up radiographs are taken or MRI is performed to elucidate the bony structures in the area of interest.

The vertebrae around the apex of the thoracic kyphosis show **typical radiographic changes** (Fig. 6):

- irregularity of the endplates
- wedging of vertebral bodies
- increased length of vertebral bodies
- loss of disc space height
- Schmorl's nodes (not pathognomonic)

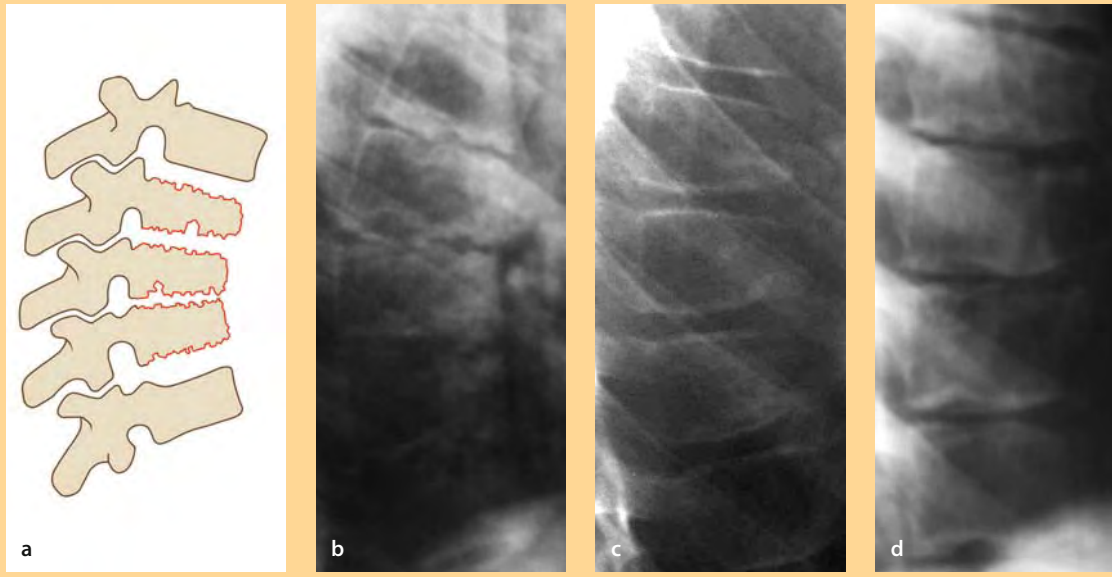


**Figure 6. Typical radiographic features (Type I)**

Wedge shape and increased sagittal diameter of vertebral bodies, irregularity of endplates, and disc space narrowing: a schematic drawing; b radiographic example. Radiographic changes with age: c 14-year-old boy and d 17-year-old boy.

Thoracic kyphosis and lumbar lordosis are measured according to Cobb. The posteroanterior radiograph is checked for secondary scoliosis. Sagittal and frontal spinal balance is assessed. **Extension films** of the kyphotic area obtained with the patient in the supine position with a sandbag under the apex of the deformity are used to assess flexibility of the deformity. In the immature patient, the skeletal age and the remaining spinal growth are determined from a radiograph of the hand and wrist [24] and the pelvis (**Risser sign**) for assessment of the risk of progression and treatment decision-making.

### Magnetic Resonance Imaging

In juvenile kyphosis, MRI is the imaging modality of choice to **demonstrate:**

- irregularity of the ossification
- wedge shape of the vertebral bodies (Fig. 7)
- premature degeneration of intervertebral discs
- Schmorl's nodes
- spinal cord compression at the curve apex (in severe cases)

MRI is indicated in unclear cases or for surgical planning

MRI of the whole spine should be performed if spinal cord compression, congenital anomalies, tumor or infection is suspected. For safety reasons, MRI is included in the preoperative work-up even if the patient's neurology is normal. There is no indication for an MRI on the first visit if the patient's clinical neuro-

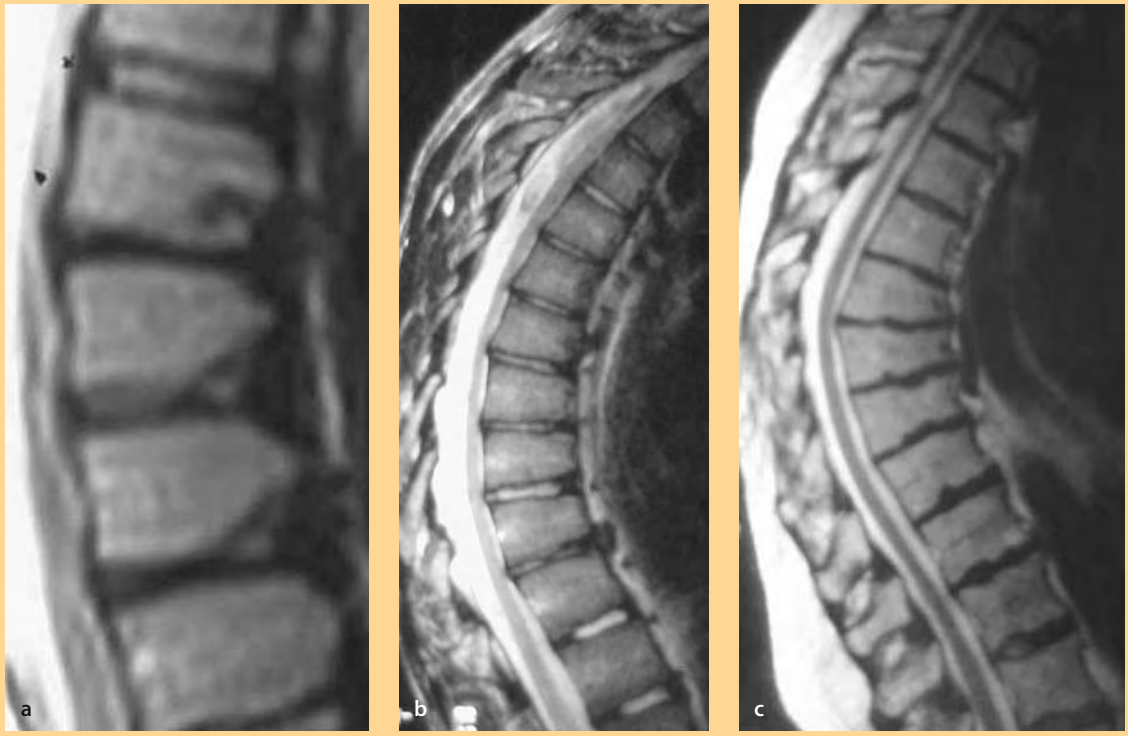


**Figure 7. MRI findings**

a MRI characteristics of juvenile kyphosis at different ages. In a 14-year-old boy (same as Fig. 5c), endplate defects, disc narrowing and disc dehydration are visible. In a 17-year-old boy (same as Fig. 5d), b vertebral wedging and disc space narrowing is more pronounced. In a 57-year-old male the final stage is visible. Note kinking of the myelon over the apex of the relatively sharp-angled kyphosis. c The patient has no neurological symptoms.

logical examination is normal, plain radiographs show the typical picture of juvenile kyphosis and observation or non-operative treatment is planned.

## Neurophysiological Tests

SSEPs and MEPs are helpful in identifying spinal cord compromise

Somatosensory evoked potentials (SSEPs) and motor evoked potentials (MEPs) are obtained in patients with neurological symptoms and in connection with preoperative work-up. MEPs are of greater importance as in kyphotic deformities cord compression is to be expected mainly from the anterior direction affecting primarily the motor tracts. Pathologic evoked potentials should alert the surgeon. The spine should be stabilized and, depending on the clinical situation and the imaging findings, anterior decompression should be considered.

## Lung Function Test

The data in the literature on lung function in juvenile kyphosis are sparse. Murray et al. found in their long-term follow-up of untreated patients decreased vital capacity only in cases with a kyphosis exceeding 100 degrees [44].

## Differential Diagnosis (Table 3)

Roundback is an important differential diagnosis

Several clinical entities must be differentiated from juvenile kyphosis:

- **Idiopathic thoracic hyperkyphosis** ("roundback", "poor posture") (Fig. 8)
  Clinically, postural thoracic hyperkyphosis is mobile, more harmonic, and not as localized as Scheuermann's kyphosis. On radiographs, there is no wedge deformation of vertebral bodies. Disc space height is not decreased. Usually, the deformity corrects on extension.
- **Congenital kyphosis**
  A defect of segmentation is sometimes difficult to see on lateral radiographs especially if it is incomplete. The anterior bar may still not be ossified. If the disc spaces are not clearly visible on plain radiographs in a rigid kyphosis, MRI should be performed.
- **Skeletal dysplasias**
  Different forms of systemic skeletal diseases can be ruled out based on the history, clinical appearance of the patient, and radiographs of long bones, joints, etc.
- **Infection and tumor**
  The patient's history, pain pattern, and clinical presentation should raise suspicions. Laboratory tests, radiographs, MRI, and (if necessary) biopsy will provide the diagnosis.

**Table 3. Differential diagnosis of juvenile kyphosis**

| | |
|---|---|
| • idiopathic hyperkyphosis ("roundback") | • connective tissue disorders |
| • neuromuscular (paralytic, spastic) | • congenital kyphosis |
| • spinal cord tumor | • skeletal dysplasia |
| • post-laminectomy kyphosis | • infection (tuberculosis, pyogenic, fungal) |
| • post-traumatic kyphosis | • tumor |

## Figure 8. Idiopathic thoracic hyperkyphosis

Idiopathic thoracic hyperkyphosis ("roundback") in a 19-year-old male. **a** Thoracic kyphosis is increased **b** but harmonic in flexion. The patient suffers from thoracic back pain during prolonged standing and sitting. He is neurologically intact. **c** On the standing lateral radiograph the thoracic kyphosis measures 66 degrees. There are no structural vertebral changes. **d** On the supine extension radiograph, the kyphosis has corrected to 26 degrees. **e** There are no pathologic changes on MRI.

## Non-operative Treatment

The **general objectives** of treatment are shown in Table 4.

| Table 4. General objectives of treatment | |
|---|---|
| • to prevent progression | • to correct severe deformity |
| • to relieve pain | • to improve cosmesis |

The **choice of the treatment** modality in Scheuermann's kyphosis **depends on**:

- age of the patient
- degree of the kyphosis
- subjective symptoms

The vast majority of patients with juvenile kyphosis can be treated non-surgically. Favorable indications for non-operative treatment are shown in Table 5. They include **exercise**, **bracing** and **casting**. However, physical exercise has not been shown to be clinically effective in terms of kyphosis improvement. It offers the advantage of increasing the patient's awareness of his or her own condition. Physiotherapy combined with strengthening exercises of the paraspinal muscles and stretching of abdominal and chest muscles is of value in painful patients during and after the growth spurt.

Physical exercises may influence pain but not the kyphosis

| Table 5. Favorable indications for non-operative treatment | |
|---|---|
| • radiologic signs of the disease are present | • before/during the growth spurt |
| • mobile curves | • painful curves |

When consulting patients on the most appropriate treatment, a thorough knowledge of the natural history is mandatory. The results of treatment must be weighed against natural history.

## Natural History

The natural history of the deformity is benign in the majority of cases. Murray et al. reported on the natural history of Scheuermann's disease over a 32-year period [44]. Patients' pain was usually mild and rarely interfered with daily activities or professional career. **Cardiorespiratory problems** were seen only in very severe deformities (kyphosis > 100 degrees). In kyphosis of more than 70 degrees the cosmetic impairment is considerable and clinical symptoms are more common. In these cases, further progression of the deformity can be expected during adult life due to the unadvantageous biomechanical situation. However, no data on the **risk of progression** after cessation of growth could be found from the literature. The cosmetic appearance may cause psychological distress to the patient. There are no specific data on psychological problems in these patients. But it is known that patients with idiopathic scoliosis are self-conscious about their body shape and cosmetic appearance [18, 22]. The patient's cosmetic concerns therefore often play a role in the decision-making toward operation.

The natural history of juvenile kyphosis is benign

Curve progression is not observed after the end of growth

Neurological problems are rare in Scheuermann's kyphosis. If neurological complications occur, they are usually due to mechanical compression of the cord at the apex of the kyphosis. Normelli et al. reported on one such observation in

Neurological deficits rarely occur in juvenile kyphosis

a 20-year-old male and collected 16 additional cases from the literature [50]. The majority were teenagers or young adults. Interestingly, male gender was overrepresented. This was attributed possibly to the fact that the adolescent growth spurt occurs later in boys than in girls and progression is possible still during early adulthood. The kyphosis was not very severe, ranging from 37 to 80 (mean 56) degrees but was **usually sharp-angled**. There was no obvious correlation between the degree of kyphosis and the neurological deficit. Anterior decompression with fusion was the most common treatment with good results in the majority of patients. Other possible reasons for neurological complications in Scheuermann's kyphosis are a coincidental disc herniation, or other spinal pathology, e.g., extradural cyst [6, 13, 17, 38, 59, 76].

A neurological deficit is usually correlated with a sharp-angled kyphosis

## Bracing and Casting

Bracing has a significant psychological impact and is therefore not harmless

It is well known from scoliosis patients that bracing can cause substantial psychological distress in an adolescent child [20, 42, 49, 54] and should therefore not be considered a harmless treatment. It has, however, also been shown that these adverse effects do not occur if the patient is well supported by the family [52] (Case Study 1). The **indication for bracing** should be based on correct indications, i.e.:

- a mobile kyphotic deformity over 45 degrees
- substantial remaining growth (>1 year)

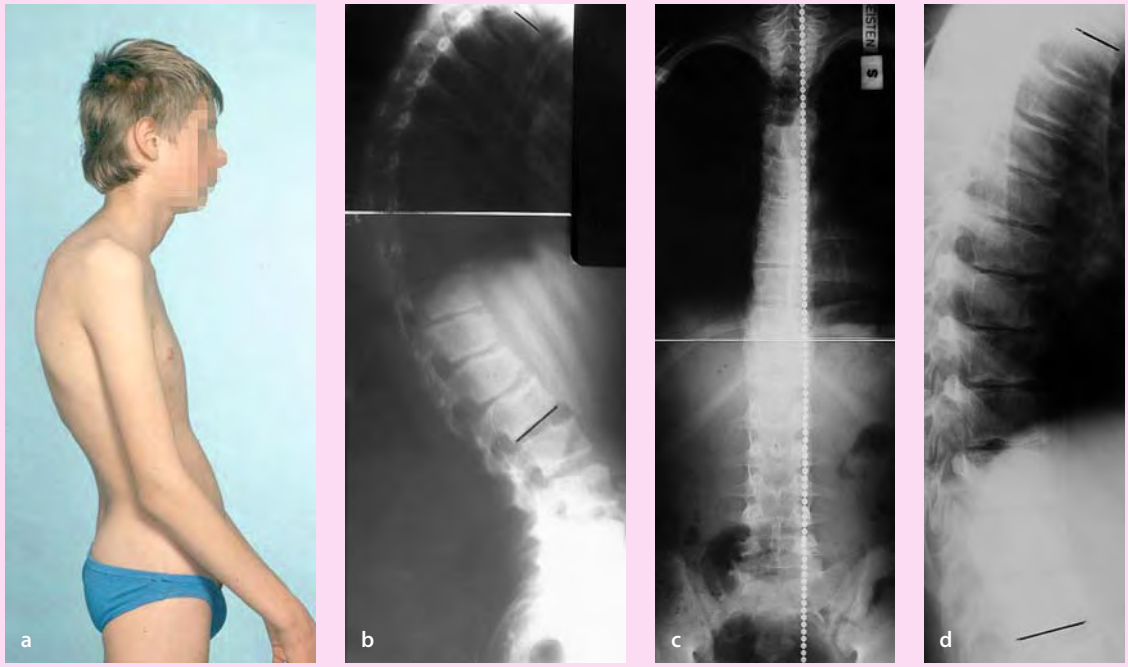


### Case Study 1

A 15-year-old otherwise healthy boy was referred by the school doctor. Within 1 year, he had developed a thoracic hyperkyphosis with disturbing thoracolumbar pain at rest, exacerbating after activity. There was no radiating pain (a). During physical examination a mobile slightly painful hyperkyphosis reaching from the midthoracic to the upper lumbar spine was noticed. Bilateral hamstring tightness was 45 degrees. No pathologic neurological signs were present (b). On the standing lateral radiograph, thoracic kyphosis measured 85 degrees with typical Scheuermann's changes from T6 to L2 (c). The standing posteroanterior film did not show anything pathologic (d). On the supine extension radiograph, the kyphosis decreased to 44 degrees.

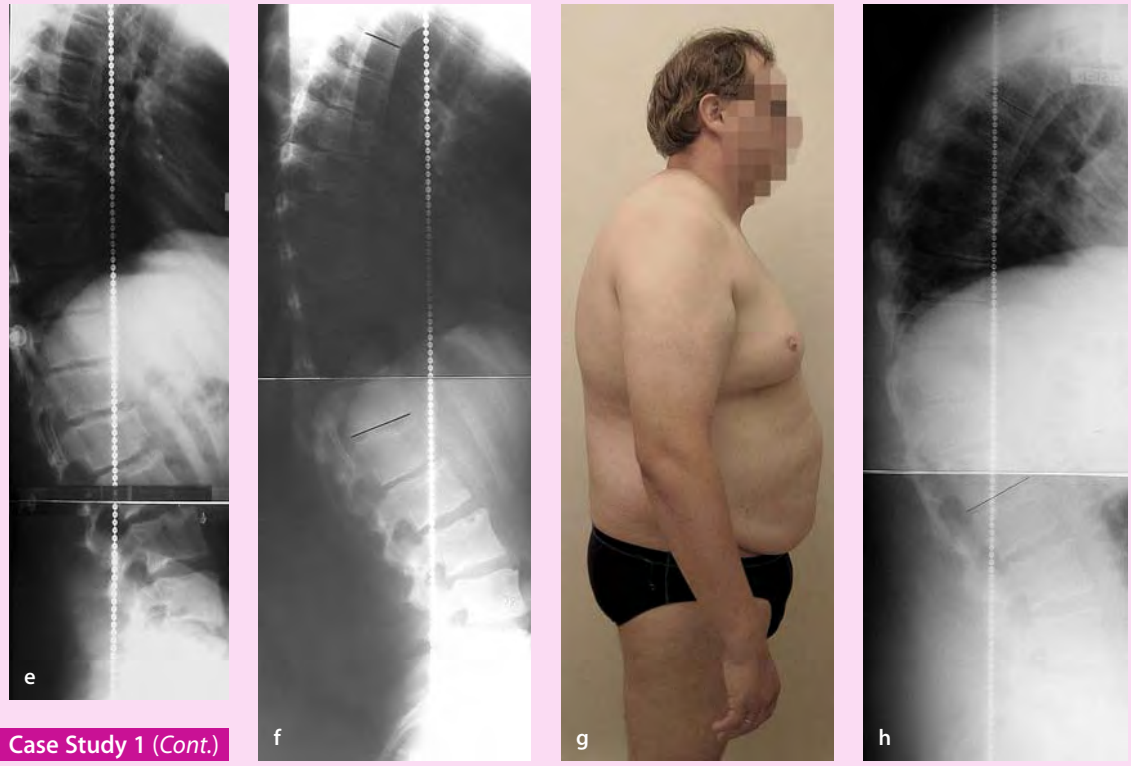


**Case Study 1** (*Cont.*)

As the kyphosis was very mobile and a considerable amount of growth was left (Risser 0, skeletal age 13.5 years), brace treatment (23 h/day) in combination with spinal extensor muscle strengthening exercises was started. The deformity corrected in the brace to 44 degrees (e). The compliance of the patient was excellent. Weaning from the brace was started after 2 years of treatment. One year after weaning, the patient was free of symptoms. Thoracic kyphosis measured 47 degrees (f). Sixteen years after weaning, the patient is free of symptoms. The cosmetic appearance is acceptable (g). On the standing lateral radiograph, the thoracic kyphosis measures 58 degrees (h).

Bracing and/or casting is known to become ineffective once the patient's Risser sign is 4 or 5. Bradford et al. reported on the results with the Milwaukee brace treatment [14, 60]. Compliant patients had stabilization or a slight improvement of their deformity. Patients with initial curves above 75 degrees required surgery in 30 % of cases [14, 60]. Montgomery and Erwin treated 39 patients with a Milwaukee brace for 18 months on average. The mean kyphosis at the beginning of treatment was 62 (43 – 87) degrees. At the end of brace treatment, mean kyphosis measured 41 degrees. During follow-up, they saw on average a loss of correction of 15 degrees. Thus, the final mean result was 54 degrees [43]. Soo et al. stated in their long-term follow-up study that patients treated by bracing or surgery had improved self-image. Patients with kyphosis over 70 degrees at follow-up had an inferior functional result [66]. Because of compliance problems with the Milwaukee brace, other braces such as the modified Boston or the modified Milwaukee have been tried and have also been shown to be effective. Gutowski and Renshaw used a Milwaukee brace and a Boston lumbar orthosis. For compliant patients they achieved an average kyphosis improvement of 27 % with the Boston brace and 35 % with the Milwaukee. Compliance with the Boston brace, however, was twice as good as with the Milwaukee brace (61 vs. 29 %) [26]. Brace treatment must usually be carried out for a minimum of 18 months to have an effect on the vertebral wedging. In cases of rigid juvenile kyphosis, serial casting has been advocated by some authors [55, 68], but it is increasingly being abandoned because it is very inconvenient for the patient.

During growth, brace treatment is indicated for mobile deformities over 45 degrees

Brace treatment is not effective for a shorter duration than 18 months

Table 6. Indications for surgery

| Absolute indications | Relative indications |
|---|---|
| • neurological compromise | • progressive curves<br>• adolescents with curves > 75 degrees<br>• painful curves<br>• cosmetic aspects |

## Operative Treatment

Indication for operation is not well defined

Indications for surgery in juvenile kyphosis are still not well defined, due to the benign natural history of this condition and the lack of comparative long-term follow-up data after operation.

Neurological compromise is the only absolute surgical indication

The only absolute indication for surgery is a neurological compromise due to an increase in kyphosis, a disc protrusion or other intraspinal pathology with neurological compromise. Such complications are fortunately exceptional and would require spinal cord decompression through an anterior approach. Apart from these rare neurological complications, there is **no evidence based indication** for surgery.

**Relative indications** for surgical correction of the juvenile kyphosis are:

- kyphotic deformity over 75 degrees
- rapidly progressive severe curve
- persistent pain unresponsive to non-operative care

According to the literature, operative treatment should be considered in patients presenting with a **kyphotic deformity of over 75 degrees** as severe curves tend to progress over time for biomechanical reasons. The assessment and the decision-making should not be based only on the Cobb angle, i.e. the degree of kyphosis. The localization of the apex of the deformity is of equal great importance. A low thoracic kyphosis with an apex close to the thoracolumbar junction has a more significant effect on the sagittal alignment of the spine than a deformity with the apex in the midthoracic area.

Kyphosis over 75 degrees and/or persistent pain are generally accepted indications for operation

Another indication for operation is **significant pain** not responding to conservative measures. The problem with pain as an indication, however, is that pain is impossible to measure objectively and the causal relation between pain and kyphosis is unclear. In addition, it has not been possible to establish a correlation so far between the amount of postoperative kyphosis correction and the patient's clinical outcome [31, 56].

Surgery must be weighed against natural history and potential complications

The surgical indications can only be looked at on a case-by-case basis because the natural history is generally benign and complications from surgery cannot be ruled out. Overtreatment must be avoided. According to Ascani and La Rosa [2], subjects who enjoy relatively good health and have a relatively benign prospect for adult life must not be "normalized" from a morphologic point of view.

### Preoperative Assessment

The preoperative work-up will focus on the patient's pain and/or cosmetic concerns, trying to identify the motivation of the patient. Preoperative assessment should include:

- assessment of hamstring tightness
- search for neurological findings
- pulmonary function tests (in severe deformities)

- radiographs (standing up, lateral, extension views)
- MRI
- clinical photograph (for outcome evaluation)

Hamstring tightness in adolescent patients with thoracic hyperkyphosis was observed by Lambrinudi [34]. He believed that it would be the primary cause of the deformity. This theory, however, could not be proven. The importance of **tight hamstrings** has recently been emphasized as a possible cause of sagittal decompensation after operation. Preoperative hamstring tightness predicts a limited lumbar and pelvic range of motion, i.e. a limited ability to adapt to curve correction. Therefore, patients with tight hamstrings have a significantly higher risk of postoperative sagittal imbalance [30]. MRI before surgery is recommended to rule out any cord compression, thoracic disc herniation, epidural cyst, possible spinal stenosis and concomitant spondylolysis (frequent). The literature has shown exceptional cases in various case reports of neurological complications in Scheuermann's kyphosis [6, 13, 16, 17, 38, 50, 74].

Tight hamstrings are a potential cause of postoperative sagittal decompensation

## General Principles

The operative approach is based on the analysis of the pathoanatomical features of the deformity. The hyperkyphosis is the result of marked structural changes in the bones and in the soft tissues of the affected area (Table 7, Fig. 9a).

For optimal correction of the deformity these obstacles of reduction have to be assessed and addressed individually. Several questions should be answered while planning the operative strategy:

- *Does the curve need an anterior release?*
  Posterior surgery alone is sufficient if the rigidity of the anterior structures is not too severe, for instance in patients before growth arrest. Bradford et al. described significant loss of correction after posterior Harrington instrumentation especially in patients with a kyphosis greater than 70 degrees despite postoperative casting [15]. They therefore proposed combined sur-

**Table 7. Structural changes in juvenile kyphosis**

| Anterior column | Posterior column |
|---|---|
| • wedged vertebral bodies | • relative overgrowth of posterior elements (broad laminae, long spinous processes) |
| • disc space narrowing | • reduced mobility of intervertebral joints |
| • premature disc degeneration | • narrow interlaminar spaces |
| • contracture of the anterior longitudinal ligament | |

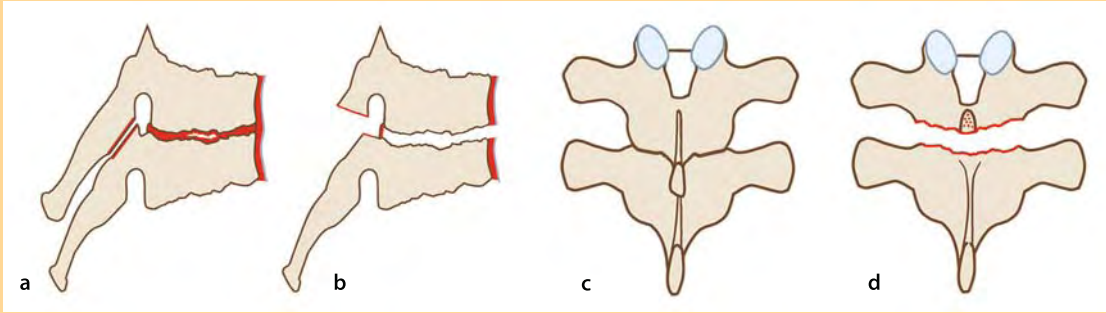


**Figure 9. Surgical release**

Structural changes to be addressed during surgery: a, b **anterior release**: stiffness of intervertebral disc and anterior longitudinal ligament; and c, d **posterior release**: overgrowth of the posterior elements.

gery in these severe cases. Lowe recommends posterior surgery alone only for immature patients. In his opinion adolescents and adults need combined surgery [40]. With modern third generation instrumentation systems, loss of correction after posterior surgery no longer seems to be a problem. Hosman et al. did not see any differences in radiological or clinical outcome in a comparison of anterior surgery alone versus combined surgery. They concluded that anterior release is indicated only if bony bridges between the vertebrae are present or in kyphosis greater than 100 degrees [31].

- *What levels have to be included in the fusion?*
  Instrumentation should be carried out proximally from the upper end-vertebra of the kyphosis (usually T2, T3, or T4) down to the upper lumbar spine including the first lordotic disc space (usually L1, L2, or L3).
- *Which technique of correction should be used?*
  The correction principle preferred by most surgeons nowadays is cantilever correction performed using two or four rods, which results in a tension bend with posterior segmental compression. The vertebrae around the apex of the deformity are usually not instrumented.
- *What is the target correction?*
  In the individual patient, it is impossible to define the optimal degree of thoracic kyphosis. The amount of correction should not exceed the ability of the adjacent mobile spinal segments to realign. The degree of hamstring tightness should be assessed and taken into consideration during planning. A kyphosis correction of more than 50 % of its initial value should be avoided as it bears the **risk of imbalance** or **junctional kyphosis** [31]. Correction of the deformity to the high "normal" kyphosis range of 40 – 50 degrees seems to be advisable in order to avoid postoperative imbalance [31]. Therefore, **straighter is not necessarily better** in the operative treatment of Scheuermann's kyphosis (Table 3).

The clinical outcome is not dependent on the amount of correction but rather on sagittal balance

## Operative Technique

The first long-term results of Scheuermann's kyphosis correction by posterior instrumentation using flexible Harrington compression rods and fusion were published by Bradford et al. in 1975 [15]. They reported on 22 patients with very satisfactory subjective outcome but a significant loss of correction, as seen also by other authors [25, 35]. Therefore, they changed their technique by adding anterior release and bone grafting to achieve circumferential fusion. Because of the flexibility of the instrumentation, postoperative cast immobilization from 9 to 12 months was deemed necessary. Using this technique in 24 patients, significant loss of correction (> 10 degrees) was observed only in five patients outside the fusion area due to insufficient length of the instrumentation. Radiographically, mean kyphosis improved from 77 degrees preoperatively to 47 degrees at follow-up. There were no neurological complications and no fatalities. Pulmonary embolus, atelectasis, and hemothorax occurred in two patients each, vascular obstruction of the duodenum, deep wound infection, and pericardial effusion in one patient each. The clinical appearance was markedly improved in all patients. Twenty-three of the 24 patients experienced significant pain relief [12]. Using modern rigid posterior double-rod instrumentation allows for immediate mobilization of the patients without a brace or cast. The rate of correction loss has diminished considerably, and in our time anterior surgery has become necessary only in extreme cases. Hosman et al., who used rigid posterior double-rod instrumentation, did not see any difference in outcome on comparing patients who had posterior surgery only with patients who had undergone additional anterior release [31].

Additional anterior release appears not to influence clinical outcome

Kyphosis correction by anterior instrumentation and fusion has been performed in some centers very recently. The aims are to save spinal segments and to avoid damage to the paraspinal muscles. There are, however, no reports yet on the outcome of this procedure.

### Posterior Approach

The **basic steps** of the classical posterior procedure for Scheuermann's kyphosis are:

- posterior release
- correction and internal fixation using posterior instrumentation
- posterior fusion with bone graft

Spinal cord monitoring and the possibility for a wake-up test are absolutely indispensable for a safe surgical correction of the kyphotic deformity.

### Posterior Release, Correction, and Fusion

The goal is shortening of the posterior column to allow for extension of the spine. The **posterior release** encompasses the resection of:

- spinous processes
- ligamenta flava
- upper and lower margins of the laminae
- facet joints
  in the area of the deformity (usually four to six segments) (Fig. 9b, c).

Instrumentation includes the upper kyphosis end vertebra and the first lordotic segment

Instrumentation and correction of the deformity follow the cantilever and posterior tension bend (compression) principle. The uppermost instrumented vertebra is the upper end vertebra of the deformity. Distally, the **first lordotic segment** caudal to the apex should be included [39, 40, 41, 53, 56].

**Claw constructs** or **pedicle screws** are used above the apex of the deformity, pedicle screws in the lower part of the instrumentation. A two-rod construct (Case Study 2) or a four-rod construct can be used for the correction maneuver (Fig. 10a, b). Stiff rods should be chosen to minimize the risk of loss of correction.

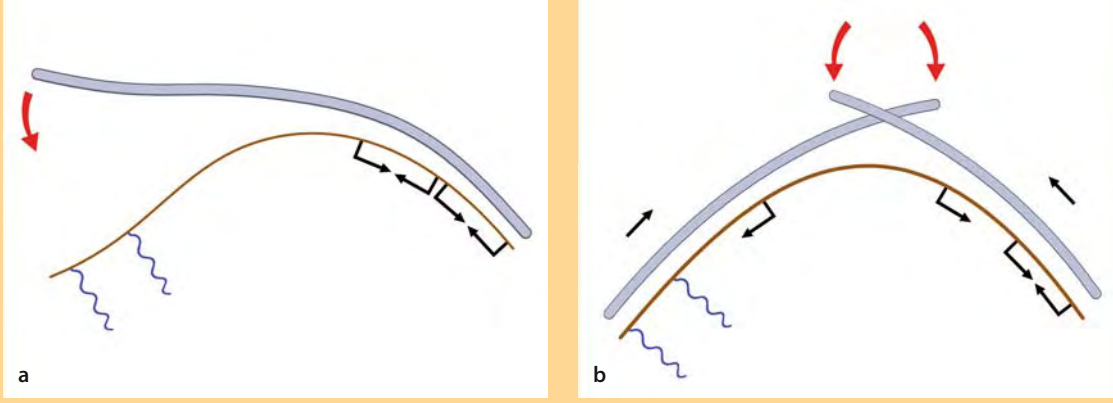


**Figure 10. Cantilever technique**

Instrumentation/correction using cantilever and posterior tension band principle: a two-rod technique and b four-rod technique.

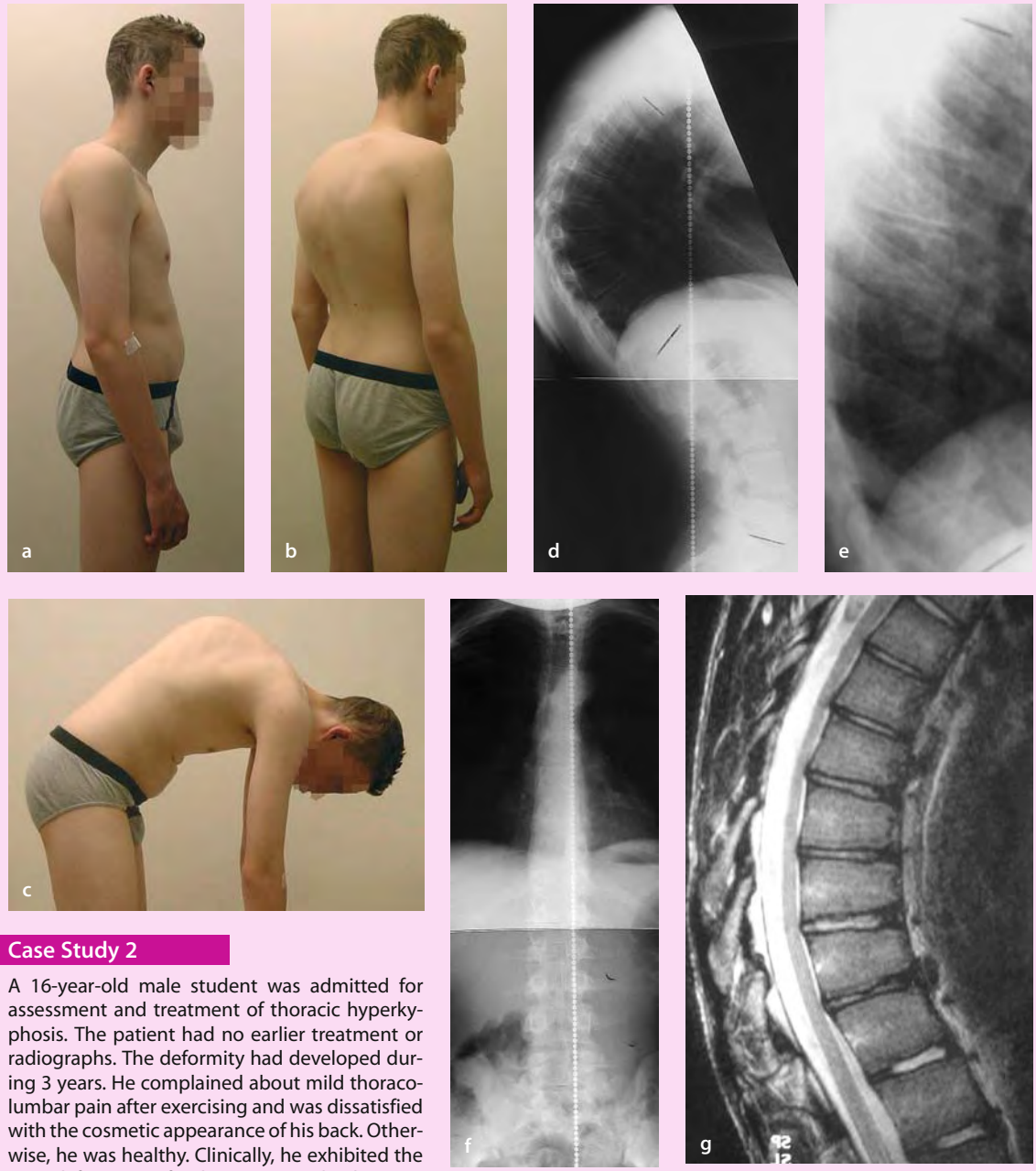

## Case Study 2

A 16-year-old male student was admitted for assessment and treatment of thoracic hyperkyphosis. The patient had no earlier treatment or radiographs. The deformity had developed during 3 years. He complained about mild thoracolumbar pain after exercising and was dissatisfied with the cosmetic appearance of his back. Otherwise, he was healthy. Clinically, he exhibited the typical features of Scheuermann's kyphosis in the lower thoracic spine (a–c) . The deformity was pain free and corrected partially in extension. Bilateral hamstring tightness of 50 degrees was present, and there were no pathologic neurological signs. On the standing lateral radiograph, thoracic kyphosis measured 95 degrees (d). It corrected to 54 degrees on the supine extension film (e). Around the apex (T8) there were five wedge vertebrae. The standing posteroanterior radiograph was normal (f). MRI showed typical Scheuermann's changes, and no cord compression or other pathology (g).

During the correction maneuver the area of the release should be watched very carefully to detect and avoid cord compression due to translation of the vertebrae or kinking of the laminae. The interlaminar gaps should not be fully closed at the end of the correction maneuver to allow for drainage of possible hematoma. After instrumentation the posterior elements of the area are decorticized with

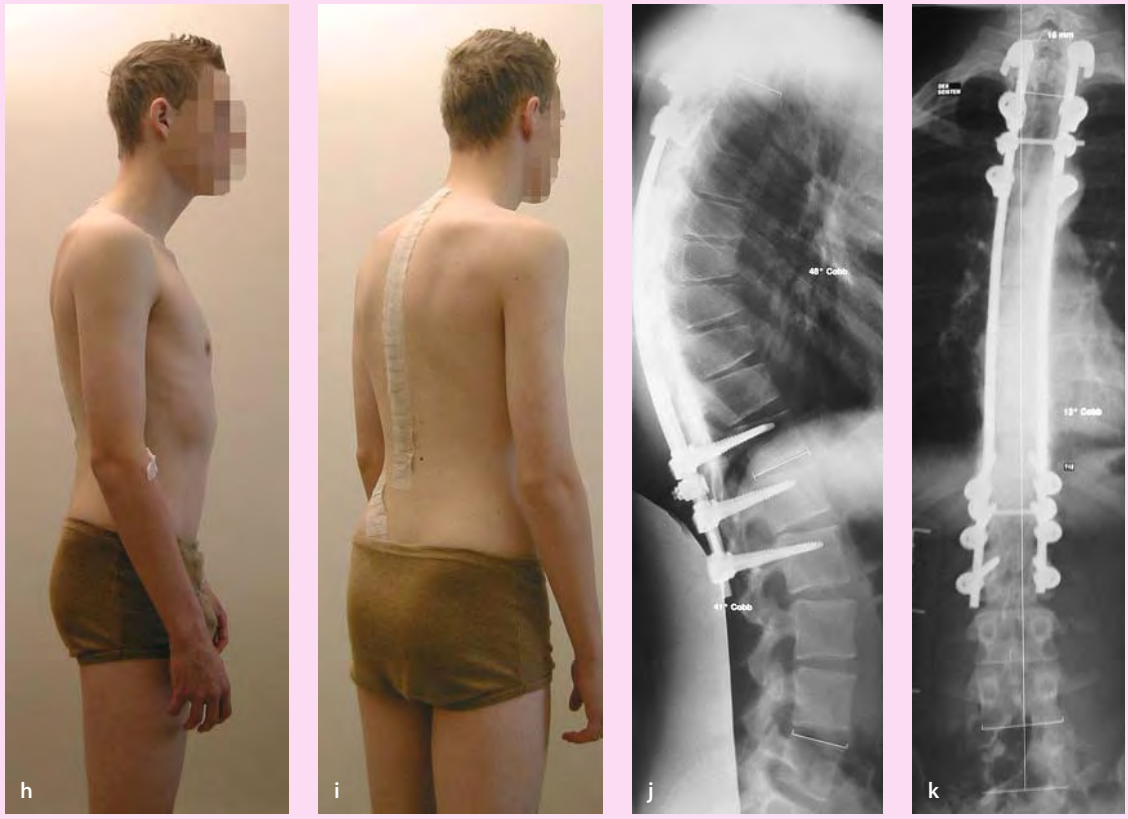


**Case Study 2** (*Cont.*)

As the deformity was relatively mobile, brace treatment was considered. It was, however, discarded because of the minimal remaining spinal growth left (Risser 4, skeletal age 18 years). A posterior release, Universal Spine System (USS) instrumentation/correction using the two-rod cantilever tension band principle, and a posterior fusion from T2 to L2 were performed. There were neither intraoperative nor postoperative complications. The cosmetic result looked very satisfactory (h, i). On radiographs 6 months after operation, thoracic kyphosis measured 48 degrees (j, k).

great care and packed with autogenous or allogenous bone graft to achieve a thick solid fusion mass. Spinal cord monitoring and/or wake-up test are mandatory. Prophylactic antibiotics are recommended.

### Combined Anterior/Posterior Approach

A combined anterior/posterior approach is indicated in very rigid kyphosis

In very rigid severe deformities, especially in adult patients, a combined approach may be considered (Fig. 9d). However, there are no scientifically based numeric data available informing the surgeon which cases need additional anterior release and which can be treated by posterior approach only. **Halo-femoral traction**, used by some authors during the interval between staged anterior and posterior surgery, does not seem to improve final results [12, 29].

Through an anterior approach the rib heads, the anterior longitudinal ligament, the intervertebral discs down to the posterior longitudinal ligament, and the cartilaginous vertebral endplates in the area of the deformity are resected. The disc spaces are distracted and filled with bone graft (morcellized rib). Traditionally, this has been performed through a thoracotomy as an open procedure. The literature has shown that **thoracoscopic anterior release** is effective in

Scheuermann's kyphosis [1]. Its definitive advantages over classic open thoracotomies are cosmesis and less morbidity. It does, however, have a considerable learning curve [45].

## Results of Operative Treatment

Surgery provides a favorable outcome in selected cases

Outcome data after operative treatment of Scheuermann's kyphosis comprise mainly retrospective short-term or mid-term follow-up reports. Results are analyzed usually according to the two major indications for which the surgery was carried out: **pain and deformity**. As far as pain is concerned, all series report an improvement in the amount of back pain of between 60% and 100% [12, 15, 29, 31, 60]. Hosman et al. showed a marked improvement concerning back pain in 31 out of 33 patients after a mean follow-up of 4.5 years. However, neck pain did not seem to have improved after surgery. Interestingly, no relationship between the amount of correction and the amount of residual back pain was found. As far as patients' satisfaction is concerned, most series report a very high satisfaction rate of up to 96% [31].

As no cosmetic scale has been available for the assessment of juvenile kyphosis, one has to judge the cosmetic correction on plain radiographs, which represent an extrapolation of the **cosmetic results**. The rate of correction given in the different surgical series is 21–51%. Loss of correction in the instrumented area is minimal at present due to the rigidity of instrumentation systems used (Table 8). Ideally, the result of correction of juvenile kyphosis should be assessed according to patient satisfaction and improvement of perceived self-image and independent judgement of clinical photographs before and after the surgery by non-medical observers. The literature definitively lacks such information. The results of corrective surgery should not be based on Cobb angle correction alone but rather on outcome instruments such as the SRS 24, the sagittal balance of the patient, and the assessment of spinal mobility and function. So far, only Poolman et al. have used the SRS questionnaire instrument, which includes assessment of the cosmetic situation [56].

**Table 8. Surgical treatment of juvenile kyphosis**

| Author | *N* | Technique | Follow-up time (months) | Kyphosis (degrees) | Outcome/complications | Conclusions |
|---|---|---|---|---|---|---|
| Bradford et al. (1974) | 22 | post Harrington compression | 35 (5–92) | pre 72 (50–128) | pain relief 100%, cosmesis improved 100% | complications frequent |
| | | cast for 9.8 months | | follow-up 47 (29–88) | pseudarthrosis 3, infection 1, thromboembolia 1, neurological 1 | indication restricted to patients with severe pain |
| | | | | correction: 35% loss > 10 in 15/22 patients | | need for combined approach to avoid loss of correction |
| Taylor et al. (1979) | 27 | post Harrington compression | 26.6 (6–72) | Pre 72 (55–93) | pain relief 100%, cosmesis improved 100% | instrument/fusion too short leading to loss of correction |
| | | cast for 5 months | | follow-up 46 (23–63) correction: 36% | new neck/shoulder pain 9/27 patients intraoperative lamina fracture 1, pneumothorax 1, donor-site hematoma 3, transient paresthesia 1, gastrointestinal obstruction 1 | recommendation to fuse whole curve |
| | | | | loss of correction: in fusion: 7 outside: 12 | | |

**Table 8.** (*Cont.*)

| Author | *N* | Technique | Follow-up time (months) | Kyphosis (degrees) | Outcome/complications | Conclusions |
|---|---|---|---|---|---|---|
| Bradford et al. (1980) | 24 | anterior release<br>Halo traction 2 weeks<br>post Harrington compression<br>Risser cast<br>9–12 months | 24–68 | pre 77 (54–110)<br>follow-up 47 (30–67)<br>correction: 39%<br>loss of correction: mean 6<br>outside fusion: 13–25 in 5 patients | hook site pain 2, fusion extended for pain 1, pulmonary embolus/deep femoral thrombosis 2, deep infection 1, vascular obstruction of duodenum 1, hematothorax 1, pericardial effusion 1, pseudarthrosis 1, intercostal neuroma 1, discomfort at lower hook 3 (2 removed) | correction after combined approach superior to anterior only but greater morbidity |
| Herndon et al. (1981) | 13 | anterior release<br>Halo traction 2 weeks<br>post Harrington compression<br>Risser cast<br>6 months | 29 (12–66) | pre 78 (61–95)<br>follow-up 45 (30–73)<br>correction: 51% | pain relief in 8/13 patients, cosmesis improved 100%<br>mortality 1, instrumentation problems 2, transient neurology 1, pressure sore 1, urinary retention 1, deep thrombosis 1, psychological problems in halo 1 | significant risk of severe complications<br>no advantage from preoperative halo; deformities over 70° need combined approach |
| Lowe (1987) | 24 | anterior release<br>Halo gravity 1 week<br>posterior Luque double rod<br>no external support | 32 (19–48) | pre 84 (72–105)<br>follow-up 49 (30–65)<br>correction: 43%<br>loss of correction: mean 5 | pain relief in 18/24 patients, cosmesis improved 100%<br>transient hyperesthesia of trunk and lower extremity 4, rod removal for bursa 4, fusion too short distally 2, rod migration 1 | longer follow-up necessary<br>hyperesthesia worrisome<br>good patient acceptance |
| Lowe and Kasten (1994) | 32 | anterior release + posterior Cotrel-Dubousset instrumentation in 28 patients<br>4 patients post C-D only | 42 (24–74) | pre 85 (75–105)<br>follow-up 47 (24–65)<br>correction: 45%<br>loss of correction: 4 (0–19)<br>sagittal balance: pre –5.3 cm follow-up –6.6 cm | preoperative back pain 27/28 patients, at follow-up 18/28 mild back discomfort with vigorous activities<br>cosmetically satisfied 26/28 patients<br>proximal junctional kyphosis 26° (12°–49°) in 10/28 patients due to overcorrection (>50%) or short fusion<br>distal junctional kyphosis 17° (10°–30°) in 9/28 patients due to short fusion | indication for surgery symptomatic kyphosis >75°<br>negative sagittal balance in Scheuermann's avoid overcorrection to avoid junctional kyphosis<br>include proximal end vertebra and first lordotic segment distally |
| Otsuka et al. (1990) | 10 | posterior heavy Harrington compression<br>Brace<br>6–9 months | 27 (18–33) | pre 71 (63–90)<br>follow-up 39 (28–57)<br>correction 45%<br>loss of correction: 8<br>in 3/10 patients loss >10 | pain relief 100%, cosmesis improved 100%<br>rod breakage after motor vehicle accident 1, intraoperative lamina fracture 1<br>lung problems in patient with preoperative congenital obstructive lung disease 1<br>Fusion too short 3 | good cosmesis improvement and pain relief<br>in flexible kyphosis (bending to <50°) posterior surgery only is sufficient |

**Table 8.** *(Cont.)*

| Author | N | Technique | Follow-up time (months) | Kyphosis (degrees) | Outcome/complications | Conclusions |
|---|---|---|---|---|---|---|
| Reinhardt and Bassett (1990) | 14 | post Harrington compression<br>anterior release in 6/14 patients cast or brace for 6 months | 32 (12–65) | pre 71 (54–101)<br>follow-up 37 (15–54) correction: 48%<br>loss of correction: 8 (4–14) | clinical outcome and complications not mentioned<br>distal junctional kyphosis 23° (15°–31°) in 5/14 patients proximal junctional kyphosis 34° in one patient | to avoid junctional kyphosis, fusion beyond the end vertebra to a non-wedged ("square") vertebra necessary |
| Poolman et al. (2002) | 23 | anterior release<br>post Cotrel-Dubousset 13/23<br>Moss-Miami 10/23 | 75 (25–126) | pre 70 (62–78)<br>follow-up 55 (36–65)<br>correction: 21%<br>loss of correction: mean 15° in 8 patients after rod removal | SRS outcome instrument at follow-up: total score 83 (55–106), 7 patients <72<br>back pain increased 4, back pain improved 10, self-image improved 10, self-image worsened 3, would have the procedure again 16, no correlation SRS score vs. radiography<br>aorta + thoracic duct lesion 1, proximal junctional kyphosis 3, screw breakage 3, painful hardware 6 | outcome relatively fair<br>loss of correction after implant removal<br>indication for surgery questioned |
| Hosman et al. (2002, 2003) | 33 | posterior H-frame instrumentation<br>anterior release in 17/33 patients, orthosis 3 months | A. Post only 50 (25–93)<br>B. Combined 55 (24–98) | A + B Pre 79 (70–103)<br>follow-up 52 (32–81)<br>correction: 34%<br>loss of correction: mean 1.4°<br>no difference A vs. B | Oswestry Disability Index Pre 21.3 (0–72), follow-up 6.6 (0–52)<br>no difference if compared posterior only versus combined surgery<br>cosmesis improved 100%<br>infection 3, instrumentation removal for prominence or irritation 4, loss of distal fixation (reop.) 1, rod breakage 1, proximal junctional kyphosis 1 | good radiographic and clinical results. No benefit from anterior release. Excessive correction should be avoided to minimize risk for postoperative sagittal malalignment.<br>patients with hamstring tightness have significantly higher risk for postoperative sagittal imbalance |

## Complications

Operative kyphosis correction carries the risk of major complications

Surgery on juvenile kyphosis is not benign and complications can occur. Neurological complications due to spinal cord compression can arise during the correction maneuver because of a rare but preoperatively undetected intraspinal problem, or due to a surgical technique failure. The exact rate of **neurological complications** is not known in surgery of juvenile kyphosis. Probably, it is higher than for idiopathic scoliosis operations. Possible complications such as death, dura lesion, vascular lesion, lamina fracture, Brown-Séquard syndrome, pulmonary problems, venous thrombosis, gastrointestinal obstruction, infection, instrument failure, and pseudarthrosis have been described as in any major corrective procedure for spinal deformities [2, 4, 12, 15, 29, 39, 53, 56].

Postoperative sagittal imbalance must be avoided

Proximal junctional kyphosis due to overcorrection occurs in 20–30% of cases according to Lowe and Kasten [41]. **Distal junctional kyphosis** due to short fusion causing loss of correction ("adding on") outside the instrumented area has been reported by several authors [12, 26, 29, 41, 58, 67]. Reinhardt and Bassett

saw distal junctional kyphosis if fusion was carried out to a wedged caudal end vertebra of the kyphosis. They recommend including the **next "square" vertebra** to allow smooth transition into lumbar lordosis [58]. Lowe postulates three possible mechanisms: firstly, fusion that is too short, distally stopping above the first lordotic disc, results in distal junctional kyphosis; secondly, fusion that is too short proximally and does not include the whole kyphosis on the top may cause proximal junctional kyphosis and a goose neck appearance. Finally, overcorrection seems to be a factor and one should not correct the kyphosis to more than 50 % of its initial value [40]. In the case of overcorrection, possibly the remaining mobile segments below the fusion are unable to adapt to the alignment changes caused by excessive kyphosis correction. As a result this leads to permanent increased flexion stress on the segment adjacent to the fusion, finally causing its breakdown. This view is supported by Hosman et al. [30], who stressed the importance of tight hamstrings for surgical correction.

According to Poolman et al., significant loss of correction occurs after removal of the instrumentation even if the fusion is healed [56]. Therefore, the metal should not be removed if it is not imperative to do so, e.g. in the case of infection. Overall, surgery in Scheuermann's kyphosis bears the risk of serious complications, a risk the surgeon should be aware of. The benign nature of the deformity should be kept in mind, and the risks and benefits of an operation should be weighed up carefully.

The benign natural history must be weighed against the risks of the surgery

## Recapitulation

The sagittal alignment of the human spine develops during growth and shows great individual variability. The range of thoracic kyphosis in healthy people ranges from 10 to 60 degrees. There are no evidence-based "normal values".

**Definition and epidemiology.** "Classic" juvenile kyphosis (**Type I**) is a **rigid thoracic or thoracolumbar hyperkyphosis** due to **wedge vertebrae** developing during adolescence. The incidence is 1–8 % according to the literature. Atypical juvenile kyphosis (**Type II**, "lumbar" Scheuermann's kyphosis) affects mainly the lumbar spine, is characterized by endplate changes of the vertebral bodies without significant wedging, and leads to loss of lumbar lordosis (**flat back**).

**Pathogenesis.** The **exact etiology** is **unknown**. Genetic, hormonal, and mechanical factors have been discussed. A disturbance of the enchondral ossification of the vertebral bodies leads to wedge vertebra formation, causing increased kyphosis. Type II is frequently seen in athletes as a sequela of axial overloading.

**Clinical presentation.** A rigid thoracic hyperkyphosis with or without pain is the reason for consultation. Hamstring tightness is common. Abnormal neurological signs are rare. In Type II, the lumbar spine is stiff and pain symptoms are more prominent.

**Diagnostic work-up.** Diagnosis is based on typical changes seen on lateral standing plain radiographs: **hyperkyphosis**, **irregularity** of the endplates, **wedged vertebrae**, increased sagittal length on the vertebral bodies, and **narrowed disc spaces**. Schmorl's nodes may be present but they are not pathognomonic. MRI is taken if abnormal neurological signs are observed or in connection with preoperative work-up.

**Non-operative treatment.** The general objectives of treatment are to prevent progression of the kyphosis, to correct the deformity, and to relieve pain. The choice of treatment must consider the natural history, which is benign in the majority of cases. In **Type I**, back pain is common but usually mild. Type II and kyphosis of greater than 70 degrees causes more clinical symptoms. Pulmonary compromise occurs only in severe deformities (> 100 degrees). Bracing and casting are effective in mobile deformities of between 45 and 60 degrees if at least 1 year of growth is left.

**Operative treatment.** The only absolute indication for surgery is a neurological compromise (spastic paraparesis). Kyphosis greater than 75 degrees, pain, and severe cosmetic impairment are relative indications. The benign natural history should be kept in mind and overtreatment must be avoided. Posterior correction, instrumentation and fusion are sufficient in the majority of cases. In very severe rigid deformities a combined approach with additional anterior release can be considered. The operative results are good in most cases concerning pain relief and cosmesis. Severe intra- and postoperative complications have been described. The risks and benefits of operative treatment must be weighed carefully against the benign natural history.

## Key Articles

**Arlet V (2000) Anterior thoracoscopic spine release in deformity surgery: a meta-analysis and review. Eur Spine J 9 Suppl 1:S17–23**
This is a meta-analysis of all the literature available on thoracoscopic spine release done for scoliosis or kyphosis. Thoracoscopic release has been effective in kyphosis for curves with an average of 78 degrees that were corrected after video-assisted thoracoscopic release and posterior surgery to 44 degrees. No report of the surgical outcome (balance, rate of fusion, rib hump correction, cosmetic correction, pain, and patient satisfaction) was available for any series.

**Bernhardt M, Bridwell KH (1989) Segmental analysis of the sagittal plane alignment of the normal thoracic and lumbar spines and thoracolumbar junction. Spine 14:717–21**
This is a review of the normal sagittal alignment of the spine segment by segment in 102 healthy individuals, indicating that there is a wide range of normal sagittal alignment of the thoracic and lumbar spines. The thoracolumbar junction is for all practical purposes straight; lumbar lordosis usually starts at L1–2 and gradually increases at each level caudally to the sacrum.

**Hosman AJ, de Kleuver M, Anderson PG, van Limbeek J, Langeloo DD, Veth RP, Slot GH (2003) Scheuermann kyphosis: the importance of tight hamstrings in the surgical correction. Spine 19:2252–9**
The author reviewed 33 patients with juvenile kyphosis who underwent surgical correction. Sixteen patients had tight hamstrings, and 17 patients had non-tight hamstrings. Hamstrings were considered tight if the popliteal angle was >30 degrees. Patients with tight hamstrings had a significantly greater risk of postoperative imbalance ($p<0.05$). Tight hamstring patients can be classified as "lumbar compensators" and as such are prone to overcorrection and imbalance.

**Hosman AJ, Langeloo DD, de Kleuver M, Anderson PG, Veth RP, Slot GH (2002) Analysis of the sagittal plane after surgical management for Scheuermann's disease: a view on over correction and the use of an anterior release. Spine 2:167–75**
A cohort of 33 patients who had undergone surgery for their Scheuermann's kyphosis were reviewed: Group A: posterior technique ($n=16$); Group B: anteroposterior technique ($n=17$). At follow-up evaluation (4.5±2 years) there was no difference in curve morphometry, correction, sagittal balance, average age, and follow-up period between Groups A and B. In reducing postoperative sagittal malalignment, the authors believe that surgical management should aim at a correction within the high normal kyphosis range of 40–50 degrees, consequently providing good results and, particularly in flexible adolescents and young adults, minimizing the necessity for an anterior release.

**Murray PM, Weinstein SL, Spratt KF (1993) The natural history and long-term follow-up of Scheuermann kyphosis. J Bone Joint Surg Am 75A:236–48**
Sixty-seven patients who had a diagnosis of Scheuermann kyphosis and a mean angle of kyphosis of 71 degrees were evaluated after an average follow-up of 32 years. The results were compared with those in a control group of 34 subjects who were matched for age and sex: The patients who had juvenile kyphosis had more intense back pain, jobs that tended to have lower requirements for activity, less range of motion of extension of the trunk and

less-strong extension of the trunk, and different localization of the pain. No significant differences between the patients and the control subjects were demonstrated for level of education, number of days absent from work because of low-back pain, extent that the pain interfered with activities of daily living, presence of numbness in the lower extremities, self-consciousness, self-esteem, social limitations, use of medication for back pain, or level of recreational activities.

**Poolman RW, Been HD, Ubags LH (2002) Clinical outcome and radiographic results after operative treatment of Scheuermann's disease. Eur Spine J 11: 561–9**
This paper is a prospective study to evaluate radiographic findings, patient satisfaction and clinical outcome, and to report complications and instrumentation failure after operative treatment of Scheuermann's kyphosis using a combined anterior and posterior spondylodesis. Significant correction was maintained at 1 and 2 years follow-up but recurrence of the deformity was observed at the final follow-up. The late deterioration of correction in the sagittal plane was mainly caused by removal of the posterior instrumentation, and occurred despite radiographs, bone scans and thorough intraoperative explorations demonstrating solid fusions. There was no significant correlation between the radiographic outcome and the SRS score. Therefore, the indication for surgery in patients with Scheuermann's disease can be questioned and surgery should be limited to patients with kyphosis greater than 75 degrees in whom conservative treatment has failed.

**Soo CL, Noble PC, Esses SI (2002) Scheuermann kyphosis: long-term follow-up. Spine J 2:49–56**
Sixty-three patients were evaluated a mean of 14 years after treatment (10–28 years) using a specially designed questionnaire. The patients had been treated using three different treatment modalities: exercise and observation, Milwaukee bracing, and surgical fusion using the Harrington compression system. At the time of follow-up evaluation, there were no differences in marital status, general health, education level, work status, degree of pain and functional capacity between the various curve types, treatment modality and degree of curve. Patients treated by bracing or surgery did have improved self-image. Patients with kyphotic curves exceeding 70 degrees at follow-up had an inferior functional result.

**Stagnara P, De Mauroy JC, Dran G, Gonon GP, Costanzo G, Dimnet J, Pasquet A (1982) Reciprocal angulation of vertebral bodies in a sagittal plane: Approach to references for the evaluation of kyphosis and lordosis. Spine 7:335–342**
This report establishes a table of references for kyphosis and lordosis in a sample of 100 healthy adults (43 females, 57 males, age 20–29 years) from France. Segmental measurements were carried out from standing lateral radiographs of the whole spine. Mean thoracic kyphosis was 37 degrees (range 7–63); mean lumbar lordosis was 50 degrees (range 32–84). The majority of individuals had a thoracic kyphosis of between 30 and 50 degrees. There was a correlation between sacral slope and lumbar lordosis and thoracic kyphosis. The considerable variability is stressed. As the distribution was found to be irregular, the authors consider it unreasonable to speak of normal kyphotic or lordotic curves. They state that average values are only indicative not normative.

## References


1. Arlet V (2000) Anterior thoracoscopic spine release in deformity surgery: a meta-analysis and review. Eur Spine J 9 Suppl 1:S17–23
2. Ascani E, La Rosa G (1994) Scheuermann's kyphosis. In: Weinstein SL (ed) The paediatric spine: Principles and practice. Raven Press, New York, pp 557–584
3. Aufdermaur E (1981) Juvenile kyphosis (Scheuermann's disease): Radiography, histology and pathogenesis. Clin Orthop 154:166–174
4. Bauer R, Erschbaumer H (1983) Die operative Behandlung der Kyphose. Z Orthop 121:367
5. Bernhardt M, Bridwell KH (1989) Segmental analysis of the sagittal plane alignment of the normal thoracic and lumbar spines and thoracolumbar junction. Spine 14:717–21
6. Bhojraj SY, Dandavate AV (1994) Progressive cord compression secondary to thoracic disc lesions in Scheuermann's kyphosis managed by posterolateral decompression, interbody

fusion and pedicular fixation. A new approach to management of a rare clinical entity. Eur Spine J 3:66 – 69
7. Blumenthal SL, Roach J, Herring JA (1987) Lumbar Scheuermann's. A clinical series and classification. Spine 9:929 – 32
8. Bosecker EH (1958) unpublished data cited in 10
9. Bouley C, Tardieu C, Hecquet J, Benaim C, Mouilleseaux B, Marty C, Prat-Pradal D, Legaye J, Duval-Beaupére G, Pélissier J (2006) Sagittal alignment of spine and pelvis regulated by pelvic incidence: standard values and prediction of lordosis. Eur Spine J 15:415 – 22
10. Bradford DS (1977) Editorial comment. Kyphosis. Clin Orthop Rel Res 128:2 – 4
11. Bradford DS (1977) Juvenile kyphosis. Clin Orthop Rel Res 128:45 – 55
12. Bradford DS, Ahmed KB, Moe JH, Winter RB, Lonstein JE (1980) The surgical management of patients with Scheuermann's disease. J Bone Jt Surg [Am] 62A:705 – 12
13. Bradford DS, Garcia A (1969) Neurological complications in Scheuermann's disease. J Bone Jt Surg [Am] 51A:567 – 72
14. Bradford DS, Moe JH, Montalvo FJ, Winter RB (1974) Scheuermann's kyphosis and round-back deformity. Results of Milwaukee brace treatment. J Bone Joint Surg [Am] 56A:740 – 58
15. Bradford DS, Moe JH, Montalvo FJ, Winter RB (1975) Scheuermann's kyphosis. Results of surgical treatment by posterior spine arthrodesis in twenty-two patients. J Bone Joint Surg [Am] 57A:439 – 48
16. Bruns I, Heise U (1994) Spastische Paraparese bei Morbus Scheuermann. Eine Kasuistik. Z Orthop Ihre Grenzgeb 132:390 – 393
17. Chiu KY, Luk KD (1995) Cord compression caused by multiple disc herniations and intraspinal cyst in Scheuermann's disease. Spine 20:1075 – 79
18. Edgar MA, Mehta MH (1988) Long-term follow-up of fused and unfused idiopathic scoliosis. J Bone Jt Surg [Br] 70B:712 – 16
19. Edgren W, Vainio S (1957) Osteochondrosis juvenilis lumbalis. Acta Chir Scand Suppl 227:3 – 47
20. Fallstrom K, Cochran T, Nachemson A (1986) Long-term effects on personality development in patients with adolescent idiopathic scoliosis. Influence of type of treatment. Spine 11:756 – 58
21. Findlay A, Conner AN, Connor JM (1989) Dominant inheritance of Scheuermann's juvenile kyphosis. J Med Genet 26:400 – 403
22. Fowles JV, Drummond DS, L'Ecuyer S, Roy L, Kassab MT (1978) Untreated scoliosis in the adult. Clin Orthop Rel Res 134:212 – 17
23. Greene TL, Hensinger RN, Hunter LY (1985) Back pain and vertebral changes simulating Scheuermann's disease. J Ped Orthop 5:1 – 7
24. Greulich WW, Pyle SI (1970) Radiographic atlas of skeletal development of the hand and wrist. Stanford University Press, Stanford, CA
25. Griss P, Pfeil J (1983) Ergebnisse rein dorsaler und combiniert ventrodorsaler Aufrichtungsoperationen bei der juvenilen Kyphose. Eine vergleichende Untersuchung am eigenen Krankengut. Z Orthop 121:369
26. Gutowski WT, Renshaw TS (1988) Orthotic results in adolescent kyphosis. Spine 5:485 – 89
27. Haglund P (1923) Prinzipien der Orthopädie. Gustav Fischer Verlag, Jena, p 495
28. Halal F, Gladhill RB, Fraser C (1978) Dominant inheritance of Scheuermann's juvenile kyphosis. Am J Dis Child 132:1105 – 1107
29. Herndon WA, Emans BJ, Micheli LJ, Hall JE (1981) Combined anterior and posterior fusion for Scheuermann's kyphosis. Spine 6:125 – 130
30. Hosman AJ, de Kleuver M, Anderson PG, van Limbeek J, Langeloo DD, Veth RP, Slot GH (2003) Scheuermann kyphosis: the importance of tight hamstrings in the surgical correction. Spine 19:2252 – 9
31. Hosman AJ, Langeloo DD, de Kleuver M, Anderson PG, Veth RP, Slot GH (2002) Analysis of the sagittal plane after surgical management for Scheuermann's disease: a view on overcorrection and the use of an anterior release. Spine 2:167 – 75
32. Ippolito E, Bellocci M, Montanaro A, Ascani E, Ponseti IV (1985) Juvenile kyphosis: An ultrastructural study. J Ped Orthop 5:315 – 322
33. Ippolito E, Ponsetti IV (1981) Juvenile kyphosis, histological and histochemical studies. J Bone Jt Surg [Am] 63A:175 – 182
34. Lambrinudi C (1934) Adolescent and senile kyphosis. Br Med J 2:800 – 4
35. Lang G, Kehr P, Aebi J, Paternotte H (1983) Die Behandlung der regulären Kyphose beim Jugendlichen. Z Orthop 121:368
36. Legaye J, Duval-Beaupere G, Hecquet J, Marty C (1998) Pelvic incidence: a fundamental pelvic parameter for three-dimensional regulation of spinal sagittal curves. Eur Spine J 7: 99 – 103
37. Lindemann K (1933) Die lumbale Kyphose im Adoleszentenalter. Z Orthop 58:54 – 65
38. Lonstein JE, Winter RB, Moe JH, Bradford DS, Chou SN, Pinto WC (1980) Neurologic deficit secondary to spinal deformity. A review of the literature and report of 43 cases. Spine 5: 331 – 55

39. Lowe TG (1987) Double L-rod instrumentation in the treatment of severe kyphosis secondary to Scheuermann's disease. Spine 12:336 – 41
40. Lowe TG (1999) Scheuermann's disease. Orthop Clin North Am 30(3):475 – 485
41. Lowe TG, Kasten MD (1994) An analysis of sagittal curves and balance after Cotrel-Dubousset instrumentation for kyphosis secondary to Scheuermann's disease. A review of 32 patients. Spine 19(15):1680 – 1685
42. MacLean WE Jr, Green NE, Pierre CB, Ray DC (1989) Stress and coping with scoliosis: psychological effects on adolescents and their families. J Ped Orthop 9:257 – 61
43. Montgomery SP, Erwin WE (1981) Scheuermann's kyphosis – Long-term results of Milwaukee brace treatment. Spine 6:5 – 8
44. Murray PM, Weinstein SL, Spratt KF (1993) The natural history and long-term follow-up of Scheuermann's kyphosis. J Bone Jt Surg [Am] 75(2):236 – 248
45. Newton PO, Shea KG, Granlund KF (2000) Defining the pediatric spinal thoracoscopy learning curve. Sixty-five consecutive cases. Spine 25:1028 – 35
46. Nissinen M (1995) Spinal posture during pubertal growth. Acta Paediatr 84:308 – 12
47. Nissinen M, Heliövaara M, Seitsamo J, Alaranta H, Poussa M (1994) Anthropometric measurements and the incidence of low back pain in a cohort of pubertal children. Spine 19:1367 – 70
48. Nissinen M, Heliövaara M, Seitsamo J, Poussa M (1995) Left handedness and risk of thoracic hyperkyphosis in prepubertal school children. Int J Epidemiol 24:1178 – 81
49. Noonan KJ, Dolan LA, Jacobson WC, Weinstein SL (1997) Long-term psychosocial characteristics of patients treated for idiopathic scoliosis. J Ped Orthop 17:712 – 17
50. Normelli HCM, Svensson O, Aaro SI (1991) Cord compression in Scheuermann's kyphosis. A case report. Acta Orthop Scand 62:70 – 72
51. O'Brien MF, Kuklo TR, Blanke KM, Lenke LG (2004) Radiographic measurement manual. Medtronic Sofamor Danek USA, Inc., pp 1 – 110
52. Olafsson Y, Saraste H, Almgren RM (1999) Does bracing affect self-image? A prospective study on 54 patients with adolescent idiopathic scoliosis. Eur Spine J 8:402 – 5
53. Otsuka NY, Hall JE, Mah JY (1990) Posterior fusion for Scheuermann's kyphosis. Clin Orthop 251:134 – 139
54. Payne WK 3rd, Ogilivie JW, Resnick MD, Kane RL, Transfeld EE, Blum RW (1997) Does scoliosis have a psychological impact and does gender make a difference? Spine 22:1380 – 84
55. Ponte A, Gebbia F, Eliseo F (1984) Nonoperative treatment of adolescent hyperkyphosis. Paper. 19th Annual Meeting of the Scoliosis Research Society, Orlando, FL
56. Poolman RW, Been HD, Ubags LH (2002) Clinical outcome and radiographic results after operative treatment of Scheuermann's disease. Eur Spine J 11:561 – 569
57. Poussa MS, Heliövaara MM, Seitsamo JT, Könönen MH, Hurmerinta KA, Nissinen MJ (2005) Anthropometric measurements and growth as predictors for low-back pain: a cohort study of children followed up from the age of 11 to 22 years. Eur Spine J 14:595 – 598
58. Reinhardt P, Bassett GS (1990) Short segmental kyphosis following fusion for Scheuermann's disease. J Spinal Disord 3(2):162 – 168
59. Ryan MD, Taylor TKF (1982) Acute spinal cord compression in Scheuermann's disease. J Bone Jt Surg [Br] 64B:409 – 12
60. Sachs B, Bradford D, Winter R, Lonstein J, Moe J, Willson S (1987) Scheuermann kyphosis. Follow-up of Milwaukee-brace treatment. J Bone Joint Surg Am 69:50 – 7
61. Schanz A (1911) Schule und Skoliose. Kritische Betrachtungen. Jahrb f Kinderrheilkunde 73:1 – 26
62. Scheuermann HW (1920) Kyphosis dorsalis juvenilis. Ugeskr Laeger 82:385 – 393
63. Scheuermann HW (1921) Kyphosis dorsalis juvenilis. Z Orthop Chir 41:305 – 317
64. Scheuermann HW (1936) Kyphosis juvenilis (Scheuermann's Krankheit). Fortschr Geb Röntgenstr 53:1 – 16
65. Sörensen KH (1964) Scheuermann's juvenile kyphosis. Munksgaard, Copenhagen
66. Soo CL, Noble PC, Esses SI (2002) Scheuermann kyphosis: long-term follow-up. Spine J 2:49 – 56
67. Speck GR, Chopin DC (1986) The surgical treatment of Scheuermann's kyphosis. J Bone Jt Surg [Br] 68B:189 – 93
68. Stagnara P (1981) Cyphoses dorsales regulieres pathologiques. In: SOFCOT – Conferences d'enseignement 1980. Expansion Scientifique, Paris, pp 51 – 76
69. Stagnara P, De Mauroy JC, Dran G, Gonon GP, Costanzo G, Dimnet J, Pasquet A (1982) Reciprocal angulation of vertebra bodies in a sagittal plane: Approach to references for the evaluation of kyphosis and lordosis. Spine 7:335 – 42
70. Tallroth K, Schlenzka D (1990) Spinal stenosis subsequent to juvenile lumbar osteochondrosis. Skeletal Radiol 19:203 – 5
71. Taylor TC, Wenger DR, Stephen J, Gillespie R, Bobechko WP (1979) Surgical management of thoracic kyphosis in adolescents. J Bone Jt Surg [Am] 61A:496 – 503
72. Timm H (1971) Zahl und Ausmass der Kyphosen in verschiedenen Altersstufen. Z Orthop 109:927 – 31

73. Vaz G, Roussouly P, Berthonnaud E, Dimnet J (2002) Sagittal morphology and equilibrium of pelvis and spine. Eur Spine J 11:80 – 87
74. Wenger DR (1993) Roundback. In: Wenger DR, Rang M (eds) The art and practice of children's orthopaedics. Raven Press, New York, pp 422 – 454
75. Willner S, Johnson B (1983) Thoracic kyphosis and lumbar lordosis during the growth period in children. Acta Paediatr Scand 72:873 – 78
76. Yablon JS, Kasdon DL, Levine H (1988) Thoracic cord compression in Scheuermann's disease. Spine 13:896 – 98

# 29 Malformations of the Spinal Cord

Dilek Könü-Leblebicioglu, Yasuhiro Yonekawa

## Core Messages

- ✔ Spinal cord malformations (=spinal dysraphisms) are usually diagnosed at birth or early infancy (open spinal dysraphism, closed spinal dysraphisms with a back mass) but are sometimes not discovered before adulthood
- ✔ Spinal cord malformations arise from defects occurring in the embryological stages of gastrulation (weeks 2–3), neurulation (weeks 3–6) and caudal regression
- ✔ The term "spina bifida" merely refers to a defective fusion of posterior spinal bony elements but is still incorrectly used to refer to spinal dysraphism in general
- ✔ "Tethered spinal cord" is a broadly used umbrella term for numerous spinal cord abnormalities, such as lipomyelomeningocele, previously operated on myelomeningoceles, or thickened filum terminale, which tether (fasten, fix) the spinal cord in the spinal canal
- ✔ Tethered cord syndrome is a stretch-induced functional disorder of the spinal cord worsened by daily, repeated mechanical stretching, and distortion may even occur in patients who have the conus at normal level
- ✔ Patients with spinal cord malformation are either diagnosed at birth or present later because of unexplained pain, neurological deficits, unclear recurrent urologic infections, cutaneous markers or orthopedic deformities
- ✔ MRI is the imaging modality of choice and has increased the number of tethered spinal cord diagnoses
- ✔ Prenatal treatment encompasses prophylactic folic acid substitution and intrauterine surgery
- ✔ Open spinal dysraphism is best surgically treated postpartum to untether the spinal cord, prevent infections, repair the dural/cutaneous defect, and restore normal anatomy as far as possible
- ✔ Closed spinal dysraphism with tethered spinal cord warrants early untethering, when minimum or mild symptoms are detected
- ✔ Surgery after development of the deficits only stops progression, but symptoms may even further progress after detethering
- ✔ Individuals with spinal malformations need both lifelong surgical and medical management, which should be provided by a multidisciplinary team

## Epidemiology

Spine and spinal cord malformations are often collectively summarized under the term of **spinal dysraphisms** [39]. This term was first employed by Lichtenstein (1940) [36]. Open spinal dysraphism is a common congenital midline defect of the nervous system and has been historically reported in 2–4/1 000 live births [14]. However, the true incidence of spinal dysraphism is not well studied. Myelomeningocele accounts for the vast majority of open spinal dysraphisms (98.8 %) [32, 39].

Myelomeningocele is the most common form of open spinal dysraphism

**Myelomeningocele** occurs in 0.6 patients per 1 000 live births, and females are affected slightly more often than males (by a ratio of 1.3 to 3), with the first-born usually affected [5, 39]. **Myelocele** is a rare malformation and represents only 1.2 % of all open spinal dysraphisms [39]. The most common locations for these malformations are, in decreasing frequency, lumbosacral, thoracolumbar and

The incidence of myelomeningocele is 0.6 per 1 000 live births

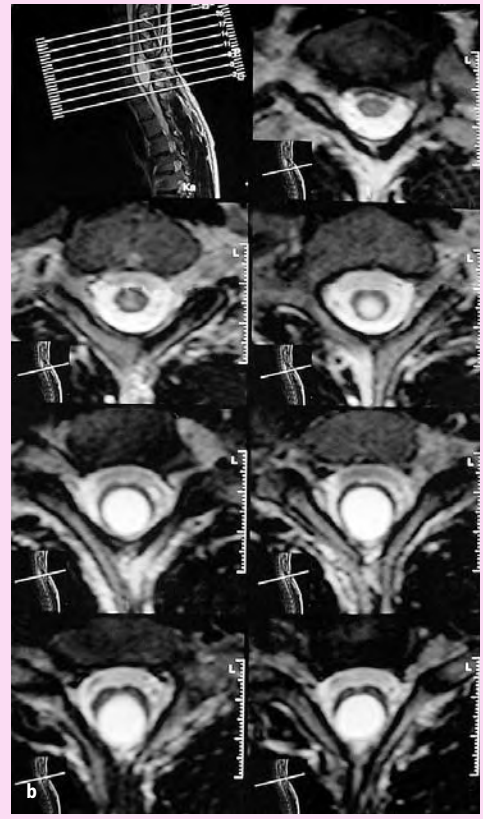


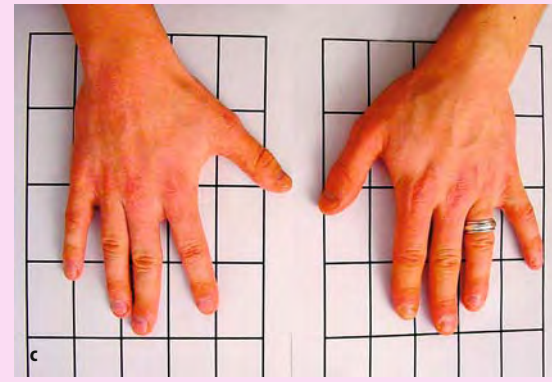


## Case Introduction

A 17-year-old patient presented with progressive tethered cord syndrome with worsening of hand functions and some leg weakness and increasing spasticity. Postnatally he had had a cervical myelomeningocele and had had only "cosmetic" closure after the birth. The MRI showed a widened spinal canal at C6–C1 (a, c), cord tethering dorsally at C6–7 and dorsal limited myeloschisis. It is possible to see the hypotrophic right hand (b). This clinical worsening recovered after an intradural exploration and dissection of the stalk placode.

cervical spine [5, 39]. The incidence of myelomeningocele varies from country to country and from one geographical region to another [20]. Since the early 1980s, estimation of the prevalence of open spinal dysraphism in many industrialized countries has been decreased by folic acid administration to pregnant women and the availability of prenatal diagnosis and elective termination [20, 29, 48]. Patients with open spinal dysraphism almost always have associated Chiari II malformation. There are also reports in the medical literature of an association between closed spinal dysraphisms and Chiari II [41].

Spina bifida is present in 90–100% of patients with tethered cord

**Spina bifida occulta** occurs in approximately 17–30% of the total population and is present in 90–100% of patients with tethered cord [35, 61]. The dermal sinus is a common abnormality and accounts for 23.7% of all closed spinal dysraphisms. Overall, caudal regression syndrome is not uncommon, accounting for

16.3 % of all closed spinal dysraphisms. **Sacral agenesis** occurs in approximately one per 7 500 births without a gender predisposition.

In the normal adult population the conus terminates at L2 in 95 % of cases [19, 48]. In its classical form, tethered cord implies a low-lying conus, but tethered cord syndrome may occur in the presence of a conus in normal position [19, 37, 40, 46, 48, 54, 56]. Up to 15 % of patients with repaired myelomeningoceles will experience a secondary tethered cord syndrome later in life [36].

The conus normally terminates at L2

## Pathogenesis

### Embryological Aspects

Knowledge of normal embryology is essential for the understanding of the pathogenesis and a wide spectrum of pathoanatomy of spine and spinal cord anomalies as well as tethered cord. The most comprehensive embryonic staging system is that of O'Rahilly [23] and most of the information on early human development has been obtained through study of the **Carnegie collection** [23]. Early neural development has been reviewed in various basic science articles [21]. O'Rahilly provides a timetable for each important event in early neural morphogenesis: the **embryonic period** begins at conception with stage 1 and ends at stage 23. Beyond this time, the developing human enters the fetal period [6, 23] (Table 1).

**Table 1.** Human embryogenesis

| | Weeks | Days | Carnegie stage | Process | Size (mm) | Somite number | Events |
|---|---|---|---|---|---|---|---|
| *Embryonal period* | **Week 1** | 1 | **1** | fertilization | 0.1 – 0.15 | | fertilized oocyte, pronuclei |
| | | 2 – 3 | **2** | cleavage | 0.1 – 0.2 | | cell division with reduction in cytoplasmic volume, formation of inner and outer cell mass |
| | | 4 – 5 | **3** | blastula | 0.1 – 0.2 | | loss of zona pellucida, free blastocyst |
| | | 5 – 6 | **4** | | 0.1 – 0.2 | | attaching blastocyst |
| | **Week 2** | 7 – 12 | **5** | | 0.1 – 0.2 | | implantation |
| | | 13 – 15 | **6** | | 0.2 | | extraembryonic mesoderm, primitive streak |
| | **Week 3** | 15 – 17 | **7** | gastrulation | 0.4 | | gastrulation, notochordal process |
| | | 17 – 19 | **8** | neurulation | 1.0 – 1.5 | | primitive pit, notochordal canal |
| | | 19 – 21 | **9** | somatization | 1.5 – 2.5 | 1 – 3 | neural folds, cardiac primordium, head fold |
| | **Week 4** | 22 – 23 | **10** | | 2 – 3.5 | 4 – 12 | neural fold fuses |
| | | 23 – 26 | **11** | | 2.5 – 4.5 | 13 – 20 | rostral neuropore closes |
| | | 26 – 30 | **12** | | 3 – 5 | 21 – 29 | caudal neuropore closes |
| | **Week 5** | 28 – 32 | **13** | organogenesis | 4 – 6 | 30 | leg buds, lens placode, pharyngeal arches |
| | | 31 – 35 | **14** | | 5 – 7 | | lens pit, optic cup |
| | | 35 – 38 | **15** | | 7 – 9 | | lens vesicle, nasal pit, hand plate |
| | **Week 6** | 37 – 42 | **16** | | 8 – 11 | | nasal pits moved ventrally, auricular hillocks, foot plate |
| | | 42 – 44 | **17** | | 11 – 14 | | finger rays |
| | **Week 7** | 44 – 48 | **18** | | 13 – 17 | | ossification commences |
| | | 48 – 51 | **19** | | 16 – 18 | | straightening of trunk |
| | **Week 8** | 51 – 53 | **20** | | 18 – 22 | | upper limbs longer and bent at elbow |
| | | 53 – 54 | **21** | | 22 – 24 | | hands and feet turned inward |
| | | 54 – 56 | **22** | | 23 – 28 | | eyelids, external ears |
| *Fetal period* | **Week 9** | 56 – 60 | **23** | phenogenesis | 27 – 31 | | rounded head, body and limbs longer |

## Relevant Embryogenetic Steps

Spinal cord embryological development occurs through **three consecutive periods** [11, 19, 26, 39, 48, 58]:

### Gastrulation

The trilaminar embryo develops by day 18 of gestation. At this point, the embryo is composed of endoderm, mesoderm and ectoderm. Shortly thereafter, the mesoderm releases factors which induce the differentiation of the overlying neuroectoderm, thereby forming the neural tube.

### Neurulation

After gastrulation the ectoderm above the notochord folds to form a tube, the neural tube; this gives rise to the brain and the spinal cord, a process known as neurulation. **Primary neurulation** (weeks 3–4): The process of fusion begins in the region of the lower medulla and proceeds rostrally and caudally. The anterior neuropore closes at about 24 days and the posterior neuropore at 26–28 days. The brain and the spinal cord are formed by primary neurulation, which involves the shaping, folding, and midline fusion of the neural plate. It is completed about the 25–26th day of conception. The central canal is formed and is lined by ependyma. The caudal cell mass, a group of undifferentiated cells at the caudal end of the neural tube, develops vacuoles. These vacuoles merge together and expand, ultimately meeting the central canal of the rostral cord and causing elongation of the neural tube in a process called canalization. **Secondary neurulation** and **retrogressive differentiation** (weeks 5–6) results in formation of the conus tip and filum terminale. The formation of the lower lumbar, sacral, and coccygeal portions of the neural tube are by canalization and retrogressive differentiation. Overlapping with canalization, the process of retrogressive differentiation of the caudal cell mass takes place. In this process, the filum terminale, conus medullaris, and ventriculus terminalis are formed.

Filum terminale and conus medullaris are formed during the process of neurulation

### Caudal Regression

The conus medullaris ascends during spinal growth

At the time when the neurulation process is complete (weeks 6–7), the terminal filum and cauda equina are formed from the caudal portion of the neural tube by **regression**. The conus medullaris initially rests in the coccygeal region and appears to ascend as the spine grows more rapidly than the cord. At birth the conus is usually at the caudal level of L2–L3 and by 3 months of age it is at L1–L2, where it remains (relative ascent of the spinal cord). The spinal cord terminates at or above the inferior aspect of the L2 vertebral body in 95 % of the population and at or above the L1–L2 disc space in 57 % of the population. The conus medullaris has reached its mature adult level at term in most infants and 100 % of cases at approximately 3 months after full-term gestation [39, 48, 58]. The conus medullaris initially rests in the coccygeal region and appears to ascend as the spine grows more rapidly than the cord. At birth the conus is usually at the caudal level of L2–L3 and by 3 months of age it is at L1–L2, where it remains.

Interference with normal development at any stage is responsible for the various abnormalities seen in the cases of **spinal malformations** [19, 26, 38, 39, 58] (Table 2).

**Table 2.** Embryological classification of spinal dysraphisms

| Embryological stage | | Dysraphism |
|---|---|---|
| Gastrulation | Notochordal integration | • neuroenteric cysts and fistula<br>• split cord malformations (diastematomyelia, diplomyelia)<br>• dermal sinus, fistula<br>• dermoid/epidermoid tumors |
| | Notochordal formation | • caudal regression syndrome<br>• segmental spinal dysgenesis |
| Primary neurulation | | • myelomeningocele<br>• myelocele<br>• lipomyelomeningocele<br>• lipomyeloschisis<br>• intradural spinal lipoma |
| Secondary neurulation<br>Canalization | | • tight filum terminale, filum terminale lipoma |
| Retrogressive differentiation | | • intrasacral meningocele, sacral cysts |

## Risk Factors

Most spinal cord anomalies result from a complex interaction between several genes and poorly understood environmental factors. A list of variables have been implicated as risk factors for spinal dysraphisms but only a few have been established.

### Genetic Factors

Spinal cord anomalies occur in many syndromes and chromosome disorders. However, a spinal dysraphism may be the only anomaly in a member of a family, in which case the relatives have an increased risk for all types of **tethered cord**. A family history is one of the strongest risk factors [20, 26].

Family history is an important risk factor

### Environmental Factors

Periconceptual multiple vitamin supplements containing **folic acid** reduce the incidence of neural tube defects. In England and the United States, it is recommended that women planning pregnancy take 0.4 mg folic acid daily before conception and during the first 12 weeks of pregnancy [14, 44]. Up to 70 % of spina bifida cases can be prevented by periconceptional folic acid supplementation [20, 26].

Periconceptual folic acid substitution reduces the incidence of neural tube defects

### Maternal Diabetes

In women with **pre-gestational diabetes**, the risk of having a child with a central nervous system malformation (including spinal malformations) is twofold higher than the risk in the general population [20].

Pre-gestational diabetes is a risk faktor for spinal malformation

### Medication

Some drugs taken during pregnancy may increase the risk. These include sodium valproate and folic acid antagonists such as trimethoprim, triamterene, carbamazepine, phenytoin, phenobarbital and primidone [20].

Valproic acid or carbamazepine increases the risk of spinal malformation

## Pathophysiology of Tethered Cord Syndrome

Tethering of the spinal cord results in progressive neurological deficits

Tethered cord is a spinal cord malformation in which the spinal cord is fixed in an abnormally low position and in a relatively immobile state [2, 19, 39, 46, 58]. In this context, the term "tether" refers to "fasten" or "restrain". Tethered cord exists in open and occult forms of spinal dysraphisms [15, 48]. The normal spinal cord is free, i.e. it is not attached to any surrounding structures in the spinal canal except for denticulate ligaments and nerve roots. A tethered cord is tightly fixed so that there is not a normal movement of the spinal cord. During the formation of the embryonic spinal cord, it fills the entire length of the spinal canal. As the fetus grows, the vertebral column grows faster than the spinal cord. Thus, the distal end of the spinal cord is located at the level of the first or second lumbar vertebral body (L1 – L2). If there is an abnormality affecting this "ascension" of the spinal cord (e.g. myelomeningocele, tight filum terminale, diastematomyelia, secondary scar formations, tumors), the spinal cord is tethered [50]. This results in stretching of the spinal cord and causes neurological damage even during the fetal period. By the time a child is born, the spinal cord is normally located between the first or second lumbar vertebral body. After birth, continuing growth puts further stretch on the tethered spinal cord; this damages the spinal cord both by directly stretching it, and by interfering with the blood supply and oxidative metabolism [51].

A tethered cord can occur even with a normal level conus

If neurological findings are already present the further clinical deterioration can be anticipated. Since an adult spine is no longer growing, children are obviously more at risk than adults. However, even adults with tethered cord can show deterioration. This is due to daily repetitive-cumulative stretching on the tethered cord. A sudden flexion movement of the spine can also produce symptomatic onset of the tethered cord syndrome [9, 51]. Irreversible neuronal damage can occur when there is sudden stretching of the already chronically tethered conus [51]. Yamada and coworkers have nicely demonstrated changes in spinal cord blood flow and oxidative metabolism following tethering of the spinal cord both in experimental animals and humans [9, 51, 52, 55, 58]. Usually a tethered cord results in a low conus position. However, there are many cases of tethered cord syndrome reported with the conus at a normal level [37, 40, 46].

A tethered cord can occur with the conus at a normal level

## Terminology and Classification

Spinal cord malformations can be categorized as:

- open spinal dysraphisms
- closed (occult) spinal dysraphism

**Open spinal dysraphism** is characterized by exposure of the abnormal spinal nervous tissue and/or meninges to the environment through a bony and skin defect. Open spinal dysraphism basically includes myelocele and myelomeningocele. In **closed spinal dysraphism**, there is no exposure of neural tissue (covered by skin). However, some kind of cutaneous stigmata, such as hairy patch, dimples, or subcutaneous masses, can be recognized in up to 50 % of closed forms [15, 32, 47].

**Spina bifida** results from a defective fusion of posterior spinal bony elements and leads to a bony cleft in the spinous process and lamina (L5 and S1). The term has incorrectly been used to refer to spinal dysraphism in general [32, 39]. The terms **spina bifida aperta or cystica** and **spina bifida occulta** were used to refer to open spinal dysraphism and closed spinal dysraphism, respectively. These terms have been progressively discarded [32].

**Table 3.** Chiari malformations

| | |
|---|---|
| **Type 1** | • caudal displacement of the cerebellum<br>• cerebellar tonsils below the plane of the foramen magnum<br>• no involvement of the brainstem<br>• associated with occult spinal dysraphism (e.g. spinal lipomas)<br>• note – *cerebellar ectopia* can be a normal finding (up to 5 mm) |
| **Type II** | • small and crowded posterior fossa<br>• caudal displacement of the fourth ventricle and medulla into the upper cervical canal<br>• tonsils can be at or below the level of the foramen magnum usually<br>• association with a variety of cerebral anomalies frequently associated with myelomeningoceles |
| **Type III** | • displacement of the posterior fossa structures into the cervical canal (seldom compatible with life) |
| **Type IV** | • cerebellar hypoplasia without herniation |

**Placode** (neural placode) is a segment of non-neurulated embryonic neural tissue. It is in contact with air in open spinal dysraphism and covered by the integument in closed spinal dysraphism. A **terminal placode** lies at the caudal end of the spinal cord and may be apical or parietal depending on whether it involves the apex or a longer segment of the cord. A **segmental placode** may lie at any level along the spinal cord [32, 39].

Differentiate hydromyelia from syringomyelia

**Hydromyelia** is the simple dilatation of the central canal and is lined by the ependyma. An extension into cord parenchyma constitutes a true **syringomyelia**. Two forms of syringomyelia can be differentiated:

- **communicating** syringomyelia
- **non-communicating** syringomyelia

Communicating syringomyelia is related to a primary dilatation of the central canal and is usually associated with abnormalities of the craniocervical junction (e.g. Chiari malformations). Non-communicating syringomyelia may result from trauma, tumors or inflammation and does not communicate with the central canal or the subarachnoidal space.

**Chiari malformations** are hind brain abnormalities and are observed in conjunction with spinal cord malformations. They are categorized into four types, with Types I and II accounting for 99 % of the clinical cases (Table 3).

## Classification of Spinal Malformation

From a clinical perspective, a practicable classification system of spinal cord anomalies is needed. However, the large variety of features associated with these anomalies makes such classification difficult. Classical classifications rely on the embryological development cascade [11, 19, 22, 39, 58] (Table 4). We find the mixed clinical-neuroradiological classification system presented by Donati et al. [5, 32, 39] useful.

From the **clinical perspective**, a question framework to approach the spectrum of spinal cord malformation is useful:

- Is there a back mass?
- Is it covered with skin?
- Are there cutaneous markers?
- Is there a tethered cord syndrome?

**Table 4.** Classification of spinal malformations

| | | |
|---|---|---|
| | **Spinal malformations with back mass** | |
| Open spinal dysraphism | *With a non-skin-covered back mass (spina bifida aperta)*<br>• myelomeningocele<br>• myelocele (myeloschisis) | Almost always associated with Chiari II malformation |
| Closed (occult) spinal dysraphism | *With a skin-covered back mass (spina bifida cystica)*<br>• meningocele (posterior)<br>• myelocytocele<br>• lipomyelomeningocele/lipomyeloschisis | |
| | **Spinal malformations without back mass**<br>• spinal lipoma (intradural and/or intramedullary)<br>• anterior sacral/lateral thoracic meningocele<br>• tight filum terminale/filum terminale lipoma<br>• dermal sinus, fistula, dermoid/epidermoid tumors<br>• neuroenteric/bronchogenic cysts and fistula (split notochord syndrome)<br>• split cord malformations (diastematomyelia, diplomyelia)<br>• caudal regression/agenesis<br>• intrasacral meningocele/sacral cysts<br>• neuroectodermal appendages | |

### Myelomeningocele and Myelocele

Myelomeningoceles and myeloceles are characterized by exposure of spinal intradural elements through a midline defect to the air. The basic defect of myelomeningocele is caused by an abnormality, which occurs at the stage of neurulation that prevents the neural tube from closing dorsally [5, 19, 22, 27, 39]. A myelomeningocele consists of a sac of exposed neural tissue-placode, which is clefting dorsally, splayed open and herniates through a large dysraphic defect through the bone and dura beyond the surface of the back. The cord is tethered posteriorly at this level. In **myelocele** (synonym: myeloschisis), however, the neural placode is flush with the plane of the back and identifiable on the surface. All children with myelomeningocele have tethered cord from the time of birth. One can easily visualize how tethering of the spinal cord might occur (Case Study 1).

Patients with myelomeningocele and myelocele almost always (75–100%) have associated **Chiari II malformation** (Table 3) [5, 14, 20, 32, 39]. Distortion and maldevelopment of the medulla and midbrain can cause lower cranial nerve palsies and central apnea (which may be misdiagnosed as epilepsy) [44].

Patients with myelomeningocele and myelocele almost always have associated Chiari II malformation

Hydrocephalus may be present at birth, but usually appears within 2–3 days after surgery [14, 32, 45]. The rate of hydrocephalus in patients with occult spinal dysraphism has been reported to be over 80% [14, 43]. Hydromyelia may occur in as many as 80% of these patients, and may be localized or extend through the whole cord. It may cause rapid development of scoliosis if left untreated [18, 29, 32].

### Meningocele

The **posterior meningocele** consists of a **herniated sac of meninges** with CSF protruding from the back and covered with skin. It is commonly lumbar or sacral in location, but thoracic and even cervical meningoceles may be found. The spinal cord and conus are seen in the normal position [5, 32, 39], although both nerve roots and, more rarely, a hypertrophic filum terminale may course within the meningocele. No part of the spinal cord is contained within the sac by definition [5]. The spinal cord itself is completely normal structurally, although it is usually tethered to the neck of sacral meningoceles [39]. A Chiari II malformation is found only exceptionally. **Anterior meningoceles** are typically presacral,

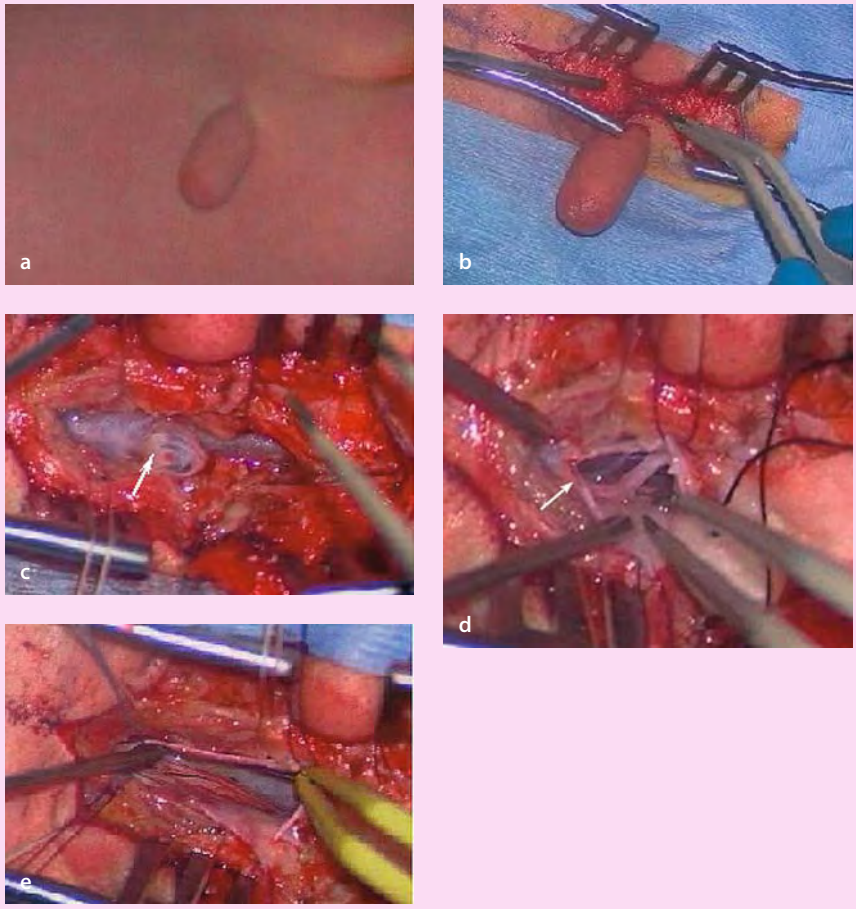


**Case Study 1**

A 9-month-old male child was brought for consultation because of a "tail-like" structure in the low back since birth. Examination revealed a subtle thinning of the right lower extremity and a caudal appendage (pseudotail) in the lower lumbosacral region (a). Plain radiographs revealed spina bifida at L5. MRI revealed a tethered cord with fatty filum terminale. The pseudotail is a short, stump-like structure (b). Spinal dysraphism is the most frequent coexisting anomaly in both anatomical variants (50 %). Other associated lesions include tethered cord syndrome, lipomas, teratomas and gliomas. Investigation of children born with human tail appendages should include a thorough neurological examination, plain X-ray films of the lumbosacral region and contrast MRI to look for dysraphism and associated lesions. During surgery, a fibrous, fatty filum terminale was seen extending from the base of the appendage through the defect in the bone and dura. The hypertrophied and fat-infiltrated filum ended at the tip of the low lying conus (c). The filum is coagulated with bipolar coagulation as there is typically a small vein within the filum (d). We prefer to remove a segment of the affected filum (e) and submit it to pathological examination for confirmation. After surgery, there was no change in the neurological status of the patient.

and are found in patients with caudal agenesis [32]. They are usually discovered in older children or adults complaining of low back pain, urinary incontinence or constipation.

### Myelocystocele

A myelocystocele consists of a cystic dilatation of the lower end of the spinal cord or the cervical region enclosed in a skin covered back mass [5, 39]. The spinal cord is low lying and tethered [5]. The subcutaneous fat lines the cyst but does not extend into the sac or the cord.

A myelocystocele represents a cystic dilatation of the spinal cord in the cervical or lumbar spine

The inner terminal cyst communicates with the central canal of the spinal cord, whereas the outer dural sac communicates with the subarachnoid space. The outer and inner fluid spaces usually do not communicate. Tethering results from the attachment of the myelocystocele to the inferior aspect of the spinal cord. The syringocele lies caudal to the meningocele in all cases and bulges through a wide spina bifida, producing a skin-covered subcutaneous mass that may be huge. Patients with terminal myelocystoceles typically have no bowel or bladder control and poor lower-extremity function [32].

### Lipomyelomeningocele/Lipomyeloschisis

In lipomyeloschisis and lipomyelomeningocele, the **intraspinal lipoma** is a portion of a larger subcutaneous lipoma, extending into the spinal canal through a wide posterior spina bifida and tethering the spinal cord; it consists of a skin-covered back mass that contains neural tissue, CSF and meninges [5, 39]. The bony anomalies include a large defect in the posterior elements of the spine, segmentation anomalies and sacral dysgenesis. Association with Chiari I malformation may be seen [5]. In lipomyelomeningoceles, a subcutaneous lumbosacral mass is found in 90 % of patients [48]. Additional skin abnormalities are found in 50 % of patients and may include an area of hypertrichosis, a capillary hemangioma, a dermal sinus tract, a dimple, or an additional appendage. Because the mass is clinically evident at birth, the diagnosis is usually obtained before neurological deterioration ensues [5].

Differentiation between lipomyeloschisis and lipomyelomeningocele is based on whether the **placode-lipoma interface** lies within the anatomic boundary of the spinal canal or outside (i.e. within an meningeal outpouching). A further classification widely used by neurosurgeons divides these lipomas into three subcategories: dorsal, transitional, and caudal, depending on whether the placode is segmental, parietal, or terminal [26].

### Spinal Lipoma (Intradural and/or Intramedullary)

Intradural and intramedullary lipomas are similar to lipomas with dural defects. However, they are contained within an intact dural sac. In other words, they are localized within the intradural space [1, 5, 26, 32, 39]. Failure to differentiate between lipomyelomeningoceles, intradural lipomas and filum terminale lipomas may lead to inaccurate assumptions regarding prognosis [4]. These lesions have different clinical presentations, courses and outcomes [4].

Differentiation of the different entities is crucial

**Intradural lipomas** account for 24.1 % of all spinal lipomas [39].

The cord is low lying and tethered to the lipomatous tissue [5]. Intradural lipomas are commonly located at the lumbosacral level, but may be found anywhere in the spinal canal, which may be focally or diffusely expanded depending on the size of the mass (Fig. 1).

Spinal lipomas can be associated with diastematomyelia

The lipoma may be associated with other cord anomalies such as diastematomyelia. Associated vertebral anomalies consisting of spina bifida at one or several vertebral levels may be present [5]. Lipomas located at the bottom of the thecal sac usually present clinically with tethered cord syndrome, whereas cervicothoracic lipomas generally produce insidious signs of spinal cord compression. It is widely accepted that congenital intraspinal lipomas are anatomically stable lesions. However, the subcutaneous and intraspinal components may grow as part of the normal increase of adipose tissue that occurs throughout childhood, other than in particular conditions such as obesity or pregnancy [48]; therefore, clinical worsening may ensue if the lesion is left untreated.

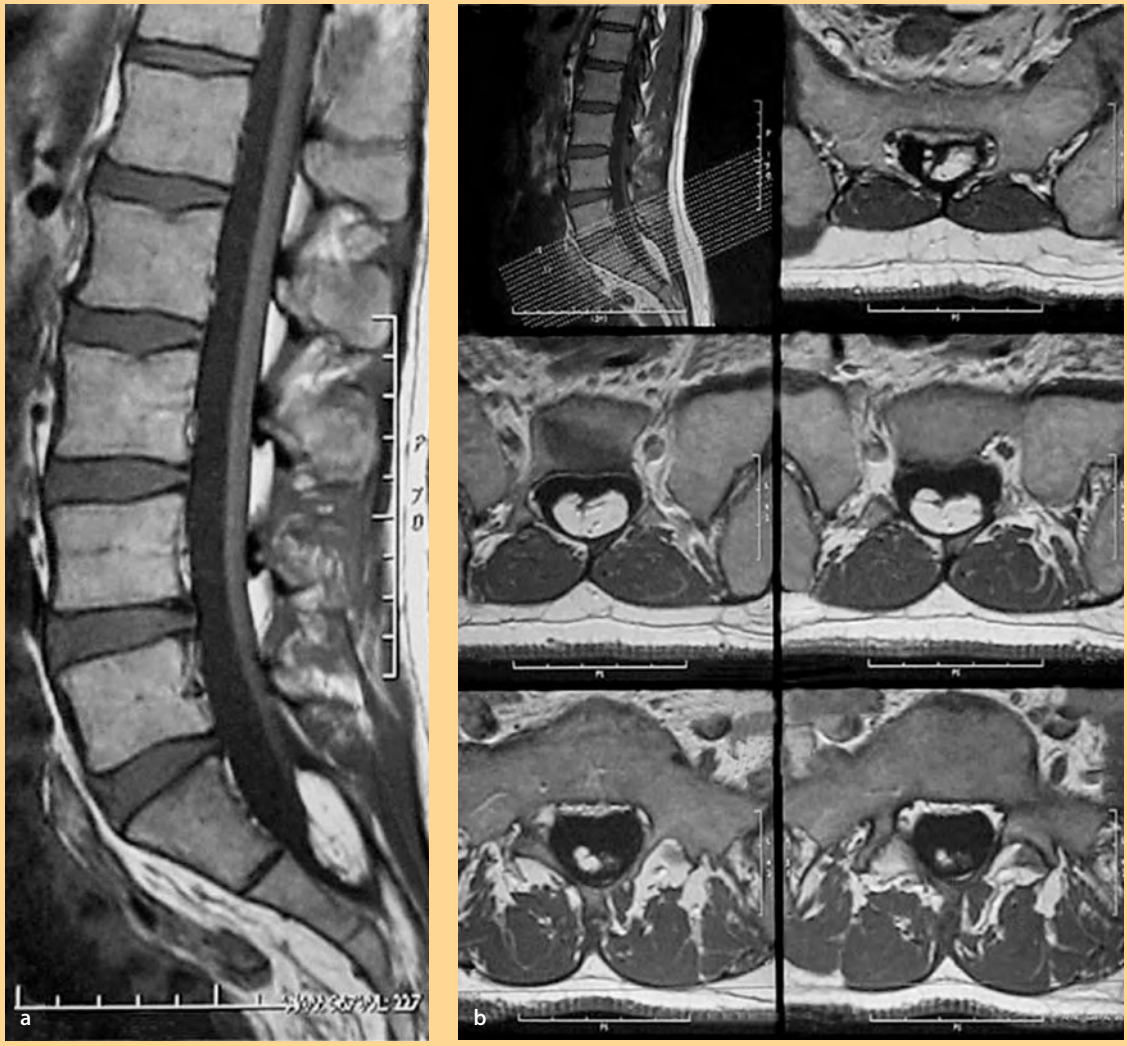


**Figure 1. Intradural spinal lipoma**

MRI of intradural spinal lipoma in a 37-year-old man. a Sagittal T1W image shows the spinal cord tethered to the anterior surface of an intradural lipoma. b Axial images show indistinct fat-cord interface.

### Anterior Sacral/Lateral Thoracic Meningocele

Anterior sacral meningocele occurs when there is communication between the retroperitoneal or infraperitoneal space and spinal subarachnoidal space through a defect in the anterior sacrum. The mass that develops is a fibrous connective tissue capsule filled with spinal fluid, and may contain some sacral nerve root elements. This malformation is three times more common in females. Similar abnormalities may occur at the lumbosacral and thoracic levels.

### Tight Filum Terminale/Filum Terminale Lipoma

The filum terminale is a **viscoelastic formation** usually <2.0 mm wide [40], which allows the conus to ascend during flexion of the spine. The tight filum terminale (9% of all closed spinal dysraphisms) is characterized by a short, hypertrophic, fatty filum terminale that produces tethering of the spinal cord and

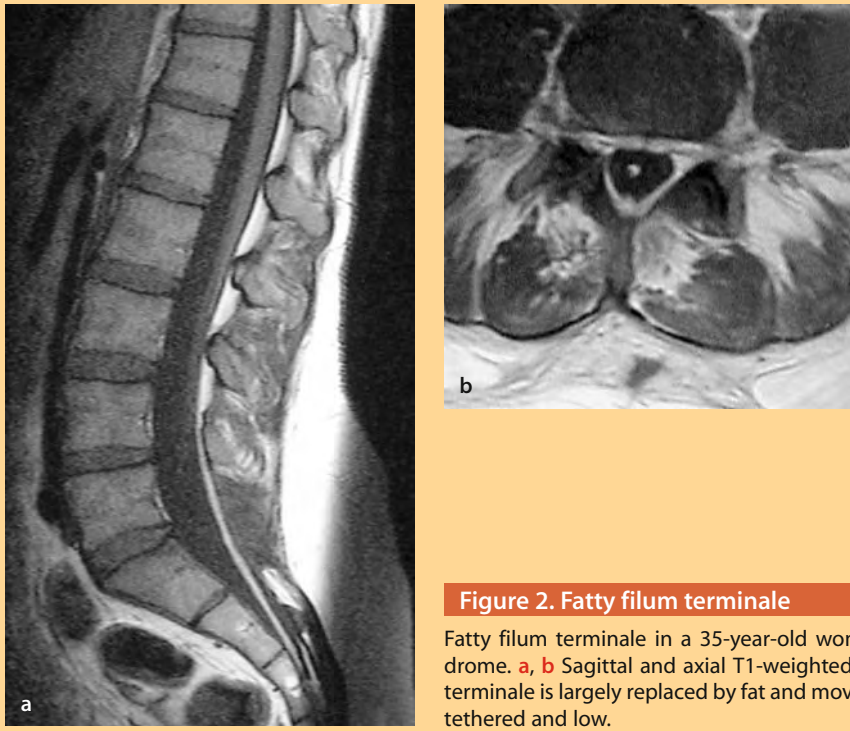


**Figure 2. Fatty filum terminale**

Fatty filum terminale in a 35-year-old woman with tethered cord syndrome. a, b Sagittal and axial T1-weighted images show that the filum terminale is largely replaced by fat and moved dorsally. The spinal cord is tethered and low.

impaired ascent of the conus medullaris [32]. A filum terminale greater than 2 mm in diameter refers to the thick-tight filum terminale [5, 19, 48].

The thickening is caused by lipomatous or fibrous tissue. The occurrence of incidental fat within the terminal filum in a normal adult population has been estimated to be 3.7% in cadaveric studies [48]. Radiologically, the conus is either normal in location or low-lying with a thickened filum terminale [5]. In 86% of patients, the tip of the conus medullaris lies inferior to L2 [19, 32]. This anomaly may be difficult to diagnose, although the association of clinical and neurological features may lead one to suspect it. The filum terminale must not be >2 mm in diameter and no fatty tissue must be present; otherwise, the abnormality is best defined as a **filar lipoma** or **fibrolipoma** [39]. The terminal filum is the tethering agent, and these patients respond to sectioning of the filum (Fig. 2). In the majority of patients, there are no cutaneous anomalies, but posterior spina bifida, scoliosis, and kyphoscoliosis are associated in a high percentage of cases.

A filum terminale of >2 mm is defined as a fibrolipoma

### Dermal Sinus, Fistula, Dermoid/Epidermoid Tumors

The dermal sinus is an **epithelium-lined fistula** that extends inward from the skin surface and can connect with the central nervous system and the meninges coating, thereby causing tethering [5, 48]. It is found more frequently in the lumbosacral region, although cervical, thoracic, and occipital locations are possible [32, 39]. Although the cutaneous abnormality is usually evident at birth, some patients are not referred to medical attention until they develop complications such as local infection or meningitis and abscesses that may result from bacteria invading the CNS through the dermal sinus tract [48].

They also may connect to a hypertrophic or fibrolipomatous filum terminale, as well as to a low-lying conus medullaris or intraspinal lipoma. In a considerable percentage of cases, dermal sinuses are associated with dermoid and epidermoid tumors, generally located at the level of the cauda equina or near the conus medullaris [5, 13, 32]. This association was found in 11.3 % of cases [32].

### Neuroenteric/Bronchogenic Cysts and Fistula (Split Notochord Syndrome)

There is abnormal splitting of the notochord with persistent connection between the gut and the dorsal skin [5, 19, 22]. The abnormal communication may involve esophagus, bronchus, and intestines. The abnormal tract may become obliterated at any point with consequent variable outcome such as a cyst (neuroenteric cyst, bronchogenic cyst), diverticulum or fistula [5, 32]. These cysts are lined with a mucin secreting epithelium that resembles the alimentary or bronchogenic epithelium. Whereas the cyst is frequently associated with anterior or posterior spina bifida, it may be found without any associated dysraphic anomalies [48].

### Split Cord Malformations (Diastematomyelia, Diplomyelia)

Split cord malformation (SCM) is a form of occult spinal dysraphism that also produces spinal cord tethering [5, 42]. Split cord malformations are classically defined as diastematomyelia. Two forms of split cord malformation have been described. From a strict point of view, diastematomyelia refers to cord splitting and diplomyelia to cord duplication [26, 34, 39].

**Split cord malformations** are usually located in the lumbar and thoracic regions and are more common in girls [5, 42].

Split cord malformations are commonly located in the lumbar and thoracic spine

- **Type I** split cord malformation accounts for 40 – 50 % of all SCMs. There is a double dural sac, a double spinal canal and two hemicords separated by an extradural bony spur [26, 34, 39].
- **Type II** split cord malformation accounts for 50 – 60 % of all SCMs. There is one dural sac, one spinal canal, and two equal hemicords between which there may be an anterior-posterior, fibrous intradural spur [26, 34, 39, 48].

**Klippel-Feil syndrome** (ranging from congenital fusion of only the vertebral bodies to entire fusion of the vertebrae and can be associated with hemivertebrae and spilt posterior elements) is known to have a potential association with split cord malformations [42] (Fig. 3).

### Caudal Regression/Agenesis

Caudal regression syndrome is a heterogeneous constellation of caudal anomalies comprising total or partial agenesis of the spinal column [5, 39], anal imperforation, genital anomalies, bilateral renal dysplasia or aplasia, and pulmonary hypoplasia. The lower limbs usually are dysplastic and show distal leg atrophy and a short intergluteal cleft. Agenesis of the sacrococcygeal spine may be part of syndromic complexes such as OEIS (omphalocele, cloacal exstrophy, imperforate anus, and spinal deformities), VACTERL (vertebral abnormality, anal imperforation, tracheoesophageal fistula, renal abnormalities, limb deformities), and the Currarino triad (partial sacral agenesis, anorectal malformation, and presacral mass: teratoma and/or meningocele) [19] (Fig. 4). Lipomyelomeningocele and terminal myelocystocele are associated in 20 % of cases. There is a definite association with maternal diabetes mellitus (1 % of offspring of diabetic mothers) [19]. It is believed that hyperglycemia occurring early during gestation could influence further development of Hensen's node and the tail bud in genetically predisposed embryos.

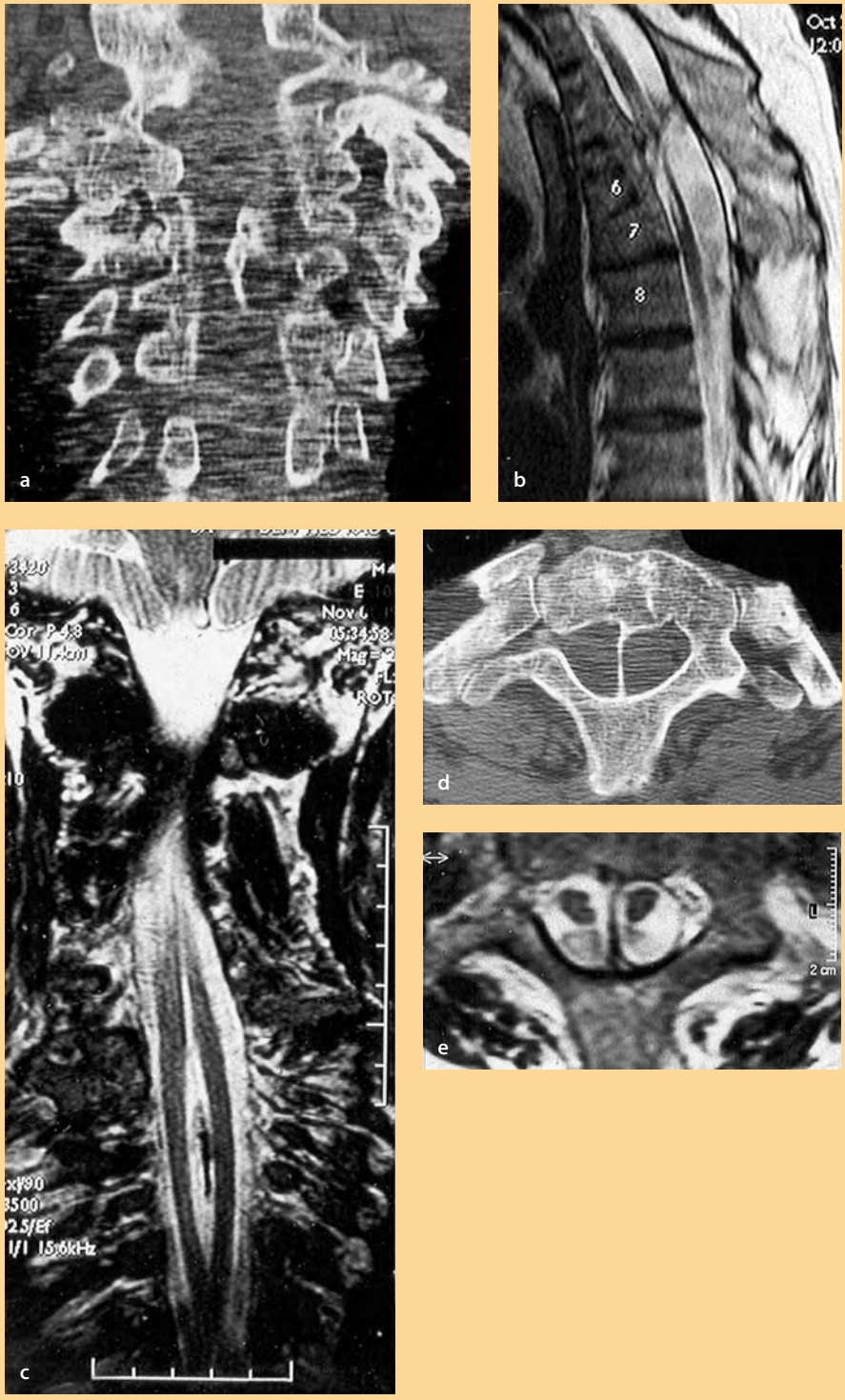


**Figure 3. Split cord malformation**

Thoracal Type I split cord malformation in a 50-year-old man with tethered cord syndrome. **a** Sagittal bony spur is visible. **b** T2-weighted image shows bony spur projecting into spinal canal. Vertebral segmentation pathology of T5–7 is also visible. **c** Coronal T1-weighted image shows the midline bony spur and split cord. **d** Axial CT presented bony spur. **e** Axial MRI shows nicely dural dual sacs and intervening bony spur.

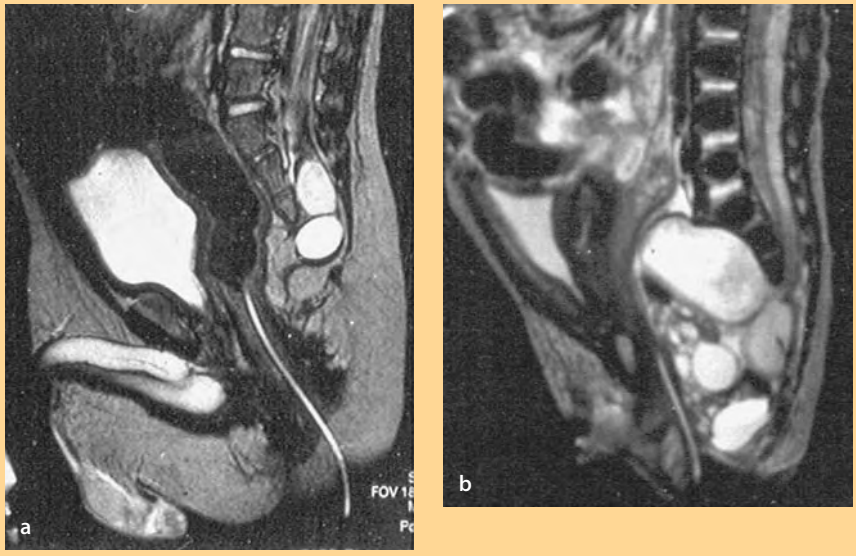


**Figure 4. Caudal regression syndrome**

Two patients (10-month-old and 9-day-old) with Currarino triad. Both have caudal regression syndrome Type II (lesser degree of sacrococcygeal agenesis). In case a the spinal cord is tethered to a sacral lipoma and epidermoid, in case b to a malformative tumor.

There are two types of caudal regression abnormality depending on the position of the conus medullaris [22, 26, 39]:

- **Type I**: If the derangement is severe (spine ending at S2 or above), then not only the caudal cell mass but also part of the true notochord fails to develop.
- **Type II**: With a minor degree of dysgenesis (S3 or lower levels present), only the whole, or a part, of the caudal cell mass fails to develop.

### Neuroectodermal Appendages

Neuroectodermal appendages are tail-like appendages arising in the posterior midline that have sinus tracts extending into the neural canal. It has been proposed that these develop initially as dermal sinus tracts with continued epithelialization outward to form an appendage (Case Study 1).

## Classification of Tethered Spinal Cord

Tethered cord syndrome may even occur with the conus at L1/2

Spinal cord anomalies can also be presented based on the conceptual framework of a tethered cord because of their association with spinal malformations and the implications for treatment. The original description of spinal cord tethering in association with a **thickened filum terminale** was offered by Garceau (1953). The term **tethered spinal cord** was coined by Hoffman et al. (1976) [9]. Classically tethered cord is defined as having the tip of conus below the L2 disc space and pathologically elongated spinal cord.

However, in the medical literature, there are many publications of tethered cord syndrome with the conus in a normal position [37, 40, 46, 48]. Tethered cord can be differentiated into two groups (Table 5):

- primary tethered cord
- secondary tethered cord

**Table 5.** Classification of tethered cord

| Primary tethered cord | Secondary tethered cord |
|---|---|
| • spinal cord malformations with back mass | • postsurgical spinal cord malformations (retethering by scar, dermoid, arachnoid, cysts) |
| • spinal cord malformations without back mass | • postsurgical intradural operations (tumors, infections) |

The term **primary tethered cord** has been used by Sarwar et al. [33] with regard to associated spinal malformations. **Secondary tethered cord** applies to scarring of the spinal cord or within the spinal canal due to previous myelomeningocele/meningocele repair [8, 10] and other intradural spinal operations such as spinal cord tumors [35, 58]. When closed spinal dysraphism becomes symptomatic they present as a tethered cord syndrome.

## Clinical Presentation

### History

**Open spinal dysraphism** is discovered at birth because of the back mass and primary associated conditions (cutaneous markers, neurological deficits and orthopedic deformities). But a significant number of patients with closed spinal dysraphism may reach adulthood with their disease undiagnosed. Some cases are discovered even as late as 72 years of age [17, 57, 58]. Often, adult patients with tethered cord syndrome are misdiagnosed as having a "failed back syndrome" [58]. These patients present for medical assessment because of:

Tethered cord can remain undiagnosed until a late age

- development of new symptoms
- progression of previously established neurological deficits
- orthopedic deformities
- acute neurological deterioration after mechanical stresses

#### Tethered Cord Syndrome

The **prevailing clinical symptoms** in closed spinal dysraphism are those of a **tethered cord syndrome** [12, 30, 53, 58]. This syndrome is a functional disorder which is almost universally associated with spinal dysraphism [5, 19], such as lipomyelomeningocele, split cord malformation, dermal sinus as well as previously operated on myelomeningoceles, which tether the spinal cord within the spinal canal and result in excessive tension of spinal cord. It is associated with a progressive neurological, orthopedic and urologic deterioration that results from spinal cord tethering due to various dysraphic spinal abnormalities [19, 43, 58]. Yamada et al. introduced the term **tethered cord syndrome** for patients suffering from a tethered cord. In the neurosurgical literature, McLone and Pang and Yamada popularized this entity [48, 58, 59, 60]. In 1982, Pang and Wilberger showed that tethered cord syndrome exists not only in children but also in adults [2, 25, 60].

The **late onset symptomatic presentation** is related to cumulative effects of repeated stretching-microtrauma during flexion and extension [48]. Tethered cord syndrome can become symptomatic quite subtly and be slowly progressive, but can also result from sudden stretching of the mechanically fixed spinal cord at any age [9, 19]. Some **precipitating events** have been reported in the literature as follows [12, 30, 36, 48]:

Precipitating events can make tethered cord symptomatic

- heavy lifting
- bending movements

- traumatic injury
- sudden movements
- lithotomy position
- sexual intercourse
- childbirth
- sport activities

There are also various reports in the literature of spinal neuronal damage, following spinal anesthesia, with patients who have previously undiagnosed tethered cord with a low lying conus [49, 62].

Consider the possibility of a low conus before a lumbar puncture

The **cardinal symptom** of tethered cord is:

- pain. The pain is usually located in the lower back [30]. The pain is increased with activity and relieved by rest. Yamada et al. described three postural changes (postural pain triade) that typically worsen pain in tethered cord syndrome patients [15]. They called these signs the **"three Bs"** [15, 58]:
- the inability to sit with legs crossed like **b**uddha
- difficulty with slight **b**ending at the waist
- inability to hold a **b**aby or light material at the waist level while standing

The cardinal symptom of tethered cord is pain

**Additional findings** are:

- low back pain and leg pain
- anorectal and perineal pain
- fatigue
- recurrent bladder infections
- progressive leg weakness
- patchy sensory loss
- sacral sensory loss
- gait disturbance
- bladder and bowel dysfunction (incontinence)
- sexual dysfunction
- progressive deformity (scoliosis, foot and leg deformities)

## Physical Findings

Regardless of the etiology of the primary tethering, children present to specialists with one or more of its typical abnormalities. In newborns and infants, the diagnosis of tethered cord syndrome is often confused with cerebral palsy [36].

### Cutaneous Markers

Most patients with a tethered cord have a mark of discoloration or lesion of some type on their skin in the midline [14, 19, 35, 48]. These skin markers are mostly localized in the lumbosacral area and are present in 50–60 % of patients who present with tethered cord syndrome [2, 7, 19, 32, 35, 48]. Most common findings in decreasing frequency are:

Midline cutaneous abnormality may indicate tethered cord

- myelomeningocele sac over the back
- subcutaneous lipoma
- deviation of the gluteal furrow
- hypertrichosis
- cutaneous hemangioma, port-wine stain
- dermal sinus, dimple
- skin tag-tail (caudal appendages)
- pigmentary nevus

A midline dimple or pinpoint ostium can indicate a dermal sinus

A midline dimple or pinpoint ostium can indicate a dermal sinus. It is often found in association with hairy nevus, capillary hemangioma, or hyperpigmented patches. The cutaneous opening of a dermal sinus tract differs from that of a sacrococcygeal fistula [5, 39]. While dermal sinus tracts are found above the natal cleft and are usually directed superiorly, sacrococcygeal pits are found within the natal cleft with a tract extending either straight down or inferiorly.

### Neurological Presentation

Individual patients often have more than one symptom or sign. However, one of the clinical features is usually predominant over the other [14, 19, 35, 48, 50]. **Most common findings** in decreasing frequency are:

- weakness of the lower limbs
- reflex changes
- muscle atrophy
- muscle spasticity and contractures
- patchy sensory loss
- sphincter (bowel, bladder) dysfunction
- trophic painless ulcers

### Orthopedic Deformities

Examine shoes for signs of wear

Various orthopedic deformities are common in spinal dysraphism patients. Often more than one deformity is seen in a single patient [14, 19, 48]. Approximately 75% of patients with tethered cord present with orthopedic anomalies [48]. **Most common findings** in decreasing frequency are:

- scoliosis
- kyphosis, exaggerated lordosis
- lower limb length discrepancy
- foot deformities (equinovarus, pes cavus, pes planus)
- hip subluxations

Asymmetric foot size may be an indicator of tethered cord

**Asymmetric foot size** may also be an indicator for a tethered cord. It is also important to examine the worn shoes of patients to look for wearing out of the tips and soles of the shoes [36].

## Diagnostic Work-up

### Prenatal Diagnosis

Serum maternal α-fetoprotein examination and ultrasonography can identify a large number of these afflicted fetuses with myelomeningoceles between 16 and 20 weeks gestation [20, 24, 28]. Many parents then make the decision to interrupt the pregnancy, which probably is why there has been a significant decrease in the number of those born with this anomaly in western countries. Dietary supplementation with folic acid via the mother prior to and during pregnancy is protective and has contributed to the decreased incidence of this disease [39].

### Ultrasonography

An ultrasound examination is **recommended for women at-risk** (positive serum α-fetoprotein screening, previously affected child, maternal drug intake associated with spinal malformations in the fetus). Ultrasound can detect spina bifida

from 16–20 weeks. However, spina bifida may be missed, particularly in the L5–S2 region [24, 44].

### Magnetic Resonance Imaging

Since its advent, MRI has become the imaging modality of choice. While ultrasonography is an excellent screening procedure, it requires considerable expertise to interpret, whereas MRI is definitive. Prenatal MRI can also be used to characterize the Chiari II and other associated malformations [24]. Prenatal imaging studies help to predict neurological deficits.

MRI is the modality of choice for prenatal imaging

## Postnatal Diagnostic Tests

### Imaging Studies

For evaluation of the spinal cord malformations and tethered cord syndrome, the most helpful diagnostic images are obtained by MRI, which provides excellent details of anatomy and characterization of soft tissue anomalies [39, 58]. Other imaging studies, including standard radiographs and CT, may also be helpful. Plain radiographs will show vertebral anomalies. A CT scan is particularly useful for the evaluation of bony anomalies and split cord malformations [34, 39].

### Magnetic Resonance Imaging

The best demonstration of the entire craniospinal axis is made by MRI and should be performed after the birth whenever possible. The T1- and T2-weighted MR images in the sagittal and axial planes provide excellent demonstrations of the anatomopathological characterization of the components of the malformation, i.e. relationship between placode and nerve roots and other associated sequences (Chiari II, hydrocephalus, hydromyelia) [32].

Before the MRI era, it had been assumed that after untethering, there would be upward migration of the spinal cord, which in fact does not occur in most cases [19]. Postoperative follow-up MRI almost always shows low-lying conus and should not be confused with a "retethering" [10]. The diagnosis of retethering and decision for untethering requires clinical judgment. Attempts to improve conventional MRI techniques, including the use of prone positioning [10], upright MRI and dynamic phase MRI, have been investigated but await validation through further studies [19].

Investigate the entire neural axis when spinal malformations are suspected

### Urodynamic Studies

Urodynamic studies may show low bladder capacity and overflow incontinence, and may serve as a baseline for postoperative follow-up [15].

## Treatment

It is important to recognize tethering of the spinal cord as early as possible. Once the neurological deficits have occurred, many patients will not have recovery of lost functions.

Although the underlying causes of tethered cord vary, the signs and symptoms of tethering are generally the same. Individuals with spinal malformations need both surgical and medical lifelong management which should be provided by a multidisciplinary team.

Tethered cord should be treated as soon as possible

**Asymptomatic patients with tethered cord** should be instructed to avoid the following activities because of the risk of a potential sudden neurological deterioration [57]:

- deep bending (touching the toes, high leg kicking)
- holding any weight while standing that causes back and leg pain
- sitting position such as the Buddha pose
- sitting in a slouching position
- horse riding
- skiing at high altitude (might produce spinal hypoxia)
- Valsalva-type maneuvers to prevent spinal venous congestion

## In Utero Treatment

Fetal surgery for spinal dysraphism is feasible

After a diagnosis of fetal spinal dysraphism, there are two choices: either termination or **fetal surgery** [24]. The period of legal termination differs between countries. The first cases of in utero open spinal dysraphism repair were done in 1994 but proved unsatisfactory [3]. In 1997, in utero repair by hysterotomy was reported [3, 20]. Up to 2004, more than 200 in utero, open spinal dysraphism closures are estimated to have been done [20]. Urodynamic and lower extremity function seem to be similar in infants treated in utero and postnatally [20]. Compared with historical controls, infants treated in utero have a lower incidence of Chiari II and hydrocephalus requiring shunting [3, 20]. Delivery via cesarean section is preferred [28].

## Postnatal Surgery

Open spinal dysraphisms must be treated surgically as early as possible (Table 6):

**Table 6.** General aims of surgery

| | |
|---|---|
| • untether the spinal cord | • prevent infections |
| • repair of the dural/cutaneous defect | • restore normal anatomy as far as possible |

Closure of the spinal lesions is usually done within 48–72 h of birth [20, 28, 58]. If there are signs of hydrocephalus, a shunt is placed at the same time as the lesion is closed.

There are some standard rules for closure of **open spinal dysraphism**, but in many cases the surgeon must vary the technique on the basis of individual anatomy. The surgical microscope should assist in defining distorted anatomy and associated pathologies in great detail. The interested reader is referred to representative articles in the literature and textbooks [26, 28, 31, 50, 58].

### Open Spinal Dysraphism

After careful and extensive dissection of the sac from the neural placode, neural tissue is repositioned into the dural sac to preserve functional neural tissue. There is no proven technique for closure of myelomeningocele at the time of the original surgery that will prevent retethering. However, there are some techniques that may minimize the amount of retethering that occur: The neural placode can be folded over and anatomically made into a tube by suturing the edges of the open placode together. It does not prevent retethering, but it seems to make the surgery for untethering easier. Sometimes the use of vascularized flaps may be necessary.

### Closed Spinal Dysraphism

In the cases of closed spinal dysraphisms, the associated lesions need careful dissection. In split cord malformation, after opening the dura, complete excision of the bony spur or fibrous septum is performed. A thickened or fatty filum terminale is cut and also released to detether the cord. Sometimes, closure of the dura is a problem. In these cases, it is necessary to use fascia lata or synthetic dura substitutes to repair the dural deficiency. Wound closure is done in multiple layers in order to prevent liquor leak.

### Tethered Cord Syndrome

Surgery for tethered cord must be early

In open spinal dysraphism, short- and long-term survival has increased with improvements in medical and surgical management. Surgical intervention for tethered spinal cord must be as early as possible to prevent progressive neural tissue damage. Once neurological function is lost it may never recover. The value of early prophylactic surgical intervention in tethered cord is evident in the literature [16, 35, 48]. The only effective treatment is **surgical untethering** of the spinal cord from the underlying cause. The goal of the untethering surgery is to stop any further neurological deterioration [35, 48]. One of the current controversies with respect to tethered cord management includes the untethering of the spinal cord in asymptomatic patients. The majority of authors recommend prophylactic surgery [16, 48].

The only effective treatment is surgical untethering

The decision about the surgical technique should be made individually on a case-by-case basis. The special details of the various surgical techniques are beyond the scope of this chapter. Several excellent textbooks exist in the field of spinal malformations–tethered cord surgery. Interested readers are referred to representative articles in the literature and these textbooks and atlases [26, 28, 31, 50, 58].

Untethering is generally a **safe surgical procedure** in experienced hands [16]. Complications include infection, bleeding, and damage to the functional part of the spinal cord. Although the causes of tethered cord vary, the general principles of the surgery are similar.

The operating microscope and microsurgical technique are necessary for better visualization and precise dissection. Different instrumentations are used to perform the dissection including endoscopy, ultrasonic aspirator, and lasers; one method is not necessarily better than the others, and the surgeon usually has her or his own preference based upon their experience [8, 10, 48].

Intraoperative neuromonitoring and the microscope are invaluable intraoperative aids

Various intraoperative monitoring techniques such somatosensory evoked potentials (SSEPs), lower extremity and anal sphincter EMGs, external anal sphincter monitoring and nerve root stimulation studies are helpful to identify functional elements [15, 58]. But it remains valid that the most important factor for a good postoperative result is the experience of the surgeon in handling these complex anomalies [12]. Retethering remains a risk and requires reexploration if signs of tethered cord syndrome are seen.

In secondary tethered cord the untethering procedure usually involves opening and dissecting the scar from the prior closure.

## Recapitulation

**Epidemiology.** Neural tube defects are the most common congenital abnormalities of the central nervous system.

**Classification.** Spinal cord malformations can be classified based on the pathomorphological presentation as presenting with and without a back mass. A secondary discriminator is related to the coverage with skin in the **presence of a back mass**. The vast majority of spinal cord malformations result in a tethering of the spinal cord. We differentiate primary tethered cord as a result of spinal malformations and secondary tethered cord which results from a surgical intervention.

**Pathogenesis.** Spinal cord malformations (=spinal dysraphism) arise from defects occurring in the embryological stages of gastrulation (weeks 2–3), neurulation (weeks 3–6) and caudal regression. There is an **increased risk** of spinal malformations in pregnant women who are taking certain drugs. An increased risk of spinal malformation is associated especially with exposure to valproic acid or carbamazepine. Patients with myelomeningocele and myelocele almost always have associated Chiari II malformation. **Hydromyelia** may occur in as many as 80% of these patients, and may be localized or extend through the whole cord. It may cause rapid development of scoliosis if left untreated. **Classically tethered cord** is defined as having the tip of the **conus below the L2 disc space** and a pathologically elongated spinal cord. However, in the medical literature, there are many publications of tethered cord syndrome with the conus in a normal position.

**Clinical presentation.** Tethered cord–spinal cord malformations are usually diagnosed at birth or early infancy (open spinal dysraphism, closed spinal dysraphisms with back mass) but sometimes are discovered in older children or adults. Tethered spinal cord should be highly suspected and considered in the differential diagnosis of patients who present with **cutaneous midline abnormalities**, low back pain, lower extremity and foot deformities, subtle neurological deficits, and bladder and sexual dysfunctions. Irreversible neuronal damage can occur when there is sudden stretching of the already chronically tethered conus.

**Diagnostic work-up.** The **prenatal examination** encompasses maternal serum $\alpha$-fetoprotein examination and ultrasound. The advent of diagnostic modalities such as **MRI** has increased the number of tethered spinal cord diagnoses and will require awareness and prompt multidisciplinary management of the syndrome before neuronal loss advances. Since multiple tethering lesions and cerebral anomalies coexist in a significant number of cases, it is absolutely necessary to investigate these patients with craniospinal MRI to screen the entire neuroaxis.

**Prenatal treatment.** It is important to counsel women of childbearing age about the need to take dietary supplements containing foliate before becoming pregnant. Up to 70% of spina bifida cases can be prevented by periconceptional folic acid supplementation. Intrauterine surgery is possible but superiority over postpartum surgery needs to be established.

**Postnatal treatment.** Individuals with spinal malformations need both surgical and medical lifelong management which should be provided by a multidisciplinary team. **Open spinal dysraphism** requires **immediate surgery** (within 2–3 days postpartum). Main goal of surgery is to untether the spinal cord, prevent infections, repair the dural/cutaneous defect, and restore normal anatomy as far as possible. Mainly the goal of the untethering is to stabilize the progressive neurological deterioration but some authors recommend a prophylactic untethering procedure for asymptomatic patients. Early untethering, when minimum or mild symptoms are detected, is essential for tethered cord syndrome treatment. Surgical intervention for tethered cord involves identification of the tethering lesion, release of the spinal cord and reconstruction of the normal anatomy as soon as possible. The operating microscope and microsurgical technique are necessary for better visualization and precise dissection. Intraoperative neuromonitoring is useful.

## Key Articles

**Yamada S (1996) Tethered cord syndrome. The American Association of Neurological Surgeons, Park Ridge, Illinois**
This is a first and excellent textbook on tethered cord syndrome. There are 16 chapters on embryology, pathophysiology, diagnosis, imaging, and therapy that cover all aspects of the syndrome. All chapters are superb didactically not only for neurosurgeons but also for orthopedic surgeons, neurologists, pediatricians, and urologists.

**Pang D (1995) Disorders of the pediatric spine. Raven Press, New York**
This book covers perfectly all aspects of childhood spine, beginning with a section on embryology and biomechanics, and bridging the philosophies of orthopedic surgeons and neurosurgeons by including chapters written by these two specialties. A large section is devoted to the many congenital malformations with deeply detailed definitions, nice photos and drawings of operative techniques.

**Tortori-Donati P, Rossi A, Cama A (2000) Spinal dysraphism: a review of neuroradiological features with embryological correlations and proposal for a new classification. Neuroradiology 42(7):471 – 91**
This paper presents the correlation between anatomy, embryology, neuroradiology and clinical findings of spinal dysraphism and formulates a working classification of these malformations.

**Mitchell LE, Adzick NS, Melchionne J, Pasquariello PS, Sutton LN, Whitehead AS (2004) Spina bifida. Lancet 364:1885 – 1895**
This is an excellent review which highlights the key features of spina bifida.

## References


1. Arai H, Sato O, Okuda O, Miyajima M, Hishii M, Nakanishi H, Ishii H (2001) Surgical experience of 120 patients with lumbosacral lipomas. Acta Neurochir (Wien) 143:857 – 864
2. Boop FA, Russell A, Chadduck WM (1992) Diagnosis and management of the tethered cord syndrome. J Arkansas Med Soc 89(7):328 – 331
3. Bruner JP, Tulipan N, Reed G, Davis GH, Bennett K, Luker KS, Dabrowiak ME (2004) Intrauterine repair of spina bifida. Am J Obstetrics Gynecol 190:1305 – 12
4. Bulsara KR, Zomorodi AR, Villavicencio AT, Fuchs H, George TM (2001) Clinical outcome differences for lipomeningoceles, intraspinal lipomas and lipomas of the filum terminale. Neurosurg Rev 24:192 – 194
5. Chopra S, Gulati MS, Paul SB, Hatimota P, Jain R, Sawhney S (2001) MR spectrum in spinal dysraphism. Eur Radiol 11(3):497 – 505
6. Dias MS, Pang D (1995) Human neural embryogenesis. In: Pang D (ed) Disorders of the pediatric spine. Raven Press, New York, pp 1 – 26
7. Guggisberg D, Smail HE, Viney C, Bodemer C, Brunelle F, Zerah M, Pierre-Kahn A, Prost Y (2004) Skin markers of occult spinal dysraphism in children. Arch Dermatol 140:1109 – 1115
8. Haberl H, Tallen G, Michael T, Hoffmann KT, Bennedorf G, Brock M (2004) Surgical aspects and outcome of delayed tethered cord release. Zentralbl Neurochir 65:161 – 167
9. Hoffman HJ (1996) Indications and treatment of the tethered spinal cord. In: Yamada S (ed) Tethered cord syndrome. The American Association of Neurological Surgeons, Park Ridge, Illinois, pp 21 – 28
10. Hudgins RJ, Gilreath CL (2004) Tethered spinal cord following repair of myelomeningocele. Neurosurg Focus 16:E7
11. Iskandar BJ, Oakes WJ (1999) Occult spinal dysraphism. In: Albright AL, Pollack IF, Adelson PD (eds) Principles and practice of pediatric neurosurgery. Thieme, New York, pp 321 – 351
12. Iskandar BJ, Fulmer BB, Hadley MN, Oakes WJ (2001) Congenital tethered spinal cord syndrome in adults. Neurosurg Focus 10:e7
13. Knierim DS (1996) Epidermoid and dermoid tumors associated with tethered spinal cord. In: Yamada S (ed) Tethered cord syndrome. The American Association of Neurological Surgeons, Park Ridge, Illinois, pp 125 – 133
14. Kumar R, Singh SN (2003) Spinal dysraphism: Trends in northern India. Pediatr Neurosurg 38:133 – 145
15. Lapsiwala SB, Iskandar BJ (2004) The tethered spinal cord syndrome in adults with spina bifida occulta. Neurol Res (7):735 – 740

16. van Leeuwen R, Notermans NC, Vandertop P (2001) Surgery in adults with tethered cord syndrome: Outcome study with independent clinical review. J.Neurosurg (Spine 2) 94:205 – 209
17. Manfredi M, Donati E, Magni E, Salih S, Orlandini A, Beltramello A (2001) Spinal dysraphism in an elderly patient. Neurol Sci 22:405 – 407
18. McLone DG, Dias MS (1991) Complications of meningomyelocele closure. Pediatr Neurosurg:17:267 – 73
19. Michelson DJ, Ashwal S (2004) Tethered cord syndrome in childhood: Diagnostic features and relationship to congenital anomalies. Neurol Res 7:745 – 753
20. Mitchell LE, Adzick NS, Melchionne J, Pasquariello PS, Sutton LN, Whitehead AS (2004) Spina bifida. Lancet 364:1885 – 1895
21. Moore KL (1977) The nervous system. In: The developing human: clinically oriented embryology. WB Saunders Co., Philadelphia, pp 327 – 357
22. Naidich TP, Zimmerman RA, McLone DG, et al. (1996) Congenital anomalies of the spine and spinal cord. In: Atlas SW (ed) Magnetic resonance imaging of the brain and spine, 2nd edn. Lippincott-Raven, Philadelphia, pp 1265 – 337
23. O'Rahilly R, Müller F (1987) Developmental stages in human embryos. Carnegie Institution Washington, Washington, DC
24. Oi S (2003) Current status of prenatal management of fetal spina bifida in the world. Childs Nerv Syst 19:596 – 599
25. Pang D, Wilberger JF, Jr (1982) Tethered cord syndrome in adults. J Neurosurg 57:32 – 47
26. Pang D (1995) Disorders of the pediatric spine. Raven Press, New York
27. Park TS (1999) Myelomeningocele. In: Albright AL, Pollack IF, Adelson PD (eds) Principles and practice of pediatric neurosurgery. Thieme, New York, pp 291 – 320
28. Perry VL, Albright AL, Adelson PD (2002) Operative nuances of myelomeningocele closure. Neurosurgery 51:719 – 724
29. Piatt JH (2004) Syringomyelia complicating myelomeningocele: review of the evidence. J Neurosurg (Pediatrics 2) 100:101 – 109
30. Ratliff J, Mahoney PS, Kline DG (1999) Tethered cord syndrome in adults and children. Southern Med J 92:1119 – 1203
31. Rengachary SS, Wilkins RH (eds) (1991 – 2000) Neurosurgical operative atlas, vols 1 – 9. The American Association of Neurological Surgeons. Williams and Wilkins, Baltimore, pp 1991 – 2000
32. Rossi A, Biancheri R, Cama A, Piatelli G, Ravegnani M, Tortori-Donati P (2004) Imaging in spine and spinal cord malformations. Eur J Radiol 50:177 – 200. Review
33. Sarwar M, Virapongse C, Bihimani S (1984) Primary tethered cord syndrome. AJNR 5: 235 – 242
34. Schijman E (2003) Split spinal cord malformations. Childs Nerv Syst 19:96 – 103
35. Schmidt DM, Robinson B, Jones DA (1990) The tethered spinal cord, etiology and clinical manifestations. Orthopaed Rev XIX(10):870 – 876
36. Schneider S (1996) Tethered cord syndrome: The neurological examination. In: Yamada S (ed) Tethered cord syndrome. The American Association of Neurological Surgeons, Park Ridge, Illinois, pp 49 – 54
37. Selcuki M, Coskun K (1998) Management of tight filum terminale syndrome with special emphasis on normal level conus medullaris. Surg Neurol 50:318 – 322
38. Tortori-Donati P, Rossi A, Biancheri R, Cama A (2001) Magnetic resonance imaging of spinal dysraphism. Top Magn Reson Imaging 12(6):375 – 409. Review.
39. Tortori-Donati P, Rossi A, Cama A (2000) Spinal dysraphism: a review of neuroradiological features with embryological correlations and proposal for a new classification. Neuroradiology 42:471 – 91. Review
40. Tubbs RS, Oakes WJ (2004) Can the conus medullaris in normal position be tethered? Neurol Res 26(7):727 – 731
41. Tubbs RS, Wellons III JC, Grabb P, Oakes WJ (2003) Chiari II malformation and occult spinal dysraphism. Pediatric Neurosurg 39:104 – 107
42. Tubbs RS, Wellons III JC, Grabb P, Oakes WJ (2003) Lumbar split cord malformation and Klippel-Feil syndrome. Pediatric Neurosurg 39:305 – 308
43. Verhoef M, Barf HA, Post MWM, van Asbeck FWA, Gooskens RHJM, Prevo AJH (2004) Secondary impairments in young adults with spina bifida. Dev Med Child Neurol 46:420 – 427
44. Verity C, Firth H, Constant CF (2003) Congenital abnormalities of the central nervous system. J Neurol Neurosurg Psychiatry 74(Suppl I):i3–i8
45. Wakhlu A, Ansari NA (2004) The prediction of postoperative hydrocephalus in patients with spina bifida. Childs Nerv Syst 20:104 – 106
46. Warder DE, Oakes WJ (1993) Tethered cord syndrome and the conus in a normal position. Neurosurgery 33(3):374 – 378
47. Warder DE (2001) Tethered cord syndrome and occult spinal dysraphism. Neurosurg Focus 10:E1
48. Warder DE (2001) Tethered cord syndrome and occult spinal dysraphism. Neurosurg Focus 10:1 – 9

49. Wenger M, Hauswirt CB, Brodhage RP (2001) Undiagnosed adult diastematomyelia associated with neurological symptoms following spinal anesthesia. Anaesthesia 56:764 – 776
50. Yamada S, Iacono RP, Douglas CD, Lonser RR, Shook JE (1996) Tethered cord syndrome in adults. In: Yamada S (ed) Tethered cord syndrome. The American Association of Neurological Surgeons, Park Ridge, Illinois, pp 139 – 165
51. Yamada S, Iacono RP, Yamada BS (1996) Pathophysiology of the tethered cord. In: Yamada S (ed) Tethered cord syndrome. The American Association of Neurological Surgeons, Park Ridge, Illinois, pp 29 – 48
52. Yamada S, Knerium DS, Mandybur GM, Schulz RL, Yamada BS (2004) Pathophysiology of tethered cord syndrome and other complex factors. Neurol Res 26(7):722 – 726
53. Yamada S, Won DJ, Kido DK (2001) Adult tethered cord syndrome. Neurosurg Q 11:260 – 275
54. Yamada S, Won DJ, Siddiqi J, Yamada SM (2004) Tethered cord syndrome: overview of diagnosis and treatment. Neurol Res 26:719 – 721
55. Yamada S, Won DJ, Yamada SM (2004) Pathophysiology of tethered cord syndrome: correlation with symptomatology. Neurosurg Focus 16(2):E6
56. Yamada S, Won DJ, Yamada SM, Hadden A, Siddiqi J (2004) Adult tethered cord syndrome: relative to spinal cord length and filum thickness. Neurol Res (7):732 – 734
57. Yamada S, Yamada SM, Mandybur GM, Yamada BS (1996) Conservative versus surgical treatment and tethered cord syndrome prognosis. In: Yamada S (ed) Tethered cord syndrome. The American Association of Neurological Surgeons, Park Ridge, Illinois, pp 183 – 202
58. Yamada S (1996) Tethered cord syndrome. The American Association of Neurological Surgeons, Park Ridge, Illinois
59. Yamada S (1996) Introduction to tethered cord syndrome. In: Yamada S (ed) Tethered Cord Syndrome. The American Association of Neurological Surgeons, Park Ridge, Illinois, pp 1 – 4
60. Yamada S (2004) Tethered cord syndrome in adults and children. Neurol Res 26(7):717 – 718
61. Youmans JR (1982) Neurological surgery, 2nd edn. WB Saunders, Philadelphia, pp 1237 – 1346
62. Zipper SG, Neumann M (2001) Conus cauda syndrome after spinal anesthesia. Anasthesio Intensivmed Nottfallmed Schmerzther 36(6):384 – 7

# 30 Cervical Spine Injuries

Michael Heinzelmann, Karim Eid, Norbert Boos

## Core Messages

- ✔ Cervical spine injuries account for about one-third of all spinal injuries and the most commonly injured vertebrae are C2, C6 and C7
- ✔ A neurological deficit occurs in about 15 % of all spinal injuries
- ✔ Atlas burst fractures result from axial compression in slight extension, dens fractures are due to a combination of horizontal shear and vertical compression, and traumatic spondylolisthesis is caused by an extension-distraction injury
- ✔ The flexed lower cervical spine is susceptible to ligamentous injuries without fractures on axial loading, which can result in bilateral facet subluxation or luxation. Additional rotation leads to unilateral dislocations
- ✔ Whiplash associated disorders, which frequently result from rear-end collisions, tend to become chronic in about half of injured individuals. Late whiplash disorders have strong similarities with chronic pain syndrome
- ✔ The assessment of vital and neurological functions is a priority in cervical injuries
- ✔ Polytraumatized and head injury patients are at very high risk of having sustained a cervical injury
- ✔ Standard radiography is indicated in cervical injuries according to the Canadian C-Spine Rule or NEXUS criteria
- ✔ CT is the imaging modality of choice for the evaluation of cervical fracture/dislocation but MRI can add important information with regard to neural compromise and injury to the disco-ligamentous complex
- ✔ Patients with a cervical sprain/strain or whiplash injury should be treated with reassurance about the absence of serious pathology (after diagnostic assessment), education about the prognosis, early return to normal activities and physical exercises (if needed)
- ✔ Fracture reduction by traction and/or urgent decompression is recommended in patients with progressive or incomplete SCI and persistent spinal cord compression
- ✔ Traction must not be applied before ruling out atlanto-occipital or discoligamentous dislocation
- ✔ Occipital condyle fractures, atlanto-occipital dislocation and atlantoaxial instabilities are relatively rare after trauma but must not be overlooked
- ✔ Unstable burst (Jefferson) fractures of the atlas must be treated by rigid external fixation or surgery (C1/2 or Judet screw fixation)
- ✔ Type I and III dens fractures can be treated non-operatively by rigid external fixation but Type II fractures require a surgical approach because of the high non-union rate
- ✔ Type II dens fractures are treated by anterior screw fixation or posterior atlantoaxial instrumented fusion in cases with delayed union or advanced age
- ✔ Traumatic spondylolisthesis of the axis can be treated non-operatively in Type I fractures, while Type II and III require anterior or posterior instrumented fusion
- ✔ Lower cervical spine fractures can be classified into Type A (compression), Type B (distraction) and Type C (rotation) injuries
- ✔ Type A injuries are usually treated conservatively in the absence of severe anterior column involvement and neurological deficits
- ✔ Type B and Type C injuries should be treated operatively by anterior or posterior instrumented fusion
- ✔ Most lower cervical spine injuries can be treated successfully by an anterior approach
- ✔ Facet dislocation injuries require closed or open reduction and adequate fixation with rigid external or internal fixation

## Case Introduction

This 20-year-old male patient had a motor vehicle accident with a polytrauma. Extraspinal injuries included a closed head injury (Glasgow Coma Scale 6) with shearing injuries and consecutive intracranial pressure monitoring for 2 weeks, a thorax injury with lung contusions, bilateral hematopneumothorax, manubrium sterni fracture, and multilevel spinal injuries with fractures of the vertebrae T6, T8, T10, T12 and L3. The thoracolumbar spinal fractures were treated conservatively. In addition, a traumatic spondylolisthesis C2 (Type Effendi II) was initially treated conservatively (a). After 6 weeks, the instability of the C2 injury became obvious, as shown in the standard lateral radiographs (b) and the CT scan (c). The small bony fragment indicates a rupture of the disc C2/C3. The fractures of the pedicles C2 are shown in the CT scan (d, e). The ruptured disc C2/C3 was removed and replaced with a tricortical iliac crest bone graft. Subsequently, the cervical spine was stabilized with an anterior plate. The lateral views demonstrate the radiographs/CT scan taken during the operation (f), postoperatively (g, h), and after 9 months (i). Note that the fractures of the arc/pedicles healed after 9 months.

## Epidemiology

The most commonly injured vertebrae are C2, C6, and C7

Cervical spine injuries account for one-third of all spinal injuries

Cervical spine injuries account for about one-third of all spinal injuries. Goldberg et al. [89] prospectively studied 34 069 patients with blunt trauma undergoing cervical spine radiographs at 21 institutions to accurately assess the prevalence, spectrum, and distribution of cervical spine injury after blunt trauma. Of these patients, 818 (2.4 %) had a total of 1 496 distinct cervical spine injuries. The second cervical vertebra was the most common (24.0 %) level of injury, one-third of which were odontoid fractures. In the subaxial spine, C6 and C7 were the most frequently affected levels (40 %). The most frequent fracture site was the vertebral body. Nearly two-thirds of all injuries (71 %) were considered clinically significant.

A neurological injury occurs in about 15 % of spine trauma patients

In order to evaluate the true incidence of spinal column and cord injury, Hu et al. [108] used the database of the Manitoba Health Services Insurance Plan (1981 – 1984) to identify all patients who had spinal injuries. The annual incidence rate of all spinal fractures was 64 per 100 000. A total of 2 063 patients were identified, 944 of whom were admitted to hospital. There were two incidence peaks, one occurring in young men and the other in elderly women. Of the hospitalized patients, 182 had cervical injury, 286 had thoracic fracture, and 403 had injury in the lumbosacral spine. Associated injuries occurred in 38 % of hospitalized patients. Neurological injury occurred in 122 patients (13 %).

A low GCS indicates a high risk for a concomitant cervical injury

In a retrospective review of 14 577 blunt trauma victims in a tertiary referral center in Baltimore, 614 (4.2 %) had cervical spine injuries. In a series of 14 755 trauma cases in Los Angeles [64], 292 (2 %) patients had cervical spinal injuries. Of these, 86 % had fractures, 10 % had subluxations and 4 % had an isolated spinal cord injury without fracture or obvious ligamentous damage. Importantly, the incidence of cervical injuries increased in patients with a low Glasgow Coma Scale (GCS) score, indicating that patients with a relevant head injury are at risk of having concomitant cervical injuries. The combination of head injury and cervical spine injury represents a difficult diagnostic problem due to the lack of consciousness in these patients. In a consecutive study of 447 patients with head injuries [106], 24 (5.4 %) patients suffered a cervical spine injury. Of these, 14 (58 %) sustained spinal cord injuries. Furthermore, patients with a GCS of less than 9 have an almost 3 times higher risk of sustaining a cervical injury [64]. Similarly, patients involved in motor vehicle accidents – either as passengers or as pedestrians – are at high risk of sustaining cervical spine injuries. Alker et al. examined 312 victims from traffic accidents and found cervical spine injuries in 24.4 %. Of these, 93 % affected the upper cervical spine [15].

A specific entity of cervical injuries (**sprains and strains**) is related to rear-end or side impact motor vehicle collisions [184], but can also occur during diving or other mishaps [201]. In the United States, **neck strain/sprain** is the most common type of injury to motor vehicle occupants treated in US hospital emergency departments, with an annual incidence of 328 per 100 000 inhabitants [158]. The impact during the motor vehicle collision may result in bony or soft-tissue injuries (**whiplash injury**), which in turn may lead to a variety of clinical symptoms (**whiplash-associated disorders**, WAD) [184].

Injury mechanism and symptoms after rear-end collision must be differentiated

The unfortunate term "**whiplash**" was introduced into the literature by Crowe in 1928 [55]. This expression was intended to be a description of a motion, but it has been accepted by physicians, patients and attorneys as the name of a disease. This misunderstanding has led to its misapplication by many physicians and others over the years [55].

The incidence of WAD is substantially increasing

Reliable epidemiological data on this type of injury is hampered by the fact that definitions are largely variable [181]. Depending on the definition of whip-

lash (e.g., compensated claims) and the country, the incidence may vary largely [143, 175, 181, 184]. In Canada, regional differences in jurisdiction resulted in a range of reported/treated injuries from 70 (Quebec) to approximately 600 (Saskatchewan) per 100 000 inhabitants [107]. The incidence and prognosis of whiplash injury from motor vehicle collisions is related to eligibility for compensation for pain and suffering as shown by Cassidy et al. [44]. Changing the policy from a "tort system" to a "no-fault" system resulted in a decrease of the 6-month cumulative incidence of claims from 417 to about 300 per 100 000 persons [44]. In the Netherlands, the incidence substantially increased from 55 (1970–1974) to 241 (1990–1994) per 100 000 inhabitants [200, 201].

Personal, societal, and environmental factors appear to play a role

Although it seems that females are at slightly greater risk, the evidence that gender is associated with risk of WAD is inconsistent [107]. Younger patients appear to have a slightly higher risk of WAD [107]. Preliminary evidence indicates that headrests/car seats which aim to limit head extension during a rear-end collision have a preventive effect on WAD reporting [107]. The evidence regarding risk factors for WAD is sparse but appears to include personal, societal, and environmental factors [107].

WAD tends to become chronic

The rate of patients reporting persistent pain, restriction of motion or other symptoms at 6 months or more after a whiplash injury (**late whiplash syndrome**) [184], sufficient to hinder return to normal activities such as driving, normal occupational and leisure activities, ranges between 1 % and 71 % [52, 175, 207]. However, it appears from the literature that there is a strong tendency for WAD to become chronic, with about 50 % of patients having symptoms one year after the injury [43]. Greater initial pain, more symptoms, and greater initial disability appear to predict slower recovery. Postinjury psychological factors such as passive coping style, depressed mood, and fear of movement were prognostic for slower or less complete recovery [43].

## Pathomechanisms

### Normal Anatomy

Functionally, the cervical spine is divided into the upper cervical spine [occiput (C0)–C1–C2] and the lower (subaxial) cervical spine (C3–C7). The C0–C1–C2 complex is responsible for 50 % of all cervical rotation while 80 % of all flexion/extension occurs in the lower cervical spine [135] (Table 1).

**Table 1.** Normal cervical spinal motion

| | Flexion/extension | R/L rotation | | In-/reclination | |
|---|---|---|---|---|---|
| C0/C1 | 20° (17 %) | 2×1° | (50 %) | 2×3° | (10 %) |
| C1/C2 | 0° | 2×3° | | 0° | |
| C3/T1 | 10–20° (83 %) | 2×2–14° | (50 %) | 2×2–6° | (90 %) |
| **Total** | 120° | 2×2° | | 2×2° | |

According to Louis [135]

#### Upper Cervical Spine

The atlas-occiput junction primarily allows flexion/extension and limited rotation. The flexion is limited by a skeletal contact between the anterior margin of the foramen magnum and the tip of the dens [204]. Flexion/extension is also limited by the tectorial membrane, which is the cephalad continuation of the posterior longitudinal ligament [204]. Axial rotation at the craniocervical junction is restricted by osseous as well as ligamentous structures (Fig. 1). The occipital con-

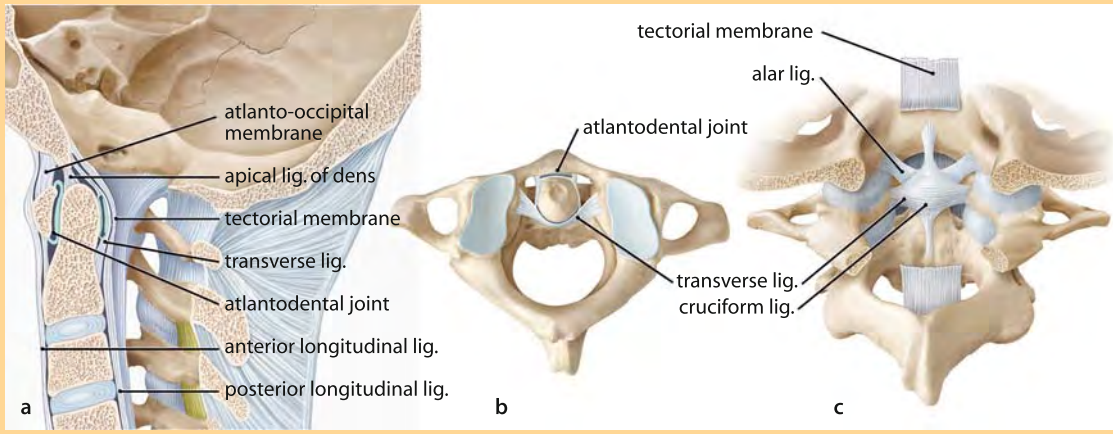


**Figure 1. Anatomy of the upper cervical spine**

a Lateral midsagittal view; b superior view; c coronal view.

dyles articulate with a concave shaped joint surface of the atlas. The **atlantoaxial joint** is composed of lateral mass articulations with loosely associated joint capsules and an atlantodental articulation [135]. The paired bilateral **alar ligaments** bilaterally connect the dens with the occiput condyle and the atlantal mass. The alar ligaments restrain rotation of the upper cervical spine, whereas the **transverse ligaments** restrict flexion as well as anterior displacement of the atlas [69]. The transverse ligament also protects the atlantoaxial joints from rotatory dislocation. Lateral bending is controlled by both components of the alar ligaments [204]. Ligamentous laxity and a horizontal articular plane at the occiput–C1 joint, along with the relatively large weight of the head, may explain why injuries at this junction are more common in children than adults [205].

The alar ligaments restrain upper cervical spine rotation

The transverse ligaments restrict flexion and displacement of the atlas

### Lower (Subaxial) Cervical Spine

The vertebrae of the lower cervical spine have a superior cortical surface which is concave in the coronal plane and convex in the sagittal plane (Fig. 2). This configuration allows flexion, extension, and lateral tilt by gliding motion of the facets [135]. The lateral aspect of the vertebral body has a superior projection (**uncinate process**) which develops during growth and is established at the end of adolescence. As the discs become degenerative, these projections articulate with the body of the next highest vertebra and can lead to an uncovertebral osteoarthrosis [135]. The range of flexion/extension is in part dictated by the geometry and stiffness of the intervertebral disc, i.e., the greater the disc height and the smaller the sagittal diameter, the greater is the motion. Conversely, the greater the stiffness of the disc, the smaller the spinal motion [204]. The C5/6 level exhibits the largest range of motion, which in part explains its susceptibility to trauma and degeneration [136]. Besides the intervertebral disc and facet joints, the muscles and the ligaments, particularly the yellow ligament, dictate the spinal kinematics [204]. The **facet joint capsules** are stretched in flexion and therefore limit rotation in this position.

The C5/6 level exhibits the largest ROM

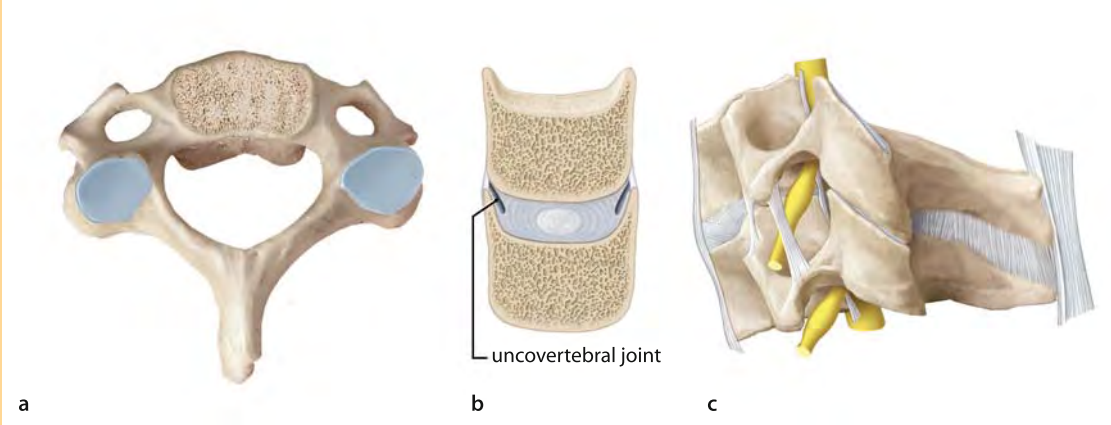


**Figure 2. Anatomy of the lower (subaxial) cervical spine**

a Axial view; b coronal view; c lateral view.

## Biomechanics of Cervical Spine Trauma

The conditions under which neck injury occurs include several **key variables** such as [205]:

- impact magnitude
- impact direction
- point of application
- rate of application

The rate of application of the impact load is a critical variable. The relative position of the head, neck and thorax is a major factor in both the threshold of failure and the pattern of failure. Pattern of failure indicates which structural components of the spine are injured. The position of the spine at the time of impact is important in explaining the injury pattern [205].

The position of the spine at impact determines the fracture pattern

Cadaveric studies have substantially increased our understanding of the fracture mechanisms that lead to specific spinal fractures [205]. Fractures of the atlas ring (**Jefferson fractures**) can be created in an experimental setup by axial loading of the straight spine in slight extension. In an experimental study, Altoff [18] has shown that **dens fractures** result from a combination of horizontal shear and vertical compression [205]. An **os odontoideum** (Fig. 3a, b) is considered to be a result of an early childhood trauma to the dens that leads to a non-union and subsequent formation of a loose ossicle. This entity usually causes an atlantoaxial instability [76, 141, 176]. In a biomechanical study, Fielding et al. [73] have shown that **atlantoaxial instabilities** can result from tears of the transverse ligament without a fracture of the dens. **Traumatic spondylolisthesis** of the axial pedicle was first described by Schneider [172] in the context of judicial hanging with a submental knot (hangman's fracture) that results in an extension-distraction injury. Similar injuries are observed in motor vehicle and diving accidents.

Os odontoideum commonly results from childhood trauma of the dens

In the lower cervical spine, Bauze and Ardran [27] were able to reproduce pure **ligamentous injuries** by vertical loading of the lower cervical spine in the forward flexed position. This mechanism produced bilateral dislocation of the facets without fracture. A unilateral dislocation was produced if lateral tilt or axial rotation occurred as well. The maximum vertical load was only 145 kg, and coincided with the rupture of the posterior ligament and capsule and the stripping of the anterior longitudinal ligament, but this occurred before dislocation. The authors

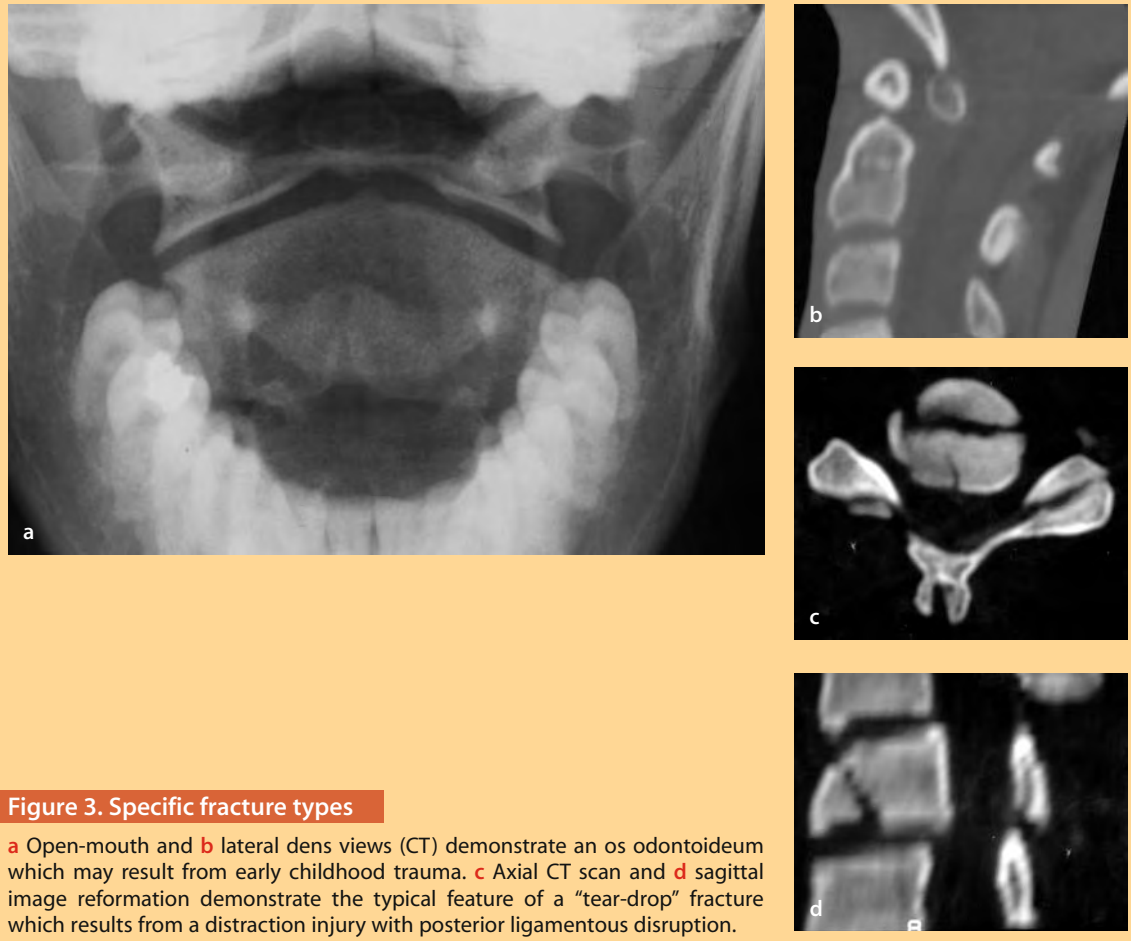


**Figure 3. Specific fracture types**

a Open-mouth and b lateral dens views (CT) demonstrate an os odontoideum which may result from early childhood trauma. c Axial CT scan and d sagittal image reformation demonstrate the typical feature of a "tear-drop" fracture which results from a distraction injury with posterior ligamentous disruption.

concluded that the low vertical load indicates a peculiar vulnerability of the cervical spine in this flexed position. This correlates well with the minor trauma often seen in association with forward dislocation [27]. Axial loading less than 1 cm anterior to the neural position produced anterior **compression fractures** of the vertebral body, while axial loads applied further anteriorly resulted in a rearward buckling with subsequent disc and endplate failure. **Burst fractures** can be produced by direct axial compression of a slightly flexed cervical spine [205]. In an experimental setup, "tear-drop" fractures could be created by axial compression of the neutral and minimally flexed cervical spine [137, 205]. The "**tear-drop fracture**" (Fig. 3a, b) was first described by Schneider and Kahn in 1956 [171]. This injury type is a fracture by the mechanism of flexion/compression with sagittal sprain of the intervertebral cervical disc and disruption of the posterior ligaments. CT investigations demonstrated the coexistence of two lines of fractures: a frontal fracture (by the mechanism of flexion), and a sagittal fracture (by compression). Displacement of the posterior vertebral body fragment frequently results in a spinal cord injury [82]. Cervical **disc ruptures** could be produced in many specimens subjected to axial impact in various degrees of flexion/extension but appear to be most common in axial rotation and lateral flexion at the time of impact [205].

Tear-drop fracture results from a flexion/compression injury with disruption of the posterior ligaments

### Instability of the Cervical Spine

Understanding cervical spine trauma is critically related to the concept of spinal stability and instability, respectively. One of the problems in the literature, however, has been the absence of a clear definition based on reliable radiological criteria. Therefore, White and Panjabi [203] defined **clinical instability** of the spine clinically as (Table 2):

**Table 2.** Definition of clinical instability

- The loss of the ability of the spine under physiological loads to maintain its pattern of displacement so that there is no initial or additional neurological deficit, no major deformity and no incapacitating pain.

The definition of instability remains controversial

However, various attempts were made to develop **radiological criteria** (see below), to guide the choice of treatment [206].

## Spinal Cord Injury

It is now well accepted that acute spinal cord injury (SCI) involves both [72, 109]:

- primary injury mechanisms
- secondary injury mechanisms

Both primary and secondary mechanisms contribute to SCI

The **primary injury** of the spinal cord results in local deformation and energy transformation at the time of injury and is irreversible. It can therefore not be repaired by surgical decompression. In the vast majority of cases the injury is caused by bony fragments that acutely compress the spinal cord. Further mechanisms include acute spinal cord distraction, acceleration-deceleration with shearing, and laceration from penetrating injuries [72]. The injury directly damages cell bodies and/or processes of neurons. The cells that are damaged might die and there is no evidence that they are replaced [37] and can therefore not be repaired by surgical decompression. Immediately after the primary injury, **secondary injury mechanisms** may initiate, leading to delayed or secondary cell death that evolves over a period of days to weeks [109]. A variety of **complex chemical pathways** are likely involved including [109]:

- hypoxia and ischemia
- intracellular and extracellular ionic shifts
- lipid peroxidation
- free radical production
- excitotoxicity
- eicosanoid production
- neutral protease activation
- prostaglandin production
- programmed cell death or apoptosis

Secondary SCI resulting from hypotension and poor tissue oxygenization must be avoided

These mechanisms result in a secondary death of neuronal and glial support cells days or weeks after the injury [109]. These secondary events are potentially preventable and reversible [72]. In the case of a lesion of the cord cranial to T1, a complete loss of sympathetic activity will develop that results in loss of compensatory vasoconstriction (leading to hypotension) and loss of cardial sympathetic activation (leading to bradycardia). Secondary deteriorations of spinal cord function that result from hypotension and inadequate tissue oxygenization have to be avoided.

Injuries to the spinal cord often result in **spinal shock.** This is a term that is commonly used but poorly understood [144]. In analogy to the electrical circuit, the state of spinal shock can be considered as a result of a blown fuse. The phenomenon of spinal shock is usually described as a loss of sensation and flaccid paralysis accompanied by an absence of all reflexes below the spinal cord injury. It is thought to be due to a loss of background excitatory input from supraspinal axons [65]. Spinal shock is considered the **first phase of the response** to a spinal cord injury, hyperreflexia and spasticity representing the following phases. When spinal shock resolves, usually within days up to 6 weeks, reflexes will return and residual motor functions can be found. The clinical significance of spinal shock lies in the associated loss of motor function (in nerves that are not necessarily damaged) and a flaccid paralysis caudal to the lesion.

Spinal shock is characterized by an immediate post-injury loss of sensation, flaccid paralysis and loss of all reflexes

**Central spinal cord injuries** are among the most common, well-recognized spinal cord injury patterns identified in neurologically injured patients after acute trauma. Originally described by Schneider et al. in 1954 [170], this pattern of neurologically **incomplete spinal cord injury** is characterized by disproportionately more motor impairment of the upper than of the lower extremities, bladder dysfunction and varying degrees of sensory loss below the level of the lesion. It has been associated with hyperextension injuries of the cervical spine, even without apparent damage to the bony spine (mainly by osseous spurs), but has also been described in association with vertebral body fractures and fracture-dislocation injuries. The natural history of acute central cervical spinal cord injuries indicates gradual recovery of neurological function for most patients, although it is usually incomplete and related to the severity of injury and the age of the patient [142, 170, 174].

Central cord syndrome is characterized by disproportionately more motor impairment of the upper than lower extremities

## Pathomechanism of Whiplash-Associated Disorders

It is likely that WAD results from cervical sprain or strain but the exact pathomechanisms remain largely unknown [107]. Structural abnormalities of cervical joints, discs, ligaments and/or muscles are very rarely found. Indeed, there is evidence that the likelihood of the development of WAD is inversely related to the severity of the injury [88, 138].

WAD is inversely related to the severity of the injury

Whiplash actually describes the injury as an **acceleration/deceleration mechanism of energy transfer** to the neck [184]. Kinematic analysis demonstrated that the whiplash mechanism consists of translation/extension (**high energy**) with consecutive flexion (**low energy**) of the cervical spine. Hyperextension of the cervical spine has not been observed during vehicle crashes if headrests are installed [45]. The current evidence does not allow any conclusions to be drawn about a specific injury mechanism; particularly the minimum threshold of impact forces causing WAD in real-life accidents remains unknown [107]. Interestingly, no evidence suggests that awareness of the collision, head position at the time of impact, or cervical spondylosis are of relevance for WAD [107].

The large variety of clinical symptoms which have been associated with whiplash injuries, including **cognitive dysfunction** following the injury, lead to the suspicion of a mild traumatic brain injury [160, 169, 191]. Based on a recent comprehensive review of the literature, there is no evidence that poor cognitive functioning in patients seeking treatment for chronic WAD is the result of demonstrable brain damage. Instead, these deficits may be linked to a chronic health condition including chronic pain [107]. In this context it has been shown that spinal cord hyperexcitability in patients with chronic pain after whiplash injury can cause exaggerated pain following low intensity nociceptive or innocuous peripheral stimulation. **Spinal hypersensitivity** may explain, at least in part, pain in the absence of detectable tissue damage [26, 56, 103].

WAD is not associated with mild brain damage

WAD has similarities with chronic pain syndromes

## Clinical Presentation

### History

The history of patients with a cervical injury is usually straightforward. The **cardinal symptoms** of an acute cervical injury are:

- pain
- loss of function (inability to move the head)
- numbness and weakness
- bowel and bladder dysfunction

In patients with evidence for **neurological deficits**, the history should include:

- time of onset (immediate, secondary)
- course (unchanged, progressive, or improving)

The time course of the neurological deficit matters

Particularly, progressive paresis must not be missed.

The history should include a detailed **assessment of the injury**, i.e.:

History should include the trauma type and injury mechanism

- type of trauma (high vs. low-energy)
- mechanism of injury (compression, flexion/distraction, hyperextension, rotation, shear injury)

In **polytraumatized** or **unconscious patients** history taking is not possible for obvious reasons and the patient must be subjected to thorough imaging studies. Polytraumatized patients must be considered to have sustained a cervical injury until proven otherwise.

Patients who have suffered a **rear-end collision** present as a particular diagnostic challenge. In these patients pain may even persist for a long time after the accident (**late whiplash syndrome**) [184] and imaging studies are usually negative. It is therefore mandatory to assess the history with great detail also with regard to the medicolegal implications of these injuries. Patients frequently complain of [104, 140, 149, 159, 161]:

- reduced/painful neck movements
- headache
- paresthesias
- temporomandibular pain
- dizziness/unsteadiness
- nausea/vomiting
- difficulty swallowing
- tinnitus
- sleep disturbances
- cognitive dysfunction (memory and concentration problems)
- vision problems
- lower back pain

The history should also comprehensively assess **details of collision and injury** such as [184]:

- type of collision (rear-end, frontal or side impact)
- use of headrest/seat belt
- position in the car
- injury pattern for all passengers
- head contusion
- severity of impact to the vehicle

The latter aspects may be of more relevance in the medicolegal than a clinical context.

## Physical Findings

The initial focus of the physical examination of a patient with a putative cervical spine injury is on:

The initial focus is on vital functions and neurological deficits

- vital functions (perfusion, respiration)
- neurological deficits

Timely and effective resuscitation is critical to the management of polytraumatized and spinal cord injury patients. In cervical spine injuries above C5, respiration may be compromised because of damage to the diaphragm innervation (C4) or injuries to the brain stem. In both polytrauma and spinal cord injury, hypotension is common although the underlying pathophysiology is different. The reason for the hypotension can be hypovolemic and/or **neurogenic shock** (due to the loss of neurovegetative function) that have to be considered and treated accordingly. The emergency room management of the multiply injured patient with spine injuries has recently been reviewed [209].

The **inspection and palpation** of the spine should include the search for:

- skin bruises, lacerations, ecchymoses
- open wounds
- swellings
- hematoma
- painful structures (spinous, transverse, and mastoid processes; facet joints)
- spinal (mal)alignment (torticollis)
- gaps/steps

Rotatory dislocations present typically with **torticollis** with the head in the "cock robin position," so called because the chin is turned towards one side and the neck is laterally flexed to the opposite side.

A full **functional testing** of the cervical spine should only be done after a fracture dislocation has been excluded by radiography or in patients who present with secondary problems. The patient is best examined sitting on an examination table with their lower limbs and feet freely moving (see Chapter 8). The functional testing should be done very carefully. The assessment of the mobility of the cervical spine consists of:

Consider a latent unstable spine before functional testing

- flexion/extension (chin-sternum distance: documentation, e.g., 2/18 cm)
- left/ride rotation (normal: 60°–0 – 60°) in neutral position
- left/ride rotation (normal: 30°–0 – 30°) in flexed position
- left/ride rotation (normal: 40°–0 – 40°) in extended position
- left/side bending (normal: 40°–0 – 40°)

In case of limitation in active movements, the examination should be repeated with **passive motion** to differentiate between a soft (muscle, pain) and a hard (bony) stop. The examiner should not only record the range of motion but also pain provocation. Examining the cervical spine **against resistance** can be used to stress the intervertebral discs (flexion, side bending) or facet joints (rotation, extension), respectively. If a cervical radiculopathy is suspected, a **Spurling** or **shoulder depression test** can be done (see Chapter 8).

A thorough **neurological examination** is indispensable (see Chapter 11). In case of a neurological deficit, the differentiation is mandatory between:

- nerve root(s) injury
- spinal cord injury (complete, incomplete)

The differentiation of a complete and incomplete paraplegia is important for the prognosis. Approximately 60 % of patients with an incomplete lesion have the

Consider spinal shock in patients with neurological deficits

potential to regain a functionally relevant improvement [57]. It is mandatory to exclude a **spinal shock** which can disguise remaining neural function and has an impact on the treatment decision and timing. However, complete spinal shock usually ends within 24 h and the first reflex to return is the bulbocavernosus reflex in over 90 % of cases. This reflex is performed by squeezing the glans penis, a tap on the mons pubis, or a tug on the urethral catheter, which cause a reflex contraction of the anal sphincter (see Chapter 11). If there is no voluntary sensory (**sacral sparing**) or motor sparing and the bulbocavernosus reflex is present, spinal shock is resolved, and a complete cord lesion is confirmed.

Neurological symptoms in patients with atlanto-occipital dislocation (AOD) can range from asymptomatic (in about 20 %) to a partial or complete "**locked-in syndrome**" [147]. This syndrome is caused by a separation of the corticobulbary and corticospinal tracts at the abducens nuclei level in the pontine. Clinically, the "lock-in syndrome" is characterized by tetraplegia, muteness and akinesia. Only movements of the eyelids and the eye in the vertical direction are preserved.

Precise documentation of the initial neurological status is mandatory

Neurological function must be precisely documented (see Chapter 11). The two most commonly used systems for quantifying and grading the spinal cord injury are the Frankel system [81] and the more comprehensive system developed by the American Spinal Injury Association (**ASIA**) [139].

### Classification of Whiplash-Associated Disorders

For patients who have sustained a cervical sprain or strain due to a motor vehicle collision, the **Quebec Task Force** has recommended a clinical classification system which grades symptoms as follows [43, 184] (Table 3):

**Table 3.** Grading of whiplash-associated disorders

| | |
|---|---|
| **Grade 0** | • WAD refers to no neck complaints and no physical signs |
| **Grade I** | • WAD refers to injuries involving complaints of neck pain, stiffness or tenderness, but no physical signs |
| **Grade II** | • WAD refers to neck complaints accompanied by decreased range of motion and point tenderness (musculoskeletal signs) |
| **Grade III** | • WAD refers to neck complaints accompanied by neurological signs such as decreased or absent deep tendon reflexes, weakness and/or sensory deficits |
| **Grade IV** | • WAD refers to injuries in which neck complaints are accompanied by fracture or dislocation |

Other symptoms such as deafness, dizziness, tinnitus, headache, memory loss, dysphagia, and temporomandibular joint pain can be present in all grades.

## Diagnostic Work-up

Immobilization of the cervical spine must be maintained until an injury is excluded

**Immobilization** of the cervical spine must be maintained until the cervical spine is "cleared," i.e., a spinal cord injury or spinal column injury has been ruled out by clinical or radiographic assessment [9, 10, 164].

### Imaging Studies

A cervical spine injury is found in 2–6 % of all symptomatic patients

The reported incidence of cervical spine injuries in the symptomatic patient ranges from 2 % to 6 % in Class I evidence studies [10]. **Symptomatic patients** require radiographic studies to rule out the presence of a traumatic cervical spine injury before the cervical spine is cleared.

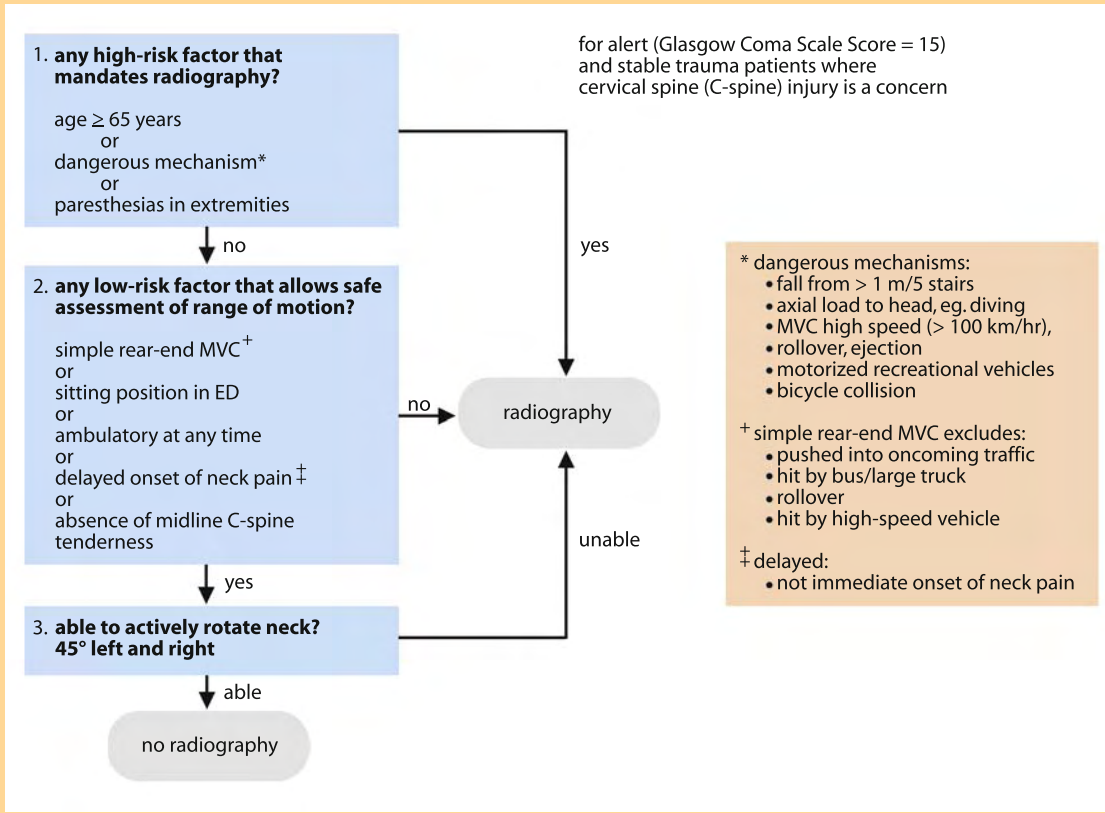


**Figure 4. Canadian C-Spine Rule**

*MVC* motor vehicle collision, *ED* emergency department. (According to Stiell et al. [186], reproduced with permission from AMA).

In 2001, a highly sensitive decision rule (**"Canadian C-Spine Rule"**) was derived, for use in cervical spine radiography in alert and stable trauma patients [186]. This rule comprises three main questions (Fig. 4) and has had a 100 % sensitivity in identifying 151 clinically important cervical spine injuries.

The **NEXUS** (National Emergency X-radiography Utilization Study) [105] developed a decision instrument which allows the identification of patients who have a low probability of a cervical injury. The **five criteria** which must be met are:

- no midline cervical tenderness
- no focal neurological deficit
- normal alertness
- no intoxication
- no painful, distracting injury

In this study, only 2 out of 34 069 evaluated patients classified as unlikely to have an injury met the preset criteria of having a potential significant injury (only one needed surgical treatment) [105]. However, this study was criticized because two criteria, "presence of intoxication" and "distracting, painful injuries," are poorly reproducible [186].

### Standard Radiographs

Radiographs remain the imaging modality of first choice

Radiography has been the standard initial "screening" examination used to evaluate alert and stable patients with suspected cervical spine trauma. At least **three views** are recommended for alert and stable trauma patients [105]:

- anteroposterior view
- cross-table lateral view
- open-mouth dens view

The lateral view should extend from the occiput to T1

The series of conventional radiographs has shown to be accurate in detecting cervical spine injuries in 84 % of cases [187]. The lateral view should extend from the occiput to T1. The lower cervical spine is often obscured by the shadow of the shoulders elevated by muscle spasm or in patients with a "short neck." It may be necessary to gently pull down the arms to visualize the entire T1 vertebra.

In trauma patients for whom the standard three view series fails to demonstrate the cervicothoracic junction, **swimmer's views** (one arm abducted 180°, the other arm extended posteriorly) and **supine oblique views** were compared. The authors concluded that both views show the alignment of the vertebral bodies with equal frequency. However, supine oblique films are safer, expose patients to less radiation, and are more often successful in demonstrating the posterior elements (e.g., riding facet) [110].

Oakley introduced a simple system (**radiological ABC**) for analyzing plain films [164]:

- **A1:** appropriateness: correct indication and right patient
- **A2:** adequacy: extent (occiput to T1, penetration, rotation/projection)
- **A3:** alignment: anterior aspect of vertebral bodies, posterior aspect of vertebral bodies, posterior pillar line, spinolaminar line; craniocervical and other lines and relationships
- **B:** bones
- **C:** connective tissues: pre-vertebral soft tissue, pre-dental space, intervertebral disc spaces, interspinous gaps

Davis et al. [61] described 32 117 acute trauma patients. Cervical spine injuries were missed in 34 symptomatic patients: 23 patients either did not have radiographs or had inadequate radiographs that did not include the region of injury, 8 patients had adequate X-ray studies that were misread by the treating physician, 1 patient had a missed injury that was undetectable on technically adequate films, even after retrospective review, and in the remaining 2 patients, the error was not described. These results confirm that it is not uncommon to miss cervical spine injuries even with adequate plain radiographic assessment of the occiput through T1.

The **most common causes** of missed cervical spine injury are:

- not obtaining radiographs
- making judgments on technically suboptimal films

Do not miss injuries at the cervicocranial and cervicothoracic junctions

The latter cause most commonly occurs at the cervical-occipital and cervicalthoracic junction levels [61, 87, 163].

#### *Functional Views*

Active flexion/extension is a safe and helpful test in conscious, cooperative patients to screen for ligamentous instability [164]. Cervical instability occurred in 8 % of alert, trauma patients in a Missouri Level I Trauma Center study, nearly half of whom had a normal three film series [130]. The addition of flexion/exten-

sion views to a three film series increases sensitivity (99 %) and specificity (93 %) with a high positive (89 %) and negative (99 %) predictive value, with false negatives largely due to muscle spasm [130]. However, flexion/extension radiography is often unable to exclude instability until the spasm has resolved.

**Passive flexion/extension views** or fluoroscopy in unconscious or sedated patients are technically inadequate in up to a third of cases and may even cause devastating neurological deficits. Their value therefore remains controversial [164]. Fortunately, the incidence of isolated ligamentous injury is low. In a retrospective review of 14 577 blunt trauma victims in a tertiary referral center in Baltimore [48], 614 (4.2 %) of patients had cervical spine injuries, of whom only 87 (0.6 %) had isolated ligamentous injuries. There were 2 605 patients in the series with a GCS of less than 15 and only 14 (0.5 %) had isolated ligamentous injuries. Interestingly, 13 were identified on the initial lateral radiograph and the other was diagnosed on CT. In these cases of isolated ligamentous injury, flexion/extension views were not needed to reveal instability. In a series of 14 755 trauma cases in Los Angeles, 292 patients had cervical spinal injuries [64]. Of these, 250 (85.6 %) had fractures, 10 % had subluxations (presumably with ligamentous disruption) and 3.8 % (11 patients) had isolated cord injury without fracture or obvious ligamentous damage.

Passive flexion/extension views in unconscious or sedated patients must not be done

### *Criteria for Trauma and Instability*

Clark et al. [50] suggested **12 helpful signs** in diagnosing cervical spine trauma (Table 4):

**Table 4. Radiographic signs of cervical spine trauma**

**Soft tissues**
- retropharyngeal space > 7 mm in adults or children
- retrotracheal space > 14 mm in adults or > 22 mm in children
- displaced prevertebral fat stripe
- tracheal and laryngeal deviation

**Vertebral alignment**
- loss of lordosis
- acute kyphotic angulation
- torticollis
- widened intraspinous space
- axial rotation of vertebra

**Abnormal joints**
- atlantodental interval > 4 mm in adults or > 5 mm in children
- narrowed or widened disc space
- wide apophyseal joints

According to Clark et al. [50]

For the **upper cervical spine**, White and Panjabi [206] suggested criteria indicative of instability based on conventional radiography (Table 5, Fig. 5a, b).

**Table 5.** Criteria for C0-C1-C2 instability

| | |
|---|---|
| > 8° | • axial rotation C0 – C1 to one side |
| > 1 mm | • translation of basion to dens top (normal 4 – 5 mm) on flexion/extension (Fig. 5a) |
| > 7 mm | • bilateral overhang C1 – C2 (see Fig. 5b) |
| > 45° | • axial rotation (C1 – C2) to one side |
| > 4 mm | • C1 – C2 translation measurement (see Fig. 5a) |
| < 13 mm | • posterior body C2 – posterior ring C1 (see Fig. 5a) |
| | • avulsion fracture of transverse ligament |

According to White and Panjabi [206], modified

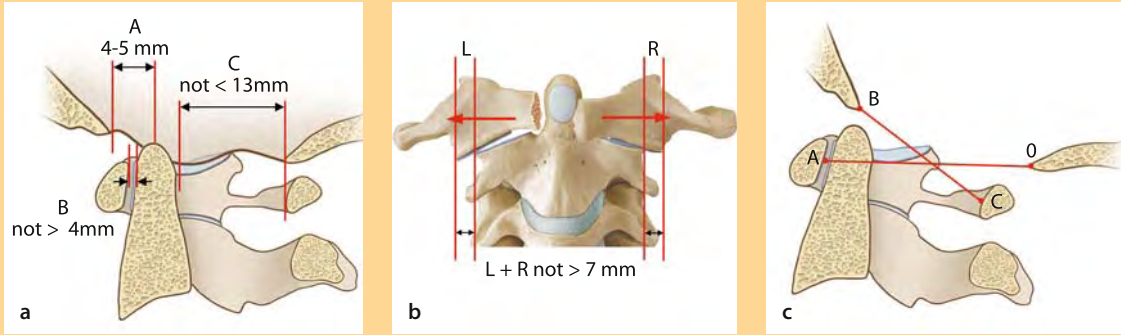


**Figure 5. Instability of the upper cervical spine**

According to White and Panjabi [206]. a Assessment of C0–1-2 stabilities on lateral radiographs. An increase of more than 1 mm in the distance between the basion (clivus) and the top of the dens on flexion/extension view (normal 4–5 mm) is indicative of an atlanto-occipital instability (only if transverse ligament is intact). b Assessment of the stability of the atlas on an open-mouth (ap) view of the dens. c Assessment of the C0–1 stability. A ratio of BC to AO of greater than 1 is indicative of an atlanto-occipital dislocation. This is only valid in the absence of atlas fracture [206].

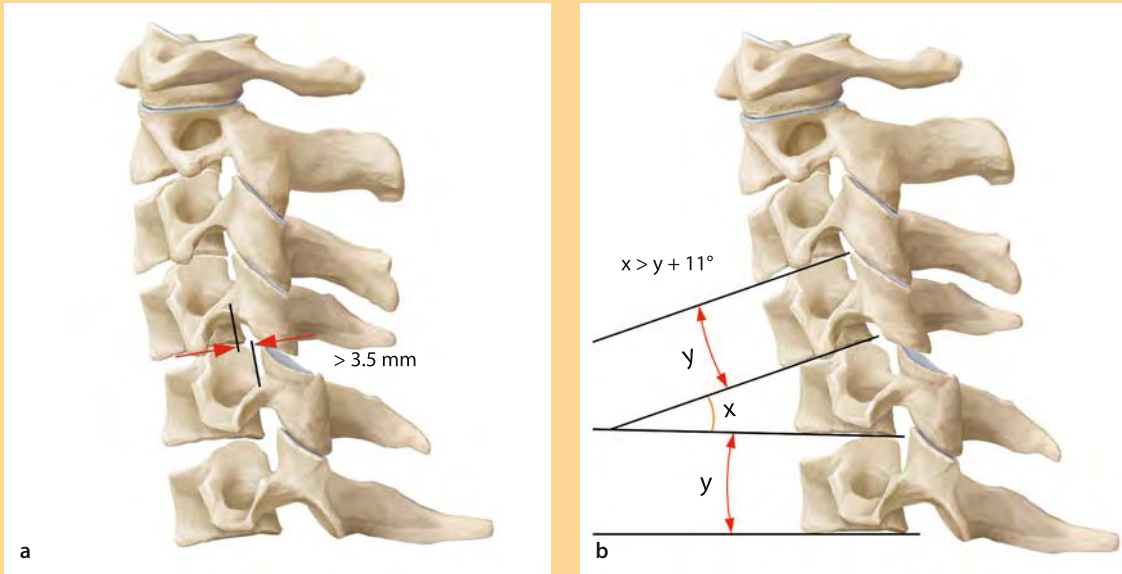


**Figure 6. Instability of the lower cervical spine**

a Sagittal plane displacement or translation greater than 3.5 mm on either static or functional views should be considered potentially unstable according to White and Panjabi [206]. b Angulation between two vertebrae which is greater than 11° than that at either adjacent interspaces is interpreted as evidence of instability by White and Panjabi [206].

Kricun [120] suggested a criterion (Fig. 5c) to detect atlanto-occipital dislocation.

For the **lower cervical spine**, White and Panjabi [206] have suggested criteria indicative of instability based on conventional radiographs (Fig. 6a, b).

### Computed Tomography

CT is the first choice for unconscious or polytraumatized patients

While standard radiographs remain the imaging study of first choice in alert and stable patients after cervical spine injuries, most large trauma centers now perform multislice CT scans for the assessment of polytraumatized or unconscious

patients [164]. The reasons why CT has surpassed radiography include the ease of performance, speed of study, and, most importantly, the greater ability of CT to detect fractures other than radiography [60]. The craniocervical scans should be of a maximum 2 mm thickness, because dens fractures can even be invisible on 1-mm slices with reconstructions [164].

Computed tomography scans are sensitive for detecting characteristic fracture patterns not seen on plain films. One such pattern is the midsagittal fracture through the posterior vertebral wall and lamina. These injuries are very frequently associated with neurological deficits. CT is the modality of choice for diagnosing rotatory instability at the atlantoaxial joints [67, 68]. Failure of C1 to reposition on a left-and-right rotation CT scan indicates a fixed deformity. CT also shows if the dens separates from the anterior arch of C1 with increased rotation. Griffen et al. [92] evaluated the role of standard radiographs and CT of the cervical spine in the exclusion of cervical spine injury for adult blunt trauma patients. For 1 199 of patients at risk for cervical spine injury, both X-rays and CT were performed to evaluate and compare cervical spine injuries. In 116 patients, a cervical spine injury (fracture or subluxation) was detected. The injury was identified on both plain films and CT scans in 75 patients but on CT only in 41 patients. Importantly, all the injuries that were missed by plain films required treatment.

CT can replace radiography

### Magnetic Resonance Imaging

Magnetic resonance imaging is the imaging study of choice to exclude discoligamentous injuries, if lateral cervical radiographs and CT are negative [164]. MRI is the modality of choice for evaluation of patients with neurological signs or symptoms to assess soft tissue injury of the cord, disc and ligaments.

According to Richards [164], MRI exhibits several significant advantages in the assessment of cervical trauma and allows the following to be diagnosed:

MRI is additional to CT for specific diagnostic assessments

- discoligamentous lesions
- vertebral artery injuries
- neural encroachment and spinal cord contusion
- traumatic meningoceles or CSF leaks
- non-contiguous vertebral fractures
- injury sequelae (e.g., myelomalacia, cysts, syrinx)

Particularly, **STIR sequences** [164] are very helpful in visualizing posterior soft tissue injuries and thereby helping to diagnose unstable Type B or Type C fractures. On the other hand, MRI of asymptomatic individuals has shown that asymmetry of alar ligaments, alterations of craniocervical and atlantoaxial joints, and joint effusions are common in asymptomatic individuals. The clinical relevance of these MR findings is therefore limited in the identification of the source of neck pain in traumatized patients [154]. Furthermore, there is wide variation of segmental motion in the upper cervical spine. Differences in right-to-left rotation are frequently encountered in an asymptomatic population. These measurements are unsuitable for indirect diagnosis of soft tissue lesions after whiplash injury and should not be used as a basis for treatment guidelines [153].

Morphological abnormalities are frequent at the craniocervical junctions and are not per se evidence for sequelae of the injury

MRI is unsuitable for unstable polytrauma patients, because of the difficulties in monitoring ventilated patients, in spite of the expensive specialized equipment. In addition, the MRI scanner is often remote from the emergency department, and necessitates further hazardous transfers and delays.

## Neurophysiology

Neurophysiologic studies are of prognostic value for recovery after SCI

It has been shown that clinical and electrophysiological examinations (see Chapter 12) are of prognostic value for functional recovery in both ischemic and traumatic SCI [111]. Motor evoked potential (MEP) recordings are of additional value to the clinical examination in uncooperative or incomprehensive patients. The combination of clinical examination and MEP recordings allows differentiation between the recovery of motor function (hand function, ambulatory capacity) and that of impulse transmission of descending motor tracts [58]. Furthermore, the initial clinical and electrophysiological examinations are of value in assessment of the degree to which the patient will recover somatic nervous control of bladder function [59].

## Vascular Assessment

The incidence of vertebral artery insufficiency ranges up to 45% in patients with cervical fractures

The association of cerebrovascular insufficiency and cervical fracture was first described by Suechting and French in a patient with Wallenberg's syndrome occurring 4 days after a C5/C6 fracture dislocation injury [189]. The incidence of vertebral artery insufficiency (VAI) is reported in up to 46% of patients with cervical fractures. Fractures through the foramen transversarium (44% [208]), facet fracture-dislocations (45% [208]), or vertebral subluxation (80% [208, 211]) have the highest incidence of post-traumatic VAI. Most patients with VAI are asymptomatic. Among the diagnostic modalities for identifying VAI, angiography, MRI, and duplex sonography seem to be of similar value, although none of these modalities has been compared in a clinical context of cervical injuries. Biffl et al. [29] reported that patients not treated initially with intravenous heparin anticoagulation despite an asymptomatic VAI reported strokes more frequently. However, because the risk of significant complications related to anticoagulation is approximately 14% in these studies, there is insufficient evidence to recommend anticoagulation in asymptomatic patients.

## Synopsis of Assessment Recommendations

The **Neck Pain Task Force** issued recommendations for the clinical management of patients with neck pain presenting to the emergency room after motor vehicle collisions, falls and other mishaps involving blunt trauma to the neck [93]. The task force proposed that the initial clinical assessment should classify patients into four broad categories or grades rather than establishing a specific structural diagnosis [93] (Table 6).

In **Grade I** neck pain, complaints of neck pain may be associated with stiffness or tenderness but no significant neurological complaints. There are no symptoms or signs to seriously suggest major structural pathology, such as vertebral

**Table 6.** Grading of blunt neck injuries

| | |
|---|---|
| **Grade I** | • neck pain with no signs of serious pathology and no or little interference with daily activities |
| **Grade II** | • neck pain with no signs of serious pathology, but interference with daily activities |
| **Grade III** | • neck pain with neurological signs of nerve compression |
| **Grade IV** | • neck pain with signs of major structural pathology |

According to the Neck Pain Task Force [93]

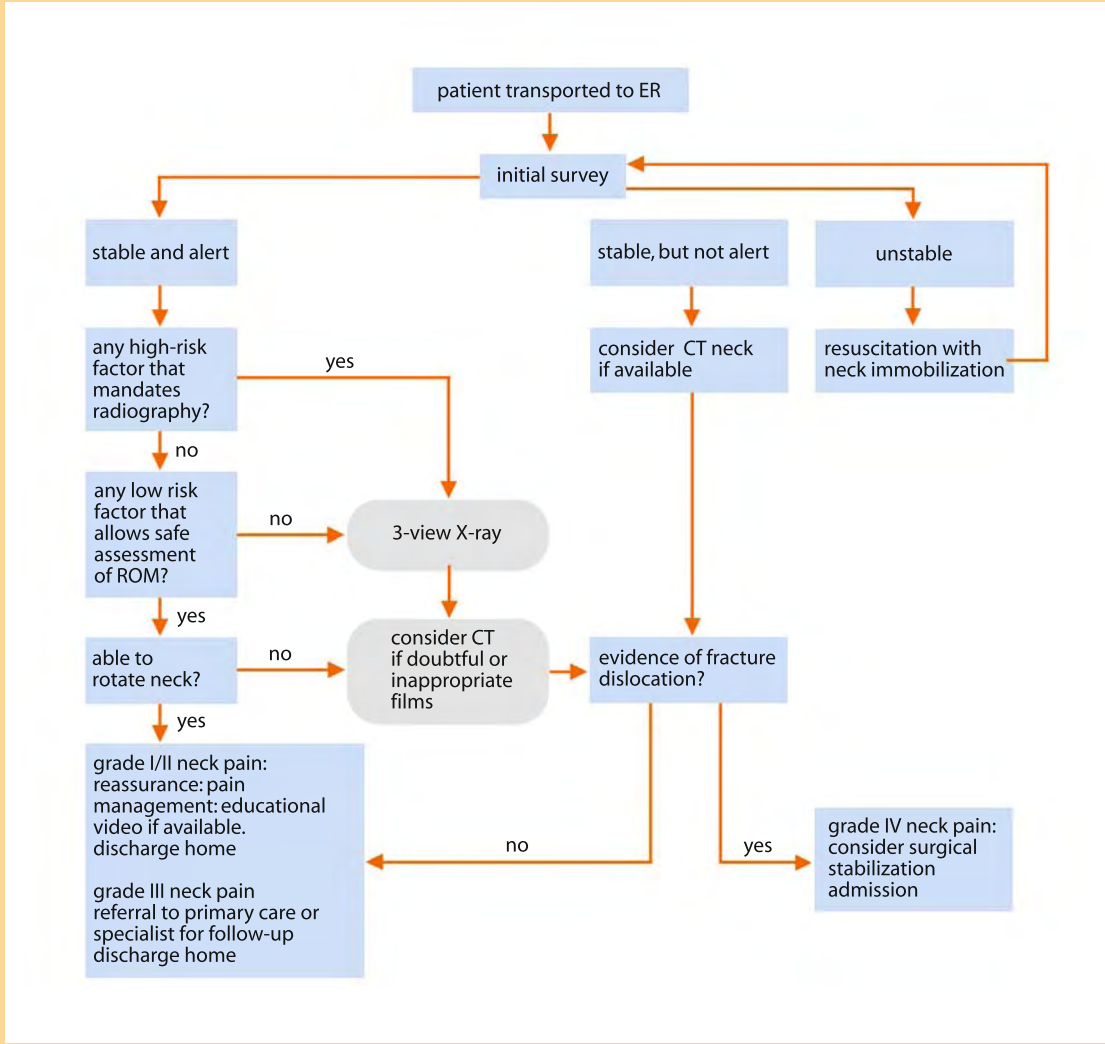


**Figure 7. Assessment recommendations**

The assessment and management of blunt neck trauma in the emergency room as proposed by the **Neck Pain Task Force** [93], reproduced with permission from Lippincott, Williams & Wilkins). High and low risk factors are defined according to the Canadian C-Spine Rule (see Fig. 4) [186].

fracture, dislocation, and injury to the spinal cord or nerves. In **Grade II** neck pain, complaints of neck pain are associated with interference in daily activities, but no signs or symptoms to seriously suggest major structural pathology or significant nerve root compression. Interference with daily activities can be ascertained by self-report questionnaires. In **Grade III** neck pain, complaints of neck pain are associated with significant neurological signs such as decreased deep tendon reflexes, weakness, and/or sensory deficits. These clinical signs suggest malfunction of spinal nerves or the spinal cord. The mere presence of pain or numbness in the upper limb without definitive neurological findings and consistent imaging studies does not warrant a Grade III neck pain designation. **Grade IV** includes complaints of neck pain and/or its associated disorders where the examining clinician detects signs or symptoms suggestive of major structural pathology. Each "grade" of neck pain requires different investigations and management.

For patients presenting to the emergency room after a blunt trauma, a **distinct algorithm** [93] is suggested (Fig. 7) and **diagnostic work-up** is recommended by the Neck Pain Task Force [93]:

- Patients with suspected blunt trauma to the neck presenting to the emergency room with decreased level of consciousness, intoxication, and/or major distracting injuries should be considered high risk for cervical spine fracture or dislocation [105]. A CT scan of the cervical spine should be considered if available.
- Alert (Glasgow Coma Scale of 15) and stable patients should be screened according to the NEXUS criteria or the Canadian C-Spine Rule [105, 186].
- Patients screened as low risk with the above criteria (i.e., Grade I and Grade II) do not require radiological investigation and should receive reassurance and supportive care.
- Patients who do not meet the low-risk criteria (NEXUS, C-Spine Rule) [105, 186] should receive a plain (three-views) radiograph or a CT of the cervical spine (C0–T1). If suspicion remains about cervical spine fracture or dislocation after plain radiography, this group should receive a CT scan.
- In the absence of radicular pain or neurological signs, and where radiographs and/or a CT scan rule out spinal fracture or dislocation, patients should be classified as Grade I or Grade II (as appropriate).
- Patients with radiographs or CT scan compatible with spinal fracture or dislocation and those with radicular findings (decreased deep tendon reflexes, weakness and/or sensory deficits) should be referred to a spinal surgery specialist for evaluation.
- Flexion/extension radiographs, five-view radiographs, and MRI of the cervical spine do not add meaningful clinical information to the emergency management of blunt trauma to the neck in the absence of fracture, dislocation, or radicular signs [148].

## General Treatment Principles

The general objectives of the treatment of cervical injuries are (Table 7):

**Table 7.** General objectives of treatment

| | |
|---|---|
| • restoration of spinal alignment | • preservation or improvement of neurological function |
| • restoration of spinal stability | • avoidance of collateral damage |
| • restoration of spinal function | • resolution of pain |

The treatment should provide a biological and biomechanical sound environment that allows uneventful bone and soft-tissue healing and finally results in a stable, fully functional and pain-free spinal column. These goals should be accomplished with a minimal risk of morbidity.

### Whiplash-Associated Disorders

Treatment recommendation cannot be solidly based on scientific evidence from the literature because of the poor methodological quality and inhomogeneity of the studies [199]. However, it appears that rest and immobilization using collars are not recommended for the treatment of whiplash, while active interventions, such as advice to “maintain normal activities,” might be effective in acute whiplash patients [177, 198]. In chronic WAD, a combination of cogni-

tive behavioral therapy with physical therapy intervention and coordination exercise therapy appear to be effective [177]. Recent research has demonstrated that both coping behaviors and depressive symptomatology play a significant role in the recovery of patients with WAD and need to be addressed at an early stage [41, 42].

In WAD, reassurance about the absence of a structural lesion and the recommendation to maintain normal activities are most important for recovery

The Bone and Joint Decade Task Force recommends certain management strategies which can help, at least in the short term. In the early stages of Grade I or II neck pain (no radiculopathy or structural pathology) after a motor vehicle collision, the Neck Pain Task Force recommends the following clinical approach [93]:

- reassurance about the absence of serious pathology
- education that the development of spinal instability, neurological injury or serious ongoing disability is very unlikely
- promotion of timely return to normal activities of living
- if needed, exercise training and/or mobilization to provide short-term relief

Cervical **sprains and strains** of the cervical spine after **non-motor vehicle accidents** are quite common [201] and similar treatment recommendations apply.

## Non-operative Treatment Modalities

Cervical orthoses limit movement of the cervical spine by buttressing structures at both ends of the neck, such as the chin and the thorax. However, applied pressure over time can lead to **complications** such as:

- pressure sores and skin ulcers
- weakening and atrophy of neck muscles
- contractures of soft tissues
- decrease in pulmonary function
- chronic pain syndrome

### Collars

**Soft collars** (Fig. 8a, b) have a limited effect on controlling neck motion, restricting flexion/extension about 20–25%, lateral bending 8%, and one-directional rotation 17% [155]. A soft collar is at best useful for the acute (short-term) treatment of minor cervical muscle strains and sprains. However, soft collars are no better than the recommendation of "return to normal activities" particularly not in WADs [148]. The **Philadelphia collar** (Fig. 8c, d) has been shown to control neck motion, especially in the flexion/extension plane, much better than the soft collar. Restriction in flexion/extension is 71%, lateral bending 34%, and axial rotation 56%. Disadvantages of the Philadelphia collar are the lack of control for flexion/extension control in the upper cervical region and lateral bending and axial rotation [155]. Further, the Philadelphia collar was shown to elicit increased occipital pressure, which may result in scalp ulcers, particularly in comatose patients.

### Minerva Brace/Cast

A Minerva cervical brace is a cervicothoracal orthosis with mandibular, occipital, and forehead contact points. Radiological evaluation showed the Minerva cervical brace to limit flexion/extension in 79%, lateral bending in 51%, and axial rotation in 88% of cases [178]. This brace provides adequate immobilization between C1 and C7, with less rigid immobilization of the occipital-C1 junc-

**Figure 8. Orthosis and casts**

a, b Soft collar, c, d Philadelphia collar, e, f Minerva cast.

tion. The addition of the forehead strap and occipital flare assists in immobilizing C1–C2 [178]. However, we prefer a customized Minerva cast made of a **Scotch** cast, which can be individually molded and provides a reliable fixation which the patient cannot simply take off (Fig. 8e, f).

### Traction

The Gardner-Wells tongs (Fig. 9a) can be applied using local anesthesia. The pin application sites should be a finger breadth above the pinna of the auricle of the ear in line with, or slightly posterior to, the external auditory canal (Fig. 9d, e). The exact anteroposterior position can be chosen to help apply traction with the neck in some flexion (*posterior site*) or extension (*anterior site*). The device should be tightened until 1 mm of the spring-loaded stylet protrudes (Fig. 9b, c), which corresponds to an average of 13.5 kg of compressive force. Of note, the pin only penetrates the external skull lamina. The average force necessary to penetrate the inner table with cadaveric specimens with the tong pin was 73 kg [126], indicating a large safety margin. If the device is planned to remain for an extended time period, the marker should be tightened once again 24–48 h after application. A nut located over each pin should be tightened down to the tong to secure the pins in position, minimizing the risk of break-out.

Rule out AOD or discoligamentous disruption before applying traction

Although most cervical injuries can be stabilized with traction, it is mandatory to rule out an atlanto-occipital dislocation or complete discoligamentous injuries before applying traction because of the inherent risk of rapid neurological deterioration, which can be irreversible.

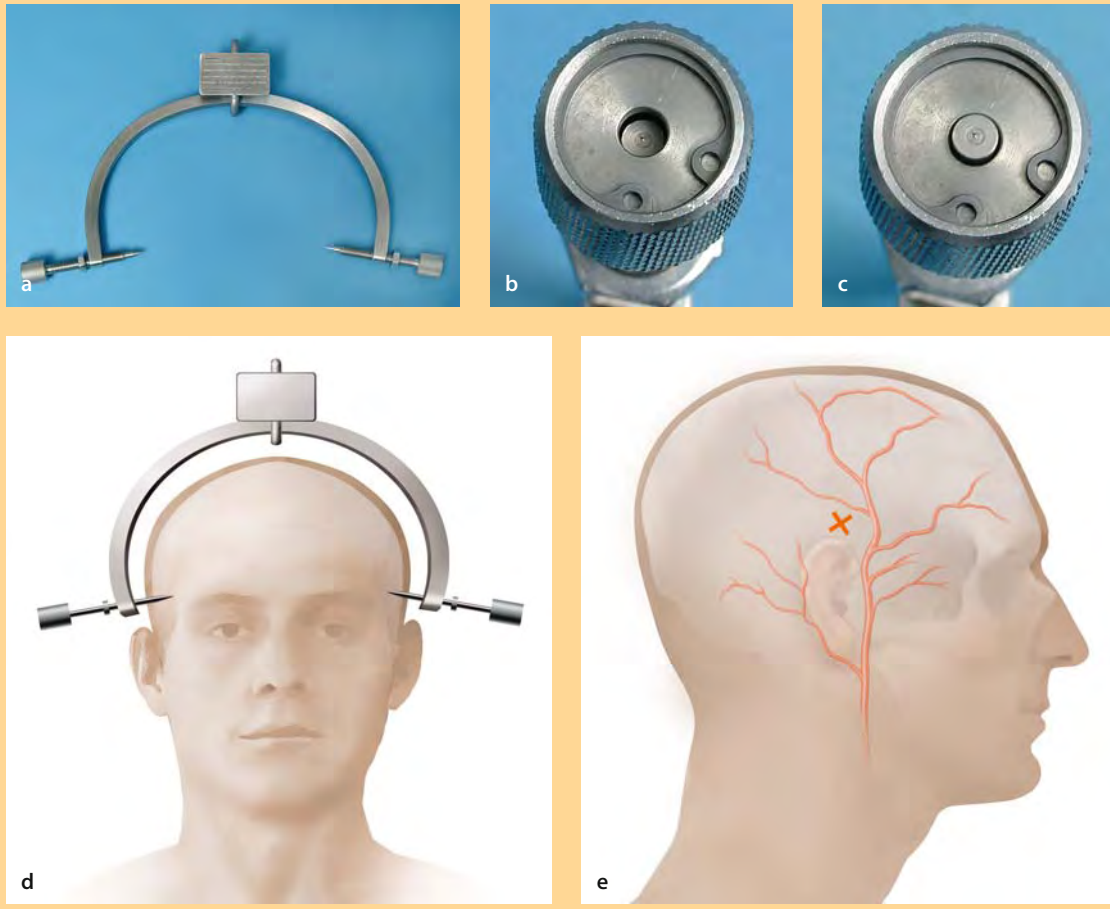


**Figure 9. Traction**

Gardner-Wells tongs. a Anteroposterior view; b view of spring-loaded stylet (unloaded); c view of spring-loaded stylet (loaded); d, e correct positioning of the skull pins.

The initial weight should not exceed 5–7 kg (depending on body weight) and increases incrementally (30–60 min) only after control imaging. Recommendations for the maximum weight cannot be based on the literature. However, weights up to 60 kg have been reported [53], but we do not recommend to go to that limit.

### Halo

The halo vest is the first conservative choice for unstable lesions

Since its introduction by Nickel [145, 146], the halo skeletal fixator has proved to be the most rigid and effective method of cervical spine immobilization [116]. It was originally developed to immobilize the unstable cervical spine for surgical arthrodesis in patients with poliomyelitis. Longitudinal traction with a cranial halo affords control and positioning in cervical flexion, extension, tilt, and rotation as well as longitudinal distraction forces. The optimal position for anterior halo pin placement is 1 cm superior to the orbital rim (eyebrow), above the lateral two-thirds of the orbit, and below the greatest circumference of the skull. This area can be considered as a relatively "**safe zone**" (Fig. 10a, b). Ring or crown size is determined by selection of a ring that provides 1–2 cm clearance around every

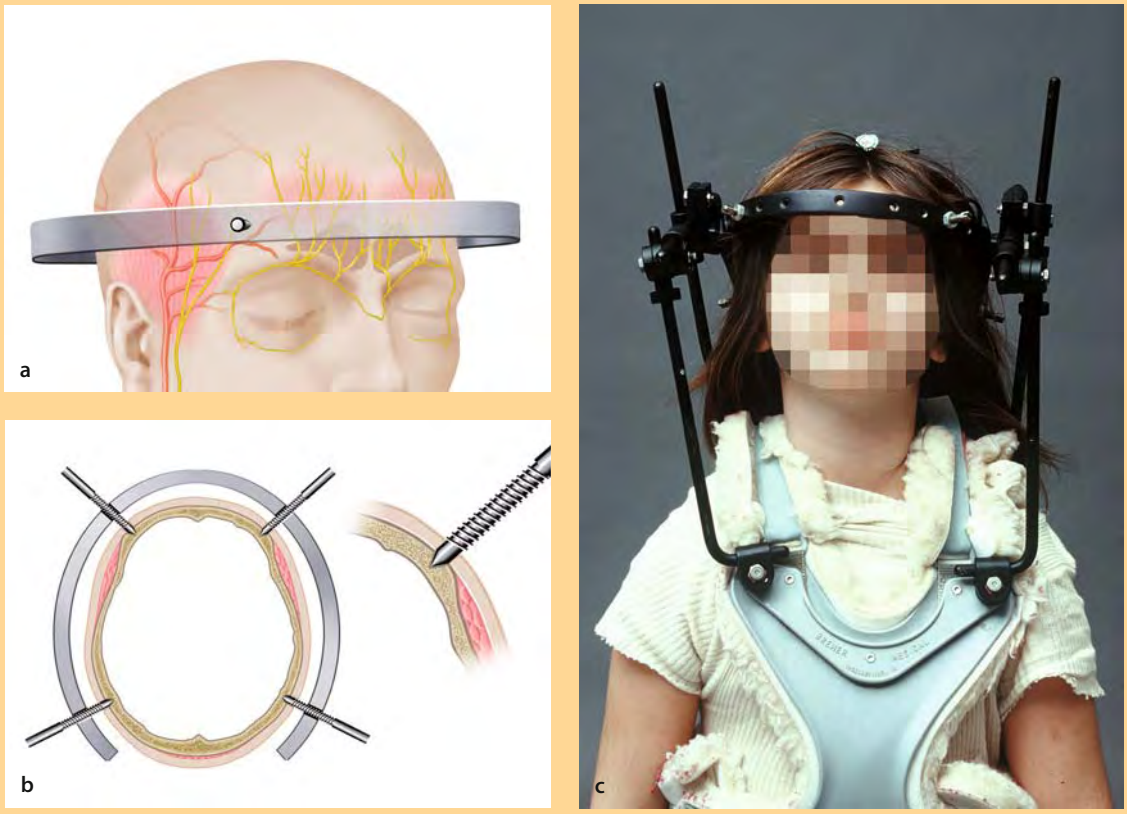


**Figure 10. Halo**

a, b Correct positioning of the skull pins, c halo vest.

aspect of the head perimeter. Vest size is determined by measurement of chest circumference with a tape measure. The halo vest (Fig. 10c) seems to be the first choice for conservative treatment of unstable injuries of the upper cervical spine, although pin track problems, accurate fitting of the vest, and a lack of patient compliance lead to clinical failures [165]. Because of these drawbacks, the authors' preference is a Minerva cast.

## Spinal Cord Injuries

Spinal cord injury frequently results from cervical fracture/dislocation

Spinal cord injuries are frequently associated with traumatic cervical spine fractures and cervical facet dislocation injuries due to a displacement of fracture fragments or subluxation of one vertebra over another. Reduction of the deformity helps to restore the diameter of the bony canal and eliminates bony compression of the spinal cord. Theoretically, **early decompression** of the spinal cord after injury may lead to improved neurological outcome. However, indication and timing of surgical interventions in patients with complete and incomplete spinal cord injuries has been debated in the literature [6]. Yablon et al. [211] found that patients who underwent operative stabilization more frequently improved regarding neurological level than patients who were treated conservatively. In tetraplegic patients, such improvement can be essential for quality of life.

### Role of Steroids in Acute Spinal Cord Injury

High-dose methylprednisolone is highly controversial in acute SCI

The role of steroids in acute spinal cord injury is very **controversial** [35, 122]. Although the use of corticosteroids can usually be considered safe in surgical patients [166, 168, 190], the potential side effects of high dose methylprednisolone such as infections [84, 86], pancreatitis [100], myopathies [157], psychosis [194], and lactate acidosis in combination with intravenous adrenaline treatment [98] are important arguments against this treatment. After the release of the NASCIS (National Acute Spinal Cord Injury Study) II study [36], the use of high-dose methylprednisolone in spinal cord injury became the standard of care. However, many researchers found the study methodology and statistics questionable. Short [180] revisited this concern within the evidence-based framework of a critical appraisal of the accumulation of clinical studies and concluded that high-dose methylprednisolone cannot be justified as a standard treatment in acute spinal cord injury within current medical practice. On the other hand, the fact that there may be some hope of benefit and that adverse medicolegal implications are feared has led many centers to adhere to the NASCIS II guidelines. Nevertheless, many centers are currently revising these guidelines to limit or discontinue the use of methylprednisolone [131]. We only consider high-dose methylprednisolone treatment for young patients with a monotrauma of the spine, i.e., without significant additional injuries.

### Role and Timing of Spinal Cord Decompression

Secondary SCI due to additional fracture/dislocation must be avoided

Particularly in unstable fractures, further mechanical injury to the spinal cord by secondary dislocations must be avoided. The severity of the injury is related to the force and duration of compression, the displacement and the kinetic energy. Many animal models, including those of primates, have demonstrated that neurological recovery is enhanced by early decompression [72].

However, this experimental evidence has not been translated to patients with acute spinal cord injury. This may in part be due to:

- heterogeneous injury patterns
- absence of well-designed RCTs

Even delayed decompression may improve neurology

While one randomized controlled trial (RCT) showed no benefit of early (< 72 h) decompression [197], several recent prospective series suggest that early decompression (< 12 h) can be performed safely and may improve neurological outcomes [72]. Aebi et al. [12] demonstrated in 100 retrospectively examined patients that reduction within the first 6 h revealed the best neurological results. Lee et al. [124] found that 26 % of patients who were reduced within 12 h improved the Frankel scale two or more grades, whereas only 8 % improved if reduction was performed after 12 h. Immediate **closed reduction** is the most rapid and effective procedure for decompression in patients presenting with significant motor deficits [90]. However, pre-reduction MRI performed in patients with cervical fracture dislocation injury will demonstrate disrupted or herniated intervertebral discs in one-third to one-half of patients with facet subluxation [3, 90]. These findings do not seem to significantly influence outcome after closed reduction in awake patients and the usefulness of pre-reduction MRI can be questioned in this setting. A number of studies have documented recovery of neurological function even after delayed decompression of the spinal cord (months to years) after the injury [21, 33, 34, 123, 193]. The improvement in neurological function with delayed decompression in patients with cervical or thoracolumbar spinal cord injury who have plateaued in their recovery is noteworthy and suggests that compression of the cord is an important contributing cause of neurological dysfunction [3].

Urgent decompression is indicated for an incomplete SCI

There are currently no standards regarding the role and timing of decompression in acute spinal cord injury. An immediate operative intervention is recommended in patients with incomplete spinal cord injury or progressive neurological deterioration, and in whom there is a persistent mechanical compression of the spinal cord by fracture fragments or disc material [6, 72].

## Specific Treatment of Upper Cervical Spine Injuries

For the vast majority of cervical injuries, there is insufficient scientific evidence to support diagnostic and treatment standards or guidelines. At best it is possible to indicate options which are evidence enhanced but not evidence based [2]. We acknowledge that the anecdotal experience of the authors has been used to attempt to fill in the gap in those areas where scientific evidence is lacking. We therefore ask the reader to **critically evaluate any treatment recommendation before adaptation**.

### Fractures of the Occipital Condyle

Occipital condyle fractures are rare and require CT/MRI assessment

Traumatic occipital condyle fracture (OCF) was first described by Bell in 1817 [28]. Occipital condyle fractures are rare injuries. Clinical suspicion should be raised by the presence of one or more of the following criteria: blunt trauma patients sustaining high-energy craniocervical injuries, altered consciousness, occipital pain or tenderness, impaired cervical motion, lower cranial nerve paresis, or retropharyngeal soft tissue swelling. Computed tomographic imaging allows the establishment of the diagnosis of OCF and for a precise assessment of fracture displacement. MRI is recommended to assess the integrity of the craniocervical ligaments [8].

#### Classification

Occipital condyle fracture can be distinguished into **three types** (Fig. 11):

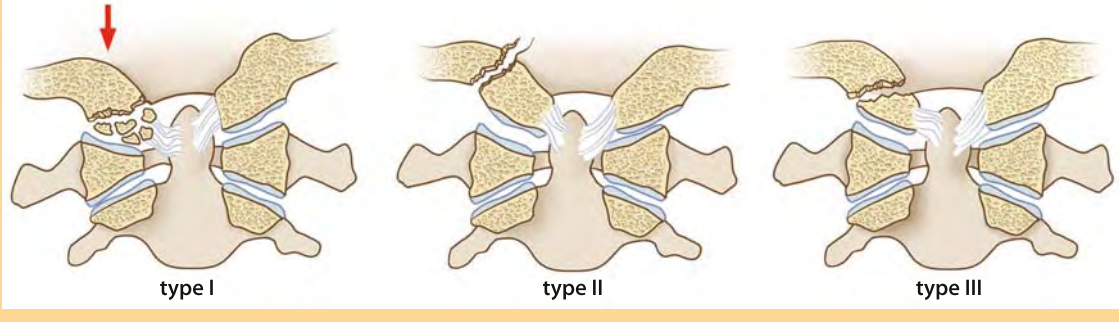


**Figure 11. Classification of occipital condyle fractures**

**Type I:** fractures may occur with axial loading. **Type II:** fractures are extensions of a cranial basilar fracture. **Type III:** fractures result from an avulsion of the condyle during rotation, lateral bending, or a combination of these mechanisms.

#### Treatment

Occipital condyle fractures are usually treated by external immobilization

The choice of treatment depends on the extent of fracture displacement (as seen in CT) and ligamentous injury. Depending on the severity of injury, the treatment ranges from collar immobilization to more rigid halo jacket or cast immo-

bilization [8]. Patients with untreated OCF may develop lower cranial nerve deficits which then require rigid immobilization [8]. However, OCFs are rarely associated with neurological deficits and can usually be treated conservatively [212]. In 2002, a review of the literature of OCF revealed 47 articles including a total of 91 patients. Based on this review, treatment with external cervical immobilization is recommended [8]. Although Type III OCFs are considered unstable, not all patients will develop neurological deficits and require surgery [8].

## Atlanto-occipital Dislocation

Atlanto-occipital dislocation is a rare and often fatal condition

Atlanto-occipital dislocation (AOD) is a rare and often fatal traumatic injury that is difficult to diagnose. Immediate death may result from injuries to the brain, spinal cord, and lesions to the vascular structures, particularly the vertebral arteries [1]. In individuals who have survived the initial injury, the diagnosis is often overlooked because AOD is frequently combined with traumatic brain injury or multiple organ trauma. Patients who survive often have neurological impairment, such as unilateral or bilateral weakness, lower cranial neuropathies, or tetraplegia. The diagnosis is frequently missed on initial lateral cervical X-rays [1]. Interestingly, nearly 20% of patients with acute traumatic AOD will have a normal neurological examination on presentation [1]. Prevertebral soft tissue swelling on a lateral cervical radiograph or craniocervical subarachnoid hemorrhage on axial CT has been associated with AOD and should increase the suspicion of this lesion. CT with 3D image reformation, MRI and angiography are the imaging modalities that will allow the diagnosis of AOD and to exclude additional concomitant injuries [121]. Avulsion fractures of the occipital condyles, apical dens fractures, and a retropharyngeal hematoma may lead to the diagnosis of an AOD [63]. The presence of upper cervical prevertebral soft tissue swelling on an otherwise non-diagnostic plain X-ray should prompt additional imaging [1]. If there is clinical suspicion of AOD, and plain X-rays do not suffice, CT and/or MRI is necessary [1].

### Classification

A lateral cervical radiograph is recommended for the diagnosis of AOD to calculate the ratio of basion/posterior arch of C1 to anterior arch of C1/opisthion according to Kricun [120] (Fig. 5c). Three types of AOD can be classified according to Traynelis [196] (Fig. 12).

A systematic review of the literature published between 1966 and 2001 revealed 48 articles including a total of 79 patients with AOD (29 Type I, 32 Type II, 4 Type III). However, 14 cases were unclassifiable because these fractures were lateral, rotational, and multidirectional dislocations not fitting the three types of Traynelis [196].

### Treatment

Rule out AOD before applying traction

All patients with AOD should be treated [1]. Without treatment, nearly all patients develop neurological deterioration and recovery is unlikely. In the presence of AOD, traction may result in devastating neurological deficits [1]. Therefore, AOD must be ruled out before applying traction.

Internal fixation and fusion is indicated in all patients with AOD

Therapeutic options aim to stabilize the cervico-occipital junction and to avoid secondary neurological deterioration [185]. Consequently, craniocervical fusion with internal fixation (using a Y-plate or newer generation occipital plate-rod systems) is recommended for the treatment of patients with acute traumatic AOD to allow for early mobilization [1].

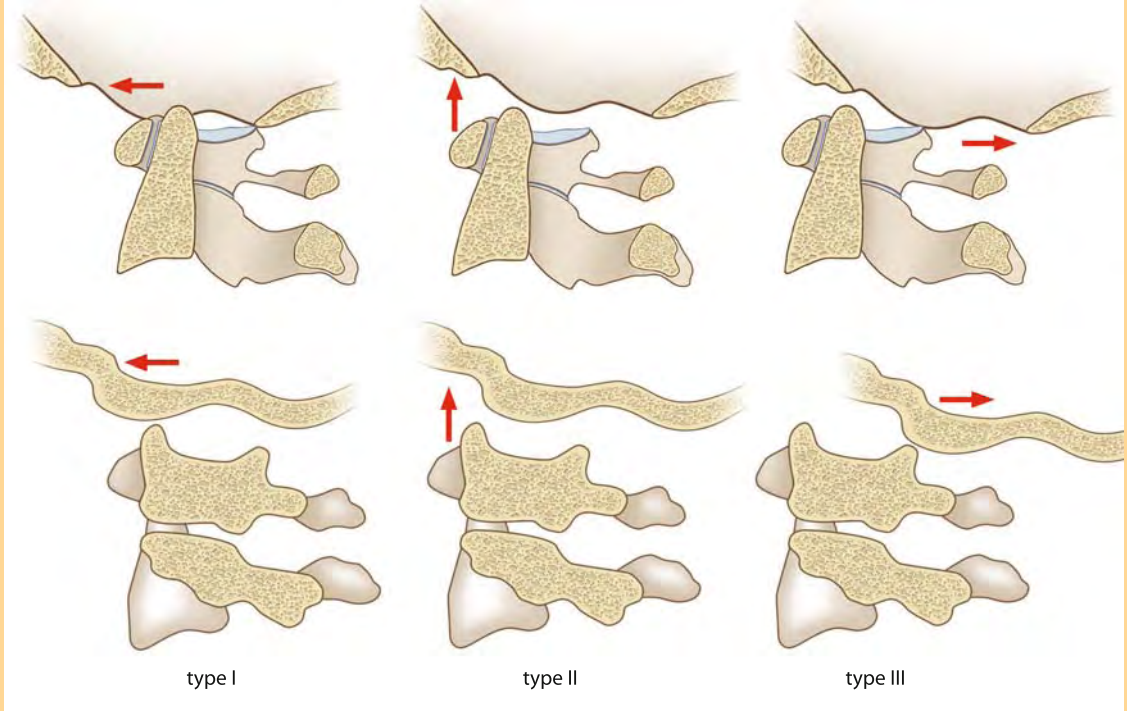


**Figure 12. Atlanto-occipital dislocations**

**Type I:** anterior dislocation. **Type II:** vertical dislocation. **Type III:** posterior dislocation.

## Fractures of the Atlas

Fractures of the atlas account for approximately 1–2% of all fractures and for 2–13% of all acute cervical spine fractures [94, 129, 179]. Cooper was the first to demonstrate a fracture of the atlas in 1822 at autopsy. In 1920, Jefferson [114] reviewed 42 previously described cases of atlas fractures adding 4 of his own cases. Although his article documents a variety of atlas fracture patterns, it is best known for the characterization of the "**Jefferson fracture**," i.e., a burst fracture injury of the atlas ring [99]. Acute atlas fractures comprise a large variety of fracture types. These fractures are frequently associated with other cervical fractures or ligamentous traumatic injuries [95, 150].

### Classification

Burst fractures of the atlas are caused by massive axial loads and often occur at the sulcus vertebralis, the weakest site of the arch. These fractures are very frequently associated with other fractures of the craniocervical junctions. According to Jefferson [114], **five types** can be differentiated (Fig. 13).

### Treatment

The extent of lateral mass displacement is decisive for the treatment

The treatment of atlas fractures in combination with other cervical fracture injuries is most commonly linked to the treatment of the associated injury [95]. The decision for the treatment of atlas fracture depends on the stability of the fracture. The main criteria to determine C1–C2 instability due to transverse atlantal ligament injury include the sum of displacement of the lateral masses of C1 com-

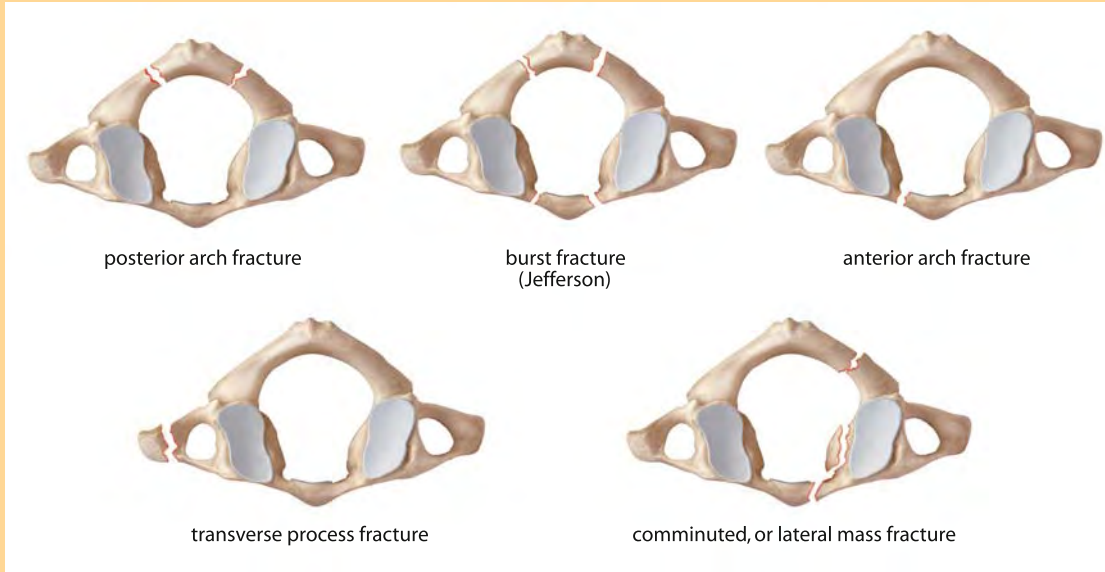


Figure 13. Classification of atlas fractures

pared to C2 of more than 8 mm on plain X-rays (rule of Spence [183] corrected for magnification [102]), a predental space of more than 4 mm in adults [206], and MRI evidence of ligamentous disruption or avulsion [4].

Unstable burst fractures should be treated with rigid external fixation or instrumented fusion

The literature does not allow treatment recommendations to be given on solid scientific evidence. So far, treatment options are based on the specific atlas fracture type [4]. It is recommended to treat isolated fractures of the atlas with **intact** transverse alar ligaments (implying C1–C2 stability) with cervical immobilization alone (rigid collar, halo vest, or Minerva cast) for a duration of 10–12 weeks [4]. It is recommended to treat isolated fractures of the atlas with **disruption** of the transverse ligament with rigid external fixation (halo vest or Minerva cast) or with atlantoaxial screw fixation and fusion [4].

## Atlantoaxial Instabilities

Atlantoaxial instabilities are rare after trauma

Atlantoaxial instability results from either a purely ligamentous injury or avulsion fractures. While atlantoaxial dislocation and subluxation is relatively common in patients with rheumatoid arthritis [40], a traumatic origin due to a rupture of the transverse ligament is rare [62]. Atlantoaxial dislocations occur more frequently in elderly patients when compared to other traumatic cervical injuries [112]. These injuries are significant, because complete bilateral dislocation of the articular processes can occur at approximately 65° of atlantoaxial rotation. When the transverse ligament is intact, a significant narrowing of the spinal canal and subsequent potential spinal cord damage is possible [54]. With a deficient transverse ligament, complete unilateral dislocation can occur at approximately 45° with similar consequences. In addition, the vertebral arteries can be compromised by excessive rotation which may result in brain stem or cerebellar infarction and death [173, 202].

A special form of atlantoaxial instability is referred to as **atlantoaxial rotatory subluxations**, which may occur with or without an initiating trauma. Non-traumatic etiologies include juvenile, rheumatoid arthritis, surgical interventions such as tonsillectomy or mastoidectomy, and infections of the upper respiratory tract ("Grisel syndrome").

### Classification

Atlantoaxial instabilities can be classified according to the direction of the dislocation as [20]:

- anterior (transverse ligament disruption, dens or Jefferson fracture)
- posterior (dens fracture, see Fielding Type IV)
- lateral (lateral mass fracture of C1, C2, or unilateral alar ligament ruptures)
- rotatory (see Fielding Types I–III)
- vertical (rupture of the alar ligaments and tectorial membrane)

#### *Rotatory Atlantoaxial Instability*

Only Types I and II occur as a result of trauma

Rotatory injuries of the atlantoaxial joint are a spectrum of rare lesions that range from rotatory fixation within the normal range of C1–C2 motion to frank rotatory atlantoaxial dislocation [51, 74, 75, 128]. Atlantoaxial rotatory dislocations frequently occur in children but rarely in adults. According to Fielding et al. [74, 75], four types can be differentiated (Fig. 14):

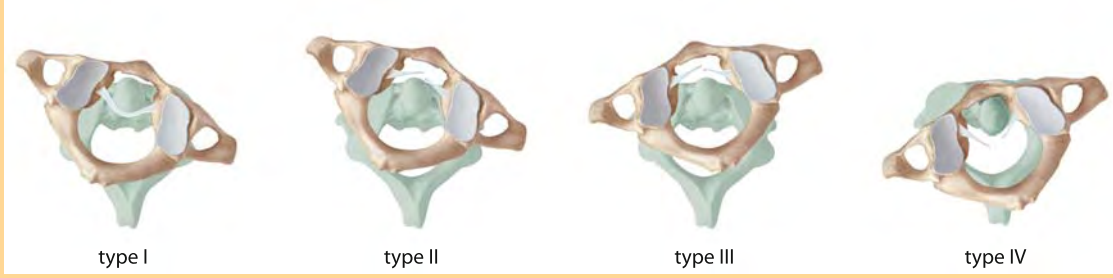


**Figure 14. Atlantoaxial rotatory subluxation**

**Type I:** rotatory fixation with no anterior displacement (transverse ligament intact) and the dens working as pivot. **Type II:** rotatory fixation with anterior displacement of 3–5 mm and one lateral articular process acting as the pivot. **Type III:** rotatory fixation with anterior displacement of more than 5 mm. **Type IV:** rotatory fixation with posterior displacement. Type III and IV were only observed in non-traumatic conditions.

### Treatment

Reduction and instrumented fusion is the treatment of choice

**Anterior dislocations** of more than 3 mm are regarded as unstable and usually fail to heal conservatively. Therefore, reduction and atlantoaxial fusion is recommended as the treatment of choice [101]. The internal fixation should reduce and prevent further translation of C1 on C2. In both cases, the transarticular screw technique or the C1–C2 fusion technique described by Harms [96] is a good surgical option. A Gallie or Brooks fusion should be added to obtain long-term stability. The treatment of **posterior** and **lateral** instabilities depends largely on the concomitant injury (e.g., dens fracture). **Vertical** instability is treated by an occipitocervical fusion [20]. **Type I rotatory** instabilities are often stable and can be treated by reduction, and rigid external fixation for 4–6 weeks. In recurrent Type I rotatory instabilities as well as in unstable **Type II** instabilities, an atlantoaxial fusion is indicated [20].

## Dens Fractures

The most common axis injury is a fracture through the odontoid process. Atlantoaxial motion is primarily rotational, accounting for about one-half of the axial

rotation of the head on the neck [203]. Translational motion of C1 on C2 is restricted by the transverse atlantal ligaments that center the odontoid process to the anterior arch of C1. With a fracture of the odontoid process, restriction of translational atlantoaxial movement is lost [205].

### Classification

According to the classification of Anderson and D'Alonzo [19], three types can be differentiated (Fig. 15):

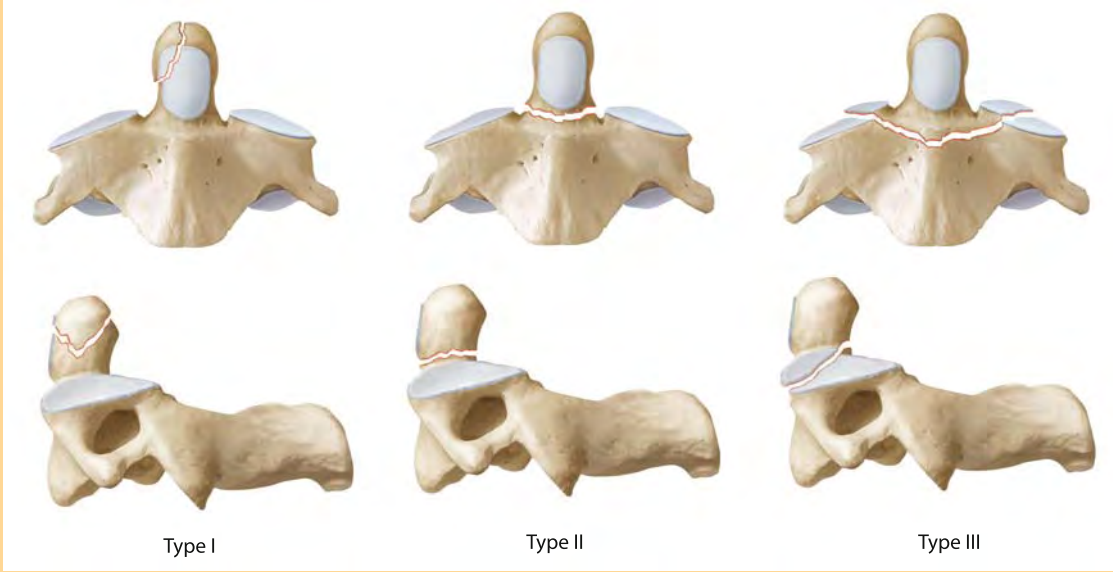


**Figure 15. Odontoid fractures**

**Type I:** oblique fractures through the upper portion of the odontoid process. **Type II:** across the base of the odontoid process at the junction with the axis body. **Type III:** through the odontoid that extends into the C2 body.

In 1988, Hadley et al. [94] added a comminuted fracture involving the base of the odontoid as a **Subtype IIA**. The incidence of a Type IIA fracture was 5% of all Type II fractures. Importantly, Type IIA fractures were associated with severe instability and inability to obtain and maintain fracture reduction and realignment.

Comminuted (Type IIA) fractures are associated with severe instability

### Treatment

A variety of non-operative and operative treatment alternatives have been proposed for odontoid fractures based on [5]:

- fracture type
- degree of (initial) dens displacement
- extent of angulation
- patient's age

#### *Non-operative Treatment*

The non-operative treatment options consist of:

- cervical collar
- traction

- Minerva cast
- halo jacket

Cervical collar is an option for Type I fractures

Several authors proposed treatment of odontoid fractures with **cervical collars**. In a series by Polin et al. [156], 36 Type II fractures were treated either with a Philadelphia collar or with halo vest immobilization. The fusion rate was lower in the patients treated with collars compared with patients managed in halos (53 % vs. 74 %, respectively). The infrequent Type I odontoid fracture seems to have an acceptable rate of fusion with rigid cervical collar immobilization, approaching 100 % in one study [19, 47, 49]. **Type III** odontoid fractures have been treated with cervical collars as well, but the fusion rates are in the range 50 – 65 % in small series.

Traction and cervical collars are inappropriate for Type II fractures

Reviews by Traynelis [195] and Julien et al. [118] address the treatment of odontoid fractures with **traction** and subsequent immobilization in a cervical collar. The authors concluded that the non-union rate of Type II dens fractures is almost 50 % indicating that traction and cervical collar immobilization is not appropriate for Type II fracture patients.

Halo immobilization is an option for Type I and III odontoid fractures

Greene et al. [91] reviewed 199 odontoid fractures and reported that successful fusion was obtained with **halo vest immobilization** in the Type I (100 %) and Type III fractures (98.5 %). Non-union resulted in 28 % of Type II fractures treated with external immobilization for a median of 13 weeks. A displacement of the dens of 6 mm or more was associated with a high non-union rate (86 % failure rate), irrespective of patient age, direction of displacement, or neurological deficit. Julien et al. [118] reviewed nine articles that dealt with treatment of odontoid fractures (total of 269 patients) using halo/Minerva fixation for 8 – 12 weeks. The non-union rate for Type I, II and III odontoid fractures was 0 %, 35 % and 16 %, respectively.

The high non-union rate of Type II dens fractures is due to inadequate fracture immobilization

White and Panjabi [205] have outlined that it is unlikely that the high non-union rate of Type II fractures is due to a limited blood supply to the fracture fragments but rather due to the inadequate immobilization of the fracture.

### *Operative Treatment*

Surgical techniques to stabilize the atlantoaxial joint complex are technically demanding. Proper understanding of the fracture, careful preoperative planning (e.g., CT studies of the anatomical landmarks), adequate knowledge of the surgical anatomy, good intraoperative fluoroscopic control, and precise surgical technique will yield the best results. Based on recent literature reviews [5, 118, 195], Type II and Type III odontoid fractures should be considered for surgical fixation in cases of:

- dens displacement of 5 mm or more
- dens fracture (Type IIA)
- inability to achieve fracture reduction
- inability to achieve main fracture reduction with external immobilization

Greene et al. [91] have found that patients with dens displacement of 6 mm or more had a non-union rate of 86 %, compared with a non-union rate of 18 % for patients with displacement of less than 6 mm.

The **surgical armamentarium** consists of:

- anterior dens screw fixation (Fig. 16a–d)
- anterior atlantoaxial screw fixation and fusion (Fig. 16e, f)
- posterior atlantoaxial fusion (Gallie or Brooks) (Fig. 17a–d)
- posterior atlantoaxial screw fixation and fusion (Fig. 17e, f)
- posterior atlas and axis screw-rod fixation and fusion (Fig. 17g, h)

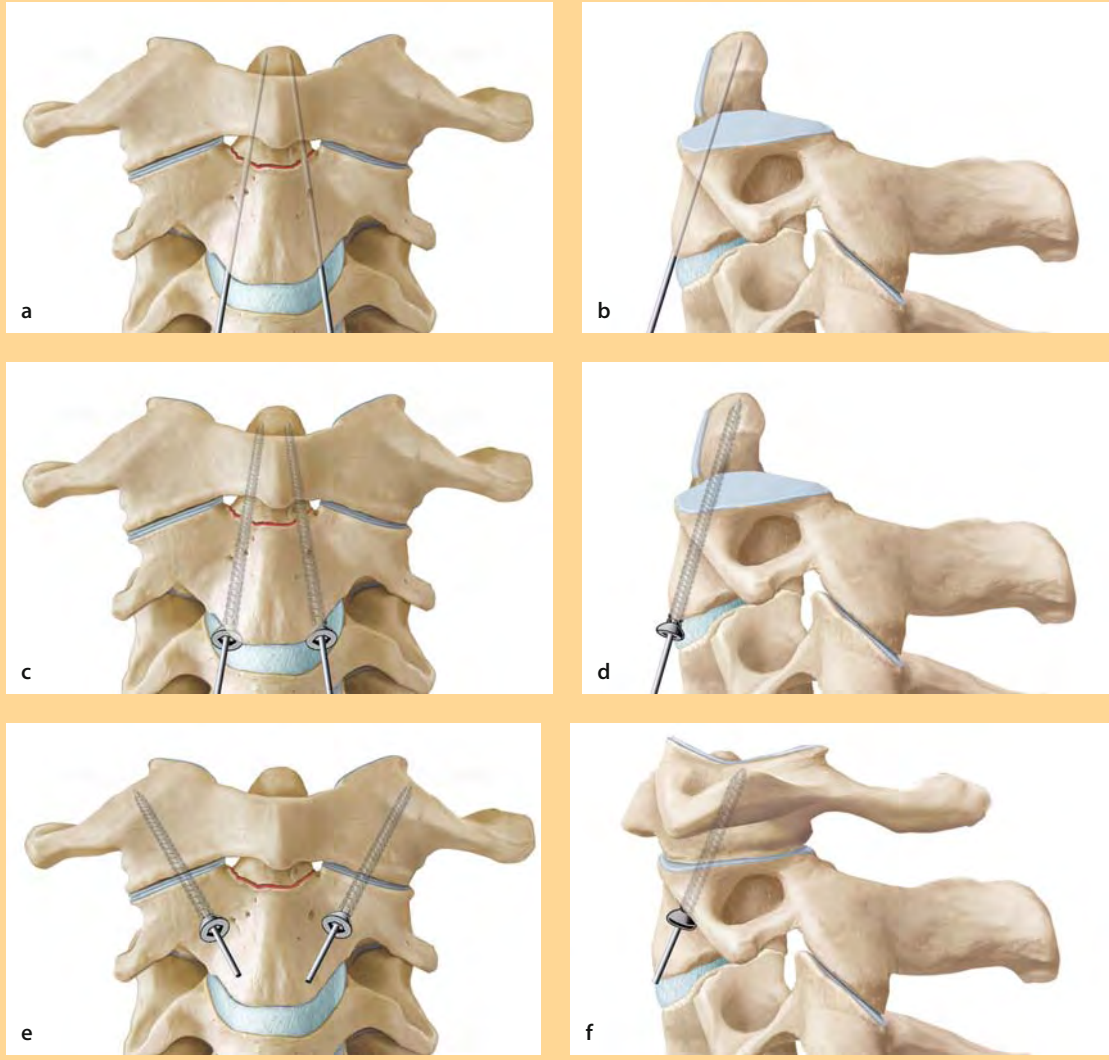


**Figure 16. Anterior surgical stabilization of dens fractures**

**Anterior dens screw fixation:** a The dens fracture is reduced prior to surgery by traction and patient positioning. Two Kirschner wires are inserted in an anterior-caudal to posterior-cranial direction. b The Kirschner wires should be convergent but must allow for enough interspace for the insertion of the cannulated screws. c, d Cannulated screws are inserted over the Kirschner wires. When inserting the screw care must be taken that the screw is not angulated to the guide wire in order not to cause breakage or proximal advancement of the guide wire. After screw insertion the wires are removed. e, f **Anterior transarticular screw fixation:** As an augmentation of the anterior dens screw or in cases of a salvage procedure, screws can be inserted over Kirschner wires from a medial-anterior-caudal to a lateral-posterior-cranial direction crossing the atlantoaxial joint.

Anterior screw fixation is indicated in Type II fractures

**Anterior odontoid screw fixation** is indicated in Type II fractures with either a horizontal or anterior cranial to posterior caudal direction of the fracture line. In cases in which the fracture line is running in the anterior caudal to posterior cranial direction, fracture displacement is likely and therefore a contraindication. This direct osteosynthesis technique aims to maintain rotational motion at the atlantoaxial joint. Transverse alar ligament disruption is a contraindication for anterior screw fixation because of persistent transverse instability. In the review by Julien et al. [118], the fusion rate of Type II fractures treated with anterior screw fixation was 89 %.

Dislocated Type II and Type IIA fractures are indications for surgery

The technical issue of whether one or two screws are needed has been addressed in various studies [25, 115, 188]. Although there is a theoretical advantage of preventing rotation with two screws, there is no increased strength for bending movements and no difference in successful bony fusion. Although two screws are theoretically desirable, fixation with one screw is sufficient with adequate technique [115, 188] (Case Study 1). Apfelbaum et al. [25] compared anterior screw fixation for recent and remote odontoid fractures in 147 patients at two institutions (138 Type II, 9 Type III). Anterior screw fixation was performed either within 6 months of injury or more than 18 months after injury. At a mean follow-up of 18 months, the fusion rates were 88 % and 25 %, respectively. These results indicate that remote dens fractures do not favorably respond to anterior screw fixation. An alternative technique for augmentation or salvage procedures of failed anterior screw fixation is an **anterior atlantoaxial screw fixation** (Fig. 16e, f).

In cases with remote dens fractures, dens non-union, os odontoideum or elderly patients with osteoporosis, a posterior approach is more likely to be successful. The classical treatment is a **posterior instrumented fusion** according to

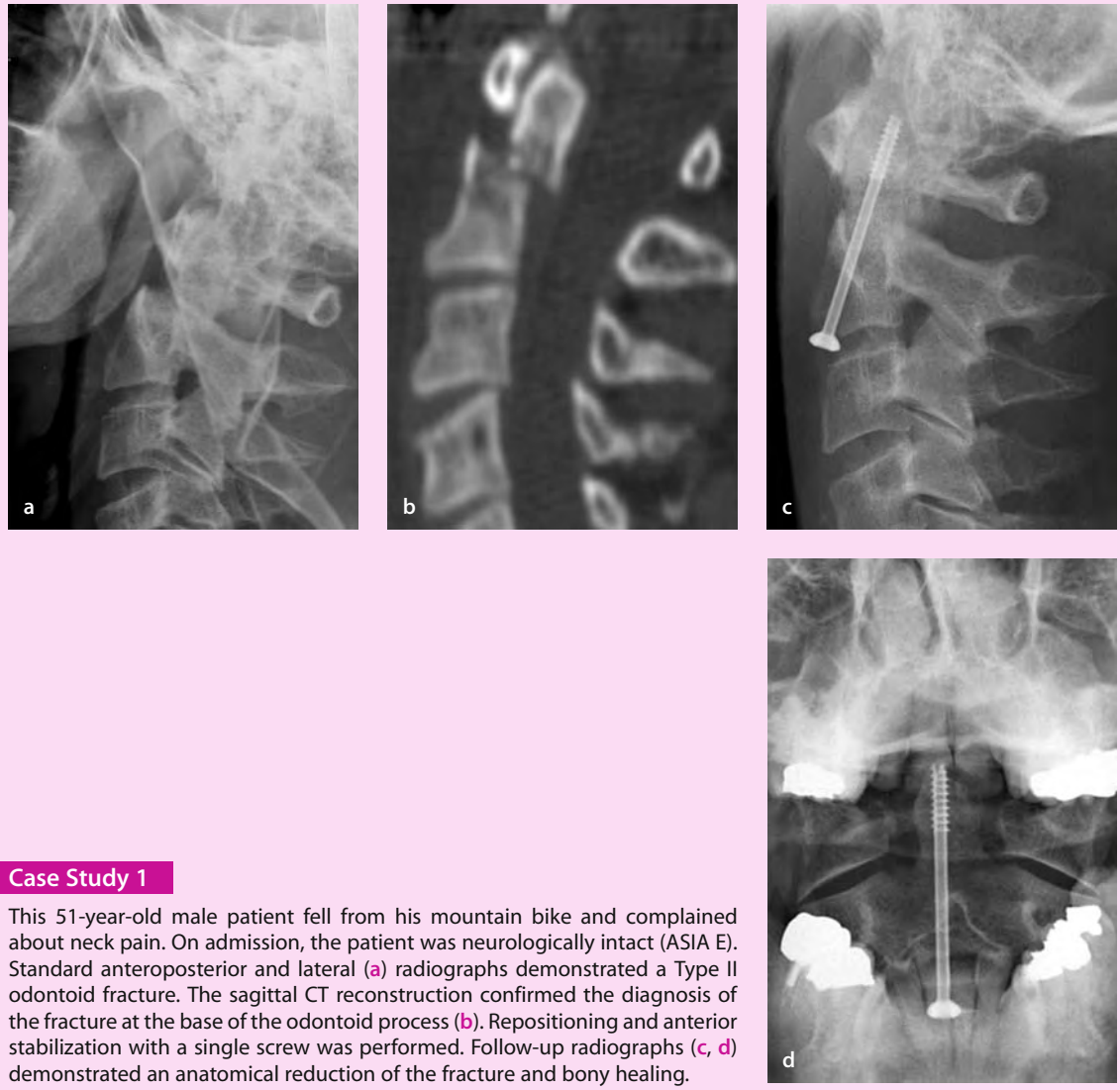


**Case Study 1**

This 51-year-old male patient fell from his mountain bike and complained about neck pain. On admission, the patient was neurologically intact (ASIA E). Standard anteroposterior and lateral (a) radiographs demonstrated a Type II odontoid fracture. The sagittal CT reconstruction confirmed the diagnosis of the fracture at the base of the odontoid process (b). Repositioning and anterior stabilization with a single screw was performed. Follow-up radiographs (c, d) demonstrated an anatomical reduction of the fracture and bony healing.

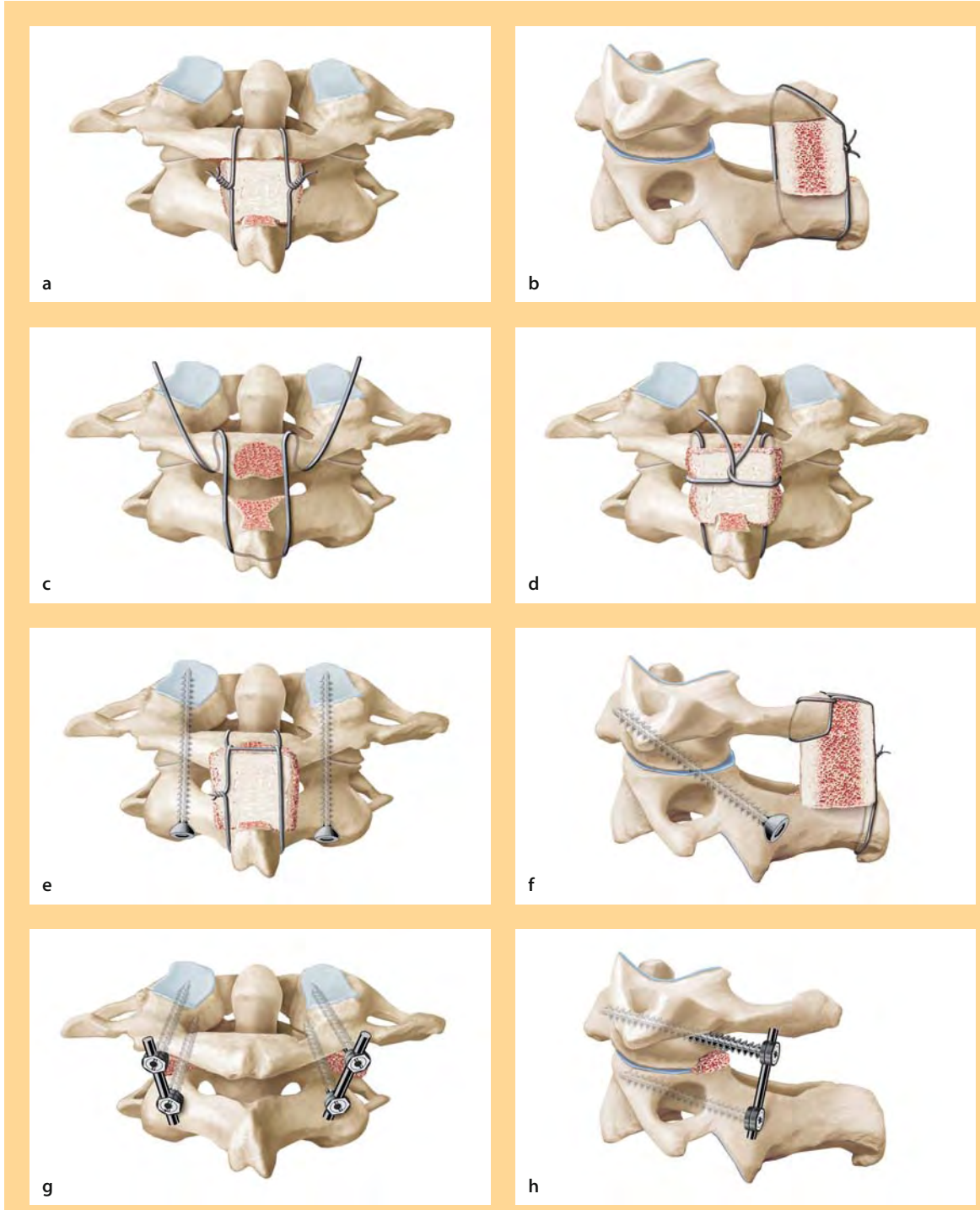


**Figure 17. Posterior atlantoaxial stabilization techniques**

Posterior C1/2 fusion according to a, b **Brooks** and c, d **Gallie**. e, f Transarticular atlantoaxial screw fixation according to **Magerl** [113] with additional wire cerclage and fusion with a bicortical bone graft. g, h Alternative screw-rod fixation according to **Harms** [96].

**Gallie** or **Brooks** (Fig. 17a–d). The drawback of these fusion techniques is the lack of primary stability increasing the rate of non-union. **Posterior atlantoaxial transaxial screw fixation and fusion** (Fig. 17e, f) according to Magerl [113] provides the highest chance of successful fusion. Harms et al. [96] have described an alternative fixation method for the atlantoaxial joint complex, i.e., a **posterior atlas and axis screw-rod fixation and fusion** (Fig. 17g, h) (Case Study 2). In a recent review [5], 8 papers describe a total of 147 patients who underwent posterior cervical fixation and fusion for Type II dens fractures and 29 patients treated similarly for Type III fractures. The overall fusion rate for fractures managed with surgical fixation and fusion was 87 % (Type II) and 100 % (Type III), respectively.

#### *Management in the Elderly Patient*

Posterior instrumented fusion is indicated for Type II fractures in the elderly

The management of odontoid fractures in the elderly patient remains controversial. Ryan and Taylor [167] described 30 patients 60 years and older with Type II odontoid fractures. The fusion success rate in patients older than 60 years treated with external immobilization was only 23 %. Similarly, Andersson et al. [24] described 29 patients 65 years and older with odontoid fractures managed by surgical and non-surgical means. In their series, six (86 %) of seven patients achieved successful fusion after posterior cervical C1–C2 arthrodesis. Patients treated with anterior odontoid screw fixation had a fusion rate of 20 % and patients managed with external immobilization alone had a fusion rate of 20 %. Pepin et al. [152] reported their experience with 41 acute odontoid fractures and found that halo immobilization was poorly tolerated in patients 75 years and older. They suggested that early C1–C2 fixation and fusion was appropriate in this group. In a recent review [5], three case series argued against surgical fixation in the elderly patient whereas seven other case series favor surgical fixation in this age group. One case-control study by Lennarson et al. [125] provides Class II medical evidence for surgical treatment of elderly patients. This study examined 33 patients with isolated Type II odontoid fractures treated with halo vest immobilization. The authors found that patients older than 50 years had a significantly increased failure rate of fusion in a halo immobilization device (21 times higher) when compared to patients younger than 50 years. Other factors such as medical conditions, sex of the patient, degree of fracture displacement, direction of fracture displacement, length of hospital stay, or length of follow-up did not influence outcome.

## Traumatic Spondylolisthesis of the Axis

Traumatic fractures of the posterior elements of the axis may occur after hyperextension injuries as seen in motor vehicle accidents, diving, and falls or judicial hangings [172, 210]. Therefore, the term "**hangman's fracture**" was coined by Schneider in 1965 [172]. Garber [85] described eight patients with "pedicular" fractures of the axis after motor vehicle accidents and used the term "**traumatic spondylolisthesis**" of the axis.

### Classification

The classification scheme of Effendi [70] has gained widespread acceptance for the classification of these injuries. Effendi et al. [70] described three types of fractures which are mechanism based (Fig. 18).

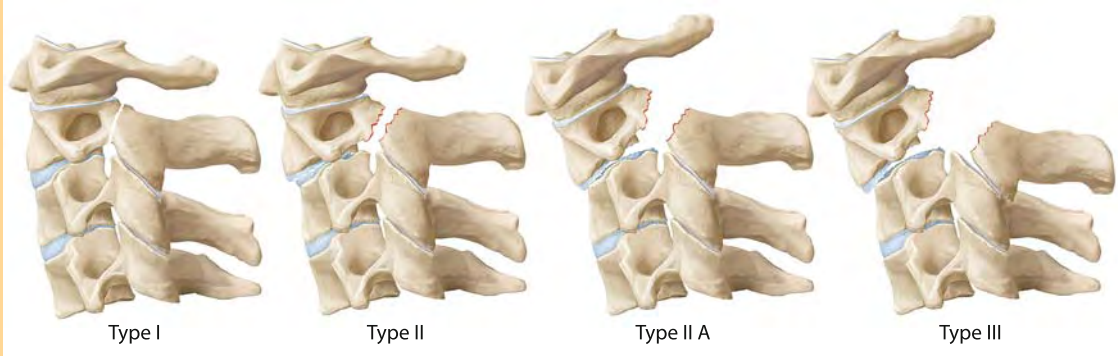


**Figure 18. Traumatic spondylolisthesis (hangman's fracture)**

**Type I:** isolated hairline fractures of the ring of the axis with minimal displacement of the body of C2. These injuries are caused by axial loading and hyperextension. **Type II:** displacement of the anterior fragment with disruption of the disc space below the axis. These injuries are a result of hyperextension and rebound flexion. **Type IIA:** displacement of the anterior fragment with the body of the axis in a flexed position without C2–C3 facet dislocation. **Type III:** displacement of the anterior fragment with the body of the axis in a flexed position in conjunction with C2–C3 facet dislocation. These injuries are caused by primary flexion and rebound extension.

In the series reported by Effendi [70], **Type I** fractures were the most prevalent (65%) while **Type II** (28%) and **Type III** fractures (7%) were less common. In 1985, Levine and Edwards [127] modified Effendi's classification scheme by adding a **subtype Type IIA** (flexion/distraction injury). However, not all axis fractures can be classified according to this scheme [39]. Fujimura et al. [83] used radiological criteria to classify axis body fractures into: avulsion, transverse, burst, or sagittal fracture.

### Treatment

Most patients with traumatic spondylolisthesis reported in the literature were treated with cervical immobilization with good results [5]. Importantly, there is no Class I or Class II evidence that addresses the management of traumatic spondylolisthesis of the axis [5]. Fractures of the axis body can mostly be treated nonoperatively [5, 91]. Most traumatic spondylolisthesis heals with 12 weeks of cervical immobilization with either a rigid cervical collar or a halo immobilization device.

Most fractures heal within 12 weeks of external immobilization

**Surgical stabilization** is a preferred treatment option in cases with:

Surgical stabilization is an option in Type II and III fractures

- severe angulation (Effendi Type II)
- disruption of the C2–C3 disc space (Effendi Type II and III)
- inability to establish or maintain fracture alignment with external immobilization

Surgical options for unstable traumatic spondylolisthesis include anterior C2/3 interbody fusion with anterior plate fixation (Case Introduction) and posterior techniques such as direct screw fixation of the posterior arch [117]. In the series by Effendi et al. [70], 42 of 131 patients with hangman's fractures were treated surgically (10 anterior C2–C3 fusion and 32 posterior fusion). All were successfully stabilized at latest follow-up. In the study by Francis et al. [78], only 7 of 123 patients with hangman's fractures were treated surgically (4 anterior C2–C3 fusion, 2 posterior C1–C3 fusion, and 1 posterior C2–C4 fusion). The authors report that 6 of the 7 patients demonstrated a C2–C3 angulation of more than

Axis body fractures are usually treated conservatively

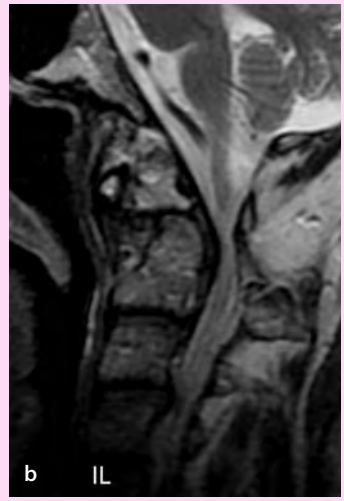

## Case Study 2

This 47-year-old male patient fell from a donkey at the age of 12 years. Neurological symptoms started at the age of 26 years. He recently presented with signs of chronic central cord compression, spasticity and gait difficulties (ASIA D). The sagittal CT reconstruction (a) demonstrates a pseudarthrosis of the odontoid process. The MRI (b) shows the compression of the spinal cord at the level of the pseudarthrosis. Flexion/extension radiographs (c, d) were taken during the operation and demonstrate the important atlantoaxial instability. Dorsal fusion of C1/C2 was performed according to the technique of Harms [96]; in addition laminectomy of C1 was performed. The intraoperative radiographs (e, f) show the reposition and the position of the hardware as well as the needles used for the intraoperative neurological monitoring (e). The postoperative CT scan demonstrates the reposition of the odontoid process in the anteroposterior view (g) and lateral view (h), the position of the pedicle screw in C1 (i) and C2 (j), as well as the laminectomy of C1 (i).

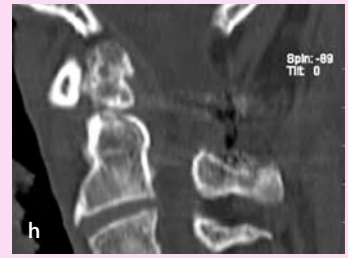

11 degrees. All seven patients achieved bony stability. A number of case series of hangman's fractures offer similar experiences with surgical management [5].

## Combined Atlas/Axis Fractures

The occurrence of the fractures in combination often implies a more significant structural and mechanical injury. Combination fractures of the C1–C2 complex are relatively common [7]. In reports focusing primarily on odontoid fractures, the occurrence of a concurrent C1 fracture in the presence of a Type II or Type III odontoid fracture has been reported in 5–53 % of cases. Odontoid fractures have been identified in 24–53 % of patients with atlas fractures. In the presence of a hangman's fracture, the reported incidence of a C1 fracture ranges from 6 % to 26 % [7].

A higher incidence of neurological deficit is associated with combined atlas and axis fractures. The atlas–Type II odontoid combination fracture seems to be the most common combination injury subtype, followed by atlas–miscellaneous axis, atlas-Type III odontoid, and atlas–traumatic spondylolisthesis fractures.

### Treatment

The axis fracture characteristics commonly dictate the management

Reports of combined atlas/axis fractures are relatively rare and no treatment guidelines but only recommendations can be derived from the literature [7]. Treatment of combined atlas-axis fractures is based primarily on the specific characteristics of the axis fracture. External immobilization is recommended for most combined atlas/axis fractures. Combined atlas–Type II odontoid fractures with an atlantodental interval of more than 4 mm and atlas–traumatic spondylolisthesis injuries with angulation of more than 10 degrees should be considered for surgical stabilization and fusion. The surgical technique must in some cases be modified as a result of loss of the integrity of the ring of the atlas. In most circumstances, the specifics of the axis fracture will dictate the most appropriate management of the combination fracture injury. The integrity of the ring of the atlas must often be taken into account when planning a specific surgical strategy using instrumentation and fusion techniques. In cases where the posterior arch of C1 is not intact, both incorporation of the occiput into the fusion construct (occipitocervical fusion) and posterior C1–C2 transarticular screw fixation and fusion have been successful [7].

## Classification and Treatment of Subaxial Injuries

Eighty percent of all cervical injuries affect the subaxial spine

In contrast to atlas and axis, the vertebrae and articulations of the subaxial cervical spine (C3–C7) have similar morphological and kinematic characteristics. However, important differences in lateral mass anatomy and in the course of the vertebral artery exist between the mid and lower cervical spine. Approximately 80 % of all cervical spine injuries affect the lower cervical spine and these injuries are often associated with neurological deficits [17, 22, 32, 182]. The variety and heterogeneity of subaxial cervical spinal injuries require accurate characterization of the mechanism and types of injury to enable a comparison of the efficacy of operative and non-operative treatment strategies.

## Classification

The Allen and Ferguson classification system [16] has been the most commonly used scheme to differentiate and characterize subaxial vertebral injuries. Based on 165 cases, Allen and Ferguson [16] described common groups for: compressive flexion, vertical compression, distractive flexion, compressive extension, distractive extension, and lateral flexion.

A systematic classification of the lower cervical spine was proposed by Aebi et al. [12, 13] and modified by Blauth [30]. The classification is adapted from the AO/ASIF (Association for the Study of Internal Fixation) classification scheme, which is widely used for thoracolumbar fractures (see Chapter 31). The three main groups are shown in Table 8 and Fig. 19.

**Table 8.** AO Fracture Classification of lower injuries

| Type A: compression injuries | Type B: anterior and posterior element injury with distraction | Type C: anterior and posterior element injury with rotation |
|---|---|---|
| A1.1<br>impaction of the endplate | B1.1<br>with transverse disc disruption | C1.1<br>rotational wedge fracture |
| A1.2<br>wedge impaction | B1.2<br>with Type A vertebral body fracture | C1.2<br>rotational split fracture |
| A1.3<br>vertebral body collapse | B1.3<br>anterior subluxation | C1.3<br>rotational burst fracture |
| A2.1<br>sagittal split fracture | B2.1<br>transverse bicolumn fracture | C2.1<br>B1 injury with rotation |
| A2.2<br>coronal split fracture | B2.2<br>transverse disruption of the disc | C2.2<br>B2 injury with rotation |
| A2.3<br>pincer fracture | B2.3<br>with Type A vertebral body fracture | C2.3<br>B3 injury with rotation |
| A3.1<br>incomplete burst fracture | B3.1<br>hyperextension subluxation | C3.1<br>slice fracture |
| A3.2<br>burst-split | B3.2<br>hyperextension spondylolysis | C3.2<br>oblique fracture |
| A3.3<br>complete burst fracture | B3.3<br>posterior dislocation | C3.3<br>complete separation of the adjacent vertebrae |

Types, groups, and subgroups allow for a morphology-based classification of cervical fractures according to Aebi and Nazarian [13] and modified by Blauth et al. [30]

The fracture types are related to **specific injury pattern**, i.e.:

- injuries of the anterior elements induced by **compression** (**Type A**)
- injuries of the posterior and anterior elements induced by **distraction** (**Type B**)
- injuries of the anterior and posterior elements induced by **rotation** (**Type C**)

Types B and C are the most common fractures

Types B and C are the most common fracture types (Table 9).

Subaxial fracture-dislocation is frequently associated with neurological injury (Table 10).

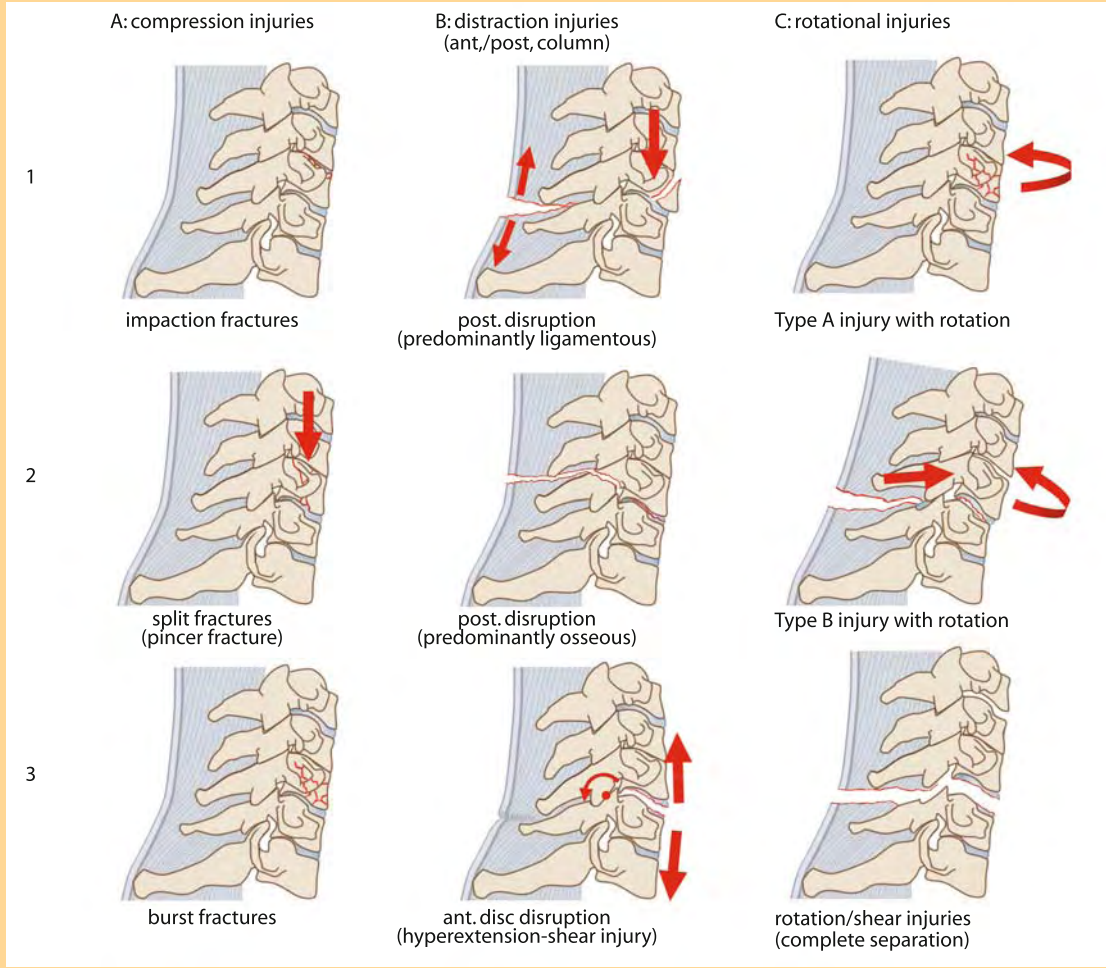


**Figure 19. AO Fracture Classification of subaxial injuries**

According to the classification of AOSPINE (Blauth et al. [30], redrawn and modified).

**Table 9.** Frequency of fracture types in subaxial injuries

| | *n* = 448 | Total percentage | Percentage within the types |
|---|---|---|---|
| **Type A** | **66** | **14.7 %** | |
| A1 | 13 | 2.9 % | 19 – 7 % |
| A2 | 9 | 2.0 % | 13.7 % |
| A3 | 44 | 9.8 % | 66.6 % |
| **Type B** | **197** | **43.9 %** | |
| B1 | 157 | 35.0 % | 79.7 % |
| B2 | 4 | 0.9 % | 2.0 % |
| B3 | 36 | 8.0 % | 18.3 % |
| **Type C** | **185** | **41.2 %** | |
| C1 | 0 | 0 % | 0 % |
| C2 | 184 | 41.0 % | 99.5 % |
| C3 | 1 | 0.2 % | 0.5 % |

Based on an analysis of 448 cases by Blauth et al. [30]

**Table 10.** Frequency of neurological deficits in subaxial injuries

| Types and groups | Number of patients | Neurological deficit |
|---|---|---|
| **Type A** | **66** | **42.4%** |
| A1 | 13 | 15.3% |
| A2 | 9 | 22.2% |
| A3 | 44 | 54.5% |
| **Type B** | **197** | **64.4%** |
| B1 | 157 | 61.0% |
| B2 | 4 | 75.0% |
| B3 | 36 | 73.0% |
| **Type C** | **185** | **62.7%** |
| C1 | 0 | 0% |
| C2 | 184 | 62.0% |
| C3 | 1 | 100% |
| **Total** | **448** | **60.7%** |

Based on an analysis of 448 cases by Blauth et al. [30]

## Treatment

### Non-operative Management

Most subaxial cervical injuries can be treated conservatively

Most subaxial spine injuries can be successfully treated by conservative means (Philadelphia collar, Minerva cast or halo vest fixation). Treatment with traction and prolonged bedrest has been associated with increased morbidity and mortality and has widely been abandoned today. After reduction of dislocated fractures, more rigid fixation techniques (halo vest fixation, Minerva cast) appear to have better success rates than less rigid orthoses (collars, traction only).

### Operative Management

Operative stabilization of unstable fractures (especially for Type B and Type C injuries) is gaining increasing acceptance because it facilitates aftertreatment without disturbing external supports. **Indications for surgical treatment** include (Table 11) [11]:

**Table 11.** Surgical indications for subaxial injuries

- irreducible spinal cord compression
- ligamentous injury with facet instability
- spinal kyphotic deformity more than 15°
- vertebral body fracture compression of 40% or more
- vertebral subluxation of 20% or more
- failure to achieve anatomical reduction (irreducible injury)
- persistent instability with failure to maintain reduction
- ligamentous injury with facet instability

Most subaxial spine injuries can be treated by an anterior approach

Both posterior (Fig. 20) and anterior (Fig. 21) cervical fusion techniques usually result in spinal stability for most patients with subaxial injuries. The outcome of **anterior vs. posterior fracture fixation** has been addressed in various recent publications [14, 77, 97, 119, 133, 162, 192]. The studies include only small case series (21 patients [77] to 35 patients [119]) and the methodology allows the classification of the studies using only Class III and Class IV [97, 192] evidence. Aebi et al. [14] were one of the first groups to suggest that most lower cervical spine fractures can successfully be treated by an anterior approach even in the case of distraction and rotation injuries with posterior element involvement. Today, literature reviews indicate that anterior fixation of fractures of the lower cervical

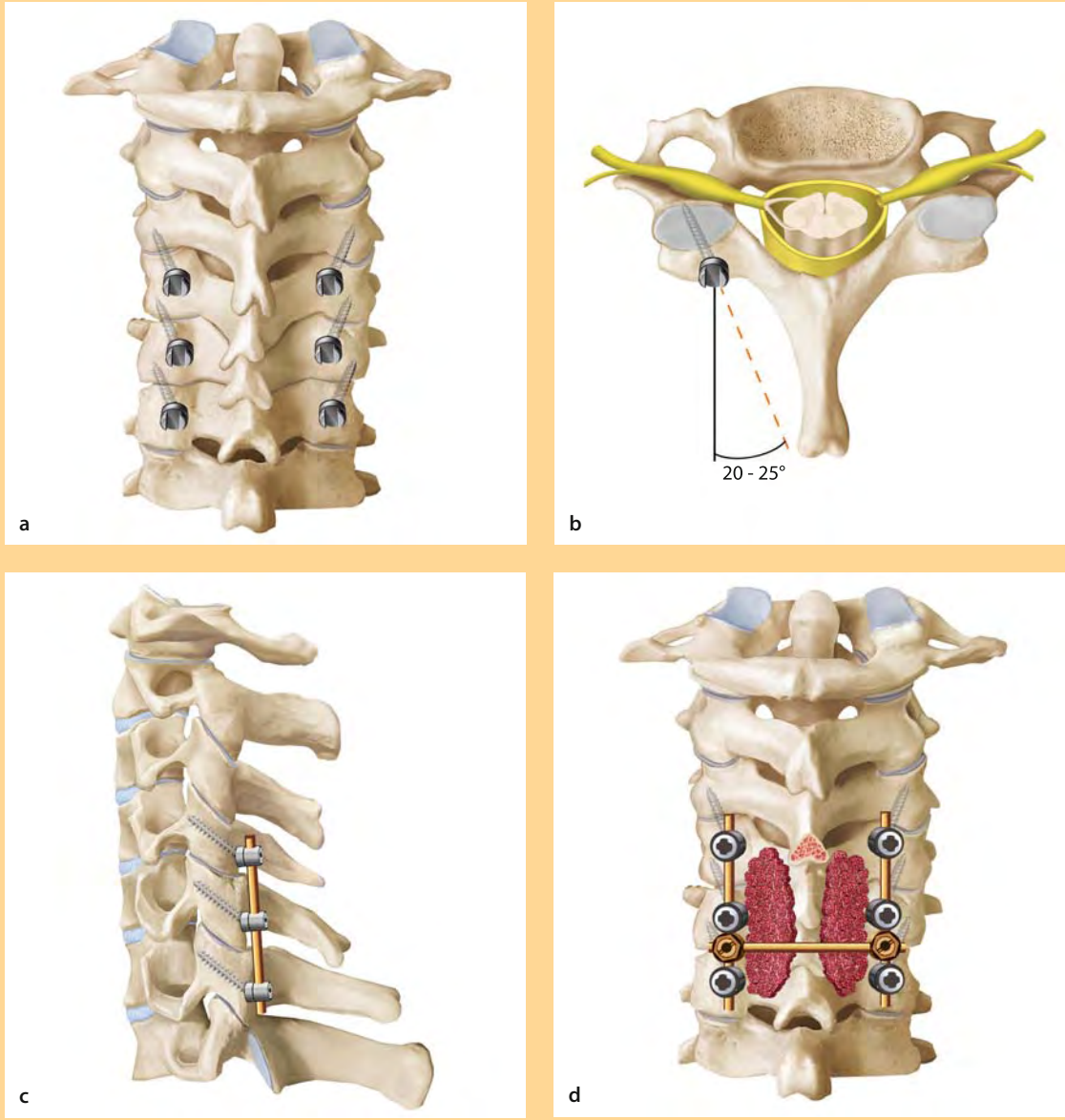


**Figure 20. Posterior fracture stabilization**

a, b Lateral mass screw fixation according to the technique of Magerl [113]. The screw is directed from the medial upper quadrant of the facet joint 20–25° laterally and 30–40° cranially. Polyaxial top-loading screws facilitate rod placement. c, d After decortication of the posterior elements, a posterior fusion is added and a cross-connector used (when appropriate) to increase construct stability.

spine is now the preferred treatment approach. Failures of this technique which may result in reoperations are rare (0–6%) [119, 133].

Anterior fusion should not be performed without plate fixation (Fig. 21), because it is associated with an increased likelihood of graft displacement and the development of late kyphosis, particularly in patients with distractive Type B and Type C injuries [11].

Anterior fusion should **not** be performed without plate fixation

Similarly, posterior fusion that uses wiring techniques is more likely to result in late displacements with kyphotic angulation when compared to posterior

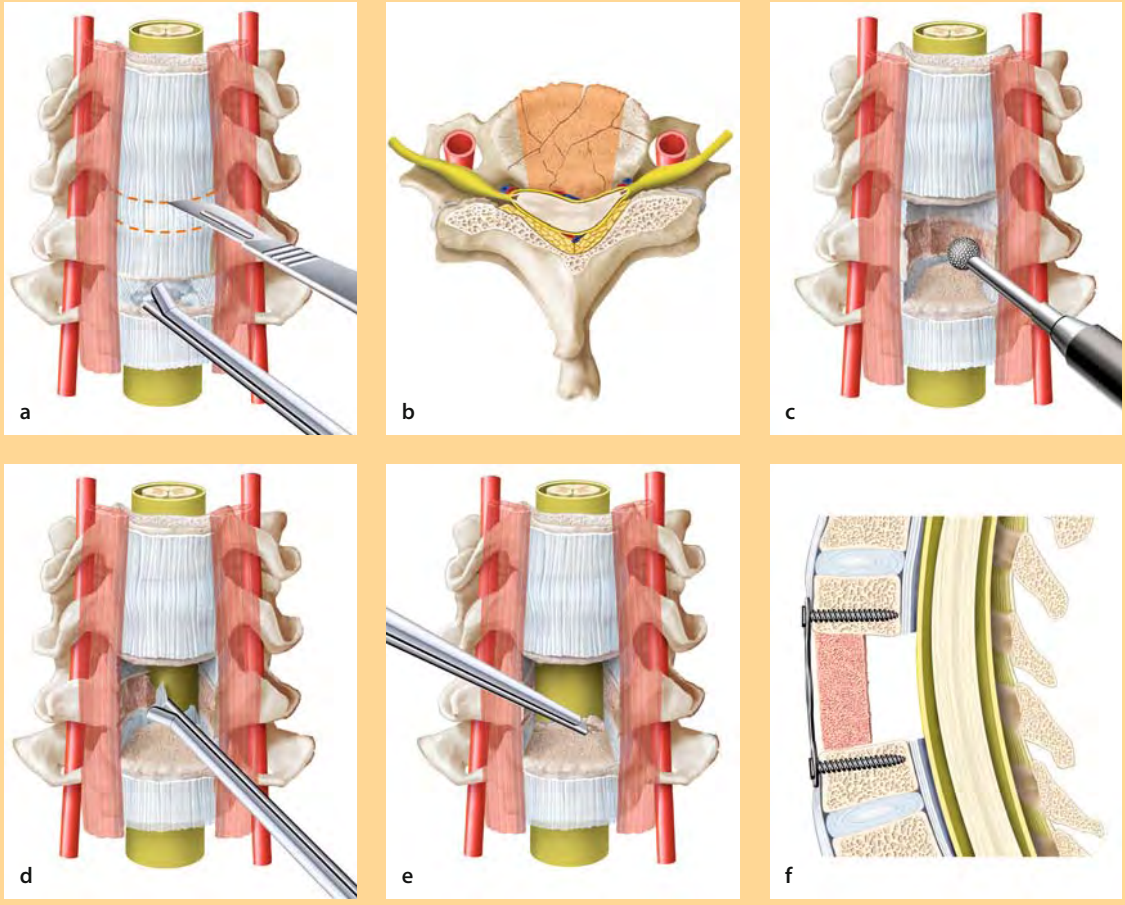


**Figure 21. Technique of corpectomy and instrumented fusion**

The cervical spine is exposed by an anteromedial approach. **a** The intervertebral discs are excised adjacent to the fractured vertebral level. **b** The medial three-fifths of the fractured vertebral body is resected. The lateral wall is preserved to protect the vertebral arteries. **c** A high-speed diamond burr is used to remove the median part of the vertebral body. Care must be taken not to push the vertebral wall against the spinal cord during this preparation. **d** The remaining part of the posterior vertebral wall is elevated away from the spinal cord and resected with a Kerrison rongeur. **e** Kerrison rongeur and curettes are used to remove posterior osteophytes and decompress spinal cord and exiting nerve roots. **f** The spine is reconstructed by insertion of a tricortical iliac bone block and anterior plating.

fusion techniques using lateral mass plates or screw-rod fixation systems (Fig. 20). **Combined anterior posterior approaches** are necessary in cases with:

- irreducible facet joint dislocations
- remote fracture dislocations with evidence of osseous/fibrous fusion
- very unstable fractures (e.g., bilateral facet joint dislocations)

Although patients with persistent or recurrent cervical spinal malalignment often achieve spinal stability with either external immobilization or surgical fusion, many of these "malaligned" patients have residual cervical pain when compared to similarly treated patients for whom anatomical spinal alignment could be achieved and maintained.

## Management Recommendations

In a systematic review of subaxial spinal injuries published in 2002 [11], 42 articles were identified that include sufficient information on the treatment of patients with subaxial injuries with or without facet joint dislocation. Standards of care or widely accepted guidelines could not be derived from the literature [11]. In view of the lack of scientific evidence, the authors feel that a pragmatic approach related to the fracture types is reasonable. However, we want to acknowledge that this approach is anecdotal but appears to provide a satisfactory outcome in a large trauma referral center.

Standards of care cannot derived from the scientific literature

### *Type A Injuries*

In **Type A1** (impaction fractures) stability is not impaired and these injuries can usually be treated conservatively with a rigid collar. The upper limit of a tolerable kyphosis is not known. Deformities of 15°–20° or more should be considered for operative stabilization with anterior cervical fusion [11, 12, 14]. Similarly, **Type A2** injuries (split fractures) can usually be treated conservatively. Frontal split fractures should be treated operatively in the presence of [11]:

Type A fractures can usually be treated conservatively

- neurological symptoms
- dislocation of a posterior vertebral fragment
- substantial kyphosis

"Simple" burst fractures (**Type A3**), i.e., without neurological impairment or significant compromise of the spinal canal, can usually be reduced with traction and immobilized in a halo for 3 months. A loss of correction occurs and in some cases late instability may develop. Therefore, we prefer a corpectomy and reconstruction of the anterior column with a tricortical bone graft and plate fixation (Fig. 21).

### *Type B Injuries*

Pure distraction injuries (**Type B1**) can be treated conservatively with a rigid collar in the absence of [11]:

- neurological deficits
- significant injuries of the anterior column

Conservative treatment results in a considerable number of late discoligamentous instabilities. Therefore, we prefer an operative treatment (anterior or posterior instrumented fusion) because it shortens the treatment duration. In the case of a **"tear-drop" injury** [170], corpectomy, two-level interbody fusion and plate fixation is indicated (Fig. 21). Transosseous disruption or ruptures of the dorsal ligament complex combined with bony defects of the anterior column (**Type B2**) are very unstable fractures and should therefore be treated operatively [11]. Because of their instability, hyperextension injuries (**Type B3**) are usually treated operatively with an anterior interbody fusion and plating [11].

Type B fractures frequently require operative treatment

### *Type C Injuries*

Rotational injuries are considered very unstable and are therefore usually treated operatively [31]. A combined anterior/posterior technique (Case Study 3) provides the best outcome although in selected cases (e.g., unilateral dislocation/fractures) either a single anterior or posterior approach may suffice.

Type C injuries should be treated operatively

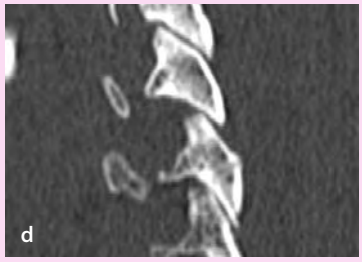


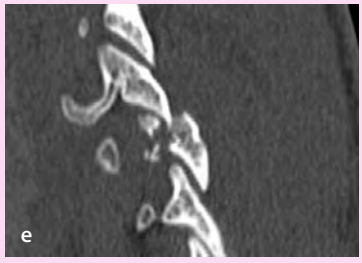

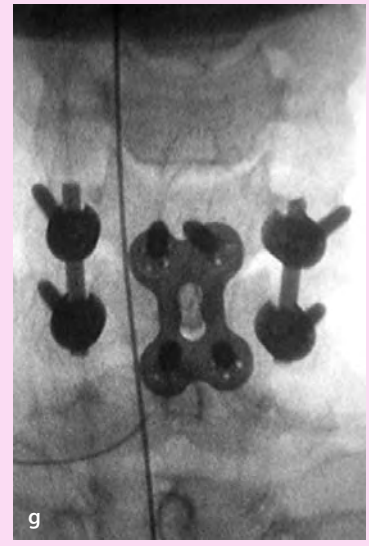


## Case Study 3

This 46-year-old female patient had a skiing accident and complained about neck pain associated with radicular pain in the right arm. She demonstrated no signs of a spinal cord injury (ASIA E) but radicular neurological symptoms at the level C5/C6. Standard lateral (a) and anteroposterior (b) radiographs demonstrated a malalignment of C5/C6, indicating a flexion injury at this level. The sagittal CT reconstruction (c) confirmed the diagnosis of the Type C flexion injury with rotation, the facet subluxation on the left (d) and unilateral facet fracture with luxation on the right side (e). In a dorsoventral approach, the nerve root on the right side was decompressed, the facet joints C5/C6 were reduced and stabilized with a lateral mass screw/rod construct, and the ruptured disc C5/C6 was removed through an anterior approach, replaced with a tricortical iliac crest bone graft and stabilized with an anterior plate. Standard intraoperative lateral (f) and anteroposterior (g) radiographs demonstrate a correct reposition and an appropriate alignment.

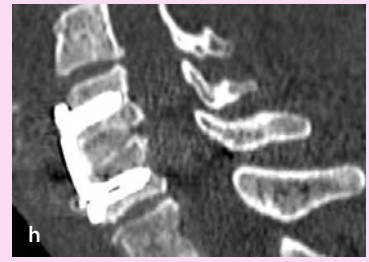


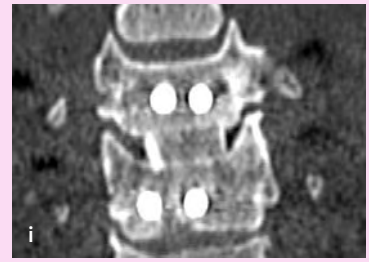

**Case Study 3** (*Cont.*)

The postoperative CT scans (h–k) demonstrate the correct position of the bone graft and the hardware, the reposition of the left-sided subluxation and the right-sided luxation of the facet joints C5/C6. The radicular pain disappeared after the surgical decompression and stabilization.

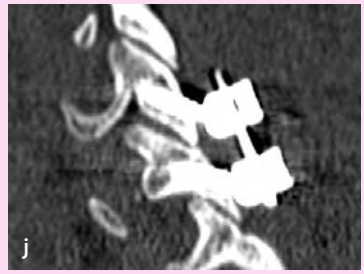


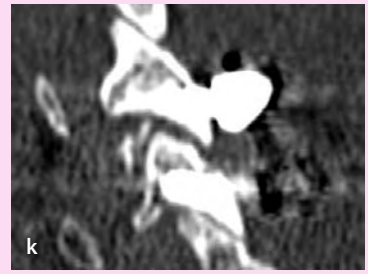


## Complications

Overall, 5 % of patients with compressive injuries of the subaxial cervical spine had persistent instability after non-operative treatment (i.e., immobilization for 8 – 12 weeks) [38, 39, 46, 79, 80, 132, 134, 151]. In contrast, nearly every patient treated with anterior (100 %, 22 of 22 patients) or posterior (96 %, 26 of 27 patients) fusion procedures developed a solid fusion [14, 22, 71]. Kyphosis or subluxation develops in about 10 % of patients who are treated with posterior fusion [38, 71]. Operative complications are more common in patients treated with posterior fusion procedures (37 %) compared with anterior fusion procedures (9 %) [14, 22, 66, 71]. Graft displacement is the most common complication found in patients treated with anterior cervical fusion **without** internal fixation (9 %) [14, 66].

## Recapitulation

**Epidemiology.** Cervical spine injuries account for one-third of all spinal injuries and occur in 2 – 5 % of trauma patients. The C2, C5 and C6 and C6/C7 are the most commonly injured vertebrae. **Head-injured patients** with an initial Glasgow Coma Scale score of less than 9 are at highest risk of concomitant cervical spine injury. Ten percent of spine trauma patients present with a neurological injury. **Whiplash injury** and whiplash associated disorder (**WAD**) must be differentiated. WADs tend to become chronic. The number is steadily increasing.

**Pathomechanism.** Functionally, the cervical spine is divided into the upper cervical spine [occiput (C0)–C1–C2] and the lower (subaxial) cervical spine (C3–C7). **Burst fractures** (Jefferson) of the atlas ring can be created by axial loading in slight extension. **Dens fractures** result from a combination of horizontal shear and vertical compression. Extension-distraction can result in a **traumatic spondylolisthesis** of the axial pedicle. Injuries to the lower cervical spine or the spinal cord usually occur indirectly as the result of a blow to the head or from rapid head deceleration and can be differentiated as compression, distraction and rotation injuries. The definition of spinal instability remains enigmatic. Primary and secondary mechanisms play an important role in **spinal cord injury**. The exact pathomechanism of WAD remains unclear but a mild brain injury is highly unlikely. Late whiplash syndrome resembles the feature of a chronic pain syndrome.

**Clinical presentation.** The assessment of **vital and neurological functions** is key in cervical spine injuries. The onset and time course of the neurological deficit is important for the prognosis (acute vs. subacute). There is a large variety of symptoms in patients with cervical strains/sprains due to rear-end collision. **Cognitive functions** are often impaired in late whiplash syndrome. A **latent unstable spine** must be considered and excluded prior to a functional testing. A thorough neurological assessment is mandatory.

**Diagnostic work-up.** Polytraumatized and head injury patients must be considered to have sustained a cervical spine injury until proven otherwise. **Standard radiography** is indicated in cervical injuries according to the **Canadian C-Spine Rule** or **NEXUS criteria**. **Oblique views** are safer and often more in-

formative than swimmer views for the assessment of the thoracocervical spine. The **radiological ABC** is helpful for image interpretation. Failure to adequately visualize the region of injury is the most common cause of missed cervical spine injury. The lateral view should extend from the occiput to C7/T1. There is increasing evidence that **CT** scans should replace cervical spine radiographs. **MRI** allows the assessment of soft tissue injury of the cord, discs, and ligaments. The usefulness of pre-reduction MRI in awake patients is uncertain. Injuries to the vertebral arteries must be ruled out. **Neurophysiological assessments** are indicative of the prognosis.

**General treatment principles.** Patients with a cervical sprain/strain or whiplash injury should be treated with reassurance about the absence of serious pathology (after diagnostic assessment), education on prognosis, early return to normal activities and physical exercises and manipulation (if needed). The **conservative armamentarium** consists of Philadelphia collar, traction, halo vest and Minerva cast. Secondary SCI due to additional fracture/dislocation must be avoided. The role of steroids in acute spinal cord trauma is controversial. Many centers are revising the guidelines to limit or discontinue the use of methylprednisolone. **High-dose methylprednisolone** is highly controversial in acute SCI and is only considered in young patients with a monotrauma of the spine without significant comorbidities. The **timing of decompressive surgery** is not well supported by the literature. However, urgent fracture/reduction and decompression is indicated in patients with incomplete or progressive tetraplegia and persistent spinal cord compression. Even delayed decompression may lead to recovery of injury-related neurological dysfunctions.

**Specific treatment.** Occipital condyle fractures are rare and require CT scan imaging. Treatment of occipital condyle fracture with external immobilization is recommended. **Atlanto-occipital dislocation** is a rare and often fatal traumatic injury. AOD must be ruled out before applying traction. Stable atlas fractures can be treated conservatively while unstable **atlas fracture** (e.g., Jefferson burst fracture) should be treated by C1/2 or Judet screw fixation. **Atlantoaxial instabilities** are relatively common in patients with rheumatoid arthritis but relatively rare after trauma. Complete bilateral dislocation of the articular processes can narrow the neural canal and subsequently damage the spinal cord. In approximately 50% of all atlantoaxial rotatory subluxations, the transverse ligament is intact. Reduction followed by posterior fusion is the treatment of choice for atlantoaxial instabilities. Recurrent or irreducible luxations of atlantoaxial rotatory subluxations are treated by atlantoaxial fusion. **Odontoid fractures** are classified according to Anderson d'Alonzo into three types: tip of the dens portion (Type I), base of the odontoid process (Type II) and axial body fractures (Type III). Type IIA fractures are comminuted fractures of the base and are associated with severe instability. Optimal treatment for odontoid fractures remains controversial. Cervical collar is a treatment option for Type I and Type III odontoid fractures. Traction and cervical collar is inappropriate for Type II odontoid fractures. Anterior screw fixation should be considered in Type II odontoid fractures and intact transverse atlantal ligament within 6 months after the injury. Type IIA fractures should be considered for early posterior surgical fixation and fusion of C1–C2. Type II odontoid fractures in patients 50 years and older should be considered for posterior instrumented fusion. **Traumatic spondylolisthesis of the axis** (hangman's fractures) is commonly classified according to Effendi into three types: minimal displacement, displacement of the anterior fragment with disruption of the disc space, and displacement with C2–C3 facet dislocation. Most hangman's fractures heal with 12 weeks of cervical immobilization with either rigid cervical collar or halo immobilization. Surgical stabilization of traumatic spondylolisthesis has to be considered in Type II fractures with severe angulation and disruption of the C2–C3 disc space, Type II with facet dislocation or when maintaining fracture alignment with external immobilization is not possible. In fractures of the **axis body**, external immobilization is suggested as the initial treatment strategy. The characteristics of the axis fracture commonly dictate the management of a combination fracture injury of C1–C2.

Approximately 80% of all cervical spine injuries are localized in the lower cervical spine. Subaxial cervical spine fractures can be classified into **Type A** (compression), **Type B** (distraction) and **Type C** (rotation) injuries. Facet dislocation injuries require open or closed reduction and adequate fixation with rigid external or internal fixation. Stable undisplaced Type A injuries of the lower cervical spine can be treated conservatively. Unstable Type B and Type C injuries should be treated operatively. Indi-

cations for surgical treatment for lower cervical spine injuries include irreducible spinal cord compression, ligamentous injury with facet instability, spinal kyphotic deformity of more than 15°, vertebral body fracture compression of 40% or more, vertebral subluxation of 20% or more, failure to achieve anatomical reduction (irreducible injury), persistent instability with failure to maintain reduction, and ligamentous injury with facet instability. Most lower cervical spine injuries can be treated by an **anterior approach**. Anterior fusion should not be performed without plate fixation.

## Key Articles

**Aebi M, Mohler J, Zach GA, Morscher E (1986) Indication, surgical technique, and results of 100 surgically-treated fractures and fracture-dislocations of the cervical spine. Clin Orthop Relat Res:244–57**
The author analyzes the results of 100 cervical spinal injuries that were treated operatively and demonstrates that immediate reduction of the injury is more important for the further neurological outcome than improved surgical techniques.

**Aebi M, Nazarian S (1987) Classification of injuries of the cervical spine. Orthopaede 16:27–36**
The authors propose a classification system of the cervical spine, which draws on the principles of classification suggested by the ASIF for fractures of the extremities in Type A, Type B and Type C injuries. Injuries are divided into those of the upper and those of the lower cervical spine. Beyond this, injuries are subdivided with reference to whether they affect primarily bone, bone and ligament equally, or primarily ligament.

**Aebi M, Zuber K, Marchesi D (1991) Treatment of cervical spine injuries with anterior plating. Indications, techniques, and results. Spine 16:S38–45**
The paper analyzed 86 patients who sustained a cervical spine injury and who had 93 anterior surgical interventions of the cervical spine. The authors demonstrate that the technique of anterior bone grafting and plating is shown to be straightforward, atraumatic, and reliable for predominantly anterior lesions as well as for posterior injuries. Furthermore, the clinical experiences do not support experimental data and earlier clinical work, which advocate posterior surgery over anterior surgery and assert that anterior surgery should not be done in predominantly posterior lesions.

**Anderson LD, D'Alonzo RT (1974) Fractures of the odontoid process of the axis. J Bone Joint Surg Am 56(8):1663–74**
The authors describe three types of odontoid fractures: Type I: oblique fractures through the upper portion of the odontoid process; Type II: across the base of the odontoid process at the junction with the axis body; Type III: through the odontoid that extends into the C2 body.

**Davis JW, Phreaner DL, et al. (1993) The etiology of missed cervical spine injuries. J Trauma 34(3):342–6**
The authors describe 32 117 trauma patients and analyzed the etiology of missed C-spine injuries. Cervical spine injuries were identified in 740 patients and the diagnosis was delayed or missed in 34 patients (4.6%). The single most common error was the failure to obtain an adequate series of C-spine roentgenograms.

**Effendi B, Roy D, Cornish B, Dussault RG, Laurin CA (1981) Fractures of the ring of the axis: A classification based on the analysis of 131 cases. J Bone Joint Surg Br 63B:319–27**
The paper describes three types of fractures of the ring of the axis based on a series of 131 patients. Their classification was based on the mechanism of injury: Type I, axial loading and hyperextension; Type II, hyperextension and rebound flexion; Type III, primary flexion and rebound extension.

**Kahn EA, Schneider RC (1956) Chronic neurological sequelae of acute trauma to the spine and spinal cord. I. The significance of the acute-flexion or tear-drop fracture-dislocation of the cervical spine. J Bone Joint Surg Am 38A:985–97**
Classic article on the significance of tear-drop fracture and neurological fracture-related spinal cord injury.

## References


1. American Association of Neurological Surgeons (2002) Diagnosis and management of traumatic atlanto-occipital dislocation injuries. Neurosurgery 50:S105 – 13
2. American Association of Neurological Surgeons (2002) Guidelines for the management of acute cervical spine injuries. Neurosurgery 50:Siv–v
3. American Association of Neurological Surgeons (2002) Initial closed reduction of cervical spine fracture-dislocation injuries. Neurosurgery 50:S44 – 50
4. American Association of Neurological Surgeons (2002) Isolated fractures of the atlas in adults. Neurosurgery 50:S120 – 4
5. American Association of Neurological Surgeons (2002) Isolated fractures of the axis in adults. Neurosurgery 50:S125 – 39
6. American Association of Neurological Surgeons (2002) Management of acute central cervical spinal cord injuries. Neurosurgery 50:S166 – 72
7. American Association of Neurological Surgeons (2002) Management of combination fractures of the atlas and axis in adults. Neurosurgery 50:S140 – 7
8. American Association of Neurological Surgeons (2002) Occipital condyle fractures. Neurosurgery 50:S114 – 9
9. American Association of Neurological Surgeons (2002) Radiographic assessment of the cervical spine in asymptomatic trauma patients. Neurosurgery 50:S30 – 5
10. American Association of Neurological Surgeons (2002) Radiographic assessment of the cervical spine in symptomatic trauma patients. Neurosurgery 50:S36 – 43
11. American Association of Neurological Surgeons (2002) Treatment of subaxial cervical spinal injuries. Neurosurgery 50:S156 – 65
12. Aebi M, Mohler J, Zach GA, Morscher E (1986) Indication, surgical technique, and results of 100 surgically-treated fractures and fracture-dislocations of the cervical spine. Clin Orthop Relat Res:244 – 57
13. Aebi M, Nazarian S (1987) Classification of injuries of the cervical spine. Orthopaede 16:27 – 36
14. Aebi M, Zuber K, Marchesi D (1991) Treatment of cervical spine injuries with anterior plating. Indications, techniques, and results. Spine 16:S38 – 45
15. Alker GJ, Oh YS, Leslie EV, Lehotay J, Panaro VA, Eschner EG (1975) Postmortem radiology of head neck injuries in fatal traffic accidents. Radiology 114:611 – 7
16. Allen BL, Jr., Ferguson RL, Lehmann TR, O'Brien RP (1982) A mechanistic classification of closed, indirect fractures and dislocations of the lower cervical spine. Spine 7:1 – 27
17. Allen RL, Perot PL, Jr., Gudeman SK (1985) Evaluation of acute nonpenetrating cervical spinal cord injuries with CT metrizamide myelography. J Neurosurg 63:510 – 20
18. Altoff B (1979) Fractures of the odontoid process. An experimental and clinical study. Acta Orthop Scand (Suppl) 177:1 – 95
19. Anderson LD, D'Alonzo RT (1974) Fractures of the odontoid process of the axis. J Bone Joint Surg Am 56:1663 – 74
20. Anderson PA (2004) Injuries to the upper cervical spine. In: Frymoyer JW, Wiesel SM (eds) The adult & pediatric spine. Lippincott Williams & Wilkins, Philadelphia, pp 633 – 57
21. Anderson PA, Bohlman HH (1992) Anterior decompression and arthrodesis of the cervical spine: long-term motor improvement. Part II – Improvement in complete traumatic quadriplegia. J Bone Joint Surg Am 74:683 – 92
22. Anderson PA, Henley MB, Grady MS, Montesano PX, Winn HR (1991) Posterior cervical arthrodesis with AO reconstruction plates and bone graft. Spine 16:S72 – 9
23. Anderson PA, Montesano PX (1988) Morphology and treatment of occipital condyle fractures. Spine 13:731 – 6
24. Andersson S, Rodrigues M, Olerud C (2000) Odontoid fractures: high complication rate associated with anterior screw fixation in the elderly. Eur Spine J 9:56 – 9
25. Apfelbaum RI, Lonser RR, Veres R, Casey A (2000) Direct anterior screw fixation for recent and remote odontoid fractures. J Neurosurg 93:227 – 36
26. Banic B, Petersen-Felix S, Andersen OK, Radanov BP, Villiger PM, Arendt-Nielsen L, Curatolo M (2004) Evidence for spinal cord hypersensitivity in chronic pain after whiplash injury and in fibromyalgia. Pain 107:7 – 15
27. Bauze RJ, Ardran GM (1978) Experimental production of forward dislocation in the human cervical spine. J Bone Joint Surg Br 60B:239 – 45
28. Bell C (1817) Surgical observations. Middlesex Hosp J 4:469
29. Biffl WL, Moore EE, Elliott JP, Ray C, Offner PJ, Franciose RJ, Brega KE, Burch JM (2000) The devastating potential of blunt vertebral arterial injuries. Ann Surg 231:672 – 81
30. Blauth M, Kathrein A, Mair G, Schmid R, Reinhold M, Rieger M (2007) Classification of injuries of the subaxial cervical spine. In: Aebi M, Arlet V, Webb JK (eds) AO Spine Manual: clinical applications, vol 2. Thieme, Stuttgart, pp 21 – 38
31. Blauth M, Knop C, Bastian L (1998) Wirbelsäule. In: Tscherne H, Blauth M (ed) Unfallchirurgie. Springer, Heidelberg, pp 241 – 381

32. Bohlman HH (1979) Acute fractures and dislocations of the cervical spine. An analysis of three hundred hospitalized patients and review of the literature. J Bone Joint Surg Am 61:1119 – 42
33. Bohlman HH, Anderson PA (1992) Anterior decompression and arthrodesis of the cervical spine: long-term motor improvement. Part I – Improvement in incomplete traumatic quadriparesis. J Bone Joint Surg Am 74:671 – 82
34. Bohlman HH, Kirkpatrick JS, Delamarter RB, Leventhal M (1994) Anterior decompression for late pain and paralysis after fractures of the thoracolumbar spine. Clin Orthop Relat Res:24 – 9
35. Bracken MB (2002) Steroids for acute spinal cord injury. Cochrane Database Syst Rev: CD001046
36. Bracken MB, Shepard MJ, Collins WF, Holford TR, Young W, Baskin DS, Eisenberg HM, Flamm E, Leo-Summers L, Maroon J, et al. (1990) A randomized, controlled trial of methylprednisolone or naloxone in the treatment of acute spinal-cord injury. Results of the Second National Acute Spinal Cord Injury Study. N Engl J Med 322:1405 – 11
37. Bradbury EJ, McMahon SB (2006) Spinal cord repair strategies: why do they work? Nat Rev Neurosci 7:644 – 53
38. Bucholz RD, Cheung KC (1989) Halo vest versus spinal fusion for cervical injury: evidence from an outcome study. J Neurosurg 70:884 – 92
39. Burke JT, Harris JH, Jr. (1989) Acute injuries of the axis vertebra. Skeletal Radiol 18:335 – 46
40. Cabot A, Becker A (1978) The cervical spine in rheumatoid arthritis. Clin Orthop Relat Res 131:130 – 40
41. Carroll LJ, Cassidy JD, Cote P (2006) Frequency, timing, and course of depressive symptomatology after whiplash. Spine 31:E551 – 6
42. Carroll LJ, Cassidy JD, Cote P (2006) The role of pain coping strategies in prognosis after whiplash injury: passive coping predicts slowed recovery. Pain 124:18 – 26
43. Carroll LJ, Holm LW, Hogg-Johnson S, Cote P, Cassidy JD, Haldeman S, Nordin M, Hurwitz E, Carragee EJ, van der Velde G, Peloso P, Guzman J (2008) Course and prognostic factors for neck pain in whiplash-associated disorders (WAD). Results of the Bone and Joint Decade 2000 – 2010 Task Force on Neck Pain and Its Associated Disorders. Spine 33 (Suppl): S83–S92
44. Cassidy JD, Carroll LJ, Cote P, Lemstra M, Berglund A, Nygren A (2000) Effect of eliminating compensation for pain and suffering on the outcome of insurance claims for whiplash injury. N Engl J Med 342:1179 – 86
45. Castro WH, Schilgen M, Meyer S, Weber M, Peuker C, Wortler K (1997) Do "whiplash injuries" occur in low-speed rear impacts? Eur Spine J 6:366 – 75
46. Cheshire DJ (1969) The stability of the cervical spine following the conservative treatment of fractures and fracture-dislocations. Paraplegia 7:193 – 203
47. Chiba K, Fujimura Y, Toyama Y, Fujii E, Nakanishi T, Hirabayashi K (1996) Treatment protocol for fractures of the odontoid process. J Spinal Disord 9:267 – 76
48. Chiu WC, Haan JM, Cushing BM, Kramer ME, Scalea TM (2001) Ligamentous injuries of the cervical spine in unreliable blunt trauma patients: incidence, evaluation, and outcome. J Trauma 50:457 – 63; discussion 464
49. Clark CR, White AA, 3rd (1985) Fractures of the dens. A multicenter study. J Bone Joint Surg Am 67:1340 – 8
50. Clark WM, Gehweiler JA, Laib R (1979) Twelve significant signs of cervical spine trauma. Skeletal Radiol 3:201 – 5
51. Corner EM (1907) Rotary dislocations of the atlas. Ann Surg 45:9 – 26
52. Cote P, Cassidy JD, Carroll L, Frank JW, Bombardier C (2001) A systematic review of the prognosis of acute whiplash and a new conceptual framework to synthesize the literature. Spine 26:E445 – 58
53. Cotler JM, Herbison GJ, Nasuti JF, Ditunno JF, Jr., An H, Wolff BE (1993) Closed reduction of traumatic cervical spine dislocation using traction weights up to 140 pounds. Spine 18:386 – 90
54. Coutts M (1934) Rotary dislocations of the atlas. Ann Surg 29:297 – 311
55. Crowe H (1964) A new diagnostic sign in neck injuries. Calif Med 100:12 – 3
56. Curatolo M, Arendt-Nielsen L, Petersen-Felix S (2004) Evidence, mechanisms, and clinical implications of central hypersensitivity in chronic pain after whiplash injury. Clin J Pain 20:469 – 76
57. Curt A, Dietz V (1999) Neurologic recovery in SCI. Arch Phys Med Rehabil 80:607 – 8
58. Curt A, Keck ME, Dietz V (1998) Functional outcome following spinal cord injury: significance of motor-evoked potentials and ASIA scores. Arch Phys Med Rehabil 79:81 – 6
59. Curt A, Rodic B, Schurch B, Dietz V (1997) Recovery of bladder function in patients with acute spinal cord injury: significance of ASIA scores and somatosensory evoked potentials. Spinal Cord 35:368 – 73
60. Daffner RH (2005) Controversies in cervical spine imaging in trauma patients. Semin Musculoskelet Radiol 9:105 – 15

61. Davis JW, Phreaner DL, Hoyt DB, Mackersie RC (1993) The etiology of missed cervical spine injuries. J Trauma 34:342 – 6
62. De Beer JD, Thomas M, Walters J, Anderson P (1988) Traumatic atlanto-axial subluxation. J Bone Joint Surg Br 70:652 – 5
63. Deliganis AV, Baxter AB, Hanson JA, Fisher DJ, Cohen WA, Wilson AJ, Mann FA (2000) Radiologic spectrum of craniocervical distraction injuries. Radiographics 20 Spec No:S237 – 50
64. Demetriades D, Charalambides K, Chahwan S, Hanpeter D, Alo K, Velmahos G, Murray J, Asensio J (2000) Nonskeletal cervical spine injuries: epidemiology and diagnostic pitfalls. J Trauma 48:724 – 7
65. Ditunno JF, Little JW, Tessler A, Burns AS (2004) Spinal shock revisited: a four-phase model. Spinal Cord 42:383 – 95
66. Dorr LD, Harvey JP, Jr., Nickel VL (1982) Clinical review of the early stability of spine injuries. Spine 7:545 – 50
67. Dvorak J, Panjabi M, Gerber M, Wichmann W (1987) CT-functional diagnostics of the rotatory instability of upper cervical spine. 1. An experimental study on cadavers. Spine 12:197 – 205
68. Dvorak J, Penning L, Hayek J, Panjabi MM, Grob D, Zehnder R (1988) Functional diagnostics of the cervical spine using computer tomography. Neuroradiology 30:132 – 7
69. Dvorak J, Schneider E, Saldinger P, Rahn B (1988) Biomechanics of the craniocervical region: the alar and transverse ligaments. J Orthop Res 6:452 – 61
70. Effendi B, Roy D, Cornish B, Dussault RG, Laurin CA (1981) Fractures of the ring of the axis. A classification based on the analysis of 131 cases. J Bone Joint Surg Br 63B:319 – 27
71. Fehlings MG, Cooper PR, Errico TJ (1994) Posterior plates in the management of cervical instability: long-term results in 44 patients. J Neurosurg 81:341 – 9
72. Fehlings MG, Perrin RG (2005) The role and timing of early decompression for cervical spinal cord injury: update with a review of recent clinical evidence. Injury 36 Suppl 2:B13 – 26
73. Fielding JW, Cochran GB, Lawsing JF, 3rd, Hohl M (1974) Tears of the transverse ligament of the atlas. A clinical and biomechanical study. J Bone Joint Surg Am 56:1683 – 91
74. Fielding JW, Hawkins RJ (1977) Atlanto-axial rotatory fixation. (Fixed rotatory subluxation of the atlanto-axial joint). J Bone Joint Surg Am 59:37 – 44
75. Fielding JW, Hawkins RJ, Hensinger RN, Francis WR (1978) Atlantoaxial rotary deformities. Orthop Clin North Am 9:955 – 67
76. Fielding JW, Hensinger RN, Hawkins RJ (1980) Os odontoideum. J Bone Joint Surg Am 62:376 – 83
77. Fisher CG, Dvorak MF, Leith J, Wing PC (2002) Comparison of outcomes for unstable lower cervical flexion teardrop fractures managed with halo thoracic vest versus anterior corpectomy and plating. Spine 27:160 – 6
78. Francis WR, Fielding JW, Hawkins RJ, Pepin J, Hensinger R (1981) Traumatic spondylolisthesis of the axis. J Bone Joint Surg Br 63B:313 – 8
79. Frankel H, Michaelis L, Paeslack V (1973) Closed injuries of the cervical spine and spinal cord: results of conservative treatment of extension rotation injuries of the cervical spine with tetraplegia. Proc Veterans Adm Spinal Cord Inj Conf:52 – 5
80. Frankel H, Michaelis L, Paeslack V, Ungar G, Walsh JJ (1973) Closed injuries of the cervical spine and spinal cord: results of conservative treatment of vertical compression injuries of the cervical spine. Proc Veterans Adm Spinal Cord Inj Conf:28 – 32
81. Frankel HL, Hancock DO, Hyslop G, Melzak J, Michaelis LS, Ungar GH, Vernon JD, Walsh JJ (1969) The value of postural reduction in the initial management of closed injuries of the spine with paraplegia and tetraplegia. I. Paraplegia 7:179 – 92
82. Fuentes JM, Bloncourt J, Vlahovitch B, Castan P (1983) Tear drop fractures. Contribution to the study of the mechanism of osteo-disco-ligamentous lesions. Neurochirurgie 29:129 – 34
83. Fujimura Y, Nishi Y, Kobayashi K (1996) Classification and treatment of axis body fractures. J Orthop Trauma 10:536 – 40
84. Galandiuk S, Raque G, Appel S, Polk HC, Jr. (1993) The two-edged sword of large-dose steroids for spinal cord trauma. Ann Surg 218:419 – 25; discussion 425 – 7
85. Garber JN (1964) Abnormalities of the atlas and axis vertebrae – congenital and traumatic. J Bone Joint Surg Am 46:1782 – 91
86. Gerndt SJ, Rodriguez JL, Pawlik JW, Taheri PA, Wahl WL, Micheals AJ, Papadopoulos SM (1997) Consequences of high-dose steroid therapy for acute spinal cord injury. J Trauma 42:279 – 84
87. Gerrelts BD, Petersen EU, Mabry J, Petersen SR (1991) Delayed diagnosis of cervical spine injuries. J Trauma 31:1622 – 6
88. Giannoudis PV, Mehta SS, Tsiridis E (2007) Incidence and outcome of whiplash injury after multiple trauma. Spine 32:776 – 81
89. Goldberg W, Mueller C, Panacek E, Tigges S, Hoffman JR, Mower WR (2001) Distribution and patterns of blunt traumatic cervical spine injury. Ann Emerg Med 38:17 – 21
90. Grant GA, Mirza SK, Chapman JR, Winn HR, Newell DW, Jones DT, Grady MS (1999) Risk of early closed reduction in cervical spine subluxation injuries. J Neurosurg 90:13 – 8

91. Greene KA, Dickman CA, Marciano FF, Drabier JB, Hadley MN, Sonntag VK (1997) Acute axis fractures. Analysis of management and outcome in 340 consecutive cases. Spine 22:1843 – 52
92. Griffen MM, Frykberg ER, Kerwin AJ, Schinco MA, Tepas JJ, Rowe K, Abboud J (2003) Radiographic clearance of blunt cervical spine injury: plain radiograph or computed tomography scan? J Trauma 55:222 – 6; discussion 226 – 7
93. Guzman J, Haldeman S, Carroll LJ, Carragee EJ, Hurwitz EL, Peloso P, Nordin M, Cassidy JD, Holm LW, Cote P, van der Velde G, Hogg-Johnson S (2008) Clinical practice implications of the Bone and Joint Decade 2000 – 2010 Task Force on Neck Pain and Its Associated Disorders. From Concepts and findings to recommendations. Spine 33 (Suppl):S199–S213
94. Hadley MN, Browner CM, Liu SS, Sonntag VK (1988) New subtype of acute odontoid fractures (type IIA). Neurosurgery 22:67 – 71
95. Hadley MN, Dickman CA, Browner CM, Sonntag VK (1988) Acute traumatic atlas fractures: management and long term outcome. Neurosurgery 23:31 – 5
96. Harms J, Melcher RP (2001) Posterior C1–C2 fusion with polyaxial screw and rod fixation. Spine 26:2467 – 71
97. Harrington JF, Jr., Park MC (2007) Single level arthrodesis as treatment for midcervical fracture subluxation: a cohort study. J Spinal Disord Tech 20:42 – 8
98. Hasse W, Weidtmann A, Voeltz P (2000) [Lactic acidosis: a complication of spinal cord injury in multiple trauma]. Unfallchirurg 103:495 – 8
99. Hays MB, Bernhang AM (1992) Fractures of the atlas vertebra. A three-part fracture not previously classified. Spine 17:240 – 2
100. Heary RF, Vaccaro AR, Mesa JJ, Northrup BE, Albert TJ, Balderston RA, Cotler JM (1997) Steroids and gunshot wounds to the spine. Neurosurgery 41:576 – 83; discussion 583 – 4
101. Hecht A, Silcox D, Whitesides T (2003) Injuries of the cervicocranium. In: Browner: Skeletal trauma: Basic science, management, and reconstruction, 3rd edn. Saunders, Philadelphia, pp 777 – 813
102. Heller JG, Viroslav S, Hudson T (1993) Jefferson fractures: the role of magnification artifact in assessing transverse ligament integrity. J Spinal Disord 6:392 – 6
103. Herren-Gerber R, Weiss S, Arendt-Nielsen L, Petersen-Felix S, Di Stefano G, Radanov BP, Curatolo M (2004) Modulation of central hypersensitivity by nociceptive input in chronic pain after whiplash injury. Pain Med 5:366 – 76
104. Hildingsson C, Toolanen G (1990) Outcome after soft-tissue injury of the cervical spine. A prospective study of 93 car-accident victims. Acta Orthop Scand 61:357 – 9
105. Hoffman JR, Mower WR, Wolfson AB, Todd KH, Zucker MI (2000) Validity of a set of clinical criteria to rule out injury to the cervical spine in patients with blunt trauma. National Emergency X-Radiography Utilization Study Group. N Engl J Med 343:94 – 9
106. Holly LT, Kelly DF, Counelis GJ, Blinman T, McArthur DL, Cryer HG (2002) Cervical spine trauma associated with moderate and severe head injury: incidence, risk factors, and injury characteristics. J Neurosurg 96:285 – 91
107. Holm LW, Carroll LJ, Cassidy D, Hogg-Johnson S, Cote P, Guzman J, Peloso P, Nordin M, Hurwitz E, van der Velde G, Carragee E, Haldeman S (2008) The burden and determinants of neck pain in whiplash-associated disorders after traffic collisions: Results of the Bone and Joint Decade 2000 – 2010 Task Force on Neck Pain and Its Associated Disorders. Spine 33 (Suppl):S52–S59
108. Hu R, Mustard CA, Burns C (1996) Epidemiology of incident spinal fracture in a complete population. Spine 21:492 – 9
109. Hurlbert RJ (2006) Strategies of medical intervention in the management of acute spinal cord injury. Spine 31:S16 – 21; discussion S36
110. Ireland AJ, Britton I, Forrester AW (1998) Do supine oblique views provide better imaging of the cervicothoracic junction than swimmer's views? J Accid Emerg Med 15:151 – 4
111. Iseli E, Cavigelli A, Dietz V, Curt A (1999) Prognosis and recovery in ischaemic and traumatic spinal cord injury: clinical and electrophysiological evaluation. J Neurol Neurosurg Psychiatry 67:567 – 71
112. Jackson H (1950) The diagnosis of minimal atlanto-axial subluxation. Br J Radiol 23:672 – 4
113. Jeanneret B, Magerl F (1992) Primary posterior fusion C1/2 in odontoid fractures: indications, technique, and results of transarticular screw fixation. J Spinal Disord 5:464 – 75
114. Jefferson G (1920) Fractures of the atlas vertebra: Report of four cases and a review of those previously reported. Br J Surg 7:407 – 422
115. Jenkins JD, Coric D, Branch CL, Jr. (1998) A clinical comparison of one- and two-screw odontoid fixation. J Neurosurg 89:366 – 70
116. Johnson RM, Hart DL, Simmons EF, Ramsby GR, Southwick WO (1977) Cervical orthoses. A study comparing their effectiveness in restricting cervical motion in normal subjects. J Bone Joint Surg Am 59:332 – 9
117. Judet J, Roy-Camille R, Zerah JC, Saillant G (1970) [Fractures of the cervical spine: fracture-separation of the articular column]. Rev Chir Orthop Reparatrice Appar Mot 56: 155 – 64

118. Julien TD, Frankel B, Traynelis VC, Ryken TC (2000) Evidence-based analysis of odontoid fracture management. Neurosurg Focus 8:1 – 6
119. Koivikko MP, Myllynen P, Karjalainen M, Vornanen M, Santavirta S (2000) Conservative and operative treatment in cervical burst fractures. Arch Orthop Trauma Surg 120:448 – 51
120. Kricun M (1988) Imaging modalities in spinal disorders. WB Saunders, Philadelphia
121. Labler L, Eid K, Platz A, Trentz O, Kossmann T (2004) Atlanto-occipital dislocation: four case reports of survival in adults and review of the literature. Eur Spine J 13:172 – 80
122. Lammertse DP (2004) Update on pharmaceutical trials in acute spinal cord injury. J Spinal Cord Med 27:319 – 25
123. Larson SJ, Holst RA, Hemmy DC, Sances A, Jr. (1976) Lateral extracavitary approach to traumatic lesions of the thoracic and lumbar spine. J Neurosurg 45:628 – 37
124. Lee AS, MacLean JC, Newton DA (1994) Rapid traction for reduction of cervical spine dislocations. J Bone Joint Surg Br 76:352 – 6
125. Lennarson PJ, Mostafavi H, Traynelis VC, Walters BC (2000) Management of type II dens fractures: a case-control study. Spine 25:1234 – 7
126. Lerman JA, Dickman CA, Haynes RJ (2001) Penetration of cranial inner table with Gardner-Wells tongs. J Spinal Disord 14:211 – 3
127. Levine AM, Edwards CC (1985) The management of traumatic spondylolisthesis of the axis. J Bone Joint Surg Am 67:217 – 26
128. Levine AM, Edwards CC (1989) Traumatic lesions of the occipitoatlantoaxial complex. Clin Orthop Relat Res:53 – 68
129. Levine AM, Edwards CC (1991) Fractures of the atlas. J Bone Joint Surg Am 73:680 – 91
130. Lewis LM, Docherty M, Ruoff BE, Fortney JP, Keltner RA, Jr., Britton P (1991) Flexion-extension views in the evaluation of cervical-spine injuries. Ann Emerg Med 20:117 – 21
131. Licina P, Nowitzke AM (2005) Approach and considerations regarding the patient with spinal injury. Injury 36 Suppl 2:B2 – 12
132. Lieberman IH, Webb JK (1994) Cervical spine injuries in the elderly. J Bone Joint Surg Br 76:877 – 81
133. Lifeso RM, Colucci MA (2000) Anterior fusion for rotationally unstable cervical spine fractures. Spine 25:2028 – 34
134. Lind B, Sihlbom H, Nordwall A (1988) Halo-vest treatment of unstable traumatic cervical spine injuries. Spine 13:425 – 32
135. Louis R (1983) Surgery of the spine. Surgical anatomy and operative approaches. Springer, Heidelberg
136. Lysell E (1969) Motion in the cervical spine. An experimental study on autopsy specimens. Acta Orthop Scand: Suppl 123
137. Maiman DJ, Sances A, Jr., Myklebust JB, Larson SJ, Houterman C, Chilbert M, El-Ghatit AZ (1983) Compression injuries of the cervical spine: a biomechanical analysis. Neurosurgery 13:254 – 60
138. Malik H, Lovell M (2004) Soft tissue neck symptoms following high-energy road traffic accidents. Spine 29:E315 – 7
139. Maynard FM, Jr., Bracken MB, Creasey G, Ditunno JF, Jr., Donovan WH, Ducker TB, Garber SL, Marino RJ, Stover SL, Tator CH, Waters RL, Wilberger JE, Young W (1997) International Standards for Neurological and Functional Classification of Spinal Cord Injury. American Spinal Injury Association. Spinal Cord 35:266 – 74
140. Mayou R, Radanov BP (1996) Whiplash neck injury. J Psychosom Res 40:461 – 74
141. Menezes AH (1999) Pathogenesis, dynamics, and management of os odontoideum. Neurosurg Focus 6:e2
142. Merriam WF, Taylor TK, Ruff SJ, McPhail MJ (1986) A reappraisal of acute traumatic central cord syndrome. J Bone Joint Surg Br 68:708 – 13
143. Mills H, Horne G (1986) Whiplash – manmade disease? N Z Med J 99:373 – 4
144. Nacimiento W, Noth J (1999) What, if anything, is spinal shock? Arch Neurol 56:1033 – 5
145. Nickel VL, Perry J, Garrett A, Heppenstall M (1968) The halo. A spinal skeletal traction fixation device. J Bone Joint Surg Am 50:1400 – 9
146. Nickel VL, Perry J, Garrett A, Heppenstall M (1989) The halo. A spinal skeletal traction fixation device. In: Nickel VL, Perry J, Garrett A, Heppenstall M, 1968. Clin Orthop Relat Res:4 – 11
147. Nordgren RE, Markesbery WR, Fukuda K, Reeves AG (1971) Seven cases of cerebromedullospinal disconnection: the “locked-in” syndrome. Neurology 21:1140 – 8
148. Nordin M, Carragee EJ, Hogg-Johnson S, Weiner SS, Hurwitz EL, Peloso PM, Guzman J, van der Velde G, Carroll LJ, Holm LW, Cote P, Cassidy JD, Haldeman S (2008) Assessment of neck pain and its associated disorders: results of the Bone and Joint Decade 2000 – 2010 Task Force on Neck Pain and Its Associated Disorders. Spine 33:S101 – 22
149. Norris SH, Watt I (1983) The prognosis of neck injuries resulting from rear-end vehicle collisions. J Bone Joint Surg Br 65:608 – 11
150. Oda T, Panjabi MM, Crisco JJ, 3rd, Oxland TR (1992) Multidirectional instabilities of experimental burst fractures of the atlas. Spine 17:1285 – 90

151. Paeslack V, Frankel H, Michaelis L (1973) Closed injuries of the cervical spine and spinal cord: results of conservative treatment of flexion fractures and flexion rotation fracture dislocation of the cervical spine with tetraplegia. Proc Veterans Adm Spinal Cord Inj Conf:39 – 42
152. Pepin JW, Bourne RB, Hawkins RJ (1985) Odontoid fractures, with special reference to the elderly patient. Clin Orthop Relat Res 193:178 – 83
153. Pfirrmann CW, Binkert CA, Zanetti M, Boos N, Hodler J (2000) Functional MR imaging of the craniocervical junction. Correlation with alar ligaments and occipito-atlantoaxial joint morphology: a study in 50 asymptomatic subjects. Schweiz Med Wochenschr 130:645 – 51
154. Pfirrmann CW, Binkert CA, Zanetti M, Boos N, Hodler J (2001) MR morphology of alar ligaments and occipitoatlantoaxial joints: study in 50 asymptomatic subjects. Radiology 218:133 – 7
155. Podolsky S, Baraff LJ, Simon RR, Hoffman JR, Larmon B, Ablon W (1983) Efficacy of cervical spine immobilization methods. J Trauma 23:461 – 5
156. Polin RS, Szabo T, Bogaev CA, Replogle RE, Jane JA (1996) Nonoperative management of Types II and III odontoid fractures: the Philadelphia collar versus the halo vest. Neurosurgery 38:450 – 6; discussion 456 – 7
157. Qian T, Cai Z, Yang MS (2004) Determination of adenosine nucleotides in cultured cells by ion-pairing liquid chromatography-electrospray ionization mass spectrometry. Anal Biochem 325:77 – 84
158. Quinlan KP, Annest JL, Myers B, Ryan G, Hill H (2004) Neck strains and sprains among motor vehicle occupants – United States, 2000. Accid Anal Prev 36:21 – 7
159. Radanov BP, di Stefano G, Schnidrig A, Ballinari P (1991) Role of psychosocial stress in recovery from common whiplash [see comment]. Lancet 338:712 – 5
160. Radanov BP, Dvorak J (1996) Spine update. Impaired cognitive functioning after whiplash injury of the cervical spine. Spine 21:392 – 7
161. Radanov BP, Sturzenegger M, Di Stefano G, Schnidrig A, Aljinovic M (1993) Factors influencing recovery from headache after common whiplash. BMJ 307:652 – 5
162. Razack N, Green BA, Levi AD (2000) The management of traumatic cervical bilateral facet fracture – dislocations with unicortical anterior plates. J Spinal Disord 13:374 – 81
163. Reid DC, Henderson R, Saboe L, Miller JD (1987) Etiology and clinical course of missed spine fractures. J Trauma 27:980 – 6
164. Richards PJ (2005) Cervical spine clearance: a review. Injury 36:248 – 69; discussion 270
165. Richter D, Latta LL, Milne EL, Varkarakis GM, Biedermann L, Ekkernkamp A, Ostermann PA (2001) The stabilizing effects of different orthoses in the intact and unstable upper cervical spine: a cadaver study. J Trauma 50:848 – 54
166. Rokkanen P, Alho A, Avikainen V, Karaharju E, Kataja J, Lahdensuu M, Lepisto P, Tervo T (1974) The efficacy of corticosteroids in severe trauma. Surg Gynecol Obstet 138:69 – 73
167. Ryan MD, Taylor TK (1993) Odontoid fractures in the elderly. J Spinal Disord 6:397 – 401
168. Sauerland S, Nagelschmidt M, Mallmann P, Neugebauer EA (2000) Risks and benefits of preoperative high dose methylprednisolone in surgical patients: a systematic review. Drug Saf 23:449 – 61
169. Schmand B, Lindeboom J, Schagen S, Heijt R, Koene T, Hamburger HL (1998) Cognitive complaints in patients after whiplash injury: the impact of malingering. J Neurol Neurosurg Psychiatry 64:339 – 43
170. Schneider RC, Cherry G, Pantek H (1954) The syndrome of acute central cervical spinal cord injury; with special reference to the mechanisms involved in hyperextension injuries of cervical spine. J Neurosurg 11:546 – 77
171. Schneider RC, Kahn EA (1956) Chronic neurological sequelae of acute trauma to the cervical spine and spinal cord. J Bone Joint Surg Am 38A:985
172. Schneider RC, Livingston KE, Cave AJ, Hamilton G (1965) "Hangman's fracture" of the cervical spine. J Neurosurg 22:141 – 54
173. Schneider RC, Schemm GW (1961) Vertebral artery insufficiency in acute and chronic spinal trauma, with special reference to the syndrome of acute central cervical spinal cord injury. J Neurosurg 18:348 – 60
174. Schneider RC, Thompson JM, Bebin J (1958) The syndrome of acute central cervical spinal cord injury. J Neurol Neurosurg Psychiatry 21:216 – 27
175. Scholten-Peeters GG, Verhagen AP, Bekkering GE, van der Windt DA, Barnsley L, Oostendorp RA, Hendriks EJ (2003) Prognostic factors of whiplash-associated disorders: a systematic review of prospective cohort studies. Pain 104:303 – 22
176. Schuler TC, Kurz L, Thompson DE, Zemenick G, Hensinger RN, Herkowitz HN (1991) Natural history of os odontoideum. J Pediatr Orthop 11:222 – 5
177. Seferiadis A, Rosenfeld M, Gunnarsson R (2004) A review of treatment interventions in whiplash-associated disorders. Eur Spine J 13:387 – 97
178. Sharpe KP, Rao S, Ziogas A (1995) Evaluation of the effectiveness of the Minerva cervicothoracic orthosis. Spine 20:1475 – 9
179. Sherk HH, Nicholson JT (1970) Fractures of the atlas. J Bone Joint Surg Am 52:1017 – 24

180. Short D (2001) Is the role of steroids in acute spinal cord injury now resolved? Curr Opin Neurol 14:759 – 63
181. Skovron ML (1998) Epidemiology of whiplash. In: Gunzburg R, Szpalski M (eds) Lippincott-Raven, Philadelphia, pp 61 – 67
182. Sonntag VK, Hadley MN (1988) Nonoperative management of cervical spine injuries. Clin Neurosurg 34:630 – 49
183. Spence KF, Jr., Decker S, Sell KW (1970) Bursting atlantal fracture associated with rupture of the transverse ligament. J Bone Joint Surg Am 52:543 – 9
184. Spitzer WO, Skovron ML, Salmi LR, Cassidy JD, Duranceau J, Suissa S, Zeiss E (1995) Scientific monograph of the Quebec Task Force on Whiplash-Associated Disorders: redefining "whiplash" and its management. Spine 20:1S–73S
185. Sponseller PD, Cass JR (1997) Atlanto-occipital fusion for dislocation in children with neurologic preservation. A case report. Spine 22:344 – 7
186. Stiell IG, Wells GA, Vandemheen KL, Clement CM, Lesiuk H, De Maio VJ, Laupacis A, Schull M, McKnight RD, Verbeek R, Brison R, Cass D, Dreyer J, Eisenhauer MA, Greenberg GH, MacPhail I, Morrison L, Reardon M, Worthington J (2001) The Canadian C-spine rule for radiography in alert and stable trauma patients. JAMA 286:1841 – 8
187. Streitwieser DR, Knopp R, Wales LR, Williams JL, Tonnemacher K (1983) Accuracy of standard radiographic views in detecting cervical spine fractures. Ann Emerg Med 12:538 – 42
188. Subach BR, Morone MA, Haid RW, Jr., McLaughlin MR, Rodts GR, Comey CH (1999) Management of acute odontoid fractures with single-screw anterior fixation. Neurosurgery 45:812 – 9; discussion 819 – 20
189. Suechting RL, French LA (1955) Posterior inferior cerebellar artery syndrome; following a fracture of the cervical vertebra. J Neurosurg 12:187 – 9
190. Svennevig JL, Bugge-Asperheim B, Vaage J, Geiran O, Birkeland S (1984) Corticosteroids in the treatment of blunt injury of the chest. Injury 16:80 – 4
191. Taylor AE, Cox CA, Mailis A (1996) Persistent neuropsychological deficits following whiplash: evidence for chronic mild traumatic brain injury? Arch Phys Med Rehabil 77:529 – 35
192. Toh E, Nomura T, Watanabe M, Mochida J (2006) Surgical treatment for injuries of the middle and lower cervical spine. Int Orthop 30:54 – 8
193. Transfeldt EE, White D, Bradford DS, Roche B (1990) Delayed anterior decompression in patients with spinal cord and cauda equina injuries of the thoracolumbar spine. Spine 15:953 – 7
194. Travlos A, Hirsch G (1993) Steroid psychosis: a cause of confusion on the acute spinal cord injury unit. Arch Phys Med Rehabil 74:312 – 5
195. Traynelis VC (1997) Evidence-based management of type II odontoid fractures. Clin Neurosurg 44:41 – 9
196. Traynelis VC, Marano GD, Dunker RO, Kaufman HH (1986) Traumatic atlanto-occipital dislocation. Case report. J Neurosurg 65:863 – 70
197. Vaccaro AR, Daugherty RJ, Sheehan TP, Dante SJ, Cotler JM, Balderston RA, Herbison GJ, Northrup BE (1997) Neurologic outcome of early versus late surgery for cervical spinal cord injury. Spine 22:2609 – 13
198. Verhagen AP, Peeters GG, de Bie RA, Oostendorp RA (2001) Conservative treatment for whiplash. Cochrane Database Syst Rev:CD003338
199. Verhagen AP, Scholten-Peeters GG, van Wijngaarden S, de Bie RA, Bierma-Zeinstra SM (2007) Conservative treatments for whiplash. Cochrane Database Syst Rev:CD003338
200. Versteegen GJ, Kingma J, Meijler WJ, ten Duis HJ (1998) Neck sprain in patients injured in car accidents: a retrospective study covering the period 1970 – 1994. Eur Spine J 7:195 – 200
201. Versteegen GJ, Kingma J, Meijler WJ, ten Duis HJ (1998) Neck sprain not arising from car accidents: a retrospective study covering 25 years. Eur Spine J 7:201 – 5
202. Werne S (1957) Studies in spontaneous atlas dislocation. Acta Orthop Scand Suppl 23:1 – 150
203. White AA, 3rd, Panjabi MM (1978) The basic kinematics of the human spine. A review of past and current knowledge. Spine 3:12 – 20
204. White AA, 3rd, Panjabi MM (1990) Kinematics of the spine. In: White AA, 3rd, Panjabi MM (eds) Clinical biomechanics of the spine. JB Lippincott, Philadelphia, pp 85 – 125
205. White AA, 3rd, Panjabi MM (1990) Practical biomechanics of spine trauma. In: White AA, 3rd, Panjabi MM (eds) Clinical biomechanics of the spine. JB Lippincott, Philadelphia, pp 169 – 275
206. White AA, 3rd, Panjabi MM (1990) The problem of clinical instability in the human spine: a systematic approach. In: White AA, 3rd, Panjabi MM (eds) Clinical biomechanics of the spine. JB Lippincott, Philadelphia, pp 277 – 378
207. Williamson E, Williams M, Gates S, Lamb SE (2008) A systematic literature review of psychological factors and the development of late whiplash syndrome. Pain 135:20 – 30
208. Willis BK, Greiner F, Orrison WW, Benzel EC (1994) The incidence of vertebral artery injury after midcervical spine fracture or subluxation. Neurosurgery 34:435 – 41; discussion 441 – 2

209. Woltmann A, Buhren V (2004) [Shock trauma room management of spinal injuries in the framework of multiple trauma. A systematic review of the literature]. Unfallchirurg 107:911 – 8
210. Wood-Jones F (1913) The ideal lesion produced by judicial hanging. Lancet 1
211. Yablon IG, Palumbo M, Spatz E, Mortara R, Reed J, Ordia J (1991) Nerve root recovery in complete injuries of the cervical spine. Spine 16:S518 – 21
212. Young WF, Rosenwasser RH, Getch C, Jallo J (1994) Diagnosis and management of occipital condyle fractures. Neurosurgery 34:257 – 60; discussion 260 – 1

# 31 Thoracolumbar Spinal Injuries

Michael Heinzelmann, Guido A. Wanner

## Core Messages

- ✔ Spinal fractures are frequently located at the thoracolumbar junction for biomechanical reasons
- ✔ The AO classification has gained widespread acceptance in Europe for the grading of thoracolumbar fractures: Type A: vertebral compression fractures; Type B: anterior and posterior column injuries with distraction; Type C: anterior and posterior element injury with rotation
- ✔ The initial focus of the physical examination of a patient with a spinal injury is on the vital and neurological functions, because effective resuscitation is critical to the management of polytraumatized patients and patients with spinal cord injury
- ✔ The imaging modalities of choice are standard radiographs and CT scans. A CT scan should routinely be made to visualize bony injury. MRI is helpful to diagnose discoligamentous injuries and to identify a possible cord lesion
- ✔ Primary goals of treatment are prevention and limitation of neurological injury as well as restoration of spinal stability, regardless of whether operative or non-operative therapy is chosen
- ✔ Secondary goals consist of correction of deformities, minimizing the loss of motion, and facilitating rapid rehabilitation
- ✔ Early stabilization and fusion is generally accepted for patients with unstable fractures and neurological deficits
- ✔ The optimal treatment for patients with less instability, moderate deformity and absence of neurological compromise is not based on scientific evidence and remains a matter of debate.
- ✔ Good clinical outcome can be achieved with non-operative as well as operative treatment

## Epidemiology

Systematic epidemiologic data on traumatic thoracolumbar fractures are rare and differ depending on the area studied and on the treating center. The studies available from western countries reveal typical and comparable data on incidence, localization, and mechanisms of injury. Thoracolumbar fractures are more frequent in men (2/3) than in women (1/3) and peak between the ages of 20 and 40 years [30, 47, 65, 81, 94]. Approximately, 160 000 patients/year sustain an injury of the spinal column in the United States. The majority of these injuries comprise cervical and lumbar (L3–L5) spine fractures. However, between 15 % and 20 % of traumatic fractures occur at the thoracolumbar junction (T11–L2), whereas 9 – 16 % occur in the thoracic spine (T1–T10) [36, 46]. Hu and coworkers [56] studied the total population of a Canadian province over a period of 3 years. The incidence of spine injuries was 64/100 000 inhabitants per year, predominantly younger men and older women. A total of 2 063 patients were registered and 944 patients were treated in hospital: 182 patients (20 %) with a cervical spine injury, 286 patients (30 %) with a thoracic spine injury and 403 patients (50 %) with an injury of the lumbosacral spine. Traumatic cross-section spinal cord injury occurred in 40 out of 1 million inhabitants. About

Fractures most frequently affect the thoracolumbar junction

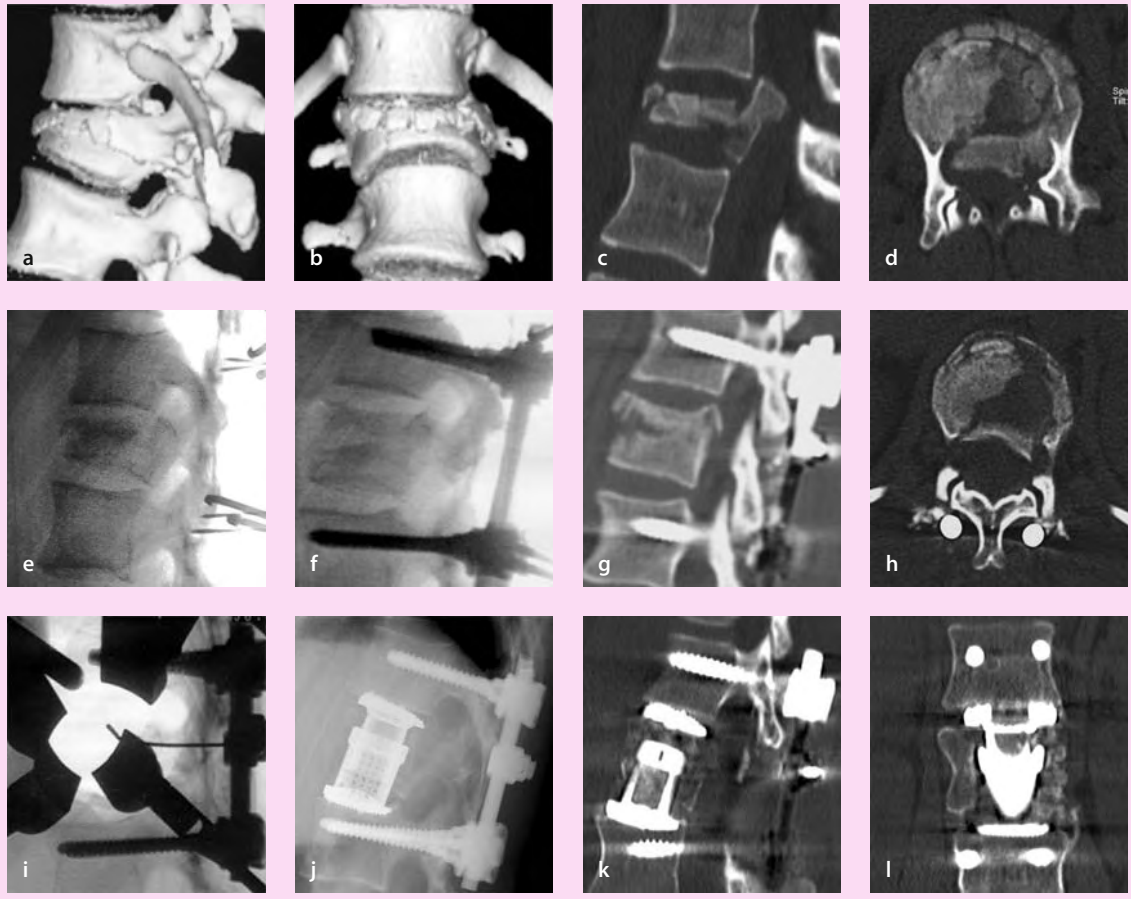


## Case Introduction

This 23-year-old female sustained a motor vehicle accident as an unrestrained passenger. Clinically, she presented with an incomplete paraplegia (ASIA C) and an incomplete conus-cauda syndrome. The initial CT (a–d) scan demonstrates an unstable complete burst fracture of L1 (Type A3.3). The 3D reconstruction (a, b) gives a good overview of the degree of comminution and the deformity; the posterior fragment is best visualized in the lateral 2D reconstruction (c) and the axial view (d). In an emergency procedure, the myelon was decompressed by laminectomy and the fracture was reduced and stabilized with an internal fixator (e–h). Interestingly, the prone position alone (e) reduced the fracture to a certain degree when compared to the CT scan taken with the patient in a supine position. With the internal fixator (RecoFix), the anatomical height and physiological alignment was restored (f) and the posterior fragment was partially reduced (g, h). This indirect reduction of bony fragments, called ligamentotaxis, is possible if the posterior ligaments and the attachment to the anulus fibrosus are intact. We performed a complete clearance of the spinal canal by an anterior approach 5 days later (i–l). In this minimally invasive technique, the spine is approached by a small thoracotomy from the left, the ruptured disc and bony fragments are removed, and an expandable cage is inserted. One of the first steps in this technique is the positioning of a K-wire in the upper disc space of the fractured vertebra (i). In this figure, the four retractors of the Synframe and the endoscopic light source are seen. The final result after 9 months (j–l) demonstrates the cage (Synex), the physiological alignment without signs of implant failure or kyphosis, a good clearance of the spinal canal from anterior and the laminectomy from posterior (k), and a bony healing of the local bone transplant of the lateral side of the cage (l). Fortunately, the patient completely recovered from her neurological deficit (ASIA E).

50–60% of thoracolumbar fractures affect the transition T11–L2, 25–40% the thoracic spine and 10–14% the lower lumbar spine and sacrum [80, 86].

In a study by Magerl and Engelhardt [81] on 1446 thoracolumbar fractures, most injuries concerned the first lumbar vertebra, i.e., 28% ($n=402$), followed by T12 (17%, $n=246$) and L2 (14%, $n=208$). The epidemiologic multicenter study on fractures of the thoracolumbar transition (T10–L2) by the German Trauma Society studied 682 patients and revealed 50% ($n=336$) L1 fractures, 25%

($n = 170$) T12 fractures, and 21 % ($n = 141$) L2 fractures [65]. Our own series at the University Hospital in Zürich demonstrated a very similar distribution for operated spine fractures (1992 – 2004, $n = 1744$): 20 % cervical spine ($n = 350$), 8 % thoracic spine T1–T10 ($n = 142$), 62 % thoracolumbar spine T11–L2 ($n = 1075$), and 10 % lumbosacral spine L3-sacrum ($n = 176$). The **susceptibility of the thoracolumbar transition** is attributed mainly to the following anatomical reasons:

- The transition from a relatively rigid thoracic kyphosis to a more mobile lumbar lordosis occurs at T11 – 12.
- The lowest thoracic ribs (T11 and T12) provide less stability at the thoracolumbar junction region compared to the rostral thoracic region, because they do not connect to the sternum and are free floating.
- The facet joints of the thoracic region are oriented in the coronal (frontal) plane, limiting flexion and extension while providing substantial resistance to anteroposterior translation [36]. In the lumbosacral region, the facet joints are oriented in a more sagittal alignment, which increases the degree of potential flexion and extension at the expense of limiting lateral bending and rotation.

Spinal cord injury occurs in about 10 – 30 % of traumatic fractures

**Spinal cord injury** occurs in about 10 – 30 % of traumatic spinal fractures [37, 56]. In thoracolumbar spine fractures (T1–L5), Magerl et al. [81] and Gertzbein [47] reported 22 % and 35.8 % neurological deficiencies, respectively. The epidemiologic multicenter study on fractures of the thoracolumbar transition (T10–L2) by the German Society of Traumatology [65] revealed neurological deficiencies in 22 – 51 %, depending on the fracture type (22 % in Type A fractures, 28 % in Type B fractures, and 51 % in Type C fractures, according to the AO classification). Complete paraplegia was found in 5 % of the patients with fractures of the thoracolumbar transition.

## Pathomechanisms

At the time of injury, several forces may act together to produce structural damage to the spine. However, most frequently, one or two major forces, defining the major injury vector, account for most of the bony and ligamentous damage. The **most relevant forces** are:

- axial compression
- flexion/distraction
- hyperextension
- rotation
- shear

### Axial Compression

Axial load may result in a burst fracture

While axial loading of the body results in anterior flexion forces in the kyphotic thoracic spine, mainly compressive forces occur in the straight thoracolumbar region [64]. Axial loading of a vertebra produces endplate failure followed by vertebral body compression [98]. Depending on the energy, the axial load may result in incomplete or complete **burst fractures**, i.e., vertical fractures with centripetal displacement of the fragments [12, 33]. The posterior elements are usually intact; however, with severe compression, significant disruption of these elements may occur. The combination of an axially directed central compressive force with an eccentric compressive force anterior to the axis of rotation (center of nucleus pulposus) typically leads to **wedge compression fractures**. Herein, the vertebral body fails in (wedge) compression, while the posterior ligamentous and osseous elements may

remain intact or fail in tension, depending on the energy level of the injury. In the latter case, the injury is classified as flexion-distraction injury. Violent trauma is the most common cause of compression fractures in young and middle-aged adults. The most frequent causes are motor vehicle accidents and falls from a height, followed by sports and recreational activity injuries. In the elderly population, osteoporotic compression fractures following low-energy trauma are most common.

## Flexion/Distraction

Flexion forces cause eccentric compression of the vertebral bodies and discs and cause tension to the posterior elements. If the anterior wedging exceeds 40 – 50 %, **rupture** of the **posterior ligaments** and **facet joint capsules** must be assumed [117]. In flexion/distraction injuries, the axis of flexion is moved anteriorly (towards the anterior abdominal wall), and the entire vertebral column is subjected to large tensile forces. These forces can produce:

- pure osseous lesion
- mixed osteoligamentous lesion
- pure soft tissue (ligamentous or disc) lesion

In flexion/distraction injuries, the posterior ligamentous and osseous elements fail in tension

Distraction leads to a **horizontal disrupture** of the anterior and/or posterior elements. A distraction fracture that extends through the bone was first described by **Chance** [22]. This lesion involves a horizontal fracture, which begins in the spinous process, progresses through the lamina, transverse processes, and pedicles, and extends into the vertebral body. Depending on the axis of flexion the vertebral body and disc may rupture or may be compressed anteriorly as described above. Although any accident providing significant forward flexion combined with distraction can produce this type of injury, the typical cause is a motor vehicle accident with the victim wearing a lap seat belt. These injuries are associated with a high rate of hollow visceral organ lesions, typically of the small bowel, colon or stomach, but also pancreatic injuries have been reported [3, 13].

## Hyperextension

Hyperextension may result in anterior discoligamentous disruption and posterior compression fractures of facets, laminae, or spinous processes

Extension forces occur when the upper part of the trunk is thrust posteriorly. This produces an injury pattern that is the reverse of that seen with flexion. Tension is applied anteriorly to the strong anterior longitudinal ligaments and anterior portion of the anulus fibrosus, whereas compression forces are transmitted to the posterior elements. This mechanism results in a rupture from anterior to posterior and may result in facet, lamina, and spinous process fractures [43]. Denis and Burks reported on a hyperextension injury pattern that they termed **lumberjack fracture-dislocation** [32]. The mechanism of this injury is a falling mass, often timber, striking the midportion of the patient's back. The injury involves complete disruption of the anterior ligaments and is an extremely unstable injury pattern. These injuries are the result of a reversed trauma mechanism. The intervertebral disc ruptures from anterior to posterior. The lesion may proceed into the posterior column and is then unstable against extension and shearing forces.

## Rotational Injuries

Rotational injuries combine compressive forces and flexion/distraction mechanisms and are highly unstable

Both compressive forces and flexion-distraction mechanisms may be combined with rotational forces and lead to **rotational fracture dislocations**. As rotational forces increase, ligaments and facet capsules fail and lead to subsequent disruption of both the anterior and posterior elements. A highly unstable injury pattern will develop, i.e., the posterior ligaments and joint capsule will rupture and the

anterior disc and vertebral body will disrupt obliquely or will be compressed. Rotational forces may further be combined with shearing forces and lead to most unstable fractures (slice fractures, Holdsworth) [54]. These patients have often been thrown against an obstacle or hit by a heavy device. Thus, the patients often have widespread dermabrasions and contusions on the back.

### Shear

Shear forces produce severe ligamentous disruption and may result in anterior, posterior or lateral vertebral displacement [98]. The most frequent type is traumatic anterior spondylolisthesis that usually results in a complete spinal cord injury.

Shear forces produce severe ligamentous disruption and are often associated with spinal cord injury

## Classification

Vertebral spine injuries are very heterogeneous in nature. Most important for the understanding and treatment of these injuries is the evaluation of spinal **stability** or **instability**, respectively. However, the conclusive evaluation of this question is difficult because the term "**instability**" is not yet clearly defined in the context of spinal disorders.

Several classifications of spinal injuries have been introduced based primarily on fracture morphology and different stability concepts. White and Panjabi [118] defined clinical instability of the spine as shown in Table 1:

**Table 1.** Definition of spinal instability

- Loss of the ability of the spine under physiologic loads to maintain relationships between vertebrae in such a way that there is neither damage nor subsequent irritation to the spinal cord or nerve root and, in addition, there is no development of incapacitating deformity or pain from structural changes

Physiologic loads are defined as loads during normal activity, incapacitating deformity as gross deformity unacceptable to the patient, and incapacitating pain as discomfort uncontrolled by non-narcotic analgesics.

Presently, there is no generally used classification for thoracolumbar injuries. However, the **most important classification** of spinal injuries aims to differentiate between:

- stable fractures
- unstable fractures

This concept was first introduced by Nicoll in 1949 [89] and is still the most widely accepted differentiation. However, this classification is insufficient to give detailed treatment recommendations.

Holdsworth [54] was the first to stress the mechanism of injury to classify spinal injuries and described five different injury types. Kelly and Whitesides [61, 119] reorganized the mechanistic classification and defined the two column concept, which became the basis of the AO classification (see below). Louis further modified this structural classification scheme and suggested the posterior facet joint complex of each side to become a separate column [79]. The ventral column consists of the vertebral body; the two dorsal columns involve the facet articulations of both sides. Roy-Camille was concerned about the relationship of the injury to vertebra, especially the neural ring, and the spinal cord. He described the "*segment moyen*," referring to the neural ring, and related injury of the *segment moyen* to instability [99]. This aspect led to the term of the so-called "middle column," which is not a distinct anatomic column.

## Denis Classification

The middle column became a central part of the classification of spinal injuries according to Denis [30], which is in widespread use in the United States. Accordingly, the vertebral column is divided into **three columns** [30]:

- anterior column
- middle column
- posterior column

The **anterior column** consists of the ventral longitudinal ligament (VLL), the anterior anulus fibrosus, and the anterior half of the vertebral bodies. The **middle column** consists of the posterior longitudinal ligament (PLL), the dorsal anulus fibrosus, and the dorsal half of the vertebral bodies. Finally, the **posterior column** consists of the bony neural arch, posterior spinous ligaments and ligamentum flavum, as well as the facet joints.

Denis considered the **middle column** to be the **key structure**. A relevant injury to the middle column was therefore the essential criterion for instability. According to the Denis classification, rupture of the posterior ligamentous complex only creates instability if there is concomitant disruption of at least the PLL and dorsal anulus. However, the middle column is not clearly defined either anatomically or biomechanically, i.e., the middle column bony part resists compression forces, and the ligamentous part resists distraction forces. Although the three column concept by Denis raised several concerns, his classification is still frequently used, because it is simple and includes all the injury patterns most commonly seen. Denis distinguished minor and major injuries: minor injuries included fractures of the articular, transverse, and spinous processes as well as the pars interarticularis. Major spinal injuries were divided into compression fractures, burst fractures, flexion-distraction (seat-belt) injuries, and fracture dislocations.

The Denis classification does not allow for a detailed fracture classification

## AO Classification

The AO/ASIF (Arbeitsgemeinschaft für Osteosynthesefragen/Association for the Study of Internal Fixation) classification introduced by Magerl et al. in 1994 [80] is increasingly being accepted as the gold standard for documentation and treatment of injuries of the vertebral spine.

The AO classification is based on the "**two column theory**" described by Holdsworth [54, 55] and Kelly and Whitesides [61, 119]. The AO classification considers the spine to comprise two functionally separate supportive columns. The **anterior column** consists of the vertebral body and the intervertebral discs and is loaded in compression. The **posterior column** consists of the pedicles, the laminae, the facet joints, and the posterior ligamentous complex, and is loaded in tension. According to the common AO classification system, injuries are categorized with increasing severity into types (Fig. 1):

- Type A: compression injuries
- Type B: distraction injuries
- Type C: rotational injuries

**Type A** injuries are the result of compression by axial loading (e.g., compression and burst fractures). **Type B** injuries are flexion-distraction or hyperextension injuries and involve the anterior and posterior column. Disruption may occur in the posterior or anterior structures. **Type C** fractures are the result of a compression or flexion/distraction force in combination with a rotational force in the horizontal plane (e.g., fracture dislocations with a rotatory component). Each type is classified into **three major groups (1–3)** of increasing severity (Fig. 2) and can further be divided into subgroups and specifications (Table 2).

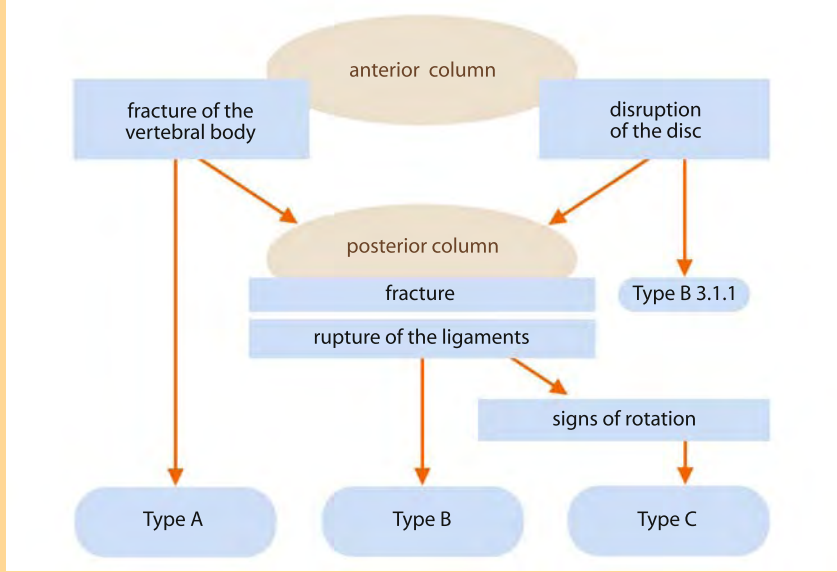


**Figure 1. Algorithm for AO fracture type classification**

According to Magerl et al. [80].

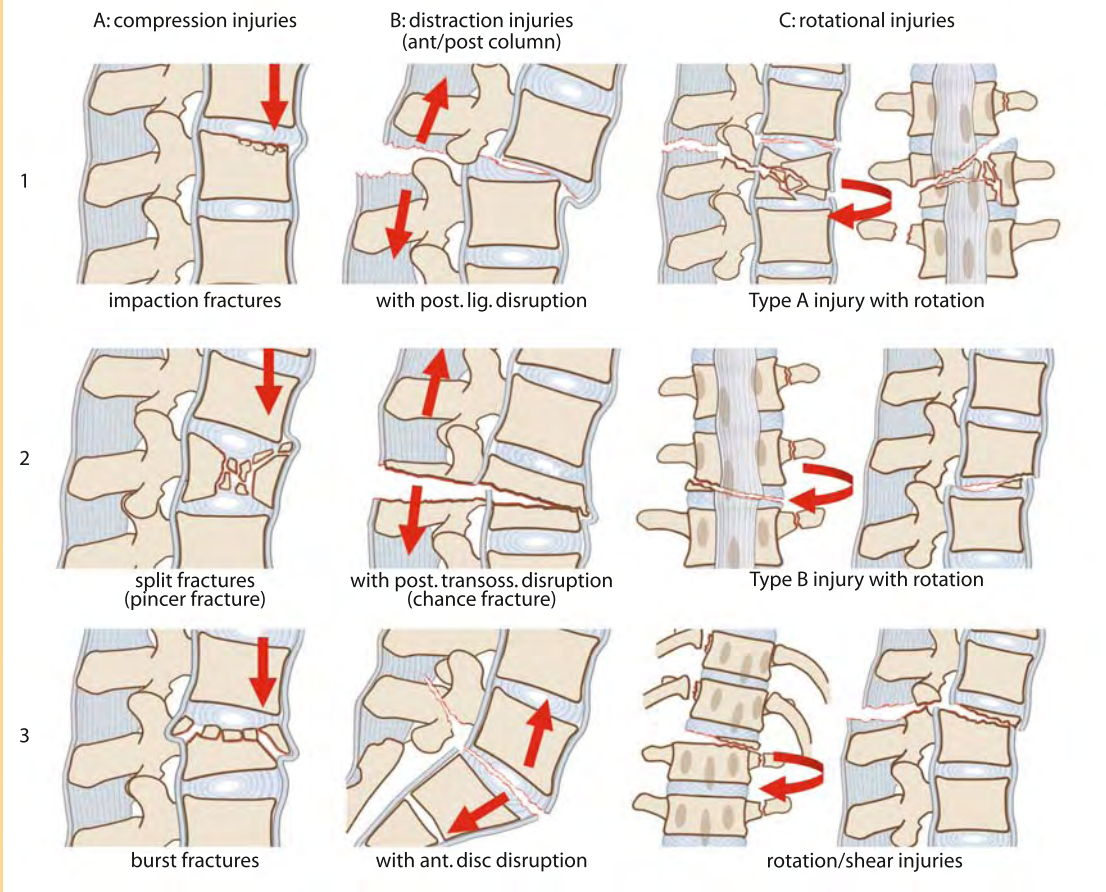


**Figure 2. AO fracture classification – fracture types and groups**

According to Magerl et al. [80].

**Table 2.** AO fracture classification

| Type A: vertebral body compression | Type B: anterior and posterior element injury with distraction | Type C: anterior and posterior element injury with rotation |
|---|---|---|
| A1. Impaction fractures<br>A1.1. Endplate impaction<br>A1.2. Wedge impaction fractures<br>A1.2.1. Superior wedge impaction fracture<br>A1.2.2. Lateral wedge impaction fracture<br>A1.2.3. Inferior wedge impaction fracture | B1. Posterior disruption predominantly ligamentous (flexion-distraction injury)<br>B1.1. With transverse disruption of the disc<br>B1.1.1. Flexion-subluxation<br>B1.1.2. Anterior dislocation<br>B1.1.3. Flexion-subluxation/anterior dislocation with fracture of the articular processes<br>B1.2. With Type A fracture of the vertebral body<br>B1.2.1. Flexion-subluxation + Type A fracture<br>B1.2.2. Anterior dislocation + Type A fracture<br>B1.2.3. Flexion-subluxation/anterior dislocation with fracture of the articular processes + Type A fracture | C1. Type A injuries with rotation (compression injuries with rotation)<br>C1.1. Rotational wedge fracture<br>C1.2. Rotational split fractures<br>C1.2.1. Rotational sagittal split fracture<br>C1.2.2. Rotational coronal split fracture<br>C1.2.3. Rotational pincer fracture<br>C1.2.4. Vertebral body separation<br>C1.3. Rotational burst fractures<br>C1.3.1. Incomplete rotational burst fractures<br>C1.3.2. Rotational burst-split fracture<br>C1.3.3. Complete rotational burst fracture |
| A2. Split fractures<br>A2.1. Sagittal split fracture<br>A2.2. Coronal split fracture<br>A2.3. Pincer fracture | B2. Posterior disruption predominantly osseous (flexion-distraction injury)<br>B2.1. Transverse bicolumn fracture<br>B2.2. With transverse disruption of the disc<br>B2.2.1. Disruption through the pedicle and disc<br>B2.2.2. Disruption through the pars interarticularis and disc (flexion-spondylolysis)<br>B2.3. With Type A fracture of the vertebral body<br>B2.3.1. Fracture through the pedicle + Type A fracture<br>B2.3.2. Fracture through the pars interarticularis (flexion-spondylolysis) + Type A fracture | C2. Type B injuries with rotation<br>C2.1. B1 injuries with rotation (flexion-distraction injuries with rotation)<br>C2.1.1. Rotational flexion subluxation<br>C2.1.2. Rotational flexion subluxation with unilateral articular process fracture<br>C2.1.3. Unilateral dislocation<br>C2.1.4. Rotational anterior dislocation without/with fracture of articular processes<br>C2.1.5. Rotational flexion subluxation without/with unilateral articular process + Type A fracture<br>C2.1.6. Unilateral dislocation + Type A fracture<br>C2.1.7. Rotational anterior dislocation without/with fracture of articular processes + Type A fracture<br>C2.2. B2 injuries with rotation (flexion distraction injuries with rotation)<br>C2.2.1. Rotational transverse bicolumn fracture<br>C2.2.2. Unilateral flexion spondylolysis with disruption of the disc<br>C2.2.3. Unilateral flexion spondylolysis + Type A fracture<br>C2.3. B3 injuries with rotation (hyperextension-shear injuries with rotation)<br>C2.3.1. Rotational hyperextension-subluxation without/with fracture of posterior vertebral elements<br>C2.3.2. Unilateral hyperextension-spondylolysis<br>C2.3.3. Posterior dislocation with rotation |
| A3. Burst fractures<br>A3.1. Incomplete burst fracture<br>A3.1.1. Superior incomplete burst fracture<br>A3.1.2. Lateral incomplete burst fracture<br>A3.1.3. Inferior incomplete burst fracture<br>A3.2. Burst-split fracture<br>A3.2.1. Superior burst-split fracture<br>A3.2.2. Lateral burst-split fracture<br>A3.2.3. Inferior burst-split fracture<br>A3.3. Complete burst fracture<br>A3.3.1. Pincer burst fracture<br>A3.3.2. Complete flexion burst fracture<br>A3.3.3. Complete axial burst fracture | B3. Anterior disruption through the disc (hyperextension-shear injury)<br>B3.1. Hyperextension-subluxations<br>B3.1.1. Without injury of the posterior column<br>B3.1.2. With injury of the posterior column<br>B3.2. Hyperextension-spondylolysis<br>B3.3. Posterior dislocation | C3. Rotational-shear injuries<br>C3.1. Slice fracture<br>C3.2. Oblique fracture |

Types, groups, subgroups and specifications allow for a morphology based classification of thoracolumbar fractures according to Magerl et al. [80]

**Table 3.** Frequency of fracture types and groups

| | Case | Percentage of total | Percentage of type |
|---|---|---|---|
| **Type A** | **956** | **66.16** | |
| A1 | 502 | 34.74 | 52.51 |
| A2 | 50 | 3.46 | 5.23 |
| A3 | 404 | 27.96 | 42.26 |
| **Type B** | **209** | **14.46** | |
| B1 | 126 | 8.72 | 60.29 |
| B2 | 80 | 5.54 | 38.28 |
| B3 | 3 | 0.21 | 1.44 |
| **Type C** | **280** | **19.38** | |
| C1 | 156 | 10.80 | 55.71 |
| C2 | 108 | 7.47 | 38.57 |
| C3 | 16 | 1.11 | 5.71 |

Based on an analysis of 1 445 cases (Magerl et al. [80])

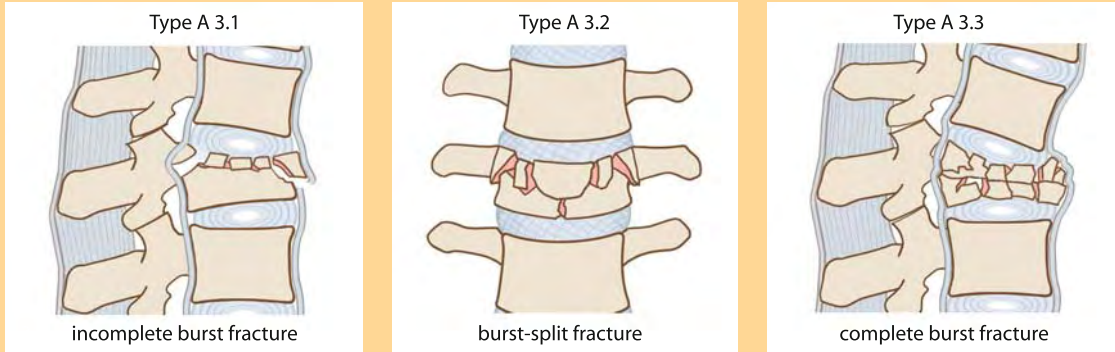


**Figure 3. Burst fracture subgroups**

According to Magerl et al. [80].

Impaction and burst fracture are the most frequent fracture types

Second to **simple impaction fractures** (A1), the most frequent injury types are burst fractures, which can be divided into **three major subgroups** (Table 3, Fig. 3). The likelihood of neurological deficit increases in the higher subgroups (Table 4).

The important morphological criteria of instability according to the AO classification are injuries to the ligaments and discs. A graded classification is useful because there is a range from "definitely stable" to "definitely unstable" fractures.

Fractures are considered **stable** if no injury to ligaments or discs is evident, e.g., pure impaction fractures (Type A1). Structural changes of the spine under physiologic loads are unlikely. **Slightly unstable fractures** reveal partial damage of ligaments and intervertebral discs, but heal under functional treatment without gross deformity and without additional neurological deficit. This is the case in a frequent type (A3), the so-called incomplete superior burst fracture (A3.1.1). **Highly unstable** implicates a severe damage of the ligaments and intervertebral discs, as it occurs in the fracture Types A3, B, and C.

**Table 4.** Frequency of neurological deficits

| Types and groups | Number of injuries | Neurological deficit (%) |
|---|---|---|
| **Type A** | **890** | **14** |
| A1 | 501 | 2 |
| A2 | 45 | 4 |
| A3 | 344 | 32 |
| **Type B** | **145** | **32** |
| B1 | 61 | 30 |
| B2 | 82 | 33 |
| B3 | 2 | 50 |
| **Type C** | **177** | **55** |
| C1 | 99 | 53 |
| C2 | 62 | 60 |
| C3 | 16 | 50 |
| **Total** | **1 212** | **22** |

Based on an analysis of 1 212 cases (Magerl et al. [80])

## Clinical Presentation

The clinical assessment of patients with a putative trauma to the spine has **three major objectives**, i.e., to identify:

- the spinal injury
- neurological deficits
- concomitant non-spinal injuries

### Spinal Injuries

About 30% of polytraumatized patients have a spinal injury

It is obvious that the management and the priorities differ between a life-threatening polytrauma that includes a spinal injury and a monotrauma of the spine. In the case of a polytrauma, about one-fourth to one-third of patients have a spinal injury [120]. In our institution, we found spinal injuries in 22% of polytraumatized patients. In a series of 147 consecutive patients with multiple trauma, Dai et al. [24] found a delayed diagnosis of thoracolumbar fractures in 19%, confirming an earlier study by Anderson et al. [5], in which 23% of patients with major thoracolumbar fractures were diagnosed after the patient had left the emergency department. A delay in the diagnosis of thoracolumbar fractures is frequently associated with an unstable patient condition that necessitates higher-priority procedures than thoracolumbar spine radiographs in the emergency department. However, with the routine use of multi-slice computed tomography (CT) in polytraumatized patients, the diagnostic work-up is usually adequate [57, 106] and delayed diagnosis of spine fractures should become rare. Multiple burst fractures occur in approximately 10–34% [10, 11, 53].

Polytraumatized patients should be screened for spinal fracture by CT

### Neurological Deficit

Sacral sparing indicates an incomplete lesion with a better prognosis

An accurate and well-documented neurological examination is of great importance. With an inaccurate or incomplete examination and a subsequent variation of the patient's neurological deficit, it will be unclear if the situation has changed or if the initial assessment was simply inappropriate. In the case of a progressive neurological deficit, this may hinder urgent further management, i.e., the need for a surgical intervention with spinal decompression. Neurological assessment is usually done according to the guidelines of the **American Spinal Injury Association** (see Chapter 11). Importantly, the examination has to include the "search for a sacral sparing" which will determine the completeness of the deficit and the prognosis.

## Concomitant Non-spinal Injuries

About one-third of all spine injuries have concomitant injuries [65, 100, 120]. In a review of 508 consecutive hospital admissions of patients with spinal injuries, Saboe et al. [100] identified the presence of associated injuries in 240 (47 %) individuals. Most frequently found **concomitant injuries** were:

- head injuries (26 %)
- chest injuries (24 %)
- long bone injuries (23 %)

About one-third of all spinal injuries have concomitant injuries

One associated injury was found in 22 %, two injuries in 15 %, and 10 % of the patients had three or more associated injuries. Most spine fractures involved the lower cervical spine (29 %) or the thoracolumbar junction (21 %). Eighty-two percent of thoracic fractures and 72 % of lumbar fractures had associated injuries compared to 28 % of lower cervical spine fractures [100]. There is an association between flexion injuries of the lumbar spine (**Chance type**) and **abdominal injuries in seat belt injuries**. Anderson et al. [2] reviewed 20 cases of Chance-type thoracolumbar flexion-distraction fractures and found that 13 patients (65 %) had associated life-threatening intra-abdominal trauma. Twelve of these patients had bowel wall injury. Conversely, specific injury mechanisms and fracture patterns should lead to a targeted search for concomitant spinal injuries. It is well established that calcaneus or tibia plateau fractures following a fall from a great height are associated with spinal burst fractures. Also, sternal injuries may be associated with spinal fractures. Injury to the sternum, when due to indirect violence, is almost always associated with a severe spinal column injury [48].

Flexion injuries are frequently associated with abdominal injuries

## History

The history of a patient who sustained a thoracolumbar spinal injury is usually obvious. The **cardinal symptoms** are:

- pain
- loss of function (inability to move)
- sensorimotor deficit
- bowel and bladder dysfunction

The history should include a **detailed assessment of the injury**, i.e.:

History should include the trauma type and injury mechanism

- type of trauma (high vs. low energy)
- mechanism of injury (compression, flexion/distraction, hyperextension, rotation, shear injury)

Fractures of the thoracolumbar spine usually result from high-energy trauma such as traffic accidents and falls from a great height. Recreational activities frequently associated with spinal injuries are skiing, snowboarding, paragliding or horseriding. A spinal fracture should be suspected in any patient who has had a high-energy trauma. Consequently, patients should be treated as if they have a spinal injury unless proven otherwise [97]. On the contrary, vertebral compression fractures can also occur in less severe accidents or more or less spontaneously in elderly patients with osteoporotic bones (see Chapter 32) [63].

In patients with **neurological deficits**, the history must be detailed regarding:

- time of onset
- course (unchanged, progressive, or improving)

The time course of the neurological deficit matters

As outlined in Chapter 30, polytraumatized and unconscious (head-injured) patients are difficult to assess. Polytraumatized patients carry a high risk (up to

30 %) of having suffered a spinal fracture and must be scrutinized for such an injury. Assessing the history is not possible in unconscious patients and the diagnosis must therefore be based on thorough imaging studies.

## Physical Findings

Similarly to the assessment of the patient with a cervical spine injury (see Chapter 30), the initial focus of the physical examination is on the **assessment** of:

- vital functions
- neurological deficits

Assess vital functions and neurological deficits

The goal is to immediately secure vital functions, which can be compromised in polytraumatized patients and patients with a spinal cord injury. Often hypotension and hypovolemia is encountered both in polytraumatized and spinal cord injured patients. Importantly, secondary deterioration of spinal cord function that results from hypotension and inadequate tissue oxygenization has to be avoided by timely and appropriate treatment.

Neurological deficits due to thoracolumbar fractures vary considerably

A thorough **neurological examination** is indispensable (see Chapter 11). The spinal cord usually terminates at the level of L1 in adults, although it may extend to L2 in some patients. Therefore, fractures at the thoracolumbar junction may result in a variety of neurological injury types and symptoms, i.e., damage to:

- distal spinal cord with complete/incomplete paraplegia
- conus medullaris with malfunction of the vegetative system
- cauda equina
- thoracolumbar nerve roots

Consider a spinal shock in patients with neurological deficits

In the case of a neurological deficit, the differentiation between a complete and incomplete paraplegia is of great importance for the prognosis, because approximately 60 % of patients with an incomplete lesion have the potential to make a functionally relevant improvement. In thoracolumbar fractures, the clinical picture of a complete neurogenic shock will not develop, because only the caudal parts of the sympathetic system are possibly damaged. However, a **spinal shock** may be present (see Chapter 30). It is mandatory to exclude a spinal shock because spinal shock can disguise remaining neural function and has an impact on the treatment decision and timing.

Thoracolumbar factures may damage the parasympathic centers located in the conus medullaris. This injury will lead to bladder dysfunction, bowel dysfunction as well as sexual dysfunction. In the case of damage to the cauda equina or in a combination with damage to the conus medullaris, a more diffuse distribution of lower extremity paresthesia, weakness and loss of reflexes is found. Radiculopathy can be identified by a segmental pattern of sensory alterations that do not have to be combined with motor dysfunction. As outlined in the previous chapter, the neurological function must be precisely documented. The **ASIA protocol** [84] has become an assessment standard for this objective (see Chapter 11).

The **inspection and palpation** of the spine should include the search for:

- skin bruises, lacerations, ecchymoses
- open wounds
- swellings
- hematoma
- spinal (mal)alignment
- gaps

## Diagnostic Work-up

### Imaging Studies

The radiographic examination is an extension of the physical examination that confirms clinical suspicions and documents the presence and the extent of many injuries. Similarly to the "clearance of the cervical spine" [97], the clinical assessment is of great importance to evaluate the necessity of imaging studies. In the alert patient who has no distracting injuries, and is not affected by sedative drugs, alcohol, or neurological deficit, the requirement for imaging is guided by clinical symptoms. The absence of back pain and tenderness has been shown to exclude a thoracolumbar injury [101].

Modern imaging studies such as computed tomography (**CT**) and magnetic resonance imaging (**MRI**) have substantially improved the diagnosis of osseous and discoligamentous injuries after spinal trauma. Thus, changes such as improvement in scan availability, image quality, acquisition time, and image reformatting have changed commonly used algorithms [6]. However, plain films are still helpful, because they allow a quick overview of the bony deformity. Also, standard radiographs are important for analyzing long-term results and deformities at follow-up.

Static imaging studies may disguise the real extent of displacement at the time of impact

It is important to remember that any static imaging study is a "snapshot in time" that is taken **after** the major impact has hit the spine. Thus, even CT scans or MRI do not reveal the actual degree of spinal displacement that may have happened during the injury. Also, routine plain X-rays, CT and MRI studies are taken with the patient in a prone position, i.e., in a position that lacks physiological load, and may therefore lead to a misjudgement of the severity and instability of the spine injury.

#### Standard Radiographs

Supine radiographs underestimate the kyphotic deformity

In most institutions, anterior-posterior and lateral radiographs of the entire spine are standard imaging studies after a spinal trauma. If there is a clinical suspicion of a spinal injury, plain radiographs (anterior-posterior and lateral view) should be obtained. Radiographs taken with the patient in the prone position underestimate the extent of kyphotic deformity. Films taken with the patient in the standing position can demonstrate a possible loss of integrity of the posterior tension band under axial loading and should be done in equivocal cases.

Emergency radiographs often do not suffice because of their poor quality

Krueger and coworkers [74] studied 28 patients with fractures of the lumbar transverse process and found that three patients (11 %) had a lumbar spine fracture that was identified by CT but was overlooked on plain radiographs. They concluded that patients with acute trauma and fractures of the transverse process should be examined with CT, because CT scanning decreases the risk of missing potentially serious injuries. In a prospective series, Hauser et al. [52] compared plain films and initial CT of the chest, abdomen, and pelvis with thin cut CT scans. The authors found that all unstable fractures were diagnosed with plain radiographs. However, the initial CT detected acute fractures that were missed with the conventional X-rays and correctly classified old fractures that plain films read as "possibly" acute. The total misclassification rate for plain films was 12.6 % compared to 1.4 % for the initial CT. In an emergency situation radiographs are often of poor quality and CT is prompted if a fracture cannot be ruled out with certainty.

CT has replaced radiographs for the assessment of seriously injured patients

Measurements should be made at the level of injury and be compared with the vertebrae at the more cranial and caudal levels. Any posterior cortical disruption seen in the lateral view or any interpedicular widening seen in the anteroposterior view suggests a burst fracture that should be further analyzed by CT scan.

When analyzing plain films, the following signs and points have to be considered and searched for [13] in **the anteroposterior view**:

- loss of lateral vertebral body height (i.e., scoliotic deformity) (Fig. 4a)
- changes in horizontal and vertical interpedicular distance (Fig. 4a)
- asymmetry of the posterior structures (Fig. 4b)
- luxation of costotransverse articulations (Fig. 4b)
- perpendicular or oblique fractures of the dorsal elements
- irregular distance between the spinous processes (equivocal sign)

In the **lateral view**, the following features should be investigated:

- sagittal profile (Fig. 4c)
- degree of vertebral body compression (Fig. 4c)
- interruption or bulging of the posterior line of the vertebral body (Fig. 4d)
- dislocation of a dorsoapical fragment (Fig. 4d)
- height of the intervertebral space

### Computed Tomography

There is an increasing trend in trauma management, especially polytrauma management, to exclude visceral injuries with a multislice spiral CT scan of the chest, abdomen and pelvis [77]. In a systematic review of the literature in polytrauma patients, Woltmann and Bühren [120] advocate that imaging diagnostics, preferably as multislice spiral CT, should be performed after stabilization of the patient's general condition and before admission to the intensive care unit. Because CT has a better sensitivity and specificity compared to standard radiographs, Hauser et al. [52] point out that an initial CT scan should replace plain

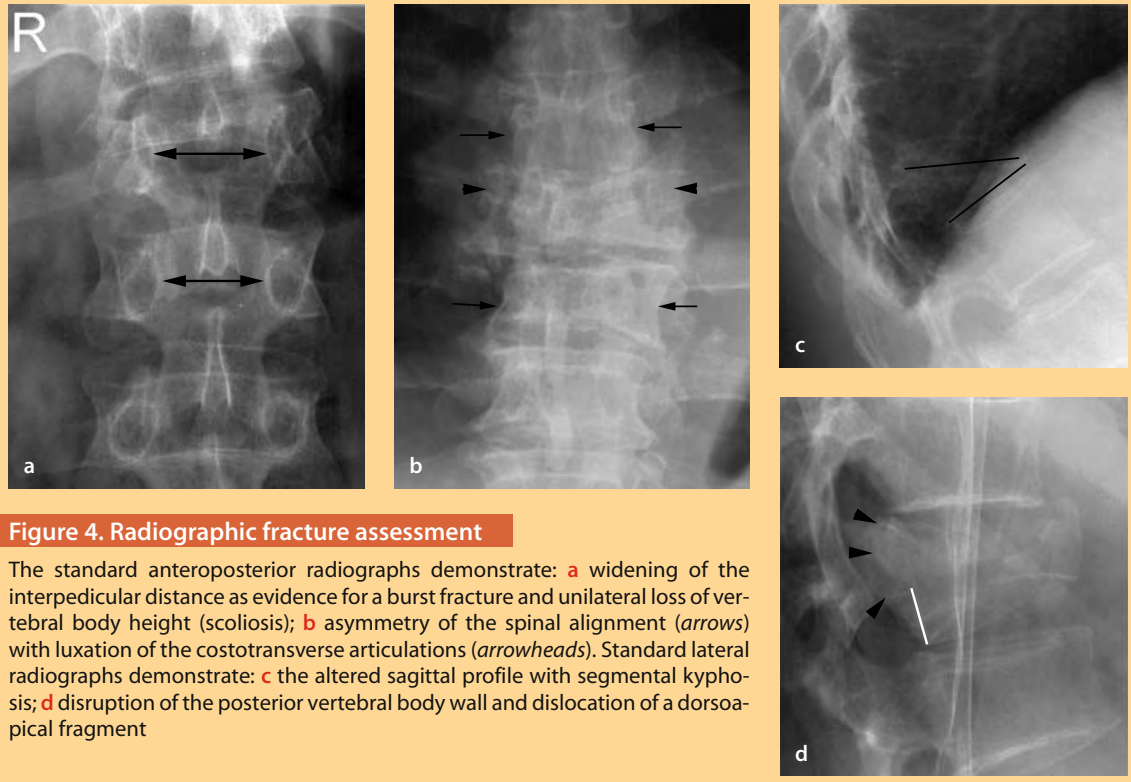


**Figure 4. Radiographic fracture assessment**

The standard anteroposterior radiographs demonstrate: a widening of the interpedicular distance as evidence for a burst fracture and unilateral loss of vertebral body height (scoliosis); b asymmetry of the spinal alignment (*arrows*) with luxation of the costotransverse articulations (*arrowheads*). Standard lateral radiographs demonstrate: c the altered sagittal profile with segmental kyphosis; d disruption of the posterior vertebral body wall and dislocation of a dorsoapical fragment

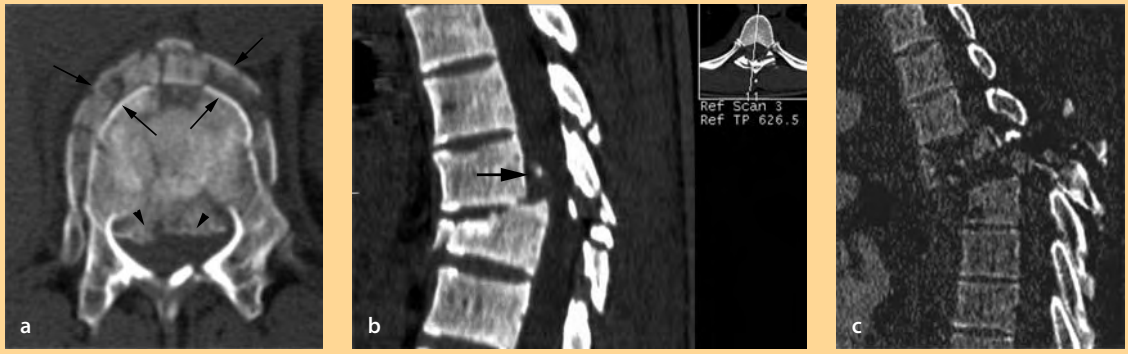


**Figure 5. CT fracture assessment**

The axial CT scan reveals: **a** significant spinal canal compromise by a retropulsed bony fragment. Note the double contour of the vertebral body indicating a "burst" component. **b** Sagittal 2D image reformation demonstrating fracture subluxation. Note the bony fragment behind the vertebral body which may cause neural compression when the fracture is reduced. **c** Severe luxation fracture of the spine. **d** The 3D CT reformation nicely demonstrates the rotation component indicating a Type C lesion

radiographs in high-risk trauma patients who require screening. In their prospective series of 222 patients with 63 thoracic and lumbar injuries, the results of conventional X-ray compared to initial CT scan were as follows: sensitivity 58 % vs. 97 %, specificity 93 % vs. 99 %, positive predictive value 64 % vs. 97 %, negative predictive value 92 % vs. 99 %, respectively.

CT is the imaging study of choice to demonstrate bony injuries

The axial view allows an accurate assessment of the comminution of the fracture and dislocation of fragments into the spinal canal (Fig. 5a). Sagittal and coronal 2D or 3D reconstructions are helpful for determining the fracture pattern (Fig. 5b–d). The canal at the injured segment should be measured in the anteroposterior and transverse planes and compared with the cephalad and caudal segments.

### Magnetic Resonance Imaging

MRI is helpful in ruling out discoligamentous lesions

In the presence of neurological deficits, MRI is recommended to identify a possible cord lesion or a cord compression that may be due to disc or fracture fragments or to an epidural hematoma (Fig. 6a). In the absence of neurological deficits, MRI of the thoracolumbar area is usually not necessary in the acute phase. However, MRI can be helpful in determining the integrity of the posterior ligamentous structures and thereby differentiate between a Type A and an unstable Type B lesion. For this purpose a fluid sensitive sequence (e.g., STIR) is frequently used to determine edema (Fig. 6b).

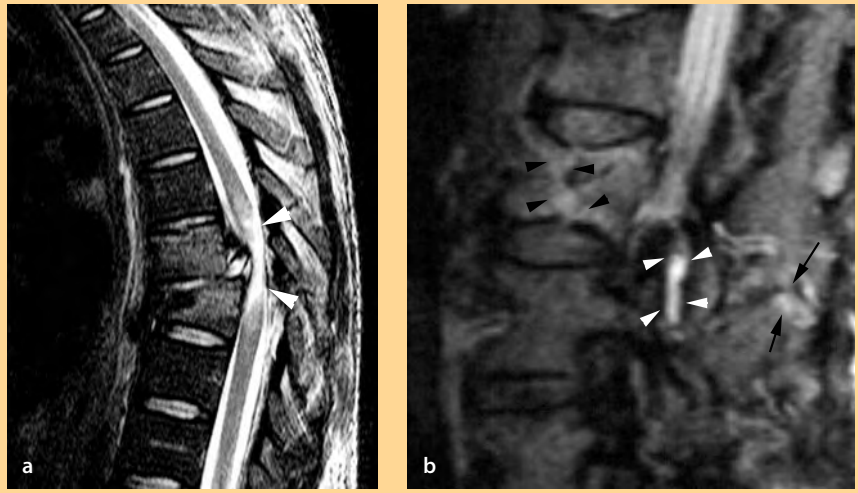


**Figure 6. MRI fracture assessment**

a The T2 weighted MR scan reveals a fracture subluxation with disc material retropulsed behind the vertebral body. Note the severe signal intensity alterations of the spinal cord as the morphological correlate for a complete spinal cord injury (*arrowheads*). b The parasagittal STIR image demonstrates a pincer fracture (*black arrowheads*). Note the joint effusion (*white arrowheads*) and the bright signal intensity alterations in the posterior elements indicating that this pincer fracture is combined with a posterior injury (Type B lesion)

### Radionuclide Studies

Radionuclide studies are **very infrequently used to diagnose acute vertebral fractures.** However, skeletal scintigraphy may be useful for fracture screening in polytraumatized patients, especially in a medicolegal context. Spitz et al. [109] found that after 10 – 12 days, with the aim of skeletal scintigraphy, an additional fracture was found in half of all patients, and was subsequently verified radiologically. Because skeletal scintigraphy can be employed with equal efficacy to reliably exclude bone injuries, the authors advocate that skeletal scintigraphy is of particular significance in the determination of the extent of bone injury in polytraumatized patients. However, bone scans have been surpassed by MRI using fluid-sensitive sequences which demonstrate the subtle lesions (e.g., bone bruise).

## Non-operative Treatment

Progress in pre-hospital care has considerably improved outcomes for patients with spinal injuries. This is in part due to the knowledge and awareness of the rescue team, the adherence to the Advanced Trauma Life Support (ATLS) protocols, and the transportation on a backboard or a vacuum board (see Chapter 30).

The general objectives of the treatment of thoracolumbar injuries are the same as for cervical injuries (Table 5):

**Table 5.** General objectives of treatment

- restoration of spinal alignment
- restoration of spinal stability
- preservation or improvement of neurological function
- avoidance of collateral damage

The treatment should provide a biologically and biomechanically sound environment that allows accurate bone and soft-tissue healing and eventually creates

a stable and pain-free spinal column. These goals should be accomplished with a minimal risk of morbidity. Hence, the **main advantage** of non-operative treatment of thoracolumbar fracture is avoidance of surgery-related complications such as:

The main advantage of non-operative treatment is the avoidance of surgery-related complications

- infection
- iatrogenic neurological injury
- failure of instrumentation
- anesthesia-related complications

The relationship between post-traumatic kyphotic deformity and chronic back pain is not well established in the literature. Most clinicians believe that kyphotic deformity of the thoracolumbar area is synonymous with a poor clinical outcome. Although few studies provide some evidence that moderate kyphosis is associated with either pain or disability [47], several studies suggest that there is no direct relationship between kyphosis and back pain or functional impairment [20, 73, 87, 89, 116].

## Steroid Treatment of Spinal Cord Injury

The controversy over steroid treatment of thoracolumbar spinal cord injury is discussed in the previous chapter (see Chapter 30). The overall consensus is that high-dose steroid treatment is regarded as an option for spinal monotrauma in young patients but not as a guideline for standard of care.

High-dose steroid treatment is highly controversial

## Non-operative Treatment Modalities

As more and more data are collected, information emerges that supports both surgical and non-operative treatment. Non-operative treatment is still a viable and effective treatment for the vast majority of thoracolumbar fractures (Table 6) and should be part of the armamentarium available to all clinicians that treat these patients [92].

**Table 6.** Favorable indications for non-operative treatment

| | |
|---|---|
| • pure osseous lesions | • absence of malalignment |
| • absence of neurological deficits | • absence of gross bony destruction |
| • only mild to moderate pain on mobilization | • absence of osteopenia/osteoporosis |

There are **three different methods** of non-operative treatment:

- repositioning and cast stabilization
- functional treatment and bracing without repositioning
- functional treatment without bracing

However, functional treatment without bracing is not applicable to all fracture types, while basically all fractures can be treated with repositioning and formal casting (Böhler technique).

### Repositioning and Cast Stabilization

Böhler [18] was one of the first to advocate a conservative treatment with repositioning and retention in a cast. The correct technique of repositioning and immobilization in a plaster of Paris cast is quite sophisticated and needs to be performed perfectly to obtain good results [13, 58]. The fracture is reduced using a fracture table with the abdomen hanging freely. The hyperextension results in a fracture reduction by ligamentotaxis (Case Study 1). As a general rule, Böhler

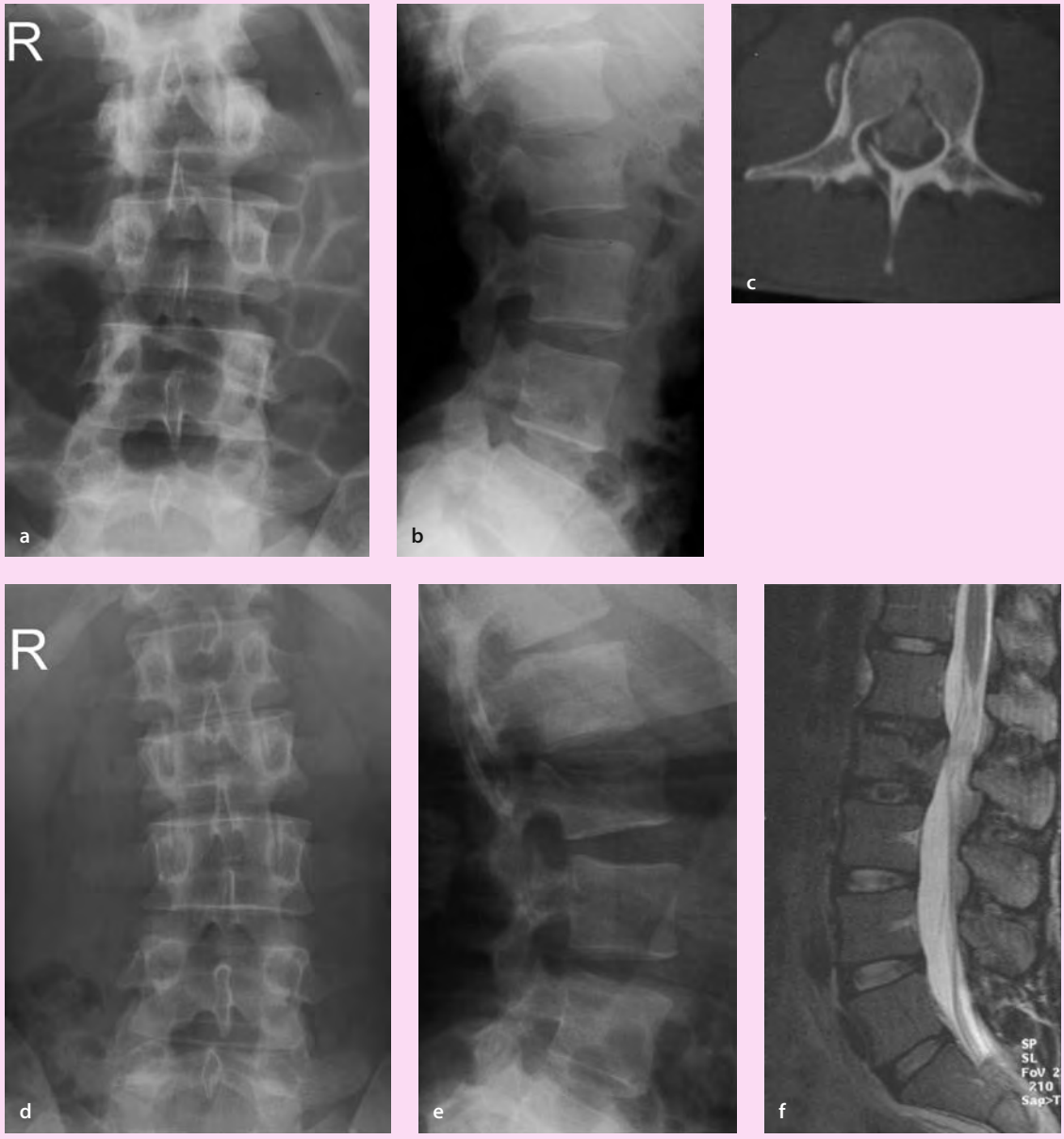


## Case Study 1

In 1988, a 33-year-old male sustained a motor vehicle accident and was admitted to hospital. On examination, the patient had severe pain at the thoracolumbar junction and in his right foot (talus neck fracture). The neurological examination was normal with some slight sensory deficit of L2 predominantly on the right side. Standard radiographs (a, b) revealed a burst fracture at the level of L2 with scoliotic deformity. The axial CT scan showed a burst fracture with severe retropulsion of a dorsoapical fragment and almost complete spinal canal stenosis (c). Despite this severe canal compromise, the patient was treated non-operatively for unknown reasons. The conservative treatment consisted of bed rest for 3–4 weeks in conjunction with reduction on a fracture table and cast fixation. The patient was mobilized thereafter with a thoracolumbar cast. At 4 months the patient was treated with a functional brace for an additional 2 months. The patient was reevaluated 10 years later in a medicolegal context related to his injury. Standard radiographs (d, e) demonstrated significant disc height decrease (L1/2) but without segmental kyphosis. The scoliotic deformity remained unchanged. An MRI scan revealed a complete resorption of the dorsoapical fragment with spontaneous canal clearance, and only mild to moderate disc degeneration at the level of L1/2 and L2/3 (f). At the time of follow-up examination, the patient was fully functional and only had very occasional back pain. This case nicely demonstrates that even severe burst fractures can be treated conservatively with excellent results although today we would suggest surgical treatment in this case to shorten the hospital stay and rehabilitation period. (Courtesy University Hospital Balgrist).

used the kyphosis angle in degrees to calculate the numbers of weeks of immobilization (minimum 12 weeks, maximum 5 months). Patients were allowed to ambulate almost immediately and were discharged home after a couple of days. Regular clinical and radiological exams were performed, initially every 2 weeks, then every 4 weeks, and the cast had to be changed if it became loose. Importantly, an intense and skillful physical therapy was, and still is, paramount to achieving good or satisfactory results.

Böhler's fracture treatment today is still a viable treatment option

The **disadvantage of the Böhler technique** is that it is very uncomfortable and painful for the patient and often requires sedation and strong analgesics. The Böhler technique is also prone to plaster cast related pressure sores. In patients with an indication for conservative treatment, we prefer to apply the cast in the standing position in hyperextension. This is possible in the vast majority of patients after a few days post-trauma and after orthostatic training on a vertically tilted board (Fig. 7).

**Figure 7. Non-operative treatment**

a The patient with an orthostatic problem after a fracture is first placed on a motorized table which can be tilted vertically. b When the patient is able to stand upright for 15–20 min, he is positioned between two vertical bars and moderately extends his spine while the cast is applied. c, d The thoracolumbar cast buttresses onto the iliac crest and reaches up to the sternum

### Functional Bracing

Reduced kyphotic fractures are prone to return to the initial deformity, placing a questionmark over reduction

Magnus [82] advocated early functional treatment without repositioning. According to this concept, a thoracolumbar fracture is bound to return to the initial deformity and repositioning is therefore not necessary. The functional treatment concept was initiated with a phase of prone position on a stable bed and, if necessary, with lordotic support. The time of immobilization in bed depended on the fracture type. The next phases of treatment consisted of physical therapy to enhance muscle strength, mobilization in a waterbath, mobilization with a three point orthesis to prevent flexion and to assure an upright position of the patient, and a discharge home after approximately 3 weeks. Outpatient treatment was continued for another 3–4 months and physical therapy to enhance spine mobility was initiated after radiologic consolidation of the fracture, i.e., after 3–4 months.

### Functional Treatment

Functional treatment is indicated only in unequivocal stable fractures

In contrast to Böhler's repositioning and stabilization [18] or Magnus' functional bracing [82], functional treatment does not include any bracing device. Especially patients with stable fractures will benefit from this treatment (Table 7). Some braces are rather cumbersome and will hinder the patient in many activities of daily life. In fact, braces can be considered an "aide-mémoire" and remind the patient not to perform painful movements. With the functional treatment, patients are advised to mobilize freely according to their capabilities and according to the resulting pain. Importantly, qualified physical therapy and adequate pain medication are necessary to obtain optimal results.

**Table 7.** Outcome of conservative and operative treatment

| Authors | Cases | Study design | Fracture type (numbers) | Type of treatment | Neurological deficit | Follow-up (months) | Outcome | Conclusions |
|---|---|---|---|---|---|---|---|---|
| Weinstein et al. (1988) [116] | 42 | retrospective | burst fractures (T10–L5) | *non-operative:* treatment ranged from immediate ambulation in a body cast or brace to 3 months bed rest | 22% | 240 | neurological deterioration: none<br>able to return to work: 88%<br>kyphotic angle 26.4° in flexion and 16.8° in extension<br>average back pain score 3.5 (0–10) | non-operative treatment of thoracolumbar burst fractures without neurological deficit can lead to acceptable long-term results |
| Mumfordt et al. (1993) [87] | 41 | retrospective | single level thoracolumbar burst fractures T11–L5:<br>type I: 5%<br>type II: 78%<br>type III: 5%<br>type V: 12%<br>(Denis classification) | *non-operative:* bedrest mean: 31.3 (range, 7–68 days)<br>bracing mean 11.9 (range, 2–24 weeks) | none | 24 | functional results:<br>excellent 49%<br>good 17%<br>fair 22%<br>poor 12%<br>one patient developed neurological deterioration that required surgery | for patients with burst fractures without neurological deficit:<br>non-operative management yields acceptable results<br>bony deformity progresses marginally relative to the rate of canal area remodeling<br>radiographic severity of injury or residual deformity does not correlate with long-term symptoms |
| Chow et al. (1996) [23] | 24 | retrospective | unstable burst fractures (T11–L2) | *non-operative:* casting or bracing and early ambulation | None | 34 | no correlation between post-traumatic kyphosis and outcome<br>little/no pain 79%<br>return to work 75%<br>no restrictions at work 75% | hyperextension casting or bracing is a safe and effective method for treatment of thoracolumbar burst fractures |

**Table 7.** (*Cont.*)

| Authors | Cases | Study design | Fracture type (numbers) | Type of treatment | Neurological deficit | Follow-up (months) | Outcome | Conclusions |
|---|---|---|---|---|---|---|---|---|
| Kaneda et al. (1997) [60] | 150 | retrospective | Frankel grades<br>A (24%)<br>B (58%)<br>C (6%)<br>D (7%)<br>E (4%) | *operative:* single stage anterior spinal decompression, strut grafting, and anterior instrumentation | 100% | 96 (60–156) | neurological function improved at least one grade in 95% of patients. 72% of patients with bladder dysfunction recovered completely. 96% returned to work, 86% to their previous job without restrictions | anterior decompression and stabilization in patients with burst fractures and neurological deficit yielded good functional results |
| Knop et al. (2001) [67] | 372 | prospective, multicenter | thoracolumbar fractures (T12–L2) type:<br>A (69%)<br>B (17%)<br>C (14%) | *operative:* Posterior (59%) combined anterior-posterior (35%) anterior (6%) stabilization | 20% | 27 (4–61) | for detailed description see text | all treatment methods resulted in comparable clinical and functional outcome<br>one-third of all patients had severe and persisting functional disabilities |
| Khoo et al. (2002) [62] | 371 | retrospective | N/A | 35% standalone anterior thoracoscopic stabilization<br>65% additional posterior pedicle screw instrumentation | 15% | 24 (4–72) | low rate of severe complications (1.3%); one case each of aortic injury, splenic contusion, neurological deterioration, CSF fluid leak, and severe wound infection<br>42% less narcotics for postoperative pain treatment compared to a group of 30 patients treated with open thoracotomy | anterior thoracoscopic-assisted reconstruction of thoracolumbar fractures can be safely accomplished, reducing pain and morbidity associated with open approaches |
| Defino and Scarparo (2005) [29] | 18 | retrospective | type B and C fractures (AO classification), T10–L4 | *operative:* posterior monosegmental fixation and arthrodesis | 38.9% | 78 (24–144) | low residual pain rates and high level patient satisfaction with final result. 95.5% returned to work and presented with a low disability index (Oswestry Disability Index = 10.33%) | posterior monosegmental fixation is an adequate and satisfactory procedure in specific types of thoracolumbar spine fractures |
| Wood et al. (2005) [122] | 38 | prospective, randomized | isolated burst fractures (T10–L2) | *operative:*<br>18 posterior fusion<br>20 anterior stabilization | none | 43 (24–108) | 17 minor complications in patients treated posteriorly, including implant removal, 3 minor complications with anterior stabilization<br>similar functional outcomes | anterior fusion and instrumentation may exhibit fewer complications and fewer additional surgeries |

## Operative Treatment

### General Principles

There is a general trend towards operative treatment of unstable fractures [31, 47], mostly because **surgical stabilizing** allows for:

- early mobilization of the patient
- diminished pain
- facilitated nursing care (polytraumatized patients)
- earlier return to work
- avoidance of late neurological complications

Despite theoretical advantages, the superiority of surgical fracture treatment is not supported by scientific evidence

However, evidence suggests that there is no difference as regards neurological recovery (**Frankel score**) and no substantial difference in functional long-term outcome between the operative and non-operative treatment [114]. This is clearly valid for compression fractures that are relatively stable, i.e., A1 and A2 fractures, according to the AO classification. Quite frequently, however, studies presented in the literature analyze a mixed cohort of fracture types without further differentiation, which leaves their results somewhat inconclusive.

In burst fractures, there is often some degree of canal compromise with a potential risk of neurological injury. Hence, progressive neurological deterioration in the presence of substantial canal compromise is an indication for surgical decompression and stabilization. Importantly, neurological status, spinal stability, degree of deformity of the injured segment, degree of canal compromise, and associated injuries are the most relevant factors that need to be considered when deciding on operative or non-operative treatment for patients with a thoracolumbar spine fracture. Most surgeons agree on **absolute indications** for surgery while relative indications are debatable (Table 8):

Progressive neurological deficit is an absolute indication for surgery

**Table 8.** Indications for surgical treatment

| Absolute | Relative |
|---|---|
| • incomplete paraparesis<br>• progressive neurological deficit<br>• spinal cord compression w/o neurological deficit<br>• fracture dislocation<br>• severe segmental kyphosis (> 30°)<br>• predominant ligamentous injuries | • pure osseous lesions<br>• desire for early return to regular activities<br>• avoidance of secondary kyphosis<br>• concomitant injuries (thoracic, cerebral)<br>• facilitating nursing in paraplegic patients |

In the absence of class I or II level scientific evidence for the vast majority of fracture types, treatment guidelines remain controversial but a pragmatic approach as used in our center may be useful.

### Spinal Cord Decompression

Decompression of incomplete spinal cord lesions with persistent compression is generally recommended

The severity of a spinal cord injury is related to the force and duration of compression, the displacement and the kinetic energy. Many animal models, including primates, have demonstrated that neurological recovery is enhanced by early decompression [40]. However, this compelling evidence has not been able to be translated into patients with acute spinal cord injury. This may in part be due to: (1) heterogeneous injury patterns and to (2) the absence of thoroughly designed and well-performed randomized controlled trials. However, a number of studies have documented recovery of neurological function after delayed decompression of the spinal cord (months to years) after the injury [4, 14, 15, 76, 112]. The improvement in neurological function with delayed decompression in patients with cervical or thoracolumbar spinal cord injury who have plateaued in their recovery is noteworthy and suggests that compression of the cord is an important contributing cause of neurological dysfunction. Although many clinical studies do not support the concept that surgery improves neurological deficits, most investigators recommend early surgical decompression in cases of an incomplete spinal cord injury and persistent compression of neurogenic structures.

### Timing of Surgery

The timing of surgery remains controversial. While one randomized controlled trial showed no benefit of early (< 72 h) decompression [113], several recent pro-

spective series suggest that early decompression (< 12 h) can be performed safely and may improve neurological outcomes [40].

Early rather than late decompression is recommended

La Rosa et al. [75] published a meta-analysis on the issue of early decompression in acute spinal cord injury. They reviewed 1 687 patients in studies published up to 2000. Patients were divided into three treatment groups: early decompression (< 24 h), delayed decompression (> 24 h), and conservative treatment. Statistically, early decompression resulted in better outcomes compared to both delayed decompression and conservative management. Because the analysis of homogeneity demonstrated that only data regarding patients with incomplete spinal cord injury who underwent early decompression were reliable, the authors concluded that early decompression can only be considered a practice option. Currently, there are no standards regarding the role and timing of decompression in acute spinal cord injury. Also, the presence and duration of a therapeutic window, during which surgical decompression could attenuate the secondary mechanisms of spinal cord injury, remains unclear. In a recent article, Fehlings et al. [40] provide evidence-based recommendations regarding spinal cord decompression in patients with acute spinal cord injury. Animal studies consistently show that neurological recovery is enhanced by early decompression. One randomized controlled trial showed no benefit to early (< 72 h) decompression. Several recent prospective series suggest that early decompression (< 12 h) can be performed safely and may improve neurological outcomes. Currently, there are no standards regarding the role and timing of decompression in acute spinal cord injury. On the other hand, no significant adverse effects of early decompression have been documented. In the absence of clear guidelines from the literature, early decompression of compressed neurological structures appears to be best practice.

Early decompression of progressive neurological deficits is indicated

## Surgical Techniques

If surgical treatment is chosen, further debate arises over the appropriate type of approach. Similarly to the treatment decision of conservative vs. operative, scientific evidence is lacking for the superiority of one surgical technique over the other. Particularly for the frequent superior burst fracture (Fig. 3), a large variety of surgical techniques are available. Finally, it depends on the surgical expertise of the surgeon and their preference which technique is chosen. It is difficult to base treatment recommendations on treatment outcome in the literature (Table 7).

### Posterior Approach

#### *Posterior Monosegmental Reduction and Stabilization*

Posterior monosegmental reduction and stabilization is feasible in selected Type A and B fractures

The group of Gotzen et al. [49, 59] was the first to publish their results after monosegmental reduction and stabilization (Case Study 2). In their initial report [49], 14 patients with unstable compression fractures Grade II were treated by posterior one-level internal fixation (9 patients had stabilization with plates and cerclage wire, 5 with internal fixator). The results were compared to a series of 11 patients with equivalent fractures treated non-operatively. The authors conclude that posterior single level stabilization and fusion is a recommendable surgical procedure. In their second publication, Junge et al. [59] describe the technique, which always included a posterior allogenic bone grafting and to some extent also transpedicular bone grafting. The 2-year follow-up of 39 patients demonstrated that 17 patients (43 %) were completely free of pain and 17 patients were only sensitive to weather changes or had minor pain during great physical stress.

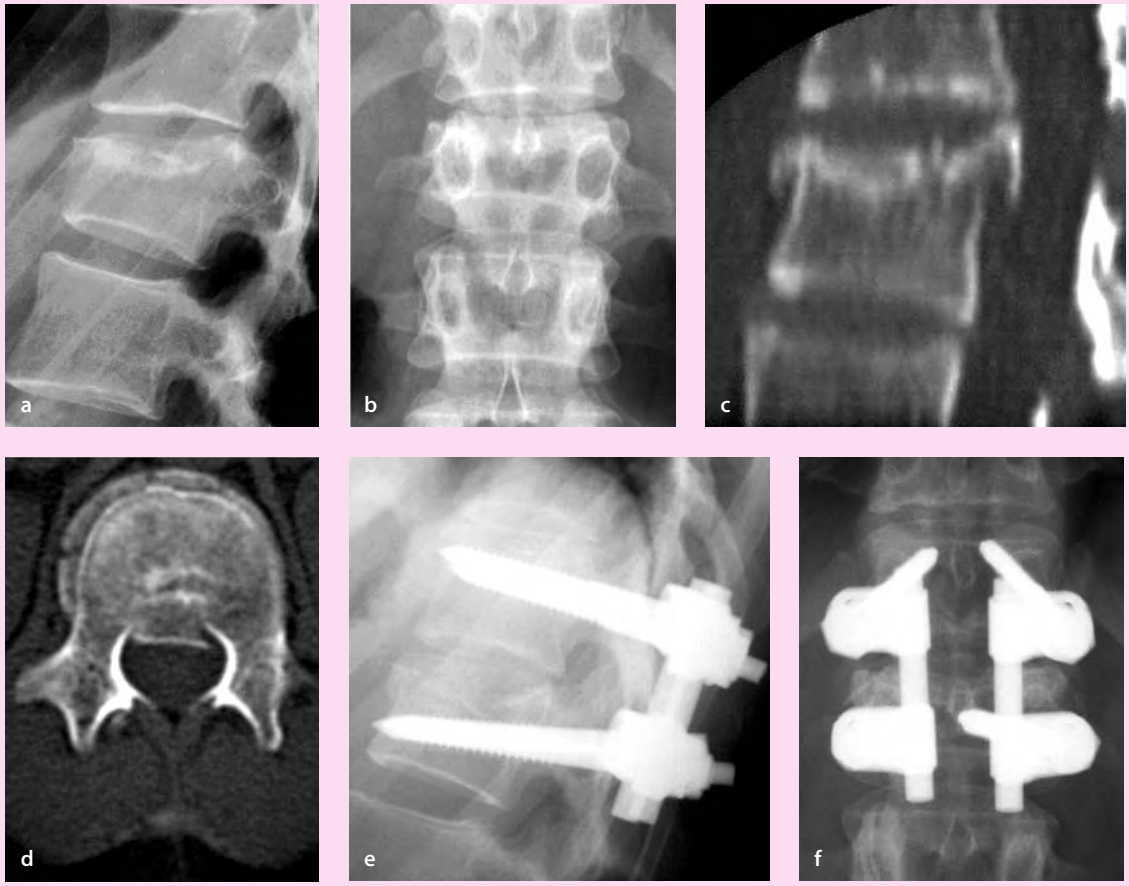


## Case Study 2

This 39-year-old female fell from her bike and complained about severe back pain at the thoracolumbar junction. On admission, the patient was neurologically intact. Standard anteroposterior and lateral radiographs demonstrated an incomplete burst fracture of L1 (a, b). The sagittal CT reformation confirmed the diagnosis of a superior burst fracture (c). The axial CT scan showed a minor dislocation of the dorsoapical vertebral fragment without neural compromise and intact pedicles (d). Based on this fracture type non-operative as well as operative treatment was discussed. The patient opted for surgery and preferred the posterior over the anterior approach. The spine was instrumented monosegmentally with the lower screw aiming towards the intact anterior vertebral cortex. A posterolateral fusion was added with autologous bone graft from the iliac crest. Follow-up radiographs (e, f) demonstrated an anatomic reduction of the fracture. The patient was fully mobile on the first postoperative day and remained symptomfree during a 5 years follow-up. (Courtesy University Hospital Balgrist).

However, five patients (13%) had pain even during slight physical stress or at rest. Importantly, no implant fatigue failure was noted although five minor complications occurred.

One-level posterior instrumentation is indicated only in incomplete burst fractures with intact pedicles

Wawro et al. [115] also published a small series of 14 patients that were stabilized over a single segment. In addition, they characterized the fracture type in which single-segment stabilization is possible and described differences in the operation technique compared with multisegmental internal fixation. For example, the pedicle screws occasionally needed to be inserted extremely close to the endplates if the remaining part of the vertebral body had been destroyed and could therefore not provide stability. Contraindications to a monosegmental posterior stabilization are broken pedicles and complete burst fractures of the body. In accordance with our concept, only incomplete burst fractures with intact pedicles

and inferior endplate (i.e., Type A1 and A3.1) should be considered for posterior monosegmental reduction and stabilization. Probably the pathophysiologically most sound indication for a monosegmental dorsal stabilization is a Type B fracture with only ligamentous posterior injury combined with a Type A1 or A3.1 fracture of the vertebral body with intact endplates and intact pedicles, because the dorsal stabilization restores the tension band function of the ruptured ligaments.

In a similar small series of 18 patients undergoing posterior monosegmental stabilization, Defino et al. [29] report a clinical and radiological follow-up after 2–12 years (mean 6.6±3 years) to demonstrate that posterior monosegmental fixation is an adequate and satisfactory procedure in specific types of thoracolumbar spine fractures. Clinical evaluation revealed low residual pain rates and a high level of patient satisfaction with the final result. Functional evaluation showed that 95.5 % of the patients returned to work on a full-time basis and presented with a low disability index (Oswestry Disability Index = 10.33 %). Radiographic evaluation demonstrated increased kyphosis in the fixed vertebral segment during the late postoperative period, accompanied by a reduced height of the intervertebral disc. There was no implant failure, and no signs of pseudoarthrosis were observed in any patient.

### *Posterior Bisegmental Reduction and Stabilization*

Posterior two-level reduction and fracture stabilization remains the gold standard for the vast majority of thoracolumbar fractures

The bisegmental, two-level posterior approach (short segmental stabilization) is the "working horse" of the posterior techniques that allows a secure fixation of the pedicle screws in the intact vertebra one level above and below the fracture (Fig. 8). With this construct, a good reduction and stable fixation is reliably achieved.

Fredrickson et al. [45] studied the mechanisms of ligamentotaxis to reduce the intracanal fragment of a burst fracture. Examination of anatomic data provided by microtome section indicated that the fibers that actually reduce the intracanal fragment originate in the anulus of the superior vertebra in the midportion of the endplate and insert into the lateral margins of the intracanal fragment. Investigations using MRI confirmed that these obliquely directed fibers account for the indirect reduction of the fragment. Further studies demonstrate that the posterior longitudinal ligament provided only a minor contribution in the reduction of the fracture in comparison to the attachments of the posterior portion of the anulus fibrosus.

Harrington et al. [51] studied the biomechanics of indirect reduction of bone retropulsed into the spinal canal in vertebral fracture and made several clinically relevant observations. It was not possible to produce an anteriorly directed force in the posterior longitudinal ligament at less than 35 % canal occlusion, partly because the posterior longitudinal ligament stands away from the midbody of the vertebra. Regardless of the relative sagittal plane angulation of the vertebrae, distraction was the governing factor in generating force in the posterior longitudinal ligament. Because positioning the vertebrae in lordosis before applying distraction significantly slackens the posterior longitudinal ligament, it is suggested that distraction be applied before angular positioning of the vertebrae is performed. However, this procedure risks overdistraction with deleterious results for the spinal cord.

A comminuted anterior column demands anterior load sharing support

Depending on the comminution of the fractured vertebral body, additional anterior load sharing support is needed. McLain et al. [85] reported early failure of short-segment pedicle instrumentation for thoracolumbar fractures. Out of 19 patients with unstable thoracolumbar fractures, 10 patients had early failure of fixation: progressive kyphosis, osseous collapse, vertebral translation, screw

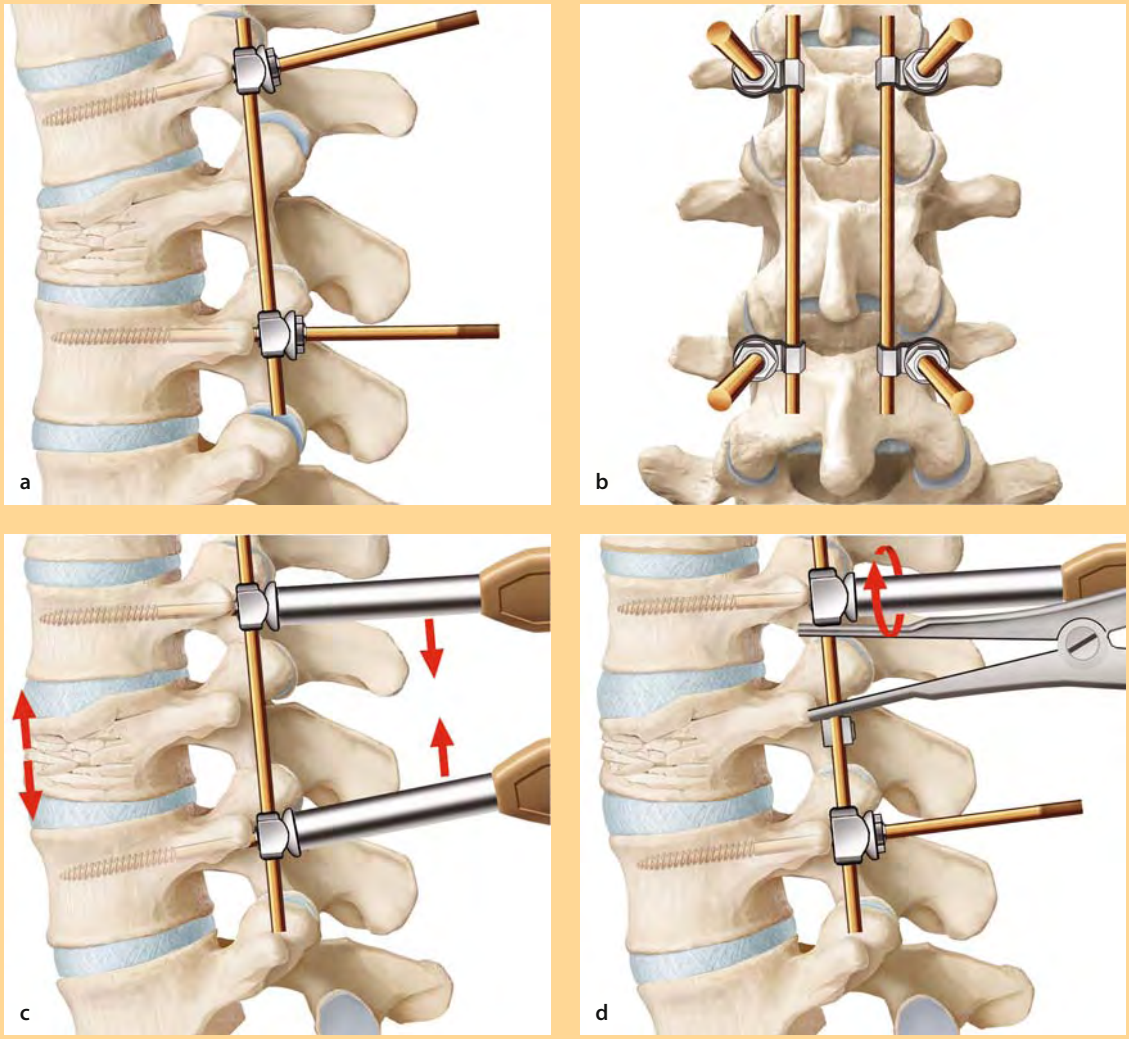


**Figure 8. Surgical technique of two-level fracture reduction and stabilization**

The technique demonstrates the use of the Fracture Module of Universal Spine System (Synthes) but the general principles similarly apply to other fracture systems. a Schanz screws are inserted in the pedicles of the vertebral bodies superior and inferior to the fracture. b Screw clamps connected with the rods are mounted and fixed (*arrow*). c The fracture can be reduced by lordosing both screwdrivers. However, it is often better to first tighten the two lower screws and reduce the fracture simultaneously by lordosing the cranial screw bilaterally with the help of the screwdriver. d If this reduction maneuver does not suffice to restore vertebral height, a temporary C-clamp can be mounted and the fracture distracted after loosening the upper screws. Care must be taken not to overdistract the fracture because of the inherent neurological risks. Finally, the Schanz screws are cut with a special screwcutter (not shown). Dependent on canal clearance and anterior vertebral column restoration, an additional anterior approach can be added (preferably in a second stage)

breakage or loosening. These results indicate the need for an adequate anterior column support and an optimal anterior-posterior column load sharing environment.

Transpedicular cancellous bone grafting is insufficient to stabilize the anterior column

If no anterior stabilization is planned, a posterolateral fusion [78, 88] is mandatory. In addition, transpedicular bone grafting in the disrupted disc space has been a treatment option [26, 78, 90]. However, transpedicular bone grafting could not prevent kyphosis after dorsal removal on implants [1, 68, 108]. Knop et al. [68] studied 56 patients after implant removal and concluded that, because

of the disappointing results, they cannot recommend the additional transpedicular cancellous bone grafting as an interbody fusion technique after posterior stabilization in cases of complete or incomplete burst injury to the vertebral body. Similarly, Alanay et al. [1] concluded that short-segment transpedicular instrumentation of thoracolumbar burst fractures is associated with a high rate of failure that cannot be decreased by additional transpedicular intracorporeal grafting.

#### *Posterior Reduction and Multisegmental Stabilization*

Fracture dislocations usually require multilevel spinal stabilization

Multilevel stabilization is indicated for the very unstable thoracolumbar luxation fractures (Type C lesions) which usually cannot be accurately reduced and stabilized with a short two-level construct. Usually, fixation of two to three segments above and below the injury is recommended for a stable fixation. Unstable fractures of the thoracic spine that need to be stabilized are often combined with a significant thorax trauma or a polytrauma. In these patients, an early posterior stabilization with additional bone grafting allows for (1) a stable fixation of the spine with restoration of the dorsal tension band function, (2) the possibility of early and orthosis-free mobilization in the intensive care unit or later in a center of rehabilitation, and finally (3) bony fusion.

### Anterior Approach

Rationale for the anterior approach is that the spine should be treated where the injury has occurred

From the biomechanical point of view, it is obvious that the damaged spine has to be treated according to the injury mechanism and the site of injury. In a flexion injury (e.g., Chance fracture) with fracture of the pedicles and the vertebral body, stabilization can be performed by a dorsal approach and restores the tension band function until bony healing has occurred. Similarly, the biomechanics of the anterior column has to be considered in the case of a burst fracture. About 80 % of the axial load of an intact spine is supported by the anterior column. When the anterior column is substantially injured, the anterior support is dramatically reduced to about 10 %, leaving 90 % of the load to be resisted by the implant and the posterior elements. These general biomechanical considerations support the use of an anterior load sharing support (e.g., by a tricortical bone graft or a cage).

The **primary indications** for the anterior approach are:

- insufficient spinal decompression
- insufficient anterior column restoration

Spinal canal compromise in patients presenting with neurological deficits which cannot adequately be resolved by a dorsal approach alone requires anterior decompression. An additional indication is a vertebral body fracture with substantial comminution and dislocation which cannot be adequately restored by a posterior approach alone [50].

Type A fractures can be treated by an anterior approach alone

However, Type A fractures can be treated by an anterior approach alone. Kaneda et al. [60] reported a study on 150 consecutive patients who had a burst fracture of the thoracolumbar spine and associated neurological deficits. The patients were managed with a single-stage anterior spinal decompression, strut-grafting, and anterior spinal instrumentation. At a mean of 8 years (range 5 – 12 years) after the operation, radiographs showed successful fusion of the injured spinal segment in 140 patients (93 %). Ten patients had a pseudarthrosis, and all were managed successfully with posterior spinal instrumentation and a posterolateral arthrodesis. Despite breakage of the Kaneda device in nine patients, removal of the implant was not necessary in any patient. None of the

patients had iatrogenic neurological deficits. Subsequent to anterior decompression, the neurological function of 142 (95%) of the 150 patients improved by at least one Frankel grade. Fifty-six (72%) of the 78 patients who had preoperative paralysis or dysfunction of the bladder recovered completely. One hundred and twenty-five (96%) of the 130 patients who were employed before the injury returned to work after the operation, and 112 (86%) of them returned to their previous job without restrictions. The authors concluded that anterior decompression, strut-grafting, and fixation with the Kaneda device in patients who had a burst fracture of the thoracolumbar spine and associated neurological deficits yielded good radiographic and functional results.

Wood et al. [122] conducted a prospective randomized study to evaluate differences in radiographic, clinical, or functional outcomes when individuals with stable burst fractures of the thoracolumbar junction (T10–L2) without neurological deficit are treated with either a posterior fusion with instrumentation or anterior reconstruction, fusion, and instrumentation. Of 43 enrolled patients, 38 completed a minimum 2-year follow-up (average: 43 months; range: 24–108 months). Eighteen patients received a posterior spine fusion and 20 an anterior approach. There were 17 "complications" including instrumentation removal for pain in 18 patients treated posteriorly, but only 3 minor complications in 3 patients treated anteriorly. Patient-related functional outcomes were similar for the two groups. The authors concluded that although patient outcomes are similar, anterior fusion and instrumentation for thoracolumbar burst fractures may present fewer complications or additional surgeries. Hence, using minimally invasive techniques (see below) the collateral damage can significantly be reduced, which increases the indications for the anterior approach in stable thoracolumbar fractures.

Sasso et al. [103] retrospectively analyzed 40 patients with unstable thoracolumbar injuries that were operated on between 1992 and 1998. The study was conducted to evaluate the efficacy of stand-alone anterior decompression and reconstruction of unstable three-column thoracolumbar injuries, utilizing current-generation anterior spinal instrumentation. According to the AO classification, there were 24 (60%) Type B1.2, 10 (25%) Type B2.3, 5 (12.5%) Type C1.3, and 1 (2.5%) Type C2.1 injuries. One early construct failure due to technical error is reported. Thirty-seven of the remaining patients (95%) went on to apparently stable arthrodesis. The authors conclude that current types of anterior spinal instrumentation and reconstruction techniques can allow some types of unstable three-column thoracolumbar injuries to be treated in an anterior stand-alone fashion. This allows direct anterior decompression of neural elements, improvement in segmental angulation, and acceptable fusion rates without the need for supplemental posterior instrumentation.

Selected Type B and C fractures can be treated with an anterior approach alone when using rigid angle-stable anterior fixation

### *Minimally Invasive Approach*

Conventional surgical approaches for the treatment of thoracic and thoracolumbar fractures require extensive exposure and often lead to significant postoperative pain and morbidity. In order to reduce the collateral damage created by the large surgical access, lesser and minimally invasive methods have been developed (**Case Study 3**). The use of a retractor system such as SynFrame allows the anterior spine to be accessed in an open but minimally invasive way. In an analysis of the first 65 patients, Kossmann et al. [72] reported no intra- or postoperative complications related to this minimally invasive procedure. In addition, no intercostal neuralgia, no post-thoracotomy pain syndromes, no superficial or deep wound infections and no deep venous thromboses occurred.

Access technology has contributed to minimizing collateral damage by the anterior approach

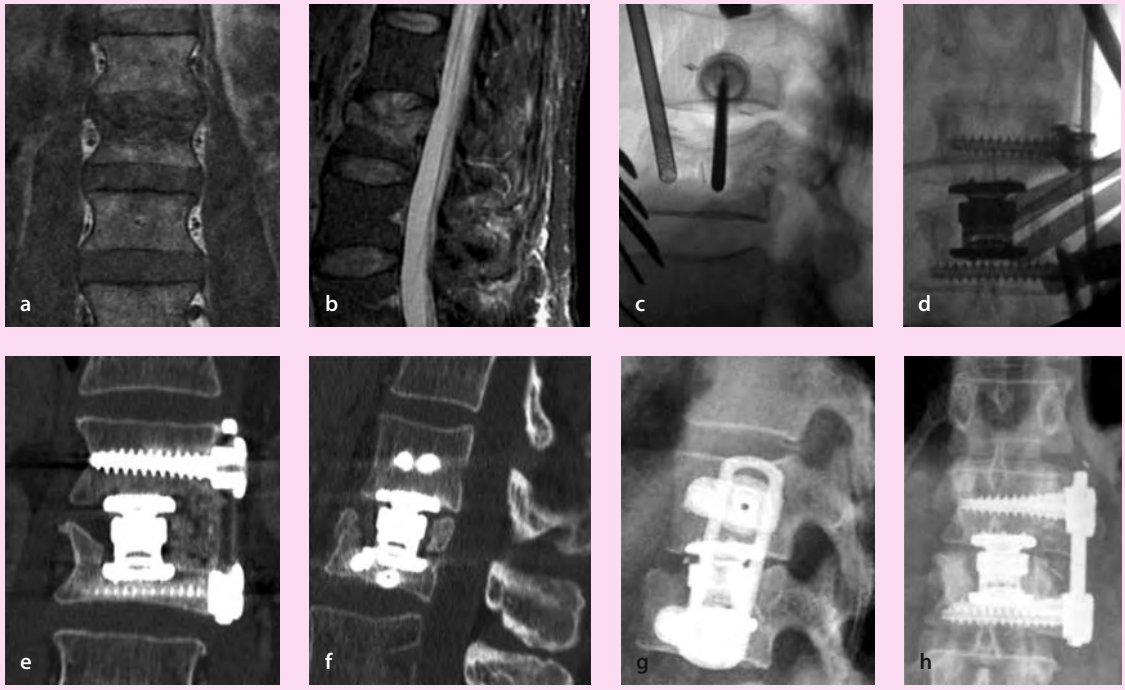


## Case Study 3

This 48-year-old female fell from a horse and presented with an incomplete burst fracture of L2 (Type A3.1) without neurological deficits (ASIA E). The MRI scan (a, b) was performed to evaluate the integrity of the dorsal elements. The coronal view (a) shows the T1 sequence and demonstrates a cranial fracture of L2 and a rupture of the disc L1/L2. The STIR sequence (b), which is very sensitive to edema, confirms the fracture of the vertebral body but does not show any evidence of a posterior injury. This allows the distinction between a Type A injury and an unstable Type B injury and helped us to choose the operative approach. We performed a monosegmental anterior stabilization with an expandable cage (Stryker) and an angular stable implant (MACS), which was especially designed for the thoracoscopic technique (c, d). After a small diaphragmatic split, one of the first steps is the positioning of a K-wire just above the endplate of L2 (c); in this figure, the retractor (*left*), the suctioning device (*middle*) and the aiming device for the K-wire (*right*) can be distinguished. The polyaxial screws are inserted under fluoroscopic control, the ruptured disc and the cranial part of the fractured vertebral body are removed, and the cage is inserted (d). The postoperative control radiographs (e–g) demonstrate a correct positioning of the screws in the anteroposterior view (e) and lateral view (f); in addition, the local bone transplant on the right side of the cage is seen in e. The conventional X-rays (g, h) demonstrate a physiologic alignment and a correct positioning of the implants.

Minimally invasive anterior access technologies offer perioperative advantages

Thoracoscopic spinal surgery is another technique that reduces the morbidity of extensive surgical approaches while it still achieves the primary goals of spinal decompression, reconstruction, and stabilization. Since the development of specially designed instruments and implants, the "pure" thoracoscopic operation technique has become possible and feasible. Through the transdiaphragmatic approach it was also possible to open up the thoracolumbar junction, including the retroperitoneal segments of the spine, to the endoscopic technique. In an early series, Bühren et al. [19] analyzed 38 patients. The authors conclude that, compared to the open method, minimally invasive surgery had the benefit of reducing postoperative pain, shortening hospitalization, leading to early recovery of function and reducing the morbidity of the operative approach. These findings have been confirmed in later reports [8, 9, 62]. The rate of severe complications was low (1.3 %), with one case each of aortic injury, splenic contusion, neurological deterioration, cerebrospinal fluid leak, and severe wound infection [62]. Overall, the complication rate was not increased when compared to the

open technique; however, there were clear advantages in terms of the reduced access morbidity.

Importantly, the endoscopic technique is also effective for anterior spinal canal decompression. Beisse et al. [8] published a series of 30 patients with thoracolumbar canal compromise that underwent endoscopic anterior spinal canal decompression and report that 25 % of patients with complete paraplegia and 65 % of those with incomplete neurological deficit improved neurologically.

The following factors have gradually opened up the entire spectrum of anterior spine surgery to endoscopic techniques [9]:

- a standardized operating technique
- instruments and implants specially developed for the endoscopic procedure, i.e.:
- angle-stable plate and screw implants and
- endoscopically implantable vertebral body replacements

### Combined Anterior-Posterior Approach

Studies on posterior stabilization of thoracolumbar fractures demonstrated that fractures with comminution of the anterior column often lead to early failure [85]. Therefore, **in addition** to the posterior two-level repositioning and stabilization, several techniques were introduced to stabilize the anterior column: iliac anterior crest [41], possibly in an inlay technique [71] or with vertebral body replacements in different materials, shapes, sizes, and configurations (i.e., non-expandable vs. expandable cages). In our institution, we prefer to adhere to a two-staged procedure that includes (Case Introduction):

- **Stage 1:** posterior fracture reduction and usually a two-level stabilization (w/o decompression depending on neural compromise)
- **Stage 2:** delayed anterior surgery depending on the patients' condition

Many peers recommend a combined posterior/anterior approach for unstable fractures

It is evident that, although posterior reduction and stabilization provides effective restoration of the sagittal alignment, the reduction capability of the intracanal bone fragments is distinctly limited [50, 107, 123]. The anterior reconstruction method permits effective decompression of the spinal canal and offers superior mechanical stability compared with the indirect decompression and stabilization of posterior instrumentation.

### Treatment Guidelines

Most treatment recommendations are not based on scientific evidence

The conflicting results and the diversity of studies presented in this chapter indicate that there is no gold standard for the vast majority of fractures and treatment decisions are almost always lacking scientific evidence. Treatment options are often based on the experience and the tradition of the institute and the treating physicians. Importantly, the patient and the treating team must be aware of the attainable results, the time course of the treatment, the pitfalls, and the complication of the respective method, be it conservative or operative. Under these limitations, we have summarized some general guidelines (Fig. 9). However, we want to emphasize that these general recommendations may not apply to the individual case and confounding variables have to be considered, e.g., general condition, injury pattern, polytrauma, age, associated diseases, etc.

Critically evaluate anecdotal treatment recommendations before adaptation

**Type A1 fractures** are usually treated conservatively. However, if kyphosis becomes relevant (more than 20°–25°) an operative correction of the kyphosis has to be considered. In this case, we advocate an early correction, i.e., when the fracture is not consolidated and still can be reduced to avoid more complex and difficult correction surgery in a later stage. Also **Type A2 fractures** can be treated

| | Type A | Type B | Type C |
|---|---|---|---|
| **Group 1** | functional treatment / functional bracing / thoracolumbar cast, if: kyphosis <20-25° | posterior approach [2,4,5] w/o anterior approach[4] | posterior approach[4,6] w/o anterior approach[4] |
| **Group 2** | functional bracing / thoracolumbar cast (A 2.1 or A2.2 lesions)<br>anterior approach[1] (A2.3 lesions) or posterior approach[2] (A2.3 lesions) | thoracolumbar cast, if:<br>• normal neurology<br>• kyphosis <20-25°)<br>• purely osseous lesion (Chance fracture)<br>posterior approach[2,3] w/o anterior approach[4] | posterior approach[4,6] w/o anterior approach[4] |
| **Group 3** | thoracolumbar cast, if:<br>• normal neurology<br>• kyphosis <20-25°)<br>• less comminuted anterior column | posterior approach[2,3] | posterior approach[4,6] w/o anterior approach[4] |
| | anterior approach[1,3] or posterior approach[2,3,4] | | |

**Figure 9. General treatment guidelines**

[1] Corpectomy, interbody fusion with strut graft/cage, anterior instrumentation
[2] Two-level instrumentation, reduction, posterolateral fusion (optional with one-level fusion and posterior implant removal after 10–12 months to liberate the uninjured segment)
[3] One-level stabilization and fusion possible in cases of monosegmental lesions (incomplete burst fractures, anterior disc disruption)
[4] Additional anterior approach (corpectomy w/o decompression, interbody fusion with strut graft/cage) is indicated in cases of persistent neural compression (incomplete canal clearance) or comminuted anterior column or to enhance fusion in discoligamentous injuries
[5] One-level stabilization and fusion possible in cases of discoligamentous injuries or concomitant incomplete burst fractures
[6] Multilevel stabilization often required (two or three levels above/below the injury)

conservatively with the exception of A2.3 type fractures, the so-called **"pincer" type**. In this fracture type, both discs are usually ruptured and pushed into the fractured vertebral body. This injury pattern often leads to non-union and results in painful instability. From a pathophysiological and biomechanical view, an anterior approach makes most sense in these A2.3 fractures, because the pathology is treated where the pathology is located. Probably the most controversy exists in **A3 type fractures** particularly the incomplete burst fracture (A3.1). In this fracture type, the accepted treatments range from bracing to combined anterior/posterior approach all with acceptable results (Case Studies 2, 3). The treatment options depend on the comminution of the vertebral body, the degree of kyphosis, and the presence or absence of neurology. If one decides to stabilize A3 fractures, the goal of neural decompression, sagittal alignment, and anterior support will dictate the operative approach. In an emergency situation, a primarily posterior approach will allow to reduce and stabilize the fracture with an internal fixator with or without laminectomy to decompress neural structure (Case Introduction). At a later stage, the surgeon can decide if an additional anterior approach is needed, based on the persistence of neurological compression and the comminution of the anterior column. A CT scan after the postoperative

Pincer fractures are prone to non-union and are better treated surgically

Type A3.1 fractures are the most controversial ones regarding treatment recommendations

approach is often helpful for decision making. Alternatively, an anterior approach only with corpectomy, interbody fusion with strut graft/cage, and anterior instrumentation will provide an appropriate stabilization (see Case Study 3).

The paradigm of a primarily posterior approach with or without an additional anterior operation is also true for Type B and Type C fractures. One exception is the **purely osseous "Chance" fracture**, because fractured bones heal better and faster than ligamentous injuries. In this case, a thoracolumbar cast fixation that prevents flexion/distraction movements of the injured segment is applied for 6–8 weeks. Alternatively, one might also prefer to treat Chance fractures with an operative stabilization and restore the ruptured tension band with a posterior bisegmental stabilization without posterolateral fusion. Removal of the hardware is then usually performed after 4 months. In **B-type fractures**, posterior stabilization is usually performed with a two-level instrumentation, reduction, and posterolateral fusion or optionally with a one-level fusion and posterior implant removal after 10–12 months to liberate the uninjured segment. Alternatively, two-level stabilization and fusion is possible in Type B cases with discoligamentous injuries or concomitant complete burst fractures. The decision whether an additional anterior support is necessary or not depends on the persistence of neural compression (**incomplete canal clearance**) or the comminution of the anterior column or the need to enhance arthrodeses by adding an interbody fusion. In **Type C injuries**, multilevel stabilization is often required (two or three levels above/below the injury) for reduction and stabilization. Additional anterior surgery again depends on canal clearance and anterior column reconstruction.

The indication for an additional anterior approach depends on neurological compromise and anterior column comminution

Type C injuries are very unstable and commonly require multisegmental fixation

## Outcome of Operative Versus Non-operative Treatment

Despite many theoretical advantages of operative spinal fracture treatment, there is a lack of scientific evidence which supports the benefits of surgery (Table 9). Many studies were not able to prove a substantial difference in functional outcome between the operative and non-operative treatment, regardless of the neurological injury [16, 17, 20, 73, 87, 92, 105, 116, 121]. Chow et al. [23] retrospectively reviewed 24 neurologically healthy patients (mean follow-up of 34 months) with unstable thoracolumbar burst fractures (T11–L2) managed with either casting or bracing and early ambulation. Clinical follow-up examination was performed by the use of a questionnaire in which the patients were asked to rate their pain, ability to work, ability to perform in recreational activities, and their overall satisfaction with treatment. Kyphotic deformity could be corrected with hyperextension casting but tended to recur during the course of mobilization and healing, as hypothesized by Magnus [82] and confirmed by other studies [96, 111]. No correlation was found between kyphosis and clinical outcome. At final follow-up evaluation, 79% had little or no pain; 75% had returned to work; 75% stated that they had few or no restrictions in their ability to work; and 67% stated that they had few or no restrictions in their ability to participate in recreational activities. Only one patient (4%) reported being dissatisfied with the initial non-operative treatment of his spine fracture. The authors conclude that non-operative management of thoracolumbar burst fractures with hyperextension casting or bracing is a safe and effective method of treatment in selected patients.

Favorable outcome has been reported with conservative as well as operative treatment when applying the correct technique

In the series of Daniaux et al. [27], 85% of patients with a thoracolumbar fracture were treated conservatively. In 40%, a functional treatment was possible; these were patients with stable impaction and split fractures as well as burst fractures that were considered to be stable and that had a kyphotic deformity of less than 10° for T12–L2 and 15° for T11, respectively. In 45%, a repositioning and

**Table 9.** Operative vs. non-operative treatment

| Authors | Cases | Study design | Fracture type (numbers) | Type of treatment | Neurological deficit | Follow-up (months) | Outcome | Conclusion |
|---|---|---|---|---|---|---|---|---|
| Burke and Murray (1976) [17] | 115 (140) | retrospective | flexion/rotation (80)<br>compression fractures (27)<br>pure ligamentous injuries (3)<br>hyperextension (2)<br>other (3) | 89 *non-operative* (postural reduction)<br>26 *operative* (posterior stabilization ± laminectomy) | 62 % | N/A | *conservative:*<br>secondary spinal fusion $n=3$<br>severe chronic pain: 2 neurological improvement 35 %<br>*operative:*<br>severe chronic pain $n=8$<br>Neurological improvement 38 % | the indication for early surgery might be still further restricted. |
| Rechtine et al. (1999) [93] | 235 | chart review for complications | unstable thoracolumbar fractures | 117 *operative*<br>118 *non-operative* 6 weeks bed rest) | | N/A | comparable rates of decubitus, deep venous thrombosis, pulmonary emboli, and mortality between both groups<br>8 % deep wound infections after operative treatment<br>shorter hospital stay after operative treatment | both treatment modalities are viable alternatives |
| Shen et al. (2001) [105] | 80 | prospective | single-level burst fractures T11–L2, no fracture dislocations or pedicle fractures | *47 non-operative:*<br>using a hyperextension brace<br>*33 operative:*<br>posterior fixation | none | 288 | less pain in the surgical group after 3 and months. Complications after surgery: 1 superficial infection and 2 broken screws<br>hospital charges were 4 times higher in the operative group | posterior fixation provides partial kyphosis correction and earlier pain relief. Functional outcome at 2 years is similar |
| Wood et al. (2003) [121] | 47 | prospective, randomized | single thoracolumbar burst fractures (T10–L2) | *24 operative:*<br>posterior or anterior instrumented fusion<br>*23 non-operative*:<br>body cast or orthosis | none | 44 | no difference between groups was found in terms of pain, and return to work. Non-operatively treated patients reported less disability | no long-term advantage for operative treatment of burst fractures compared with non-operative treatment |

retention in a cast according to Böhler's principles was performed. A repositioning was possible in 90 %; however, only 50 % could be maintained over the treatment period, 20 % returned to the initial kyphotic level and 5 % had a worse result.

Reinhold et al. [95] reviewed 43 patients 16.3 years after thoracolumbar fracture and non-operative therapy. On average, patients showed a radiologic increase in the kyphosis angle of 5.2° compared to the time of injury. No difference was noted between early functional therapy and treatment with closed reduction and immobilization by cast. Results of validated psychometric questionnaires such as SF-36 and VAS showed the characteristic pattern of a population with chronic back pain. The authors conclude that a radiologic increase in the traumatic kyphotic deformity in patients with a non-operative treatment protocol has to be expected and that measurable negative physical and social long-term consequences can be anticipated after sustaining a Type A fracture of thoracolumbar vertebral bodies. However, no correlation between radiologic and functional results was observed.

In an earlier report, Weinstein et al. [116] also addressed the long-term results of 42 patients with non-operative treatment for fractures of the thoracolumbar spine. Average time from injury to follow-up was 20.2 years. At follow-up, the average back pain score was 3.5, with 0 being no pain at all and 10 being very severe pain. No patient required narcotic medication for pain control. Eighty-eight percent of patients were able to work at their usual level of activity. Follow-up radiographs revealed an average kyphosis angle of 26.4° in flexion and 16.8° in extension. The degree of kyphosis did not correlate with pain or function at follow-up.

Burke et al. [17] reported in his retrospective study that 3 of 89 patients with conservative therapy required a secondary spinal fusion for suspected instability after a period of conservative treatment. Frankel [44] found that 2 of 394 conservatively treated patients required surgery because of instability.

Braakman et al. [16] prospectively studied 70 consecutive patients with injuries of the thoracic and lumbar spine with a neurological deficit. The authors could not establish a difference in neurological recovery between those patients who were managed conservatively and those in whom a surgical decompression and stabilization procedure was performed. Surgical stabilizing procedures, however, resulted in immediate stabilization of the spine, diminished pain, facilitated nursing care and allowed more rapid mobilization and earlier active rehabilitation.

Shen at al. [104] studied 38 patients after functional treatment with a follow-up of 4.1 years. Four patients had moderate pain, 2 had moderate to severe pain, and 29 (76%) were able to work at the same level. The authors conclude that activity restriction and bracing may be important for pain control but probably do not change the long-term result. The same authors [105] also conducted a prospective trial with 80 patients to compare the results of non-operative treatment ($n = 47$) versus short-segment posterior fixation using pedicle screws; follow-up was 2 years. They found that posterior fixation provides partial kyphosis correction and earlier pain relief, but the functional outcome at 2 years is similar.

Wood et al. [121] published a prospective, randomized study comparing operative (posterior or anterior arthrodesis and instrumentation) and non-operative treatment (application of a body cast or orthosis) of stable thoracolumbar burst fractures in 47 patients without neurological deficit. After treatment, patients indicated the degree of pain with use of the visual analog scale and they completed the Roland and Morris Disability Questionnaire, the Oswestry Back-Pain Questionnaire, and the Short Form-36 (SF-36) Health Survey. No significant difference was found between the two groups with respect to return to work. The preinjury scores were similar for both groups; however, at the time of the final follow-up (on average after 44 months), those who were treated non-operatively reported less disability. The authors conclude that operative treatment of patients with a stable thoracolumbar burst fracture and normal findings on the neurological examination provided no major long-term advantage compared with non-operative treatment.

The superiority of surgical fracture treatment is not well supported in the literature

Rechtine et al. [93] reviewed the medical charts of 235 patients with thoracolumbar fractures to evaluate a difference in the occurrence of complications after conservative (118 patients) or operative treatment (117 patients). There was no significant difference in the occurrence of decubitus, deep venous thromboses, pulmonary emboli, or mortality between the two groups. Deep wound infections occurred in 8% of the operative cases. However, the length of stay was 24 days longer in the non-operative group. The authors conclude that the selection of treatment method remains a matter of controversy.

## Complications

The reported complication rate in the literature varies largely

A surgery-related complication is a relevant shortcoming of any operative procedure with potentially devastating consequences, especially in spine surgery (see Chapter 39). The reported complication rate in the literature is largely variable and critically dependent on the pathology and type of surgery [7, 8, 19, 25, 34, 35, 38, 39, 42, 62, 68, 70, 83, 102, 110, 115].

One of the largest series which considered complications in the surgical treatment of spinal fractures is the multicenter study of the Spine Study Group of the German Trauma Association (DGU). Knop et al. [69] reviewed sources of error and specific complications [67, 65, 66]. A total of 682 patients were operated on for acute traumatic injuries of the thoracolumbar spine. In 101 cases (15 %) at least one complication occurred intra- or postoperatively. In 41 patients (6 %) a revision was performed, and in 60 patients (9 %) complications without operative revision were observed. Typical errors and possible complications during operations were related to different steps of the operation:

- positioning and closed reduction of fractures
- approach
- decompression of the spinal canal
- instrumentation and stabilization
- intervertebral fusion

Postoperative neurological complications are rare

In addition, there are general surgical complications, which are not specific to spinal operations.

- Complications specific to the procedure that were **revised** included ($n = 40$): deep infection 15 (2.2 %), hematoma/wound healing disorder 12 (1.8 %), instability or segmental malalignment 5 (0.7 %), misplacement of screw/implant 4 (0.6 %), persisting liquor fistula 2 (0.3 %), sewn-in drain 1 (0.1 %), arterial embolism of femoral artery 1 (0.1 %).
- Complications specific to the procedure that were ($n = 29$) **not revised** included: intraoperative bleeding 10 (1.5 %), iatrogenic pedicle fracture 5 (0.7 %), misplacement of screw/implant 3 (0.4 %), instability or consecutive malalignment 2 (0.3 %), infection/healing disorder iliac crest 2 (0.3 %), not specified 2 (0.3 %), iatrogenic rip fracture, approach related 1 (0.1 %), iatrogenic lesion of pleura/peritoneum 1 (0.1 %), narrowing of spinal canal with bone graft 1 (0.1 %), fracture of iliac crest after graft harvesting 1 (0.1 %), persisting liquor fistula 1 (0.1 %).
- Neurological complications ($n = 13$), revised and non-revised included: peripheral lesion of nerve roots (0.7 %), remittent neurologic deficit 4 (0.6 %), neurologic deterioration (Frankel/ASIA E to D) 2 (0.3 %), neurologic deterioration (Frankel/ASIA D to A) 1 (0.1 %), paresthesia without neurological deficit 1 (0.1 %).

## Recapitulation

**Epidemiology.** About 60% of thoracic and lumbar spine fractures are located at the transition **T11–L2**, 30% in the thoracic spine and 10% in the lower lumbar spine. **Spinal cord injury** occurs in about 10–30% of traumatic spinal fractures.

**Pathogenesis.** The most relevant forces that produce structural damage to the spine are axial compression, flexion/distraction, hyperextension, rotation, and shear. **Axial load** may result in a burst fracture; the posterior elements are usually intact. In **flexion/distraction injuries**, the posterior ligamentous and osseous elements fail in tension; a wedge compression fracture of the vertebral body is often associated. **Hyperextension** may result in rupture of the anterior ligament and the disc as well as in compression injuries of the posterior elements, i.e., fracture of the facets, the laminae, or the spinous processes. **Rotational injuries** combine compressive forces and flexion/distraction mechanisms and are highly unstable injuries. Shear forces produce severe ligamentous disruption and usually result in complete spinal cord injury.

**Clinical presentation.** In the case of a polytrauma, about 30% of the patients have a spinal injury. The neurological examination has to include the "**search for a sacral sparing**" which determines the completeness of the deficit and the prognosis. About one-third of all spinal injuries have **concomitant injuries**; the most frequent are: head injuries, chest injuries and long bone injuries. The history should include the type of trauma (high vs. low energy injuries) and the time course of a possible neurological deficit. The initial focus of the physical examination is on the assessment of **vital functions and neurological deficits**. Because the spinal cord usually terminates at the level of L1, injuries to the thoracolumbar junction may result in various neurological symptoms: e.g., complete/incomplete paraplegia (distal spinal cord), malfunction of the vegetative system (conus medullaris), or cauda equina syndrome.

**Diagnostic work-up.** Static imaging studies are "snapshots in time" and do not reveal the real degree of spinal canal compromise that may have happened during the injury. A posterior cortical disruption seen in the lateral view or an interpedicular widening seen in the anteroposterior view suggests a burst fracture that should be further analyzed by CT scan. **CT is the imaging study of choice** to demonstrate bony destruction. **MRI** is recommended to identify a possible cord lesion or a cord compression in patients with **neurological deficits**. MRI can be helpful in determining the integrity of the posterior ligamentous structures and thereby in **differentiating between a Type A and a Type B lesion**.

**Non-operative treatment.** Management of thoracolumbar and sacral spinal fractures remains a controversial area in modern spinal surgery. The literature demonstrates a wide range of conflicting results and recommendations. Unfortunately, the vast majority of clinical studies can be criticized because of their retrospective design, heterogeneous patient populations and treatment strategies, limited follow-up, and poorly defined outcome measures.
The main advantage of non-operative treatment of thoracolumbar fracture is the avoidance of surgery-related complications. According to Böhler, the time of immobilization in a cast is usually 3–5 months depending on the fracture type. Importantly, skillful physical therapy is paramount to achieve good results. Because thoracolumbar fractures are bound to return to the initial deformity, functional bracing without repositioning is an alternative to Böhler's concept of repositioning and stabilization with a cast if the initial deformity is acceptable. Many studies were not able to prove a substantial difference in functional outcome between the operative and non-operative treatment, regardless of the neurological injury.

**Operative treatment.** There is a general trend towards operative treatment of unstable fractures mostly because surgical stabilizing procedures result in early mobilization, diminished pain, facilitated nursing care, earlier return to work, and avoidance of late neurological complications. In experimental animal models, persistent compression of the spinal cord is potentially reversible from a secondary injury by early decompression. Most investigators **recommend a surgical decompression** in the setting of major neurological deficit, progressive neurological loss, and substantial compromise of the spinal canal. Currently, there are **no gold standards regarding the role and timing of decompression** in acute spinal cord injury. Posterior bisegmental reduction and stabilization is the "working horse" of the posterior approach technique that allows for fracture reduction and stable

fixation. Depending on the persistence of spinal canal compromise or comminution of the fractured vertebral body, an additional anterior approach is needed. Transpedicular cancellous bone grafting for interbody fusion after posterior stabilization is not recommended in complete or incomplete burst fractures. Only incomplete Type A burst fractures with intact pedicles and a lower endplate should be considered for **posterior monosegmental reduction and stabilization**. Compared to the open method, minimally invasive surgery reduces postoperative pain, shortens hospitalization, leads to early recovery of function and reduces morbidity of the operative approach. A **combined posterior and anterior approach** is used to reduce and stabilize severely comminuted vertebral body fractures and to decompress the spinal canal. In **Type C lesions often multisegmental instrumentation** is needed to reliably stabilize the spine.

**Complications.** The reported complication rate in the literature varies largely and ranges from 3.6 % to 10 %. Postoperative neurological complications range from 0.1 % to 0.7 %. Only honest and accurate assessment of complications will lead to scientific and clinical progress.

## Key Articles

**Böhler L (1951) Die Technik der Knochenbruchbehandlung. Maudrich, Vienna**
Lorenz Böhler was one of the first to advocate a conservative treatment with fracture reduction and retention in a cast.

**Roaf R (1960) A study of the mechanics of spinal injuries. J Bone Joint Surg Br 42B:810 – 23**
In this article Roaf studies the biomechanics of spinal injuries and describes the results of studies of spinal units when subjected to forces of different magnitude and direction, i.e., compression, flexion, extension, lateral flexion, rotation, and horizontal shear.

**Denis F (1983) The three column spine and its significance in the classification of acute thoraco-lumbar spinal injuries. Spine 8:817 – 31**
This article is a presentation of the concept of the three-column spine. The concept evolved from a retrospective review of 412 thoracolumbar spine injuries and observations on spinal instability. The posterior column consists of what Holdsworth described as the posterior ligamentous complex. The middle column includes the posterior longitudinal ligament, posterior anulus fibrosus, and posterior wall of the vertebral body. The anterior column consists of the anterior vertebral body, anterior anulus fibrosus, and anterior longitudinal ligament.

**Dick W (1987) The "fixateur interne" as a versatile implant for spine surgery. Spine 12:882 – 900**
This article introduced a new angle-stable fixation device which first allowed a short segmental reduction and fixation of fractures.

**Magerl F, Aebi M, Gertzbein SD, Harms J, Nazarian S (1994) A comprehensive classification of thoracic and lumbar injuries. Eur Spine J 3:184 – 201**
This article describes a classification of thoracic and lumbar injuries. As a result of more than a decade of consideration of the subject matter and a review of 1 445 consecutive thoracolumbar injuries, a comprehensive classification of thoracic and lumbar injuries is proposed. The classification is primarily based on pathomorphological criteria. Three mechanisms classify the injury pattern according to the AO classification: axial compression (Type A), flexion distraction (Type B) and rotational/shear injuries (Type C).

**Kaneda K, Taneichi H, Abumi K, Hashimoto T, Satoh S, Fujiya M (1997) Anterior decompression and stabilization with the Kaneda device for thoracolumbar burst fractures associated with neurological deficits. J Bone Joint Surg Am 79:69 – 83**
One hundred and fifty consecutive patients who had a burst fracture of the thoracolumbar spine and associated neurological deficits were managed with a single-stage anterior spinal decompression, strut-grafting, and Kaneda spinal instrumentation. The authors conclude that anterior decompression, strut-grafting, and fixation with the Kaneda

device in patients who had a burst fracture of the thoracolumbar spine and associated neurological deficits yielded good radiographic and functional results. This article established the single stage anterior approach for this fracture type.

**Knop C, Blauth M, Bühren V, Hax PM, Kinzl L, Mutschler W, Pommer A, Ulrich C, Wagner S, Weckbach A, Wentzensen A, Wörsdörfer O (1999) Surgical treatment of injuries of the thoracolumbar transition. 1: Epidemiology. Unfallchirurg 102:924 – 35**

**Knop C, Blauth M, Bühren V, Hax PM, Kinzl L, Mutschler W, Pommer A, Ulrich C, Wagner S, Weckbach A, Wentzensen A, Wörsdörfer O (2000) Surgical treatment of injuries of the thoracolumbar transition. 2: Operation and roentgenologic findings. Unfallchirurg 103:1032 – 47**

**Knop C, Blauth M, Bühren V, Arand M, Egbers HJ, Hax PM, Nothwang J, Oestern HJ, Pizanis A, Roth R, Weckbach A, Wentzensen A (2001) Surgical treatment of injuries of the thoracolumbar transition – 3: Follow-up examination. Results of a prospective multi-center study by the "Spinal" Study Group of the German Society of Trauma Surgery. Unfallchirurg 104:583 – 600**
These three reports summarize the experience based on 682 patients included in a prospective multicenter study by the "Spinal" Study Group of the German Society of Trauma Surgery. All treatment methods under study were appropriate for achieving comparable clinical and functional outcome. The internal fixator was found superior in restoration of the spinal alignment. Best radiological outcomes were achieved by combined stabilization. Merely by direct reconstruction of the anterior column the postoperative re-kyphosing is prevented and a gain in segmental angle is achieved. However, this benefit was not reflected in the clinical outcome.

**Fehlings MG, Perrin RG (2005) The role and timing of early decompression for cervical spinal cord injury: Update with a review of recent clinical evidence. Injury S-B13–S-B26**
Evidence-based recommendations regarding spinal cord decompression in patients with acute spinal cord injury.

**Beisse R (2006) Endoscopic surgery on the thoracolumbar junction of the spine. Eur Spine J 15:687 – 704**
This article summarizes the technique and results based on a large patient group from a German trauma center: A now standardized operating technique, instruments and implants specially developed for the endoscopic procedure, from angle stable plate and screw implants to endoscopically implantable vertebral body replacements, have gradually opened up the entire spectrum of anterior spine surgery to endoscopic techniques.

## References


1. Alanay A, Acaroglu E, Yazici M, Oznur A, Surat A (2001) Short-segment pedicle instrumentation of thoracolumbar burst fractures: does transpedicular intracorporeal grafting prevent early failure? Spine 26:213 – 7
2. Anderson PA, Henley MB, Rivara FP, Maier RV (1991) Flexion distraction and chance injuries to the thoracolumbar spine. J Orthop Trauma 5:153 – 60
3. Anderson PA, Rivara FP, Maier RV, Drake C (1991) The epidemiology of seatbelt-associated injuries. J Trauma 31:60 – 7
4. Anderson PA, Bohlman HH (1992) Anterior decompression and arthrodesis of the cervical spine: long-term motor improvement. Part II – Improvement in complete traumatic quadriplegia. J Bone Joint Surg Am 74:683 – 92
5. Anderson S, Biros MH, Reardon RF (1996) Delayed diagnosis of thoracolumbar fractures in multiple-trauma patients. Acad Emerg Med 3:832 – 9
6. Bagley LJ (2006) Imaging of spinal trauma. Radiol Clin North Am 44:1 – 12, vii
7. Been HD, Bouma GJ (1999) Comparison of two types of surgery for thoraco-lumbar burst fractures: combined anterior and posterior stabilisation vs. posterior instrumentation only. Acta Neurochir (Wien) 141:349 – 57
8. Beisse R, Muckley T, Schmidt MH, Hauschild M, Buhren V (2005) Surgical technique and results of endoscopic anterior spinal canal decompression. J Neurosurg Spine 2:128 – 36
9. Beisse R (2006) Endoscopic surgery on the thoracolumbar junction of the spine. Eur Spine J 15:687 – 704

10. Bensch FV, Kiuru MJ, Koivikko MP, Koskinen SK (2004) Spine fractures in falling accidents: analysis of multidetector CT findings. Eur Radiol 14:618 – 24
11. Bensch FV, Koivikko MP, Kiuru MJ, Koskinen SK (2006) The incidence and distribution of burst fractures. Emerg Radiol 12:124 – 9
12. Benson DR (1988) Unstable thoracolumbar fractures, with emphasis on the burst fracture. Clin Orthop Relat Res 14 – 29
13. Blauth M, Knop C, Bastian L (1998) Wirbelsäule. In: Tscherne H, Blauth M (eds) Tscherne Unfallchirurgie, vol 3. Springer, Berlin Heidelberg New York, pp 241 – 381
14. Bohlman HH, Anderson PA (1992) Anterior decompression and arthrodesis of the cervical spine: long-term motor improvement. Part I – Improvement in incomplete traumatic quadriparesis. J Bone Joint Surg Am 74:671 – 82
15. Bohlman HH, Kirkpatrick JS, Delamarter RB, Leventhal M (1994) Anterior decompression for late pain and paralysis after fractures of the thoracolumbar spine. Clin Orthop 24 – 9
16. Braakman R, Fontijne WP, Zeegers R, Steenbeek JR, Tanghe HL (1991) Neurological deficit in injuries of the thoracic and lumbar spine. A consecutive series of 70 patients. Acta Neurochir (Wien) 111:11 – 7
17. Burke DC, Murray DD (1976) The management of thoracic and thoraco-lumbar injuries of the spine with neurological involvement. J Bone Joint Surg Br 58:72 – 8
18. Böhler L (1951) Die Technik der Knochenbruchbehandlung. Maudrich Verlag, Vienna
19. Bühren V, Beisse R, Potulski M (1997) [Minimally invasive ventral spondylodesis in injuries to the thoracic and lumbar spine]. Chirurg 68:1076 – 84
20. Cantor JB, Lebwohl NH, Garvey T, Eismont FJ (1993) Nonoperative management of stable thoracolumbar burst fractures with early ambulation and bracing. Spine 18:971 – 6
21. Carl AL, Tromanhauser SG, Roger DJ (1992) Pedicle screw instrumentation for thoracolumbar burst fractures and fracture-dislocations. Spine 17:S317 – 24
22. Chance G (1948) Note on a type of flexion fracture of the spine. Br J Radiol 21:452 – 3
23. Chow GH, Nelson BJ, Gebhard JS, Brugman JL, Brown CW, Donaldson DH (1996) Functional outcome of thoracolumbar burst fractures managed with hyperextension casting or bracing and early mobilization. Spine 21:2170 – 5
24. Dai L-Y, Yao W-F, Cui Y-M, Zhou Q (2004) Thoracolumbar fractures in patients with multiple injuries: diagnosis and treatment – a review of 147 cases. J Trauma 56:348 – 55
25. Daniaux H (1986) Transpedicular repositioning and spongioplasty in fractures of the vertebral bodies of the lower thoracic and lumbar spine. Unfallchirurg 89:197 – 213
26. Daniaux H, Seykora P, Genelin A, Lang T, Kathrein A (1991) Application of posterior plating and modifications in thoracolumbar spine injuries. Indication, techniques, and results. Spine 16:S125 – 33
27. Daniaux H, Wagner M, Kathrein A, Lang T (1999) [Fractures of the thoraco-lumbar junction. Conservative management]. Orthopade 28:682 – 91
28. Defino HL, Rodriguez-Fuentes AE (1998) Treatment of fractures of the thoracolumbar spine by combined anteroposterior fixation using the Harms method. Eur Spine J 7:187 – 94
29. Defino HL, Scarparo P (2005) Fractures of thoracolumbar spine: monosegmental fixation. Injury 36 Suppl 2:B90 – 7
30. Denis F (1983) The three column spine and its significance in the classification of acute thoracolumbar spinal injuries. Spine 8:817 – 31
31. Denis F, Armstrong GW, Searls K, Matta L (1984) Acute thoracolumbar burst fractures in the absence of neurologic deficit. A comparison between operative and nonoperative treatment. Clin Orthop Relat Res 142 – 9
32. Denis F, Burkus JK (1992) Shear fracture-dislocations of the thoracic and lumbar spine associated with forceful hyperextension (lumberjack paraplegia). Spine 17:156 – 61
33. DeWald RL (1984) Burst fractures of the thoracic and lumbar spine. Clin Orthop Relat Res 150 – 61
34. Dick W (1987) The "fixateur interne" as a versatile implant for spine surgery. Spine 12: 882 – 900
35. Dickson JH, Harrington PR, Erwin WD (1978) Results of reduction and stabilization of the severely fractured thoracic and lumbar spine. J Bone Joint Surg Am 60:799 – 805
36. el-Khoury GY, Whitten CG (1993) Trauma to the upper thoracic spine: anatomy, biomechanics, and unique imaging features. AJR Am J Roentgenol 160:95 – 102
37. Evans L (1988) Risk of fatality from physical trauma versus sex and age. J Trauma 28:368 – 78
38. Eysel P, Meinig G, Sanner F (1991) Comparative study of various dorsal stabilization procedures in recent fractures of the thoracic spine. Unfallchirurgie 17:264 – 73
39. Faciszewski T, Winter RB, Lonstein JE, Denis F, Johnson L (1995) The surgical and medical perioperative complications of anterior spinal fusion surgery in the thoracic and lumbar spine in adults. A review of 1 223 procedures. Spine 20:1592 – 9
40. Fehlings MG, Perrin RG (2005) The role and timing of early decompression for cervical spinal cord injury: Update with a review of recent clinical evidence. Injury S-B13–S-B26
41. Feil J, Wörsdörfer O (1992) [Ventral stabilization in the area of the thoracic and lumbar spine]. Chirurg 63:856 – 65

42. Feil J, Wörsdörfer O (1992) Complications in surgical management of spinal injuries. Langenbecks Arch Chir Suppl Kongressbd 304 – 10
43. Floman Y, Fast A, Pollack D, Yosipovitch Z, Robin GC (1986) The simultaneous application of an interspinous compressive wire and Harrington distraction rods in the treatment of fracture-dislocation of the thoracic and lumbar spine. Clin Orthop Relat Res 207 – 15
44. Frankel HL, Hancock DO, Hyslop G, Melzak J, Michaelis LS, Ungar GH, Vernon JD, Walsh JJ (1969) The value of postural reduction in the initial management of closed injuries of the spine with paraplegia and tetraplegia. I. Paraplegia 7:179 – 92
45. Fredrickson BE, Edwards WT, Rauschning W, Bayley JC, Yuan HA (1992) Vertebral burst fractures: an experimental, morphologic, and radiographic study. Spine 17:1012 – 21
46. Gertzbein SD (1992) Fractures of the thoracic and lumbar spine. Williams & Wilkins, Baltimore
47. Gertzbein SD (1992) Scoliosis Research Society. Multicenter spine fracture study. Spine 17:528 – 40
48. Gopalakrishnan KC, el Masri WS (1986) Fractures of the sternum associated with spinal injury. J Bone Joint Surg Br 68:178 – 81
49. Gotzen L, Puplat D, Junge A (1992) Indications, technique and results of monosegmental dorsal spondylodesis in wedge compression fractures (grade II) of the thoracolumbar spine. Unfallchirurg 95:445 – 54
50. Haas N, Blauth M, Tscherne H (1991) Anterior plating in thoracolumbar spine injuries. Indication, technique, and results. Spine 16:S100 – 11
51. Harrington RM, Budorick T, Hoyt J, Anderson PA, Tencer AF (1993) Biomechanics of indirect reduction of bone retropulsed into the spinal canal in vertebral fracture. Spine 18:692 – 9
52. Hauser CJ, Visvikis G, Hinrichs C, Eber CD, Cho K, Lavery RF, Livingston DH (2003) Prospective validation of computed tomographic screening of the thoracolumbar spine in trauma. J Trauma 55:228 – 34; discussion 34 – 5
53. Henderson RL, Reid DC, Saboe LA (1991) Multiple noncontiguous spine fractures. Spine 16:128 – 31
54. Holdsworth F (1963) Fractures, dislocations, and fracture-dislocations of the spine. J Bone Joint Surg Am 45:6 – 20
55. Holdsworth F (1970) Fractures, dislocations, and fracture-dislocations of the spine. J Bone Joint Surg Am 52:1534 – 51
56. Hu R, Mustard CA, Burns C (1996) Epidemiology of incident spinal fracture in a complete population. Spine 21:492 – 9
57. Inaba K, Munera F, McKenney M, Schulman C, de Moya M, Rivas L, Pearce A, Cohn S (2006) Visceral torso computed tomography for clearance of the thoracolumbar spine in trauma: a review of the literature. J Trauma 60:915 – 20
58. Jahna H, Wittich H (1985) Konservative Methoden in der Frakturbehandlung. Urban & Fischer, Vienna, pp 121 – 38
59. Junge A, Gotzen L, von Garrel T, Ziring E, Giannadakis K (1997) [Monosegmental internal fixator instrumentation and fusion in treatment of fractures of the thoracolumbar spine. Indications, technique and results]. Unfallchirurg 100:880 – 7
60. Kaneda K, Taneichi H, Abumi K, Hashimoto T, Satoh S, Fujiya M (1997) Anterior decompression and stabilization with the Kaneda device for thoracolumbar burst fractures associated with neurological deficits. J Bone Joint Surg Am 79:69 – 83
61. Kelly RP, Whitesides TE (1968) Treatment of lumbodorsal fracture-dislocations. Ann Surg 167:705 – 17
62. Khoo LT, Beisse R, Potulski M (2002) Thoracoscopic-assisted treatment of thoracic and lumbar fractures: a series of 371 consecutive cases. Neurosurgery 51:104 – 17
63. Kim DH, Silber JS, Albert TJ (2003) Osteoporotic vertebral compression fractures. Instr Course Lect 52:541 – 50
64. King AG (1987) Burst compression fractures of the thoracolumbar spine. Pathologic anatomy and surgical management. Orthopedics 10:1711 – 9
65. Knop C, Blauth M, Bühren V, Hax PM, Kinzl L, Mutschler W, Pommer A, Ulrich C, Wagner S, Weckbach A, Wentzensen A, Wörsdörfer O (1999) Surgical treatment of injuries of the thoracolumbar transition. 1: Epidemiology. Unfallchirurg 102:924 – 35
66. Knop C, Blauth M, Bühren V, Hax PM, Kinzl L, Mutschler W, Pommer A, Ulrich C, Wagner S, Weckbach A, Wentzensen A, Wörsdörfer O (2000) Surgical treatment of injuries of the thoracolumbar transition. 2: Operation and roentgenologic findings. Unfallchirurg 103:1032 – 47
67. Knop C, Blauth M, Bühren V, Arand M, Egbers HJ, Hax PM, Nothwang J, Oestern HJ, Pizanis A, Roth R, Weckbach A, Wentzensen A (2001) Surgical treatment of injuries of the thoracolumbar transition – 3: Follow-up examination. Results of a prospective multi-center study by the "Spinal" Study Group of the German Society of Trauma Surgery. Unfallchirurg 104:583 – 600
68. Knop C, Fabian HF, Bastian L, Blauth M (2001) Late results of thoracolumbar fractures after posterior instrumentation and transpedicular bone grafting. Spine 26:88 – 99

69. Knop C, Bastian L, Lange U, Oeser M, Zdichavsky M, Blauth M (2002) Complications in surgical treatment of thoracolumbar injuries. Eur Spine J 11:214 – 26
70. Knop C, Fabian HF, Bastian L, Rosenthal H, Lange U, Zdichavsky M, Blauth M (2002) Fate of the transpedicular intervertebral bone graft after posterior stabilisation of thoracolumbar fractures. Eur Spine J 11:251 – 7
71. Kossmann T, Ertel W, Platz A, Trentz O (1999) [Combined surgery for fractures of the thoraco-lumbar junction using the inlay-span method]. Orthopade 28:432 – 40
72. Kossmann T, Jacobi D, Trentz O (2001) The use of a retractor system (SynFrame) for open, minimal invasive reconstruction of the anterior column of the thoracic and lumbar spine. Eur Spine J 10:396 – 402
73. Kraemer WJ, Schemitsch EH, Lever J, McBroom RJ, McKee MD, Waddell JP (1996) Functional outcome of thoracolumbar burst fractures without neurological deficit. J Orthop Trauma 10:541 – 4
74. Krueger MA, Green DA, Hoyt D, Garfin SR (1996) Overlooked spine injuries associated with lumbar transverse process fractures. Clin Orthop 191 – 5
75. La Rosa G, Conti A, Cardali S, Cacciola F, Tomasello F (2004) Does early decompression improve neurological outcome of spinal cord injured patients? Appraisal of the literature using a meta-analytical approach. Spinal Cord 42:503 – 12
76. Larson SJ, Holst RA, Hemmy DC, Sances A (1976) Lateral extracavitary approach to traumatic lesions of the thoracic and lumbar spine. J Neurosurg 45:628 – 37
77. Leidner B, Adiels M, Aspelin P, Gullstrand P, Wallen S (1998) Standardized CT examination of the multitraumatized patient. Eur Radiol 8:1630 – 8
78. Lindsey RW, Dick W (1991) The fixateur interne in the reduction and stabilization of thoracolumbar spine fractures in patients with neurologic deficit. Spine 16:S140 – 5
79. Louis R (1977) Unstable fractures of the spine. III. Instability. A. Theories concerning instability. Rev Chir Orthop Reparatrice Appar Mot 63:423 – 5
80. Magerl F, Aebi M, Gertzbein SD, Harms J, Nazarian S (1994) A comprehensive classification of thoracic and lumbar injuries. Eur Spine J 3:184 – 201
81. Magerl F, Engelhardt P (1994) Brust- und Lendenwirbelsäule – Verlaufsformen. In: Witt AN, Rettig H, Schlegel KF (eds) Orthopädie in Praxis und Klinik, Spezielle Orthopädie (Wirbelsäule – Thorax – Becken). Thieme, Stuttgart New York, pp 3.82 – 3.132
82. Magnus G (1930) Die Begutachtung und Behandlung des Wirbelbruchs. Arch Orthop Unfallchir 29:277
83. Mayer H, Schaaf D, Kudernatsch M (1992) Use of internal fixator in injuries of the thoracic and lumbar spine. Chirurg 63:944 – 9
84. Maynard FM, Jr, Bracken MB, Creasey G, Ditunno JF, Jr, Donovan WH, Ducker TB, Garber SL, Marino RJ, Stover SL, Tator CH, Waters RL, Wilberger JE, Young W (1997) International Standards for Neurological and Functional Classification of Spinal Cord Injury. American Spinal Injury Association. Spinal Cord 35:266 – 74
85. McLain RF, Sparling E, Benson DR (1993) Early failure of short-segment pedicle instrumentation for thoracolumbar fractures. A preliminary report. J Bone Joint Surg Am 75:162 – 7
86. Meyer PR, Heim S (1989) Fractures of the thoracic spine T1–T10. In: Meyer PR (ed) Surgery of spine trauma. Churchill Livingstone, Edinburgh, pp 525 – 72
87. Mumford J, Weinstein JN, Spratt KF, Goel VK (1993) Thoracolumbar burst fractures. The clinical efficacy and outcome of nonoperative management. Spine 18:955 – 70
88. Müller U, Berlemann U, Sledge J, Schwarzenbach O (1999) Treatment of thoracolumbar burst fractures without neurologic deficit by indirect reduction and posterior instrumentation: bisegmental stabilization with monosegmental fusion. Eur Spine J 8:284 – 9
89. Nicoll EA (1949) Fractures of the dorso-lumbar spine. J Bone Joint Surg Br 31:376 – 94
90. Olerud S, Karlstrom G, Sjostrom L (1988) Transpedicular fixation of thoracolumbar vertebral fractures. Clin Orthop Relat Res 227:44 – 51
91. Place HM, Donaldson DH, Brown CW, Stringer EA (1994) Stabilization of thoracic spine fractures resulting in complete paraplegia. A long-term retrospective analysis. Spine 19:1726 – 30
92. Rechtine GR (1999) Nonsurgical treatment of thoracic and lumbar fractures. Instr Course Lect 48:413 – 6
93. Rechtine GR, 2nd, Cahill D, Chrin AM (1999) Treatment of thoracolumbar trauma: comparison of complications of operative versus nonoperative treatment. J Spinal Disord 12:406 – 9
94. Reid DC, Hu R, Davis LA, Saboe LA (1988) The nonoperative treatment of burst fractures of the thoracolumbar junction. J Trauma 28:1188 – 94
95. Reinhold M, Knop C, Lange U, Bastian L, Blauth M (2003) Non-operative treatment of thoracolumbar spinal fractures. Long-term clinical results over 16 years. Unfallchirurg 106: 566 – 76
96. Resch H, Rabl M, Klampfer H, Ritter E, Povacz P (2000) Surgical vs. conservative treatment of fractures of the thoracolumbar transition. Unfallchirurg 103:281 – 8
97. Richards PJ (2005) Cervical spine clearance: a review. Injury 36:248 – 69
98. Roaf R (1960) A study of the mechanics of spinal injuries. J Bone Joint Surg Br 42B:810 – 23

99. Roy-Camille R, Saillant G (1984) Spinal injuries without neurologic complications. Int Orthop 8:155 – 62
100. Saboe LA, Reid DC, Davis LA, Warren SA, Grace MG (1991) Spine trauma and associated injuries. J Trauma 31:43 – 8
101. Samuels LE, Kerstein MD (1993) 'Routine' radiologic evaluation of the thoracolumbar spine in blunt trauma patients: a reappraisal. J Trauma 34:85 – 9
102. Sasso RC, Cotler HB (1993) Posterior instrumentation and fusion for unstable fractures and fracture-dislocations of the thoracic and lumbar spine. A comparative study of three fixation devices in 70 patients. Spine 18:450 – 60
103. Sasso RC, Best NM, Reilly TM, McGuire RA (2005) Anterior-only stabilization of three-column thoracolumbar injuries. J Spinal Disord Tech 18 Suppl:S7 – 14
104. Shen WJ, Shen YS (1999) Nonsurgical treatment of three-column thoracolumbar junction burst fractures without neurologic deficit. Spine 24:412 – 5
105. Shen WJ, Liu TJ, Shen YS (2001) Nonoperative treatment versus posterior fixation for thoracolumbar junction burst fractures without neurologic deficit. Spine 26:1038 – 45
106. Sheridan R, Peralta R, Rhea J, Ptak T, Novelline R (2003) Reformatted visceral protocol helical computed tomographic scanning allows conventional radiographs of the thoracic and lumbar spine to be eliminated in the evaluation of blunt trauma patients. J Trauma 55:665 – 9
107. Shono Y, McAfee PC, Cunningham BW (1994) Experimental study of thoracolumbar burst fractures. A radiographic and biomechanical analysis of anterior and posterior instrumentation systems. Spine 19:1711 – 22
108. Speth MJ, Oner FC, Kadic MA, de Klerk LW, Verbout AJ (1995) Recurrent kyphosis after posterior stabilization of thoracolumbar fractures. 24 cases treated with a Dick internal fixator followed for 1.5 – 4 years. Acta Orthop Scand 66:406 – 10
109. Spitz J, Becker C, Tittel K, Weigand H (1992) [Clinical relevance of whole body skeletal scintigraphy in multiple injury and polytrauma patients]. Unfallchirurgie 18:133 – 47
110. Spivak JM, Neuwirth MG, Giordano CP, Bloom N (1994) The perioperative course of combined anterior and posterior spinal fusion. Spine 19:520 – 5
111. Steindl A, Schuh G (1992) Late results after lumbar vertebrae fracture with Lorenz Böhler conservative treatment. Unfallchirurg 95:439 – 44
112. Transfeldt EE, White D, Bradford DS, Roche B (1990) Delayed anterior decompression in patients with spinal cord and cauda equina injuries of the thoracolumbar spine. Spine 15:953 – 7
113. Vaccaro AR, Daugherty RJ, Sheehan TP, Dante SJ, Cotler JM, Balderston RA, Herbison GJ, Northrup BE (1997) Neurologic outcome of early versus late surgery for cervical spinal cord injury. Spine 22:2609 – 13
114. Vaccaro AR, Kim DH, Brodke DS, Harris M, Chapman JR, Schildhauer T, Routt ML, Sasso RC (2004) Diagnosis and management of thoracolumbar spine fractures. Instr Course Lect 53:359 – 73
115. Wawro W, Konrad L, Aebi M (1994) Single segment internal fixator device in treatment of thoracolumbar vertebral fractures. Unfallchirurg 97:114 – 20
116. Weinstein JN, Collalto P, Lehmann TR (1988) Thoracolumbar "burst" fractures treated conservatively: a long-term follow-up. Spine 13:33 – 8
117. Weitzman G (1971) Treatment of stable thoracolumbar spine compression fractures by early ambulation. Clin Orthop 76:116 – 22
118. White AA, 3rd, Panjabi MM (1978) The basic kinematics of the human spine. A review of past and current knowledge. Spine 3:12 – 20
119. Whitesides TE (1977) Traumatic kyphosis of the thoracolumbar spine. Clin Orthop 78 – 92
120. Woltmann A, Bühren V (2004) Emergency room management of the multiply injured patient with spine injuries. A systematic review of the literature. Unfallchirurg 107:911 – 9
121. Wood K, Butterman G, Mehbod A, Garvey T, Jhanjee R, Sechriest V (2003) Operative compared with nonoperative treatment of a thoracolumbar burst fracture without neurological deficit. A prospective, randomized study. J Bone Joint Surg Am 85-A:773 – 81
122. Wood KB, Bohn D, Mehbod A (2005) Anterior versus posterior treatment of stable thoracolumbar burst fractures without neurologic deficit: a prospective, randomized study. J Spinal Disord Tech 18 Suppl:S15 – 23
123. Young B, Brooks WH, Tibbs PA (1981) Anterior decompression and fusion for thoracolumbar fractures with neurological deficits. Acta Neurochir (Wien) 57:287 – 98

# 32 Osteoporotic Spine Fractures

Paul F. Heini, Albrecht Popp

## Core Messages

- ✔ Vertebral body compression fractures are the hallmark of osteoporosis and represent an increasing health care problem
- ✔ There is a high morbidity associated with these fractures
- ✔ If conservative treatment fails, percutaneous cement reinforcement appears to be the treatment of choice
- ✔ Ongoing mechanical pain is associated with progressive collapse of vertebrae
- ✔ The surgical procedure requires familiarity with the technique of percutaneous cement reinforcement
- ✔ Cement viscosity is the crucial parameter regarding the safety of percutaneous cement reinforcement
- ✔ Real time high quality fluoroscopy is mandatory during cement injection
- ✔ A combination of cement reinforcement and internal fixation can help to overcome the problems associated with poor bone quality and limited anchoring power of implants

## Epidemiology

Vertebral compression fractures are the hallmark of osteoporosis

Within the next few decades the increasing number of elderly people will represent one of the most challenging changes in Western and Asian societies. Musculoskeletal diseases are one of the predominant illnesses and of these osteoporosis represents the most important. Osteoporotic **vertebral body compression fractures** (VBCFs) are the hallmark of osteoporosis.

VBCF incidence rises exponentially with increasing age

At the age of 75 years, about 25 % of all women show at least one fractured vertebra. At the age of 80 years this number grows to 50 % [67]. In the United States, about 700 000 new osteoporotic fractures are seen every year, of which one-third become chronically painful [16, 92]. In the European Union, in 2000, the number of osteoporotic fractures was estimated at 3.79 million [82]. The incidence of osteoporotic VBCFs in women older than 50 years is greater than 10 per 1 000 per year and is three times higher after the age of 75 years [2, 16, 83]. Approximately 30 – 50 % of women and 20 – 30 % of men will develop vertebral fractures during their life, and half of them will develop multiple fractures [47].

VBCFs are related to serious morbidity and loss of quality of life

Osteoporotic compression fractures are a leading cause of disability and morbidity in the elderly [15, 29, 43, 83, 85, 87]. Patients with VBCFs show a higher mortality than the general population [10]. Vertebral fractures contribute to pain and disability and are associated with declines in physical performance even when pain is not reported. Indeed, the adverse effect of vertebral fractures on most activities of daily living is almost as great as that seen for hip fractures [92]. Finally, physical function, self-esteem, body image, and mood can be adversely affected [29, 55, 85]. The occurrence of one vertebral fracture (even if asymptomatic) quadruples the likelihood of a second fracture, and after a second fracture the risk of further fractures is 12 times higher [58]. The respiratory function is impaired with increasing deformity of the spine [87].

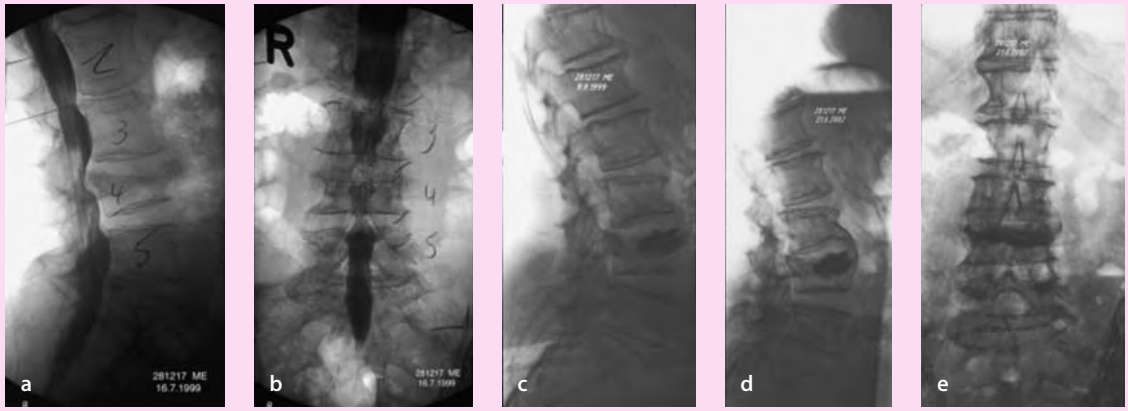


## Case Introduction

An 82-year-old female presented with severe claudication symptoms which limited her significantly in walking. A myelography examination demonstrated a spinal stenosis which was caused by a dislocated dorsoapical fragment of the fractured L4 vertebra (a, b). A kyphoplasty procedure was performed since open surgery with spinal canal decompression was not possible because of the poor general patient condition (c). The surgery was performed using local anesthesia. The anterior height of L4 was restored, resulting in an indirect decompression of the spinal canal. The intervention was carried out without complications and the patient recovered rapidly. The severe leg pain disappeared and the patient regained her mobility. Three years after the procedure, the patient is still mobile without significant leg pain. The follow-up radiographs demonstrated a spontaneous fusion between L3 and L4 (d, e).

In the United States, over 1.5 million vertebral fractures per year are attributable to osteoporosis; these fractures result in 500 000 hospitalizations, 800 000 emergency room visits, 2.6 million physician visits, 180 000 nursing home placements, and US $12–18 billion in direct health care costs each year [27].

The annual cost of VBCF treatment is about EUR 25 billion

The annual cost of treating all osteoporotic fractures in Europe is estimated to be EUR 25 billion. As the elderly population in Europe increases, this cost will rise to an estimated EUR 31.8 billion for all osteoporotic fractures by 2025. This figure is an underestimate, since it assumes there will be no increase in treatment costs per patient, and no increase in incidence [39]. In Switzerland, the direct medical cost of hospitalization of patients with osteoporosis and/or related fractures is SF 357 million. Among other common diseases in women and men, osteoporosis is ranked number 1 in women and number 2 (behind COPD) in men [59].

## Pathogenesis and Definition

Osteoporosis is a **progressive systemic skeletal disease** characterized by:

- low bone mass and
- microarchitectural deterioration of the bone

leading to increased bone fragility and susceptibility to fracture. There are not only quantitative but also qualitative changes to the bone. The magnitude of *peak bone mass* and the rate of duration of *bone loss* determine the likelihood of developing osteoporosis [1] (Fig. 1).

Osteoporosis can be either primary or secondary:

- **Primary osteoporosis** is either *postmenopausal* (type 1) or *senile osteoporosis* (type 2).
- **Secondary osteoporosis** can be due to metabolic bone diseases (Table 1), medical treatments, or lifestyle (diet, smoking).

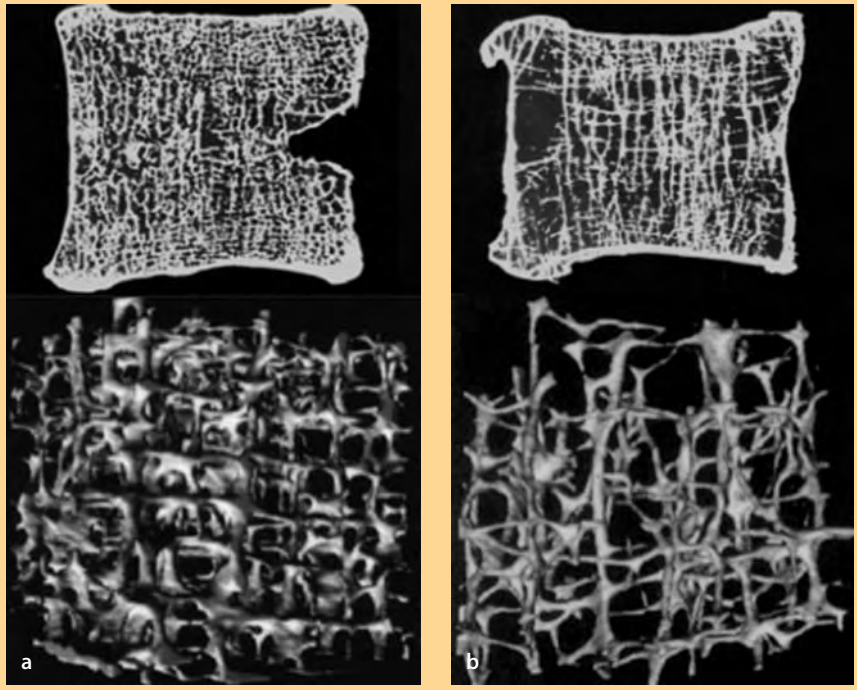


**Figure 1. Normal and osteoporotic bone**

Osteoporosis is a progressive systemic skeletal disease characterized by low bone mass and microarchitectural deterioration of bone tissue, leading to enhanced bone fragility and susceptibility to fracture. **a** Normal vertebral body. **b** Osteoporotic vertebral body. The images of osteoporotic bone depict not only the thinning of the trabeculae but also the distorted microarchitecture.

**Table 1.** Synopsis of metabolic bone diseases

| Other metabolic bone diseases | Etiology | Clinical presentation | Diagnosis | Treatment |
|---|---|---|---|---|
| **Paget's disease** | Second most common bone disease after osteoporosis. Focal disorder of accelerated skeletal remodeling (excessive resorption and formation) involving single bones or multiple bones | The disease leads to bone pain and bone deformity/skeletal fragility. Most commonly involved are the pelvis, the spine, skull, femur and tibia. The bone may become sclerotic and enlarged showing bowing deformities and may fracture. In affected spines nerve root and spinal cord compression can occur | X-rays show typical bony changes with increased density and deformities. Bone metabolism is increased. In bone scans the affected bones show an increased activity | There is no cure for Paget's disease. Bisphosphonates and calcitonin decrease the rate of bone resorption |
| **Osteomalacia (rickets)** | Term for bony abnormalities for more than 50 different etiologies. This includes (a) abnormal vitamin D metabolism, (b) phosphate deficiency, (c) other with normal vitamin D and phosphate metabolism | Rickets is the disease of the growing skeleton and osteomalacia is the disorder of the mature bone. Usually the condition is asymptomatic and multiple skeletal pain can be present as well as muscle weakness and wasting. Fractures may occur after minor trauma. In children various skeletal deformities can be present | In (a): low vitamin D and normal to low Ca level in the blood (secondary hyperparathyroidism)<br>In (b): hypophosphatemia and hyperphosphaturia<br>In (c): decreased or increased alkaline phosphatase | Correct hypocalcemia and the deficiency of active vitamin D metabolites. The choice for the different vitamin D preparations is the underlying pathologic defect of vitamin D metabolism |

**Table 1.** (*Cont.*)

| Other metabolic bone diseases | Etiology | Clinical presentation | Diagnosis | Treatment |
|---|---|---|---|---|
| **Multiple myeloma** is a cancer of plasma cells (antibody-producing cells of the bone marrow) | Myeloma cells activate osteoclast cells, which destroy bone, and block osteoblast cells, which normally repair damaged bone. The likelihood of myeloma increases with age | Approximately 70% of myeloma patients experience pain of varying intensity, often in the lower back. Sudden severe pain can be a sign of fracture or collapse of a vertebra. Patients also have general malaise and vague complaints | Abnormal or monoclonal protein produced by the myeloma cells is released into the bloodstream and can pass into the urine (Bence Jones protein) | It is not yet possible to cure myeloma, although it is possible to improve the clinical status and the survival in patients through the use of bisphosphonates, chemotherapy, alpha-interferon and, possibly, bone marrow transplants |
| **Primary hyperparathyroidism** is a benign overproduction of parathyroid hormone by the parathyroid glands | Unknown, hyperparathyroidism leads through an increased bone resorption and intestinal absorption to hypercalcemia and later hypercalciuria as well | The mild form is asymptomatic or osteoporosis occurs. But with severe hypercalcemia, fatigue, muscle weakness, joint and abdominal pain can be observed. Chronic hypercalciuria may lead to nephrolithiasis | Increased parathyroid hormone and hypercalcemia/hypophosphatemia is present | The only cure for primary hyperparathyroidism is surgical removal of the affected gland(s). Guidelines indicate when surgery should be recommended. To control hypercalcemia and protect the bone, bisphosphonates have shown to be effective |
| **Osteopetrosis** is a congenital condition present at birth in which the bones are overly dense | The osteoclasts are either fewer in number or are ineffective in bone resorption. There are three major types of osteopetrosis: the malignant infantile, the intermediate and the adult form | Fractures (because the bones, although dense, are also weak), frequent infections (due to impaired white blood cell production) and blindness, deafness and strokes | Hyperdense bones are found on X-ray. If suspected, bone biopsy is indicated | Interferon gamma-1B, high dose calcitriol and prednisone stimulate the osteoclasts. In infantile osteopetrosis bone marrow transplantation is an option |
| **Fibrous dysplasia** is a chronic disorder of the skeleton that causes expansion of one or more bones due to abnormal development of the fibrous, or connective, tissue within the bone. The abnormality will cause uneven growth, brittleness and deformity in affected bones. There is no evidence, however, that the disorder can be inherited | Fibrous dysplasia may be caused by a chemical abnormality in a protein in the bone that leads to an overgrowth of bone cells that produce fibrous tissue | Bone pain may occur due to the expanding fibrous tissue in the bone. Bone deformity caused by fibrous dysplasia is most obvious when it occurs in the skull and facial bones with blindness and deafness. Even though the fibrous tissue thickens, the bone itself becomes fragile and fractures can occur | The bones affected by fibrous dysplasia usually have a characteristic appearance on X-ray. When there is doubt about the diagnosis, a doctor may obtain a small bone specimen for examination by a pathologist | Beyond surgical treatment, including orthopedic and neurologic surgery, multiple intravenous infusions of pamidronate have been reported to relieve bone pain and lessen the extent of the disease in some patients with fibrous dysplasia |

Skeletal mass and density remain fairly constant once growth has stopped. The distribution of bone mineral density (BMD) in healthy young adults follows approximately a Gaussian distribution. Because of the Gaussian distribution, bone density values in individuals can be expressed as a relation to a reference population in standard deviation units (SDs) [79]. This reduces the difficulties associated with differences in the calibration between instruments. When SDs are used in relation to the *healthy young population*, this measurement is referred to as the *T-score* (Fig. 2) [46].

Osteoporosis is defined as a T-score below –2.5

**Dual-energy X-ray absorptiometry** (DEXA) is used for BMD assessment. In 1994, the World Health Organization (WHO) Working Group established some guidelines related to the SD for BMD as compared to a young adult female refer-

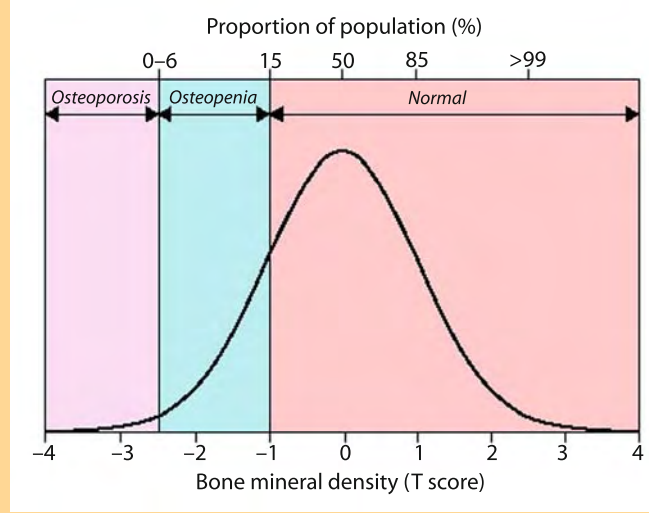


**Figure 2. Bone mineral density**

Distribution of bone mineral density (BMD) in healthy women aged 30–40 years [46].

ence population. This so-called **T-score** is the number of SDs that the bone density is above or below the average value for the reference population. Four general **diagnostic categories** have been distinguished:

BMD can be differentiated into four categories

- normal: BMD equal to or more than –1 SD (T-score –1)
- osteopenia: BMD between –1 SD and –2.5 SD (T-score <–1)
- osteoporosis: BMD less than –2.5 SD (T-score <–2.5)
- severe osteoporosis: BMD less than –2.5 SD in the presence of *one or more fragility fractures*.

For diagnosis, measurements of BMD at the hip and the lumbar spine are the gold standard.

Besides the diagnostic use of bone densitometry, these measurements have an additional *prognostic value* with respect to fracture probability: the age-adjusted relative increase in risk (e.g., of vertebral fracture) is 2.3 for every one SD decrease in lumbar BMD [61].

## Classification of Vertebral Body Compression Fractures

Unlike traumatic fractures, osteoporotic vertebral body fractures can be difficult to diagnose on conventional radiographs. The fracture patterns often do not fit into fracture classifications known from spinal trauma [60]. For this purpose morphometric criteria were established for diagnosing incident fractures (Fig. 3) [28, 68]. From the spine surgeon's perspective, the assessment of an osteoporotic fracture includes **consideration of** the following criteria (Fig. 4):

From a surgical perspective, the differentiation of acute and old fractures is most important

- acute and subacute single level fractures
- fractures with persistent instability
- (multiple) fractures with progressive/creeping vertebral collapse and loss of sagittal balance and posture
- vertebral fractures with subsequent spinal stenosis/neural compression

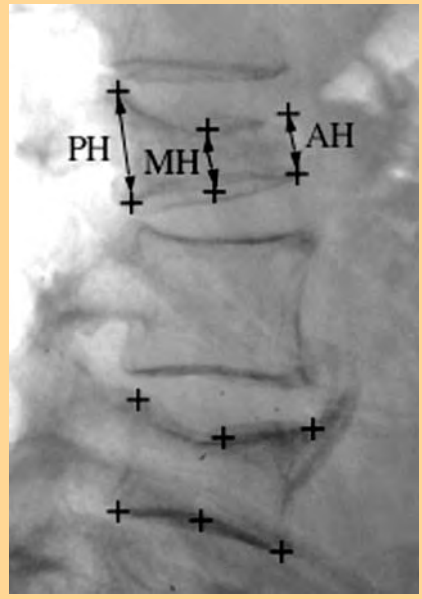


**Figure 3. Morphometric criteria**

Typical morphometric criteria for diagnosing incident fractures: Melton [68] defines a vertebral fracture as present if any of the ratios AH/PH, MH/PH, PH/PH1, PH/Ph-1 of a vertebra are less than 85% of the mean ratio in normal women for that vertebral level. Semiquantitative evaluation describes a mild grade 1 deformity as a 20–25% reduction in anterior, middle and/or posterior height and a 10–20% reduction in area. A moderate grade 2 deformity is defined as a 25–40% reduction in any height and a 20–40% reduction in area, and a severe grade 3 deformity is defined as a 40% reduction in any height and area [28].

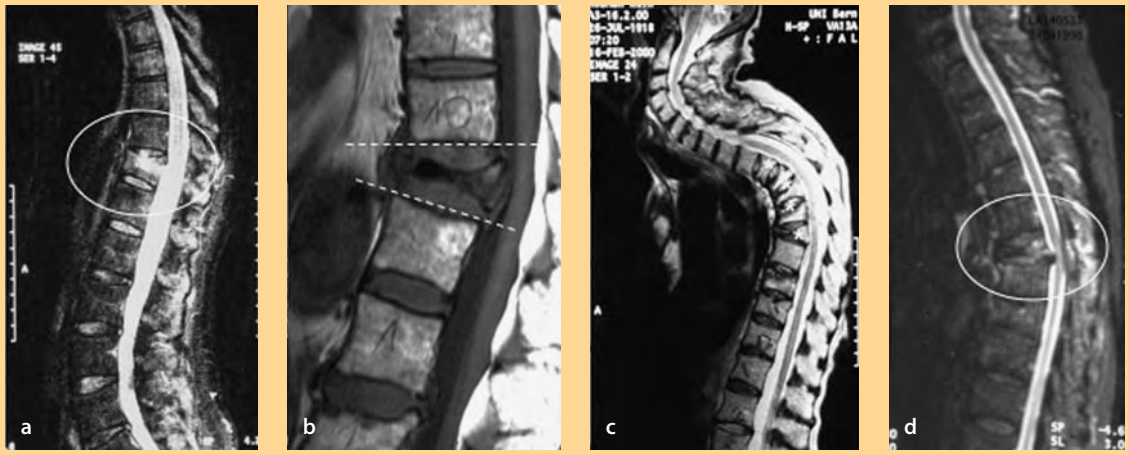


**Figure 4. Spectrum of osteoporotic vertebral fractures**

a Simple compression fracture with ongoing pain 2 months after onset. b Non-union 6 months after fracture of T11. The persisting instability causes pain during change of position. c Fractures of multiple vertebrae are responsible for loss of posture and neck pain in order to compensate for the deformed thoracic spine. d Fracture of T7 with concomitant spinal canal encroachment and compression of the spinal cord.

## Clinical Presentation

### History

Less than 10% of VBCFs necessitate in-hospital treatment

The medical history appears crucial for the clinical appraisal. However, the symptoms are often misinterpreted. Overall, only about one-third of all vertebral fractures come to clinical attention and less than 10% necessitate **admission to hospital**. The incidence of vertebral fractures is underreported. The low rate of clinical vertebral fracture diagnosis may be related in part to the lack of a traumatic precipitating event (only 25% of vertebral fractures result from falls), and

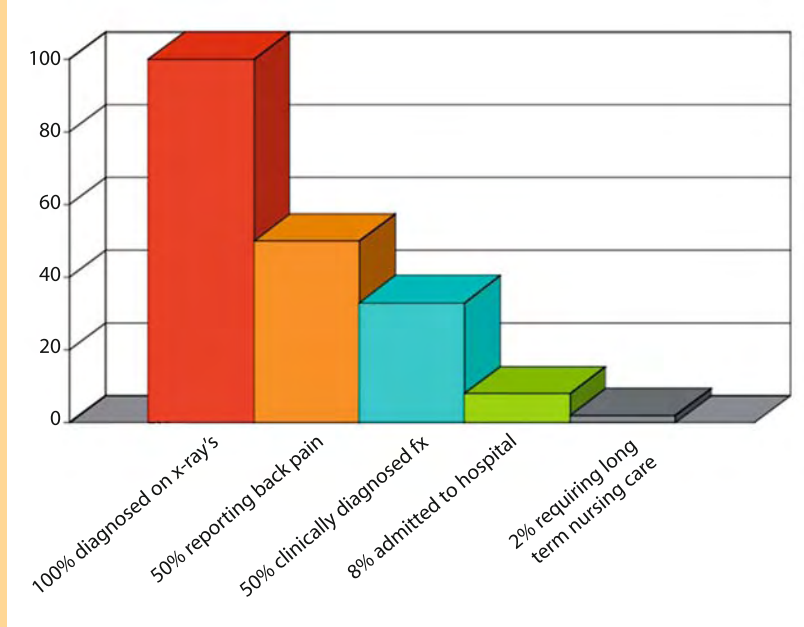


**Figure 5. The scale of vertebral fractures**

Data according to Cooper et al. [16].

therefore the symptoms are often misinterpreted as muscle strain instead. Most clinically diagnosed fractures (84%) are detected during investigation for back pain; the remaining 16% without pain may be old fractures that are detected incidentally during a radiological work-up (Fig. 5) [92].

The **cardinal symptoms** of acute osteoporotic vertebral fractures are:

Most VBCFs cause acute sharp localized pain

- acute onset, often initially breathtaking
- sharp localized, girdle like pain
- sensation of a crack in the back

Fractures are most often associated with physical activity (lifting of weights). However, they can also occur spontaneously. In the majority of patients, the pain subsides spontaneously within a couple of weeks. Persisting pain is a hallmark of ongoing instability with progressive loss of vertebral body height.

Pain persistence indicates further collapse risk

Therefore, patients should be monitored carefully with repeated X-ray examinations. Severe mechanical back pain for weeks or even months during positional changes (e.g., getting up from the supine position) leads one to suspect a non-union with persisting instability. This can be verified by comparing the standing X-ray with an investigation taken with the patient in the supine position such as an MRI scan (Fig. 6). However, a hyperextension cross table view depicts the difference between the standing and supine positions more accurately. Diffuse mechanical back pain of the whole thoracic or lumbar spine can be found in severe osteoporosis.

Severe positional pain indicates putative non-union

More and more frequently, we observe patients complaining about claudication like symptoms or sciatica after a VBCF. Usually, the symptoms subside while lying down and are accentuated in the upright position. If a narrowing of the spinal canal occurs, the patient can present with:

- radiculopathy
- claudication symptoms
- myelopathic symptoms with gait abnormalities and/or ataxia (thoracic fractures)

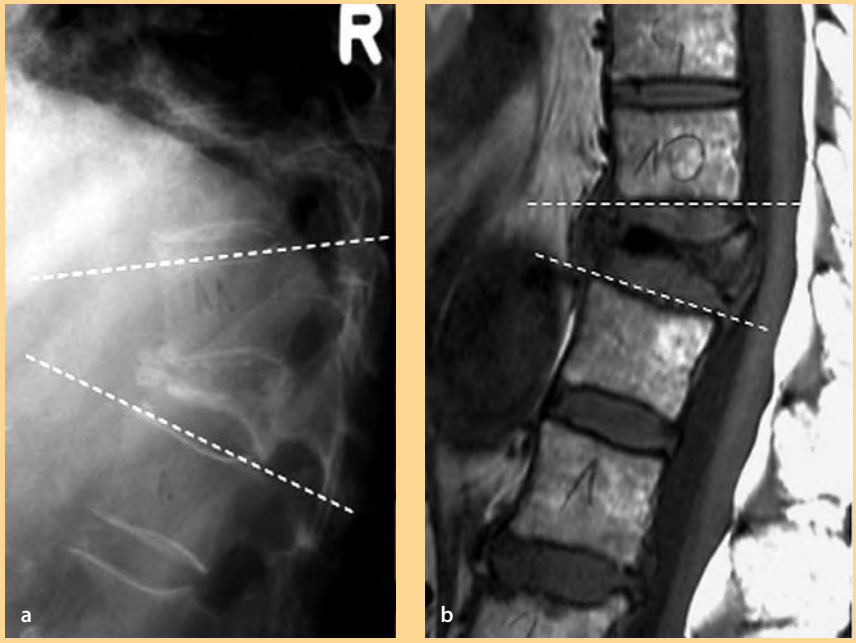


**Figure 6. Positional differences**

Patient with persisting pain 6 months after a T11 fracture. The pain is severe during the change from supine to sitting position. **a** The radiograph shows a nearly complete collapse of T11 with a severe kyphotic deformity. **b** In the MRI scan there is some degree of spontaneous correction of the kyphosis in comparison to the standing X-ray, which demonstrates the segmental instability.

The history should also include a search for risks of a new osteoporotic fracture (Table 2) [45].

**Table 2.** Risk factors for VBCF

| Age |
|---|
| • previous fragility fracture<br>• low bone mineral density (BMD, T-score)<br>• glucocorticoid therapy<br>• high bone turnover<br>• family history of hip fracture<br>• poor visual acuity<br>• low body weight<br>• neuromuscular disorders<br>• cigarette smoking<br>• excessive alcohol consumption<br>• long-term immobilization<br>• low dietary calcium intake<br>• vitamin D deficiency |

According to Kanis [45]

## Physical Findings

The **clinical examination** is not conclusive in the majority of cases. Frequent but non-specific physical findings are:

The clinical examination is rarely helpful for the diagnosis of a VBCF

- local tenderness
- painful motion examination
- pain provocation in flexion and rarely in extension

However, a **thorough neurological examination** is absolutely mandatory to rule out a neural compression syndrome. It is recommended to measure the body height of patients. This can be used as a reference in further follow-up controls. The sagittal balance of the spine should be assessed because a sagittal decompensation indicates an increased risk of progressive kyphosis. Furthermore, a thorough general medical assessment is required to rule out secondary causes of the fracture and to establish a differential diagnosis.

A thorough neurological exam is compulsory

## Diagnostic Work-up

### Imaging Studies

#### Standard Radiographs

The investigation of choice remains a standing X-ray of the region of interest in two planes. If there is a concordance of the clinical and imaging investigations, no further examinations are needed. The comparison with older X-rays can be helpful (patients may have had previous chest X-rays). If the fracture pattern or the patient's history (**red flags**, see Chapter 6) is not clear, further imaging studies are necessary. "Instability" can be identified by comparing a standing X-ray with the MRI or CT scan taken with the patient in a supine position. Alternatively, a hyperextension cross table view can provide the same information (Fig. 6). This provides further information about the potential for achieving some reduction when the patient is positioned prone during surgery [66].

Standard radiographs remain essential for diagnosis

#### Computed Tomography

A CT scan can be useful for assessment of the bony anatomy. If the exact fracture pattern is difficult to appraise, a CT scan with reformatted pictures in the sagittal and coronal planes should be performed. The evaluation of tumors with a CT scan shows the exact bony destruction and is recommended before cement reinforcement is considered.

CT best depicts the bony anatomy

#### Magnetic Resonance Imaging

An MRI investigation is recommended if the findings on standard X-rays are not obvious, especially if there are preexisting fractures of which the age is not known. The MRI though allows fresh osteoporotic fractures to be identified.

MRI differentiates acute and old fractures

Also a metastatic lesion can be ruled out on the MRI scan. The T2-weighted (T2W) image can depict a bone marrow edema which can be verified further with a fluid sensitive sequence [e.g., **s**hort **t**au **i**nversion **r**ecovery **s**equence (STIR), Fig. 7, Table 3]. An osteoporotic fracture is differentiated from another pathologic fracture if the pattern of signal change in the T1W and especially in the T2W image is not as homogeneous. A high signal intensity in T1W images (resembling fat) argues for an osteoporotic fracture. Sometimes imaging is not

MRI differentiates tumor and osteoporosis

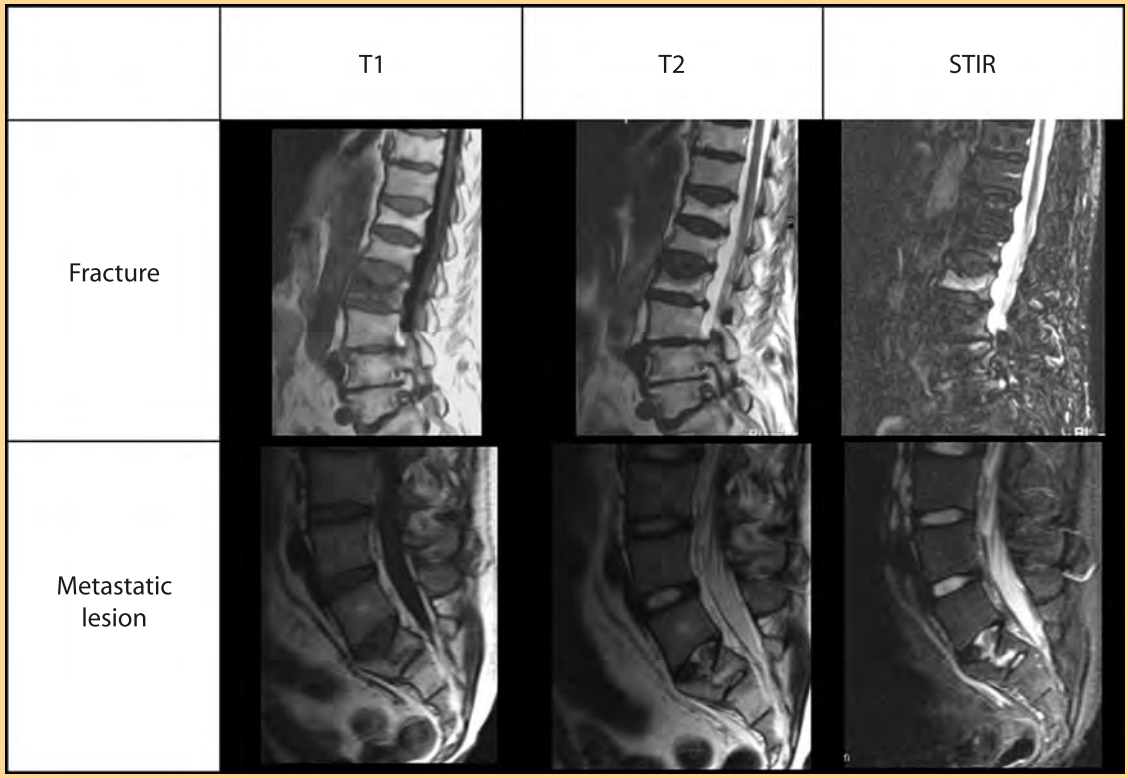


**Figure 7. Differential diagnosis**

Comparison of MR findings of a metastatic lesion (rhabdomyosarcoma) and an osteoporotic fracture with T1- and T2-weighted images as well as with STIR sequences (see Table 2).

**Table 3.** MR findings

| Pathology | MR sequence T1W | T2W | STIR |
|---|---|---|---|
| Osteoporotic fracture | Dark signal | Clear signal, located close to the fractured endplate | Clear signal involving the whole vertebra |
| Metastatic lesion | Different patterns depending on the underlying tumor | Signal change includes the major part of the vertebra | Clear signal of the whole vertebra |

able to give a definitive answer. In these cases, a CT-guided biopsy should be obtained prior to cement reinforcement.

## Radionuclide Studies

Radionuclide studies are helpful in differentiating tumors and generalized bone disease

When a tumorous lesion or another generalized bone disease is suspected, a bone scan is indicated. Furthermore, if a patient is not suitable for an MRI scan (e.g., pacemaker, claustrophobia), a bone scan can be performed to detect a fresh fracture. Of note, a bone scan shows a high sensitivity but is not specific.

## Densitometry

If a patient presents with an osteoporotic spine, the BMD should be determined. There are two methods for the assessment of the BMD.

### Dual-Energy X-ray Absorptiometry

Dual-energy X-ray absorptiometry (DEXA) determines the bone density per area measured (mg/cm$^2$). For diagnosis, measurements of BMD at the hip and the lumbar spine are the gold standard. The method is simple, fast and reliable. It became the standard assessment for osteoporosis and is especially helpful in monitoring the effect of medical treatment. Besides the diagnostic use of bone densitometry, these measurements have an additional *prognostic value* with respect to fracture probability.

DEXA has become the modality of choice for BMD assessment

### High-Resolution Quantitative Peripheral Computed Tomography

High-resolution quantitative peripheral computed tomography (hrpQCT) is a more sophisticated method for the assessment of the BMD. It allows a volumetric measure of the bone density (mg/cm$^3$) and can differentiate between cancellous and cortical bone. Despite the higher sensitivity of this method compared to DEXA, which allows small changes of bone density and structure also to be detected, it did not gain widespread use in clinical practice and is of more importance in the scientific field [19].

## Bone Biopsy

A biopsy is indicated if the preexisting cause of a fracture cannot be determined in order to rule out a tumorous lesion. It is not performed routinely although the incidence of unexpected cases of plasma cell dyscrasia in a series of 142 patients undergoing a kyphoplasty procedure was 3 % [96]. In rare instances, assessment of bone metabolism necessitates a biopsy.

A bone biopsy is required in equivocal cases of a tumorous lesion

## Laboratory Investigations

The laboratory work aims to rule out secondary osteoporosis and to investigate the bone metabolism:

- **alkaline phosphatase:** Raised serum levels are found in the presence of an increased bone turnover or mineralization disorders. In osteoporosis, the values are usually within the normal range or slightly raised.
- **osteocalcin:** plays a role in the mineralization of the osteoid. Increased levels are found in renal failure and during treatment with calcitriol.
- **desoxypyridinoline**: This substance is released during bone resorption and secreted by the kidneys and can be traced in the urine.

Table 4 provides an overview of the **specific laboratory parameters** for the evaluation of different aspects of bone metabolism disorders.

**Table 4.** Laboratory assessment

| |
|---|
| **Level 1 (exclusion of secondary osteoporosis):**<br>Ca, P, alkaline phosphatase, osteocalcin, creatinine, bilirubin, SGOT, SGPT, BSR, serum and urine immunoelectrophoresis, blood cell count, urine status |
| **Level 2 (clinical suspicion of secondary osteoporosis):**<br>25(OH)$D_3$ (malabsorption), parathyroid hormone, T4, TSH, testosterone, 1,25$(OH)_2D_3$ (renal osteodystrophy) |
| **Level 3 (dynamics of bone metabolism):**<br>Osteocalcin (bone formation parameter), desoxypyridinoline/creatinine ratio (bone resorption parameter) |

## Non-operative Treatment

### Conservative Fracture Management

Carefully monitor patients to avoid progressive kyphotic collapse and sagittal imbalance

Treatment of VBCF is **empirical**. Only about one-third of all fractures come to clinical attention and less than 10% necessitate hospital admission (Fig. 5) [16]. In the latter group, however, a high percentage become chronically painful due to non-union or spinal deformity [16, 92]. Bed rest for a few days and pain medication are the first measures of treatment. Bracing may be applied, but this is often not suitable in the older age group and the effect is questionable [51]. The first aim of conservative treatment is to monitor the patient and avoid a collapse of a vertebral body with consecutive kyphosis and loss of sagittal balance. Pain is the crucial parameter. If there is any doubt, serial radiographic controls should be performed.

### Medical Treatment

Every patient with VBCF should be evaluated by an osteologist

Patients with fractures after inadequate trauma are likely to be osteoporotic. Besides the treatment of the fracture, patients should be evaluated by an osteologist with regard to a formal assessment of bone metabolism and adequate medical treatment.

Osteoporosis requires appropriate systemic medical treatment

**Treatment of osteoporosis** focuses on agents that:

- prevent bone loss
- increase bone mass

The main goal of conservative treatment is to reduce the number of fragility fractures. Osteoporosis, however, is a multifactorial disease, and skeletal fragility results from various factors. Thus, achievement of optimal bone metabolism should be the aim throughout life, by age-specific non-pharmacological intervention first and adequate medication where needed.

In the past 10 years, large double-blind placebo-controlled trials have been performed to assess the efficacy of medical treatment in postmenopausal women with incident vertebral and non-vertebral fractures as a primary endpoint (Table 5). The **treatment focuses** on:

- restoration/maintenance of calcium and vitamin D metabolism
- inhibition of bone resorption by biphosphonates

The relative fracture risk is reduced 30–60% by these drugs. The absolute risk reduction is between 5% and 10%. Out of 1000 women with osteoporosis, about

**Table 5.** Pharmacological treatment for fracture prevention

| Drug | Vertebral fractures | Non-vertebral fractures |
|---|---|---|
| Alendronate | +++ | ++ |
| Calcitonin (nasal) | + | 0 |
| Etidronate | + | 0 |
| Fluoride | ± | – |
| Hormone replacement therapy[a] | + | 0 |
| Parathyroid hormone[b] | +++ | ++ |
| Raloxifene | +++ | 0 |
| Risedronate | +++ | ++ |
| Vitamin D derivatives | ± | 0 |

+++ strong evidence, ++ good evidence, + some evidence for the efficacy of treatment to prevent fractures (in addition to the effects of calcium and/or vitamin D based on RCT [20]), ± equivocal, 0 no effects, – negative effects.
[a] Evidence derived mainly from observational studies.
[b] Effect on hip fractures not documented.

**Table 6.** Risk reduction for vertebral fractures (according to Delmas [20])

| Drug | Mean age (years) | Number of patients randomized | Fracture incidence (%) | | Risk reduction (%) | |
|---|---|---|---|---|---|---|
| | | | Placebo | Drug | Rel. | Abs. |
| Alendronate 5–10 mg | 71 | 2007 | 15 | 8 | 47 | 7 |
| Calcitonin 200 IU | 69 | 557 | 16 | 11 | 25 | 4 |
| Raloxifene 60 mg | 68 | 1539 | 21 | 15 | 29 | 6 |
| Risendronate 5 mg | 69 | 1628 | 16 | 11 | 25 | 5 |
| Risendronate 5 mg | 71 | 815 | 29 | 18 | 38 | 11 |
| Recombinant human 1–34 PTH 20 µg | 69 | 892 | 14 | 5 | 64 | 9 |

150 will show a VBCF within one year. With medical treatment the number of fractures will be about 80 (9%). The absolute risk reduction is 6%, and the relative risk reduction is 60 out of 150 (40%) [20] (Table 6). However, as many as one-third of patients continue to experience pain. Approximately 15% of individuals continue to sustain fractures despite therapy. Furthermore there is a considerable number of non-responders and non-compliant patients [20, 24, 58, 83].

Approximately 15% of individuals continue to experience pain despite osteoporosis treatment

**Medical treatment** includes (Tables 4, 5):

- calcium
- vitamin D
- bisphosphonates
- raloxifene
- hormone replacement
- parathormone

A calcium intake of at least 1 g per day should be achieved and is supplemented if dietary intake is not sufficient. Vitamin D intake is about 200–400 IU per day.

## Operative Treatment

### General Principles

The majority of VBCFs respond well to non-operative treatment. However, about one-third of vertebral fractures become chronically painful [16] and 10% need hospital admission [92]. However, the number of patients who need surgical treatment remains obscure. The indications for and the goals of surgical treatment are (Table 7):

**Table 7.** Indications and goals for surgical treatment

| Indication | Goal |
|---|---|
| • Mechanical pain<br>• Claudication/sciatica<br>• (Severe) deformity | • Stabilization of the spine/vertebra<br>• Decompression of the spinal canal<br>• Restoration of anatomy |

### Surgical Principles

The surgical principles applicable for the treatment of VBCFs **depend on**:

- fracture location
- type of fracture
- number of involved vertebrae
- compromise of neural structures

The spectrum of surgical options includes:

- simple percutaneous cement reinforcement (vertebroplasty)
- restoration of vertebral body height by kyphoplasty or lordoplasty
- open surgical intervention with decompression and instrumentation
- combined procedures with internal fixation and cement reinforcement

### Vertebroplasty

Over the last decade, the approach towards osteoporotic VBCF has changed. The possibility of percutaneous cement injection into the vertebral body offers a new and extremely efficient treatment option. The technique is rather simple from a spine surgeon's perspective. However, the critical aspect of the treatment represents cement leakage. Following the technical recommendations (Tables 8, 9), the procedure can be performed safely.

Vertebroplasty is indicated after failed non-operative treatment

The indications and contraindications for vertebroplasty (VB) are listed in Tables 10 and 11. The main indication represents acute and subacute VBCF due to osteoporosis after non-operative treatment has failed.

In this group of patients, percutaneous reinforcement provides a major pain improvement in more than 80 % of cases and prevents the further vertebral col-

**Table 8.** Key points of surgical technique

- high quality C-arm
- guidewire
- large diameter cannulas (8G)
- direct cement application with small syringes (1 cc, 2 cc)
- cement with high radiopacity
- Cement with high/adapted viscosity

**Table 9.** Steps of surgical technique

- positioning and monitoring of patient, i.v. line
- image control previous to draping, marking of levels to be treated
- local anesthesia in line with the pedicle (unless general anesthesia is used)
- stab incision and preliminary placement of guidewire(s)
- readjustment and definitive placement of guidewire(s)
- placement of filling cannulas
- preparation of cement according to recommendations of producer, distribution into small syringes
- cement application with adequate viscosity, high viscous cement is inserted with the aid of 1 cc syringes or the trocar
- cannula removal after curing of the cement

**Table 10.** Indications for vertebroplasty

- ongoing pain for more than 2 weeks after occurrence of a new fracture
- severe pain; patients remain bedridden for more than 4 days
- progressive compression fractures of one or multiple vertebrae with subsequent loss of posture
- non-union with persisting instability (Kummel-Verneuil disease)
- combined procedures with internal fixation in severe osteoporosis

**Table 11.** Contraindications for vertebroplasty

- pain unlikely to be related to a fracture
- infection
- blood clotting disorders
- neurological compromise
- impaired visibility during surgery
- poor general state of patient, unable to stand in prone position
- if an open procedure appears more appropriate

**Table 12.** Results of vertebroplasty

| Reference | Patient number | Levels treated | Duration of FU | Pain improved (%) | Complications/remarks |
|---|---|---|---|---|---|
| **Prospective case series** | | | | | |
| McKiernan [65] | 46 | 66 | 6 months | | none |
| Zoarski [105] | 30 | 54 | 15–18 months | 96 | none, 2 local leaks, not symptomatic |
| Perez-Higueras [77] | 13 | 27 | 60 months | 12/13 | 2 transitory neuritis, local leakage 48%, 3 adjacent fractures |
| McGraw [64] | 100 | 156 | 21 months | 93 | 1 sternal fracture, 1 transient neuritis |
| Heini [37] | 17 | 45 | 12 months | 76% | none/local leakage in 20%, clinically insignificant |
| Cortet [17] | 16 | 20 | 6 months | – | no complications |
| McKiernan [66] | 41 | 65 | 2 weeks | – | dynamic fracture mobility present in 44% of patients |
| **Retrospective case series** | | | | | |
| Barr [4] | 39 | 70 | 18 months (2–42) | 95 | 1 transient neuritis |
| Hodler [38] | 152 | 363 | 8.8 months (1–24) | 86 | 71% local leakage without clinical sequelae |
| Jensen [41] | 29 | 47 | – | 90 | |
| Brown [9] | 41 | 77 | 15.8 months (6–28) | 80 | fractures older than 12 months |
| Maynard [63] | 27 | 35 | – | 93 | patients with positive bone scan |
| Cyteval [18] | 20 | nm | – | 75 | one leakage into psoas, one adjacent level fracture |
| Kaufmann [48] | 75 | 122 | 7 days | – | preprocedural pain medication and activity level = predictive for outcome |
| Peh [76] | 37 | 48 | 11 months (3–24) | 97 | 43% leakage without clinical symptoms |

lapse [37]. Even in older fractures, VP can still be effective [9]. In patients with severe osteoporosis and rapidly developing fractures, the reinforcement of multiple levels is an efficient means to preserve posture and prevent further collapse (Fig. 4) [36]. A non-union after a VBCF can occur in up to 40% of patients [66]. In these situations cementing of the defect provides stability (Fig. 6).

Vertebroplasty improves pain in about 80–90% of patients

The treatment of osteoporotic VBCF by percutaneous cement injection has become a well established treatment option. Several prospective case series have been published and confirm a rapid and lasting pain relief in 80–90% of patients (Table 11) [4, 23, 36–38, 77]. In fresh fractures the pain improvement is seen in 93% of patients [63]. But also in older lesions the treatment can be effective in as many as 80% of patients (Table 12) [9, 48].

The scientific evidence for the superiority of vertebroplasty compared to non-operative care is still lacking

However, there are no randomized controlled trial (RCT) studies to compare this treatment with conservative measures. Besides the rapid pain reduction, an important aspect of vertebroplasty is the prevention of further collapse of the VB [36]. Restoration of lordosis after a VBFC can be attempted if the fracture is still mobile [100]. This is applicable in non-unions, which can occur in up to 40% [66] just by placing the patient in hyperextension. Furthermore, this can be achieved in fractures that are up to 2 months old.

### *Pitfalls of Cement Reinforcement*

**Complications** (Table 13) related to percutaneous cement reinforcement may occur due to:

- Positioning of the patient (fragility fractures of the rib, prone position alone)

**Table 13.** Complications reported for vertebroplasty and kyphoplasty

| | |
|---|---|
| Rib and sternal fractures | few case reports [41, 56, 64] |
| Technical complications | pedicle fractures [21, 44]<br>fracture of transverse process [21]<br>spinal cord injury during cannula placement [26] |
| Infection | 4 case reports [44, 88, 101, 104] |
| Cement leakage | severe complication after pulmonary cement embolism [11, 25, 69, 93, 94, 97]<br>oligosymptomatic cement embolism [5, 7, 74, 79]<br>neurological complication [12, 53, 91, 103]<br>renal cement embolism [13]<br>cerebral cement embolization [90] |
| Fat embolism | fatal outcome due to fat embolism [94] |
| Adjacent fractures | increased risk after VP [6, 30, 50, 57, 98]<br>not significantly increased [54, 95] |

- Anesthesia
- Placement of cannula
- Cement injection

The **inherent problems** associated with any percutaneous cement injection technique are:

- cement extravasation with compromise of neural structures
- cement embolization

Although local cement leakage is well tolerated in most cases, if cement leaks into the spinal canal, it is potentially deleterious and the resulting neural damage often irreversible. Furthermore systemic reactions during cement injection can occur which might be related to the leaking of the toxic cement monomer in the blood circulation. In the literature many reports of complications can be found [7, 32, 75, 81, 86, 90, 97, 99, 103].

Cement leakage into the spinal canal is the most serious complication

The **frequency of local cement leakage** in vertebroplasty is reported to be between 3% and 75% [80]. This wide variance depends on technique of assessment, i.e., radiographs are less reliable than CT [89].

In order to minimize the extravasation risk, it is strongly advocated to respect strictly the following recommendations:

- use of large diameter cannulas
- inject cement with enhanced radiopacity
- be aware of the key factor cement **viscosity** [8]

The surgical guidelines must be strictly respected

The use of small syringes allows direct control of the cement flow [3]. Any suspicious cement flow behavior must lead to immediate discontinuation of injection. The filling behavior is changing with increasing viscosity – if the cement flow does not behave as expected, one should pause for 45 s and reinject a small amount of cement.

Pulmonary cement embolism is a potentially lethal complication

Reinforcement of the osteoporotic VB means substitution of the bone marrow with cement. The fatty bone marrow is expelled into the circulation and is cleared in the lungs [94]. Therefore the **maximal amount of cement** that is injected per session is restricted to **25 cc**; in other words not more than six levels should be reinforced per session [36].

### *Risk of Adjacent Vertebral Fractures*

The risk of a fracture in the adjacent levels seems to be increased after cement reinforcement [6, 30, 50, 98]. However, the natural history of osteoporotic VBCF needs to be taken into consideration, as the risk of a new fracture rises exponentially with increasing number of fractures [58, 84]. Therefore patients and their post-treatment doctors should be informed about controlling the situation if new pain does appear. In such cases, reinforcement of the adjacent vertebrae should be performed.

The risk of adjacent level fractures appears to be increased after vertebroplasty

Of course, during the placement of the cannula itself there is the potential risk of an injury of the neural structures. Familiarity with the spinal anatomy and experience with open surgery is therefore mandatory. The occurrence of rib fractures during positioning might occur. Complications associated with local anesthetic can occur in very rare instances.

## Kyphoplasty and Lordoplasty

Vertebroplasty does not per se allow the restoration of the kyphotic deformity (unless the positioning itself provides some correction; Fig. 6). VP stabilizes the fractured vertebral body in situ. **Kyphoplasty** was therefore promoted to restore the VB height and correct the kyphotic deformity and realign the spine [26, 102].

Kyphoplasty aims to correct kyphosis and height loss

Height restoration and decrease in cement leakage are the main points that differentiate this technique from vertebroplasty [70, 78]. However, the potential of kyphosis reduction appears to be moderate. The absolute **correction** of the kyphotic angle is reported with an **average of 8.5 degrees** [35, 56] without taking into consideration the spontaneous correction due to positioning [100] (Table 14).

Lordotic positioning is an important component of kyphoplasty

**Table 14.** Comparison of kyphoplasty and lordoplasty

| | Kyphoplasty | Lordoplasty |
|---|---|---|
| Number of patients | 27 pts. | 31 pts. |
| Min. FU | > 1 year | > 1 year |
| Average kyphosis correction | 8.5° (47 %) | 14° (68 %) |
| Cost (euros) | 3 000 | 300 |

Based on a prospective case series [73]

Its excessive cost and more complex procedure on one hand and the improved surgical technique in vertebroplasty by injecting high viscosity cement, with a rate of leakage no different from that of kyphoplasty on the other hand, place a questionmark over its usefulness. Its indications are restricted to selected cases where height loss is associated with a spinal stenosis and its restoration can relieve the symptoms or in cases of traumatic fractures where the repositioning of the endplate is attempted (Case Introduction). Furthermore the cavity formation might be of help in difficult indications for tumorous lesions [31, 35, 62, 70].

Alternatively, a **lordoplasty** procedure can be performed. Analogous to the established principle of the "fixateur interne," an indirect reduction maneuver is performed [22]. The vertebral bodies above and below the fracture are instrumented with cannulas and reinforced in a classical technique. After curing of the cement, the cannulas are used as a lever and the collapsed VB is reduced and maintained in this position until the cement is injected and cured in the fractured vertebra [35]. This principle might be combined with a kyphoplasty procedure and help to overcome a shortcoming of kyphoplasty, i.e., the partial loss of initial reduction after deflation of the balloons [100]. The resulting segmental kyphosis correction was 14° on average measured one year postoperatively in a prospective series of 31 patients for the lordoplasty procedure and 8.5° for kyphoplasty

Lordoplasty is an effective alternative to kyphoplasty

(Table 14) [73]. **The indication for this procedure is given if a relevant kyphotic deformity is present that still has a potential for reduction.**

### Combined Procedures

Cases of VBCF with subsequent neural compromise due to a deformity (thoracic kyphosis) or instability (lumbar spinal stenosis, Fig. 4d) are seen with increasing frequency [33, 34, 49, 52, 72]. Displaced fragments may narrow the spinal canal with subsequent compression of the myelon or nerves. Due to the height loss, a foraminal narrowing may lead to nerve root compression. The fact of increasing incidence of spinal stenosis per se and the high risk of osteoporotic fractures seems to boost the frequency of acute exacerbation of these groups of patients where only open surgery with decompression and stabilization can help to solve the problem [14, 40, 42, 71].

Pedicle screw fixation with cement reinforcement allows even fragile vertebrae to be stabilized

A surgical decompression procedure only, without stabilization, provides unsatisfactory results for this kind of problem – the decompressive measure will further compromise the mechanical stability [49, 71]. Any closed measures with cement reinforcement will not relieve symptoms derived from a spinal stenosis as long as the collapsed segment cannot be restored (see below). An open procedure with decompression of the spinal canal and internal fixation and fusion is usually required. However, the problem of **anchoring the implants** in the osteoporotic bone on one hand and the risk of new fractures adjacent to the stabilized part of the spine needs to be addressed. Combined internal fixation with cemented screws and the reinforcement of adjacent levels can help to overcome the troubles associated with these osteoporotic spines and allow the same technical principles to be applied as in healthy bone. The combination of internal fixation and cement reinforcement appears extremely helpful.

Prophylactic vertebroplasty of an adjacent vertebra must be considered

However, in our series of 21 patients who were treated in this manner, five out of eight who received only a cement fixation of screws showed a fracture of the adjacent vertebrae within 2–6 weeks after the stabilization, and needed an extension of the fixation. Therefore it appears mandatory to **reinforce the adjacent vertebrae** in order to prevent this complication.

## Recapitulation

**Epidemiology.** Osteoporotic vertebral body compression fractures (VBCFs) are the **hallmark of osteoporosis** and are frequent. Approximately 30–50% of women and 20–30% of men will develop vertebral fractures during their life, and half of them will develop multiple fractures. The socioeconomic costs of this problem are enormous.

**Pathogenesis and classification.** Osteoporosis is the result of an imbalance between bone formation and bone loss. Osteoporosis can be either primary or secondary. **Primary osteoporosis** is either postmenopausal (type 1) or senile osteoporosis (type 2). **Secondary osteoporosis** can be due to diseases, medical treatments, or lifestyle (diet, smoking). Osteoporosis is defined as a bone mineral density below 2.5 SD of the mean for a young adult reference population.

**Clinical presentation.** Patients who acquire a fracture can be asymptomatic. The **cardinal symptoms** of acute osteoporotic vertebral fractures are acute, sharp girdle like pain that can be breathtaking initially. The pain is often misconceived as back strain and is not further diagnosed unless more severe problems occur. The physical findings are almost always non-specific. However, neurologic assessment is mandatory to rule out neural compromise.

**Diagnostic work-up.** The assessment of patients with VBCFs should include a formal evaluation of the underlying osteoporosis as a systemic disease (laboratory testing, DEXA scan). A tumorous lesion or secondary osteoporosis must be excluded. Standard radiographs remain the method of choice in the diagnostic work-up. An MRI scan is necessary to

determine whether a fracture is acute or has already healed by using a fluid-sensitive sequence (e.g. STIR). A CT scan is helpful to better assess the fracture type and anatomy.

**Non-operative treatment.** Medical treatment of the osteoporosis is mandatory after a thorough osteologic assessment. The majority of patients with osteoporotic vertebral fractures become pain free within a few days or weeks. Bed rest for a few days may be necessary. **Painkillers** should be prescribed. Non-operative treatment means careful follow-up of the patients. Severe pain that is persisting means a progression of vertebral collapse and patients should obtain a follow-up X-ray examination.

**Operative treatment.** **Vertebroplasty** is the treatment of choice for severely painful fractures. This leads to immediate pain relief in up to 90 % of cases and prevents further collapse of the vertebrae while helping to preserve spinal alignment and balance. If a complex fracture is present, which means a concomitant neurological compression and/or a severe spinal deformity, **open surgical treatment** is advocated. In these cases a combination of cement reinforcement and internal fixation might be necessary in order to achieve sufficient stability.

## Key Articles

**Delmas PD (2002) Treatment of postmenopausal osteoporosis. Lancet 359:2018 – 26**
Excellent review on the medical treatment of osteoporosis.

**Hodler J, Peck D, Gilula LA (2003) Midterm outcome after vertebroplasty: predictive value of technical and patient-related factors. Radiology 227:662 – 668**
This study evaluated different types of polymethylmethacrylate (PMMA) leakage and patient-related factors in relation to clinical midterm (1 – 24 month) outcome after vertebroplasty. Standardized four-view radiographs obtained during 363 vertebroplasties in 181 treatment sessions in 152 patients were reviewed (121 patients with osteoporotic fractures, 30 with malignant disease, and one with hemangioma). Four types of PMMA leakage and other potential predictors were related to postprocedural pain response and midterm outcome after vertebroplasty. The mean follow-up period was 8.8 months (range 1 – 24 months). At the time of discharge after the procedure, pain was absent after 106 of the 181 sessions (58.5 %), better after 50 (27.6 %), and the same after 25 (13.8 %). In 258 of the 363 treated vertebral levels, at least one type of leakage was found. None of the evaluated factors was related significantly to postprocedural pain response, including PMMA leakage. The authors concluded that small to moderate amounts of PMMA may escape from the vertebral body with no significant effect on therapeutic success. Immediate postprocedural pain relief was regarded as the best predictor of midterm clinical outcome after vertebroplasty.

**Alvarez L, Alcaraz M, Perez-Higueras A, Granizo JJ, de Miguel I, Rossi RE, Quinones D (2006) Percutaneous vertebroplasty: functional improvement in patients with osteoporotic compression fractures. Spine 31:1113 – 8**
In this prospective, double-cohort study on the outcome of vertebral compression fractures, 101 consecutive patients who underwent percutaneous vertebroplasty (PV) were compared to 27 patients who refused PV treatment and were managed conservatively. Patients elected for PV as a treatment had significantly more pain and functional impairment before the procedure than the patients of the conservative group ($P < 0.001$). The pain, functional, and general health scores of the PV group were improved from the preoperative mean values ($P < 0.001$) in all postoperative periods. Compared with the conservative treatment group, there was a significant difference at month 3. However, no statistical differences on function were observed between these groups at 6 months and 1 year post-treatment. The authors concluded that PV demonstrated a rapid and significant relief of pain and improved the quality of life.

## References


1. Anonymous (1993) Consensus Development Conference on Osteoporosis. Hong Kong, April 1 – 2, 1993. Am J Med 95:1S–78S
2. Anonymous (2002) Incidence of vertebral fracture in Europe: results from the European Prospective Osteoporosis Study (EPOS). J Bone Miner Res 17:716 – 724
3. Baroud G, Bohner M, Heini P, Steffen T (2004) Injection biomechanics of bone cements used in vertebroplasty. Biomed Mater Eng 14:487 – 504
4. Barr JD, Barr MS, Lemley TJ, McCann RM (2000) Percutaneous vertebroplasty for pain relief and spinal stabilization. Spine 25:923 – 928
5. Baumann A, Tauss J, Baumann G, Tomka M, Hessinger M, Tiesenhausen K (2006) Cement embolization into the vena cava and pulmonal arteries after vertebroplasty: interdisciplinary management. Eur J Vasc Endovasc Surg 31:558 – 561
6. Berlemann U, Ferguson SJ, Nolte LP, Heini PF (2002) Adjacent vertebral failure after vertebroplasty. A biomechanical investigation. J Bone Joint Surg Br 84:748 – 752
7. Bernhard J, Heini PF, Villiger PM (2003) Asymptomatic diffuse pulmonary embolism caused by acrylic cement: an unusual complication of percutaneous vertebroplasty. Ann Rheum Dis 62:85 – 86
8. Bohner M, Gasser B, Baroud G, Heini P (2003) Theoretical and experimental model to describe the injection of a polymethylmethacrylate cement into a porous structure. Biomaterials 24:2721 – 2730
9. Brown DB, Gilula LA, Sehgal M, Shimony JS (2004) Treatment of chronic symptomatic vertebral compression fractures with percutaneous vertebroplasty. AJR Am J Roentgenol 182:319 – 322
10. Center JR, Nguyen TV, Schneider D, Sambrook PN, Eisman JA (1999) Mortality after all major types of osteoporotic fracture in men and women: an observational study. Lancet 353:878 – 882
11. Chen HL, Wong CS, Ho ST, Chang FL, Hsu CH, Wu CT (2002) A lethal pulmonary embolism during percutaneous vertebroplasty. Anesth Analg 95:1060 – 1062, table of contents
12. Chen YJ, Tan TS, Chen WH, Chen CC, Lee TS (2006) Intradural cement leakage: a devastatingly rare complication of vertebroplasty. Spine 31:E379 – 382
13. Chung SE, Lee SH, Kim TH, Yoo KH, Jo BJ (2006) Renal cement embolism during percutaneous vertebroplasty. Eur Spine J 15(Suppl. 5):590 – 594
14. Ciol MA, Deyo RA, Howell E, Kreif S (1996) An assessment of surgery for spinal stenosis: time trends, geographic variations, complications, and reoperations. J Am Geriatr Soc 44:285 – 290
15. Cook DJ, Guyatt GH, Adachi JD, Clifton J, Griffith LE, Epstein RS, Juniper EF (1993) Quality of life issues in women with vertebral fractures due to osteoporosis. Arthritis Rheum 36:750 – 756
16. Cooper C, Atkinson EJ, O'Fallon WM, Melton LJ, 3rd, (1992) Incidence of clinically diagnosed vertebral fractures: a population-based study in Rochester, Minnesota, 1985 – 1989. J Bone Miner Res 7:221 – 227
17. Cortet B, Cotten A, Boutry N, Flipo RM, Duquesnoy B, Chastanet P, Delcambre B (1999) Percutaneous vertebroplasty in the treatment of osteoporotic vertebral compression fractures: an open prospective study. J Rheumatol 26:2222 – 2228
18. Cyteval C, Sarrabere MP, Roux JO, Thomas E, Jorgensen C, Blotman F, Sany J, Taourel P (1999) Acute osteoporotic vertebral collapse: open study on percutaneous injection of acrylic surgical cement in 20 patients. AJR Am J Roentgenol 173:1685 – 1690
19. Dambacher MA, Neff M, Kissling R, Qin L (1998) Highly precise peripheral quantitative computed tomography for the evaluation of bone density, loss of bone density and structures. Consequences for prophylaxis and treatment. Drugs Aging 12 Suppl 1:15 – 24
20. Delmas PD (2002) Treatment of postmenopausal osteoporosis. Lancet 359:2018 – 2026
21. Diamond TH, Champion B, Clark WA (2003) Management of acute osteoporotic vertebral fractures: a nonrandomized trial comparing percutaneous vertebroplasty with conservative therapy. Am J Med 114:257 – 265
22. Dick W (1987) The "fixateur interne" as a versatile implant for spine surgery. Spine 12: 882 – 900
23. Einhorn TA (2000) Vertebroplasty: an opportunity to do something really good for patients. Spine 25:1051 – 1052
24. Ettinger B, Pressman A, Schein J (1998) Clinic visits and hospital admissions for care of acid-related upper gastrointestinal disorders in women using alendronate for osteoporosis. Am J Manag Care 4:1377 – 1382
25. Francois K, Taeymans Y, Poffyn B, Van Nooten G (2003) Successful management of a large pulmonary cement embolus after percutaneous vertebroplasty: a case report. Spine 28: E424 – 425
26. Garfin SR, Yuan HA, Reiley MA (2001) New technologies in spine: kyphoplasty and verte-

broplasty for the treatment of painful osteoporotic compression fractures. Spine 26: 1511 – 1515
27. Gass M, Dawson-Hughes B (2006) Preventing osteoporosis-related fractures: an overview. Am J Med 119:S3–S11
28. Genant HK, Wu CY, van Kuijk C, Nevitt MC (1993) Vertebral fracture assessment using a semiquantitative technique. J Bone Miner Res 8:1137 – 1148
29. Gold DT (1996) The clinical impact of vertebral fractures: quality of life in women with osteoporosis. Bone 18:185S–189S
30. Grados F, Depriester C, Cayrolle G, Hardy N, Deramond H, Fardellone P (2000) Long-term observations of vertebral osteoporotic fractures treated by percutaneous vertebroplasty. Rheumatology (Oxford) 39:1410 – 1414
31. Groen RJ, du Toit DF, Phillips FM, Hoogland PV, Kuizenga K, Coppes MH, Muller CJ, Grobbelaar M, Mattyssen J (2004) Anatomical and pathological considerations in percutaneous vertebroplasty and kyphoplasty: a reappraisal of the vertebral venous system. Spine 29:1465 – 1471
32. Harrington KD (2001) Major neurological complications following percutaneous vertebroplasty with polymethylmethacrylate : a case report. J Bone Joint Surg Am 83A:1070 – 1073
33. Heaney RP (1992) The natural history of vertebral osteoporosis. Is low bone mass an epiphenomenon? Bone 13:S23 – 26
34. Heggeness MH (1993) Spine fracture with neurological deficit in osteoporosis. Osteoporos Int 3:215 – 221
35. Heini PF, Orler R (2004) Kyphoplasty for treatment of osteoporotic vertebral fractures. Eur Spine J 13:184 – 192
36. Heini PF, Orler R (2004) Vertebroplasty in severe osteoporosis. Technique and experience with multi-segment injection. Orthopaede 33:22 – 30
37. Heini PF, Walchli B, Berlemann U (2000) Percutaneous transpedicular vertebroplasty with PMMA: operative technique and early results. A prospective study for the treatment of osteoporotic compression fractures. Eur Spine J 9:445 – 450
38. Hodler J, Peck D, Gilula LA (2003) Midterm outcome after vertebroplasty: predictive value of technical and patient-related factors. Radiology 227:662 – 668
39. IOF (2003) Osteoporosis in the European Community: Action plan. www.osteofound.org/advocacy_policy/eu_policy_project.html
40. Jansson KA, Blomqvist P, Granath F, Nemeth G (2003) Spinal stenosis surgery in Sweden 1987 – 1999. Eur Spine J 12:535 – 541
41. Jensen ME, Evans AJ, Mathis JM, Kallmes DF, Cloft HJ, Dion JE (1997) Percutaneous polymethylmethacrylate vertebroplasty in the treatment of osteoporotic vertebral body compression fractures: technical aspects. AJNR Am J Neuroradiol 18:1897 – 1904
42. Johnsson KE, Sass M (2004) Cauda equina syndrome in lumbar spinal stenosis: case report and incidence in Jutland, Denmark. J Spinal Disord Tech 17:334 – 335
43. Kado DM, Browner WS, Palermo L, Nevitt MC, Genant HK, Cummings SR (1999) Vertebral fractures and mortality in older women: a prospective study. Study of Osteoporotic Fractures Research Group. Arch Intern Med 159:1215 – 1220
44. Kallmes DF, Schweickert PA, Marx WF, Jensen ME (2002) Vertebroplasty in the mid- and upper thoracic spine. AJNR Am J Neuroradiol 23:1117 – 1120
45. Kanis JA (2002) Diagnosis of osteoporosis and assessment of fracture risk. Lancet 359:1929 – 1936
46. Kanis JA, Melton LJ, 3rd, Christiansen C, Johnston CC, Khaltaev N (1994) The diagnosis of osteoporosis. J Bone Miner Res 9:1137 – 1141
47. Kanis JA, Pitt FA (1992) Epidemiology of osteoporosis. Bone 13:S7 – 15
48. Kaufmann TJ, Jensen ME, Schweickert PA, Marx WF, Kallmes DF (2001) Age of fracture and clinical outcomes of percutaneous vertebroplasty. AJNR Am J Neuroradiol 22:1860 – 1863
49. Kim KT, Suk KS, Kim JM, Lee SH (2003) Delayed vertebral collapse with neurological deficits secondary to osteoporosis. Int Orthop 27:65 – 69
50. Kim SH, Kang HS, Choi JA, Ahn JM (2004) Risk factors of new compression fractures in adjacent vertebrae after percutaneous vertebroplasty. Acta Radiol 45:440 – 445
51. Kishimoto H (2001) [Orthopaedic management for severe osteoporosis]. Clin Calcium 11:1582 – 1587
52. Korovessis P, Maraziotis T, Piperos G, Spyropoulos P (1994) Spontaneous burst fracture of the thoracolumbar spine in osteoporosis associated with neurological impairment: a report of seven cases and review of the literature. Eur Spine J 3:286 – 288
53. Lee BJ, Lee SR, Yoo TY (2002) Paraplegia as a complication of percutaneous vertebroplasty with polymethylmethacrylate: a case report. Spine 27:E419 – 422
54. Legroux-Gerot I, Lormeau C, Boutry N, Cotten A, Duquesnoy B, Cortet B (2004) Long-term follow-up of vertebral osteoporotic fractures treated by percutaneous vertebroplasty. Clin Rheumatol 23:310 – 317
55. Leidig G, Minne HW, Sauer P, Wuster C, Wuster J, Lojen M, Raue F, Ziegler R (1990) A study of complaints and their relation to vertebral destruction in patients with osteoporosis. Bone Miner 8:217 – 229

56. Lieberman IH, Dudeney S, Reinhardt MK, Bell G (2001) Initial outcome and efficacy of "kyphoplasty" in the treatment of painful osteoporotic vertebral compression fractures. Spine 26:1631 – 1638
57. Lin EP, Ekholm S, Hiwatashi A, Westesson PL (2004) Vertebroplasty: cement leakage into the disc increases the risk of new fracture of adjacent vertebral body. AJNR Am J Neuroradiol 25:175 – 180
58. Lindsay R (2001) Risk of new vertebral fracture in the year following a fracture. JAMA 285:320 – 323
59. Lippuner K, Golder M, Greiner R (2005) Epidemiology and direct medical costs of osteoporotic fractures in men and women in Switzerland. Osteoporos Int 16 Suppl 2:S8–S17
60. Magerl F, Aebi M, Gertzbein SD, Harms J, Nazarian S (1994) A comprehensive classification of thoracic and lumbar injuries. Eur Spine J 3:184 – 201
61. Marshall D, Johnell O, Wedel H (1996) Meta-analysis of how well measures of bone mineral density predict occurrence of osteoporotic fractures. BMJ 312:1254 – 1259
62. Mathis JM, Ortiz AO, Zoarski GH (2004) Vertebroplasty versus kyphoplasty: a comparison and contrast. AJNR Am J Neuroradiol 25:840 – 845
63. Maynard AS, Jensen ME, Schweickert PA, Marx WF, Short JG, Kallmes DF (2000) Value of bone scan imaging in predicting pain relief from percutaneous vertebroplasty in osteoporotic vertebral fractures. AJNR Am J Neuroradiol 21:1807 – 1812
64. McGraw JK, Lippert JA, Minkus KD, Rami PM, Davis TM, Budzik RF (2002) Prospective evaluation of pain relief in 100 patients undergoing percutaneous vertebroplasty: results and follow-up. J Vasc Interv Radiol 13:883 – 886
65. McKiernan F, Faciszewski T, Jensen R (2004) Quality of life following vertebroplasty. J Bone Joint Surg Am 86-A:2600 – 2606
66. McKiernan F, Jensen R, Faciszewski T (2003) The dynamic mobility of vertebral compression fractures. J Bone Miner Res 18:24 – 29
67. Melton LJ, 3rd, Kan SH, Frye MA, Wahner HW, O'Fallon WM, Riggs BL (1989) Epidemiology of vertebral fractures in women. Am J Epidemiol 129:1000 – 1011
68. Melton LJ, 3rd, Lane AW, Cooper C, Eastell R, O'Fallon WM, Riggs BL (1993) Prevalence and incidence of vertebral deformities. Osteoporos Int 3:113 – 119
69. Monticelli F, Meyer HJ, Tutsch-Bauer E (2005) Fatal pulmonary cement embolism following percutaneous vertebroplasty (PVP). Forensic Sci Int 149:35 – 38
70. Myers ME (2004) Vertebroplasty and kyphoplasty: is one of these procedures the best choice for all patients? AJNR Am J Neuroradiol 25:1297
71. Natelson SE (1986) The injudicious laminectomy. Spine 11:966 – 969
72. Nguyen HV, Ludwig S, Gelb D (2003) Osteoporotic vertebral burst fractures with neurologic compromise. J Spinal Disord Tech 16:10 – 19
73. Orler R, Frauchiger LH, Lange U, Heini PF (2006) Lordoplasty: report on early results with a new technique for the treatment of vertebral compression fractures to restore the lordosis. Eur Spine J 15:1769 – 75
74. Padovani B, Kasriel O, Brunner P, Peretti-Viton P (1999) Pulmonary embolism caused by acrylic cement: a rare complication of percutaneous vertebroplasty. AJNR Am J Neuroradiol 20:375 – 377
75. Padovani B, Kasriel O, Brunner P, Peretti-Viton P (1999) Pulmonary embolism caused by acrylic cement: a rare complication of percutaneous vertebroplasty. AJNR Am J Neuroradiol 20:375 – 377
76. Peh WC, Gilula LA, Peck DD (2002) Percutaneous vertebroplasty for severe osteoporotic vertebral body compression fractures. Radiology 223:121 – 126
77. Perez-Higueras A, Alvarez L, Rossi RE, Quinones D, Al-Assir I (2002) Percutaneous vertebroplasty: long-term clinical and radiological outcome. Neuroradiology 44:950 – 954
78. Phillips FM, Todd Wetzel F, Lieberman I, Campbell-Hupp M (2002) An in vivo comparison of the potential for extravertebral cement leak after vertebroplasty and kyphoplasty. Spine 27:2173 – 2178; discussion 2178 – 2179
79. Pleser M, Roth R, Worsdorfer O, Manke C (2004) [Pulmonary embolism caused by PMMA in percutaneous vertebroplasty. Case report and review of the literature]. Unfallchirurg 107:807 – 811
80. Ploeg WT, Veldhuizen AG, The B, Sietsma MS (2006) Percutaneous vertebroplasty as a treatment for osteoporotic vertebral compression fractures: a systematic review. Eur Spine J 15:1749 – 58
81. Ratliff J, Nguyen T, Heiss J (2001) Root and spinal cord compression from methylmethacrylate vertebroplasty. Spine 26:E300 – 302
82. Reginster JY, Burlet N (2006) Osteoporosis: a still increasing prevalence. Bone 38:S4 – 9
83. Riggs BL, Melton LJ, 3rd (1995) The worldwide problem of osteoporosis: insights afforded by epidemiology. Bone 17:505S–511S
84. Ross PD, Genant HK, Davis JW, Miller PD, Wasnich RD (1993) Predicting vertebral fracture incidence from prevalent fractures and bone density among non-black, osteoporotic women. Osteoporos Int 3:120 – 126

85. Ryan PJ, Blake G, Herd R, Fogelman I (1994) A clinical profile of back pain and disability in patients with spinal osteoporosis. Bone 15:27 – 30
86. Ryu KS, Park CK, Kim MC, Kang JK (2002) Dose-dependent epidural leakage of polymethylmethacrylate after percutaneous vertebroplasty in patients with osteoporotic vertebral compression fractures. J Neurosurg 96:56 – 61
87. Schlaich C, Minne HW, Bruckner T, Wagner G, Gebest HJ, Grunze M, Ziegler R, Leidig-Bruckner G (1998) Reduced pulmonary function in patients with spinal osteoporotic fractures. Osteoporos Int 8:261 – 267
88. Schmid KE, Boszczyk BM, Bierschneider M, Zarfl A, Robert B, Jaksche H (2005) Spondylitis following vertebroplasty: a case report. Eur Spine J 14:895 – 899
89. Schmidt R, Cakir B, Mattes T, Wegener M, Puhl W, Richter M (2005) Cement leakage during vertebroplasty: an underestimated problem? Eur Spine J 14:466 – 473
90. Scroop R, Eskridge J, Britz GW (2002) Paradoxical cerebral arterial embolization of cement during intraoperative vertebroplasty: case report. AJNR Am J Neuroradiol 23:868 – 870
91. Shapiro S, Abel T, Purvines S (2003) Surgical removal of epidural and intradural polymethylmethacrylate extravasation complicating percutaneous vertebroplasty for an osteoporotic lumbar compression fracture. Case report. J Neurosurg 98:90 – 92
92. Silverman SL (1992) The clinical consequences of vertebral compression fracture. Bone 13:S27 – 31
93. Stricker K, Orler R, Yen K, Takala J, Luginbuhl M (2004) Severe hypercapnia due to pulmonary embolism of polymethylmethacrylate during vertebroplasty. Anesth Analg 98:1184 – 1186, table of contents
94. Syed MI, Jan S, Patel NA, Shaikh A, Marsh RA, Stewart RV (2006) Fatal fat embolism after vertebroplasty: identification of the high-risk patient. AJNR Am J Neuroradiol 27:343 – 345
95. Syed MI, Patel NA, Jan S, Harron MS, Morar K, Shaikh A (2005) Intradiskal extravasation with low-volume cement filling in percutaneous vertebroplasty. AJNR Am J Neuroradiol 26:2397 – 2401
96. Togawa D, Lieberman IH, Bauer TW, Reinhardt MK, Kayanja MM (2005) Histological evaluation of biopsies obtained from vertebral compression fractures: unsuspected myeloma and osteomalacia. Spine 30:781 – 786
97. Tozzi P, Abdelmoumene Y, Corno AF, Gersbach PA, Hoogewoud HM, von Segesser LK (2002) Management of pulmonary embolism during acrylic vertebroplasty. Ann Thorac Surg 74:1706 – 1708
98. Uppin AA, Hirsch JA, Centenera LV, Pfiefer BA, Pazianos AG, Choi IS (2003) Occurrence of new vertebral body fracture after percutaneous vertebroplasty in patients with osteoporosis. Radiology 226:119 – 124
99. Vasconcelos C, Gailloud P, Martin JB, Murphy KJ (2001) Transient arterial hypotension induced by polymethylmethacrylate injection during percutaneous vertebroplasty. J Vasc Interv Radiol 12:1001 – 1002
100. Voggenreiter G (2005) Balloon kyphoplasty is effective in deformity correction of osteoporotic vertebral compression fractures. Spine 30:2806 – 2812
101. Walker DH, Mummaneni P, Rodts GE, Jr (2004) Infected vertebroplasty. Report of two cases and review of the literature. Neurosurg Focus 17:E6
102. Wong W, Riley MA, Garfin S (2000) Vertebroplasty/kyphoplasty. J Womens Imaging 2:117 – 124
103. Yoo KY, Jeong SW, Yoon W, Lee J (2004) Acute respiratory distress syndrome associated with pulmonary cement embolism following percutaneous vertebroplasty with polymethylmethacrylate. Spine 29:E294 – 297
104. Yu SW, Chen WJ, Lin WC, Chen YJ, Tu YK (2004) Serious pyogenic spondylitis following vertebroplasty – a case report. Spine 29:E209 – 211
105. Zoarski GH, Snow P, Olan WJ, Stallmeyer MJ, Dick BW, Hebel JR, De Deyne M (2002) Percutaneous vertebroplasty for osteoporotic compression fractures: quantitative prospective evaluation of long-term outcomes. J Vasc Interv Radiol 13:139 – 148

# 33 Primary Tumors of the Spine

Bruno Fuchs, Norbert Boos

## Core Messages

- ✔ Primary spine tumors are relatively rare
- ✔ Cancer is a genetic disease
- ✔ The acquired capabilities of cancer are: self-sufficiency to growth signals, insensitivity to anti-growth signals, tissue invasion and metastasis, limitless replicative potential, sustained angiogenesis, evading apoptosis
- ✔ Spine tumors are classified based on the histology
- ✔ Pain, spinal deformity, and neurologic deficits frequently are presenting symptoms
- ✔ Age and location are important parameters for establishing a differential diagnosis
- ✔ CT and MRI are essential for systemic and surgical staging
- ✔ Biopsy is required to establish the tissue diagnosis
- ✔ The biopsy has to be placed so that it does not compromise subsequent surgical resection
- ✔ Do not rely completely on the result of the biopsy – the final histology may be different
- ✔ The "wait and see" approach is very rarely indicated
- ✔ Conservative treatment is only indicated for benign tumors and in asymptomatic patients
- ✔ Malignant tumors in general are treated surgically
- ✔ In sensitive tumors, chemo- and radiotherapy are considered as an adjuvant treatment
- ✔ The goal of surgery is to remove the primary tumor in its entirety followed by stable reconstruction of the spine

## Epidemiology

Primary spinal tumors are rare

Approximately 2000 new cases of bone cancer and 6000 new cases of soft tissue tumor are diagnosed in the United States each year [30]. Of these, only about 5% involve the spine. The incidence of primary spinal tumors has been estimated at 2.5–8.5 per 100000 people per year [15]. Tumors of the lymphoid system, e.g., plasmocytoma, are generally considered in the discussion of spine tumors although they are tumors of the **lymphoreticular system**. Some bone tumors have a special predilection for the vertebral column (e.g., osteoblastoma), while others occur exclusively in the spine (e.g., chordoma). There are two important clinical features to be considered when evaluating the potential of malignancy of a spine lesion, i.e.:

Plasmocytomas are tumors of the lymphoreticular system

- age
- location

In **children younger than 6 years** of age, most spinal tumors are malignant, e.g.:

- neuroblastoma
- astrocytoma
- sarcoma (less commonly)

However, benign spinal tumors outnumber malignant tumors by a ratio of 2:1 among children of all ages.

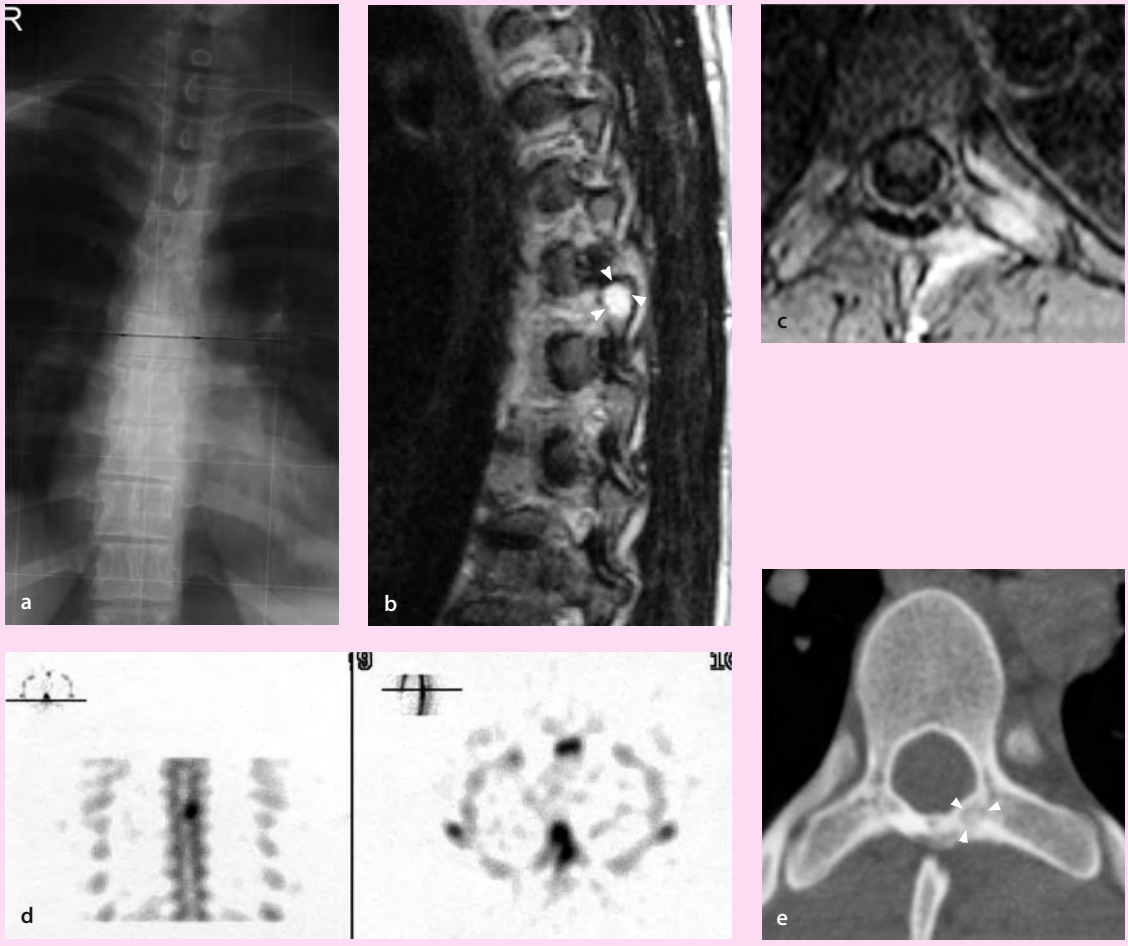


## Case Introduction

A 20-year-old girl presented with severe intermittent dorsal pain with occasional radiation into the ribcage. The patient was unsuccessfully treated with physiotherapy. The pain got progressively worse particularly during the night; she was then referred for further evaluation. Standard radiographs of the thoracic spine were unremarkable although it was noted that she had a significant shift to the left side (a). The patient noticed a decrease of symptoms when she took NSAIDs. An MRI scan demonstrated increased signal intensity in the posterior elements of T7 on the left side (b, c). The bone scan showed increased uptake in that region (d). A CT scan showed the typical features of an osteoidosteoma with a hypodense lesion with a nidus (e). The lamina was exposed for an excision biopsy. However, since the nidus was clearly visible it was decided to remove it by curettage. The bed of the nidus was cleaned with a high-speed air drill. The patient's symptoms completely disappeared after the operation and she remained painfree during follow-up.

In **adults older than 35 years**, most spinal tumors are:

- metastatic adenocarcinoma
- multiple myeloma
- osteosarcoma

Spinal tumors exhibit a specific anatomic predilection

Spinal tumors demonstrate a specific anatomic predilection. Osseous tumors of the anterior vertebral body are most likely metastatic lesions, multiple myeloma, histiocytosis, chordoma, and hemangioma. The most common osseous spinal tumors involving the **posterior elements** are:

- aneurysmal bone cysts
- osteoblastoma
- osteoid osteoma

Malignant osseous tumors occur much more commonly in the anterior than the posterior spinal elements.

Age and tumor location help to classify tumor lesion

## Tumor Biology

### Molecular Tumor Biology

Recent advances in basic research of musculoskeletal tumors revealed that the sheer complexity of the molecular process of carcinogenesis may be conceptually reduced to a small number of molecular, biochemical, and cellular traits that are shared by most if not all types of human cancer. Hanahan and Weinberg [25] described the **hallmarks of cancer** which represent a fundamental concept that governs the development of malignant transformation. It is hypothesized that a developing cancer may represent the interplay between these fundamental concepts. The acquired capabilities of malignant tumors are shown in Fig. 1.

Whenever a cell divides, the telomeres (i.e., ends of chromosomes) shorten until a point of no return and the cell then dies. Cancer cells can switch on a protein component of telomerase that allows them to maintain their telomeres and to divide indefinitely. The normal cell has a built-in cellular program to die or undergo apoptosis, respectively. For a cancer cell to become immortal, it needs to escape **apoptosis**. A malignant cell needs to have the capacity to mimic extracellular growth signals, for example by activating mutations, in order for the tumor to grow. Malignant tumors need to produce their own **blood supply** if they are to grow beyond a certain size. The nature of the angiogenic switch is still unclear, but endothelial cells must be recruited, grow, divide, and invade the tumor to form blood vessels. A further capacity of a malignant cell is to acquire the poten-

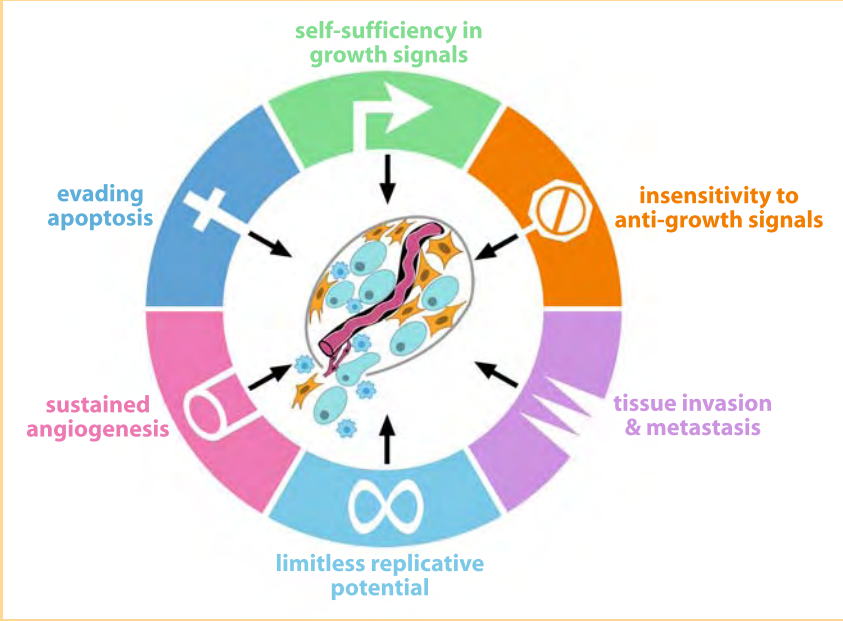


**Figure 1. The hallmarks of cancer**

According to Hanahan and Weinberg, most if not all cancers have acquired the same set of functional capabilities during their development, although through various mechanistic strategies. (Redrawn from Hanahan et al. [25] with permission from Elsevier).

tial to break away from the original tumor mass, resist anoikis (apoptosis that is induced by inadequate or inappropriate cell-matrix interactions) and crawl through the extracellular matrix into blood or lymphatic vessels in order to recur and survive in a distant organ.

The hallmarks represent a concept of carcinogenesis

The hallmarks of cancer help us to understand the complexity of such a disease in terms of a relatively small number of underlying molecular principles. Obviously, these hallmarks only represent a working model. An emerging paradigm is that this set of principles has a specific mechanism for each tumor type so that each tumor bears its own molecular circuitry that needs to be characterized individually.

## Pathways of Metastasis

More than a hundred years ago, Sir Stephen Paget first launched the "seed and soil" hypothesis, asking the question: "What is it that decides what an organ shall suffer in case of disseminated cancer?" His answer is basically still valid today: "The microenvironment of each organ (*the soil*) influences the survival and growth of tumor cells (*the seed*)."

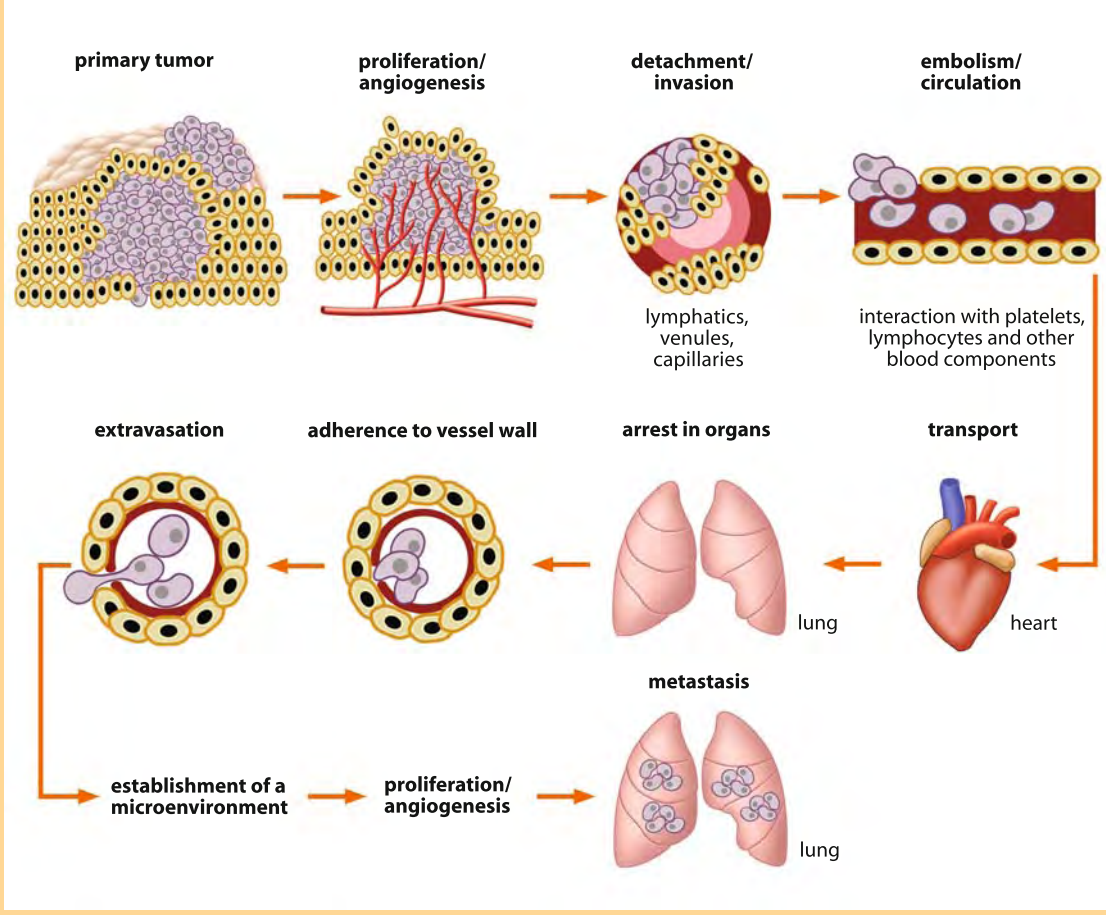


**Figure 2. The metastatic cascade**

The schematic drawing exemplifies the main steps in the formation of a metastasis. (Redrawn from Fidler [18] with permission from Macmillan Publishers Ltd.).

The process of **metastatic spread** of a primary tumor can be described in the following steps (Fig. 2):

- local tumor proliferation
- angiogenesis
- migration and invasion
- intravasation
- adhesion
- extravasation
- migration and invasion
- metastatic growth in target organ

Stem cells appear to play a key role in metastasis

In the metastatic process, the primary tumor proliferates locally until it reaches a size when nutrition cannot be provided by diffusion alone. Neovascularization or angiogenesis is therefore present at an early stage in a tumor. The tumor cell then detaches from the neighboring cells and invades the surrounding normal tissue. It seeks access to the blood and/or lymphatic system (**intravasation**), where it gets distributed in the body until it adheres in the capillaries of the target organ. The metastatic tumor cell then crawls through the vessel wall (**extravasation**) and invades the tissue of the target organ, where finally it may grow into the metastatic nodule. It is not yet entirely understood how these processes are governed. Originally, it was assumed that metastasis is the clonal expansion of a pri-

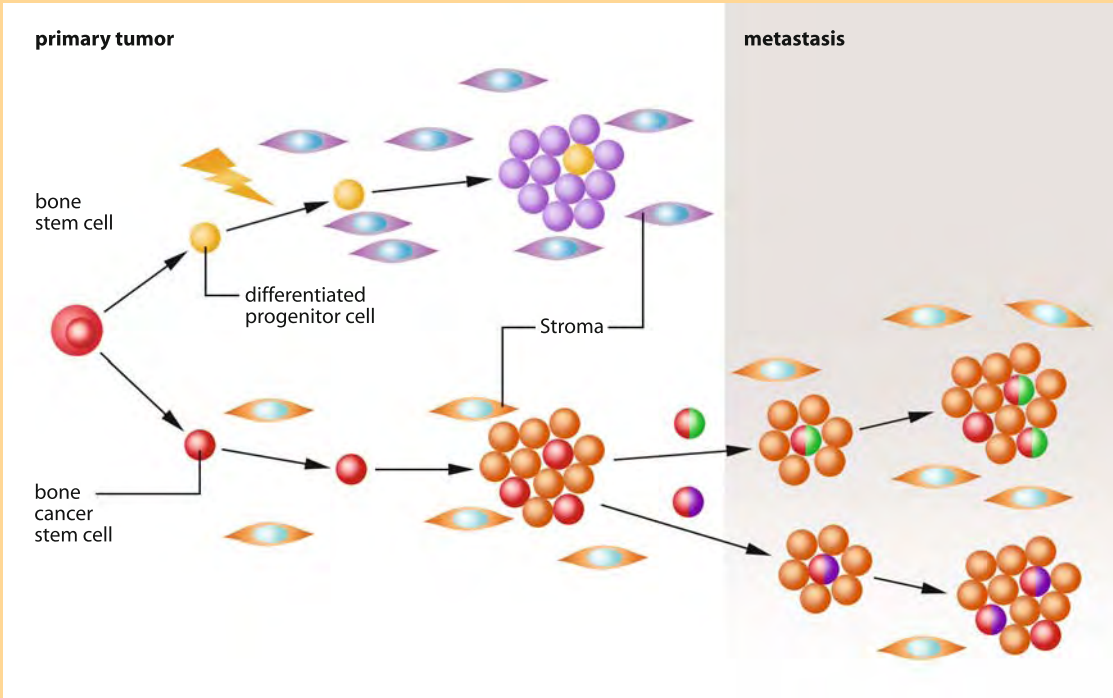


**Figure 3. Evolution of the cancerous bone cell**

Oncogenic mutations may occur in bone stem cells (*red*) and can cause the transformation to a bone cancer stem cell, generating "poor-prognosis" tumors (*orange*). Mutations which occur in differentiated progenitor cells (*yellow*) may form a non-metastatic "good-prognosis" bone carcinoma (*pink*). Under the influence of stromal fibroblasts, only the population of bone cancer stem cells has the ability to metastasize. There might be variant cancer stem cells that differ in their tissue selectivity for metastasis, expressing an additional tissue-specific profile (e.g., *green* liver, *purple* lung). (Redrawn and adapted to bone from Weigelt et al. [42] with permission from Macmillan Publishers Ltd.).

mary tumor cell. Microarray analyses revealed that for several cancers, the expression profile of a primary tumor is indifferent to its metastatic site, thus in contrast to the clonal expansion theory. The current theory implies that stem cells may play an important role. The current model of metastasis synthesizes the **clonal expansion theory**, the expression profiles and stem cells. Oncogenic mutations in stem cells cause transformation, thereby generating "poor-prognosis" tumors. However, mutations occurring in differentiated progenitor cells might form a non-metastatic good-prognosis tumor that does not metastasize. In the metastatic poor-prognosis tumors, under the influence of stromal fibroblasts, only the populations of stem cells have the ability to metastasize (Fig. 3). There might be variant stem cells that differ in their tissue selectivity for metastasis, expressing an additional tissue-specific profile. At the site of metastasis, the disseminated cancer stem cells would again induce a similar stromal response as in the primary tumor.

## Histology and Biology of Spinal Tumors

Spine tumors are classified according to their **histology**. Based on the age of the patient, the anatomic location of the lesion, supplemented by modern imaging, and tumor histology, the **biological behavior of the tumor** can be determined (Table 1).

**Table 1.** Primary benign spinal tumors

| Lesion | Age | Location | Histology | Imaging |
|---|---|---|---|---|
| Osteoidosteoma | second decade | posterior elements (75 %) | vascularized connective tissue, nidus surrounded by reactive cortical bone | radiolucent nidus with surrounding sclerosis, rarely extended to vertebral body, epidural or paraspinal spaces |
| Osteoblastoma | Second and third decades | posterior elements; equally distributed in the cervical, thoracic, and lumbar segments | osteoid-producing neoplasms | expansile destructive lesion partially calcified; common extension to vertebral body |
| Osteochondroma | third decade | exclusively posterior elements; predilection for spinous processes of cervical spine | cartilage cap with normal bone component | continuity of the lesion with marrow and cortex of the underlying bone |
| Hemangioma | any age; peak fourth decade | vertebral body lower thoracic-upper lumbar regions | vascular spaces lined by endothelial cells | vertical parallel densities spotted appearance on CT high signal on T1W and T2W images; involvement of posterior elements |
| Aneurysmal bone cyst | young patients<br>< 20 years | posterior osseous elements 60 %<br>vertebral body 40 %<br>thoracic, lumbar | cystic spaces containing blood products | lytic expansile lesion with fluid-filled levels involvement of contiguous vertebrae |
| Langerhans cell histiocytosis | first, second decades | vertebral body rarely posterior elements, thoracic, rarely lumbar, cervical | sheets of Langerhans cells, lymphocytes, and eosinophils | lytic lesion of the vertebral body leading to collapse |

## Clinical Presentation

### History

A complete history, detailed general assessment and physical examination are essential for evaluating patients with spinal tumors. Patients with spinal tumors usually present with:

- pain
- spinal deformity
- neurologic deficit

Pain is the cardinal symptom

**Back pain** is the most common symptom (Case Introduction) [16]. Pain in spinal tumors usually is:

- persistent
- unrelated to activity
- worsening during rest and at night

Night pain is a warning signal

Persistent, non-mechanical back pain must be distinguished from common back pain, which is often the opposite. **Night pain** is an important differential symptom of certain skeletal neoplasms such as osteoid osteoma and osteoblastoma.

**Pathological fracture** of vertebral bodies can occur and can cause severe acute pain similar to that seen in traumatic vertebral compression fractures. Spinal nerve root and cord compression from a pathological fracture or invasion of neoplasm results in local pain, radicular pain along the affected nerve roots or myelopathy [24]. Symptoms of spinal instability and neurologic compromise arise with increasing vertebral destruction and tumor expansion [14, 19].

**Malignant lesions** with metastases usually cause associated systemic symptoms. Systemic symptoms usually are present in malignant lesions, especially in tumors such as:

- lymphoma
- myeloma
- Ewing's sarcoma
- tumors with metastasis

With the **progression of the disease**, patients can present with:

- weight loss
- fever
- fatigue
- general deterioration

However, these symptoms often appear late during the disease.

### Physical Findings

A palpable mass is rarely the initial finding

Although spinal tumors seldom present with obvious physical findings, a **local palpable mass** may be present in some instances. Sacral tumors like chordoma, after growth of an anterior mass, may cause bowel or bladder symptoms and may be palpable on rectal examination [16]. Benign tumors such as osteoid osteoma are often associated with **scoliosis** and typically present with paraspinal muscle spasm and stiffness. Structurally, there is absence of a lumbar or thoracic hump as in adolescent idiopathic scoliosis. The necessity for a **thorough neurologic examination** is self-evident but it usually reveals only findings in late tumor stages.

## Diagnostic Work-up

### Imaging Studies

The evaluation of spinal tumors includes plain radiographs, bone scans, computed tomography (CT), magnetic resonance imaging (MRI), angiography, as well as single photon emission computed tomography (SPECT) bone scanning [22] and positron emission tomography (PET) scans.

#### Standard Radiographs

Standard radiography is the imaging modality of first choice

Standard radiographs are still the first imaging modality used to explore the spine when a tumor is suspected and they may demonstrate the tumor lesion. **Neoplasms** in the vertebrae can **present as:**

- osteolytic (Fig. 4a, b)
- osteoblastic/sclerotic (Fig. 4c, d)
- mixed

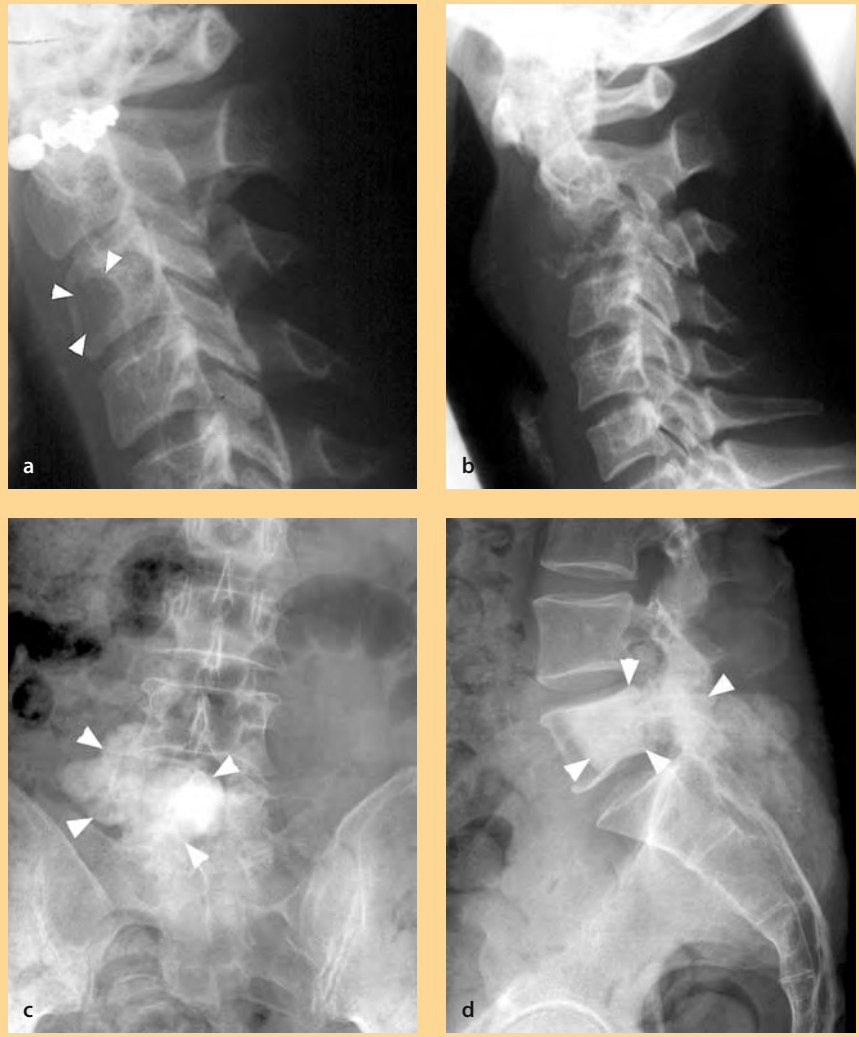


**Figure 4. Radiographic findings**

a Osteolytic lesion in the vertebral body of C3. b This lesion was primarily overlooked and progressed to a severe destruction of the vertebral body of C3 with kyphotic deformity (histology: chordoma). c, d AP and lateral radiographs show a dense, sclerotic bone lesion with extension in the paraspinal muscles (*arrowheads*) on the right side (histology: osteosarcoma).

Benign tumors such as osteoid osteoma and osteoblastoma frequently are seen as sclerotic lesions in the posterior elements of the spine, with a central lytic area surrounded by reactive bone [39]. Lytic destruction of pedicles with the **winking owl sign** (see Chapter 34, Case Study 2) seen on an anteroposterior view is the most classic early sign of vertebral involvement by malignant lesions, although the vertebral body typically is affected first. Before changes can be recognized radiographically, 30–50% of a vertebral body must be destroyed. In contrast, slight lysis of the pedicle can be seen early on the AP radiographs [26]. It is difficult to differentiate pathological compression fracture secondary to tumor from compression fractures of osteoporosis (Case Study 1). This differential diagnosis is always prompted when osteoporotic spine fractures are diagnosed. The intervertebral disc is usually preserved in patients with neoplasm. This helps in differentiating tumors from pyogenic infection where the disc is frequently destroyed along with the adjacent vertebral body [6]. Sometimes, a soft tissue shadow can be seen on the radiographs extending from a vertebral body lesion through the outer cortex.

Malignant neoplasm usually preserves the intervertebral disc

Lytic processes become visible on radiographs not before 30–50% of the bone is destroyed

### Magnetic Resonance Imaging

MRI should be used to fully define the extent and nature of the lesion [7] and is recommended for investigating the suspected lesion in terms of:

- spinal level
- extent of suspected lesions
- vertebral bone marrow infiltration
- infiltration of the paraspinal soft-tissues (muscles, vessels)
- infiltration of the nerve roots, thecal sac, and spinal cord

Generally, MRI is a very sensitive imaging modality for detecting alterations of the bone marrow, but it does not allow a type specific diagnosis. The only exception may be a benign cavernous hemangioma. This lesion is unique in that it shows increased signal intensity relative to the bone marrow on T1W and T2W images, allowing a diagnosis with a very high probability (Fig. 5). MRI features of other tumors are not characteristic and MRI can at best narrow the differential diagnosis (Fig. 6, Tables 1, 2). Contrast enhancement is useful to detect a strong vascular uptake which can prompt an angiography. It is particularly useful for assessing the response to chemotherapy. Diffusion weighted MRI may potentially be capable of detecting and quantifying the amount of tumor necrosis after neoadjuvant therapy, but it is premature to finally conclude on this possibility [32].

High signal in T1W and T2W images indicates an hemangioma

### Computed Tomography

In general, CT is more reliable in demonstrating the cortical outlines of bone and calcification in comparison to MRI. It can better show the extent of the tumor destruction (Fig. 7). Occasionally, CT allows the direct demonstration of the tumor, e.g., in case of an osteoidosteoma (Case Introduction). In terms of tumor biopsies, CT allows accurate assessment of proper needle placement during needle biopsies. However, in general, CT is not as sensitive as MRI in the detection of both metastatic disease and primary malignant bone tumors [1, 2, 13].

CT can better show the extent of bony destruction

## Case Study 1

A 72-year-old male presented with acute onset of thoracolumbar back pain after an unusual movement. The pain was worse on motion and the patient could not be mobilized. An initial lateral radiograph demonstrated compression fractures at L1 and L2 (a). Non-operative treatment failed and the patient was referred for a vertebroplasty. An MRI investigation was done showing fresh compression fractures at L1 and L2 and older endplate fractures of L4 and L5. Note the bone marrow changes which are hypointense on the T1W image (b) and the hyperintense signal intensity on the T2W image (c). The signal intensity increase is better visible on the STIR sequence (d). The patient underwent a biportal vertebroplasty of L1 and L2, which instantaneously resolved the patient's symptoms (e, f). The patient was sent for a formal assessment of the putative osteoporosis during which a multiple myeloma was diagnosed. In retrospect, the assessment should have been done prior to the treatment by vertebroplasty although it would not have changed the indication for a vertebroplasty.

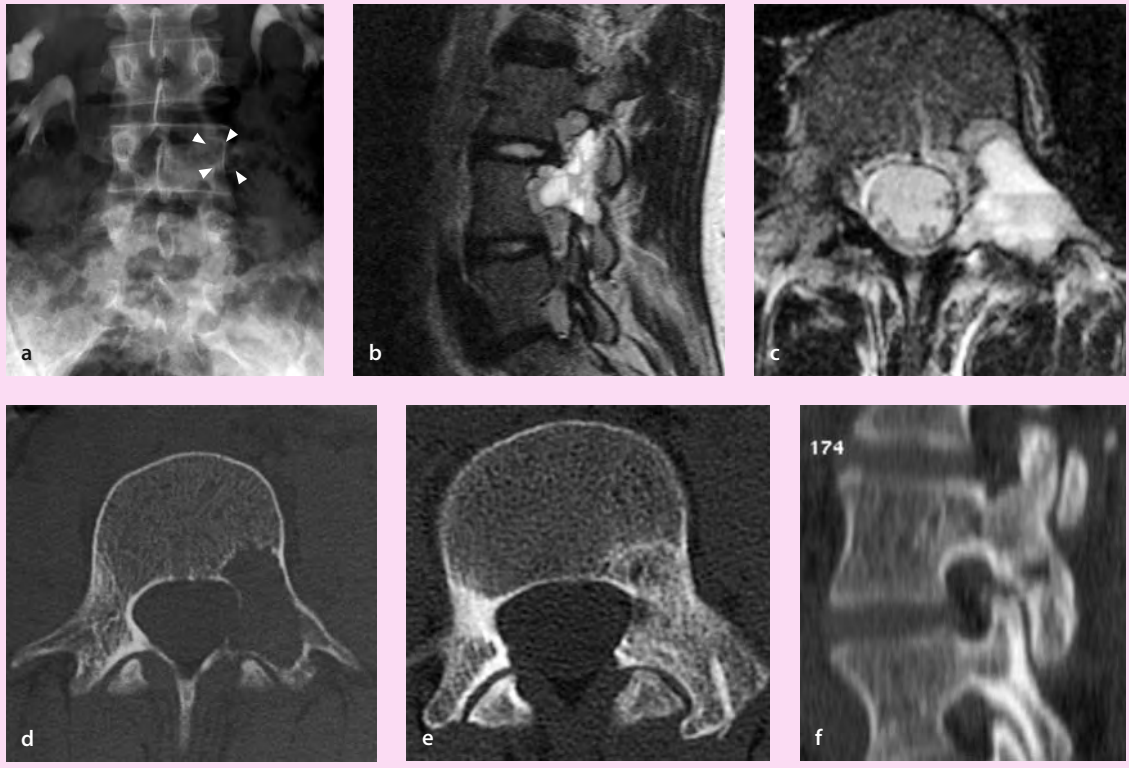


**Case Study 2**

A 16-year-old female underwent an i.v. pyelogram for a diagnostic assessment of recurrent urinary tract infections. The radiologist noticed a disappearance of the regular structure of the L3 pedicle on the left side (winking owl sign) (a). A referral and further diagnostic work-up were prompted. The MRI scan showed a large cyst without significant septal partitions on the T2W sagittal (b) and T2W axial (c) scans. No soft tissue infiltration was seen. The CT scan confirmed the diagnosis of a large cyst (d). The biopsy ruled out malignancy although a confirmation of the suspected aneurysmatic bone cyst was not reliably possible on the material submitted. Because of the benign lesion, an intralesional resection of the transverse process and a curettage of the superior articular process and the pedicle was done. The medial border to the thecal sac was covered with Gelfoam and the defect was filled with autologous cancellous bone. At one year follow-up the patient is symptom free and the CT scan shows a nice remodeling of the pedicle (e, f).

## Radionuclide Studies

A technetium-99m ($^{99m}$Tc) bone scan is widely used in the initial diagnosis and follow-up of bone tumors. Technetium scans are sensitive to any area of increased osteoid reaction to destructive processes in bones (Case Introduction). They can detect lesions as small as 2 mm, and as little as a 5–15 % alteration in local bone turnover. They can identify changes in osteolytic or osteoblastic disease 2–18 months sooner than radiographs [22, 31]. Total body scans can show most of the (also remote) skeletal lesions, and therefore are used as a screening test to determine whether a lesion is solitary or multifocal in expression and local extent. Plasmocytoma is particular in that it may be purely lytic, and therefore an ordinary scan may be negative. In these patients, $^{99m}$Tc-sestamibi has been proven to very useful with a specificity of 96 % and sensitivity of 92 %. As an alternative, MRI may be regarded as today's standard.

A bone scan is the screening method of choice for investigating extraspinal tumor manifestation

**Figure 5. MRI findings of a benign hemangioma**

Typical spotted bright signal intensity changes within the vertebral body of L1 on **a** T1W and **b** T2W image suggesting a benign hemangioma.

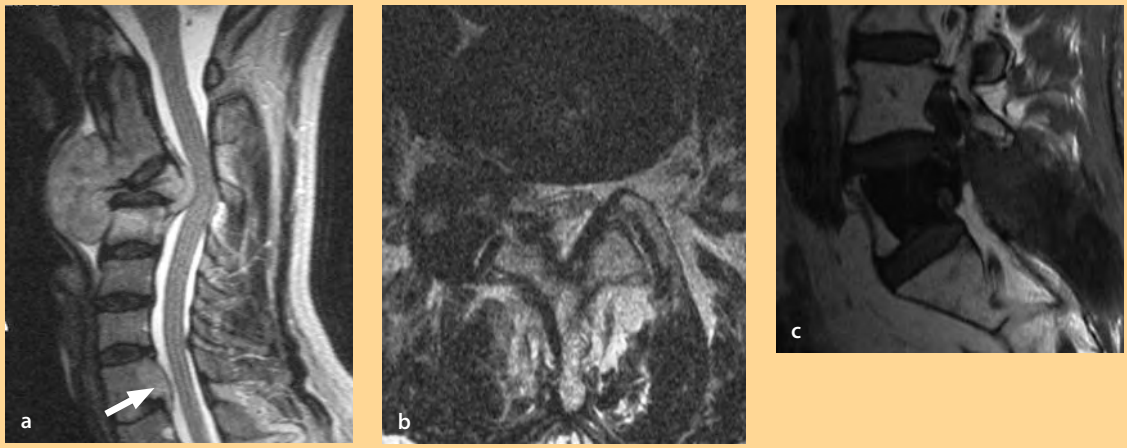


**Figure 6. MRI findings in primary spinal tumors**

**a** Expansive lesion with a pseudocapsule with compression of the spinal cord and the retropharyngeal space. Note the skip lesion at the level of C7 (*arrow*, same patient as in Fig. 4a, b). Extension of a hypointense mass into the foramen L5 and the adjacent facet joint L4/5 on a T2W axial (**b**) and T1W sagittal image (**c**) (same patient as in Fig. 4c, d).

**Table 2.** Primary malignant spinal tumors

| Lesion | Age | Location | Histology | Imaging |
|---|---|---|---|---|
| Osteosarcoma | Fourth decade | Vertebral body<br>Lumbosacral region | Osteoid within sarcomatous tissue | Osteosclerotic and osteolytic areas with soft tissue component; common extension to posterior elements |
| Chondrosarcoma | Fifth decade | Predilection for vertebral body<br>Thoracic region | Hyaline cartilage with increased cellularity within myxoid matrix | Bone destruction with characteristic punctuate calcifications |
| Malignant fibrous histiocytoma | Second to eighth decades | Vertebral body | Mixture of histiocytes, fibroblasts and primitive mesenchymal cells | Lytic lesion with low signal on T1W and high signal on T2W images |
| Giant cell tumor | Third decade | Vertebral body<br>Sacrum | Osteoclastic giant cells intermixed with spindle cells | Osteolytic geographic area with soft tissue component |
| Plasmocytoma | >40 years old | Vertebral body<br>Thoracic and lumbar spine | Sheets of plasma cells on a delicate reticular stroma | Radiolucent areas or reduction in bone density<br>Hypointense on T1W and hyperintense on T2W images |
| Ewing's sarcoma | Second to third decades | Vertebral body, lumbosacral spine | Sheets of small round blue cells | Lytic lesion, associated soft tissue mass |
| Chordoma | Middle-aged patients | Exclusively affects vertebral body; most often sacrum, rarely mobile spine | Lobulated mass with mucinous containing cells | Destructive midline expansile lesion with associated soft tissue mass; extension into adjacent vertebra |

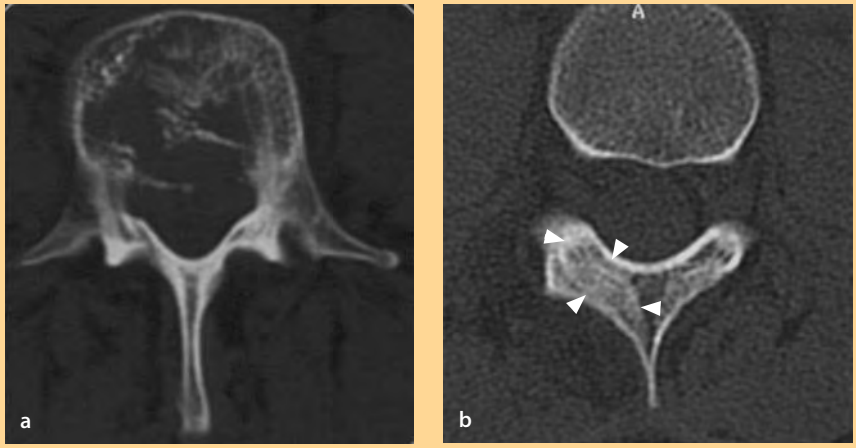


**Figure 7. Computer tomography findings of primary spinal tumors**

a Axial CT scan showing an extensive infiltration and destruction of the posterior wall (histology: plasmocytoma). b Axial scan indicating increased bone density in the lamina (histology: osteoblastoma).

## Spinal Angiography

Spinal angiography has only rare indications for spinal lesions, usually when rich vascular structures such as aneurysmal bone cysts and hemangiosarcoma are present. Angiography is capable of showing the vascularity of all feeding and draining vessels and can be used for selective embolization of hypervascular lesions to reduce intraoperative blood loss [35].

## Biopsy

The biopsy type and track must be carefully considered

One of the most important principles of tumor surgery is that of including the biopsy track with an adequate margin of healthy tissue which can be excised at definitive resection. This is sometimes impossible in the spine if an approach violating the anatomic planes is used. Poorly planned biopsies increase the local recurrence risk by tumor dissemination along fascial planes and the biopsy tract. There are **three different types** of biopsies:

- needle
- open incisional
- excisional

Place the biopsy track so that it can be excised at definitive surgery

For tumors limited to the posterior elements, an **excisional biopsy** is both diagnostic and therapeutic. Most needle biopsies are performed under fluoroscopic or CT control [23]. In experienced hands, the accuracy rate ranges from 80 % to 90 %, but it is non-diagnostic in 25 % of patients [34]. CT guidance offers a great margin of safety for surrounding blood vessels and viscera, but complications include pain, bleeding, and pneumothorax. If **open incisional biopsy** is planned, several fundamental principles should be considered. The incision has to be planned such that it can be excised at definitive surgery. Bone windows should be small and carefully planned so that pathological fractures do not result. They are packed with bone wax and Gelfoam, hydroxyapatite or cement, depending on the surgeon's preference. Postoperative hematomas need to be avoided because they carry the potential of disseminating tumor cells along fascial planes.

**Acceptable biopsy techniques** for malignant tumors of the spine depend on the anatomic extent and location of the tumor. In the cervical spine, posterior tumors with or without extraosseous soft tissue involvement are easily sampled by needle using CT guidance. However, because of the predominance of benign lesions in the posterior elements and when confined to the osseous elements, **excisional biopsy** techniques may be preferred. Anteriorly, in the craniocervical region, transpharyngeal stereotactic needle biopsy is an alternative to open biopsy using the approaches for resection of tumors in this region. Tumors of the anterior thoracic spine are sampled via posterior percutaneous CT-directed needle biopsy. An open biopsy can be performed through a posterolateral approach by costotransversectomy, with careful consideration of biopsy placement. In the lower thoracic and lumbar spine, CT-guided biopsy techniques can be used; for anteriorly located lesions, transpedicular biopsy placement is possible, but later necessitates resection of the involved pedicle and soft tissue track if the lesion turns out to be malignant.

## Laboratory Investigations

A complete laboratory work-up should be ordered. For patients with multiple myeloma and metastatic osteolytic lesions, serum calcium should be evaluated and the possible hypercalcemia corrected. Anemia, hypoalbuminemia and electrolyte imbalances need to be corrected before considering surgery. There are no tumor specific biochemical markers yet available for spine tumors.

## Tumor Staging

A benign tumor is defined by its incapacity to metastasize, whereas a malignant tumor has the potential to metastasize. Boriani et al. [11] have suggested a surgical staging system for the spine based on Enneking's pioneering work [17] for limb lesions (Fig. 8).

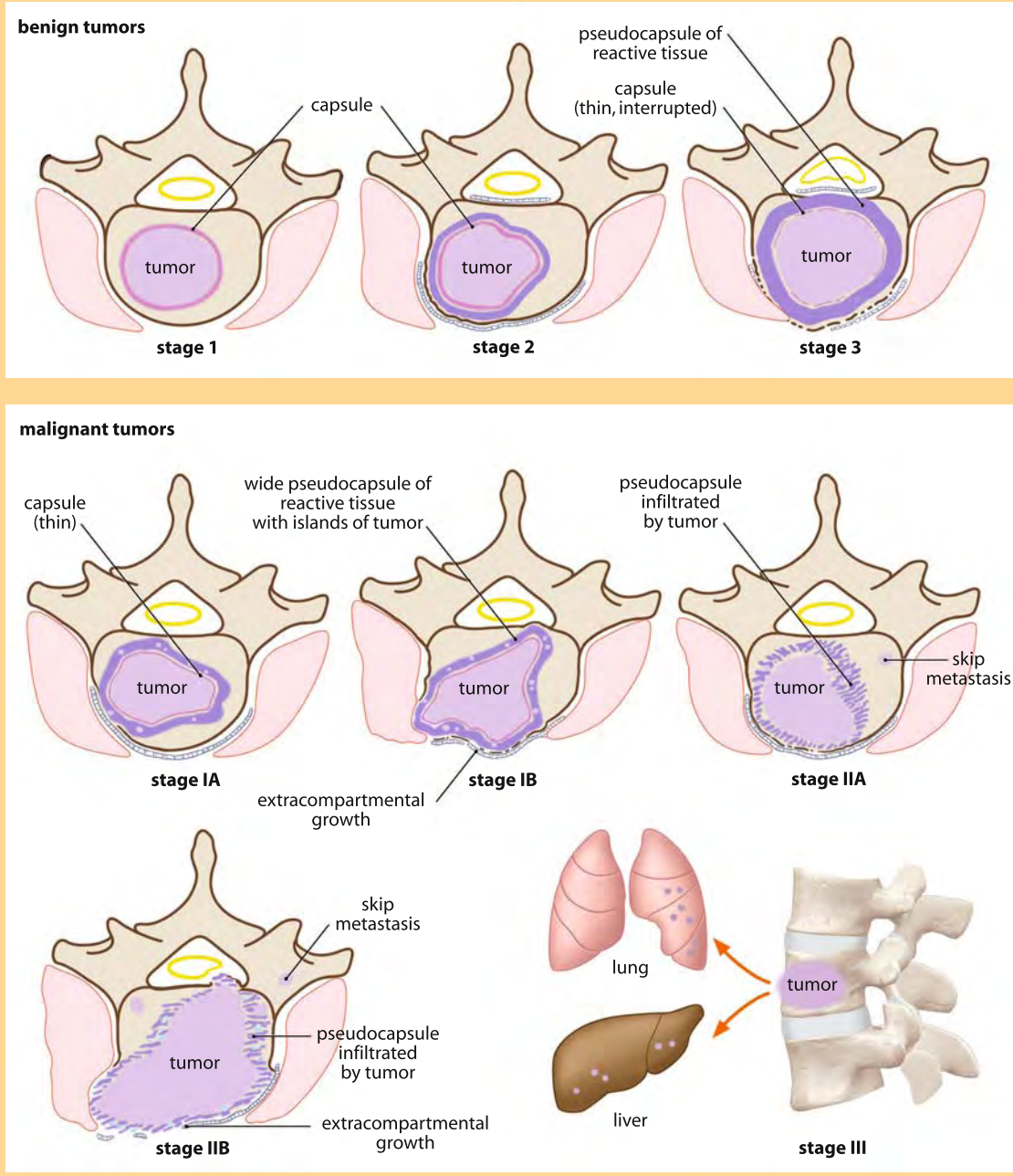


**Figure 8. Staging of benign and malignant spinal tumors.**

The staging considers the presence of a capsule (pseudocapsule), aggressiveness of the lesion, presence of skip lesions, extracompartmental growth, and metastases (for details see text). (Redrawn and modified from Boriani et al. [11], reproduced with permission from Lippincott, Williams & Wilkins).

## Benign Tumors

Benign tumors are **staged** into:

- latent lesion
- active lesion
- aggressive lesion

### Stage 1

No treatment is required for stage 1 lesions

Stage 1 (S1, **latent, inactive**) lesions include **asymptomatic lesions**, bordered by a **true capsule**. In these tumors, a well-defined margin around the circumference of the lesion is seen even on plain radiographs. These tumors usually do not grow or if they do then only very slowly. No treatment is required for S1 lesions, unless palliative surgery is needed for decompression or stabilization. Examples include hemangiomas of bone and osteochondroma.

### Stage 2

Intralesional resection can be performed for Stage 2 lesions

Stage 2 (S2, active) lesions **grow slowly** and **cause mild symptoms**. There is a **thin capsule** around the tumor and a layer of **reactive tissues**, sometimes seen on plain radiographs as an enlargement of the tumor outline and sometimes clearly defined on MRI. Bone scans are often positive. An intralesional excision is performed with a low rate of recurrence. Examples include osteoid osteoma, aneurysmal bone cysts, and giant cell tumor of bone.

### Stage 3

Intralesional resection is insufficient for Stage 3 lesions

Stage 3 (S3, aggressive) lesions are represented by **rapidly growing** benign tumors. The **capsule** is **very thin, incomplete, or absent**. The tumor invades neighboring compartments and often has an associated wide, reactive, hypervascularized pseudocapsule, which sometimes is permeated by neoplastic digitations. There are fuzzy limits on plain radiographs; bone scans are also positive. CT scans show the tumor extension, and MRI defines the pseudocapsule and its relationship to adjacent neurologic structures. Intralesional curettage is often not enough and is associated with a high recurrence rate.

## Malignant Tumors

Malignant tumors are divided into low grade tumors, high grade tumors, and tumor metastasis (independent of grade).

### Stage I

Wide en bloc resection is indicated in Stage 1 and 2 lesions

Stage I (**low grade**) malignant tumors are further subdivided with regard to the containment into:

- **Stage IA**, i.e., the tumor remains inside the vertebra, and
- **Stage IB**, i.e., the tumor invades paravertebral compartments

No true capsule is associated with these lesions, but a thick pseudocapsule of reactive tissue often is penetrated by small, microscopic islands of tumor. Because resection along the pseudocapsule may leave behind residual foci of tumor, wide en bloc excision is indicated if possible.

### Stage II

Stage II (**high grade**) malignant tumors are accordingly defined as:

- **Stage IIA**, i.e., the tumor remains inside the vertebra, and
- **Stage IIB**, i.e., the tumor invades paravertebral compartments

The neoplastic growth is so rapid that the host has no time to form a continuous reactive tissue layer. There is seeding with satellite tumor cells as well as skip lesions at some distance. These tumors show up on plain radiographs as radiolu-

cent and destructive lesions, often associated with pathological fractures. CT and MRI confirm the absence of a reactive tissue margin. Invasion of the epidural space is rapid particularly in Ewing's sarcoma or lymphoma, and is characterized by infiltrating tumor spread beyond the cortical border of the vertebra with no evident destruction. The resection should be wide or en bloc. The survival between Stages 1 and 3 differs significantly, whereas there is no difference in survival between patients with A or B lesions [3].

### Stage III

In Stage III malignant tumors, metastasis represents the situation where the tumor has spread to a distant organ different from, and independent of, the histological grade of the primary tumor.

## Non-operative Treatment

The treatment of spine tumors is determined by the:

- biology
- location
- extent of the lesion

For these reasons, establishing the tissue diagnosis is of great importance. It is extremely dangerous to wait and see if the biopsy is not reliable and the imaging studies not entirely conclusive.

The wait and see approach is rarely indicated

Even if the imaging findings indicate a benign lesion such as a vertebral hemangioma, the final histology may reveal a malignant lesion such as a solitary plasmocytoma [8]. For benign lesions, there are only rare indications for non-operative treatment, such as hemangioma or Langerhans cell histiocytosis. For malignant lesions, non-surgical treatment generally is an adjunct to surgery and consists of:

- pain management
- chemotherapy
- radiotherapy

### Non-steroidal Anti-inflammatory Drugs

Non-steroidal anti-inflammatory drugs (NSAIDs) are often used for mild pain. Opioid drugs are used for severe pain. Other options include epidural and intrathecal administration of local anesthesia. Systemic steroids are used to control pain and mitigate neurologic deficit in patients with spinal cord compression. Chemotherapy has been valuable for the treatment of selected primary tumors and metastases such as osteosarcoma, Ewing's sarcoma and multiple myeloma. Radiotherapy has been the mainstay for treating radiosensitive primary malignant tumors such as Ewing's sarcoma as well as metastases [29].

## Adjuvant Therapy

The goal of radiotherapy is to maximally destroy the tumor while minimizing the effects on normal tissue [10]. **Radiotherapy** may be the choice of initial treatment for radiosensitive lesions. With the advances in surgical technique and instrumentation, initial surgical excision followed by radiation if indicated is preferred because of the risk of developing postirradiation sarcoma. **Chemotherapy** is used particularly for the most common primary bone tumors such as osteosarcoma and Ewing's sarcoma. Its main effect is directed at reducing tumor volume and surrounding edema.

Radiotherapy is indicated for radiosensitive lesions

Chemotherapy is indicated particularly for osteosarcoma and Ewing's sarcoma

## Operative Treatment

### General Principles

The indication for operative treatment of spine tumors has to be carefully considered and treatment should be performed using a **team approach**. The biopsy path has to be carefully selected in order not to compromise further surgery. The type of resection depends on the synthesis of a plethora of parameters such as the biology of the tumor, the precise anatomic location, and the patient's general condition.

**Traditionally,** the indications for open surgery included:

- spinal instability due to bony destruction
- progressive neurologic deficit
- radioresistant tumor that is growing
- the need for open biopsy
- intractable pain unresponsive to non-surgical treatment

The primary goal is wide or en bloc resection and spinal reconstruction

Advances in vertebral resection and stabilization and improved survival with various neoadjuvant therapies have expanded the indications for surgical intervention of primary spinal tumors. Today, the ultimate goal must be a "**wide**" and preferably an **en bloc resection** of the primary tumor in combination with a spinal reconstruction which allows for early mobilization.

The **surgical techniques** are classified by the tissue planes and approach as:

- curettage
- intralesional resection
- en bloc resection

**Curettage** and **intralesional resection** describe a piecemeal removal of the tumor. **En bloc resection** indicates the attempt to remove the whole tumor in one piece together with a layer of normal tissue.

The resected pathological specimen is histologically analyzed, and further classified into:

- intralesional
- marginal
- wide

The term "**intralesional"** is used when the tumor mass is violated; **marginal** is appropriate when the surgeon dissects along the pseudocapsule, the layer of reactive tissue around the tumor; and **"wide"** is appropriate if surgical separation has occurred outside the pseudocapsule, removing the tumor with a continuous shell of healthy tissue.

It is essential to distinguish the removal en bloc, i.e., the whole tumor in one piece, from a simple intralesional procedure. Intralesional resection of malignant tumors may provide functional palliation and pain relief, but has a very high incidence of local recurrence [5]. When resecting a malignant spinal tumor, the widest possible surgical margin should be sought. The goal of surgery should be complete extirpation of the tumor with stable reconstruction of the vertebral column. Resections involving extensively contaminated surgical margins or debulking should be avoided. An aggressive approach with adequate resection can enhance local control and prolong survival.

The widest possible margin should be sought for the excision of malignant spinal tumors

Surgical planning and decision-making are complex and require a team approach

Surgical planning and decision-making are complex processes. To address this difficulty, the vertebral elements are divided into zones [11, 27], thereby predicating the resectability of any particular lesion based on the zones involved [36, 43]. In the transverse plane, the vertebra is divided into 12 radiating zones (numbered 1–12 in clockwise order) and into five layers (A to E), starting from the

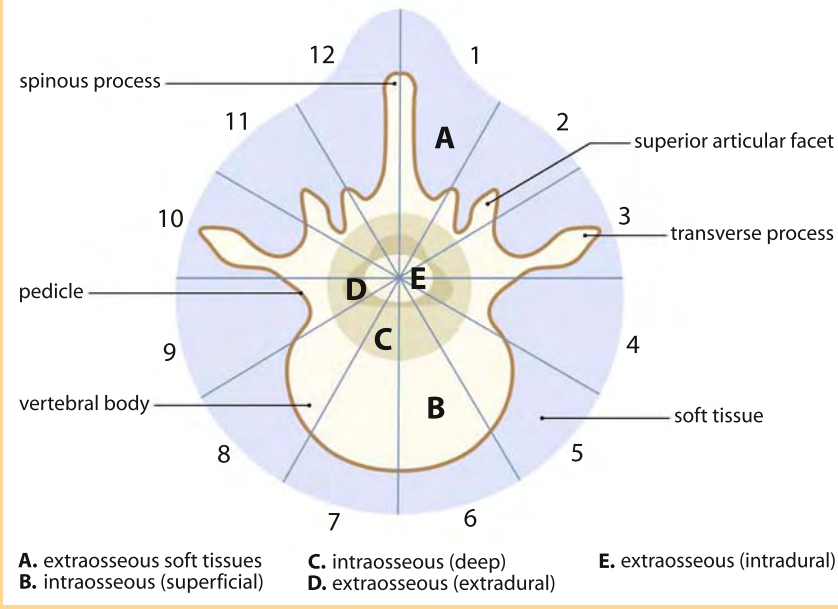


**Figure 9. Surgical staging system**

The transverse tumor extension is described with reference to 12 radiating zones and five concentric layers. (Redrawn and modified from Boriani et al. [11], reproduced with permission from Lippincott, Williams & Wilkins).

paravertebral osseous region to the dural involvement (Fig. 9). The longitudinal extent of the tumor is assessed by counting the spine segments involved. Comprehensive imaging studies are needed preoperatively to assess and describe the transverse and longitudinal expansion of a tumor, which allows appropriate surgical planning.

## Surgical Techniques

The final tumor diagnosis may be different than expected

The surgical techniques of primary spinal tumors are very complex and demand excellent surgical skills. Particularly for the en bloc resection of spinal tumors, the surgical strategy and reconstruction measure have to be decided on an individual basis because of a high variability of tumor location and extension. The surgeon should always consider that the final histological diagnosis may be different than expected or diagnosed on the biopsy material. Even in that case the surgeon should be capable of appropriately treating the case.

Consider referring primary spine tumors to a larger center

A detailed description of the surgical techniques is far beyond the scope of this chapter. We prefer to concentrate on general principles rather than on a "how to do" approach. The surgery for primary malignant tumors should be concentrated in centers with sufficient case load and experience.

### Intralesional Resection

This surgical technique is only used for benign tumors (Case Introduction) or for debulking of inoperable primary or metastatic lesions. The surgical approach for any malignant tumor of the spine is determined by the:

- tumor location
- extent of the tumor

The approach should be planned in such a manner as to provide the opportunity to excise the lesion completely as well as to stabilize the spine mechanically. Often, a combination of anterior and posterior approaches is used [12, 38]. In general, lesions involving the posterior elements of the spine with or without soft tissue extension are approached posteriorly for both resection and reconstruction (Case Study 2). If the lesion extends into the soft tissue, an appropriate soft tissue resection is required. In case of a typical osteoidosteoma, the lesion can be curetted and the bed of the tumor should be excised using a high-speed airdrill (Case Introduction).

If a malignant tumor involves the anterior vertebral body with or without soft tissue extension, but not the pedicle of the vertebral body or posterior elements, then an anterior approach is indicated. If a malignant lesion involves both anterior and posterior elements, an en bloc resection with a wide or even marginal resection is usually impossible unless the patient is willing to become paraplegic. The resection is usually accomplished by a combination of anterior and posterior approaches with intralesional contamination at the level of the pedicle when it is transected at the time of removal of the posterior elements [41]. In the thoracic and lumbar spine, some lesions involving both anterior and posterior elements are amenable to marginal resection through a posterolateral approach, thereby sacrificing a nerve root at the level of resection and one level above. The selected surgical approaches are chosen depending on the anatomic locations.

### En Bloc Resection and Reconstruction of the Spine

There are three major methods of performing en bloc resections in the thoracolumbar spine:

- vertebrectomy
- sagittal resection
- resection of the posterior arch

The term "vertebrectomy," also termed "spondylectomy," is used to describe removal of the entire tumor in one piece together with portions of the posterior elements [37, 41, 43]. This approach is **indicated** if:

- tumor is confined to zones 4–8 or 5–9
- tumor is centrally located in the vertebral body
- at least one pedicle is free from tumor

The procedure can be performed in one or two stages. The posterior approach involves excision of the posterior elements, which allows the section of the anulus fibrosus and the posterior longitudinal ligament, careful hemostasis of the epidural venous plexus and posterior stabilization. The anterior approach, either by a transpleural thoracotomy, retroperitoneal, or thoracoabdominal approaches, allows the ligature of segmental vessels, proximal and distal discectomies, the en bloc removal of the vertebral body and anterior reconstruction [20, 38]. A bilateral approach for vertebrectomy has the main advantage of dissecting the tumor off the anterior soft-tissues under direct vision, thereby achieving a better margin.

When the tumor predominately involves the posterior spinal elements on one side (e.g., chondrosarcoma), an en bloc resection is feasible even in the presence of extensive soft tissue extension. In such cases, posterior serial pedicle and sagittal vertebral osteotomies in conjunction with rib resection are necessary (Case Study 3).

For **tumors of the sacrum** in particular, the surgical approach depends on the biology of the tumor as well as the anatomic location. The general principle is to remove the entire tumor mass in toto [4, 9, 28, 33]. It has been shown that for lesions below S3, a posterior approach only is sufficient whereas for lesions above

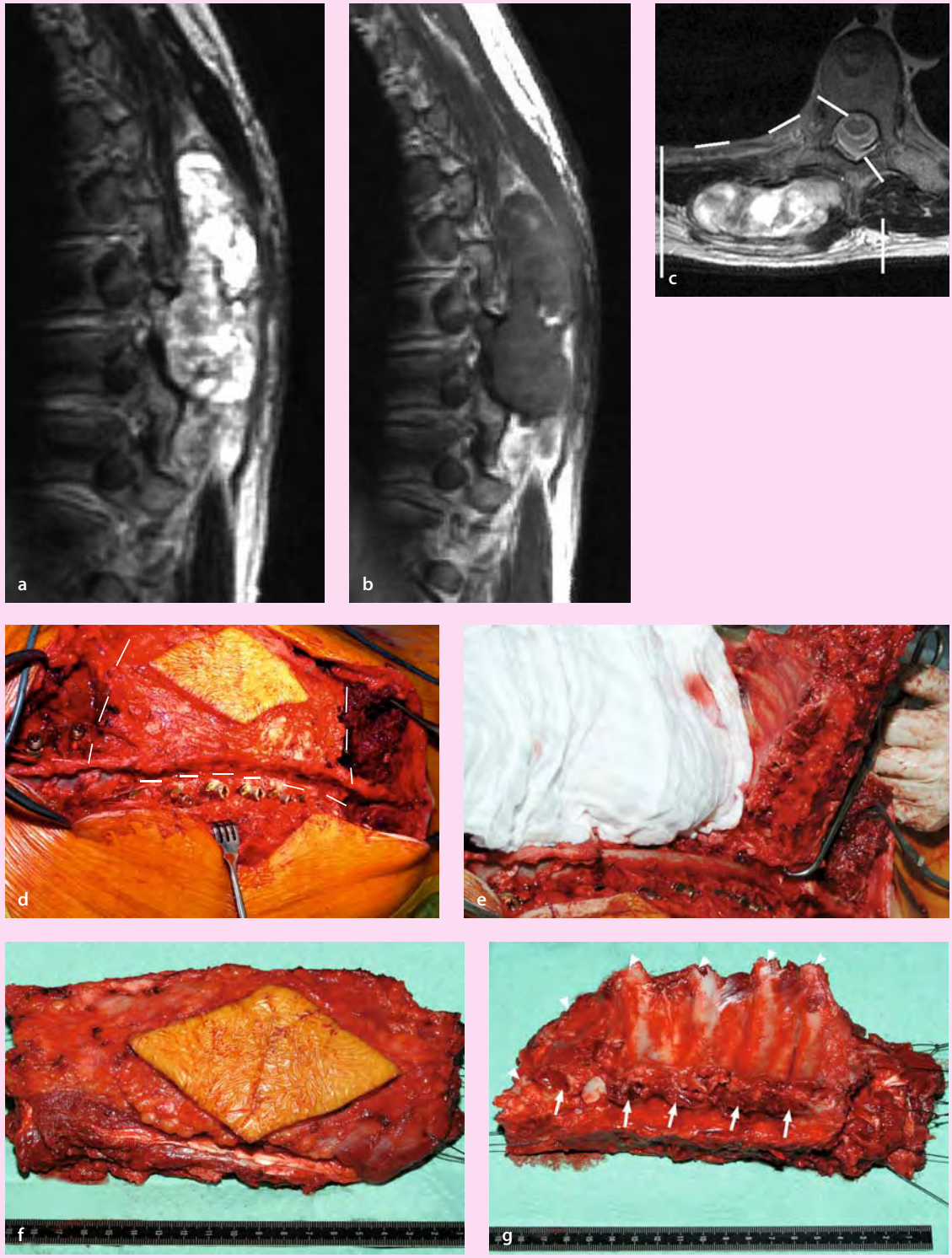


## Case Study 3

A 50-year-old male presented with a painful parasagittal mass at the midthoracic spine. A diagnostic assessment included MRI, thoracoabdominal CT, bone scan and laboratory investigations. The T1W (a) and T2W MR (b) images showed a large polylobulated mass with varying signal intensity and a not clearly visible capsule. The tumor appeared to originate from the posterior part of the T7 pedicle (not shown). The soft tissue infiltration suggested a malignant

## Case Study 3 (*Cont.*)

tumor. The axial T2W scans (c) demonstrated extension to the ribcage. A biopsy revealed the histological diagnosis of a Grade II chondrosarcoma. No metastases were discovered. An en bloc resection was planned. The lines indicate the level of osteotomies of the laminae, pedicles and ribs. The skin with the biopsy channel was excised (d). Prior to tumor resection, the spine was instrumented with pedicle screws at T3–T12 on the right side and at T3, T4, T11 and T12 on the left side. Tumor resection was performed along the indicated lines. The en bloc resection was done with serial contralateral laminotomies at T5–T10 (e), ipsilateral pedicle osteotomies at T5–T9, and rib osteotomies at T5–T10. An en bloc resection of the tumor was achieved with wide margins (f, g). Particularly the osteotomies at the level of the pedicles (*arrows*) and ribs (*arrowheads*) were tumor free. The resected pleura was covered with an artificial membrane (*asterisk*) and the dura with Gelfoam sponges (*arrowheads*). The spine was stabilized at T3–T12 and fusion was carried out on the right side (h). The defect was covered with an ipsilateral latissimus dorsi flap (i). Three years after surgery, the patient is functioning well although he had initial problems with the mobility of the left shoulder (unstable scapula). The follow-up radiographs show the stabilization of the spine at T3–T12 (j, k). Regular follow-up imaging studies (MRI, and thoracoabdominal CT scan) demonstrate a tumor-free course so far.

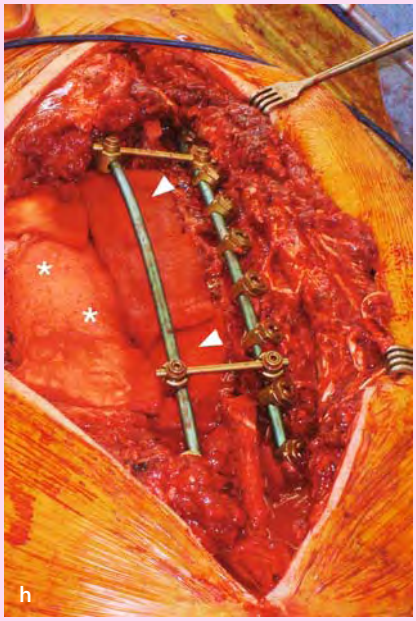

S3 a combined anterior and posterior approach is preferred [21]. The possible disadvantages of a posterior only approach include hemorrhage and laceration of pelvic viscera including ureters. The combined approach allows exposure of the entire pelvic contents and safe ligation of the internal iliac vessels, which assists in reducing bleeding during mobilization of the specimen from posteriorly. It has been shown that the combined approach reduces the local recurrence rate in patients with chordomas, and does not compromise the harvest and use of a pedicled transpelvic rectus flap for posterior wound closure [21].

### Adjuvant Treatment and Local Recurrences

There are few large studies dealing with malignant primary bone tumors of the spine. Talac et al. [40] showed that local recurrence is directly related to the surgical margin obtained during surgery, with a fivefold increase comparing marginal and intralesional resections over wide resections. Because primary bone tumors are rare overall, in primary spine tumors in particular there are no randomized studies available which have assessed the outcome of combined treatment regimens. Basically, patients are treated, e.g., by chemotherapy according to the biology of the tumor independent of the location, including spinal locations. There are no large series which have assessed the effect of adjuvant treatment on the outcome of patients with primary malignant spine tumors. In a recent series, with the small numbers available, no conclusion could be drawn with respect to adjuvant treatment except for the fact that over 90 % of patients who had local recurrences died from their disease.

The local recurrence is directly related to the surgical margin

## Recapitulation

**Epidemiology.** Primary spine tumors are relatively rare. The **incidence** is estimated at 2.5–8.5 per 100 000 individuals per year. When evaluating the potential of malignancy of a spine lesion, age of the patient and location of the lesion are the most important parameters.

**Tumor biology.** Cancer is a **molecular disease**. Cancer development is determined by the **five hallmarks of cancer**: unlimited replicative potential, avoidance of apoptosis, self-sufficient proliferation, angiogenesis and metastasis. **Metastasis** is the stepwise progression which includes proliferation, migration, invasion, intra- and extravasation, and local growth in the target organ.

**Classification.** Spine tumors are classified based on the **histological diagnosis**. Together with the age of the patient and the location of the lesion, the biology can be predicted, and treatment is performed accordingly.

**Clinical presentation.** Patients with spinal tumors present with pain, spinal deformity and neurologic deficit. **Back pain** is the most common symptom. It is persistent and usually not related to activity, and often aggravates during the night. Patients with spinal tumors **rarely** present with a **palpable mass**. Spinal instability and neurologic compromise may arise from a lesion in the vertebral body and depend on the level and location.

**Diagnostic work-up.** This includes laboratory investigations, imaging studies, and tumor staging with a biopsy from the lesion. Imaging studies include **standard radiographs** in two planes, **CT** and **MRI** as well as a **bone scan**. **Tumor staging** defines the systemic extent of the disease, which allows the prognosis to be determined, as well as the local extent, which is mandatory for surgical planning and should be done in accordance with the surgeon performing the tumor resection. The **biopsy** needs to be planned such that it does not compromise subsequent surgical resection. Serum calcium has to be evaluated, and anemia, hypoalbuminemia and electrolyte imbalances need to be assessed and corrected prior to surgery.

**Treatment.** Non-operative treatment is only indicated for benign lesions and if the patient is asymp-

tomatic. If surgery cannot be performed for malignant tumors, pain management is very important, and radiotherapy as well as chemotherapy needs to be taken into consideration. Surgical treatment can be performed as **curettage**, **intralesional** or **en bloc removal** of the tumor. Histologically, en bloc removal is classified into **wide**, **marginal** or **intralesional resection**. The goal of surgery is the complete extirpation of the tumor with stable reconstruction of the vertebral column. The surgical approach and technique is determined by the level and anatomic extent of the tumor lesion.

### Key Articles

**Hanahan D, Weinberg RA (2000) The hallmarks of cancer. Cell 100:57 – 70**
Landmark paper on modern principles of carcinogenesis. This article describes the necessary key steps which a cell of a given tissue has to fulfill to become cancerous.

**Sundaresan N, Boriani S, Rothman A, Holtzman R (2004) Tumours of the spine. J Neurooncology 69:273 – 290**
This article provides a detailed overview of primary benign and malignant as well as metastatic bone tumors.

**Fisher CG, Keynan O, Boyd MC, Dvorak MF (2005) The surgical management of primary tumors of the spine. Spine 30:1899 – 1908**
This article underlines the importance of the surgical principles in the treatment of primary tumors of the spine.

**Talac R, Yaszemki MJ, Currier BL, Fuchs B, Dekutoski MB, Kim CW, Sim FH (2002) Relationship between surgical margins and local recurrence in sarcomas of the spine. Clin Orthop Rel Res 397:127 – 132**
This article comprises one of the largest and most recent series on the outcome of surgical treatment of primary bone sarcomas of the spine. It exemplifies the importance of obtaining a wide surgical margin.

**Fuchs B, Dickey ID, Yaszemski MJ, Inwards CY, Sim FH (2005) Operative management of sacral chordoma. J Bone Joint Surg [Am] 87:2211 – 16**
This article includes the largest series on surgically treated chordomas of the sacrum. It shows that for lesions above the S3 level, a combined anterior-posterior approach is preferred over a posterior approach alone.

**Garg S, Dormans JP (2005) Tumors and tumor-like conditions of the spine in children. J Am Acad Orthop Surg 6:372 – 81**
This article provides a comprehensive overview on tumors and tumor-like conditions in children. It highlights the differential diagnosis of back pain in children and adolescents and illustrates diagnostic and therapeutic options.

## References


1. Algra PR, Bloem JL, Tissing H, Falke TH, Arndt JW, Verboom LJ (1991) Detection of vertebral metastases: comparison between MR imaging and bone scintigraphy. Radiographics 11:219 – 32
2. Avrahami E, Tadmor R, Dally O, Hadar H (1989) Early MR demonstration of spinal metastases in patients with normal radiographs and CT and radionuclide bone scans. J Comput Assist Tomogr 13:598 – 602
3. Bacci G, Savini R, Calderoni P, Gnudi S, Minutillo A, Picci P (1982) Solitary plasmacytoma of the vertebral column. A report of 15 cases. Tumori 68:271 – 5
4. Bailey CS, Fisher CG, Boyd MC, Dvorak MF (2006) En bloc marginal excision of a multilevel cervical chordoma. Case report. J Neurosurg Spine 4:409 – 14
5. Bilsky MH, Boland PJ, Panageas KS, Woodruff JM, Brennan MF, Healey JH (2001) Intralesional resection of primary and metastatic sarcoma involving the spine: outcome analysis of 59 patients. Neurosurgery 49:1277 – 86; discussion 1286 – 7
6. Black P (1979) Spinal metastasis: current status and recommended guidelines for management. Neurosurgery 5:726 – 46

7. Body JJ (1992) Metastatic bone disease: clinical and therapeutic aspects. Bone 13 Suppl 1:S57 – 62
8. Boos N, Goytan M, Fraser R, Aebi M (1997) Solitary plasma-cell myeloma of the spine in an adolescent. Case report of an unusual presentation. J Bone Joint Surg Br 79:812 – 4
9. Boriani S, Bandiera S, Biagini R, Bacchini P, Boriani L, Cappuccio M, Chevalley F, Gasbarrini A, Picci P, Weinstein JN (2006) Chordoma of the mobile spine: fifty years of experience. Spine 31:493 – 503
10. Boriani S, De Iure F, Bandiera S, Campanacci L, Biagini R, Di Fiore M, Bandello L, Picci P, Bacchini P (2000) Chondrosarcoma of the mobile spine: report on 22 cases. Spine 25:804 – 12
11. Boriani S, Weinstein JN, Biagini R (1997) Primary bone tumors of the spine. Terminology and surgical staging. Spine 22:1036 – 44
12. Bruder E, Zanetti M, Boos N, von Hochstetter AR (1999) Chondromyxoid fibroma of two thoracic vertebrae. Skeletal Radiol 28:286 – 9
13. Chin CT (2002) Spine imaging. Semin Neurol 22:205 – 20
14. Constans JP, de Divitiis E, Donzelli R, Spaziante R, Meder JF, Haye C (1983) Spinal metastases with neurological manifestations. Review of 600 cases. J Neurosurg 59:111 – 8
15. Dreghorn CR, Newman RJ, Hardy GJ, Dickson RA (1990) Primary tumors of the axial skeleton. Experience of the Leeds Regional Bone Tumor Registry. Spine 15:137 – 40
16. Enneking W (1983) Spine. New York: Churchill Livingstone, 1983: 303 – 354
17. Enneking WF, Spanier SS, Goodman MA (1980) A system for the surgical staging of musculoskeletal sarcoma. Clin Orthop Relat Res:106 – 20
18. Fidler IJ (2003) The pathogenesis of cancer metastasis: the 'seed and soil' hypothesis revisited. Nat Rev Cancer 3:453 – 8
19. Fielding JW, Pyle RN, Jr, Fietti VG, Jr (1979) Anterior cervical vertebral body resection and bone-grafting for benign and malignant tumors. A survey under the auspices of the Cervical Spine Research Society. J Bone Joint Surg Am 61:251 – 3
20. Fourney DR, Abi-Said D, Rhines LD, Walsh GL, Lang FF, McCutcheon IE, Gokaslan ZL (2001) Simultaneous anterior-posterior approach to the thoracic and lumbar spine for the radical resection of tumors followed by reconstruction and stabilization. J Neurosurg 94:232 – 44
21. Fuchs B, Dickey ID, Yaszemski MJ, Inwards CY, Sim FH (2005) Operative management of sacral chordoma. J Bone Joint Surg Am 87:2211 – 6
22. Gates GF (1998) SPECT bone scanning of the spine. Semin Nucl Med 28:78 – 94
23. Ghelman B, Lospinuso MF, Levine DB, O'Leary PF, Burke SW (1991) Percutaneous computed-tomography-guided biopsy of the thoracic and lumbar spine. Spine 16:736 – 9
24. Griffin JB (1978) Benign osteoblastoma of the thoracic spine. Case report with fifteen-year follow-up. J Bone Joint Surg Am 60:833 – 5
25. Hanahan D, Weinberg RA (2000) The hallmarks of cancer. Cell 100:57 – 70
26. Harrington KD (1986) Metastatic disease of the spine. J Bone Joint Surg Am 68:1110 – 5
27. Hart RA, Boriani S, Biagini R, Currier B, Weinstein JN (1997) A system for surgical staging and management of spine tumors. A clinical outcome study of giant cell tumors of the spine. Spine 22:1773 – 82; discussion 1783
28. Heary RF, Vaccaro AR, Benevenia J, Cotler JM (1998) "En-bloc" vertebrectomy in the mobile lumbar spine. Surg Neurol 50:548 – 56
29. Heidecke V, Rainov NG, Burkert W (2003) Results and outcome of neurosurgical treatment for extradural metastases in the cervical spine. Acta Neurochir (Wien) 145:873 – 80; discussion 880 – 1
30. Jemal A, Murray T, Ward E, Samuels A, Tiwari RC, Ghafoor A, Feuer EJ, Thun MJ (2005) Cancer statistics, 2005. CA Cancer J Clin 55:10 – 30
31. Joo KG, Parthasarathy KL, Bakshi SP, Rosner D (1979) Bone scintigrams: their clinical usefulness in patients with breast carcinoma. Oncology 36:94 – 8
32. Lang P, Johnston JO, Arenal-Romero F, Gooding CA (1998) Advances in MR imaging of pediatric musculoskeletal neoplasms. Magn Reson Imaging Clin N Am 6:579 – 604
33. Min K, Espinosa N, Bode B, Exner GU (2005) Total sacrectomy and reconstruction with structural allografts for neurofibrosarcoma of the sacrum. A case report. J Bone Joint Surg Am 87:864 – 9
34. Simmons ED, Zheng Y (2006) Vertebral tumors: surgical versus nonsurgical treatment. Clin Orthop Relat Res 443:233 – 47
35. Sundaresan N (1986) Chordomas. Clin Orthop Relat Res:135 – 42
36. Sundaresan N, Boriani S, Rothman A, Holtzman R (2004) Tumors of the osseous spine. J Neurooncol 69:273 – 90
37. Sundaresan N, DiGiacinto GV, Krol G, Hughes JE (1989) Spondylectomy for malignant tumors of the spine. J Clin Oncol 7:1485 – 91
38. Sundaresan N, Steinberger AA, Moore F, Sachdev VP, Krol G, Hough L, Kelliher K (1996) Indications and results of combined anterior-posterior approaches for spine tumor surgery. J Neurosurg 85:438 – 46
39. Sweriduk ST, DeLuca SA (1987) The sclerotic pedicle. Am Fam Physician 35:161 – 2

40. Talac R, Yaszemski MJ, Currier BL, Fuchs B, Dekutoski MB, Kim CW, Sim FH (2002) Relationship between surgical margins and local recurrence in sarcomas of the spine. Clin Orthop Relat Res:127 – 32
41. Tomita K, Kawahara N, Baba H, Tsuchiya H, Fujita T, Toribatake Y (1997) Total en bloc spondylectomy. A new surgical technique for primary malignant vertebral tumors. Spine 22:324 – 33
42. Weigelt B, Peterse JL, van't Veer LJ (2005) Breast cancer metastasis: markers and models. Nat Rev Cancer 5:591 – 602
43. Yao KC, Boriani S, Gokaslan ZL, Sundaresan N (2003) En bloc spondylectomy for spinal metastases: a review of techniques. Neurosurg Focus 15:E6

# 34 Spinal Metastasis

Dante G. Marchesi

## Core Messages

- ✔ Two-thirds of cancer patients develop metastases and the spine is a predilection area
- ✔ Pathological fractures are frequent with potential risks of neurologic complications
- ✔ Diagnosis should be advocated in all cancer patients with neck or back pain
- ✔ MRI is the imaging modality of choice in spinal metastases
- ✔ The best management concept is obtained with a multidisciplinary team approach involving oncologists, radiotherapists and spinal surgeons
- ✔ In the absence of neurologic deficit, spinal deformity and instability or incapacitating pain, radiosensitive tumors can be managed by radiotherapy
- ✔ The goals of surgery are to decrease pain, preserve or improve neurologic function and stabilize the spine
- ✔ Decompressive laminectomy alone is rarely indicated
- ✔ The surgical treatment should include decompression of neural structures, debulking of tumor mass, realignment of spinal deformity and spinal reconstruction/stabilization

## Epidemiology

The most distinct characteristic of cancer is its ability to produce metastatic lesions in distant parts of the body. Of the one million new cases of cancer diagnosed annually, two-thirds of patients develop metastases [2]. After the lung and the liver, the skeletal system is the third most common site for metastatic diseases and regardless of the origin of the primary tumor, the spine is the most common site of skeletal metastasis [9]. Autopsy findings have indicated that up to 70 % of patients with bone metastatic carcinoma have vertebral deposits at the time of death [28]. In about 70 % of cases, the metastatic lesion is localized in the **thoracic** and **thoracolumbar regions** of the spine, the lumbar and sacral regions are involved in 22 % of cases and the cervical spine in 8 % [11].

Two-thirds of cancer patients develop metastases and the spine is a predilection area

Following a review of the literature, the **most frequent primary tumors** metastasizing to the spine are tumors of the:

- breast (16.5 %)
- lung (15.6 %)
- prostate (9.2 %)
- kidney (6.5 %)

The **primary lesion** remains **unknown in 12.5 %** of cases [11]. Most patients with metastatic lesions present between 50 and 60 years of age, and there is no difference with regard to the gender of the patients.

Breast, lung, prostate and kidney are the most frequent primary tumors

These patients are at risk of developing pathological vertebral fractures and symptomatic spinal cord compression with neurologic deficits. This danger will increase with the improvement of oncologic treatment and prolonged patient life expectancy.

Pathological spine fractures are frequent

## Case Introduction

A 44-year-old female working for the university complained of severe neck pain and was initially sent for physiotherapy. Because of the resistance of her symptoms and especially because her doctor had taken into account her medical history of breast cancer treated several years previously, she was sent for X-ray examination. Standard radiographs showed collapse of the C4 vertebral body with severe angular kyphosis and spinal instability (a, b). Subsequent CT demonstrated the classical signs of spinal metastasis with pathological fracture and severe osteolysis of C4 as well as spinal instability and cord compression (c, d). Biopsy was not necessary due to the previous history of breast carcinoma. Because of the severity of spinal instability with enormous risks for the neurologic structures in a patient otherwise in good general health, surgical treatment was clearly indicated. Realignment of the cervical spine was obtained by positioning the patient on the operating table using mild skull traction and neck extension (e). Surgery consisted of a resection of C4 vertebral body and the two adjacent discs followed by spinal reconstruction with bone cement and anterior screw/plate fixation (f, g). Radiotherapy was performed 2 weeks after surgery, after adequate wound healing. The patient was still alive 2 years following surgery.

## Pathogenesis

There are **four potential pathways** of metastasis:

- arterial
- direct extension
- lymphatic
- venous

Spinal metastases that embolize through the **arterial system** enter the vertebral bodies through the nutrient arteries. This appears to be a common mechanism of metastasis for lung cancers and has been suggested as a potential pathway for prostate cancer [13]. Tumors located either in the retroperitoneum or the mediastinum may **directly erode** into the vertebral bodies as they expand, or they may enter the spinal canal through neuroforaminae. Although lymphangiography has demonstrated lymph channels within bone, their clinical significance for tumor

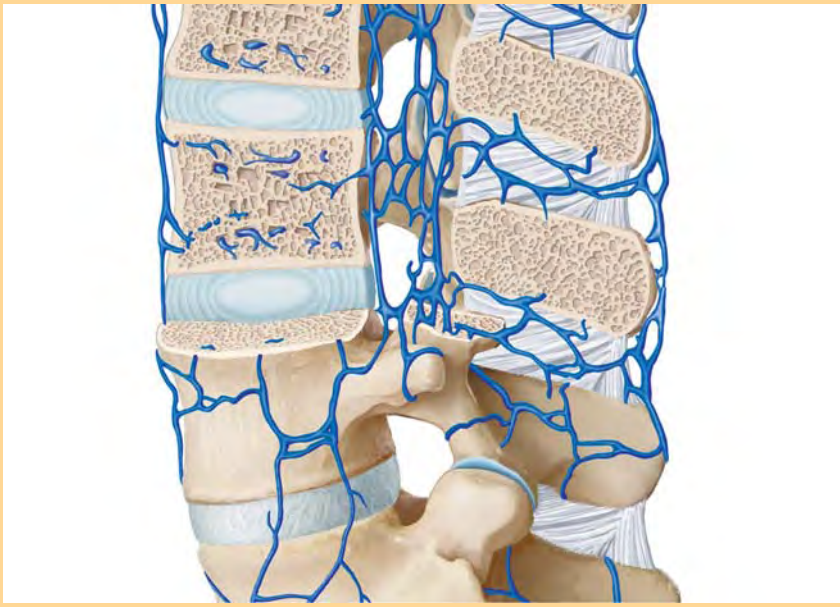

**Figure 1. Pathomechanism of spinal metastases**

The richly vascularized vertebral bodies connected with the epidural venous plexus, a valveless system of veins within the spinal canal (Batson), are suggested to predispose to metastatic embolization.

embolization has not been defined [3]. The most common pathway for metastatic embolization to the spine is through the **venous system**. The extremely well developed vein system of the vertebral bodies connected with the epidural venous plexus, a valveless system of veins within the spinal canal, is suggested to be a potential source of metastatic embolization [5].

Increased intra-abdominal pressure has been demonstrated to divert blood into the epidural venous plexus, thus providing a potential pathway of vertebral metastatic embolization (Fig. 1).

Spinal metastases are mainly localized in the vertebral body

In the spine, the **vertebral body** is the most common site of metastatic seeding, and is involved 20 times more often than the posterior elements. This is possibly due to the affinity of metastatic emboli for developing within red marrow. Less often the epidural space becomes the initial site of metastasis and only rarely (<5%) compromise of the patients with neurologic subdural or intramedullary metastases may occur [11].

Spinal metastases appear as osteolytic or osteoblastic lesions

Following cancellous bone seeding, cortical bone invasion, for example metastatic involvement of a pedicle, occurs secondarily. The host responds by producing bone in an attempt to repair the injury produced by the cancer invasion. Fast-growing aggressive lesions are associated with minimum reactive bone and radiologically appear purely **osteolytic**. Slow-growing or less aggressive metastases allow the formation of reactive bone to various degrees and appear radiographically **osteoblastic**. Mixed areas can occur either within a single metastasis or at different sites. Histologically, there is no difference in the quality of the reactive bone, which occurs in osteolytic and osteoblastic lesions. Only quantitative differences are found regarding the amount of reactive bone produced by the host.

Spinal metastases can result in vertebral body collapse, spinal instability and canal compromise

The type of **host response** present influences the probability that spinal deformity will occur. Spinal metastases that are primarily lytic have a tendency toward vertebral body collapse and spinal instability. Lesions that are primarily osteo-

blastic are less likely to result in spinal deformity from loss of vertebral body integrity. The intervertebral disc appears to be resistant to metastatic invasion. After metastases have established in the spine, they may cause neurologic compromise through **several mechanisms**:

- direct extension of the metastatic lesion
- metastatic seeding in the epidural space
- pathological fracture with retropulsed tissues (more frequently)
- spinal deformity with localized kyphosis or dislocation

## Clinical Presentation

### History

Pain is the most common initial symptom

Spinal metastases may be asymptomatic for a long time and 36 % of these lesions are discovered incidentally [32]. Local pain is the most common initial symptom of metastatic spinal disease and it is the presenting symptom in up to 96 % of the symptomatic cases.

The **cardinal symptoms** of spinal metastasis are:

- slowly progressive, continuous, and localized back pain
- pain exacerbation during rest and at night

Additional but **less frequent findings** may be:

- nerve root pain (unilaterally or bilaterally)
- pain aggravation by coughing, sneezing or movement of the trunk (instability)
- symptoms of myelopathy due to spinal cord compression

All patients are at risk of spinal cord compression

Pain is associated with neurologic dysfunction in only 5 % of cases. These patients are at risk of developing symptomatic spinal cord compression and this danger will continue to increase with the improvement of oncologic treatment [4]. The interval between pain and neurologic deterioration is longer for cervical or lumbar metastases (up to 6 months) whereas thoracic lesions are more typically associated with neurologic findings soon after symptoms first begin.

### Physical Findings

Clinical examination is seldom helpful in making the diagnosis. However, the most frequent but unspecific findings are:

- local tenderness
- pain provocation by flexion, rotation, and percussion

A careful neurologic examination is mandatory to diagnose neural compromise at an early stage

A **thorough neurologic examination** is a must to diagnose neural compression syndromes at an early stage (see Chapter 11). Patients may present with either a spinal cord, conus or cauda equina lesion or radiculopathy depending on the level of the neurologic compromise. Metastatic lesions affecting the cervical and thoracic cord produce both motor weakness and spasticity with pathological reflexes. Lesions at the level of the conus medullaris produce lower motor neuron paralysis, legs that are hypotonic, loss of reflexes and bladder/bowel dysfunction. Lesions involving the cauda equina may cause either nerve root, unilateral, or bilateral lower extremity motor weakness with decreased reflexes. Objective sensory disturbances usually present following the onset of motor dysfunction. Metastatic lesions producing posterior compression of the spinal cord may result in

early posterior column dysfunction, with resulting abnormalities in position sense and vibratory and light touch sensation.

## Diagnostic Work-up

### Imaging Studies

Modern imaging modalities have substantially improved the accuracy in diagnosing spinal metastases. Appropriate radiological assessment should be performed in all cancer patients presenting with neck or back pain.

All cancer patients with spinal pain should undergo spinal imaging

#### Standard Radiographs

Radiological signs are delayed on plain X-rays

Although conventional plain X-rays are the most common initial means to evaluate patients with neoplastic disease spinal pain, they are not sensitive indicators of the presence and extent of metastatic involvement. It has been shown that 30–70% bony destruction must occur before osteolytic metastases can be seen [15].

**Characteristic radiological findings** (Fig. 2a, b) suggestive for spinal metastases are:

- missing pedicle (winking owl sign, Fig. 2c)
- changes in vertebral body contours
- lytic lesions within vertebral body (one or multiple)
- endplate fracture
- vertebral body collapse
- sclerotic areas within vertebral bodies (may represent blastic metastases)

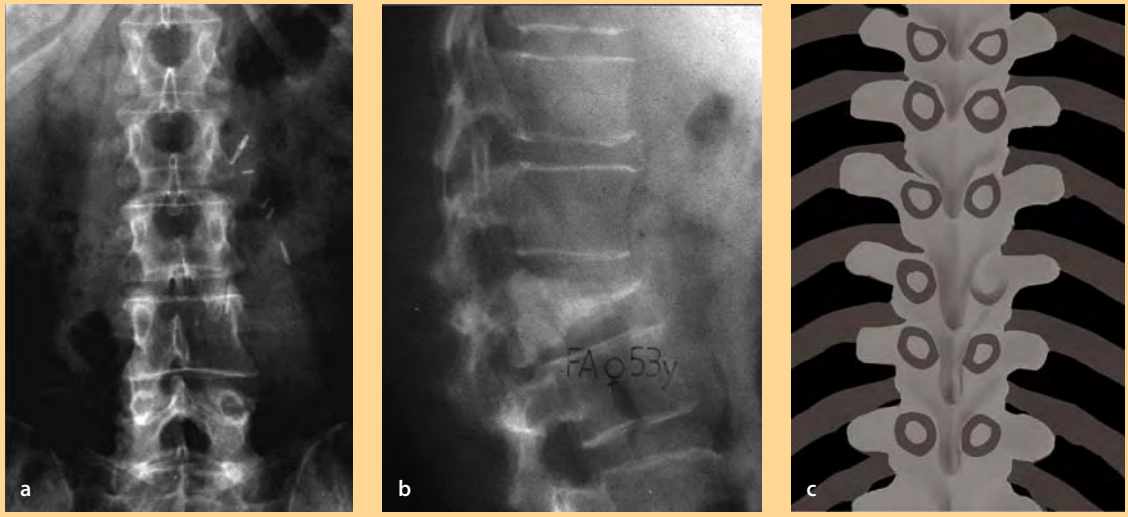


**Figure 2. Radiographic findings in spinal metastases**

The classical radiographic signs of spinal metastases are a the missing pedicle and b changes in vertebral body contours with vertebral body collapse and kyphotic deformity. c The **winking owl sign** indicates osteolysis of the pedicle.

### Magnetic Resonance Imaging

Today magnetic resonance imaging (MRI) provides the most complete information for evaluating a vertebral metastatic lesion and therefore it has become the imaging modality of choice [6]. MRI is both sensitive and specific and is recommended as the initial study in patients with suspected metastatic spinal disease. It clearly provides:

- tumor localization (unifocal vs multifocal)
- extent of bony destruction (sometimes better seen on CT)
- soft tissue involvement
- localization of neural compression (anterior, posterior, foraminal)

MRI is the imaging study of choice

The application of contrast medium is helpful when intrathecal metastasis is suspected. Repeat MRI studies can demonstrate evolution of the disease process with minimum discomfort to the patient.

**Characteristic MRI findings** (Fig. 3a, b) suggestive for spinal metastasis are:

- bone marrow replacement with decreased signal on T1- and increased signal on T2-weighted images
- preservation of disc structure on both T1- and T2-weighted images
- spinal cord compression on T1-weighted images
- compression of subarachnoid space on T2-weighted images
- contrast enhancement of the metastatic vertebral body

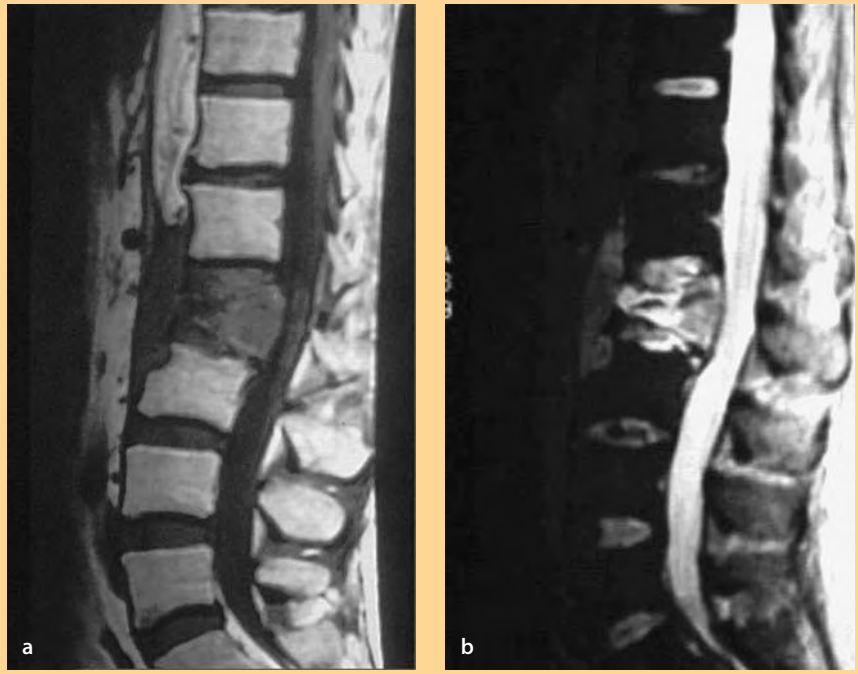


**Figure 3. MRI characteristics of spinal metastases**

The predominant findings of spinal metastases are the bone marrow replacement with decreased signal intensity on a T1W and increased signal on b T2W images, the preservation of disc structure on both T1W and T2W images, the spinal cord compression on T1W images and the compression of subarachnoid space on T2W images.

### CT Scans

The CT scan is superior only in the assessment of cortical bone and it has nowadays been surpassed by MRI [6]. It can be of value when extensive spinal reconstructions are required to improve preoperative planning.

### Bone Scans

A radionucleotide bone scan of the skeleton is routinely performed as a **screening** to rule out the presence of metastatic disease in the spine and other areas of the skeleton. Bone scanning is very sensitive and may predate radiographic changes of osteolytic or osteoblastic disease by 2–18 months [22]. It is not specific to metastatic lesions and will be positive in a variety of benign processes [30]. However, false negative findings can occur with very aggressive rapidly growing metastatic lesions and multiple myeloma [17]. Successfully treated metastases are inactive and may also produce normal bone scans [17].

A bone scan should be performed as screening for extraspinal tumor involvement

### Angiography

Because of the lack of specificity and the occurrence of negative scans, this imaging modality has distinct limitations in evaluating the presence of metastatic disease. It provides poor visualization of the bony structures and cannot evaluate the presence of spinal canal compromise. For a conclusive screening of the spine, bone scanning has been surpassed by MRI.

Angiography has demonstrated to be also very helpful in evaluating the extent of the tumor, the localization of **major feeder vessels**, and in providing a vehicle for embolization as primary treatment or in association with surgical resection, e.g. highly vascularized renal tumors.

Angiography is helpful to embolize major feeder vessels in highly vascularized metastasis

## Biopsy

Either open or percutaneous vertebral biopsy can be performed and it is indicated to confirm metastatic disease in a patient with a known primary tumor, to evaluate a suspicious radiographic lesion, or to provide tissue for hormonal evaluation.

A biopsy is a must prior to treatment

It is important to consider that the metastasis is not necessarily due to the known primary tumor but may be a result of a new so far unknown second primary tumor.

Always consider a second primary tumor

Percutaneous biopsy is better performed using a large biopsy needle in order to obtain a sufficient amount of tissue. An anterolateral approach is occasionally used in the cervical spine while a posterior transpedicular approach is preferred in the thoracic and lumbar spine. The biopsy can be performed under image intensifier control but **CT guidance** is preferable because of the more accurate spatial resolution. The accuracy rate for percutaneous bone biopsies is reported to be 95 % in diagnosing metastatic lesions and the complication rate is as low as 0.2 % [26, 27].

CT guidance is preferred for optimal biopsy

## Laboratory Investigation

Routine blood studies are non-specific and often not very helpful in diagnosing spinal metastases. However, for a comprehensive **tumor screening** the following investigations are recommended:

- complete blood count
- calcium
- phosphorus
- alkaline phosphatase
- urea
- creatinine
- total proteins
- tumor markers

Hypercalcemia frequently occurs in cancer patients

**Hypercalcemia**, which is frequently observed in cancer patients with metastatic disease, is thought to be the result of either resorption of bone in osteolytic lesions or tumor secretion of bone resorbing humoral substances. Tumors often produce antigens or markers that can be recognized with modern radioimmunoassays. The most frequently used antigens are the carcinoembryonic antigen (CEA) and the prostatic specific antigen (PSA).

## Classification

Numerous classifications have been proposed to describe the clinical presentation (pain, neurologic function, radiographic changes) and results of treatment for patients with spinal metastases. As the treatment of malignant diseases advances and the percentage of patients developing symptomatic metastases increases, there has been a clear need for a better selection of patients requiring these treatments. The most recent **scoring systems** [12, 19, 20, 23, 33–36] not only take into account the:

- local extension of the spinal lesion
  but are also based on:
- general health status of the patients
- neurologic conditions
- primary site of the cancer
- number of spinal metastases
- existence of extraspinal bone metastases
- involvement of major internal organ metastases

Classification systems help to guide further management

According to these classification systems, it is possible to formulate guidelines for the treatment corresponding to patient condition and estimated length of survival.

The most recently introduced **Tokuhashi scoring system** is based on **six parameters** to assess the severity of the metastatic spinal disease [33, 34]:

- general condition of the patient (Karnofsky performance status) [23]
- number of extraspinal metastases
- number of vertebral metastases
- metastases to major organs
- primary tumor site (length of survival)
- severity of spinal cord palsy (Faenkel's grades)

Each of the six parameters is graded from 2 (positive) to 0 points (negative perspective). Their score allows the prediction of a postoperative survival period (< 3 months with 5 points or less, > 12 months with 9 or more points) and therefore the indication for surgical management for each patient with spinal metastasis.

## Non-operative Treatment

The treatment of symptomatic spinal metastases remains controversial. The cancer patient should not be withheld modern advances in medical care, even if they are merely palliative. The general goals of treatment are (Table 1):

**Table 1.** General goals of treatment

- relieve pain
- reverse or prevent a neurologic deficit
- restore spinal stability
- correct spinal deformity
- cure the disease (in case of a solitary metastasis)
- improve remaining quality of life

It is important to maintain realistic treatment goals, which are to provide pain relief and to prevent the complications of the metastatic disease process, especially neurologic complications. Symptomatic spinal metastases can be treated with various **treatment options** including:

- hormonal treatment
- chemotherapy
- steroids
- radiation therapy
- surgical interventions

However, for most cases a combination of these options is best suited. The choice of therapy is also based on the general objectives of treatment.

Ideally every patient should benefit from a multidisciplinary team approach involving oncologists, radiotherapists and spinal surgeons, in order to find the best management concept and timing.

A multidisciplinary approach is mandatory

## Steroids

In acute neurologic deterioration, the use of steroids has been shown to be effective in stabilizing and sometimes reversing neurologic dysfunction. Dexamethasone has been demonstrated to reduce the spinal cord edema and pain associated with some spinal column tumors. Dosage schemes range from a low dose of dexamethasone (16 mg/day in divided doses) to very high doses (96 mg/day) [7]. The optimal dose which is necessary to treat patients with acute spinal cord compression is somewhat controversial. In addition, it is unclear whether high doses are associated with improved neurologic outcomes when compared to low-to-moderate doses. High-dose steroids are associated with significantly higher complication rates such as hyperglycemia, gastrointestinal ulceration and perforation, and avascular necrosis of the hip. In addition, steroids may affect the yield of biopsy specimens of undiagnosed spinal masses.

Steroids are used initially in acute neurologic deterioration

Higher dose steroid treatment is not proven to be better than low-dose treatment

## Radiotherapy

Radiation therapy has become a well-established modality for the treatment of symptomatic skeletal metastases. Significant pain relief has been reported to occur in 70–90% of patients, probably depending on the etiology of the tumor [3]. When evaluating patients with possible neoplastic cord compression for radiotherapy, it is important to determine the tumor size and extent, pathological grade, relative radiosensitivity and whether the source of compression is from

the tumor mass or whether it is from bony fragments. Favorable indications for radiotherapy are (Table 2):

**Table 2.** Indications for radiation therapy

- radiosensitive tumor
- neurologic deficit is either stable or slowly progressing
- spinal canal compromise resulting from soft tissue impingement
- multiple myelographic blocks
- no evidence of spinal instability
- systemic condition of the patient precludes surgical consideration
- widespread spinal metastatic disease
- poor prognosis for long-term survival

Radiation therapy is routinely used in symptomatic skeletal sensitive metastases

Patients with significant neoplastic bony destruction will often have concomitant pathological vertebral fractures, with retropulsion of vertebral body fragments into the spinal canal that may impinge on the spinal cord. Radiotherapy has no chance of relieving the compression in these cases. In addition, the bony destruction may result in destabilization of the spinal column, which may predispose the patient to future neurologic injury. These patients are best managed with surgical decompression and stabilization in case their overall medical condition will permit surgery.

The standard radiotherapy protocol for palliation of spinal tumors is 300 cGy daily fractions up to a total dose of 3 000 cGy. A single posterior field or opposed fields are used to encompass the involved segments plus one to two levels above and below [7]. The tolerance of the spinal cord and cauda equina to radiation therapy is the major limiting factor in treatment with higher doses of radiation. Higher doses increase the risk of developing radiation-induced myelopathy with resultant loss of spinal cord function.

After the decision to proceed with radiotherapy has been made, the timing must be carefully considered. Several studies have shown that radiotherapy has deleterious affects on wound and bone healing as well as bone graft incorporation. The negative affects of radiation on skin healing have also been well documented. The operative incision must be taken into account when developing a radiation treatment plan to prevent potentially disastrous wound dehiscence and infection. However, **delayed postoperative therapy** (>21 days) has not been shown to have this same negative affect and radiotherapy is presently used in combination with surgery in the majority of spinal metastases operated on [3, 10, 16, 38].

Delayed postoperative radiotherapy is the preferred treatment

## Operative Treatment

### General Principles

Before recommending a surgical intervention, several factors should be considered. The surgeon must determine whether the patient is an appropriate surgical candidate. This **consideration should include** [3]:

- life expectancy of the patient (at least 3–6 months)
- immunologic status
- nutritional status
- tissue conditions (previous radiotherapy)
- pulmonary function should be evaluated and taken into consideration

A formal tumor staging is required prior to treatment

In this context, a formal **tumor staging** is required and classification of the spinal metastasis (e.g. Tokuhashi score) is often helpful.

The general indications for surgery are (Table 3):

**Table 3.** General indications for surgery

- intractable pain
- progressive neurologic compromise
- spinal instability and deformity
- potentially curable disease
- radioresistant tumors
- failure of radiotherapy
- failure of chemotherapy
- need for open biopsy

## General Surgical Techniques

### Percutaneous Vertebroplasty

Vertebroplasty is better performed if the posterior vertebral wall is intact

Vertebroplasty was first developed for the treatment of vertebral angiomas and the indications have been successively extended to osteoporotic vertebral fractures and spinal metastases [14]. The procedure is generally performed using local anesthesia with fluoroscopic or CT guidance. From a posterior approach, the vertebroplasty needle (about 8 – 10 gauge) is introduced through a transpedicular approach to the center of the vertebral body. Polymethylmethacrylate or special vertebroplasty cements are injected under careful radiological control. The goal of the procedure is pain relief (obtained in > 80 % of cases) and the consolidation of the vertebra avoiding further collapse. Vertebroplasty is performed in the thoracic and lumbar spine. Pathological fractures with an intact posterior wall are the best indication. In experienced hands, the technique can be performed under very careful fluoroscopy control also in cases with some degree of posterior wall destruction.

### Decompressive Laminectomy

Laminectomy alone is rarely indicated

Decompressive laminectomy alone is rarely indicated because metastatic lesions normally arise from the vertebral body and result in epidural compression that is either anterior or anterolateral to the thecal sac. In these cases, laminectomy is not effective. It produces spinal instability and is reported not to be more effective than radiotherapy in the improvement of neurologic deficits [21, 37].

However, **posterior decompression without instrumentation** is indicated in:

- tumors arising from the posterior elements and producing posterior epidural compression
- patients with multiple vertebral involvements without spinal instability
- rapidly progressive paralysis in very advanced tumor stage (where extensive spinal procedures would be ill advised)

Prophylactic laminectomy sometimes over several levels can be indicated but should better be done in conjunction with spinal instrumentation to avoid further vertebral collapse.

Metastatic tumors involving the upper cervical spine (C1 or C2) are difficult to address with an anterior approach. Due to the wide spinal canal in this particular area of the spine, they can be treated with decompressive laminectomy, realignment of the spine and posterior segmental instrumentation extended to the occiput (Case Study 1) [25].

### Tumor Resection and Spinal Stabilization

In contrast to decompressive laminectomy, the general goals of treatment (Table 1) in metastatic spinal tumors are best accomplished by:

- decompression of neural structures
- debulking (or, if possible, en bloc resection) of the metastasis
- realignment of spinal deformity
- spinal reconstruction/stabilization

However, the **feasibility** of the various approaches depends on:

- location and extent of neural impingement
- number of vertebrae involved
- region of the spine affected
- need for spinal stabilization
- patient's medical condition

## Specific Surgical Techniques

### Cervical Spine

Tumors involving a vertebral body between C3 and C7 (possibly T1) can be easily approached with classical anterolateral exposure of the cervical spine [25]. For this surgery, the patient is placed prone on the operating table with the cervical spine in extension and mild skull traction. Patient intubation may need to be performed under endoscopic guidance due to the severe spinal instability. Following exposure of the spine, the affected vertebral body and the two adjacent discs are completely resected to the posterior longitudinal ligament. Care is taken always to work in a posterior-to-anterior direction and never towards the spinal canal. The realignment of the cervical spine is easy and mainly occurs spontaneously after the **vertebrectomy** is completed. The reconstruction of the vertebral body is obtained using **bone cement** or a special **reconstruction cage** and spinal fixation with **anterior plate and screws** is finally performed to produce a solid spinal stabilization (Case Introduction). In the cervical spine, a two or more level involvement will require additional posterior instrumentation.

Corpectomy and anterior column reconstruction is the therapy of choice for vertebral body lesions

Tumors involving C1/C2, multilevel cervical metastases, or the cervicothoracic junction without spinal instability are better addressed from posterior as previously described [25, 29]. One or multilevel level laminectomy combined with a plate/rod fixation using lateral mass screws or possibly pedicle screws will provide spinal stabilization (Fig. 4).

Metastatic tumors involving the upper cervical spine (C1 or C2) are difficult to address with an anterior approach. Due to the wide spinal canal in this particular area of the spine, they can be treated with **decompressive laminectomy**, realignment of the spine and **posterior segmental instrumentation** extended to the occiput (Case Study 1).

Metastases at the craniocervical and cervicothoracic junctions are better treated from posterior (if possible)

### Thoracic Spine

Tumors involving the **thoracic spine between T7 and T12** can be easily approached through a standard thoracotomy [3, 7, 8, 18, 35]. The segmental vessels, which course in the vertebral body depressions between the intervertebral discs, are ligated and divided. The intervertebral discs are completely resected back to the posterior longitudinal ligament. The tumoral mass is progressively removed down to the posterior longitudinal ligaments with rongeurs, curettes and, if necessary, high-speed drills. Following an **adequate corpectomy**, the pos-

Solitary thoracic vertebral body metastases are best treated by anterior corpectomy and spinal reconstruction

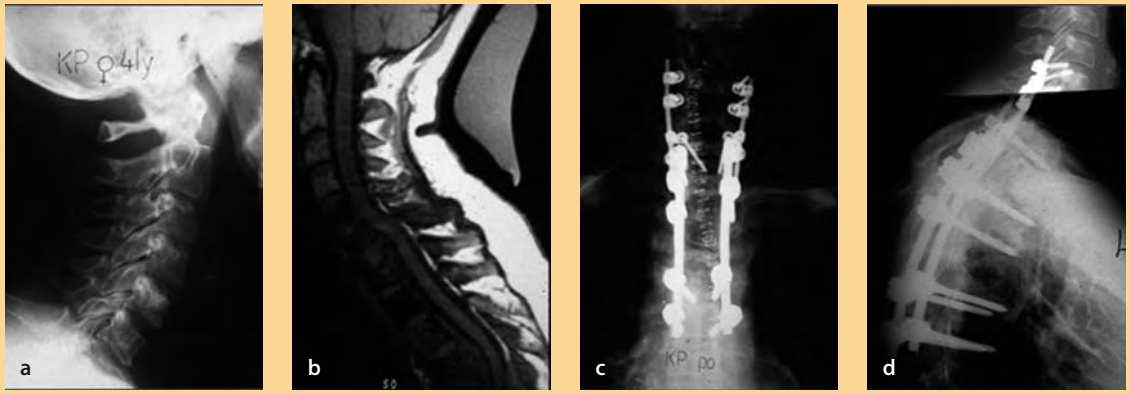


**Figure 4. Treatment of metastasis at the cervicothoracic junction**

a, b A 41-year-old lady with a history of breast cancer and multilevel vertebral metastases and cord compression in the cervicothoracic junction. c, d Decompressive laminectomies and multilevel posterior stabilization with lateral mass screws in C4 and C5, and pedicle screws from C7 to T6, were performed at surgery.

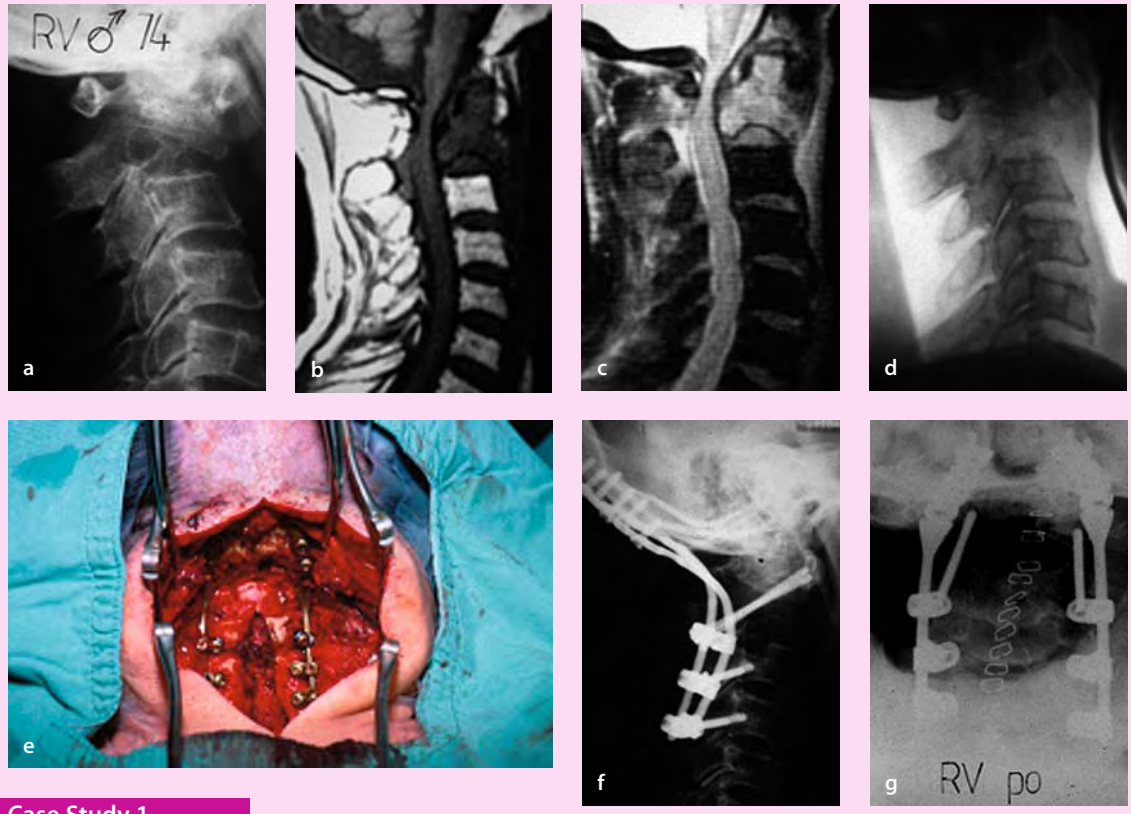


**Case Study 1**

A 74-year-old man with a history of lung adenocarcinoma presented with disabling upper neck pain resistant to major pain medication. Physical examination revealed adequate general health and a normal neurologic status. Radiological assessment including plain X-rays and MRI showed a pathological fracture of C2 with severe instability and cord compression (a–c). The patient was selected for a posterior approach. After careful intubation under endoscopic guidance, partial spinal alignment was obtained by positioning the patient on the operating table with high skull traction and neck extension (d). Cord decompression was obtained by laminectomy of C1/C2 and enlargement of the foramen magnum. Occipitocervical fixation was performed using a screw/rod system from the occiput down to C4 (e–g). The patient died 1½ years after surgery with preserved neurologic conditions and free of neck pain.

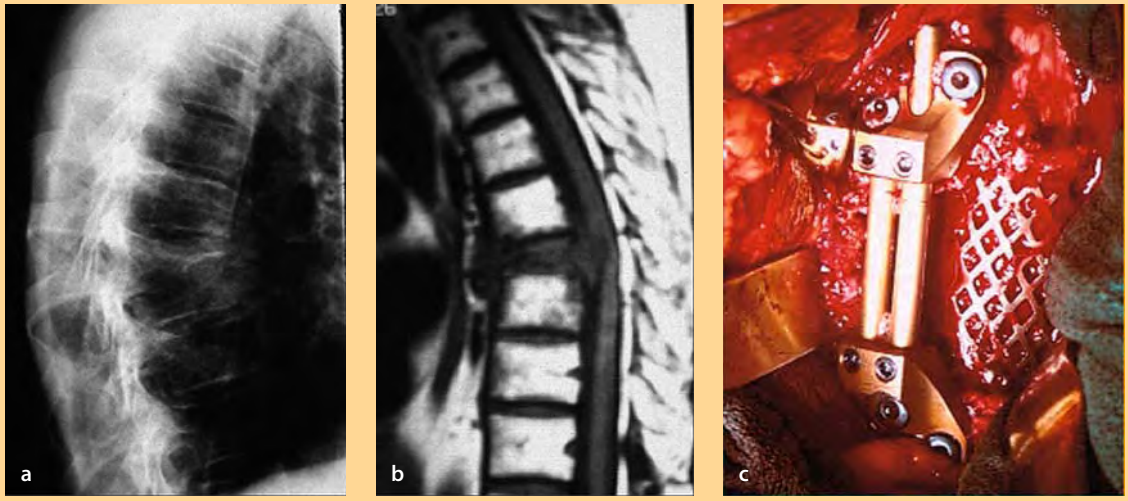


**Figure 5. Treatment of thoracic vertebral body metastasis**

a, b A 74-year-old man with multiple myeloma and T7 pathological fracture with cord compression. c Anterior resection of the T7 vertebral body and the adjacent discs was carried out before spinal reconstruction with a cage and a screw/rod fixation system.

terior longitudinal ligament typically bulges into the defect created between the intact vertebral bodies. It should be removed to allow a complete excision of all the tumor that has infiltrated into the spinal canal. The reconstruction of the vertebral body is obtained using bone cement or a special reconstruction cage. Bone graft is only indicated in cases with a long life expectancy. However, bone integration may be a problem in cases with postoperative radiotherapy. Spinal stabilization is completed with an anterior plate and screw system to obtain solid spinal reconstruction (Fig. 5).

Metastatic lesions localized in the upper thoracic spine are more difficult to address using an anterior approach. A sternotomy is sometimes required and this particular surgery should be performed only in patients with long life expectancy [3, 35, 38].

Posterior transpedicular vertebrectomy is a valid alternative for tumors in the entire lumbar and thoracic spine

The technique of **posterior transpedicular vertebrectomy** (Fig. 6) has been described as a valid alternative approach for tumors localized in the entire thoracic and lumbar spine [1, 7, 8, 10, 24]. Using this technique, posterior cord decompression is obtained through a large laminectomy extended laterally to the costotransversal joints. The surgery is continued by performing the spinal instrumentation before the hemorrhagic phase of tumor resection. Pedicle screws are placed in the adjacent vertebrae, usually one level above and one below. The procedure is followed by the complete resection of both pedicles using drill, curettes and pituitary rongeurs until exposure of both nerve roots. Following the pedicle structures, in an oblique inwards direction, a cavity is created in the vertebral body by piecemeal tumor resection. The vertebrectomy is progressively carried out as an eggshell procedure, taking care to leave the vertebral body cortex intact and avoid any injury with the anterior located segmental vessels. Using the same access and passing above and below the nerve root, the adjacent discs are also resected. The vertebrectomy is completed by ventrally pushing and resecting the tissues left along the posterior longitudinal ligament. Care must be taken not to push against the cord. The reconstruction of the anterior column is obtained using methylmethacrylate pushed into the defect with a large

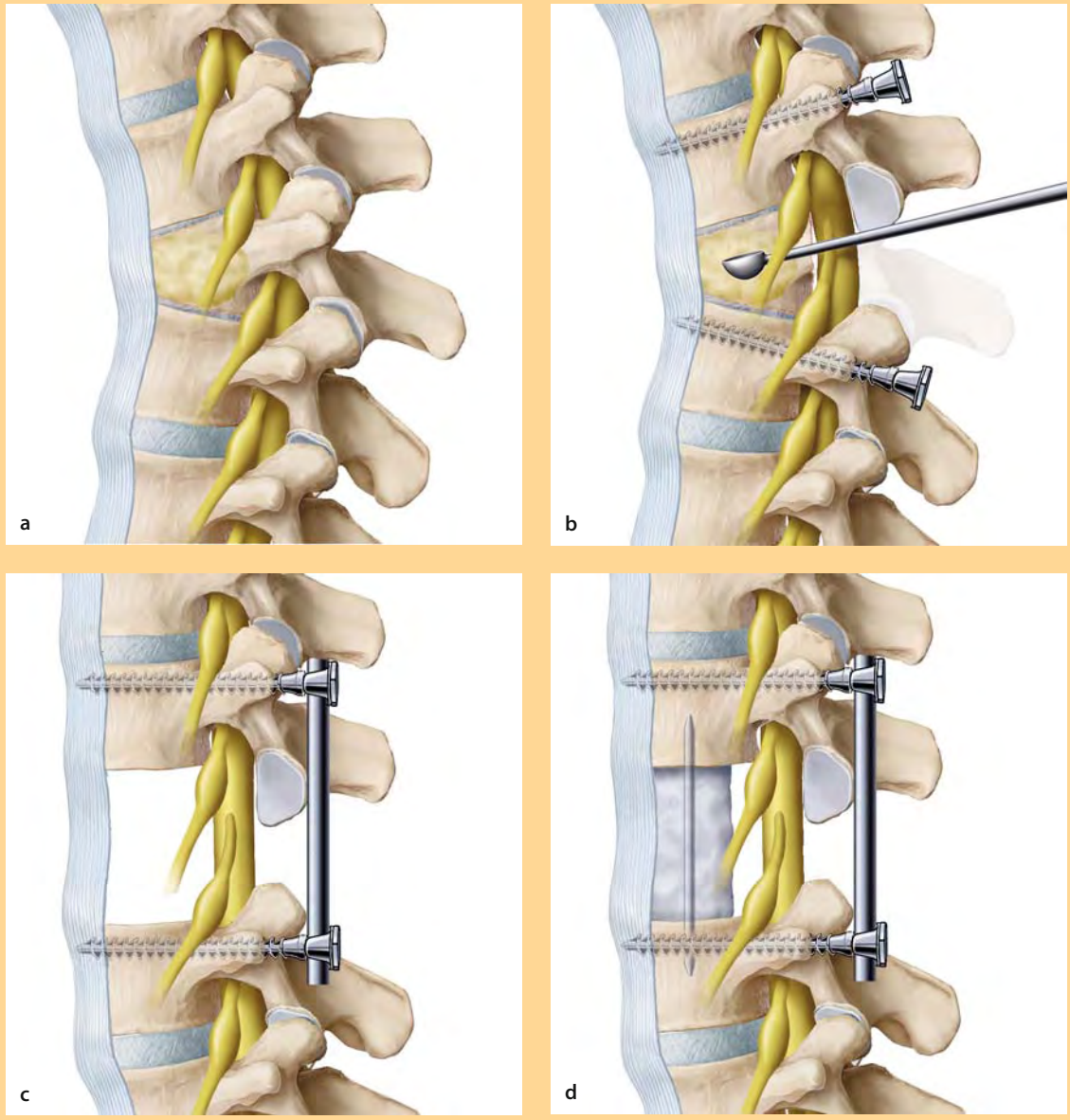


**Figure 6. Single-stage posterior transpedicular vertebrectomy and circumferential reconstruction**

a For metastatic compressive fractures of the thoracic and lumbar spine in a patient with fair general health and/or multiple metastases, an accepted approach is a vertebrectomy and reconstruction through a single-stage posterior transpedicular approach. b Pedicle screw instrumentation of the vertebrae above and below is first performed. The posterior decompression includes complete laminectomy, cord decompression, facet joint resection and pedicle removal on both sides. Careful piecemeal vertebrectomy and resection of the two discs is performed from posterior using curettes and pituitary rongeurs. c At this point, the previously inserted instrumentation is used to realign the spine. d The vertebral body is reconstructed using bone cement, which can be finally compressed by the instrumentation in order to obtain solid fixation.

syringe. The definitive posterior instrumentation is then completed connecting the previously inserted pedicle screws with two lateral rods (Case Study 2). This technique may be less effective in the radical resection of the metastatic lesion but has been described as less invasive for the patient who does not require postoperative ICU recovery and can be immediately mobilized without external sup-

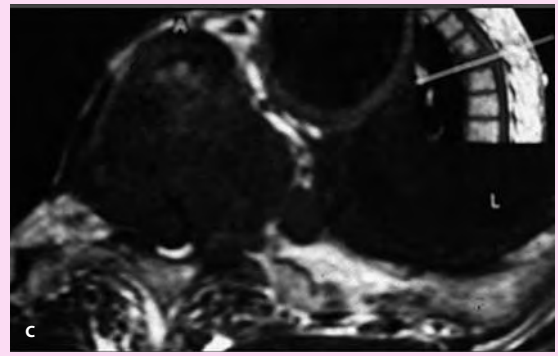

**Case Study 2**

A 78-year-old man with a history of lung adenocarcinoma presented with severe mid thoracic pain and signs of cord compression in both lower extremities. Radiological assessment including plain X-rays and MRI revealed a pathological fracture of T5 with very severe cord compression at the same level (a–c). Due to limited general conditions, the patient was selected for a posterior approach. Large cord decompression was obtained by T5 laminectomy, resection of both pedicles and partial posterolateral vertebrectomy. Spinal reconstruction followed using bone cement and T4–T6 pedicular screw instrumentation (d–e). The patient was still alive 1 year after surgery.

port [1, 8]. This procedure is consequently indicated for patients with limited general health condition and life expectancy.

Endovascular embolization plays a critical role in the management of certain spinal tumors. Some metastatic lesions such as renal cell or thyroid tumors are extremely hypervascular, which may result in tremendous intraoperative blood loss. Preoperative angiography and embolization offer a means of reducing the blood supply to the tumor mass, thus significantly reducing the morbidity associated with surgical resections with only a minimal complication rate [31]. This procedure is recommended to be performed within the 48 h preceding surgery.

### Lumbar Spine

Metastatic lesions localized between L1 and L4 can be managed (tumor debulking and spinal reconstruction) in a similar fashion to the tumors of the mid-lower thoracic spine as previously described. Depending on the location, a **lateral retroperitoneal lumbotomy** or a **low thoracotomy** with release of the diaphragm will be required to expose the lumbar spine [3, 9, 11, 35].

Metastasis of the lumbar spine can be approached from an anterior as well as a posterior approach

Tumor localized in L5 can be resected through an anterior retroperitoneal or transperitoneal approach. Due to the localization, the instrumentation to the sacrum is not possible and an additional posterior fixation will complete the spinal reconstruction [3].

#### *Posterolateral Vertebrectomy*

**Posterolateral vertebrectomy with instrumentation** as described for the thoracic spine can also be advocated in the lumbar spine [1, 8, 10, 24]. In this area, the

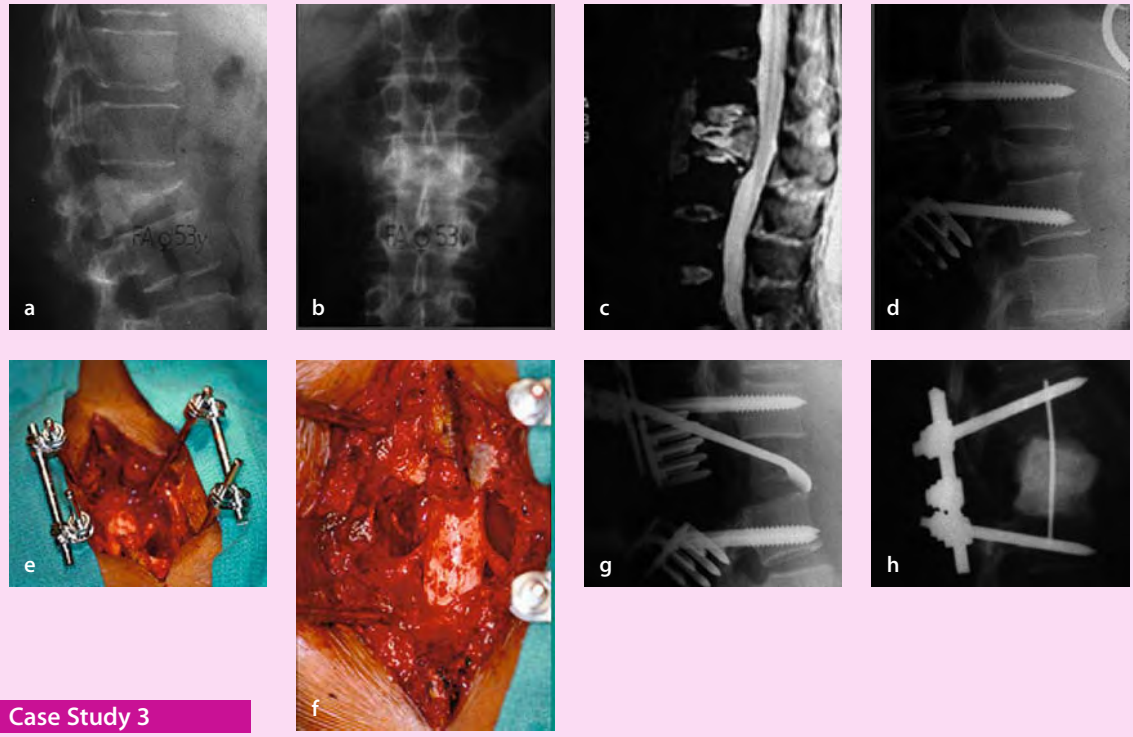


**Case Study 3**

A 53-year-old woman with a history of breast cancer presented with invalidating lumbar pain. Physical examination revealed adequate general health and normal neurologic status. Radiological assessment including plain X-rays and MRI showed an L2 pathological fracture with moderate narrowing of the spinal canal (a–c). Liver and other skeletal metastases were also detected. The patient was selected for a posterior approach. Temporary pedicle screw instrumentation was first accomplished in order to stabilize the spine during decompressive laminectomy (d, e). Bilateral pedicle resection and posterolateral vertebrectomy using pituitary rongeurs and bone curettes was carried out (f, g). Intervertebral distraction using the previously inserted instrumentation allowed more radical vertebrectomy (h). The operation was completed by spinal reconstruction with bone cement, restoration of lumbar lordosis and final L1 – L3 instrumentation.

debulking of the lesion will be even easier, the surgeon being able to retract the neural structures for the posterolateral resection of the tumor. Using the posterior instrumentation, partial reduction of the deformity caused by the pathological fracture can be obtained prior to the reconstruction of the spine using bone cement (Case Study 3).

### *Radical Resection and Reconstruction*

Radical tumor resection and spinal reconstruction is indicated in solitary metastasis

In some rare conditions, such as patients with a solitary metastasis localized in the spine or those with an especially good prognosis (as for example indicated by a scoring system), a more radical resection of the tumor may be indicated. **Spondylectomy** is normally performed through a **combined approach** with a posterior resection of the arch and an anterior radical corpectomy using a ventrolateral thoracotomy or a thoracoabdominal retroperitoneal approach [18]. When reasonable survival is expected, spinal reconstruction using biological material (cage and autologous bone graft) and plate fixation is preferred.

## Postoperative Patient Management

One of the major goals of surgery is to improve the remaining quality of life. Therefore, surgery must allow for an early mobilization of the patient without

rigid external fixation. In the vast majority of these cases, additional radiotherapy is performed about 2 weeks after surgery, as soon as complete wound healing is observed. In cases with previous radiotherapy, the surgeon may consider administering prophylactic antibiotics until the wound has healed to reduce the risk of infections because postoperative infections are often a detrimental complication which reduce life expectancy.

## Recapitulation

**Epidemiology.** About two-thirds of cancer patients will develop metastases and the **spine is a predominant area** for these. Breast, lung, prostate and kidney are the most frequent primary tumors metastasizing to the spine. **Pathological spine fractures** are frequent with potential **risks of neurologic complications**.

**Pathogenesis.** The most frequent **metastatic pathway** is believed to be venous. Arterial, lymphatic and direct extension of the tumor are other possible pathomechanisms. Spinal metastases are mainly **localized** in the **vertebral body** and appear as **osteolytic** or **osteoblastic** lesions. They can result in **vertebral body collapse**, spinal instability and neural compromise.

**Clinical presentation.** **Localized pain** is the most common initial **symptom**. It is aggravated by the trunk movement, sometimes by coughing or sneezing. Less frequent are nerve root pain (unilateral or bilateral) and **myelopathy** signs due to spinal cord compression. The physical findings are often non-specific (local tenderness) unless neurologic deficits are present.

**Diagnostic work-up.** All cancer patients with spinal pain require spinal imaging. **Radiological signs** are delayed on plain X-rays. Missing pedicle, changes in vertebral body contours, lytic lesions within vertebral body, endplate fracture and vertebral body collapse are common findings. **MRI is the imaging study of choice**. Characteristic findings on MRI are bone marrow replacement with decreased signal on T1W and increased signal intensity on T2W images, preservation of disc structure, spinal cord compression and contrast enhancement of the metastatic vertebral body. **Bone scan** is routinely performed to rule out bony metastases in the skeleton but is non-specific. The **identification of the primary tumor** is very important and must be attempted in every case prior to treatment. Percutaneous **biopsy** (CT guided or under image intensifier control) is reported to have a 95% accuracy rate. The most frequent primary tumors are breast (17%), lung (16%), prostate (9%) and kidney (6%). Blood studies are non-specific.

**Non-operative treatments.** The general **goals of treatment** are to relieve pain, reverse or prevent neurologic deficit, restore spinal stability, cure the disease (in case of a solitary metastasis) and improve remaining quality of life. A multidisciplinary approach involving oncologists, radiotherapists and spinal surgeons is a standard of care. **Steroids** are used initially in patients with acute neurologic deterioration. **Radiation therapy** is routinely used in symptomatic skeletal metastases and can be indicated in cases with radiosensitive tumors, stable or slowly progressing neurologic deficits, spinal canal compromise resulting from soft tissue impingement, no evidence of spinal instability, widespread spinal metastatic disease, contraindications for surgery or poor prognosis with short life expectancy. **Radiotherapy** is normally used as combined treatment following surgery.

**Operative treatment.** Surgery is indicated in patients with intractable pain, progressive neurologic changes, failure of radiotherapy during or after radiotherapy, spinal instability, cord compression or in radioresistant tumors. Decompressive **laminectomy alone is rarely indicated**. The goals of surgical intervention are better accomplished combining **decompression** of neural structures, **debulking of tumor mass, realignment** of spinal deformity and **spinal reconstruction** with instrumentation. Different anterior or posterior approaches are possible and will depend on location and extent of neural impingement, number of vertebrae involved, region of the spine affected, need for spinal stabilization and the patient's medical condition.

## Key Articles

**Tokuhashi Y, Matsuzaki H, Hiroshi O, et al. (2005) A revised scoring system for preoperative evaluation of metastatic spine tumor prognosis. Spine 30:2186 – 2191**
Clinical and radiological assessment of patients with spinal metastases. Preoperative classification system with guidelines for surgery and prognosis.

**Wise J, Fischgrund J, Herkowitz H, et al. (1999) Complications, survival rates, and risk factors of surgery for metastatic disease of the spine. Spine 24:1943 – 1951**
Retrospective study analyzing risk factors for surgical complications. A relatively long survival time after spinal surgery and a low rate of major complications justify surgical treatment. Careful preoperative selection is discussed.

**Bilsky M, Boland P, Lis E, et al. (2000) Single-stage posterolateral transpedicle approach for spondylectomy, epidural decompression and circumferential fusion of spinal metastases. Spine 17:2240 – 2250**
Retrospective study and a good description of the surgical technique for posterolateral vertebrectomy and spinal reconstruction. The authors demonstrate the feasibility of the technique with a low complication rate and no need for ICU in the postoperative follow-up.

**Gokaslan Z, York J, Walsh G, et al. (1998) Transthoracic vertebrectomy for metastatic spinal tumors. J Neurosurg 89:599 – 609**
Article reporting the surgical technique for radical vertebrectomies in the thoracic spine. Indications and complications are reported in a retrospective study.

## References


1. Akeyson E, McCutcheon I (1996). Single-stage posterior vertebrectomy and replacement combined with posterior instrumentation for spinal metastases. J Neurosurg 85:211 – 220
2. American Cancer Society (1982) Cancer facts and figures. ACS, New York
3. Asdourian P (1997) Metastatic disease of the spine. In: Bridwell K, DeWald R (eds) The textbook of spinal surgery, 2nd edn. Lippincott-Raven, Philadelphia, PA, pp 2007 – 2050
4. Barron K, Hirano A, Araki S, et al. (1959) Experiences with metastatic neoplasms involving the spinal cord. Neurology 9:91
5. Batson O (1940) The function of the vertebral veins and their role in the spread of metastases. Ann Surg 112:138
6. Beltrans J, Noto A, Chakeres D, et al. (1987) Tumors of the osseous spine: staging with MR imaging versus CT. Radiology 162:565
7. Bilsky M, Lis E, Raizer J, et al. (1999) The diagnosis and treatment of metastatic spinal tumor. Oncologist 4:459 – 469
8. Bilsky M, Boland P, Lis E, et al. (2000) Single-stage posterolateral transpedicle approach for spondylectomy, epidural decompression and circumferential fusion of spinal metastases. Spine 17:2240 – 2250
9. Boland P, Lane J, Sundaresan N (1982) Metastatic disease of the spine. Clin Orthop 169: 95 – 104
10. Bridwell K, Jenny A, Saul T, et al. (1988) Posterior segmental spinal instrumentation with posterolateral decompression and debulking for metastatic thoracic and lumbar spine disease: limitation of the technique. Spine 13:1383 – 1394
11. Brihaye J, Ectors P, Lemort M, et al. (1988) The management of spinal epidural metastases. Adv Tech Stand Neurosurg 16:121 – 129
12. Bünger C, Laursen M, Hansen E, et al. (1999) A new algorithm for the surgical treatment of spinal metastases. Spine 24:101 – 105
13. Coman D, De Long R, Mc Cucheon J (1951) Studies on the mechanism of metastasis: the distribution of tumors in various organs in relation to the distribution of arterial emboli. Cancer Res 11:648
14. Deramond H, Depriester C, Galibert P, Le Gars D (1988) Percutaneous vertebroplasty with polymethylmethacrylate. Radiol Clinics North Am 36:533 – 546
15. Edelstyn G, Gillespie P, Grebbel F (1967) The radiological demonstration of osseous metastases: experimental observation. Clin Radiol 18:158
16. Emery S, Brazinski M, Koka A, et al. (1994) The biological and biomechanical effects of irradiation on anterior spinal bone grafts in a canine model. J Bone Joint Surg 76(A):540 – 548

17. Galasko C (1986) Skeletal metastases. Clin Orthop 210:18 – 25
18. Gokaslan Z, York J, Walsh G, et al. (1998) Transthoracic vertebrectomy for metastatic spinal tumors. J Neurosurgery 89:599 – 609
19. Harrington K (1986) Metastatic disease of the spine. J Bone Joint Surg 68A:1110 – 1115
20. Harrington K (1997) Orthopaedic surgical management of skeletal complications. Cancer 80:1614 – 1627
21. Jansson K, Bauer H (2006) Survival complication and outcome in 282 patients operated for neurological deficit due to thoracic or lumbar spinal metastases. Eur Spine J 15:196 – 202
22. Joo K, Parthasaranthy K, Bakshi S, et al. (1979) Bone scintigrams: their clinical usefulness in patients with breast carcinoma. Oncology 36:94 – 99
23. Karnofsky D (1967) Clinical evaluation of anti-cancer drugs: cancer chemotherapy. GANN Monogr 2:223 – 231
24. Magerl F, Coscia M (1988) Total posterior vertebrectomy of the thoracic or lumbar spine. Clin Orthop 232:62 – 69
25. Marchesi D, Boos N, Aebi M (1993) Surgical treatment of tumors of the cervical spine and first two thoracic vertebrae. J Spinal Disord 6:489 – 496
26. Mink J (1986) Percutaneous bone biopsy in the patient with known or suspected osseous metastases. Radiology 161:191 – 195
27. Murphy W, Destonet J, Gilula L (1981) Percutaneous skeletal biopsy: a procedure for radiologists – results, review and recommendations. Radiology 139:545 – 561
28. Nottebaert M, von Hochstetter A, Exner G, et al. (1987) Metastatic carcinoma of the spine. Int Orthop 11:345 – 348
29. Oda I, Abumi K, Ito M, et al. (2006) Palliative spinal reconstruction using cervical pedicle screws for metastatic lesions of the spine. Spine 31:1439 – 1444
30. O'Mara R (1974) Bone scanning in osseous metastatic disease. JAMA 229:1915 – 1918
31. Prabhu V, Bilsky M, Jambhekar K, et al. (2003) Results of preoperative embolization for metastatic spinal neoplasms. J Neurosurg Spine 2:156 – 164
32. Schaberg J, Gainor B (1985) A profile of metastatic carcinoma of the spine. Spine 10:19 – 26
33. Tokuhashi Y, Matsuzaki H, Toriyama S, et al. (1990) Scoring system for the preoperative evaluation of metastatic spine tumor prognosis. Spine 15:1110 – 1113
34. Tokuhashi Y, Matsuzaki H, Hiroshi O, et al. (2005) A revised scoring system for preoperative evaluation of metastatic spine tumor prognosis. Spine 30:2186 – 2191
35. Tomita K, Kawahara N, Kobayashi T, et al. (2001) Surgical strategy for spinal metastases. Spine 26:298 – 306
36. Ulmar B, Richter M, Cakir B, et al. (2005) The Tokuhashi score: significant predictive value for the life expectancy of patients with breast cancer with spinal metastases. Spine 30:2222 – 2226
37. Weigel B, Maghsudi M, Neumann C, et al. (1999) Surgical management of symptomatic spinal metastases: postoperative outcome and quality of life. Spine 24:2240 – 2246
38. Wise J, Fischgrund J, Herkowitz H, et al. (1999) Complication, survival rates, and risk factors of surgery for metastatic disease of the spine. Spine 24:1943 – 1951

# 35 Intradural Tumors

Yashuhiro Yonekawa, Richard Marugg

## Core Messages

- ✔ Intradural spinal tumors can be classified into extramedullary tumors (tumors that are inside the dura but outside the spinal cord – approximately 65 % of cases) and intramedullary tumors (tumors within the spinal cord tissue – approximately 35 % of cases)
- ✔ The majority of intradural extramedullary tumors (80 %) are meningiomas and nerve sheath tumors (neurinomas and neurofibromas)
- ✔ Intradural intramedullary tumors are frequently (60 %) ependymomas and astrocytomas
- ✔ MRI is the diagnostic method of choice
- ✔ Introduction of the microsurgical technique has greatly improved surgical results
- ✔ Intraoperative ultrasound localization or navigation can be helpful, while intraoperative neurophysiological monitoring still needs to be refined for credible use
- ✔ Most extramedullary tumors can be resected totally. For intramedullary tumor a gross total resection can be achieved in ependymomas, hemangioblastomas and cavernous angiomas with a clear cleavage plane between the tumor and normal spinal cord tissue. This is not usually the case in astrocytomas
- ✔ Consideration should always be given to whether the spine has been rendered unstable by the pathology or by surgical intervention

## Epidemiology

Successful removal of a spinal tumor was first reported by Horsely in 1888 [15]. Elsberg proposed a two-stage operation in the case of intramedullary tumors lacking a definitive plane between the spinal cord and tumor in the early part of the twentieth century [12, 13], albeit with high morbidity and mortality. With new technological advances especially the introduction of the bipolar coagulator and microsurgery, starting in the 1950s and 1960s respectively [16, 17, 21], the surgical risks were dramatically reduced.

Intradural tumors especially intramedullary tumors are rare and are most often slow-growing tumors

Intradural tumors represent about 10 % of primary central nervous system (CNS) tumors, and about two-thirds of these tumors are in an **extramedullary location**. Around 80 % of extramedullary tumors are meningiomas and nerve sheath tumors (neurinomas and neurofibromas). Fifteen percent of extramedullary tumors are ependymomas of the filum terminale in the conus cauda region. Although the filum terminale is of neuroectodermal origin, these tumors are often categorized as extramedullary from the anatomical and surgical point of view. Rare tumors such as paragangliomas, drop metastases or granulomas represent the remaining 5 % [9]. **Intramedullary tumors** are uncommon and the incidence is below 1 per 100 000 population. Most of them are slow-growing neoplasms. More than 60 % of all spinal cord tumors are gliomas, e.g., ependymomas (Case Introduction) and astrocytomas. Around 70 % of tumors are located in the cervical or upper thoracic part of the spinal cord [3, 14, 20].

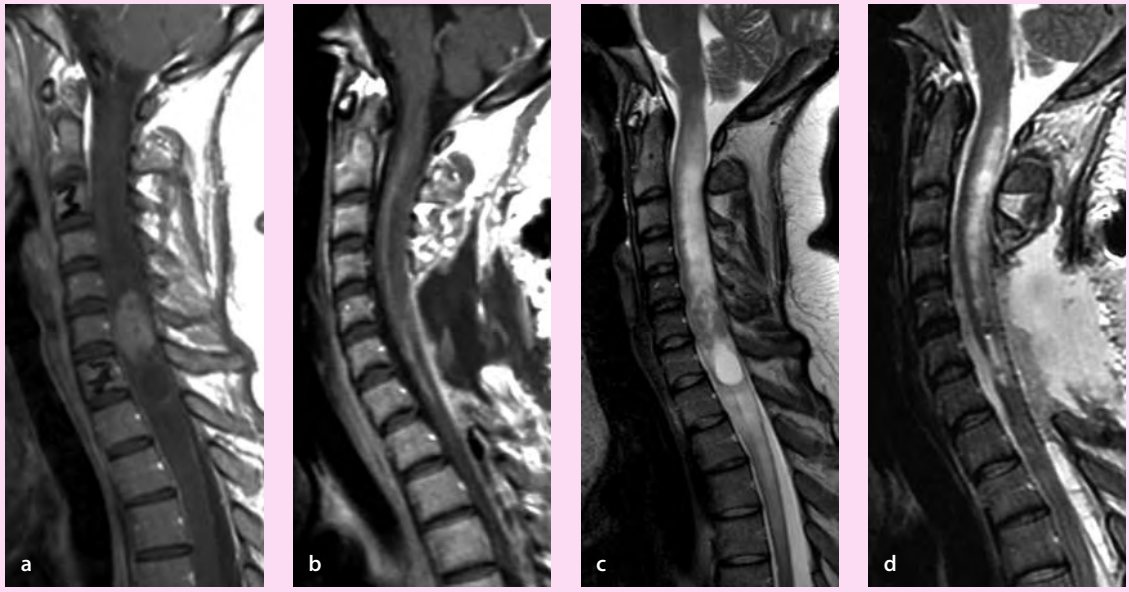


## Case Introduction

A 32-year-old woman presented with a 9-month history of complaints. In the last pregnancy trimenon she complained about paresthesias in the right leg with an increasing weakness of both legs. Just after the normal delivery, she had a complete paraplegia for 5 min. Three months later she noticed paresthesia in the left hand, followed by a bandlike painful dysesthesia radiating to the chest and weakness in both arms. The MRI of the spine showed an intradural intramedullary tumor (a, c). The cervical cord is enlarged at both ends of the solid tumor component, which shows a contrast enhancement. At the caudal end of the tumor a cyst is visible. The signal behavior of the cyst is similar to cerebrospinal fluid and at the rostral end multicystic formations are visible. At both ends of the tumor there are hydromyelia and extensive edema. The tumor was grossly radically resected by posterior midline longitudinal myelotomy **(for surgical treatment see Fig. 5).** The histopathologic diagnosis was ependymoma (WHO grade 1). The patient showed no additional postoperative deficits; the motor function was intact. Postoperative MRI (b, d) shows the cervical spinal cord after tumor resection. At the time of follow-up 3 months later, the patient showed normal motor function but complained of girdle-like dysesthesia at the chest radiating into the small finger on the left side.

Multiplicity of extramedullary tumors and their association with intramedullary tumors is typical for patients with neurofibromatosis [24, 38].

## Etiology and Pathogenesis

Some neoplasms appear to be the result of genetic disease

The etiology of intradural tumors remains unclear, but there is now considerable evidence that some neoplasms are the result of genetic disease. Genetic studies of tumors are focused on chromosomal aberrations, the role of mitogenic differentiation factors and their surface receptors, growth factors, oncogenes and tumor suppressor genes.

Multiple meningiomas in combination with bilateral acoustic neurinomas establish the diagnosis of **neurofibromatosis Type 2** (NF-2). An NF disorder should be considered even in patients with solitary meningioma or nerve sheath tumor. Between 35 % and 45 % of patients with nerve root tumors have neurofibromatosis. Intramedullary tumors are common in NF-2 (Fig. 1). These are typically ependymomas. NF-2 is associated with an abnormality on chromosome 22 [24, 38]. Spinal hemangioblastomas occur in 30 % of patients with von Hippel-Lindau disease, which is associated with an abnormality on chromosome 3 [31].

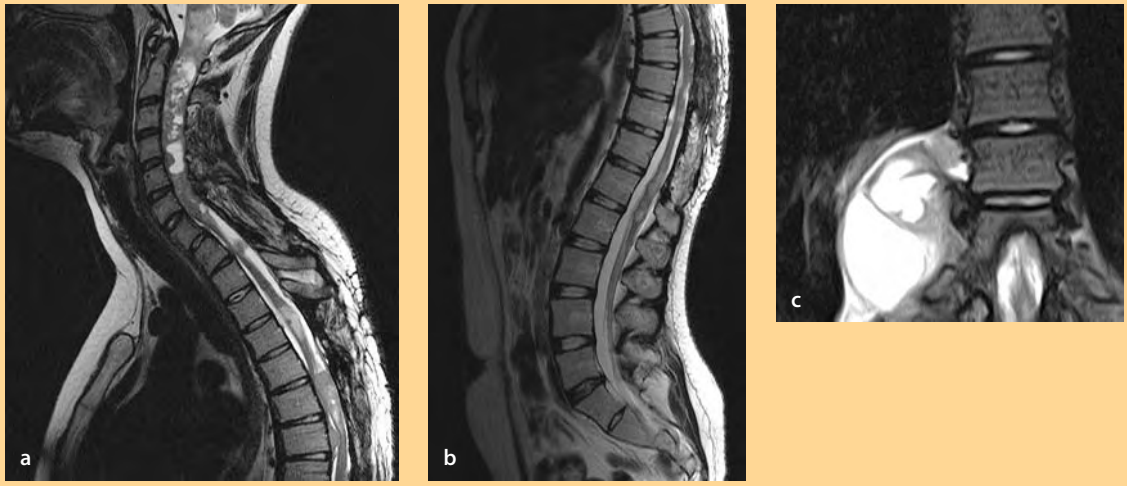


**Figure 1. Neurofibromatosis Type 2**

A patient with neurofibromatosis Type II. a, b Different intradural extramedullary (meningiomas and neurofibromas) and intradural intramedullary tumors (ependymoma) as well as c extraspinal tumors are to be seen in the whole spine.

For unknown reasons **most intramedullary tumors are benign**, in contrast to brain tumors.

Disorders associated with intradural spinal tumors are neurofibromatosis Type 2 and von Hippel-Lindau disease

Often an extensive perilesional edema can be found in a caudal and rostral direction, which is considered to be due to impaired venous return in the presence of the special anatomy of the valveless venous plexus [27]. Around 70 % of intramedullary tumors are accompanied by syringo- or hydromyelia and/or intramedullary cyst formation. There is an enormous functional adaptability of the spinal cord tissue to compression of slow-growing tumors, so that the average reported duration between the onset of symptomatology and the diagnosis has been reported to be as long as 3.5 years. Neurological impairment is produced mainly by compression of the tissue rather than by tumor invasion [31].

The spinal cord has an enormous functional adaptability to slowly growing compressive tumors

## Classification of Intradural Tumors

### Intradural-Extramedullary Tumors

#### Meningiomas

The arachnoid cap cells or immature fibroblasts of the dura are considered to be the tumor precursor cells. Most meningiomas are found entirely intradurally. However, transdural growth or entirely extradural growth is also possible. Invasive growth or hyperostotic reaction of the bone is rare. Tumors are predominantly found in the thoracic spine. The tumor attachment is often lateral with a ventral or dorsal extension.

Meningiomas frequently occur in the thoracic spine and in females

The upper cervical spine and the foramen magnum are also common sites. Meningiomas of this location often occupy a ventral or ventrolateral position and may adhere to the vertebral artery near its intradural entry and initial intracranial course [1, 4, 33, 35]. The ratio of spinal to intracranial meningiomas is about 1 : 8; the mean age at presentation is 56 years. More than 80 % of spinal meningiomas occur in women [24, 35]. Multiple spinal meningiomas are rare. Meningio-

Symptomatology is very insidious

mas in the region of the conus and cauda equina are uncommon, representing only 2 % of all spinal cord meningiomas. Due to the predilection for the thoracic location and above-mentioned functional adaptability of the spinal cord, clinical symptoms are very insidious.

A complete removal of spinal meningiomas is achieved in the vast majority of cases with a recurrence rate of less than 10 %. Aggressive meningiomas and malignant upgrading of spinal meningiomas are extremely rare [24, 35].

### Nerve Sheath Tumors

Two main types are found in the spine:

- neurinoma (schwannoma or neurilemoma)
- neurofibroma

Nerve sheath tumors occur at every level of the spinal canal

The proliferating cell is the Schwann cell. **Neurinomas** (Case Study 1) are well-circumscribed intradural or extradural or combined intra-extradural tumors starting either from the nerve sheaths of peripheral nerves or spinal nerve roots or peripheral nerves. Their occurrence can be sporadic or can be within the scope of NF-2 or less frequently of NF-1 [7, 9, 25, 38]. Most are solitary and distributed equally over the whole spinal canal level.

Peak incidence is around the **5th decade**. Males and females are equally affected. Most nerve sheath tumors are intradural. Around 10 % of tumors extend through the dural root sleeve, comprising the so-called "dumbbell" type. Most nerve sheath tumors derive from a dorsal nerve root, while ventral nerve root tumors are neurofibromas.

Nerve sheath tumors can mimic the symptoms of disc herniations

The clinical symptoms are often indistinguishable from those associated with disc herniation: pain and radiculopathy, followed by paresthesias and limb weakness. Spinal cord compression can result in myelopathic symptoms. A **sarcomatous transformation** has been reported to occur in up to 11 % of patients with neurofibromatosis [31].

### Filum Terminale Ependymoma

From the anatomical and surgical perspective this tumor is often categorized as extramedullary in location, although it should be classified as an intramedullary tumor, since the filum terminale is of neuroectodermal origin. Astrocytomas, oligodendrogliomas and paragangliomas can also originate in the filum terminale. **Myxopapillary ependymoma** is the most common histologic type [30].

### Paraganglioma

Paragangliomas are rare tumors that are found in the cauda equina and filum terminale [37].

## Differential Diagnosis

Differential diagnosis includes rare **non-neoplastic causes** of diffuse nerve root enlargement or thickening such as:

- toxic neuropathy
- inflammatory neuritis
- sarcoidosis (Fig. 2a)
- histiocytosis
- spinal intradural malignant metastasis (Fig. 2b, c)

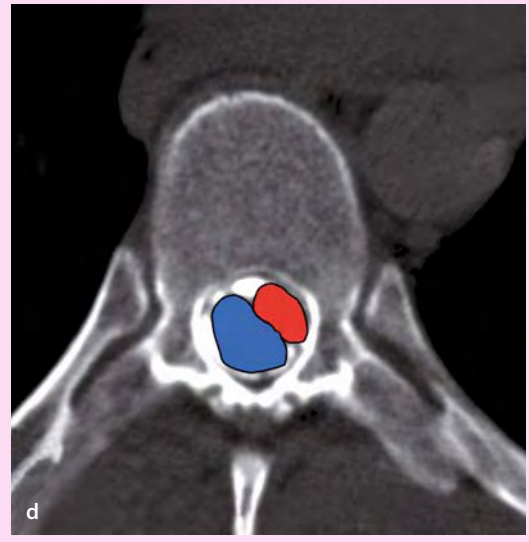


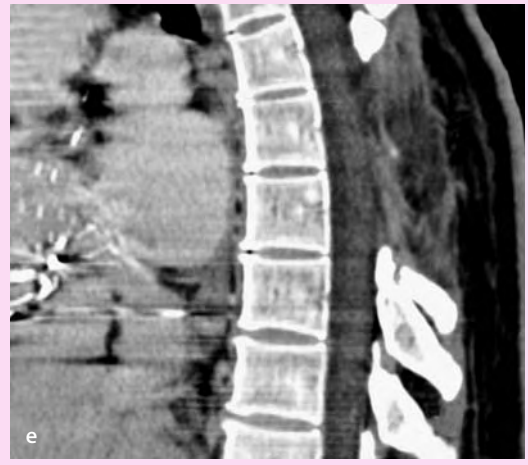


## Case Study 1

A 40-year-old woman noticed gait disturbance of abrupt onset with motor weakness of the right lower limb and a sensory impairment below the level of T6 but without sphincter disturbances. Since 2 years previously she had suffered from progressive thoracic pain. Since 1 year previously the thoracic back pain had worsened associated with paresthesias in both legs, more on the right side. Fifteen and 8 years previously, she had microdiscectomies at the level of L4/5 and L5/S1. Due to a tachyarrythmia a heart pacemaker was implanted at the age of 20 years. Therefore a myelography and a myelo-CT were performed as the diagnostic method of choice instead of the contraindicated MRI. The myelography (a, b) demonstrated the tumor and the cord contour and the contrast block at the level of the caudal tumor pole at T8. The CT scan after the myelography presented an intradural-extramedullary tumor on the right side at thoracic level 6–8 with an enormous compression of the spinal cord (c, d). A laminectomy at three levels was performed and a neurinoma (WHO grade 1) was totally removed (**for surgical treatment see Fig. 4**). The sensory roots at the level were partly sacrificed. The postoperative sagittal reconstructed CT scan (e) of the thoracic region demonstrated laminectomies, tumor removal and the contour of the spinal cord without any signs of compression. Two days after surgery the motor weakness of the lower extremity was improved so that she could ambulate without aid. At 12 months follow-up she had no back pain and a normal gait but still had a sensory disturbance at the thoracic level due to the sacrificed dorsal roots.

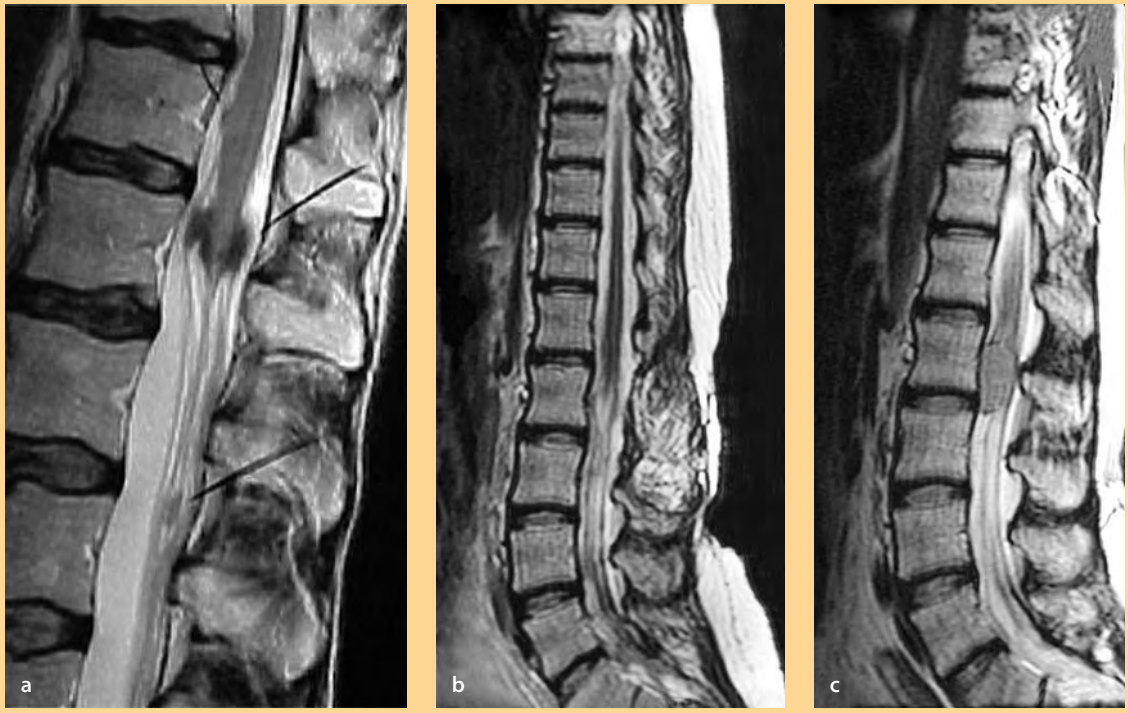


**Figure 2. Differential diagnosis**

A differential diagnosis is mandatory because various diseases can mimick a primary spinal tumor. a T2W sagittal image shows a tumorous lesion at the conus level. Frozen section biopsy revealed a sarcoidosis and further surgery was stopped subsequent to the biopsy. b Preoperative T2W image and c postoperative MRI of another case with a conus lesion being a metastasis of a malignant melanoma.

- non-Hodgkin's lymphoma
- hypertrophic neuropathies, e.g., Dejerine-Sottas disease, Charcot-Marie-Tooth disease [31]

## Intradural-Intramedullary Tumors

### Ependymomas

Myxopapillary ependymomas exclusively occur in the conus and filum terminale

Spinal ependymomas are usually **well circumscribed** (Case Introduction), arising from ependymal cells lining the central canal or its remnants and from the cells of the ventriculus terminalis in the filum terminale. **Myxopapillary ependymomas** occur exclusively in the conus medullaris and filum terminale. Hemorrhage and cystic degeneration are common. Ependymomas account for 60% of glial spinal cord tumors and comprise 90% of primary tumors in the filum terminale and cauda equina [30, 31]. **Mean age is 43 years** with a slight female predominance. For myxopapillary ependymomas of the cauda equina region the mean age is 28 years with a slight male predominance. Intramedullary tumors are mainly benign tumors found in children or young adults. Complaints of **back pain or neck pain** are found in 65% of patients with intramedullary ependymomas. Previous history is usually often long, because these tumors are slow growing and there are often mild objective neurological deficits. The average reported duration between the onset of such symptomatology and diagnosis has been reported to be around 3.5 years [2, 3, 14, 27, 31].

Symptoms precede diagnosis by years

Low back pain or sacral pain, leg weakness and sphincter dysfunction are the complaints and signs found in patients with myxopapillary ependymomas of the cauda equina region. Some sacral and presacral lesions can behave aggressively and can metastasize to the lymph nodes, the lung and the bone [34].

Ependymomas (in adults) and astrocytomas (in children) are the two most frequent intramedullary tumors

### Astrocytoma

**Most** spinal cord astrocytomas **are low-grade tumors**. Malignant gliomas are rare: 15% are anaplastic astrocytoma and 1% are glioblastoma multiforme. Intramedullary astrocytomas diffusely expand the spinal cord, cyst formation is common and there is often an associated syrinx. Tumor cysts are often eccentrically positioned within the cord, whereas the syrinx and benign cysts are rostral or caudal to the tumor and cause symmetric cord expansion. Astrocytoma is the most common intramedullary tumor in children. **Median age is 21 years**. The predominant location is the cervical spine (Fig. 3), followed by the thoracic spine [6, 13, 14, 20, 26, 32]. Pain is the early presenting symptom. Symptoms or signs of neurological dysfunction are often lacking early in the course of disease.

### Hemangioblastoma

Hemangioblastomas comprise 3–8% of intramedullary tumors. About one-third of patients with hemangioblastomas have von Hippel-Lindau disease. Retinal or cerebellar involvement often precedes spinal cord symptoms. A highly vascular nodule with an extensive cyst is found in around half of cases (Case Study 2), usually emerging at the dorsal portion of the spinal cord. Half of hemangioblastomas are found at the thoracic level followed by the cervical level. There are usually prominent leptomeningeal vessels near the lesion. More than 80% of patients are symptomatic before the age of 40 years. Eighty percent of spinal cord hemangioblastomas are solitary lesions [31].

About one-third of patients with hemangioblastomas suffer from von Hippel-Lindau disease

**Figure 3. Astrocytoma**

A case of cervical astrocytoma with cyst formation at the caudal tumor pole and within the tumor. Intraoperatively, no clear cleavage plane could be found, so the surgery ended up with partial removal and remnant tumor left to the anterior part. The postoperative follow-up revealed only slight sensory disturbance and no other neurological abnormalities.

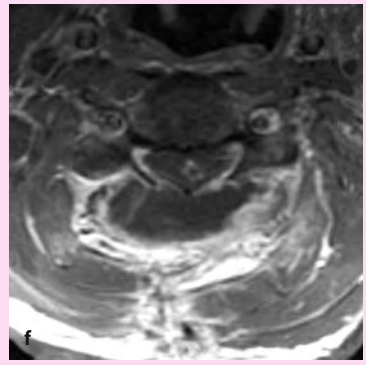

## Case Study 2

A case of hemangioblastoma of 5 years history beginning with sensory disturbance on the left hand progressing more recently to tetraparesis with gait disturbance. This was embolized twice without subsequent surgical removal 1.5 years and 6 months ago respectively. T1W image with CE (a, b) revealing an intramedullary hemangioblastoma at C2–C4 with hydromyelia formation extending cranially to the medulla and caudally to C6. Conventional vertebral angiography (c) in the lateral view displaying the tumor staining supplied by radicular arteries and the anterior spinal artery. MR angiography AP view (d) displaying the tumor with a vascular supply from the anterior spinal artery and the radicular arteries. The patient underwent microsurgical complete removal of the tumor. Postoperative T1W sagittal (e) and T2W axial (f) images revealed complete removal of the tumor with disappearing hydromyelia. MR angiography (g) revealing opacification neither of the tumor nor of the feeding arteries. At 3 years follow-up the patient presented with good recovery of neurological findings and no signs of recurrence depicted on neuroimagings.

### Other Intramedullary Tumors

Oligodendroglioma, ganglioglioma and intramedullary neurinoma can occur but are rare. Intramedullary metastases are very rare. **Intramedullary metastasis** occurs as a result of primary malignancies such as:

Although intramedullary metastases are very rare, they must be considered as an important differential diagnosis

- breast cancer
- lung cancer
- lymphomas
- leukemia
- malignant melanoma (Fig. 2b, c) [31]

**Cavernous angiomas** are briefly mentioned here as these should be differentiated from other intramedullary tumors and are encountered rather occasionally as is shown in our series (Table 4). They are similar to intracranial cavernous angiomas of typical blackberry appearance associated with localized hemorrhage in different ages. They become symptomatic between the 3rd and 6th decades and have a female predominance of 2:1. They are found most frequently at the thoracic level followed by the cervical level [31].

## Clinical Presentation

### History

The **key feature** of slowly growing tumors is the long history of signs and symptoms due to the substantial plasticity of the spinal cord. The time course of symptoms and signs is very insidious and longstanding but can be of abrupt onset due to hemorrhage in cases of ependymomas and cavernous angiomas. **Acute onset** with a **subarachnoid hemorrhage** can also be a rare presentation of spinal cord tumors such as neurinomas, cavernous angiomas and ependymomas.

The symptoms of a slowly growing tumor are insidious

The **signs and symptoms** differ depending on:

- level
- location
- size of tumor
- speed of growth

In general, intramedullary tumors produce segmental deficits while extramedullary tumors produce radicular and segmental deficits. Both tumors reveal long tract symptoms and signs in their advanced stage. Lateralization or asymmetry of early signs and symptoms reflects the lateral location of a tumor. **Hemicord syndrome** or **Brown-Séquard's syndrome** is observed commonly at the advanced stage. Mainly in the German literature some stagings of spinal compression have been advocated:

- *early stage* – neuralgic stage
- *second stage* – Brown-Séquard's syndrome or incomplete transsectional lesion
- *third stage* – complete transsectional stage [30]

The **cardinal symptoms** are:

The cardinal symptoms are pain and neurologic deficits

- progressive local pain (stiff neck or back pain)
- pain during recumbency (nocturnal pain)
- radicular or myelopathic pain
- non-painful sensory disturbances
- motor weakness (gait disturbance)

- clumsiness and ataxia
- sphincter disturbances (usually urogenital, less commonly anal)

Nocturnal pain is the most common form of pain

The pain might be of the radicular type, with radiation often increasing with Valsalva's maneuver and/or spine movement. Segmental or medullary pain (non-radicular, diffuse non-describable pattern) might be present continuously, radiating into the whole leg or one-half of the body without affection of movement. Suboccipital pain and distal arm weakness with atrophy and clumsiness of the intrinsic hand muscles reported to be peculiar to upper cervical and foramen magnum tumors have been attributed to probable venous return insufficiency [26].

## Physical Findings

A thorough neurological exam is compulsory

A thorough neurological examination is key to the assessment of spinal tumors. **Findings** on clinical examination **include:**

- sensory deficits (without sacral sparing)
- motor weakness
- gait disturbance
- ataxia
- bowel and bladder dysfunction
- Horner's syndrome
- headache (due to increased intracranial pressure)
- torticollis
- spinal deformity (scoliosis and kyphosis)

Motor weakness including gait disturbance usually occurs late

Sensory disturbance of intramedullary tumors is often characterized by **dissociated sensory disturbance** in which pain and temperature sensation are impaired already in the early stage and touch and position sense are intact. The motor weakness which often follows the sensory symptoms results in a gait disturbance.

If sacral sparing is present, an intramedullary tumor should be suspected

**Long tract symptoms** are presented with clumsiness and ataxia. Sphincter disturbances are usually urogenital (less commonly anal) with difficulty in evacuation, retention, incontinence, and impotence. They are usually of late manifestation except for tumors at the conus and cauda equina. Findings of **sacral sparing**, however, are frequently observed in patients with intramedullary tumors, since a distal portion of the impaired level tends to be spared as the sacral fibers locate peripherally in the lateral spinothalamic tract.

**Increased intracranial pressure** often associated with papilledema might occur at any level of extramedullary tumor (preferably at the upper cervical levels) presumably due to elevated protein in the cerebrospinal fluid (CSF); hence its flow impairment and absorption. **Horner's syndrome** (enophthalmos, proptosis, myosis and loss of sweating) appears at the time of impairment of the lateral horn between C8 and T3 or of sympathetic pathways in the C8 and T1 anterior roots. Scoliosis, loss of lordosis or torticollis can take place within the scope of root irritation and muscle weakness or atrophy and has been reported to be present in one-third of cases with intramedullary tumors.

## Diagnostic Work-up

Magnetic resonance imaging should be performed as the first diagnostic modality when symptoms and signs indicate a spinal tumor should be suspected. The other imaging modalities are second in line.

## Imaging Studies

### Standard Radiography

Standard radiography sometimes exhibits clues to intradural tumors

Plain films are still routinely obtained but have a limited diagnostic value. **Abnormal findings** of intradural tumors can be:

- bony destruction in metastasis or anaplastic tumors
- widening of the spinal canal represented by widening of the intrapedicular distance
- thinning of the pedicle
- "scalloping" of the posterior vertebral surface (in cases with slow-growing tumors)
- widening of the intervertebral foramen (especially in patients with neurinomas)
- disappearance of the normal spinal curvature
- progressive scoliosis
- tumor calcification

### Myelography

Myelography has been superseded by MRI for the diagnostic work-up of intradural spinal tumors. Myelon distension in intramedullary tumors is outlined by contrast dye remaining at its periphery. Distension of the myelon is more diffuse and smooth in astrocytomas than in ependymomas. Extramedullary tumors show an extramedullary block with cord displacement and "shoulder of contrast material."

### CT and Myelo-CT

These are the methods of choice in patients in whom MRI cannot be performed because of contraindications (e.g., pacemaker) (Case Study 1). **Typical findings** are:

- bony deformation such as destruction, scalloping, widening of the spinal canal and/or the intervertebral foramen
- calcification
- contrast enhancement
- spinal cord compression
- expanding medullary mass

### Magnetic Resonnance Imaging

MRI is the first choice in the diagnosis of spinal cord tumors

MRI is the diagnostic imaging procedure of choice. T1W- and T2W-weighted (= W) images as well as gadolinium-enhanced T1W images should be systematically obtained. The entire spinal cord must be studied.

At least two different imaging planes must be used in order to locate the tumor properly and to differentiate intramedullary tumors from extramedullary tumors. Coronal sections (anteroposterior view) can demonstrate a tumor in relation to the bony structures in the same view as in the operating room, which can be helpful in planning the extent of the laminectomy.

**General findings** in **intradural spinal** tumors are:

- Extramedullary tumors and many intramedullary tumors such as ependymomas or hemangioblastomas have clear demarcations, but infiltrating tumors or aggressive tumors of the latter have ill-defined borders. Contrast enhancement (CE) can be seen quite often, but an enhancing medullary

mass does not necessarily mean a neoplasm. Both edema and hydromyelia associated with intramedullary tumors can be very extensive but usually disappear after total tumor removal.

- **Solid nodules** can be distinguished from **cystic elements** (the signal behavior of these cysts is usually different from CSF, due to the high protein content of the fluid).
- **Hemorrhage** may complicate spinal cord tumors and can be recognized on T1W images as hyperintense areas, when the hemorrhage is 1 week to approximately 4 weeks old. Hemosiderin deposits can later be identified as low-signal areas on T2W images, preferably obtained by gradient-echo sequences.

Most tumors are isointense but enhance with contrast medium

**Specific findings** for **intradural spinal tumors** are:

- **Nerve sheath tumors** are usually isointense on T1W images and hyperintense on T2W images; almost 100 % CE positive; foraminal widening; calcification rare.
- **Meningiomas** present as isointense with cord on both T1W images and T2W images; moderate CE with or without association of dural tail; no bone destruction; calcification occasional.
- **Ependymomas** are isointense with cord on T1W images and hyperintense on T2W images; CE strong somewhat inhomogeneous due to cyst formation or hemorrhage; foci of points or trails of signal void due to strong vascularization; vertebral body scalloping in conus tumors.
- **Astrocytoma** are iso- to hypointense on T1W images and hyperintense on T2W images with no sharp delineation; almost 100 % CE positive but rather spotty; cyst formation common.
- **Hemangioblastoma** are isointense to cord on T1W images, hyperintense on T2W images; foci of signal void spots and trails due to high vascularization; CE strongly positive; cyst formation common.
- **Cavernous angioma** present with mixed signals "popcorn-like or cat's eye" lesion; blooms on T2W images and gradient echo; multiple lesions in more than half of cases.

### Angiography

Spinal angiography has a place in the definitive diagnosis of hemangioblastoma (showing dense vascular stain and prominent draining veins) and vascular malformations and/or their endovascular treatment (Case Study 2).

## Lumbar Puncture

Lumbar puncture as an invasive method has a limited diagnostic value. **Queckenstedt's sign** (a rapid rise in the intracranial pressure measured by spinal puncture at the time of jugular vein compression) is only of classic significance. Furthermore, spinal puncture is considered to be a contraindication in cases of suspected complete block of the subarachnoid space because of the risk of sudden neurological deterioration.

**Laboratory CSF findings** obtained from the puncture have now practically only supportive significance:

- **Elevated protein** (500 – 100 mg/dl) in the CSF below the blocked level of the subarachnoid space due to spinal cord tumors is found especially in cases with extramedullary intradural tumor rather than intramedullary tumors. Froin's syndrome of coagulation of CSF due to high protein contents has been well described in the book so far.

- **Cytology** can be obtained to find neoplastic cells. There is no pleocytosis and no change in glucose and chlorine contents in intradural tumors.
- **Xanthochromia** might indicate tumor bleeding so that ependymomas, cavernous angiomas or other vascular malformations are brought into question.

Laboratory findings of CSF are supportive rather than diagnostic in value

## Treatment

### Non-surgical Treatment

Recent developments in chemotherapy and radiotherapy have made it possible to apply these modalities, especially the former for intramedullary gliomas of children and the latter for high-grade gliomas [28]. In the case of hemangioblastomas, endovascular embolization in trained hands can be a good preparation for surgical removal or it can even suffice as a treatment. Further discussion on this topic is, however, beyond the scope of this chapter.

### Surgical Treatment

#### General Principles

The goal is tumor debulking and preserving function

The goal of surgery for any benign intradural neoplasms is gross total resection. The goal for a malignant glioma is debulking with preservation of the function. Recent technological developments such as MRI, ultrasonography, the **Cavitron Ultrasound Aspirator** (CUSA), and microsurgical technique with intraoperative neurophysiological monitoring have brought about a remarkable improvement in surgical results [12, 19].

Perioperative administration of steroids according to the regime for intracranial tumors is now a routine procedure. Administration of a high dosis of Solumedrol (methylprednisolone 30 mg/kg, followed by 5.4 mg/kg/h for 23 h) instead of dexamethasone especially for intramedullary tumors is preferred to prevent spinal shock due to surgical manipulation by some authors and in our department [5, 22].

The **sitting position** is used for tumor removal when tumors are located above the level of T5, and for tumors below this level the prone position is the usual position in our department [40]. The target level should be marked under the fluoroscope prior to surgery.

For tumors associated with hemorrhage-hematoma such as cavernous angiomas and ependymomas, the optimal timing of surgery might be the subacute stage in which the acute stage of edema is declining and hematoma begins to be absorbed, as delineation and dissection of tumors is rather easy without damaging the surrounding neural structures [22]. Noticeable space-occupying hematomas should be removed, however, at the acute stage.

Extension of laminectomies should be one more lamina above and below tumor extension. This enables surgical manipulation to be easy and safe and is also appropriate for decompression. If benign extramedullary tumors or intramedullary ependymomas are found, osteoplastic laminotomy might also be considered to prevent traction damage or kyphosis. Care should be taken at least to maintain the integrity of the facets to preserve spinal stability.

The surgery outcome has been improved with the advent of microsurgical techniques, CUSA and neuromonitoring

**Intraoperative neurophysiological monitoring** with somatosensory evoked potentials (SSEPs) is recommended. A noticeable change in SSEP findings at the time of myelotomy or at the time of suturing the spread myelotomy margins of the pia to the dura and their recovery at the time of closure of the spread myelon is observed. But there is no convincing reliable and useful monitoring system which includes motor evoked potentials at the moment [1, 4, 5, 8, 10, 14, 19, 26, 27].

Knowledge of standard peri- and intraoperative management such as:

- edema prevention
- respiratory management in cervical tumors
- critical interpretation of neurophysiological monitoring

Complete total resection is a realistic goal for intradural tumors

is key to successful surgery.

Respiratory disturbances encountered at the time of removal of high cervical intramedullary tumors should be checked carefully postoperatively and the corresponding timely use of a respirator should be kept in mind. Ondine's curse or sleep apnea are also well known such respiratory complications [14, 22, 26].

**Possible surgical complications** (amongst other complications) include:

- bladder and bowel dysfunction
- bleeding or hematoma
- CSF leak
- infection
- chronic pain
- neurological deterioration
- sexual dysfunction
- spinal instability
- ventilator dependence
- wound dehiscence

Troublesome chronic dysesthetic pain is the most persistent noticeable complaint after a successful removal of intramedullary tumors as shown in our case presentation.

Postoperative neurological complications are less than 15 % in extramedullary tumors

In terms of outcome (Table 1), **postoperative neurological morbidity** in the surgery of extramedullary tumors is usually less than 15 %. Surgical results are usually curative in nerve sheath tumors, while a total recurrence rate of meningiomas is 7 – 15 %. The neurological deterioration in filum terminale ependymomas is more frequent, also the recurrence rate. Postoperative radiotherapy and chemotherapy are often applied in such situations. In Brotchi's series of 239 patients with low-grade intramedullary tumors, 5 % of them worsened, 50 % stabilized and 40 % improved. These figures are in close correspondence with our series as shown in Table 1. Neurological function of a patient after surgical intervention mostly depends on his or her preoperative neurological condition. The **5-year survival rate** for patients with spinal cord neoplasm is **greater than 90 %**. Prognosis depends on the histopathology of the neoplasm [13, 14, 26, 31, 36].

## Surgical Techniques

### Surgical Approach for Intradural Extramedullary Tumors

**Localization** of intradural extramedullary tumors can be classified as:

- posterior
- posterolateral
- lateral
- anterolateral
- anterior

Laminectomy is the standard approach for removal of intradural spinal cord tumors

Although most tumors can be managed by standard laminectomy, the approach can be varied accordingly such as by using:

- hemilaminectomy and complete laminectomy
- costotransversectomy

**Table 1.** Surgical results

| Author | Cases | Follow-up | Complications/outcome/recurrence |
|---|---|---|---|
| Hoshimaru et al. (1999) [18] | 36 spinal cord ependymomas | 56 months | 14 improved<br>5 persistent deterioration<br>17 stabilized |
| Conti et al. (2004) [7] | 179 neurinomas | 5 years | total removal 174<br>excellent recovery 108<br>local recurrence 3 (malignant neurinoma) |
| El-Mahdy et al. (1999) [9] | 66 nerve sheath tumors | | 37 improved<br>3 worsened<br>26 stabilized |
| Kane et al. (1999) [20] | 54 intramedullary tumors | 18 years in 40 patients | 90% independently mobile |
| Schick et al. (2001) [33] | 197 benign spinal tumors | 5 years | recurrence rate: meningiomas 8.6%<br>neurinomas 7.7%<br>ependymomas 20%<br>complications (10%): hematoma 9, hydrocephalus 4, CSF fistula 3, wound infection 2, meningitis 2 |
| Constantini et al. (2000) [6] | 164 intramedullary tumors in children and young adults | 5 years | 60% stabilized<br>15.8% improved<br>23.8% worsened<br>5-year progression-free survival was 78% with low-grade gliomas and 30% with high-grade gliomas |
| Fischer and Brotchi (1996) [14] | 239 patients with low-grade intramedullary tumors | | 5% worsened, 50% stabilized, and 40% improved |
| Author's series (2004, unpublished) | **79 intramedullary tumors:**<br>ependymoma 26 (33%) | Follow-up: 3 months to 11 years | complete removal with good recovery except that one patient died of respiratory insufficiency |
| | astrocytoma 20 (25%) | | complete removal only in 10% but with stabilization over 3 years on average |
| | hemangioblastoma 12 (15%) | | complete removal with good recovery |
| | cavernous angioma 4 (5%) | | complete removal with stabilized residual deficits |
| | anaplastic glioblastoma 4 (5%) | | death within 2.5 years in spite of aggressive therapy including transection of the spinal cord, irradiation, chemotherapy |
| | cauda ependymoma 3 (4%) | | complete removal with good recovery, one recurrence under observation |
| | metastasis 3 (4%) | | |
| | primitive neuroectodermal tumors 3 (4%) | | |
| | others 4 (5%) | | |

- extracavitary approach
- far lateral laminectomy and partial facetectomy
- posterolateral approach through the facet joint and pedicle
- transthoracic approach
- far lateral approach-transcondylar approach for tumors at the cervicomedullary junction
- ventral corpectomy

Neurinomas or neurofibromas can usually be completely excised except for the dumbbell type. Sacrifice of the affected nerve roots is often necessary and should be done with respect to the function of the nerve root (Case Study 1, Fig. 4). Almost all meningiomas can be completely removed, with excision or coagulation of the dural attachment. The recurrence rate following complete resection is

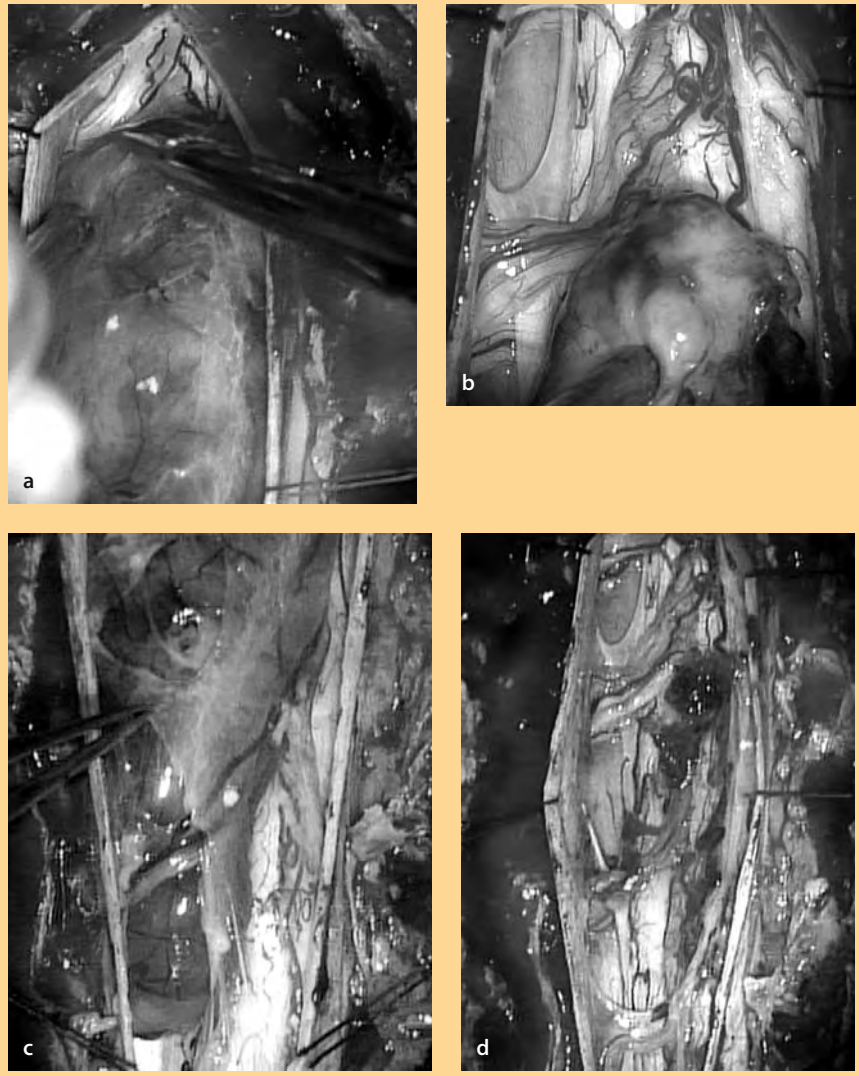


**Figure 4. Surgical treatment of a neurinoma**

Intraoperative views of a neurinoma at the thoracic region (see Case Study 1). a After the dural opening in the midline, dissection of the rostral pole of the tumor is shown. b After intracapsular gutting of the tumor, the spinal cord, the roots and the ligamentum dentatum become visible. c View just at the time of opening of the arachnoidea at the rostral pole of the tumor. One recognizes a dorsal root crossing the tumor on its dorsal surface. d View at the end of the tumor removal. The neurinoma was carefully dissected and removed from the spinal cord preserving the posterior spinal veins. A part of the dorsal root with tumor attachment was removed together with the tumor.

around 7–15%. There is no clear correlation between the results and the extent of resection of the dural attachment. The surgical approach is usually via a laminectomy for midline dorsal tumors. A hemilaminectomy can sometimes be performed in small tumors more laterally located. For tumors in a lateroventral location a lateral approach has to be performed [7, 9, 23–25, 33, 35].

## Intrinsic Spinal Cord Tumor Resection

The surgical approach is mostly via a laminectomy with the patient in the prone position or sitting position. The opening should be large enough to expose the

cranial and caudal poles of solid tumor. Intraoperative ultrasound echography can therefore be helpful for this purpose. After the laminectomy, the dura and the arachnoidea are opened in the midline and the opened dural edge is secured by traction sutures.

Longitudinal posterior median myelotomy through the sulcus medianus is the standard approach for removal of intramedullary tumors

Most intramedullary spinal cord tumors are approached through an incision between the posterior column, i.e., **spreading the sulcus medianus**, which can be difficult but is mostly possible by searching out small emerging veins in the sulcus (Case Study 3). Occasionally (for hemangioblastomas or astrocytomas) the access might be through the dorsal root entry zone. Once the tumor is encountered, spread pial edges are sutured using 6-0 Prolene to the opened edge of the dura on both sides, so that the tumor comes into view more extensively between the spread posterior columns.

The **myelotomy** must expose and open the rostral and caudal cysts or the poles of the solid tumor. A frozen section biopsy is obtained for immediate histopatho-

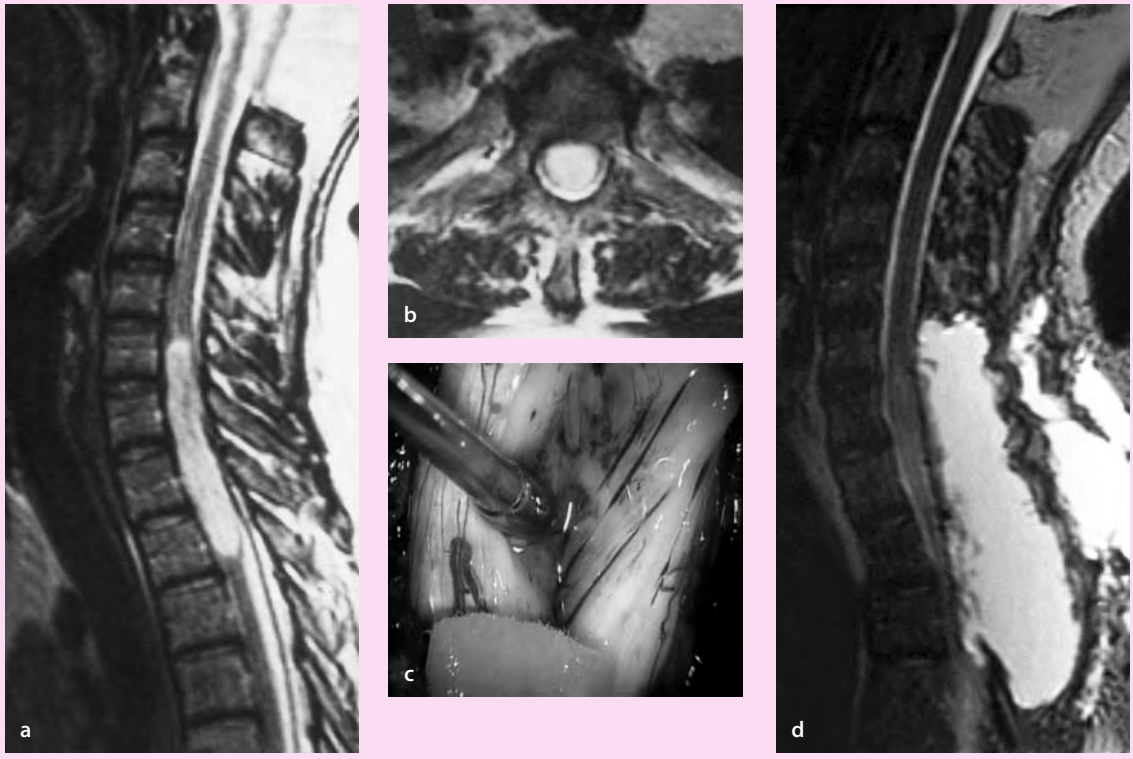


## Case Study 3

This 32-year-old male noticed weakness of the right lower extremity associated with paresthesia at its lateral side, which appeared only episodically. The paresthesia was noticed in the fourth and fifth toes also on the right side since about 6 months previously. Weakness and fine motor skills of the left hand had been noted recently. Neurological findings on admission were: no gait disturbance, difficulty standing on one foot, no noticeable weakness in the extremities except for the right iliopsoas muscle (M4), difficulty walking blind straight, tendon reflex symmetric, no abdominal wall reflex, no Babinski signs, hypesthesia below T2/3 level especially on the lateral side of the right leg, position sense intact, and normal sphincter tonus. Preoperative MRI displayed an intramedullary tumor from the level of C6 to T2 with only slight contrast enhancement and with neither syringomyelia nor cyst formation, presenting as a so-called "stift" or "pencil" glioma (a, b). The patient underwent laminectomy from C5 to T2 followed by partial extirpation of intramedullary pilocytic astrocytoma following a longitudinal myelotomy (c). Demarcation between the tumor and the surrounding tissue was partly not clear so that only about one-third of the tumor was removed and the myelotomy was left open without pial closure. Postoperative neurostatus was almost unchanged, so that the patient was discharged for physiotherapy on the 9th postoperative day.

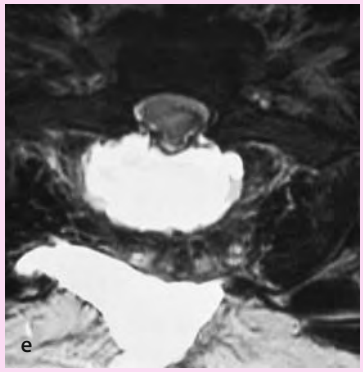

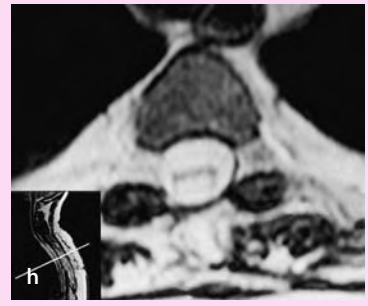


**Case Study 3** (*Cont.*)

The patient was readmitted on the 13th day after the primary surgery due to a pseudomeningocele and neurological deterioration presenting with tetraparesis and respiratory distress. The T2W images revealed a swollen spinal cord at the level of surgery and pseudomeningocele (d, e). At the time of repeat laminectomy 3 weeks after the primary laminectomy, a swollen spinal cord was noticed especially at the level of C7–T1 so that additional laminectomy of T3 was performed followed by further subtotal removal of tumor. The tumor was lateralized to the right side, At the end of tumor removal, the anterolateral part of the spinal cord was paper thin at the level of C7–T1. The myelotomy was left open and a dural patch with fascia lata was performed for decompression, as the spinal cord was still swollen at the level of T2. Postoperatively the patient was unable to walk due to motor paraparesis and also due to loss of position sense. It took him 2 years to be able to walk with a stick and another 2 years without a stick (f). At the time of follow-up 4 years postoperative examination, no bowel or bladder dysfunction was complained of. MRI displayed no tumor but a very thin spinal cord (g, h). Most annoying for him after these all years is the dysesthesia or burning sensation in the left lower extremity and in the left flank which trouble him occasionally.

logical analysis. If a malignant glioma is a possible diagnosis, the information may be crucial in deciding whether tumor removal should be continued, and if so, how aggressive it should be.

**Ependymomas** can be delineated by a red gray color or by a consistency slightly more solid than the spinal cord (Case Introduction, Fig. 5). After having sent a piece of tumor for frozen section, gutting of the tumor is carried out by suction or with low-power CUSA so that several millimeters of tumor "capsule" are left. Blunt dissection of the capsule from the surrounding spinal cord can be done with ease in ependymomas, in which sometimes feeding arteries and draining veins have to be coagulated with low-power currents and cut. This procedure should be done with great care at the most anterior part of the tumor, as the site might be very close to the anterior sulcal artery or even to the anterior spinal artery. Dissection of ependymomas at the cranial pole or caudal pole can be easy in cases where cyst or syrinx is present. Otherwise the tumor tapers into the spinal cord, so that its removal should be performed with great care.

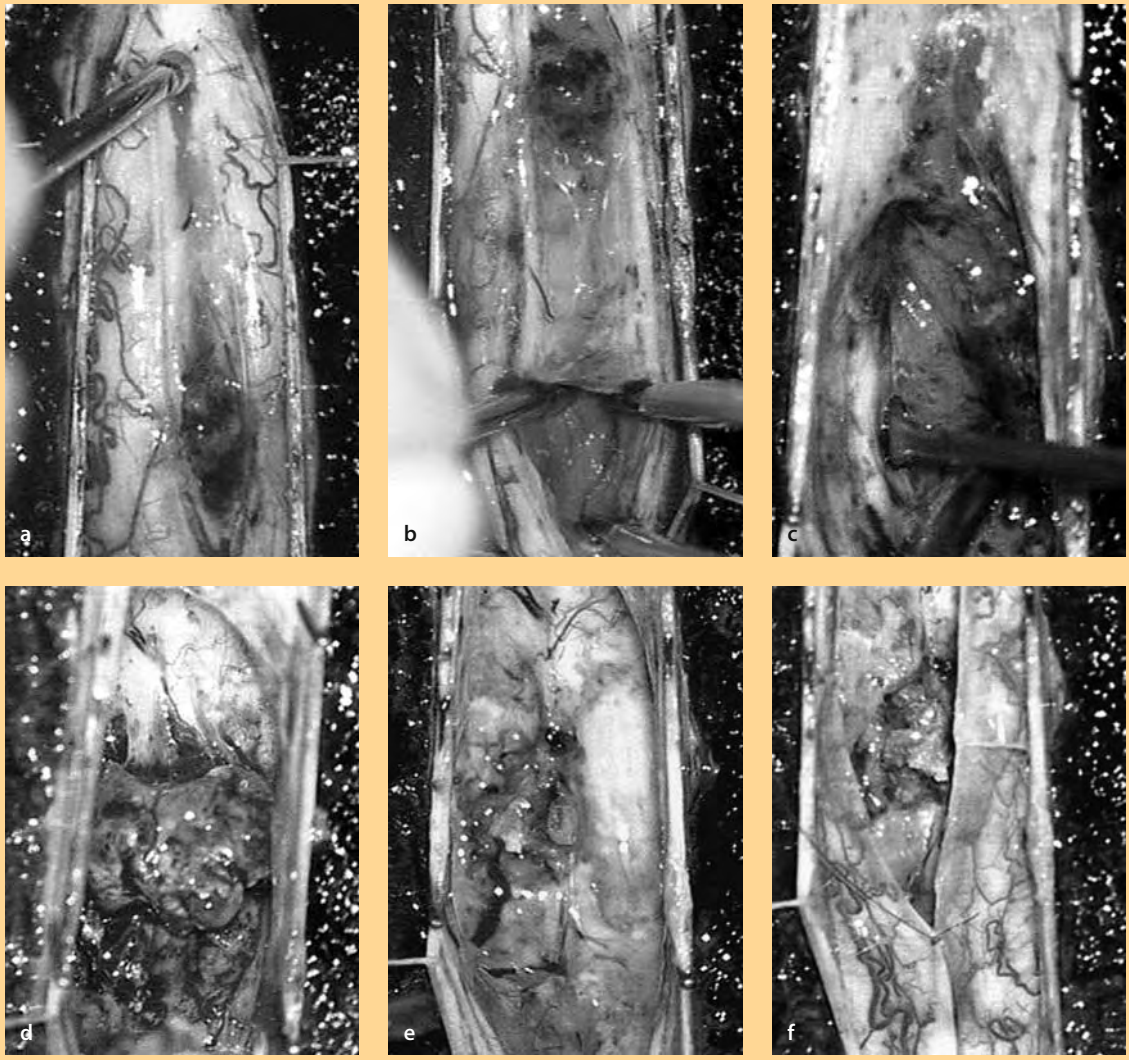


**Figure 5. Surgical treatment of an ependymoma**

A case of an ependymoma of the thoracic spinal cord (see Case Introduction). Intraoperative views: **a** After dural opening followed by a longitudinal myelotomy in the midline, the tumor tissue can be clearly distinguished as pathologic tissue. **b** Dissection of the associated cyst enables identification of the most caudal end of the tumor. **c** Searching out a clear cleavage plane is crucial for successful tumor removal. **d** The clear cleavage plane at the rostral tumor end is visible. **e** The most critical part of the surgical removal of the tumor is its relation to the anterior spinal artery and the branches. **f** Part of the tumor tissue adhered strongly to the anterior spinal artery so that the part with hemostatic sponges is coagulated and left in order to preserve the artery. The spread margin of the pia mater is approximated and closed with continuous sutures prior to watertight dural closure.

After the removal the spread pial ends are closed with 6-0 continuous suture followed by dural closure. The closure of arachnoidea as much as possible to prevent CSF leakage or adhesive arachnoidopathy should be kept in mind at the time of dural closure [22].

In the case of **astrocytoma** which is diagnosed on frozen section at the early stage of tumor removal, part of the dissection might not become possible since the delineation between the tumor and normal tissue is not clear even in the presence of cysts or syrinx, although a considerable part of the tumor is revealed to be well delineated up to that stage. Tumor extirpation should be stopped at this

site to prevent postoperative new neurological deficits. The dangers of tumor extirpation are at the anterior and lateral margins. Anterior resection may cause vascular damage to the anterior spinal artery, and lateral resection may directly damage the corticospinal tracts. Hemostasis is obtained by warm saline irrigation and microfibrillar collagen. It is rarely necessary to coagulate major vessels outside the tumor bed [5, 12–14, 20, 22, 36].

Intramedullary ependymomas have good delineation, while astrocytomas usually do not have an impact on tumor removal

Spread pial edges do not need to be closed by suture to accomplish decompression. Even a dural patch is needed for decompression in the case of spinal cord swelling at the end of partial tumor removal. One additional laminectomy (below and above tumor extension) might be necessary or recommendable for effective decompression.

**Hemangioblastomas** are located usually at the dorsum of the spinal cord, so that this can be detected just after the dural opening. This orange-dark red colored tumor is usually attached to the pia at the margin and is strongly vascularized, so that its gutting is not recommended due to profuse bleeding. This tumor is usually associated with cyst or syrinx formation, so that the delineation is clear and dissection is not difficult. Tumor capsule coagulation and coagulation of feeding arteries followed by their cutting are the method of removal. The main feeding arteries might be branches of the anterior spinal artery or a radicular artery [39].

Pial closure at the end of tumor removal is to be recommended to prevent collapse of the spinal cord [22]. For a large hemangioblastoma, its preoperative embolization by a trained interventional neuroradiologist might reduce intraoperative blood loss and even reduce the extent of the laminectomy levels and of myelotomy.

**Cavernous angiomas** are to be removed in the subacute stage of bleeding. In this subacute stage, detection of cavernous angioma can occasionally be problematic, as one hardly sees any changes on the dorsal surface of the spinal cord such as swelling or discoloration, so that ultrasound echography can be helpful for its detection. With midline access, one encounters the hematoma cavity and the typical cavernous angioma with blackberry-like appearance. Less than 10% of cavernous angiomas are located eccentrically, so that access through the posterior root entry zone is necessary. When the cavernous angioma is located at the conus, a strong posterior longitudinal vein might cover the sulcus medianus, so that its microsurgical dislocation for preservation is recommended by some authors in order to accomplish the midline access [22].

A decompressive laminectomy and duraplasty are the minimal surgical procedure in the surgery of **"inoperable" intramedullary tumors**, since patients with high-grade lesions on biopsy have rapid progression in neurological dysfunction even with aggressive resections.

**Acknowledgements.** The authors are indebted to Mr. P. Roth, Ms. R. Frick and Ms. H. Job for their secretarial and technical assistance.

## Recapitulation

**Epidemiology.** Intradural tumors represent about 10% of primary CNS tumors. About **two-thirds** of these tumors are found in an **extramedullary location**. The incidence of intramedullary tumors is below 1 per 100000. Most extra- and intramedullary tumors are **slow-growing neoplasms** and can be operated on with a low morbidity.

**Etiology and pathogenesis.** There is considerable evidence that some neoplasms are the result of genetic disease. **Genetic systemic diseases** associated with intradural tumors are neurofibromatosis and von Hippel-Lindau disease. There is an enormous functional adaptive capacity of the spinal cord to slow-growing tumor compression.

**Classification.** **Meningiomas** and **nerve sheath tumors** represent 80% of extramedullary tumors and most of them can be surgically removed with a low recurrence rate. The most frequent intramedullary tumors are **ependymomas** and **astrocytomas**. About one-third of patients with **hemangioblastoma**, one of the infrequent intramedullary tumors, have von Hippel-Lindau disease.

**Clinical presentation.** Onset is usually very insidious, but an abrupt onset can take place. **Cardinal symptoms** are progressive **local pain**, **nocturnal pain** of a radicular or medullary nature, **non-painful sensory disturbances**, **motor weakness**, **ataxia** and **sphincter disturbances**. In intramedullary tumors, sensory disturbance tends to be of the dissociated type and motor disturbance may present with the type of Brown-Séquard's syndrome. Sensory disturbance of the sacral segment can be preserved (**sacral sparing**) until a far advanced stage of intramedullary tumors. Scoliosis or torticollis is often observed.

**Diagnostic work-up.** MRI is the diagnostic modality of choice. At least two different imaging planes must be used in order to locate the tumor properly and to differentiate intra- from extramedullary tumors. The tumor is iso- to hypointense on T1W and hyperintense on T2W images. Almost all spinal cord tumors demonstrate more or less contrast enhancement. Existence of a "dural tail" and calcification in meningiomas may differentiate them from neurinomas. Most nerve sheath tumors and ependymomas also demonstrate uniform contrast enhancement but can be inhomogeneous due to intratumoral cyst, hemorrhage or necrosis. Intramedullary tumors are frequently associated with cysts or syringomyelia.

**Operative treatment.** Surgery is indicated in any case of intradural tumor. The goal of surgery for any benign tumor is **gross total resection**. The goal for a non-resectable glioma is debulking with preservation of the function. The approach for microsurgical tumor removal is usually via a laminectomy. **Extramedullary tumors** can basically be **completely removed**. **Intramedullary tumors** are mostly accessed via a dorsal **midline myelotomy**. Tumors such as ependymomas, hemangioblastomas and cavernous angioma with a distinct cleavage plane between tumor and normal spinal cord tissue can be removed totally. An immediate intraoperative biopsy may be crucial in deciding whether tumor removal should be continued, and if so, how aggressive it should be. In non-resectable gliomas a tumor debulking or a decompressive laminectomy and duraplasty are the minimal surgical procedure. Patients with high-grade lesions on biopsy have a rather rapid progression even with aggressive resections.

## Key Articles

**Balériaux D (1999) Spinal cord tumors. Eur Radiol 9:1252–1258**
This paper summarizes the state of the art in MRI diagnostics of intramedullary tumors.

**Jallo GI, Kothbauer KF, Epstein FJ (2001) Intrinsic spinal cord tumor resection. Neurosurgery 49:1124–1128**
This paper shows the present status of preparation of a surgical approach for intramedullary astrocytomas, ependymomas and vascular lesions, including neuromonitoring and video demonstration.

**Brotchi J (2002) Intrinsic spinal cord tumor resection. Neurosurgery 50:1059–63**
This article describes the surgical method of the author developed during a period of 15 years (with Georges Fischer in Lyon) on the basis of experience with more than 260 patients and 300 operations. The authors highlight that the standard treatment is complete resection whenever possible. For gliomas (ependymomas and astrocytomas), the author favors a midline approach; for most vascular tumors (such as hemangioblastomas and cavernomas), however, he prefers to proceed from the point at which the lesion is observed through the microscope and to dissect the lesion in one piece. Meticulous non-bleeding surgery and experience are regarded as the keys to success.

## References


1. Al-Mefty O (1998) Operative atlas of meningiomas. Lippincott-Raven, New York, pp 249 – 382
2. Balériaux D, Brotchi J (1992) Spinal cord tumors: Neuroradiological and surgical considerations. Riv Neuroradiol 5:29 – 41
3. Balériaux D (1999) Spinal cord tumors. Eur Radiol 9:1252 – 1258
4. Birch BD, McCormick PC, Resnick DK (2005) Intradural extramedullary spinal lesions. In: Benzel EC (ed) Spine surgery: Techniques, complication avoidance, and management, 2nd edn. Livingstone, New York, pp 948 – 960
5. Brotchi J (2002) Intrinsic spinal cord tumor resection. Neurosurgery 50:1059 – 1063
6. Constantini S, Miller DC, Allans JC, Rorke LB, Fred D, Epstein FJ (2000) Radical excision of intramedullary spinal cord tumors: surgical morbidity and long-term follow-up evaluation in 164 children and young adults. J Neurosurg (Spine 2) 93:183 – 193
7. Conti P, Pansini G, Mouchaty H, Capuano C, Conti R (2004) Spinal neurinomas: retrospective analysis and long-term outcome of 179 consecutively operated cases and review of the literature. Surg Neurol 61:34 – 43
8. Cooper P, Epstein F (1985) Radical resection of intramedullary spinal tumors in adult. Recent experience in 29 patients. Neurosurgery 63:492 – 499
9. El-Mahdy W, Kane PJ, Powell MP, Crockard HA (1999) Spinal intradural tumours: Part I – extramedullary. Br J Neurosurg 13:550 – 557
10. Elsberg C, Beer E (1911) The operability of intramedullary tumors of the spinal cord. A report of two operations, with remarks upon the extrusion of intraspinal tumors. Am J Med Sci 142:636 – 647
11. Elsberg CA (1925) Tumors of the spinal cord and the symptoms of irritation and compression of the spinal cord and nerve roots. Hoeber, New York, pp 206 – 239
12. Epstein FJ, Farmer JP (1990) Pediatric spinal cord tumor surgery. Neurosurg Clin North Am 1:569 – 590
13. Epstein FJ, Farmer JP, Freed D (1992) Adult intramedullary astrocytomas of the spinal cord. J Neurosurg 77:355 – 359
14. Fischer G, Brotchi J (1996) Intramedullary spinal cord tumors. Thieme, Stuttgart
15. Gowers W, Horsely V (1888) A case of tumour of the spinal cord: removal, recovery. Med Chir Trans 71:377 – 428
16. Greenwood J Jr (1954) Total removal of intramedullary tumors. J Neurosurg 11:616 – 621
17. Guidetti B (1967) Intramedullary tumors of the spinal cord. Acta Neurochir 17:7 – 23
18. Hoshimaru M, Koyama T, Hashimoto N, Kikuchi H (1999) Results of microsurgical treatment for intramedullary spinal cord ependymomas: Analysis of 36 cases. Neurosurgery 44:264 – 269
19. Jallo GI, Kothbauer KF, Epstein FJ (2001) Intrinsic spinal cord tumor resection. Neurosurgery 49:1124 – 1128
20. Kane PJ, El-Mahdy W, Sing A, Powell MP, Crockard HA (1999) Spinal intradural tumours: Part II. Intramedullary. Br J Neurosurg 13:558 – 63
21. Kurze T(1964) Microtechniques in neurological surgery. Clin Neurosurg 11:128 – 137
22. Koyama T, Kikuchi H (2000) Microsurgery of spinal cord and nerve roots, chapter 6. Surgery of spinal cord tumors and intramedullary hemangiomas. Nankodo, Tokyo, pp 198 – 258
23. Levy WJ, Bay J, Dohn DF (1982) Spinal cord meningeoma. J Neurosurg 57:804 – 812
24. Levy WJ, Latchaw J, Hahn JF (1986) Spinal neurofibromas: A report of 66 cases and a comparison with meningiomas. Neurosurgery 18:331 – 334
25. Mautner VF, Tatagiba M, Lindenau M, Funsterer C, Pulst SM, Baser ME, Kluwe L, Zanella FE (1995) Spinal tumors in patients with neurofibromatosis type 2: MRI imaging study of frequency, multiplicity, and variety. AJR 165(4):951 – 955
26. McCormick PC, Anson JA (2005) Intramedullary spinal cord lesions. In: Benzel EC (ed) Spine surgery: Techniques, complication avoidance, and management, 2nd edn. Livingstone, New York, pp 939 – 947
27. McCormick PC, Stein BM (1996) Spinal cord tumors in adults. In: Youmans JR (ed) Neurological surgery, 4th edn. Saunders, Philadelphia, pp 3102 – 3122
28. Nishio S, Morioka T, Fujii K, Inamura T, Fukui M (2000) Spinal cord gliomas: management and outcome with reference to adjuvant therapy. J Clin Neurosci 7:20 – 23
29. Nittner K (1972) Raumbengende Prozesse im Spinalkanal (einschliesslich Angiome und Parasiten) – Stadien der Rückenmarkskompression. In: Olivecrona H, Tönnis W, Krenkel W (eds) Handbuch der Neurochirurgie, vol VII 2. Springer, Berlin, pp 186 – 197
30. Norstrom CW, Kernohan JW, Love G (1961) One hundred primary caudal tumors. JAMA 178:1071 – 1077
31. Osborn AG (1994) Diagnostic neuroradiology, Chap 21: Tumors, cysts, and tumorlike lesions of the spine and spinal cord. Mosby, Boston, pp 876 – 918
32. Samii M, Klekamp J (1994) Surgical results of 100 intramedullary tumors in relation to accompanying syringomyelia. Neurosurgery 35:865 – 73

33. Schick U, Marquardt G, Lorenz R (2001) Recurrence of benign spinal neoplasms. Neurosurg Rev 24:20 – 25
34. Schweitzer JS, Batzdorf U (1992) Ependymoma of the cauda equina region: diagnosis, treatment and outcome in 15 patients. Neurosurgery 30:202 – 207
35. Solero CL, Fornari M, Giombini S, Lasio G, Oliveri G, Cimino C, Pluchino F (1989) Spinal meningiomas: Review of 174 operated cases. Neurosurgery 25:153 – 160
36. Stein BM (1990) Surgery of intramedullary lesions and escapable pitfalls. In: deVilliers JC (ed) Some pitfalls and problems in neurosurgery. Karger, Basel, pp 131 – 153
37. Strommer KN, Brandner S, Sarioglu AC, Sure U, Yonekawa Y (1995) Symptomatic cerebellar metastasis and late local recurrence of a cauda equina paraganglioma. Case report. J Neurosurg 83:166 – 169
38. Thakkar SD, Feigen U, Mautner VF (1999) Spinal tumors in neurofibromatosis type 1: An MRI study of frequency, multiplicity and variety. Neuroradiology 41:625 – 629
39. Yasargil MG, Antic J, Laciga R, de Preux J, Fideler RW, Boone SC (1976) The microsurgical removal of intramedullary spinal hemangioblastomas: Report of twelve cases and a review of the literature. Surg Neurol 6:141 – 148
40. Yonekawa Y, Khan N, Yoshimura K, Yoshimura S, Imhof HG, Roth P (2003) Posterior fossa tumors – surgical strategies and tactics. In: Sakai N (ed) Brain tumor surgery. Management strategies and Navigator/Neuroendoscope. Med Pub, Osaka, pp 2 – 14

# 36 Infections of the Spine

Norbert Boos

## Core Messages

- ✔ Spinal infections remain a potentially life-threatening disease
- ✔ Diagnosis is very often delayed
- ✔ MRI is the imaging modality of choice in spinal infections
- ✔ In the absence of neurologic deficit, spinal deformity and instability or incapacitating pain not responsive to pain medication, spinal infections are treated by chemotherapy
- ✔ Radical debridement and bone grafting accelerates healing of the infection
- ✔ Spinal instrumentation does not prevent healing of the spinal infection. Instead, the additional stability promotes clinical resolution of the infection and related symptoms

## Epidemiology

Although evidence for spinal infections in humans can be found in the *Edwin Smith Surgical Papyrus* [6], an ancient Egyptian medical document written about 2000 B.C., Sir Percival Pott is credited with the first description of spinal tuberculosis in 1779 [37]. In 1897, Lannelongue was the first to describe a pyogenic infection of the spine [27]. At the end of the nineteenth century, Makins and Abbot reported mortality rates in children and young adults of as high as 70% [31].

Based on the results of a Swedish and a Danish study, the **incidence** of vertebral osteomyelitis was 0.5 and 2.2/100000 inhabitants/year, respectively [4, 26]. In particular, if a spinal epidural abscess is present, the morbidity and mortality remain high [9, 22, 29, 40]. Spinal infections today occur predominantly in the elderly [44]. In young adults, the disease appears to have increased in recent decades because of immunodeficiency syndromes and intravenous drug abuse [24]. While in Western industrialized societies spinal tuberculosis has become rare, the incidence seems to be increasing again because of immigrants, extensive tourism into Third World countries, and HIV infections [1, 5, 20, 36, 38].

Spinal infections occur predominantly in the elderly and immunocompromised patient

Despite the fact that treatment of spinal infections has been improved dramatically by the **advent of chemotherapy** and sophisticated surgical techniques for advanced stages, this medical condition remains a potentially life-threatening disease. Today, this fact is sometimes neglected in an era of very powerful antibiotics. Early diagnosis and aggressive conservative or surgical treatment remain mandatory for a satisfactory outcome.

Spinal infections remain a potentially life-threatening disease

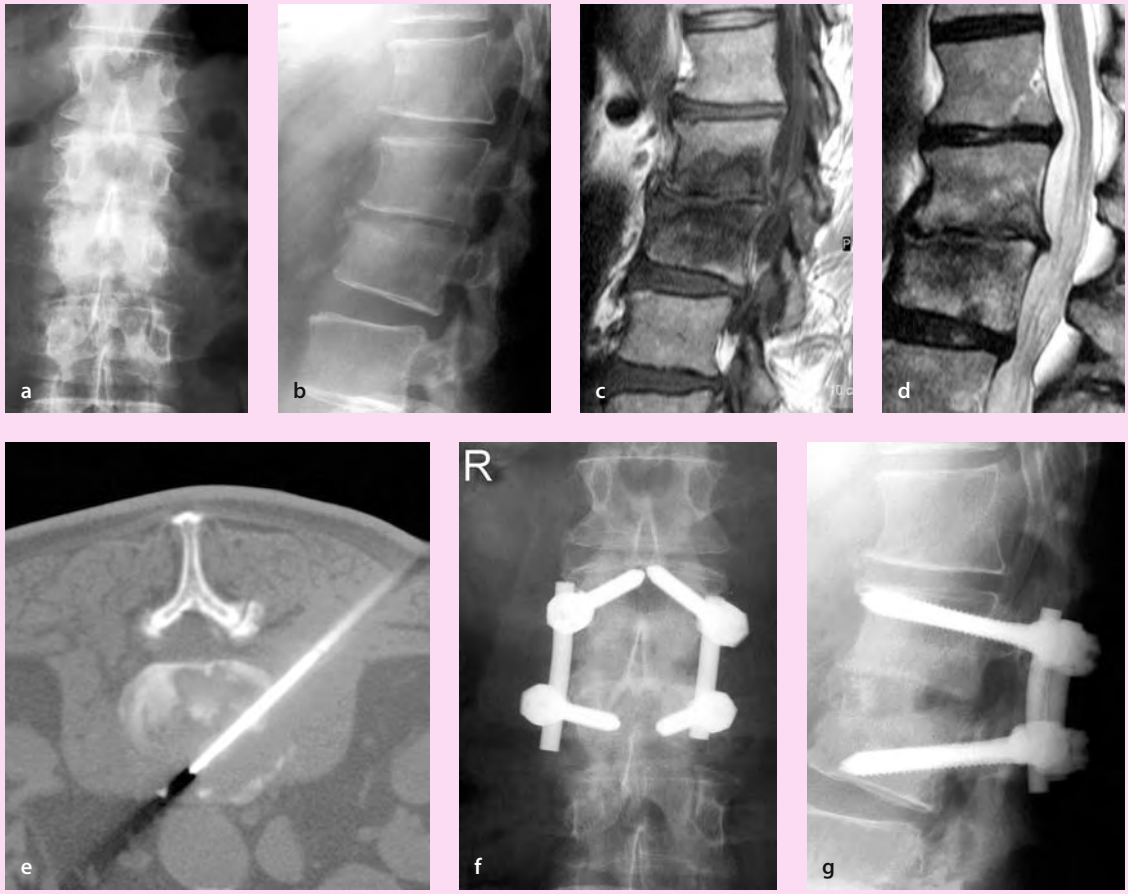


## Case Introduction

A 70-year-old patient presented with increasing low-back pain that was worse with movement. Initial therapy consisted of analgesics and physiotherapy. The clinical history of the patient was otherwise normal. There was no evidence of a general illness and no clinical signs of infection. Despite intensive non-operative treatment, 3 months after onset of symptoms, the patient continued to have back pain, now radiating into the legs and worse during the night. Walking became difficult because of general weakness. Standard radiographs were taken showing a collapsed disc space at the level of L2/3 with segmental kyphosis (a, b). The key finding was a blurred endplate indicating putative spinal infections. Subsequent MRI demonstrated classical signs of spinal infection with decreased signal intensity of the endplates on T1-weighted images (c) and partial signal increase on T2-weighted images (d). Blood samples revealed an elevated blood sedimentation rate and C-reactive protein without any leukocytosis. The patient was treated with a broad spectrum of antibiotics for 2 months. Despite antibiotic treatment the patient continued to have severe pain with movement and during the night. At referral, the patient was in poor general health. In a first diagnostic approach, CT-guided biopsy was performed, but remained negative (e). Surgery was indicated because of deteriorating general health, incapacitating back pain, and inability to ambulate because of pain. In the first stage, pedicle screws were inserted in the spine from the back at L2 and 3. The kyphotic deformity was corrected using indirect reduction (see Fig. 6). In a second stage during the same operation, the spine was approached by a left-sided lumbotomy. Radical debridement was carried out with reconstruction of the anterior spinal column using a tricortical bone graft and additional cancellous bone graft. No causative organism could be isolated most likely due to the previous, antibiotic treatment. Double chemotherapy was administered postoperatively for 3 months. The patient completely recovered from the spinal infection and became completely asymptomatic at 4 months follow-up. The follow-up radiographs demonstrate an anatomic monosegmental reconstruction of the anterior column with solid interbody fusion (f, g).

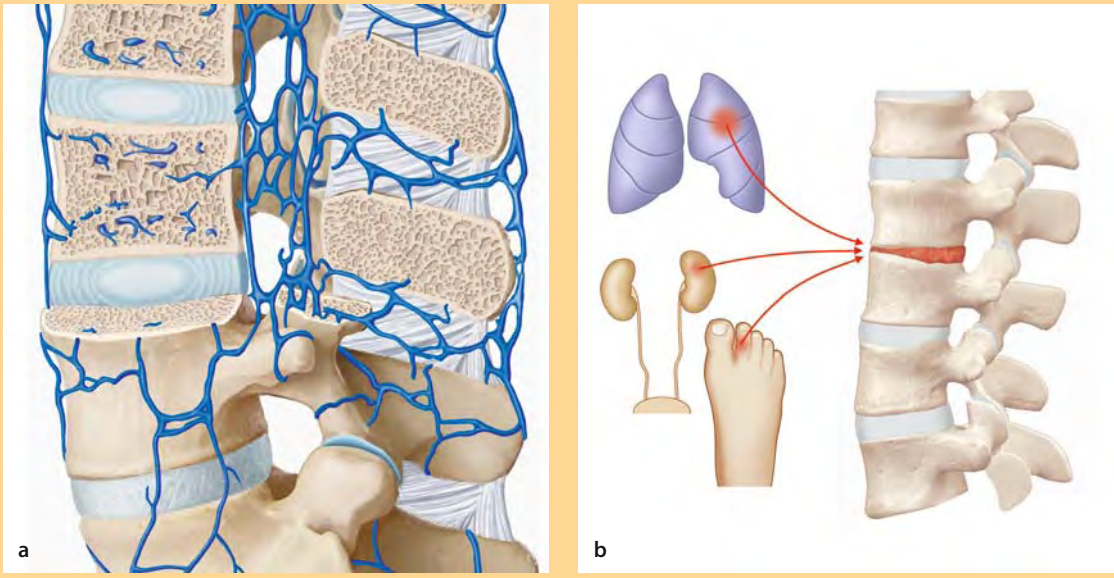


**Figure 1. Pathomechanism of spinal infections**

a The richly vascularized vertebral bodies with their valveless venous plexus (Batson) predispose to infection in this anatomic region. b Hematogenous seeding from peripheral ulcers, genitourinary infection, or pulmonary infection can result in an outbreak of the infection close to the vertebral endplates and affect the intervertebral disc.

## Pathogenesis

Spinal infections are assumed to start from the disc space in children, in whom the intervertebral disc is still vascularized. In contrast, the disease appears to start from the vertebral endplates in adults. However, this strict distinction has recently been questioned by Ring et al. [41], who consider it more a continuous disease. The **blood supply** to the **vertebral bodies** and intervertebral disc remains a **key issue** in the predilection of spinal infections. The most frequent pathomechanism is a hematogenous spread of microorganisms via the blood vessels, resulting from urogenital, pulmonary, or diabetic foot infections (Fig. 1). Batson [2] assumed that the **valveless venous plexus** and the slow blood flow within predisposes to spinal infections of the vertebral body. Wiley and Trueta [50] have provided evidence from injection studies that the arterial route is of significant relevance. Today it is assumed that both mechanisms play a role. With the increased frequency of spinal interventions, direct inoculation of microorganisms has become an additional relevant pathomechanism [3, 4, 10].

The richly vascularized vertebral bodies predispose to spinal infections

## Classification

Spinal infections can be classified according to the **causative organism**. Classically, we differentiated between specific and so-called non-specific infections. Today, it is more appropriate to differentiate tuberculosis from pyogenic (e.g., *Staphylococcus, Streptococcus, E. coli*), fungal (e.g., *Aspergillus, Cryptococcus neoformans*), parasitic (e.g., *Echinococcus*) and postoperative infections.

**Table 1.** Classifcation of spinal infections

| Causative organism | Spatial location |
|---|---|
| • pyogenic infections<br>• tuberculosis<br>• parasitic infections<br>• fungal infections | • vertebrae (spondylitis)<br>• intervertebral disc (discitis)<br>• epidural abscess<br>• paravertebral abscess |

A different approach is to classify the spinal infection according to the anatomic region within the spine, i.e., anterior spine, spinal canal, or posterior spine. More reasonable is differentiation with regard to the involvement of specific compartments, i.e., vertebral body, intervertebral disc, epidural, intradural or paravertebral (e.g., psoas muscle, retropharyngeal) extension (Table 1).

## Clinical Presentation

### History

Diagnosis of spinal infection is often delayed

The **key feature** of the history is the **delayed diagnosis** (Case Introduction). In an extensive literature review, Sapico and Montgomerie [43] found that only 20 % of patients had a symptom duration of less than 3 weeks, 20 % had complaints for 3 weeks to 3 months, and the remaining 50 % of individuals had symptoms for more than 3 months prior to diagnosis. The clinical presentation is related to the virulence of the organism, immunocompetence of the host, and duration of the infection. In this setting, **Louis Pasteur's maxim**, "*The organism is nothing, the environment is everything*," has to be kept in mind. In general, the history of patients with spinal infections is highly variable and non-specific.

Clinical presentation is dependent on virulence, host immunocompetence and duration

The **cardinal symptoms** are:

- slowly progressive, continuous, and localized back pain
- pain exacerbation during rest and at night
- back pain and gibbus (in spinal tuberculosis)

Additional but **less frequent findings** may be:

- muscle spasm (e.g., torticollis)
- weight loss
- "feeling sick"
- pain exacerbation with movement and weight bearing (as signs of instability)
- pain in the loin, groin, or buttocks (due to an abscess)
- symptoms of radiculopathy and myelopathy (late)

Search for predisposing factors

Although the source of infection remains unidentified in more than one-third of cases [43], **predisposing factors** should be specifically sought:

- diabetes mellitus
- intravenous drug abuser
- immune deficiency states
- preexisting paraplegia
- dental granuloma
- soft tissue ulcers
- urinary tract infections
- previous septic conditions

Cardinal symptoms in children and adults are similar

In **children**, spinal infections **most frequently occur in the first decade of life**. The mean age at presentation appears to be lower in children with discitis

compared to vertebral osteomyelitis (2.8 vs 7.5 years of age) [15]. The presentation of similar spinal infection in children can differ from that in adults, while the cardinal symptoms remain very similar, i.e., slowly progressing symptoms with a general aspect of appearing ill. Frequent findings in children are [15, 16, 49]:

- refusal to walk
- back pain and abdominal pain
- "appearing ill"
- fever (in cases of vertebral osteomyelitis)

### Physical Findings

Physical findings are non-specific

Although clinical examination is seldom helpful in making the diagnosis, the most frequent findings are:

- local tenderness (less specific)
- positive psoas sign
- pain provocation by flexion, rotation, and percussion
- limping (in children)

Triad of Pott: gibbus, spinal abscess, paraparesis

A thorough **neurological examination is mandatory** to diagnose neural compression syndromes, in particular to rule out early para/tetraparesis.

The **classic clinical presentation of spinal tuberculosis** includes back pain and a gibbus and in later stages symptoms caused by an epidural abscess and developing neurologic deficits [23]. In Western industrialized countries, patients today present with less specific symptoms and often have an underlying general illness (e.g., HIV, diabetes). The prevailing symptoms in a study by Fam and Rubenstein were back pain and weight loss [13].

## Diagnostic Work-up

Key to diagnosis is "consider it"

The most important aspect of diagnosing spinal infection is to include this diagnosis in the differential diagnosis. The diagnostic work-up is apparently clear when spinal infection is considered as a cause of the patient's symptoms and consists of laboratory investigations, imaging studies, and biopsy.

### Laboratory Investigations

BSR, CRP and WBC are frequently elevated

The most helpful laboratory investigations are:

- elevated blood sedimentation rate (BSR)
- C-reactive protein (CRP)
- white blood cell count (WBC)

Infection parameters are sensitive but not specific

These inflammation markers are sensitive but non-specific and are more helpful in terms of the temporal course rather than as absolute (single) values. The parameters can reliably be used to monitor treatment response. The white blood cell count is only elevated in about half of the patients and depends on the nutritional state of the patient. The determination of antibody titers for putative bacteria is valuable in identifying certain causative organisms.

In the presence of a septic state, blood cultures should be obtained, but the hit rate is low. It can be increased if more than one blood sample (three to five recommended) is taken from different veins.

In putative tuberculosis, the Mantoux or tuberculin skin test is helpful to investigate present or past exposure to *Mycobacterium tuberculosis*. Direct evi-

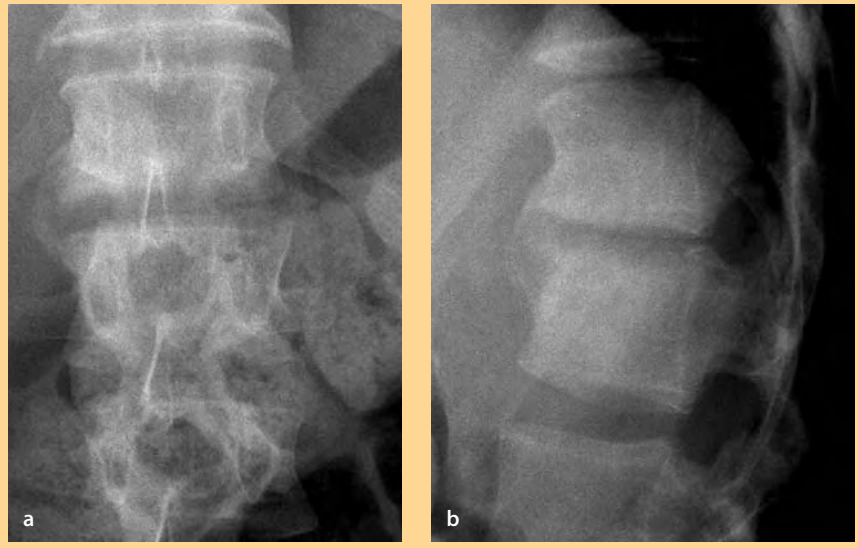


**Figure 2. Radiographic findings in spinal infection**

The classical radiographic signs of spinal infection consist of a loss of vertebral endplate definition, b decrease of disc height, gradual development of osteolysis, development of a paravertebral soft tissue mass, and reactive changes with sclerosis.

dence can seldom be obtained from examination of material aspirated from an abscess.

## Imaging Studies

Modern imaging modalities have substantially improved accuracy in diagnosing spinal infection. However, standard radiographs are still very helpful because they allow an overview of the osseous destruction and resulting deformity.

### Standard Radiographs

Radiographic diagnosis is hampered by a delay in the appearance of alterations

The major drawback of standard radiography is the delay in the appearance of radiographic signs (Fig. 2). The **sequence of changes** demonstrable on radiographs is [48]:

- loss of vertebral endplate definition (at earliest 10–14 days after onset)
- reduction of disc height
- gradual development of endplate osteolysis
- development of a paravertebral soft tissue mass
- reactive changes with sclerosis and new bone formation (at earliest 4–6 weeks after onset)
- vertebral collapse (late) with spinal deformity (kyphosis/scoliosis)

### Magnetic Resonance Imaging

MRI is the imaging study of choice

Today MRI has become the imaging modality of choice in diagnosing spinal infection. Recent comparisons with bone scans have demonstrated that MRI is as accurate and sensitive [48].

**Characteristic findings** (Fig. 3) suggestive of spinal infections are [11]:

- decreased vertebral endplate signal intensity on T1-weighted images (95%)

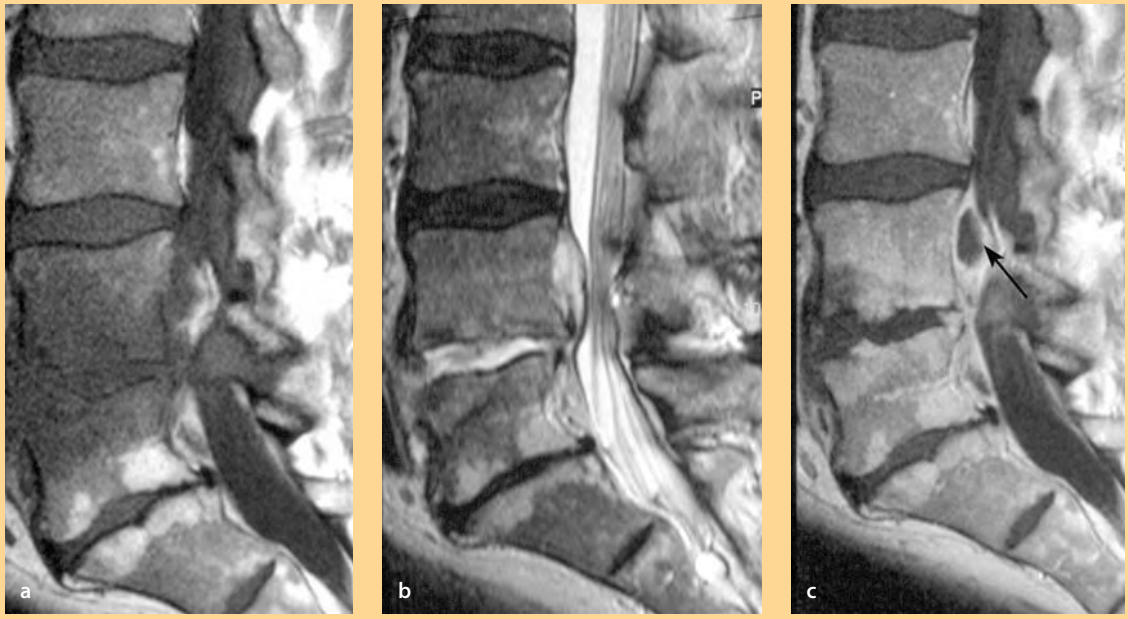


**Figure 3. MRI characteristics of spinal infections**

a The predominant features of spinal infections are decreased vertebral body signal intensity on T1-weighted images, b loss of endplate definition and increased disc signal on T2-weighted images, increased vertebral body signal intensity on T2-weighted images and increased signal intensity on T1-weighted fat-suppressed images after injection of gadopentetate. c Note the retrovertebral epidural spinal abscess *(arrow)*.

- loss of endplate definition (95 %)
- increased disc signal on T2-weighted images (95 %)
- increased vertebral endplate signal intensity on T2-weighted images (56 %)
- contrast enhancement of the disc and vertebral body (94 %)

The increased signal intensity is more obvious on short tau inversion recovery (STIR) or frequency-selective fat-suppressed T2-weighted spin echo sequence, but with the depiction of less anatomical detail [11].

In appropriate cases, the diagnosis of spinal tuberculosis (Fig. 4) can be made by MRI with high diagnostic accuracy [46]. Loke et al. [28] have reported that the most common site is the lumbar spine, often with involvement of more than one vertebra. **Contrast enhancement** is helpful in differentiating spinal tuberculosis from other granulomatous infections [46]. **Frequent findings** [28] suggestive of **spinal tuberculosis** are:

Contrast enhancement is helpful in differentiating spinal TB from other granulomatous infections

- paraspinal soft-tissue masses (73 %)
- vertebral destruction and collapse (73 %)
- epidural abscess (53 %)
- posterior element involvement (40 %)
- intraosseous abscess (20 %) with contrast enhancement

## Computed Tomography

The predominance of computed tomography in diagnosing spinal infections has been surpassed by MRI because of its spatial resolution, multiplanar capabilities and tissue contrast. However, CT still has a role with regard to the assessment of the osseous destruction, which is important for the choice of treatment (i.e., non-oper-

CT demonstrates bony destruction better than MRI

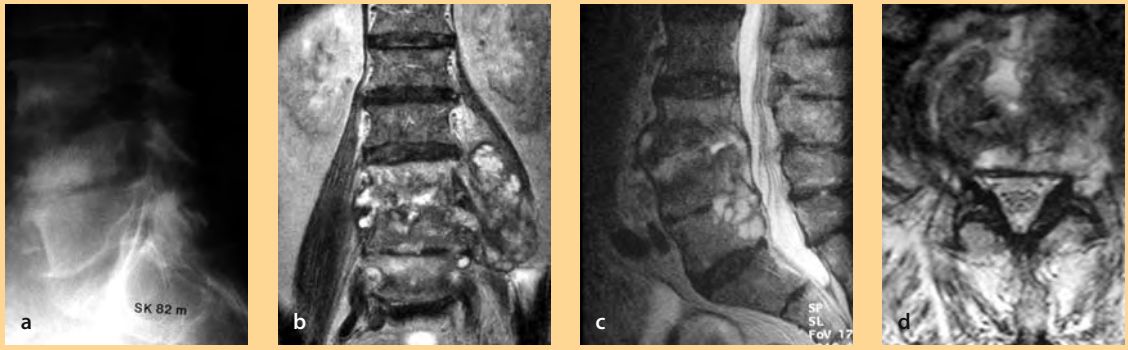


**Figure 4. Radiographic features of spinal tuberculosis**

Spinal tuberculosis can be diagnosed with satisfactory accuracy using standard radiographs and MRI. The key findings include paraspinal soft-tissue masses, vertebral destruction and collapse, epidural abscess, posterior element involvement, and intraosseous abscess.

ative vs surgical) and planning of the surgical approach and technique. It is also invaluable in patients unsuitable for an MRI scan (e.g., because of a pacemaker).

### Radionuclide Studies

Bone scan and FDG-PET are helpful in making the diagnosis

Because of the comparable diagnostic accuracy of MRI, technetium-99m labeled methylene-diphosphonate (Tc-99m MDP) bone scintigraphy is today more infrequently used in the diagnosis of spinal infections. However, an indication for a bone scan is still the search for a focus lesion, e.g., dental granuloma and osteomyelitis.

Confusion may arise with regard to the differential diagnosis of a degenerative endplate abnormality and spinal infections. Positron emission tomography (PET) with fluorine-18 fluorodeoxyglucose (FDG) (Fig. 5) has been used in suspected spinal infection [45]. In a recent study, FDG-PET has been shown to be helpful in differentiating spinal infection from disc degeneration because the latter condition generally does not show FDG uptake [47].

## Biopsy

Biopsy is a "must" prior to treatment

The isolation of the causative organism is of utmost importance and must be attempted in every case. While a biopsy can be performed under image intensifier control, **CT guidance** [7, 34, 39] is preferable because of the accurate spatial resolution, which is important to document that the biopsy was actually taken from within the lesion. This is particularly valid in areas that are difficult to access, such as the sacrum or sacroiliac joints and upper thoracic or cervical region [48].

**Percutaneous needle biopsy** provides a definitive diagnosis ranging from 57 % to 92 % [7, 34, 39] and depends on previous antibiotic treatment.

The most frequently found **organisms** are:

- *Staphylococcus aureus* (30 – 55 %)
- gram-negative organisms (*e.g., E. coli, Salmonella, Enterococcus, Proteus*)
- *Pseudomonas aeruginosa* (in 65 % of drug abusers)
- *Streptococcus viridans*, epidermatitis
- *Proprionibacterium acnes*

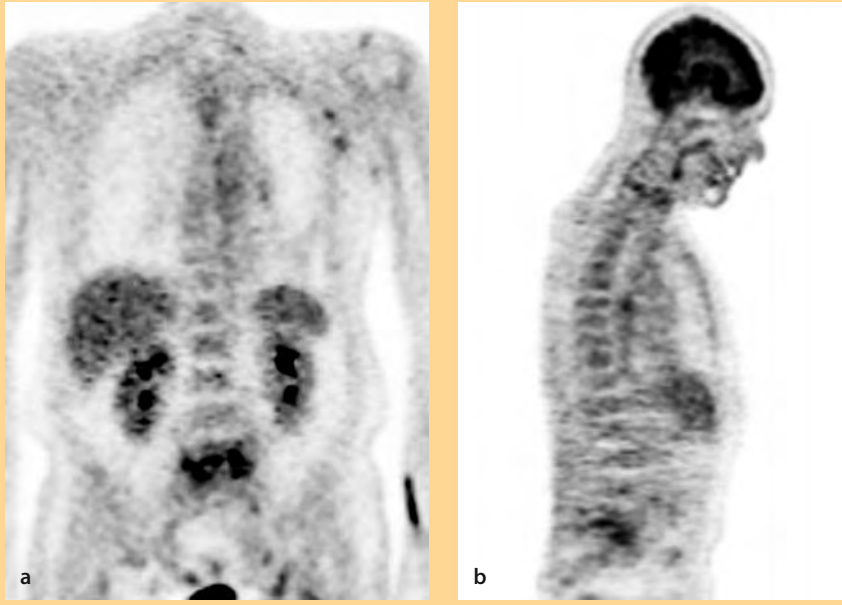


**Figure 5. Radionuclide study of spinal infection**

Positron emission tomography with FDG demonstrates uptake at the level of L4/5 (same patient as in Fig. 3), strongly indicative of spinal infection.

Differentiation of tuberculosis from tumor may sometimes be difficult and a culture takes considerable time. In the clinical situation it is not possible to await the results from the culture and the diagnosis has to rely on the imaging findings.

Tuberculosis can mimic tumor

## Non-operative Treatment

In the absence of a life-threatening condition, treatment of spinal infections should not be started without vigorous attempts to isolate the causative organism. It is mandatory to obtain the causative organism prior to antibiotic treatment because of the substantially reduced likelihood of a secondary diagnosis (Case Introduction). In the absence of a causative organism and progressing infection despite (non-specific) antibiotic treatment, high-dose broad-spectrum double or triple drug chemotherapy is often required. However, subsequent severe pharmacological side effects may limit the use of high-dose antibiotics and may result in a life-threatening situation if the infection is not controlled. This holds true for conservative as well as surgical treatment.

Do not start treatment prior to isolation of the causative organism (if possible)

**Table 2.** General objectives of treatment

| | |
|---|---|
| • eradicate the infection | • prevent or reverse a neurologic deficit |
| • prevent recurrence | • restore spinal stability |
| • relieve pain | • correct spinal deformity |

The **choice of treatment** is related to the chances of achieving the general objectives of treatment with the respective therapy (Table 2). While radical debridement, internal fixation, and appropriate antibiotic treatment have become the gold standard in the treatment of osteomyelitis of long bones, the mainstay for

Non-operative therapy is still the gold standard for uncomplicated cases

**Table 3.** Favorable indications for non-operative treatment

- single disc space infection (discitis)
- known causative organism
- absence of gross bony destruction and instability
- mobile patients with only moderate pain
- absence of relevant neurologic deficit
- rapid normalization of inflammation parameters

the treatment of spinal infection is still non-operative (Table 3). However, the trend in the literature is to support more aggressive treatment of spinal infections even in situations where non-operative treatment can be successful. This trend is because of a shorter hospitalization and recovery time.

The mainstay of treatment is chemotherapy

The **mainstay for the treatment** of bacterial and parasitic infection is still rest and intravenous antibiotics for a minimum of 4–6 weeks, depending on the extent of the infection and organism (Case Study 1). As outlined above, specific chemotherapy is mandatory. Depending on the resistance of the organism and the bone penetration of the respective antibiotic drug, administration by the oral route may be appropriate for the post-primary treatment. We strongly recommend that the antibiotic treatment be discussed with an infection specialist to

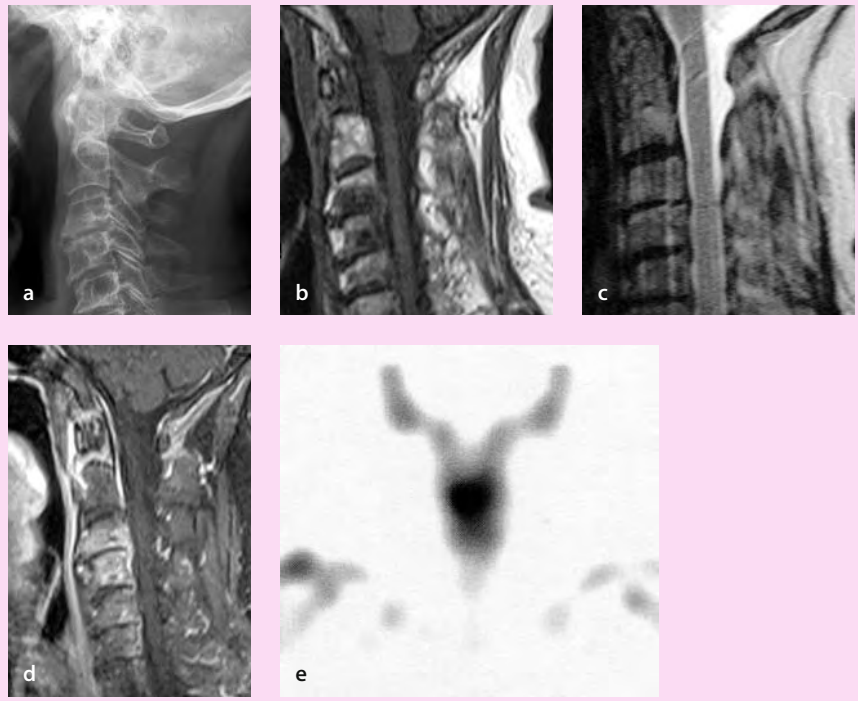


## Case Study 1

A 70-year-old woman presented with an infected great toe and was treated with antibiotics for 3 weeks after a biopsy was taken. The biopsy revealed *Proteus mirabilis* and *Pseudomonas aeruginosa* as the responsible germs. Two months later the patient developed severe neck pain, which became worse with movement. There were no radicular symptoms or neurologic deficits. The radiographic evaluation of the cervical spine demonstrated blurred endplates and somewhat narrowed disc space (a). The MRI showed strong evidence of a spinal infection at the level of C3/4 (b, c). Note the contrast enhancement from C2 to C5 (d). There was no epidural abscess or spinal cord compromise. A CT-guided needle biopsy did not reveal a positive result, but allowed the exclusion of a tumor. This case exemplifies the notion that detection of a germ after previous antibiotic treatment is unlikely. Bone scintigraphy provided further evidence of an infection (e). The patient was treated with double chemotherapy and a hard collar. In the absence of a neurologic deficit, severe pain or substantial deformity, non-operative treatment was successful. The patient recovered completely from her symptoms within 2 months.

allow for the most specific (narrow) drug therapy with the least chances of pharmacological side effects.

According to Pertuiset et al. [35], there appears to be a consensus that the initial antituberculous treatment should consist of a triple (isoniazid, rifampin, and pyrazinamide) or quadruple chemotherapy (plus ethambutol) given for 2–3 months. After this period, chemotherapy should be continued with isoniazid and rifampin in the absence of resistance or side effects. There is still debate on the **optimal duration** of antituberculous chemotherapy required for complete recovery. While a minimum of 12 months is favored by the majority of experts, no convincing evidence can be derived from the literature [35].

Early ambulation is attempted

While bedrest may be indicated for the initial treatment, early mobilization of the patient with an orthosis is recommended. The need for cast immobilization, including neck or thigh extension, has to be determined on an individual basis and depends on the location of the infection, general condition, and age of the patient.

CRP is helpful in monitoring healing of infection

It is imperative to monitor the treatment success by regular determination of the inflammation parameters (i.e., SR, CRP, and WBC). Follow-up imaging studies should be done in the case of persistent symptoms and in the absence of decreasing inflammation parameters. In general, antibiotic treatment should be continued for at least 4–6 weeks because of a high recurrence rate in pyogenic spinal infections. Antibiotic treatment should only be ceased after normalization of the CRP.

Indication for a change from non-operative to operative treatment is the persistence of the infection despite adequate antibiotic treatment or in the presence of pharmacological side effects (e.g., kidney or liver dysfunction) limiting the further use of specific antibiotics in adequate dosage. A recent study has demonstrated a favorable outcome by surgical treatment in this situation [8].

## Operative Treatment

### General Principles

Although the majority of cases with spinal infections can be successfully treated non-operatively, surgery may become **necessary in about one-third** of the patients (Table 4):

**Table 4.** Indications for surgery

- disease progression despite adequate antibiotic treatment
- progressive spinal deformity and instability
- neurological compromise
- incapacitating pain

Increasing evidence is presented in the literature [32] that radical debridement and bone grafting of specific (TB) spinal infections are superior to non-operative treatment [30, 33]. Less information is available from the literature with regard to the treatment of pyogenic infections. On the other hand, no evidence is presented that the spinal infection responds differently to radical debridement and bone grafting than to long bone osteomyelitis. No reports indicate that this approach is ill-advised in cases where conservative treatment does not result in rapid resolution of the infection and recovery of the patient.

### Surgical Techniques

The surgical approach is largely dependent on the extent and location of the infection, spinal destruction, neurologic deficits, health status, and comorbidity of the patient (Fig. 6).

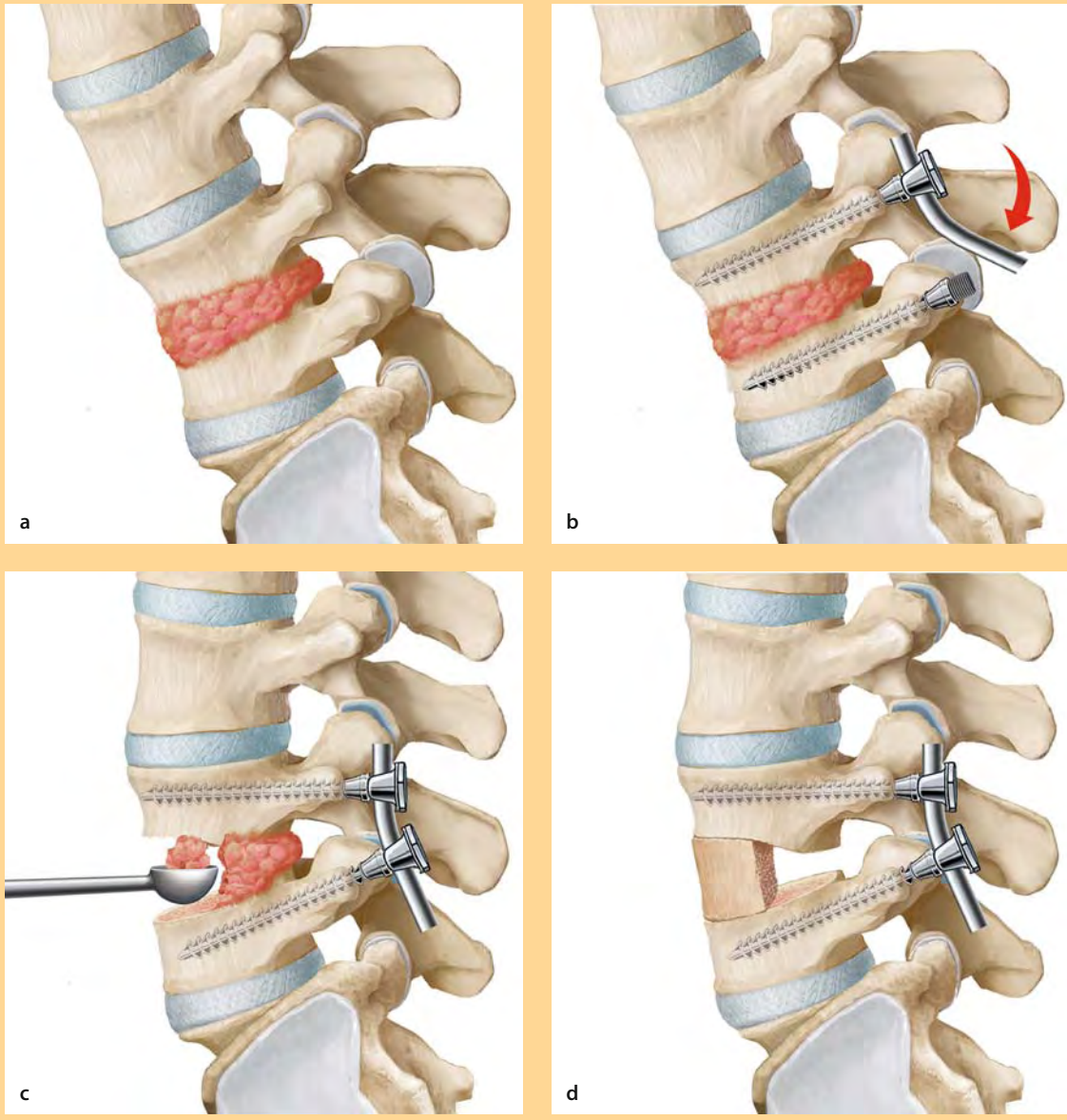


**Figure 6. Surgical treatment of spinal infections**

The key to the treatment of spinal infections is radical debridement of the infected spine. a Often spinal infections are associated with disc space collapse, instability, and kyphotic deformity. In cases of thoracolumbar spondylodiscitis, an accepted standard for the treatment of spinal infection today is posterior instrumentation, followed by anterior radical debridement. In a first step, the spine is exposed by a posterior approach. Pedicle screws are inserted in the vertebrae adjacent to the infection. If a kyphotic deformity is present, a lordic prebent rod is first inserted and connected to the distal screws. b By levering the rod into the distal screws, the deformity is corrected. c In a second stage, the spine is approached anteriorly. With curets and pituitary forceps, the infected area is debrided to the bleeding bone. The intervertebral disc is resected as completely as possible. d The anterior column is reconstructed with a tricortical iliac bone graft and additional circumferential cancellous bone.

### Percutaneous Debridement and Drainage

In discitis with suspicion of abscess formation, **percutaneous debridement and drainage** is the preferred treatment [17, 18]. It can be performed using local anesthesia, sufficient material can be obtained for culture, and it allows for debridement and drainage of the infection.

### Radical Debridement

Radical debridement without bone grafting is sufficient in cases with:

Radical debridement is the key to successful surgery

- predominant epidural abscess
- absence of significant vertebral or intradiscal involvement
- absence of gross bony destruction, deformity, and instability

### Radical Debridement and Bone Grafting

Radical debridement and bone grafting are indicated in patients:

- with intraspinal abscesses
- without gross bony destruction, deformity, or instability

Primary bone grafting is preferred

There is still debate on the **timing of the bone grafting**. The main concern in primary bone grafting is the resolution of the graft by the infection. On the other hand, secondary bone grafting requires reoperation with theoretically increased morbidity. In the absence of conclusive data in the literature, the present author prefers primary bone grafting unless radical debridement is not achieved. In this case, a second-look operation is imperative and, depending on the local situation, bone grafting is performed during the latter intervention.

### Radical Debridement, Bone Grafting, and Instrumentation

Radical debridement and bone stable reconstruction of the spine are favored as the surgical technique of choice based on the good results obtained with surgical treatment of spinal tuberculosis [23, 32, 33] (Table 5):

**Table 5.** Rationales for radical debridement and stable reconstruction of the spine

| | |
|---|---|
| • improvement of general condition after abscess drainage | • in early stages, extirpation of infected focus is easy |
| • prevention of secondary deformity | • late recurrence is less frequent |
| • rapid progress of infection is prevented | • putative shorter hospitalization and earlier return to work |

Instrumentation has increasingly been used without recurrent infection

While the use of spinal instrumentation in the presence of spinal infection has been controversial in the literature, an increasing number of articles indicate that instrumentation is not contraindicated in cases where radical debridement is achieved [14]. There are no sufficient data in the literature to allow a conclusive statement on the role of instrumentation in spinal infection. However, there is no evidence to suggest that instrumentation prevents the healing of the spinal infection. The additional stability instead promotes clinical resolution of the infection and related symptoms (Table 6).

**Anterior Approach.** A **single-stage anterior approach** is best suited for cases with:

- predominant anterior column involvement
- effective radical debridement
- absence of gross deformity or instability

Anterior instrumentation appears not to have an adverse effect unless radical debridement is not achieved [12]. The use of anterior cages in the absence of a structural auto- or allograft remains controversial. However, early reports in the literature indicate that this approach can be successful [21].

**Posterior Approach.** A single posterior approach is only indicated in cases with a lesion with difficult anterior access, e.g., at the upper thoracic spine T2-4. In

**Table 6.** Surgical treatment of spinal infections with instrumentation

| Author | Cases | Type of infection | Follow-up | Technique | Complications/outcome | Conclusions |
|---|---|---|---|---|---|---|
| Moon et al. (1995) [33] | 44 | 44 tuberculosis | 3.6 (2–11) years | 44 posterior instrumentation and anterior debridement with fusion | 1 loss of correction<br>0 recurrent infection | Posterior instrumental stabilization and anterior interbody fusion were found helpful in arresting the disease early, providing early fusion, preventing progression of kyphosis and correcting the kyphosis |
| Carragee (1997) [8] | 17 | 17 pyogenic | >2 years | 15 anterior debridement and posterior debridement and instrumentation | 2 instrumentation failure,<br>1 wound dehiscence,<br>2 thrombosis,<br>1 symptomatic pseudarthrosis,<br>0 neurological deterioration,<br>0 recurrent infection | Spinal infection in selected cases allows early mobilization and does not compromise the ability to clear infection |
| Eysel et al. (1997) [12] | 55 | 32 pyogenic,<br>12 tuberculosis,<br>11 unknown | >2 years | 32 combined anterior debridement and posterior instrumentation vs 23 anterior debridement and instrumentation alone | 3 superficial infection,<br>1 intraoperative aorta rupture,<br>1 gastric ulcer,<br>3 neurological compromise,<br>0 recurrent infections | No adverse effect of anterior instrumentation was observed |
| Kroedel et al. (1999) [25] | 33 | 19 pyogenic,<br>4 tuberculosis,<br>10 unknown | mean 22<br>(13–53) months | 33 radical anterior debridement and extrafocal posterior instrumentation | 1 septic brain abscess,<br>1 peritonitis owing to bowel laceration,<br>2 superficial infection,<br>2 implant failures,<br>0 recurrent infection | Posterior extrafocal stabilization offers the advantage of braceless rehabilitation without life-threatening complications |
| Faraj and Webb (2000) [14] | 31 | 31 pyogenic | mean 3.8<br>(1–12) years | Anterior radical debridement and 30 posterior stabilization or 1 anterior stabilization | 1 graft dislodgement,<br>1 nosocomial chest infection (died),<br>3 wound infection,<br>1 implant failure,<br>2 recurrence of spinal infection,<br>2 recurrent spinal deformities,<br>0 recurrent infection | Spinal instrumentation is indicated when after radical debridement of infected vertebrae, disc material, and bone grafting, the stability of the spine is still compromised |

those cases, a costotransversectomy approach is necessary to allow for adequate decompression of the anterior column.

**Combined Approach.** This is the most widely used approach [8, 12, 19, 25, 42] consisting of short-segmental posterior pedicle screw fixation, followed by radical anterior debridement and bone grafting (Fig. 6). In the cervical spine, a two or

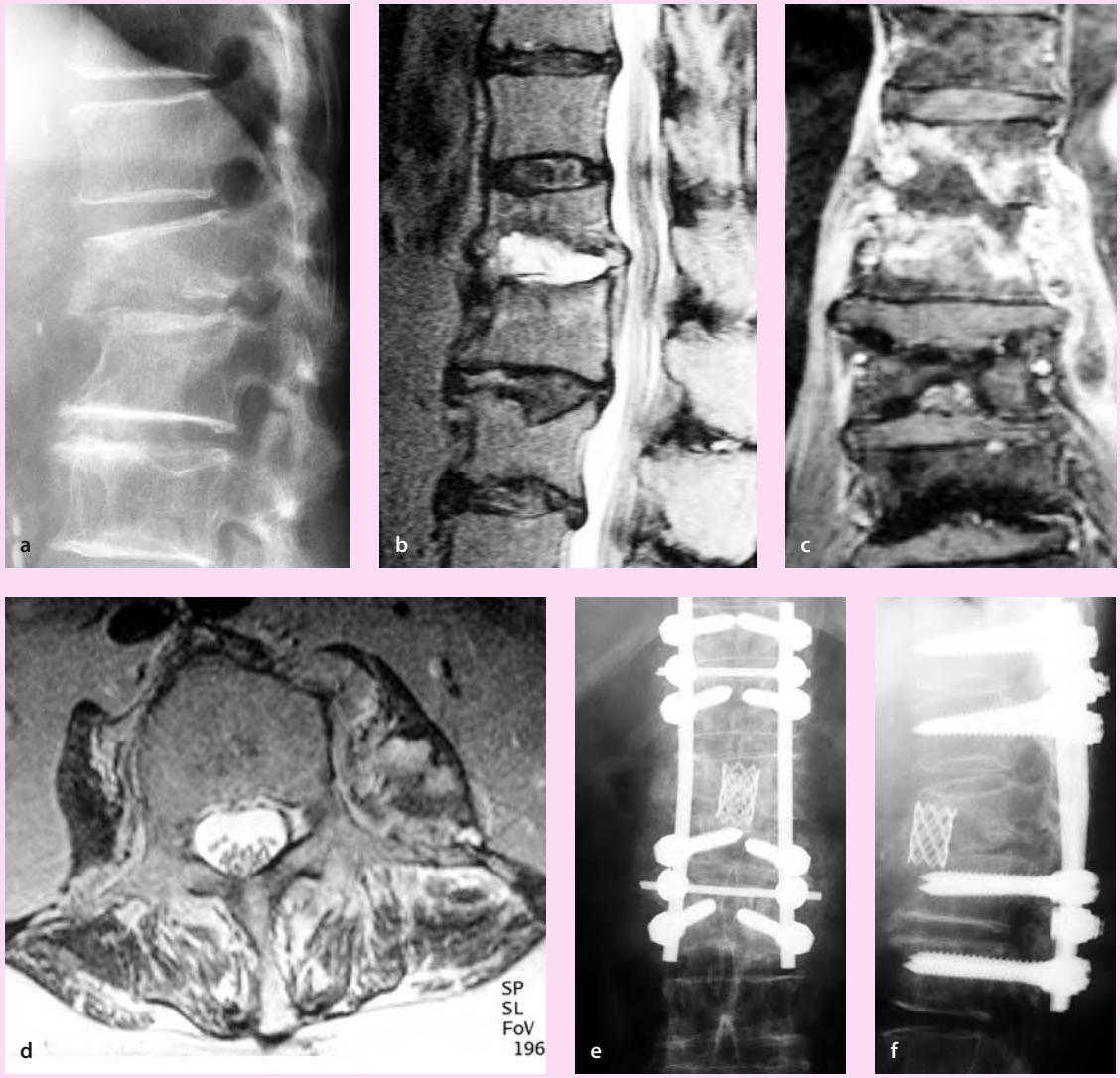


## Case Study 2

An 81-year-old woman developed progressive, severe back pain. Despite initial analgesics and physiotherapy, the patient continued to get worse. The patient developed a slight increased fever and felt sick. After severe pain with ambulation, a radiograph (a) was taken, demonstrating a collapsed L1/2 disc space with partial destruction of the lower endplate of L1. The MRI exhibits typical signs of a spinal infection. Note the high signal intensity in a T2W MR sagittal image (b) and a paravertebral abscess in the psoas muscles (c, d). In a first stage the spine was stabilized from T11 to L3 with a titanium pedicle screw system. In a second stage, during the same operation, the paravertebral abscess and the disc space and adjacent vertebral bodies L1/2 were debrided. The bone quality was osteoporotic. A tricortical bone graft was harvested from the iliac crest, but broke during insertion because of poor bone quality. Rather than leaving a large anterior gap, a titanium mesh cage was implanted, supporting the anterior cortex of the severely osteoporotic vertebrae (e, f). At 6 months follow-up the patient was ambulating without aid without limiting her daily activities, but she still had occasional back pain. There was no sign of recurrent infection during a further 1-year follow-up.

more level involvement requires additional posterior stabilization. However, in cases where the general health status does not allow an additional posterior approach, external splinting is imperative until the bone graft has healed. In cases of poor bone quality, e.g., in an osteoporotic spine, longer instrumentation may become necessary. In those cases, anterior buttress support is necessary to allow for stable construction. In cases where a tricortical bone graft is too brittle (osteoporosis), a titanium mesh cage can be applied. As a prerequisite, radical debridement has to be achieved prior to cage implantation and bone grafting (Case Study 2).

## Recapitulation

**Epidemiology.** In an era of very powerful antibiotics, it is sometimes forgotten that spinal infections are still a **potentially life-threatening disease**. Today, spinal infections predominantly occur in the elderly and immunocompromised patient, but the incidence of spinal tuberculosis in younger patients is again increasing in industrialized countries.

**Pathogenesis.** Spinal infections in adults appear to start from the vertebral endplates. The most frequent pathomechanism is a **spread of microorganisms via the blood vessels** from urogenital, pulmonary, or diabetic foot infections. Spinal infections are most frequently classified according to the **causative organism** (pyogenic, parasitic, fungal infections, tuberculosis) or the **location** (i.e., discitis, spondylitis, epidural, and paravertebral abscess).

**Clinical presentation.** The key feature of spinal infections is the delayed diagnosis. **Cardinal symptoms** are slowly progressive, continuous pain with pain exacerbation during rest and at night. Fever and septic states are rare. It is mandatory to search for **predisposing factors** such as diabetes, intravenous drug abuse, immunodeficiency, diabetic ulcers, and previous septic conditions. The physical findings are often non-specific unless neurologic deficits are present.

**Diagnostic work-up.** The **key to diagnosis** is to consider spinal infections. CRP and BSR are almost always elevated while the WBC can remain normal. The major drawback of standard radiography is the **delay in the appearance of radiographic signs**. The sequence of changes demonstrable on radiographs is blurred endplates, disc space collapse, development of osteolysis and a paravertebral shadow, reactive sclerosis and kyphotic deformity. MRI is the imaging modality of choice. Characteristic findings on MRI suggestive of spinal infections are decreased vertebral endplate signal intensity on T1W images, loss of endplate definition, increased signal intensity on T2W images, and contrast enhancement of the disc and vertebral endplates. The isolation of the causative organism is very important and must be attempted in every case. **CT-guided biopsy** is the method of choice because it allows the sample to be taken from inside the lesion. The most frequently found **organisms** are *Staphylococcus aureus* (30–55%), *E. coli, Salmonella, Enterococcus, Proteus mirabilis, Pseudomonas aeruginosa* (in 65% of drug abusers), *Streptococcus viridans*, and epidermatitis. In the absence of a life-threatening condition, treatment should not be started without vigorous attempts to isolate the causative organism. The likelihood of isolating the organism after the beginning of antibiotic treatment is minimal.

**Non-operative treatment.** The **general objectives of treatment** are to eradicate the infection, relieve pain, prevent or reverse a neurologic deficit, restore spinal stability, correct spinal deformity, and prevent recurrence. **Antibiotic treatment** is the therapy of choice for uncomplicated cases. Chemotherapy should not be stopped prior to normalization of the infectious parameters (CRP, BSR, WBC) and is usually given for 6–12 weeks. Early ambulation is attempted and a corset can be used optionally. In cases of **spinal tuberculosis**, a triple (isoniazid, rifampin, and pyrazinamide) or quadruple chemotherapy (plus ethambutol) is recommended for 2–3 months. After this period, chemotherapy should be continued with isoniazid and rifampin in the absence of resistance or side effects. While there is still debate on the **duration of treatment**, a total of 12 months is favored by the majority of experts.

**Operative treatment.** Surgery is **indicated** in cases of **disease progression** despite adequate antibiotic treatment, **progressive spinal deformity and instability**, and **neurological compromise**. The key to

successful surgery is radical debridement. This has been well demonstrated for the treatment of spinal tuberculosis, but is applicable to pyogenic infections as well. **Radical debridement and bone grafting** are indicated in patients with intravertebral abscess and without gross bony destruction, deformity, and instability. However, in many cases additional spinal stabilization is required. **Instrumentation** is still controversial in the literature, but an increasing number of articles have demonstrated that implants can be used without side effects. Spinal instrumentation promotes rather than prevents resolution of the infection because of the added stability. Posterior instrumentation with correction of the deformity, followed by anterior radical debridement and bone grafting, is the method of choice for a spinal infection with predominant anterior column involvement of the thoracolumbar spine. **Implants** can be used **at the site of infection** (e.g., in the cervical spine) with the prerequisite that radical debridement is thoroughly achieved.

### Key Articles

**Hodgson AR (1964) Report on the findings and results in 300 cases of Pott's disease treated by anterior fusion of the spine. J West Pacific Orthop Assoc 1:3–7**
Landmark paper favoring surgical treatment of spinal tuberculosis in a series of 300 cases.

**Moon MS, Woo YK, Lee KS, Ha KY, Kim SS, Sun DH (1995) Posterior instrumentation and anterior interbody fusion for tuberculous kyphosis of dorsal and lumbar spines. Spine 20:1910–6**
This paper summarizes present knowledge of spinal tuberculosis and its management. Antituberculosis agents remain the mainstay of management, with chemotherapy for 12 months preferred to shorter courses. Anterior surgery consisting of radical focal debridement without fusion does not prevent vertebral collapse. Patients who present late with deformity are candidates for anterior debridement and stabilization with corrective instrumentation. Posterior stabilization with instrumentation has been found to help arrest the disease and to bring about early fusion. Posterior instrumented stabilization to prevent kyphosis in early spinal tuberculosis is indicated, however, only when anterior and posterior elements of the spine are involved, particularly in children.

**Carragee EJ (1997) Instrumentation of the infected and unstable spine: a review of 17 cases from the thoracic and lumbar spine with pyogenic infections. J Spinal Disord 10:317–24**
In a retrospective review of 17 consecutive cases of spinal instrumentation for pyogenic vertebral osteomyelitis (PVO) with follow-up of >2 years, the authors demonstrated that spinal instrumentation in selected cases of PVO allows for early mobilization and did not seem to compromise the ability to clear infection. In certain recalcitrant cases, stabilization seemed to promote clinical resolution of the infection.

## References


1. Barnes PF, Bloch AB, Davidson PT, Snider DE Jr (1991) Tuberculosis in patients with human immunodeficiency virus infection. N Engl J Med 324:1644–50 2.Batson OV (1942) The role of vertebral veins in metastatic processes. Ann Intern Med 16:38–45
3. Belzunegui J, Del Val N, Intxausti JJ, De Dios JR, Queiro R, Gonzalez C, Rodriguez-Valverde V, Figueroa M (1999) Vertebral osteomyelitis in northern Spain. Report of 62 cases. Clin Exp Rheumatol 17:447–52
4. Beronius M, Bergman B, Andersson R (2001) Vertebral osteomyelitis in Goteborg, Sweden: a retrospective study of patients during 1990–95. Scand J Infect Dis 33:527–32
5. Brancker A (1991) Tuberculosis in Canada, 1989. Health Rep 3:92–6
6. Breasted JH (1930) The Edwin Smith Surgical Papyrus. Chicago: University of Chicago Press, 1930: 425–426.
7. Brugieres P, Gaston A, Voisin MC, Ricolfi F, Chakir N (1992) CT-guided percutaneous biopsy of the cervical spine: a series of 12 cases. Neuroradiology 34:358–60
8. Carragee EJ (1997) Instrumentation of the infected and unstable spine: a review of 17 cases from the thoracic and lumbar spine with pyogenic infections. J. Spinal Disord. 10:317–24

9. Chelsom J, Solberg CO (1998) Vertebral osteomyelitis at a Norwegian university hospital 1987–97: clinical features, laboratory findings and outcome. Scand J Infect Dis 30:147–51
10. Colmenero JD, Jimenez-Mejias ME, Sanchez-Lora FJ, Reguera JM, Palomino-Nicas J, Martos F, Garcia de las Heras J, Pachon J (1997) Pyogenic, tuberculous, and brucellar vertebral osteomyelitis: a descriptive and comparative study of 219 cases. Ann Rheum Dis 56:709–15
11. Dagirmanjian A, Schils J, McHenry M, Modic MT (1996) MR imaging of vertebral osteomyelitis revisited. AJR Am J Roentgenol 167:1539–43
12. Eysel P, Hopf C, Vogel I, Rompe JD (1997) Primary stable anterior instrumentation or dorsoventral spondylodesis in spondylodiscitis? Results of a comparative study. Eur Spine J 6:152–7
13. Fam AG, Rubenstein J (1993) Another look at spinal tuberculosis. J Rheumatol 20:1731–40
14. Faraj AA, Webb JK (2000) Spinal instrumentation for primary pyogenic infection report of 31 patients. Acta Orthop Belg 66:242–7
15. Fernandez M, Carrol CL, Baker CJ (2000) Discitis and vertebral osteomyelitis in children: an 18-year review. Pediatrics 105:1299–304
16. Glazer PA, Hu SS (1996) Pediatric spinal infections. Orthop Clin North Am 27:111–23
17. Haaker RG, Senkal M, Kielich T, Kramer J (1997) Percutaneous lumbar discectomy in the treatment of lumbar discitis. Eur Spine J 6:98–101
18. Hadjipavlou AG, Crow WN, Borowski A, Mader JT, Adesokan A, Jensen RE (1998) Percutaneous transpedicular discectomy and drainage in pyogenic spondylodiscitis. Am J Orthop 27:188–97
19. Hadjipavlou AG, Mader JT, Necessary JT, Muffoletto AJ (2000) Hematogenous pyogenic spinal infections and their surgical management. Spine 25:1668–79
20. Halsey JP, Reeback JS, Barnes CG (1982) A decade of skeletal tuberculosis. Ann Rheum Dis 41:7–10
21. Hee HT, Majd ME, Holt RT, Pienkowski D (2002) Better treatment of vertebral osteomyelitis using posterior stabilization and titanium mesh cages. J Spinal Disord Tech 15:149–56; discussion 156
22. Hlavin ML, Kaminski HJ, Ross JS, Ganz E (1990) Spinal epidural abscess: a ten-year perspective. Neurosurgery 27:177–84
23. Hodgson AR (1964) Report on the findings and results in 300 cases of Pott's disease treated by anterior fusion of the spine. J West Pacific Orthop Assoc 1:3–7
24. Jellis JE (1995) Bacterial infections: bone and joint tuberculosis. Baillieres Clin Rheumatol 9:151–9
25. Krodel A, Kruger A, Lohscheidt K, Pfahler M, Refior HJ (1999) Anterior debridement, fusion, and extrafocal stabilization in the treatment of osteomyelitis of the spine. J Spinal Disord 12:17–26
26. Krogsgaard MR, Wagn P, Bengtsson J (1998) Epidemiology of acute vertebral osteomyelitis in Denmark: 137 cases in Denmark 1978–1982, compared to cases reported to the National Patient Register 1991–1993. Acta Orthop Scand 69:513–7
27. Lannelongue OM (1897) On acute osteomyelitis. Miscellaneous, pathological and practical medicine tracts. Paris: 1897
28. Loke TK, Ma HT, Chan CS (1997) Magnetic resonance imaging of tuberculous spinal infection. Australas Radiol 41:7–12
29. Lu CH, Chang WN, Lui CC, Lee PY, Chang HW (2002) Adult spinal epidural abscess: clinical features and prognostic factors. Clin Neurol Neurosurg 104:306–10
30. Luk KD (1999) Tuberculosis of the spine in the new millennium. Eur Spine J 8:338–45
31. Makins GH, Abbott FC (1896) On acute primary osteomyelitis of the vertebrae. Ann Surg 23:510–539
32. Moon MS (1997) Tuberculosis of the spine. Controversies and a new challenge. Spine 22:1791–7
33. Moon MS, Woo YK, Lee KS, Ha KY, Kim SS, Sun DH (1995) Posterior instrumentation and anterior interbody fusion for tuberculous kyphosis of dorsal and lumbar spines. Spine 20:1910–6
34. Omarini LP, Garcia J (1993) CT-guided percutaneous puncture-biopsy of the spine. Review of 104 cases. Schweiz Med Wochenschr 123:2191–7
35. Pertuiset E (1999) Medical therapy of bone and joint tuberculosis in 1998. Rev Rhum Engl Ed 66:152–7
36. Pertuiset E, Beaudreuil J, Liote F, Horusitzky A, Kemiche F, Richette P, Clerc-Wyel D, Cerf-Payrastre I, Dorfmann H, Glowinski J, Crouzet J, Bardin T, Meyer O, Dryll A, Ziza JM, Kahn MF, Kuntz D (1999) Spinal tuberculosis in adults. A study of 103 cases in a developed country, 1980–1994. Medicine (Baltimore) 78:309–20
37. Pott P (1779) Remarks on that kind of palsy of the lower limbs which is frequently found to accompany a curvature of the spine. London: I. Johnson, 1779
38. Rieder HL, Cauthen GM, Kelly GD, Bloch AB, Snider DE, Jr (1989) Tuberculosis in the United States. JAMA 262:385–9
39. Rieneck K, Hansen SE, Karle A, Gutschik E (1996) Microbiologically verified diagnosis of infectious spondylitis using CT- guided fine needle biopsy. APMIS 104:755–62

40. Rigamonti D, Liem L, Sampath P, Knoller N, Namaguchi Y, Schreibman DL, Sloan MA, Wolf A, Zeidman S (1999) Spinal epidural abscess: contemporary trends in etiology, evaluation, and management. Surg Neurol 52:189 – 96; discussion 197
41. Ring D, Johnston CE, 2nd, Wenger DR (1995) Pyogenic infectious spondylitis in children: the convergence of discitis and vertebral osteomyelitis. J Pediatr Orthop 15:652 – 60
42. Safran O, Rand N, Kaplan L, Sagiv S, Floman Y (1998) Sequential or simultaneous, same-day anterior decompression and posterior stabilization in the management of vertebral osteomyelitis of the lumbar spine. Spine 23:1885 – 90
43. Sapico FL, Montgomerie JZ (1979) Pyogenic vertebral osteomyelitis: report of nine cases and review of the literature. Rev Infect Dis 1:754 – 76
44. Sapico FL, Montgomerie JZ (1990) Vertebral osteomyelitis. Infect Dis Clin North Am 4: 539 – 50
45. Schmitz A, Risse JH, Grunwald F, Gassel F, Biersack HJ, Schmitt O (2001) Fluorine-18 fluorodeoxyglucose positron emission tomography findings in spondylodiscitis: preliminary results. Eur Spine J 10:534 – 9
46. Shanley DJ (1995) Tuberculosis of the spine: imaging features. AJR Am J Roentgenol 164: 659 – 64
47. Stumpe KD, Zanetti M, Weishaupt D, Hodler J, Boos N, Von Schulthess GK (2002) FDG positron emission tomography for differentiation of degenerative and infectious endplate abnormalities in the lumbar spine detected on MR imaging. AJR Am J Roentgenol 179: 1151 – 7
48. Tyrrell PN, Cassar-Pullicino VN, McCall IW (1999) Spinal infection. Eur Radiol 9:1066 – 77
49. Wenger DR, Bobechko WP, Gilday DL (1978) The spectrum of intervertebral disc-space infection in children. J Bone Joint Surg Am 60:100 – 8
50. Wiley AM, Trueta J (1959) The vascular anatomy of the spine and its relation to pyogenic vertebral osteomyelitis. J Bone Joint Surg 41B:796 – 809

# 37 Rheumatoid Arthritis

Dieter Grob

## Core Messages

- ✔ Rheumatoid arthritis (RA) most commonly affects the cervical spine
- ✔ Tissue destruction causes instability of the atlantoaxial segment
- ✔ Compressive myelopathy is the consequence of instability and repetitive trauma
- ✔ The "wait and see" policy is rarely advocated
- ✔ Early surgery prevents extensive and risky interventions
- ✔ Marked osteoporosis requires anterior and posterior procedures in advanced stages of the disease
- ✔ Consider structural weakness of bone in the planning of the extent of fusion (adjacent segment decompensation)
- ✔ Inclusion of the occiput into the fusion usually requires fusion of the whole cervical spine

## Epidemiology

Rheumatoid arthritis (**RA**) is a worldwide disease. The original theory, that RA only occurs in areas with cold and wet weather conditions, turned out to be wrong; however, its incidence does seem to vary between countries [1].

In about 40 % of all patients with RA, the cervical spine is involved with neck pain, and of these patients, approximately 50 % show instability of the upper cervical spine complex (occiput to C2) [17]. The most common instability is the anterior translational C1/2 instability, but lateral or posterior subluxation occurs in a minority of patients. In approximately 20 %, vertical migration of the dens may be observed, and 15 – 20 % suffer from **subaxial instability** with subluxations and spinal stenosis.

Anterior atlantoaxial displacement is the most frequent cervical instability encountered in RA

In spite of the success of modern **medical treatment** and the decreasing incidence of manifest instability of the spine, surgery will remain one of the treatment options in advanced stages of the disease. While in the second half of the last century decompressive and stabilizing surgery was the only solution for severe alterations due to RA and thus represented some kind of last resort for neglected RA patients, surgery in the future will be the option for non-responders to modern chemical treatment or untreated "leftovers" [7].

Despite the success of modern medical treatment, surgery will remain a valid option for non-responders

## Pathogenesis

Rheumatoid arthritis affects synovial tissue, finally forming an inflammatory pannus, which represents an aggressive tissue with consecutive destruction of discoligamentous structures and bony elements around the facets. Due to the anatomical configuration of the atlantoaxial segment, the manifestation of RA is most often observed in the upper cervical spine. The three-dimensional motion in the atlantoaxial segment is controlled exclusively by the joint capsule and the

## Case Introduction

At the time of first presentation the patient was 52 years old and had suffered from rheumatoid arthritis for 4 years. Due to the aggressive course of the disease she had had her hips and knees replaced due to rheumatoid destruction of these joints. Her neck problem was revealed by the flexion radiograph of her cervical spine, where a reducible subluxation of the atlas was detected (a). Due to persisting pain, atlantoaxial fixation was performed by transarticular screw fixation. In spite of several other subsequent interventions, the patient was without symptoms in her neck for several years and a routine check-up 6 years postsurgery showed solid fusion of the atlantoaxial segment in an anatomical position. Twelve years after her neck surgery, she started to have painful sensations in her neck; however, she refused to seek medical advice, being afraid of needing further intervention (she had sustained a total of 23 interventions due to her rheumatoid disease up to that date!). The functional views revealed an subaxial instability (b, c). However, the pain became more intensive and she noted increasing clumsiness of her hands. She finally presented with a stiff and painful neck. A hyperreflexia of upper and lower extremities was found together with sensory disturbances in her hands. A neurophysiological examination confirmed the presence of a significant cervical myelopathy. The radiographs showed decompensation of the adjacent levels with significant retroposition of the vertebral body C3 producing severe spinal stenosis (d, e).

**Case Introducton** (*Cont.*)

A one-stage surgery was performed with initial anterior resection of the vertebral body of C3. With this step, decompression of the spinal canal and reduction of the deformity was achieved. In the same sitting, posterior fixation was carried out to maintain reduction and stability. Laminectomy and flavectomy were performed at the same time to decompress posteriorly. Since there was no upward migration or pathology in the atlanto-occipital joint, the occiput was not included in the fixation (f, g). After surgery, the patient recovered well and noticed an improvement in the dexterity of her hands and a reduction of the paresthesias.

ligaments – with the exception of extension, in which the dens axis serves as a bony blocker. With the destruction of the capsuloligamentous elements, a mainly **horizontally orientated instability** (Fig. 1) occurs, which is complicated by subsequent bony arrosion of dens and lateral masses of the atlas, leading to an additional upward migration of the atlantoaxial complex towards the foramen magnum.

Pannus formation is related to instability

The **inflammatory pannus** seems to be one of the **key factors** in tissue destruction. If there is no motion, there is no pannus formation and – as a consequence – no tissue destruction occurs [10]. In this view, surgically induced fusion, e.g. of the atlantoaxial joint, prevents the destructive process and therefore prevents the transformation of a horizontal instability into a **vertical instability** [10] (Fig. 1).

Disc/facet joint destruction and bony erosion cause subaxial instability

The **subaxial cervical spine** may also show instability and spinal stenosis due to RA changes. Facet joint and disc destruction as well as bony erosion cause anterolisthesis and loss of lordosis and – with increasing deformity – spinal stenosis with encroachment of the medulla and nerve roots. Even if the involvement of the lower cervical spine is mostly primary in the underlying disease, it may occur secondarily as a consequence of increased lever arms due to stabilizing procedures of the upper cervical spine (Case Introduction).

The **lumbar spine** may also be involved in RA patients; however, here the consequences of long-standing steroid therapy rather than disease specific alterations are predominant. Therefore, **degenerative spondylolisthesis** and **vertebral fractures** may be observed.

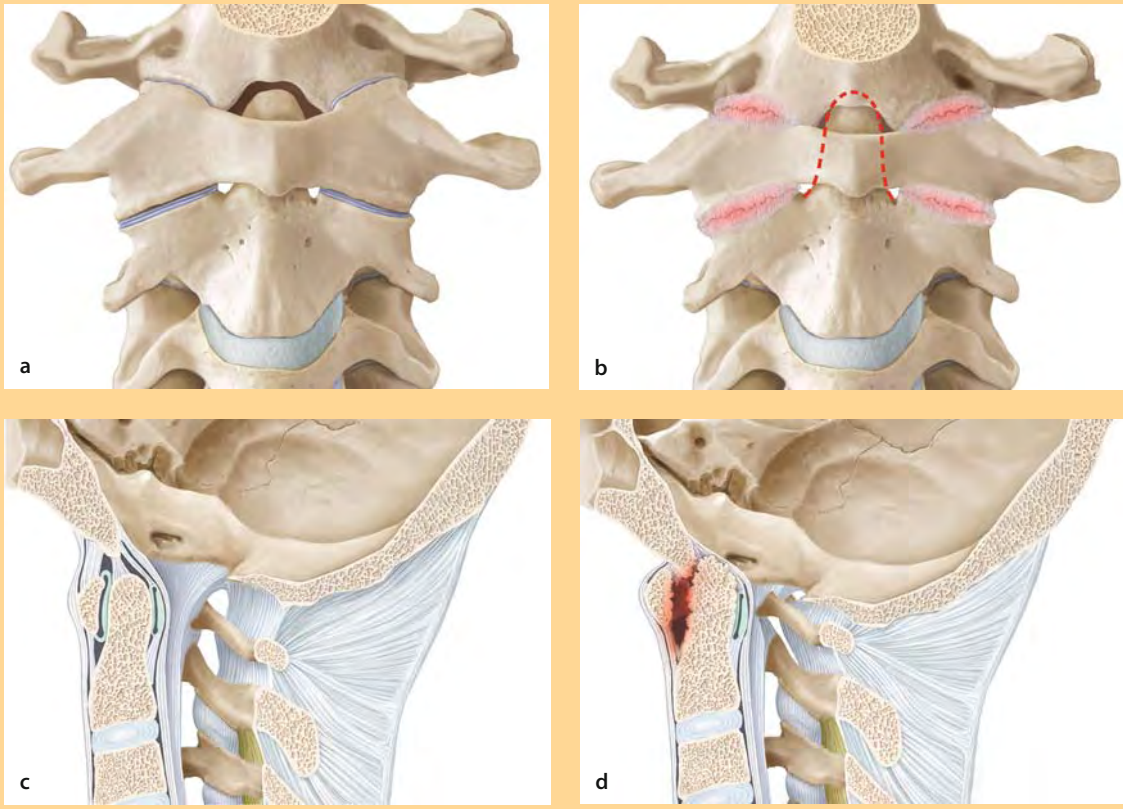


**Figure 1. Horizontal and Vertikal Instability**

a, c Normal anatomy of the occipitocervical junction. b Advanced stage of instability and resorption of the lateral masses of the atlas. The dens axis moves upward into the foramen magnum. d **Horizontal instability** in the atlantoaxial segment with decreased posterior atlantodental interval and increasing anterior atlantodental interval. **Vertical instability** with upward migration of the dens into the foramen magnum.

## Classification

The commonly used classification is the **Ranawat classification** [20], which differentiates between the different stages of the rheumatoid influence on the patient's mobility (Table 1). This relatively crude differentiation is hardly able to assess the situation of these patients satisfactorily. Important items such as hygienic independence, eating capacities and general use of the hands are not included in the classification, but are of the utmost importance to the patient. Therefore the classification is barely sufficient to serve as an outcome measurement of surgery. For the practical clinical user, the recently published and validated Core Questions [17] have proven to be a useful basis for assessment.

**Table 1.** Ranawat classification

| | |
|---|---|
| Class I | Pain, no neurological deficit |
| Class II | Subjective weakness, hyperreflexia, dysesthesias |
| Class III | Objective weakness, long-tract signs |
| Class IIIA | Ambulatory |
| Class IIIB | Non-ambulatory |

## Clinical Presentation

As known from other conditions in the spine, radiological changes are not always concordant with the clinical symptomatology. Therefore major instabilities may be without symptoms, and minor alterations may be very painful.

The radiological alterations in RA do not correlate with the symptoms

### History

The history of RA is generally evident when the spine becomes involved. Therefore, diagnosis does not cause any clinical problems.

The **cardinal symptom** of atlantoaxial instability is:

- suboccipital pain
- pain exacerbation on head rotation or flexion

Sometimes a painful "clunk" may be heard or felt by the patient or the examiner during examination.

If **vertebrobasilar insufficiency** is involved, patients complain about:

- tinnitus
- vertigo
- disturbance of visual orientation
- dysphagia

### Physical Findings

Often occipital and neck pain are so severe that clinical examination is almost impossible due to protective muscle spasms. Neurological involvement with compression of the brainstem and the medulla oblongata may be demonstrated by a positive **Lhermitte sign**: The patient complains of a sharp electric pain irradiation in the body during a flexion maneuver of the cervical spine. Myelopathic symptoms occur in chronic instability due to repetitive trauma of the medulla. Typically, the clinical manifestation expresses itself by:

Pain can be so severe that a physical exam is not possible

- a positive scapulohumeral reflex [21]
- atrophy of the small muscles of the hand [19]

However, in RA patients **myelopathic symptoms** may be difficult to detect clinically due to multiple alterations on various joints from frequent surgical interventions, thus making it critical to assess reflexes or muscle tonus. In these cases, neurophysiological investigations with electrophysiological examinations are indispensable.

Cervical RA can cause myelopathy

## Diagnostic Work-up

### Imaging Studies

#### Standard Radiographs

Conventional radiographs are standard. Views in the lateral and anteroposterior (including the transoral anteroposterior view of the atlas) positions contain valuable information about bone quality, segmental changes and alignment.

Standard radiography is the initial imaging modality of choice

Several lines that orientate at bony landmarks of the upper cervical spine allow the degree of subluxation and vertical migration to be quantified. Atlantoaxial instability may only be detected in lateral flexion/extension views. While in flex-

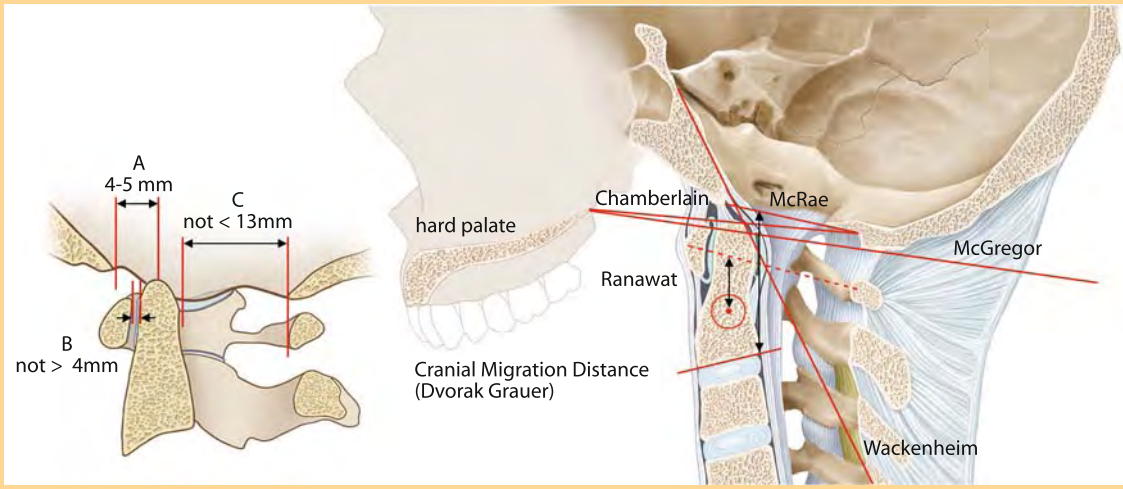


Figure 2. Radiographic assessment of instability

Reducibility of atlantoaxial subluxation influences surgical strategy

ion the atlas slips anteriorly into a subluxed position, and in extension reduction an anatomical position occurs as long as there is no fixed subluxation. The transverse instability is measured by the anterior (**ADI**) or posterior (**PADI**) (Fig. 2) atlantodental intervals (Fig. 2). The information on reducibility will influence the strategy for the surgical procedure. The flexion view is also able to demonstrate segmental instability of the subaxial cervical spine.

The presence of gross atlantoaxial instability requires fiberoptic intubation

This information is not only valid for the surgeon who intends to assess the degree of instability but also for the anesthetist who has to intubate the patient. In the presence of gross instability, **fiberoptic intubation** is recommended in order not to move the neck.

### Magnetic Resonance Imaging

MRI is indispensable for surgical planning

This type of imaging represents the standard diagnostic procedure. It allows direct visualization of soft tissue and bone and the relation to the neurogenic tissue (Case Study 1). Myelon compression by pannus can only be detected on MRI. If the space available for the cord (SAC) in flexion is less than 6 mm, the risk of myelopathy increases significantly [5, 6]. The precise anatomical details shown on the MRI scan are indispensable for the planning of the surgery. Information about the dimension of the isthmus of C2 may be crucial in deciding whether a transarticular screw fixation is suitable or not.

### Computed Tomography

The information contained in the CT scan is able to reveal anatomical details of bony structures and CT is indicated as an additional investigation in complex cases with rotational deformities of the upper cervical spine.

### Ultrasound

Ultrasound is useful as a screening method in cases where anomalies of the course of the vertebral artery are suspected, namely in significant destruction and deformities.

## Case Study 1

A 52-year-old female patient had suffered from seropositive rheumatoid arthritis for 18 years. Medical treatment had been successful and the course was relatively benign. Both hips had been replaced 6 and 4 years previously. The patient had been feeling increasing neck pain for 9 months that had increased with physical activity and subsided at rest. Several weeks previously, the patient noted a noise in her neck when flexing the cervical spine, which increased the neck pain. The neurological investigation revealed no neurological deficit. The radiographs in flexion showed atlantoaxial instability with anterior subluxation of the atlas (a). This dislocation was reduced to normal in the extension views (b). The MRI scan of the cervical spine showed mild degenerative changes in the lower cervical spine but no stenosis in the suboccipital area (c). It was decided to fix the atlantoaxial instability with a transarticular C1/2 screw fixation and posterior bone graft (d, e).

### Magnetic Resonance Angiography

Magnetic resonance angiography is the method of choice for identification of anomalies of the vertebral artery. The details obtained about the vessel through this non-invasive technique allow optimization of the position of the screws for internal fixation.

## Injection Studies

### Facet Infiltration

Facet joint infiltrations are helpful in localizing the pain source

Also not commonly used in RA, facet infiltration may help to determine the source of pain. The injection of a small amount of local anesthetic into the facet joint should relieve the pain if the corresponding facet is the origin of pain. In cases with concomitant osteoarthritis of the atlantoaxial joints, this diagnostic procedure may be helpful to differentiate between pain originating from C1/2 and subaxial pain.

### Nerve Root Infiltration

The placement of local anesthetics into the intervertebral foramen can help to separate peripheral nerve compression syndromes from compressive symptoms due to local stenosis at the cervical spine.

## Neurophysiological Investigations

These investigations are performed by the neurologist and provide information about the localization and the extent and severity of myelopathy. These additional techniques have a special place in the context of RA. The clinical examination in severe RA may be extremely difficult to evaluate. Patients with severe RA have undergone multiple surgery with soft tissue repair and joint replacement during the course of the disease. Provocation of reflexes or the testing of muscle tonus might be impossible. The objective evaluation of these neurophysiological tests helps to determine the severity of the damage.

## Non-operative Treatment

The course of the rheumatoid disease is unidirectional

The course of the rheumatoid disease is unidirectional [18] (Case introduction). Recent medical treatment, i.e. the advent of **TNF-α inhibitors**, is able to stop or to slow down the progression, but there is still no medication to restore stability, correct deformity or decompress the spinal canal. This knowledge includes the aspect of prophylaxis. Regular follow-ups are necessary to detect the progression of instability.

## Operative Treatment

### General Principles

The **general objectives** of surgery include:

- eliminating instability
- restoring anatomical alignment
- decompressing neurological structures
- preventing adjacent segment decompensation

If the intervention is performed at an advanced stage, the surgery is much more invasive, requiring anterior decompression/stabilization and additional posterior stabilization, while at an earlier stage of the deformity a relatively simple posterior approach would have the same effect. On the other hand, the patient probably has undergone multiple interventions and has more planned surgery ahead in his or her schedule. Prophylactic surgery will be hardly acceptable in this situation, but a regular work-up with imaging will be mandatory in order not to miss any progression of instability in the cervical spine. The same applies for the myelopathy. Repetitive traumatization of the myelon by instability can cause myelopathy. Once manifest, recovery becomes more unlikely. Early stabilization can prevent the occurrence of myelopathy.

Early surgery minimizes the operative risks

## Indications

The **most frequent indication**s for surgery are:

- severe neck pain
- instability
- neurological symptoms

It is important to note that instability of the atlantoaxial segment can occur without significant pain. If there is a clear progression with increasing atlantodental interval (**ADI**) in different follow-up investigations, stabilization should be planned even in the absence of severe pain. In unchanged situations, the patient should be given careful information and the possible risks and advantages of early surgery or a "wait and see" policy should be explained to involve the patient in the decision-making process. If myelopathic symptoms are present, decompressive and stabilizing surgery is indicated to prevent further damage [2, 5] (Table 2):

**Table 2.** Indications for atlantoaxial surgery based on imaging

| | |
|---|---|
| SAC in MRI (flexed position) | Less than 6 mm |
| PADI in flexion radiographs | Less than 14 mm |
| Distance from base of the corpus C2 to the foramen magnum | Less than 31.5 mm |

SAC = space available for cord; PADI = posterior atlantodental interval

The decision on surgical indications and even on surgical strategy in rheumatoid patients should take into account the general situation and other surgery that might be planned. If inclusion of the occiput into the fusion of the cervical spine is considered necessary, the situation of the upper limbs should be carefully checked: In the presence of restricted **elbow mobility**, the postoperative situation with a smaller range of motion of the cervical spine may not allow a spoon and fork to be brought to the mouth and may lead to an inability to eat independently and therefore to a significant loss of independence for the patient. A careful re-evaluation of the indication or synchronized surgery of the elbow will be necessary in this situation. Similarly if shoulder surgery and cervical surgery are planned in one sitting, it has to be taken into account that for shoulder surgery special positioning with head rotation is necessary. It should be carefully evaluated whether this rotation is tolerable in the presence of instability and whether the operated cervical spine is sufficiently stabilized.

The patient's general condition must be taken into account

The function of the elbow and shoulder has to be taken into account when occipitocervical fusion is planned

## Surgical Techniques

### Upper Cervical Spine

#### *Atlantoaxial Stabilization*

The classic wiring techniques were introduced by Gallie in 1939 [8] and Brooks in 1978 [3] (see Chapter 30).

Transarticular screw fixation (Magerl) is the method of choice for atlantoaxial instability

One or two iliac bone grafts are inserted posteriorly and fixed with wires to the posterior arch of the atlas and the spinous process of C2 or the lamina of C2. The advantage of these procedures is the easy technique; however, the lack of stability mainly in rotation and translation leads to a considerable rate of pseudarthrosis. Attempts have been made to improve this by introducing posterior clamps between the atlas and axis but these have failed because of frequent loosening. The technique of Magerl/Seemann (1986) [16] was finally able to improve the results of posterior atlantoaxial fusion by using transarticular screws (Case Study 1). This procedure provides a three-dimensional stability [11, 12] by insertion of screws bilaterally through the facet joints, thus preventing dislocation in translation and rotation (Fig. 3). The construct is completed by a posterior bone graft fixed with wires or non-absorbable suture to the atlas and axis in the midline. This additional posterior support provides stability in flexion and extension. It is possible to reduce the rate of pseudarthrosis to 0–5% with this procedure. The disadvantage remains the technically difficult insertion of the screws. An increased capacity for reduction in cases of fixed subluxation is achieved by lateral mass fixation in the atlas [9, 14]. Four polyaxial screws of appropriate size are inserted bilaterally into the lateral masses of the atlas and the pedicle of C2 and connected with longitudinal rods. This complex construct represents a difficult operative technique but is excellent for special cases and salvage procedures.

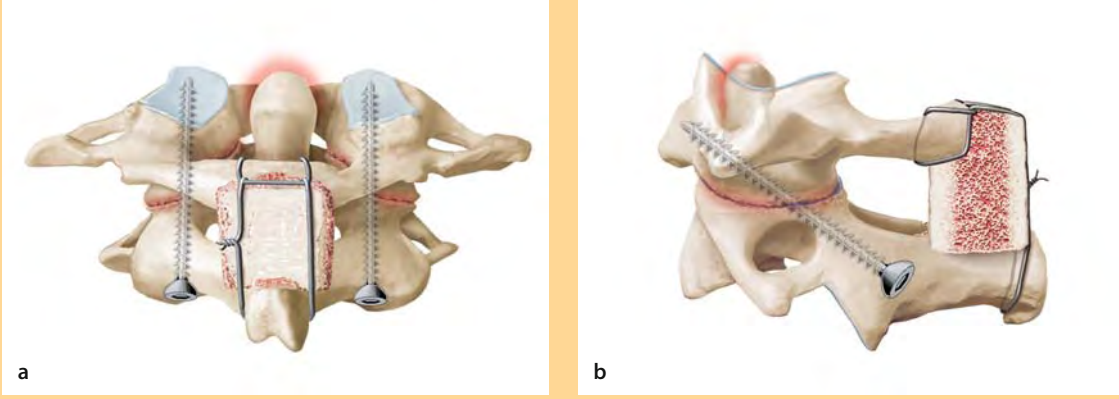


**Figure 3. Atlantoaxial fusion in RA**

a, b A midline bone graft is fixed posteriorly in the midline by a wire loop between the posterior aspect of C1 a and C2. Transarticular C1/C2 screw fixation. By inserting bilateral transarticular screws and a posterior bone graft in the midline, a solid three-point fixation is achieved between the atlas and the axis (b).

### *Occipitocervical Fusion*

As mentioned earlier, the inclusion of the occiput into the fusion mass in rheumatoid patients should be carefully indicated. The increased lever arm produces additional forces to the adjacent levels. In RA patients with reduced bone quality, this leads to decompensation in the non-fused segment of the lower cervical spine in 30–40% of patients [15, 18]. As a consequence, the inclusion of the occiput implies the extension of the fusion to the whole cervical spine, leading to a significant reduction in range of motion [13].

Inclusion of the occiput often leads to subaxial decompensation

### *Decompression of the Upper Cervical Spine (C0–C2)*

The most frequent compression of the myelon occurs at the atlantoaxial level by the subluxation that causes a dens axis protruding dorsally into the lumen of the spinal canal. The easiest way to decompress therefore is to restore the normal anatomical situation by reducing the subluxation. This can be achieved during the fixation procedure if the subluxation has not yet been fixed by advanced joint destruction. In non-reducible dislocations, an anterior transoral approach may be used to decompress the spinal canal by resection of the dens [4]. Since this procedure requires partial resection of the anterior part of the atlas, additional fixation should be performed. In the same sitting, posterior atlantoaxial fixation can be added. This also allows posterior decompression by laminectomy or widening of the foramen magnum if required (Table 3):

**Table 3.** Interventions of the upper cervical spine

| Pathology/intervention | "Wait and see", regular follow-up | Stabilization C1/2 | Transoral decompression | Inclusion of the occiput |
|---|---|---|---|---|
| Painfree, moderate C1/2 dislocation | X | | | |
| C1/2 subluxation without myelopathy | (X) | X | | |
| C1/2 reducible subluxation with myelopathy | | X | | |
| Locked C1/2 subluxation with myelon compression | | X | X | |
| Vertical migration of the dens without myelopathy | | | | X |
| Vertical migration of the dens with myelopathy | | | X | X |

## Subaxial Cervical Spine (C2–C7)

### *Decompression of the Subaxial Spine*

Narrowing of the spinal canal can occur by pannus formation or secondarily by segmental dislocation and malalignment. Due to the anatomical configuration, the cervical spine tends to produce anterior dislocation and loss of lordosis with mainly anteriorly located compression. The anterior decompression therefore represents the standard procedure. According to the severity of the stenosis, one or several levels are involved, requiring corpectomy with removal of the anterior part of the vertebral body (Fig. 4). From a posterior approach, laminectomy can be added if posterior compression is identified.

Corpectomy is the preferred method for anterior decompression

### *Stabilization of the Subaxial Cervical Spine*

The administration of steroids over a period of years produces marked osteoporosis in rheumatoid patients, which represents a most challenging situation. Bone grafts, cages and plates tend to subside, producing recurrent deformation and pseudarthrosis. Therefore in most situations of multisegmental fusion, a

Marked osteoporosis may require anterior and posterior fixation

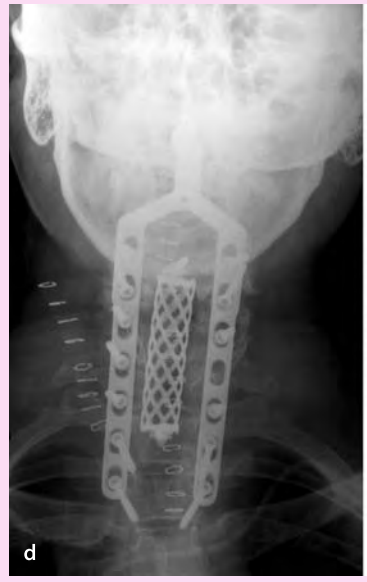

## Case Study 2

A 46-year-old female had suffered from seropositive rheumatoid arthritis for 11 years. Seven years previously she experienced an episode of mild neck pain. The radiographs at the time revealed an atlantoaxial subluxation in the flexion view (a). Her treating physician considered conservative treatment appropriate. She underwent several interventions to the peripheral joints (hips, elbow, hand), but developed neck pain only 8 months previously. Four weeks previously she felt it difficult to maintain her head in an upright position and preferred to wear a collar for stabilization. She reported intermittent paresthesias in both hands. The radiograph of her cervical spine showed in the lateral view a kyphotic deformity involving C4–C6 (b). Bone resorption and sclerosis of the endplates with resorbed discs were the morphological changes. The MRI scan confirmed the deformity and revealed a spinal stenosis at the level of C5/6 due to subluxation (c). Neurophysiological examination of the patient provided evidence of mild cervical myelopathy. The patient was surgically treated with anterior decompression by corpectomy C4–C7. The reconstruction of the anterior column was achieved by insertion of a titanium mesh cylinder. It was filled with the debris of the corpectomy bone and fixed in place with two bicortical bone screws. In the same session the posterior fixation from C0 to T2 was executed. Abundant iliac bone was used as fusion mass along the entire cervical spine (d, e).

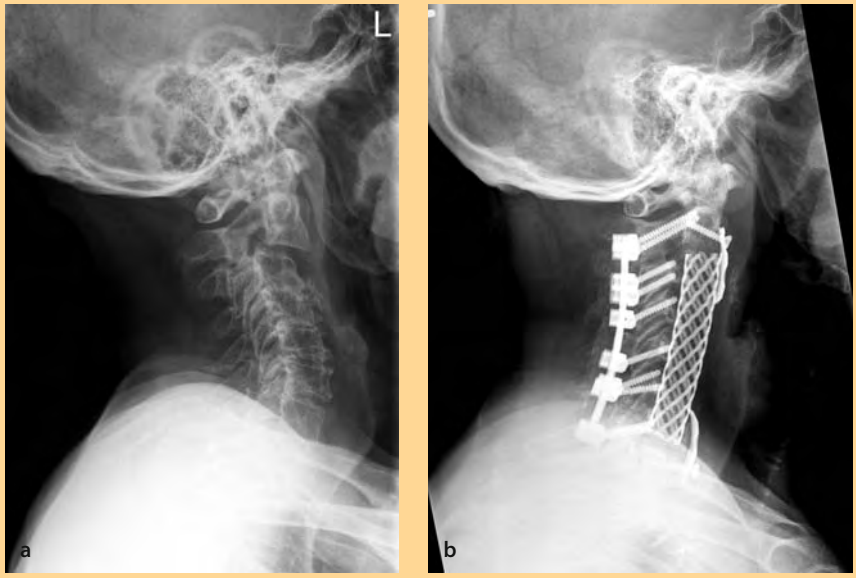


**Figure 4. Subaxial fusion in RA**

a, b Reduced bone quality in RA often requires complex surgery with anterior decompression by corpectomy, reconstruction with a cage or bone graft and posterior fixation with a screw rod system.

combined anterior and posterior approach will be necessary to achieve sufficient stability (Case Study 2). Anteriorly, plates and strut grafts are common implants to compensate for the iatrogenic instability produced by corpectomy. Posteriorly, **lateral mass screws** and **plate** or **rod fixation** (Fig. 4) provide sufficient stability. In special cases where additional reduction is required, the transpedicular screw fixation technique provides more stability but carries a higher risk of nerve root injury.

## Recapitulation

**Epidemiology.** Approximately 40 % of patients with rheumatoid arthritis show pathology in the cervical spine, mainly the atlantoaxial segment.

**Pathogenesis.** The **translational instability** between axis and atlas might be painful and leads in the long term to **myelopathic changes** due to chronic traumatization of the myelon. Ongoing osseous resorption of the lateral masses of the atlas causes upward migration of the dens into the foramen magnum. In the subaxial cervical spine, the inflammatory process causes instability and deformity.

**Clinical presentation.** The instability and deformity are mostly associated with the corresponding clinical symptoms: **pain** and **neurological signs** in different stages. However, it has to be kept in mind that these patients are used to tolerating pain and that often other problems of the joints are more prominent. The pathology of the cervical spine may progress unnoticed in these cases.

**Diagnostic work-up.** Every patient with RA should have a lateral flexion radiography of the cervical spine performed as a screening investigation at least every 3 – 5 years (according to the aggressivity of the disease). In cases of manifest instability or deformity, a neurophysiological work-up and MRI should be performed.

**Non-operative treatment.** If surgery is not indicated, the patient should be given regular observation with neurophysiological examinations, radiographs and MRI.

**Operative treatment.** **Neck pain** is the most common indication for surgery, but **neurological symptoms with myelopathy** or **radicular deficits** might be the primary cause for surgery. It should be kept in mind that clinical assessment in rheumatoid patients might be extremely difficult since previous surgery on various articulations of the extremities makes interpretation of clinical findings difficult. Neurophysiological investigation is a suitable means for obtaining objective results. Stabilization of the **atlantoaxial** segment is the most common procedure for treatment of atlantoaxial instability. It is performed by **screw fixation** technique from a posterior approach. In the case of severe occipitocervical dislocation, the fixation should be extended to the occiput. Persistent dislocation or compression by the dislocated dens should be treated by transoral decompression. In the subaxial spine, instabilities may be treated by posterior plate fixation with lateral mass screws or pedicle screws. Concomitant narrowing of the spinal canal should be approached by **anterior decompression with corpectomy** and/or posterior laminectomy. The timing of surgery in rheumatoid patients is crucial to obtaining satisfactory clinical results.

## Key Articles

**Boden SC, Dodge LD, Bohlmann HH, Rechtine GL (1993) Rheumatoid arthritis of the cervical spine. Long term analysis with predictors of paralysis and recovery. J Bone Joint Surg 75-A(9):1282 – 1297**
The authors report their experience in treating 73 patients with rheumatoid arthritis with an average follow-up of 7 years. The authors highlight that the most important predictor of the potential for neurological recovery after the operation was the preoperative posterior atlanto-odontoid interval. In patients who had paralysis due to atlantoaxial subluxation, no recovery occurred if the posterior atlanto-odontoid interval was less than 10 mm, whereas recovery of at least one neurological class always occurred when the posterior atlanto-odontoid interval was at least 10 mm. If basilar invagination was superimposed, clinically important neurological recovery occurred only when the posterior atlanto-odontoid interval was at least 13 mm. All patients who had paralysis and a posterior atlanto-odontoid interval or diameter of the subaxial canal of 14 mm had complete motor recovery after the operation.

**Crockard HA, Pozo JL, Ransford AO, Stevens JM, Kendall BE, Essigman WK (1986) Transoral decompression and posterior fusion for rheumatoid atlanto-axial subluxation. J Bone Joint Surg 68B(3):350 – 356**
In this landmark paper, Crockard et al. describe a surgical technique for transoral anterior decompression and posterior occipitocervical fusion, which removes both bony and soft-tissue causes of compression and allows early mobilization without major external fixation.

## Key Articles

**Dvorak J, Grob D, Baumgartner H, Gschwend N, Grauer W, Larsson S (1989) Functional evaluation of the spinal cord by magnetic resonance imaging in patients with rheumatoid arthritis and instability of upper cervical spine. Spine 14(10):1057 – 1064**
This study describes the imaging findings in patients with atlanto-axial instability due to rheumatoid arthritis and provides recommendations for surgical treatment.

**Matsunaga S, Sakou T, Onishi T, Hayashi K, Taketomi E, Sunahara N, Komiya S (2003) Prognosis of patients with upper cervical lesions caused by rheumatoid arthritis: comparison of occipitocervical fusion between C1 laminectomy and nonsurgical management. Spine 15(28):1581 – 1587**
In a matched controlled comparative study, non-surgical treatment and occipitocervical fusion associated with C1 laminectomy were evaluated in patients with upper cervical lesions caused by rheumatoid arthritis. The authors concluded that occipitocervical fusion associated with C1 laminectomy for patients with rheumatoid arthritis is useful for decreasing nuchal pain, reducing myelopathy, and improving prognosis.

**Combe B, Landewe R, Lukas C, Bolosiu HD, Breedveld F, Dougados M, Emery P, Ferraccioli G, Hazes JM, Klareskog L, Machold K, Martin-Mola E, Nielsen H, Silman A, Smolen J, Yazici H (2007) EULAR recommendations for the management of early arthritis: report of a task force of the European Standing Committee for International Clinical Studies Including Therapeutics (ESCISIT). Ann Rheum Dis 66:34 – 45**
Excellent review on the conservative treatment of rheumatoid arthritis with recommendations on the management of early rheumatoid arthritis

## References


1. Almeida Mdo S, et al. (2005) Epidemiological study of patients with connective tissue diseases in Brazil. Trop Doct 35(4)206 – 9
2. Boden SC, et al. (1993) Rheumatoid arthritis of the cervical spine. Long term analysis with predictors of paralysis and recovery. J Bone Joint Surg 75A(9):1282 – 1297
3. Brooks AL, Jenkins EG (1978) Atlanto-axial arthrodesis by the wedge compression method. J Bone Joint Surg 60A:279 – 284
4. Crockard HA, et al. (1986) Transoral decompression and posterior fusion for rheumatoid atlanto-axial subluxation. J Bone Joint Surg 68B(3):350 – 356
5. Dvorak J, et al. (1989) Functional evaluation of the spinal cord by magnetic resonance imaging in patients with rheumatoid arthritis and instability of upper cervical spine. Spine 14(10):1057 – 1064
6. Dvorak J, et al. (1993) Clinical validation of functional flexion/extension radiographs of the cervical spine. Spine 18(1):120 – 127
7. Edwards CJ, et al. (2005) The changing use of disease-modifying anti-rheumatic drugs in individuals with rheumatoid arthritis from the United Kingdom General Practice Research Database. Rheumatology (Oxford) 44(11)1394 – 1398
8. Gallie WE (1939) Fractures and dislocations of the cervical spine. Am J Surg 46A:495 – 499
9. Goel A, Laheri V (1994) Plate and screw fixation for atlanto-axial subluxation. Technical report. Acta Neurochir 129:47 – 53
10. Grob D (2000) Atlantoaxial immobilization in rheumatoid arthritis: a prophylactic procedure? Eur Spine J 9:404 – 409
11. Grob D, et al. (1992) Biomechanical evaluation of four different posterior atlantoaxial fixation techniques. Spine 17(5):480 – 490
12. Grob D, et al. (1994) The role of plate and screw fixation in occipitocervical fusion in rheumatoid arthritis. Spine 19:2545 – 2551
13. Grob D, Schütz U, Plötz G (1999) Occipitocervical fusion in patients with rheumatoid arthritis. Clin Orthop 366:46 – 53
14. Harms J, Melcher RP (2001) Posterior C1–C2 fusion with polyaxial screw and rod fixation. Spine 26(22):2467 – 71
15. Kraus DR, et al. (1991) Incidence of subaxial subluxation in patients with generalized rheumatoid arthritis who have had previous occipital cervical fusions. Spine 16(10S):486 – 489
16. Magerl F, Seemann P (1986) Stable posterior fusion of the atlas and axis by transarticular screw fixation. Cervical Spine 1:322 – 327
17. Mannion AF, Elfering A (2006) Predictors of surgical outcome and their assessment. Eur Spine J 15(Suppl 1)93 – 108

18. Matsunaga S, et al. (2003) Prognosis of patients with upper cervical lesions caused by rheumatoid arthritis: comparison of occipitocervical fusion between C1 laminectomy and nonsurgical management. Spine 15(28):1581 – 1587
19. Ono K, Ebara S, Fuji T (1987) Myelopathy hand. J Bone Joint Surg 69B:215 – 219
20. Ranawat CS, et al. (1979) Cervical spine fusion in rheumatoid arthritis. J Bone Joint Surg 61A:1003 – 1010
21. Shimizu T, Shimada H, Shirakura K (1993) Scapulohumeral reflex (Shimizu). Its clinical significance and testing maneuver. Spine 18(15):2182 – 2190

# 38 Ankylosing Spondylitis

Thomas Liebscher, Kan Min, Norbert Boos

## Core Messages

- ✔ Ankylosing spondylitis (AS) is a systemic, inflammatory, seronegative rheumatoid disease
- ✔ Ankylosing spondylitis in 90% of cases is associated with HLA-B27
- ✔ The male/female ratio is 2–7:1
- ✔ The onset of the disease is usually between 15 and 35 years of age, and it can take up to 10 years before the diagnosis is made
- ✔ The imaging modalities of choice are standard radiographs and MRI. Computed tomography is useful for diagnosing occult fractures and for preoperative planning
- ✔ Ankylosing spondylitis is treated non-operatively by analgesics, anti-inflammatory drugs and physiotherapy
- ✔ Spinal surgery is only indicated if conservative treatment has failed to prevent spinal deformities and instabilities or in the case of disc space infections
- ✔ The surgical techniques for treating spinal deformity, instabilities and infections depend on the localization and etiology of the pathology
- ✔ Surgical techniques include lumbar closing wedge (pedicle subtraction) osteotomies, multisegmental posterior wedge osteotomy, cervical opening or closing wedge osteotomies
- ✔ Meticulous preoperative planning of the osteotomy is mandatory
- ✔ Unstable fractures with neurological dysfunctions at the cervical spine are stabilized from a combined anterior and posterior approach. In the lumbar spine, the surgery is most frequently done from posterior
- ✔ Surgical interventions for ankylosing spondylitis are prone to complications

## Epidemiology

**Spondyloarthropathies** (SPAs) are systemic and chronic inflammatory rheumatic disorders with involvement of the axial skeleton or asymmetrical arthritis of large joints of the lower extremities.

Spondyloarthropathies are chronic systemic inflammatory rheumatic disorders

SPAs are divided into **five subcategories:**

- ankylosing spondylitis
- psoriatic arthritis
- reactive arthritis
- inflammatory bowel disease related arthritis
- undifferentiated spondyloarthropathy

Ankylosing spondylitis (AS) is the most common form of SPA affecting the whole spine [7, 17, 20, 105]. The final result is a kyphosis of the whole column with sagittal imbalance (Case Introduction). Besides spinal ankylosis, inflammatory lesions, bony erosions, discitis and loss of bone mineral density (BMD) can occur during the process of this disease. AS was described for the first time by Vladimir von Bechterew in 1893 [9]. The description was initially based on clinical symp-

Ankylosing spondylitis is the most common form of SPA

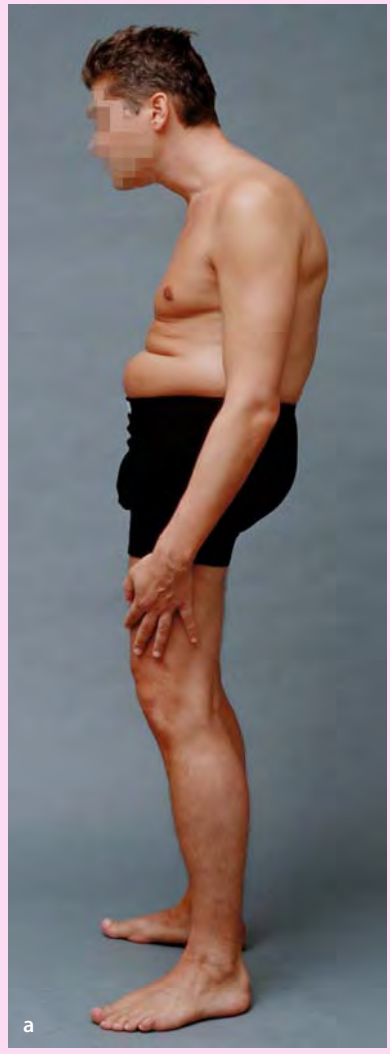

## Case Introduction

A 42-year-old male had suffered from ankylosing spondylitis for over 10 years and developed a progressive ankylosis of the entire spine. Despite intensive physiotherapy, the patient developed an increasing sagittal deformity and loss of his vertical gaze (a). When shaking hands, he was unable to look at his counterpart, which was quite disturbing in his job. The standing lateral radiograph demonstrates a significant loss of lumbar lordosis (b). Since the pathology was predominantly located in the lumbar spine, a lumbar closing wedge osteotomy at L3 was suggested and carried out.

toms and the spinal deformity. With the advance of radiography, it was possible to document the articular changes. AS is associated with **chronic inflammation** of the:

- sacroiliac joints
- vertebral column
- osteoarthritis of the large joint (hip, knee and shoulder joints)
- extra-articular disorders including enthesitis and uveitis

AS more frequently occurs in males

Ankylosing spondylitis occurs more frequently in the male population with a ratio of between 2 and 7 to 1 [28, 31, 43, 49, 53, 79, 105]. The prevalence rate in Europe and North America ranges between 0.1 and 1.4/100 000 and regionally

**Case Introduction** (*Cont.*)

Postoperative radiographs (c, d) demonstrate an excellent correction and alignment of the spine with recreation of lumbar lordosis. At a 2-year follow-up, the patient was very satisfied with the result, able to look straight ahead and fully functional in his job (e).

can rise up to 8.2/100 000 [87]. The onset of disease is usually between 15 and 35 years. Up to 10 years can pass before the diagnosis is made [40, 43, 49, 79].

The onset of disease is usually between 15 and 35 years of age

This delay in diagnosis is due to the initially non-specific clinical symptoms (e.g., low back pain) and lack of early pathognomonic imaging findings. During the later disease stage, **inflammatory spinal lesions** can be found which most commonly occur in the thoracic and lumbar spine [8, 105]. Aseptic spondylodiscitis is an erosive lesion of the disc and vertebral body without infection or trauma, first described by Andersson in 1937 [2]. Clinical and radiographic findings demonstrate a progressive vertebral and discovertebral kyphosis with segmental instability [99, 103]. The prevalence of aseptic discitis is about 18 % of patients with AS [61]. Almost half (40 – 50 %) of the patients with mild AS exhibit osteopenic or osteoporotic lumbar vertebrae [6, 94, 107]. Severe complications of osteoporosis and loss of trabecular bone are **spinal fractures** subsequent to minor trauma. The prevalence of spinal fracture is about 5 % and increases with age [40]. It reaches about 15 % at the age of 42 years and older [40]. Unilateral

AS is characterized by progressive kyphosis with segmental instability, aseptic discitis and osteoporosis

The prevalence of spinal fractures is about 5 % and increases with age

AS also frequently affects hips, knee and shoulder joints

inflammation of large diarthrodial joints such as hips, knees and shoulders is a common symptom of SPA. Hip joints are affected in 57 % of patients [37]. The prevalence of unilateral shoulder arthritis in patients with AS is estimated to be between 30 % and 58 %. Approximately 25 % of AS patients even suffer from bilateral shoulder arthritis [37, 38, 43]. Besides changes in physical function, other areas also affect the **quality of life** such as [12]:

- psychological domain [67]
- social domain
- economic aspects

A disease duration of 15 years is associated with a 50 % inability to work

After a disease duration of 15 years, about 50 % of patients are usually no longer able to work full time [43]. Up to 80 % of patients suffer from daily pain and more than 60 % need to take painkillers daily [43]. In addition, anxiety and depression are correlated with the degree of disorder [45, 67].

## Pathogenesis

Despite intensive research, the pathogenesis of AS is not yet clear [19]. There is increasing evidence that AS is genetically linked. The association of AS and the **HLA-B27 gene** is well known. *HLA-B27* can be found in up to 90 % of patients with AS [49, 79, 105]. The *HLA-B27* gene is mapped to the major histocompatibility complex (MHC) class I region on the short arm of chromosome 6 [55]. There are 24 subtypes of *HLA-B27* [54, 55]. The subtype *HLA-B27 05* is most common worldwide. Twin studies have shown that AS is passed on to the next generation with a higher incidence for monozygotic than for dizygotic or even heterozygotic parent-child pairs [24, 49]. Since 80 – 90 % of all *HLA-B27* carriers do not develop AS, it is widely assumed that more genetic factors are involved [87]. *HLA* subtype carriers *B27 06* (found in the Southeast Asian population) and *B27 09* (Sardinian population) do not develop AS [54, 55], which also strongly indicates the existence of other genetic factors. Whole genome mapping and within-family studies have demonstrated a link between AS and other non-*HLA-B27* genes mainly on the short arm of chromosome 6 [23, 62, 89, 93].

The pathogenesis of AS is not clear

Genetic factors play a key role

Bacterial infections may trigger autoimmune responses

An **infection-based pathogenesis** of AS has been the subject of critical debate [19, 41, 66, 96]. Antigenic peptides are thought to derive from bacterial proteins (*P. aeruginosa, E. coli* and *Bacillus megaterium*) which have a similar alignment of amino acids like peptides inside articular joints [41, 66]. *HLA-B27* restricted CD8-T lymphozytes are suspected of identifying the bacterial protein as a target and thereafter could also aim at peptide structures inside the sacroiliac joint or vertebral column resulting in an autoimmune reaction with inflammatory signs. The finding that reactive arthritis is triggered by genitourinary infections with *Chlamydia trachomatis* or by enteritis caused by gram-negative enterobacteria (e.g., *Shigella, Salmonella, Yersinia* and *Campylobacter*) supports this hypothesis, but the evidence for triggering infections in other spondylarthopathies is limited [19].

Inflammatory reactions play a key role in the pathogenesis

The detailed pathogenetic mechanisms have yet to be elucidated for associated **bone mineral density loss**, bony lesions as well as the **formation of new bone** material ending up in **ankylosis**. It is assumed that new bone formations are independent of local inflammatory processes [66]. On the other hand, there is some evidence that persistent inflammation might be an etiologic factor of bone loss in AS [65]. Consequences of bone loss are (occult) fractures and pseudarthrosis, in which microscopically necrotic bone material and cartilage can be observed besides vascular fibrous tissue [39]. The existence of an **aseptic discitis** supports an inflammatory origin for bony changes. CD3+ lymphocytes and IgA

positive plasma cells have been identified in vertebral bones and the surrounding soft tissue affected by aseptic discitis [76]. Blood markers for inflammation (CRP, ESR) are found elevated in aseptic discitis as well [61, 76]. After local inflammatory processes, disc replacing fibrous tissue and cartilaginous nodules have been identified in later stages of aseptic discitis [27, 61]. Bone marrow from zygapophyseal joints demonstrates persistent inflammation even in those patients with long-standing disease. The findings of increased numbers of T cells and B cells and neoangiogenesis suggest that these features play a role in the pathogenesis of AS [3].

Stages of pathological changes include inflammatory responses, proliferative bone sclerosis and ankylosis with increasing deformity

**Pathological changes** of the vertebral column due to AS occur in three consecutive or side by side stages: First, there is an **inflammatory process** with bony erosions and destruction of vertebrae and discs. The development of square vertebral bodies is shown to be based on a combination of a destructive osteitis and repair [5]. These changes initially are noted in the whole spine yet more frequently are seen in the lower thoracic spine [8, 105]. Second, a **proliferatory bone sclerosis** develops followed by a reactive bone formation with syndesmophytes. These changes are slow in growth throughout the whole spine followed by kyphotic deformation and progressive sagittal imbalance of the spine. Third, the **spine deformity will increase** to an ankylosing process and end in a so-called bamboo spine.

The rationale of conservative therapy is to protract the consequences of inflammation and osteoporosis and defer structural damage to the affected bones. The finding of abundant **tumor necrosis factor** (TNF)-α message in affected joints provides the rationale for the therapeutic use of TNF-α inhibitors [18, 19]. A strategy of continuous use of non-steroidal anti-inflammatory drugs (**NSAIDs**) has been shown to reduce radiographic progression in symptomatic patients with AS, without increasing toxicity substantially [102]. Early treatment therefore appears essential for a good clinical outcome [15, 71].

## Clinical Presentation

### History

The diagnosis is often delayed

Ankylosing spondylitis predominantly affects the mobility of the vertebral column, joint function and pain. This entity is sometimes difficult to diagnose particularly during the onset of the disease. Quite often the diagnosis is therefore delayed.

It is important to consider the diagnosis of AS in patients who present with **early symptoms** such as:

- morning stiffness
- pain in the pelvic region (sacroiliac joints)
- pain at night
- decreasing pain during movement
- musculoskeletal pain at varying locations
- fatigue
- loss of body weight
- subfebrile temperature

When AS has become manifest, the disease affects the function and mobility of the spine and diarthrodial joints and results in pain. The **cardinal symptoms** are:

Inflammatory back pain is a hallmark

- "inflammatory" back pain
- typical arthritis pain (pain at night and stiffness in the morning)
- progressive spinal stiffness
- progessive hyperkyphosis (inability to look straight ahead)

**Table 1.** Criteria for inflammatory back pain

| | |
|---|---|
| • morning stiffness > 30 min | • improvement in back pain with exercise but not with rest |
| • awakening because of back pain during the second half of the night | • alternating buttock pain |

The criteria are fulfilled if at least two of four of the parameters are present [80]

Inflammatory pain is among the first symptoms and the key clinical sign of AS. The criteria [80] for **inflammatory back pain** in younger patients (< 50 years) are shown in Table 1.

Rudwaleit reported that none of the single parameters sufficiently differentiated AS from mechanical low back pain. Several sets of combined parameters proved to be well balanced between sensitivity and specificity. If at least two of the aforementioned four parameters were fulfilled (positive likelihood ratio 3.7), a sensitivity of 70.3 % and a specificity of 81.2 % was found. If at least three of the four parameters were fulfilled, the positive likelihood ratio increased to 12.4 [80].

**Additional symptoms** are:

- enthesitis (e.g., Achilles tendon, plantar fascia)
- anterior uveitis
- pulmonary, cardial and bowel inflammation

Typical concomitant disorders or extra-articular manifestations have been observed to be part of AS: painful tendinopathy, acute anterior uveitis (AAU), pulmonary and cardial inflammation, e.g., aortitis, and bowel disease. The frequency, duration and intensity of these concomitant disorders varies individually. The prevalence of AAU is between 33 % and 49 % [21, 25, 43]. AS is perceived as a systemic disease.

AS is a systemic disease

## Physical Findings

Ankylosing spondylitis is a potentially progressive disease. The first symptoms of AS are mild and non-specific.

The physical findings are often non-specific

Frequent **physical findings** are:

- pain provocation of sacroiliac joints (positive Mennell test)
- decreased spinal mobility (Schober and Ott test)
- anterior sagittal imbalance (plumbline falling in front of the hip joint)
- coronal spinal imbalance (less frequently)
- reduced chest expansion during inspiration and expiration after a chronic progression
- loss of body height

A neurological examination of the upper and lower extremities is mandatory to diagnose neural compression. In the presence of severe back pain, it is mandatory to rule out a **spinal instability** or an **occult fracture** [34, 42] in order to prevent neurological deterioration due to epidural bleeding or secondary fracture displacement [77, 78]. Compensatory balance adjustment occurs in the cranial segments of the cervical spine as a direct consequence of the AS associated column stiffening. Furthermore, an increased force effect for the small vertebral joints can be observed with the risk of atlanto-occipital subluxation or even a vertebral dislocation. Pain, stiffness and reduced range of motion in peripheral joints can occur at any stage of the disease. A thorough examination of the large diarthrodial joints and the search for enthesopathies is compulsory in addition to the mandatory clinical examination of the spine [37, 38].

Rule out spinal instability or an occult fracture in cases of severe back pain

## Diagnostic Work-up

The ultimate goal is to diagnose AS as early as possible so as to start an appropriate therapy. When AS is suspected, a thorough diagnostic assessment must be enforced because early diagnosis can improve treatment outcome. A positive family history and reports of typical arthritis symptoms such as pain at night and stiffness in the morning can be helpful. In addition to the physical examination, the diagnostic work-up comprises laboratory investigations, including *HLA-B27* determination and imaging studies.

Early diagnosis can improve treatment outcome

### Laboratory Investigations

The most **important laboratory investigations** are:

- C-reactive protein (CRP)
- elevated erythrocyte sedimentation rate (ESR)
- white blood cell count (WBC)
- determination of *HLA-B27* only in symptomatic patients

These inflammation markers are sensitive but non-specific [35, 36, 68, 69]. Occasionally, a light anemia can be observed. The sensitivity of *HLA-B27* determination is about 90 % but the specificity is low since up to 80 % of *HLA-B27* carriers do not suffer from AS [43, 49, 54]. The laboratory examination could evolve to a better diagnostic tool through the identification of non-major histocompatibility complex (n-MHC) "genetic susceptibility factors" in AS using gene mapping techniques [23, 55, 62].

Inflammatory markers are sensitive but non-specific

### Imaging Studies

Besides the typical clinical signs and laboratory investigations, the imaging studies are essential for the early diagnosis of AS. However, imaging findings of acute inflammation, or bony alterations of sacroiliac joints (SI joints) or vertebral column, can be absent in the early stages of AS (Fig. 1). **Imaging studies** of the spine are **essential to**:

- make the diagnosis of AS
- exclude fractures, spondylolisthesis or Andersson lesions
- assess sagittal imbalance
- monitor progress of the disease
- assess the treatment effect

Clinical examinations are complemented by various imaging studies (X-ray, CT, MRI and bone scan). However, **whole-body MR imaging** will more and more be used to monitor inflammatory spinal lesions at an early or an active stage of disease. The possibility of evaluating shoulder and hip joints together with the axial skeleton is the major advantage of whole-body MRI [105].

Signs of acute inflammation and bony alterations can be absent in early stages

#### Standard Radiographs

Standard radiographs of the spine and sacroiliac joints (SIJs) remain the **mainstay of diagnostic imaging** for AS (Fig. 1a).

The hallmark of AS is a sacroiliitis and at a later stage ankylosis of the SIJs (Fig. 1a–c). Radiologic alterations of the SIJs are differentiated by the modified New York classification [97] into **four grades** (Table 2).

Standard radiography remains the mainstay of diagnostic imaging

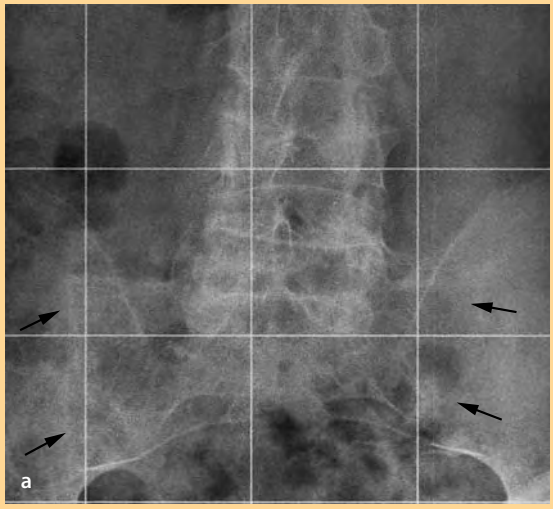


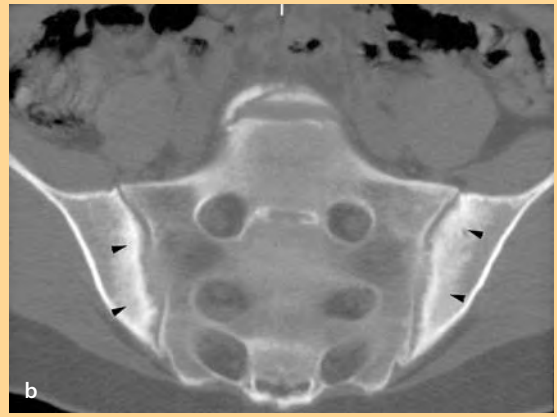


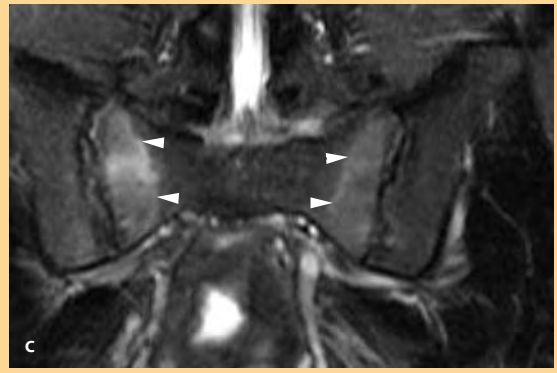

**Figure 1. Typical imaging findings**

a Endstage ankylosis of the sacroiliac joint (SIJ). b Dense sclerosis and irregularities of the SIJ at the iliac side. Note the osseous bridges crossing the SIJ. c STIR sequence showing increased signal intensity within the SIJ at the sacral side. Joint irregularities are less visible on MRI compared to CT. d Typical syndesmophyte with calcification of the longitudinal ligament and outer anulus fibrosus. Note the preserved disc height.

**Table 2.** Radiologic grading of sacroiliac joint alterations

| | |
|---|---|
| **Grade I** | • suspicious |
| **Grade II** | • evidence of erosion and sclerosis |
| **Grade III** | • Grade II and ankylosis |
| **Grade IV** | • complete ankylosis |

New York criteria [97]

However, inflammatory processes in AS must be well differentiated from a septic sacroiliitis (e.g., *Staphylococcus aureus, Streptococcus* species). Septic sacroiliitis (SS) is a rare disease. Typically a septic sacroiliitis shows non-specific symptoms similar to AS such as low back pain, pain in the pelvic region, and related pain in varying locations (hip joints).

The radiologic hallmark is a sacroiliitis

**Typical radiological changes** of the spine indicative of AS are [20, 58]:

- bony erosions
- bony sclerosis
- syndesmophytes
- Andersson lesions (erosive discovertebral lesions) [61]
- ankylosis (bamboo spine)
- vertebral osteoporosis

**Syndesmophytes** as a result of an ossification of outer anulus fibrosus (Sharpey's fibers) must be differentiated from osteophytes by their shape and site (Fig. 1d). Syndesmophytes exhibit a slow growth from the cervical to the lumbar spine [17] leading to a kyphotic deformation of the entire spine and often resulting in a progressive sagittal imbalance. The **kyphotic deformity** is most pronounced in the thoracic spine.

Syndesmophytes must be differentiated from osteophytes

During the advanced stage of the disease, **vertebral column alterations** can include:

- severe kyphotic spinal deformity with sagittal imbalance
- spinal fractures (often occult) [42, 57, 75]
- atlanto-occipital instability

Patients with AS are susceptible to fractures of the spinal column which are frequently overlooked. The fractures are atypical compared to fractures of the undiseased bone [57] and frequently involve all three spinal columns [103]. Radiographs are strongly recommended after each single trauma with pain symptoms. Persistent pain even after minor trauma should prompt a thorough imaging work-up.

Rule out spinal fractures in case of trauma

### Magnetic Resonance Imaging

Magnetic resonance imaging (MRI) provides an excellent depiction in early stages of the inflammatory disease. Standard examinations **searching for inflammatory alterations** are done in the coronal and sagittal plane using fluid sensitive sequences with fat signal suppression, e.g., short tau inversion recovery (**STIR**) sequence. The advantage is a better contrast of fat and water which results in a better sensitivity for inflammatory spinal lesions than in T1-weighted MRI after contrast enhancement [7, 8]. The STIR sequence is also helpful in diagnosing occult fractures of the vertebral column indicated by indirect signs of a bony edema or soft tissue (Fig. 1c).

Magnetic resonance imaging can demonstrate injuries to the ligaments or sequelae of spinal trauma, e.g., neural compromise and epidural hematoma. Therefore, especially at the level of the cervical column, MRI should be compul-

MRI can demonstrate inflammatory alterations early

Examination of AS patients in the MR magnet is difficult because of the spinal deformity

sory [75]. MRI does not show fewer fractures for the whole spine than computed tomography (CT) [103]; however, a disadvantage of MRI is the difficult examination of dorsal elements of the vertebral and cervical columns, e.g., facets. In these cases detection of fractures with MRI can be difficult [57].

**Characteristic findings** of MRI suggestive of AS are [17, 105]:

- discitis
- erosions
- syndesmophytes
- partial fusion
- ankylosis

Signs of an **inflammatory lesion** are:

Differentiate inflammatory and septic sacroiliitis

- **subchondral sclerosis** without increased signal after contrast enhancement
- **edema-like bone marrow abnormalities** (by STIR and/or contrast enhanced sequences)
- **fatty replacement** of subchondral bone marrow of SI joints

Magnetic resonance imaging allows the differentiation of inflammatory and septic sacroiliitis. **Signs** indicative of a **septic origin** are [91]:

- anterior and/or posterior subperiosteal infiltrations
- transcapsular infiltrations of juxta-articular muscle layers

### Computed Tomography

The spine can be precisely visualized with 3D CT imaging, particularly the dorsal elements (posterior longitudinal ligament, spinous process and facet joints), which are more difficult to visualize with MRI [57, 103]. A spiral CT with multiplanar reconstruction can improve the image resolution, which makes identification of bone fractures easier and thus helps in elucidating "**occult**" fractures [46].

CT scan is helpful in the detection and localization of spinal fractures

The domain of the CT is the diagnosis of fractures. Patients with AS can sustain fractures after minor trauma [42, 57, 75, 78, 103] or even without recalling a trauma [77]. Furthermore, CT can be utilized for preoperative planning of corrective spinal osteotomies.

### Bone Scan

Bone scan remains a screening tool for inflammatory processes

Bone scans still play a role as a **supraregional screening modality** for inflammatory reactions. The scintigraphy is less sensitive than an MRI scan for detecting a sacroiliitis (61 % vs. 55 %) [48]. The specificity of a sacroiliac joint scintigraphy is reduced due to a high bone turnover metabolism [20]. However, the scintigraphy is a good alternative method for diagnosing AS in the early stages, at the time when typical radiological changes of SI joints are missing in standard radiographs [48, 83]. A scintigraphy can also be useful in the search for inflammatory lesions or aseptic discitis. The location of the spine pathology is important for differentiation between a fracture, metastasis, inflammatory lesions or discitis.

## Diagnostic Criteria

The diagnosis is difficult at an early stage

The diagnosis of AS is difficult at an early stage because of non-specific clinical symptoms and a lack of radiological signs. Therefore, AS often remains undiagnosed for several years. The **most frequent clinical symptom** in AS is a **sacroiliitis**, which is present in 90 % of all chronic cases. However, in the early stages a sacroiliitis can be absent in 70 – 90 % of all cases [81]. Other typical clinical symptoms and signs are inflammatory back pain, progressive spinal stiffness and

reduced chest expansion. At the level of the spinal column inflammatory lesions appear mainly at the thoracic level [8, 17, 105]. Chronic inflammatory alterations appear at all levels of the vertebral column. Mainly affected are spinous processes and facet joints [105]. The modified New York criteria allow the diagnosis of AS (Table 3) [97]:

**Table 3.** Modified New York criteria for ankylosing spondylitis

| Clinical criteria | Radiologic criterion |
|---|---|
| • low back pain and stiffness for more than 3 months which improves with exercise, but is not relieved by rest<br>• limitation of motion of the lumbar spine in both the sagittal and frontal planes<br>• limitation of chest expansion relative to normal values corrected for age and sex | • sacroiliitis grade 2 bilaterally, or sacroiliitis grade 3–4 unilaterally |

Definite AS is present if the radiological criterion is associated with at least one clinical criterion [97]

The modified New York criteria differentiate non-active and active stages of AS. An active stage is defined as persisting clinical symptoms for a minimum of 6 months.

Diagnosis is still difficult and based on the presence of multiple findings

## Non-operative Treatment

Ankylosing spondylitis is a **chronic, systemic disease** which cannot be cured. All treatment measures remain palliative, i.e., can reduce clinical symptoms and slow disease progression and ankylosis. The general objectives of treatment are (Table 4):

**Table 4.** General objectives of treatment

| | |
|---|---|
| • control of inflammatory processes | • pain relief |
| • prevention of disease progression | • preservation of spinal balance |
| • preservation of spinal mobility | • improvement of quality of life |

## Natural History

Ankylosing spondylitis is a chronic inflammatory disorder with varying disease progressions and accordingly mild to severe clinical symptom intensity. However, in less than 1% of all patients a long term remission has been described [52]. **Progression** of ankylosing spondylitis is **usually linear** [22] and affects either isolated structures or a combination of them [106]:

Ankylosing spondylitis is a chronic inflammatory disorder with a varying level of disease

- sacroiliac joints
- axial skeleton
- peripheral joints
- extra-articular structures

In spondylarthopathies in general, several **prognostic factors** have been identified which correlate with disease severity [1]:

- hip arthritis
- high erythrocyte sedimentation rate (>30 mm/h)
- poor efficacy of non-steroidal anti-inflammatory drugs
- limitation of lumbar spine
- sausage-like finger or toe
- onset 16 years

Hip involvement is a strong predictor of poor outcome

If none of these factors is present at entry, a mild outcome can be predicted with a high sensitivity (92.5 %) and specificity (78 %). If a hip is involved or if three factors are present, a severe course is predictable (sensitivity: 50 %) and a mild disease practically excluded (specificity: 97.5 %) [1]. In particular, hip involvement has been demonstrated as a predictor of poor outcome [22]. There is an increase in the prevalence of spinal fracture with age [40], which has been associated with a decreased bone mineral density [64] though the intensity of the disease itself is independent of age [21].

## Non-operative Management

Early treatment improves the clinical course

It has been demonstrated that early treatment can improve the clinical course and general treatment outcome [13, 15]. The **mainstay of treatment** remains drug therapy in conjunction with structured exercise programs. However, debate continues on the effect of structured exercise programs [19]. The current best available evidence suggests that physiotherapy is beneficial for people with AS. However, it is still not clear which treatment protocol should be recommended in the management of AS [32].

### Pharmacological Therapy

There is a rank order for drug therapy

The medication armamentarium includes [19, 110]:

- non-selective and selective cyclooxygenase (COX) inhibitors (NSAIDs)
- analgesics
- disease modifying antirheumatic drugs (e.g., sulfasalazine)
- corticosteroids
- TNF-α inhibitors

NSAIDs are the first choice for treatment

In a "rank order," **NSAIDs** represent the first choice of medication and are given continuously or during the onset of disease. However, the individual response depends on the agent and often several different medications have to be tested. When continuously applied, patients with NSAIDs show reduced pain and increased activity in daily life [13, 15, 71]. Also one study with NSAIDs as a therapy for AS led to the inhibition of radiographic progression [102]. Typical side effects of non-selective NSAIDs are gastrointestinal ulcera and bleeding, whereas COX-2 selective inhibitors show cardiovascular complications. When NSAIDs fail, disease-modifying antirheumatic drugs (**DMARDs**), i.e., sulfasalazine or methotrexate, can be used as an alternative. Sulfasalazine is used against peripheral joint pain. There is no objective evidence that treatment with DMARDs is effective for AS [13]. When inflammation cannot be controlled by the aforementioned drug therapy, **inhibitors of TNF-α** are indicated (e.g., infliximab, adalimumab and etanercept). These monoclonal antibodies show a significant improvement in function, spinal mobility and quality of life in comparison to placebo [13, 15, 71]. In addition, a significant regression of spinal inflammation can be demonstrated [16]. The hope is that with suppression of spinal inflammation structural damage of bony structure can be delayed. The clinical outcome is slightly worse when these medicinal drugs are used for the treatment of chronic AS compared to acute AS [15, 71]. Therefore, an early diagnosis is essential. However, severe side effects have been reported with the use of TNF-α inhibitors, e.g., leukopenia, allergic pulmonal reactions and reactivation of tuberculosis disease [13].

TNF-α inhibitors are potent and effective pharmacological agents but are not without serious side effects

## Physiotherapy

Physiotherapy is an essential part of treatment

Besides medical treatment physiotherapy plays an important role [31, 32, 101]. Main goals are pain reduction, prevention of hypomobility of the affected segments and improvement of activity of daily life [32]. Continuous physiotherapy should take place and the patient should perform a **daily home exercise program**. A high level of motivation and compliance by the patient could substantially improve outcome. The primary goal of the physiotherapy is postural exercises which should preserve the natural spinal alignment during the process of ankylosis. Study results showed that supervised group physiotherapy programs were better than individualized home exercise regimes and individualized home exercises were better than no physiotherapy [31].

### Patient Education

Patient education is a very important treatment component

Patient education is a very important component with the ability to support all the therapeutic measures applied to patients suffering from ankylosing spondylitis. In most developed countries efficient **self-help organizations** have been established aiming for a better information policy, awareness of ankylosing spondylitis in the public as well as supporting the affected individual. Self-help organizations are key to an integrated therapeutic approach by medical doctors, physiotherapists, patients and their families. Through the excellent cooperation of medical doctors, physiotherapists, patients and their relatives, the incidence of neglected, untreated and therefore upsetting chronic cases is very low in Switzerland.

## Treatment Recommendations

A combined ASsessment in Ankylosing Spondylitis (ASAS) working group and European League Against Rheumatism (EULAR) task force has postulated a flowchart and ten main recommendations for the management of AS (Fig. 2, Table 5).

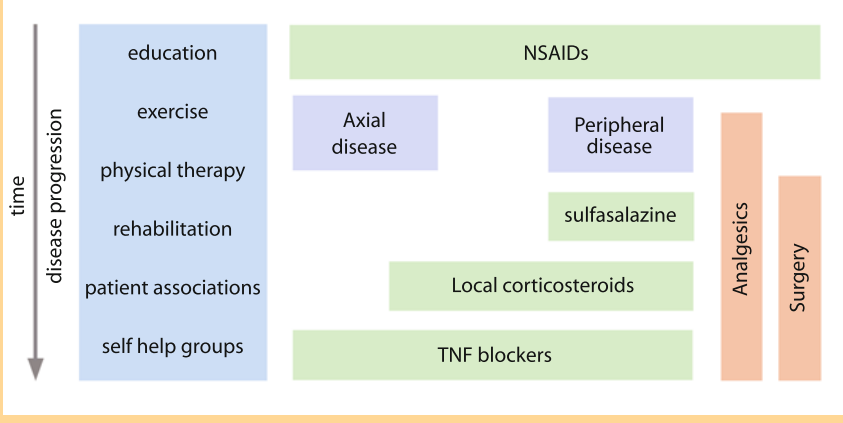


**Figure 2. Treatment recommendations**

ASAS/EULAR flowchart summary (modified) of the recommended management of AS based on clinical expertise and research evidence [110].

**Table 5.** Expert propositions on treatment

- Treatment of AS should be tailored according to:
  - current manifestations of the disease (axial, peripheral, entheseal, extra-articular symptoms and signs)
  - level of current symptoms, clinical findings, and prognostic indicators
  - disease activity/inflammation
  - pain
  - function, disability, handicap
  - structural damage, hip involvement, spinal deformities
  - general clinical status (age, sex, comorbidity, concomitant drugs)
  - wishes and expectations of the patient
- Disease monitoring of patients with AS should include: patient history (for example, questionnaires), clinical parameters, laboratory tests, and imaging, all according to the clinical presentation, as well as the ASAS core set. The frequency of monitoring should be decided on an individual basis depending on symptoms, severity, and drug treatment
- Optimal management of AS requires a combination of non-pharmacological and pharmacological treatments
- Non-pharmacological treatment of AS should include patient education and regular exercise. Individual and group physical therapy should be considered. Patient associations and self-help groups may be useful
- NSAIDs are recommended as first line drug treatment for patients with AS with pain and stiffness. In those with increased GI risk, non-selective NSAIDs plus a gastroprotective agent, or a selective COX-2 inhibitor, could be used
- Analgesics, such as paracetamol and opioids, might be considered for pain control in patients in whom NSAIDs are insufficient, contraindicated, and/or poorly tolerated
- Corticosteroid injections directed to the local site of musculoskeletal inflammation may be considered. The use of systemic corticosteroids for axial disease is not supported by evidence
- There is no evidence for the efficacy of DMARDs, including sulfasalazine and methotrexate, for the treatment of axial disease. Sulfasalazine may be considered in patients with peripheral arthritis
- Anti-TNF treatment should be given to patients with persistently high disease activity despite conventional treatments according to the ASAS recommendations. There is no evidence to support the obligatory use of DMARDs before, or concomitant with, anti-TNF treatment in patients with axial disease
- Total hip arthroplasty should be considered in patients with refractory pain or disability and radiographic evidence of structural damage, independent of age. Spinal surgery – for example, corrective osteotomy and stabilization procedures – may be of value in selected patients

ASAS/EULAR expert propositions on the management of AS developed through three Delphi rounds [110]

## Operative Treatment

### General Principles

Indications for surgery are rare in patients under rheumatologists' surveillance

Surgical intervention is rarely necessary in cases with AS when the patient is under medical surveillance with a baseline therapy and physical exercises. However, in some cases the inflammatory process cannot be controlled very well and spinal deformities develop [21, 22]. Indications for surgery are strong limitations in daily life due to progressive kyphotic deformity and unacceptably severe chronic pain non-responsive to conservative management. The usual age at surgery is in the late 30s and 40s [28, 29, 108]. Patients with AS are prone to developing spinal fractures [34, 40, 77] and discitis [61]. In these cases, surgery is indicated (Table 6):

**Table 6.** Indications for surgery

| Absolute | Relative |
|---|---|
| • unstable spinal fractures<br>• kyphosis-related progressive myelopathy<br>• progressive spondylodiscitis | • painful sagittal imbalance<br>• loss of horizontal gaze<br>• chin-chest impingement<br>• stable spinal fractures with delayed fracture healing<br>• segmental instability |

Conservative treatment of spinal fractures is often unsuccessful

In cases of spinal fractures, conservative treatment is often hampered by the concomitant sagittal imbalance leading to a high non-union rate and progressive deformity. Although there is a general trend for good bone healing in patients

with AS, there are individuals with very active disease in whom this is not the case. A rare side effect of a massive kyphotic deformation of the whole spinal column is **cauda equina syndrome**. This syndrome develops only after a long history of ankylosing spondylitis. Clinical symptoms are slowly progressive with sphincter disturbance and impotence. The pathogenesis is unclear. However, it is hypothesized that arachnoiditis can affect adherence of individual nerve roots to the arachnoidal surface. MRI showed florid, multilocular dural ectasia, marked irregularity and thickening of nerves, and adherence to the dural diverticula [30, 85]. Therapy consisted of a lumboperitoneal shunt, which is effective [51].

Cauda equina syndrome is a rare complication

## Planning of Osteotomies

The ultimate goal of surgery is to rebalance the spine and correct the **chin-brow to vertical angle** (CBVA) [92] to an extent that the patient is again able to look straight ahead, or to resolve a chin-chest impingement (in case of severe cervicothoracic kyphosis. It is very important to plan precisely the level and extent of the osteotomies because the spine usually cannot compensate for any resulting over- or undercorrections. It is also important to assess the mobility of the hip and knee joint and to consider the mobility of these joints in the planning for surgery. The planning can be done using:

Meticulous preoperative planning is mandatory to avoid over- or undercorrections which cannot be compensated

- lateral standing whole spine radiographs
- lateral photography [72]

Using the **whole spine lateral radiograph**, the vertebral bodies are traced out on transparent paper. The paper is cut with scissors at the level of the target osteo-

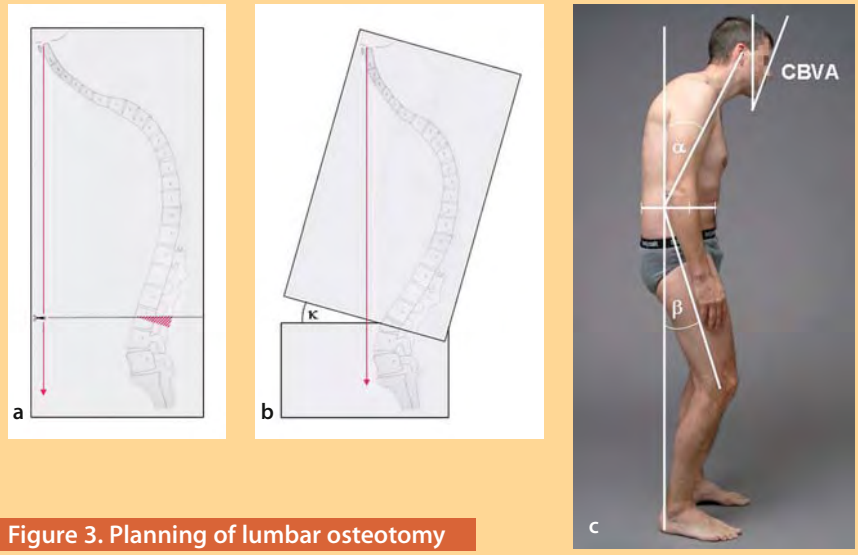


**Figure 3. Planning of lumbar osteotomy**

**Graphic planning:** a Transparent paper is placed over the whole spine standing lateral radiograph. The spine is traced out and the gravity line from C2 is added. The target level of the osteotomy is identified (*red area*). The paper is cut along the superior border of the osteotomy. b The upper part of the paper is rotated until the gravity line falls in front of the sacrum (or through the hip joints if depicted on the radiograph). The resulting angle κ is the target correction angle. The dens should be vertically oriented at the end of the planning. **Photographic planning:** c A horizontal line is drawn at the level of the umbilicus and graphically separated into three parts. A vertical line is drawn intersecting the horizontal line between the posterior and middle thirds. The intersection point of the two lines is connected to the meatus externus of the ear and the lateral femur condyle, respectively. The sum of the resulting angles α and β responds to the whole body kyphosis angle (WBKA) and is the target angle for correction. The chin-brow to vertical angle (CBVA) should be assessed and taken into account to avoid overcorrection.

tomy, which usually lies at L2 or L3 for lumbar subtraction osteotomies. The rotating hinge lies in the anterior vertebral cortex. The upper part of the drawing is then adjusted until sagittal balance is achieved. The required correction angle can then be measured as a result of the resulting overlap on the sketch (Fig. 3a, b). The maximum angle which can be achieved at one level is about 40 degrees [63, 72, 100]. Spinal corrections demanding more than 40 degrees of correction should rather be treated with a second osteotomy, which may be performed at the thoracic or lumbar level.

In cases of severe sagittal imbalance, radiographs cannot depict the whole spine on one film. In these cases, planning using lateral photography can be done as described by Min et al. [72] (Fig. 3c).

Potential problems related to patient positioning and intubation/ventilation must be considered

Another important aspect is the perioperative anesthesia. **Patient positioning and intubation** often are very difficult due to kyphotic deformation. The surgeon must take these issues into account prior to surgery. Furthermore, the vital capacity can be reduced because of a kyphosis-related restricted pulmonary disease. A **preoperative lung function test** is recommended. With the advent of intraoperative neuromonitoring, surgery using local anesthesia and sedation is outdated. Neuromonitoring is nowadays regarded as indispensable for a safe deformity correction (see Chapter 12).

## Surgical Techniques

The first corrective osteotomy of AS was described by Smith-Peterson in 1945 [90]. This surgical procedure in the thoracolumbar spine consisted of a monosegmental V-shaped opening wedge osteotomy during local anesthesia. Only later was this operation technique combined with internal stabilization, which was not available in the 1940s. Due to the relatively high rate of postoperative complications, new operation techniques such as the polysegmental posterior wedge osteotomy or the closing wedge (pedicle subtraction) osteotomy were introduced [11, 47, 74, 100]. Today, the monosegmental [28, 33, 63, 74] or polysegmental closing-wedge technique [45, 98] is preferred for the thoracolumbar region.

### Thoracolumbar Closing Wedge Osteotomy

The most common technique is a closing wedge osteotomy

The most common technique is the closing wedge osteotomy [50, 63]. In 1963, Scudese introduced this new technique with the aim of reducing perioperative and postoperative complications seen with the opening wedge osteotomy [86]. The underlying concept is to achieve a monosegmental extension while keeping the anterior longitudinal ligament intact. The procedure is usually carried out at the L3 or L2 level depending on the sagittal alignment.

The closing wedge technique consists of removal of the posterior elements including the pedicles (**pedicle subtraction osteotomy**) (Fig. 4, Case Introduction). This technique is often combined with a so-called **eggshell procedure** (i.e., decancellation of the vertebral body) [11, 33, 74]. A posterior wedge excision of the vertebral body is then performed under protection of the spinal cord. The closing wedge osteotomy can be applied to one or two lumbar vertebrae depending on the desired amount of correction. However, corrections of more than 40 degrees at one level should be avoided. In general, the outcome of closing wedge osteotomies (Table 7) is satisfactory [14, 45, 88]. However, function can only moderately be enhanced [45].

Corrections of more than 40 degrees at one level should be avoided

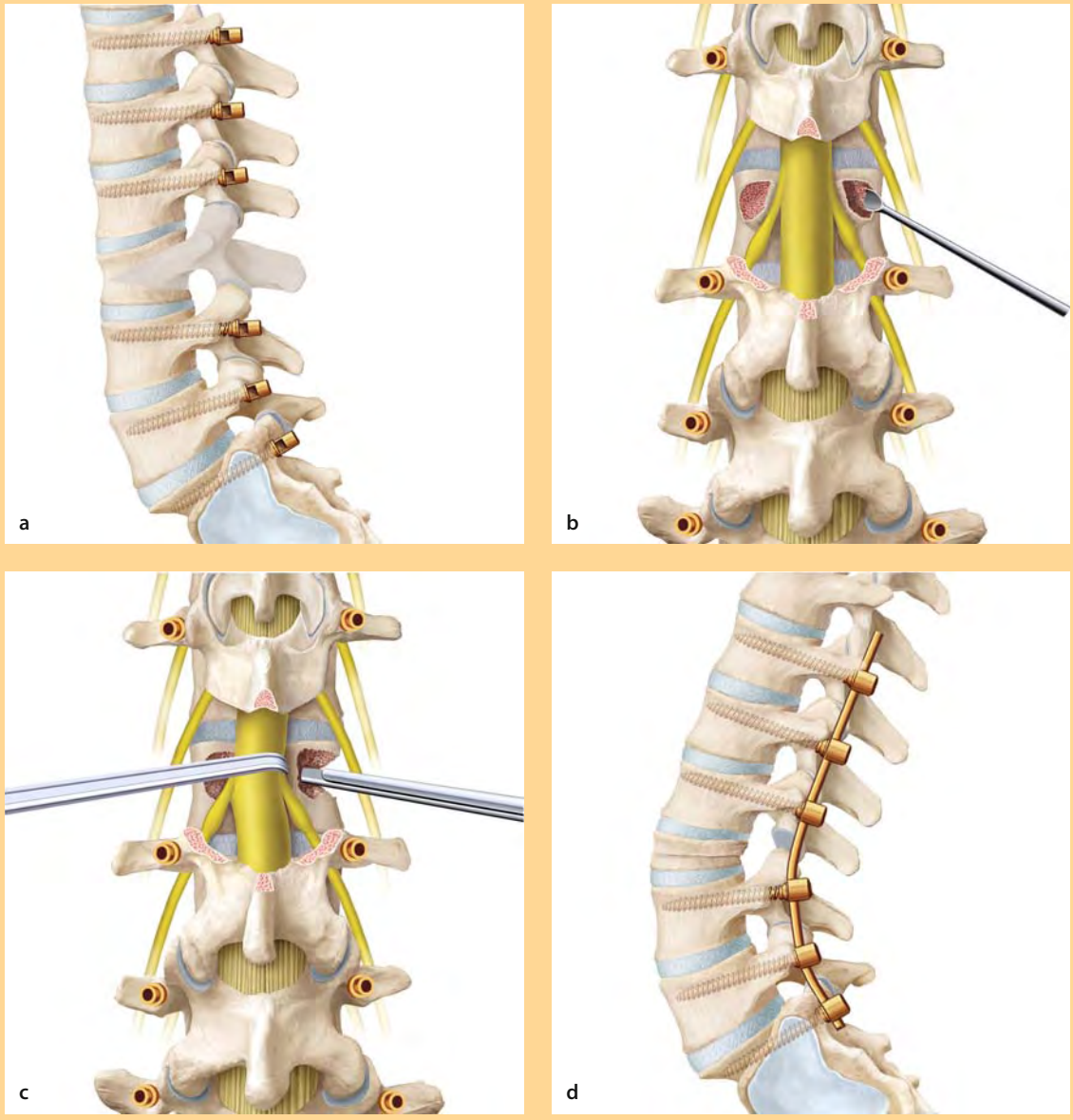


**Figure 4. Lumbar pedicle subtraction osteomy (closing wedge)**

a The osteotomy starts by instrumenting the spine with pedicle screws three levels above and below the osteotomy to allow for a rigid stabilization of the osteotomized spine. b The posterior elements (i.e., spinous, transverse laminae, and articular processes) are removed until only the pedicle stumps at the transition to the posterior wall of the vertebral body are left. The cancellous part of the vertebral body is then resected with curettes in the form of an "eggshell" procedure. c The remaining posterior bridge between the two wholes of the pedicle stumps is then resected by a large Kerrison rongeur. d The created wedge is then closed using a motorized operation table lordosing the whole patient. Posterior rods are applied further compressing the wedge resulting in a tension band osteosynthesis. A posterolateral fusion is added across the osteotomized level.

### Multisegmental Posterior Wedge Osteotomy

Main goal of the multisegmental V-shaped posterior wedge osteotomy (MPWO) is to address a thoracic kyphosis where extensive closing wedge osteotomies would jeopardize the spinal cord. This type of osteotomy results in a more har-

MPWO predominately addresses segmental thoracic kyphosis

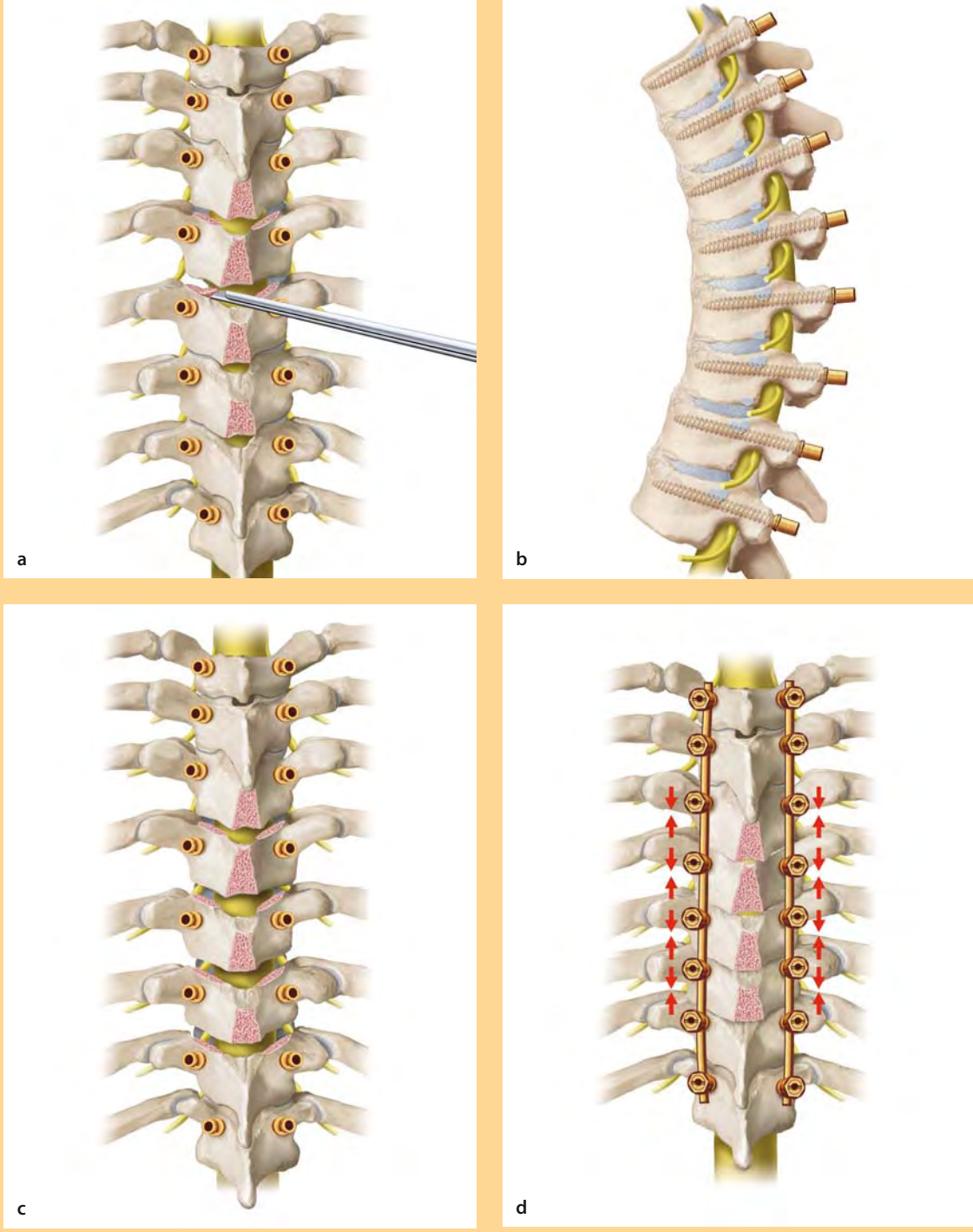


**Figure 5. Multisegmental posterior wedge osteotomy**

This technique creates lordosis and is usually applied to one or multiple levels. **a** The spine is instrumented with pedicle screws two levels above and below the planned osteotomies. **b** The interspinous ligament and the adjoining spinous process are resected with a rongeur. The yellow ligament is removed and v-shaped bilateral osteotomies are carried out through the isthmus. **c** These osteotomies are directed laterocranially at an angle of 30–40 degrees. The desired slot width of 5–7 mm is obtained by using appropriate rongeurs. If there is a scoliotic deformity, the osteotomies are made slightly larger on the convex side. **d** The rods are applied first cranially. The osteotomy gaps are closed by stepwise segmental compression and connection to the rods. A posterior spinal fusion is added. With one single osteotomy approximately 10 degrees of correction can be achieved.

monic bending of the spine. In contrast to a closing wedge osteotomy, the MPWO removes the posterior elements of a thoracic and/or lumbar level without the need for a wedge excision of the vertebral body (Fig. 5). Osteotomies can be performed at four to six thoracic or lumbar levels depending on the extent and location of the spinal deformity [47, 98]. With one singular osteotomy approximately 10 degrees of correction can be achieved [98]. The results of this technique are satisfying [47] (Table 7).

Osteotomies can be performed at four to six levels

### Cervical Wedge Osteotomy

Cervical closing wedge osteotomy corrects severe cervicothoracic kyphosis

A fixed cervicothoracic kyphotic deformity is rare (Case Study 1). However, this deformity can cause a significant morbidity because of an impingement of the chin with the chest, making eating and drinking difficult. Furthermore, patients lose their horizontal gaze. A cervical corrective osteotomy was first described by Urist in 1958 [95]. The **opening wedge osteotomy** was originally carried out at the level of C7/T1 during local anesthesia. The osteotomy level is chosen at the cervicothoracic junction because the vertebral artery only enters the spine at the level of C6. With the advent of neuromonitoring, these interventions can today be performed with the patient under general anesthesia and with less stress for the patient. The disadvantage of the opening wedge osteotomy is the resulting anterior gap with potential instability and need for an additional anterior fusion (Case Study 1). The correction of kyphosis can be balanced up to the level of lordosis and corrections have been reported up to 54° [70]. Webb advocates a **closing wedge osteotomy** because of a better stability without the need for an uncontrolled cracking of the spine to achieve the correction [104] (Fig. 6). Method of choice is a closing wedge osteotomy with or without an anterior interbody fusion depending on the fusion status of the anterior column. Case reports of chin on chest deformities so far show excellent resolution of the deformity and solid fusion [73]. Retrospective studies show that cervical spine surgery in AS appears to have a fairly good clinical outcome [56] (Table 7). However, this osteotomy is very demanding and carries a high risk of neurological injuries [60, 70].

### Treatment for Fracture and Spondylodiscitis

Fractures are most common at thoracic level and unstable

Fractures in AS patients are most commonly localized at the thoracic spine and are very often unstable because they involve the anterior and posterior column [10, 34, 77, 84, 109]. In contrast to a healthy individual, AS patients sustain fractures more easily from minor trauma and experience fatigue fractures. These fractures often remain occult (see above) as clinical symptoms are masked by chronic pain. Not infrequently, the spine spontaneously corrects its kyphotic deformity within the fracture (Case Study 2). Thirty to 75 % of cases are associated with severe neurological deficits [10, 34, 42, 77].

Instrumentation should be long rather than short in AS

The general concepts of treatment also apply (see Chapters 30, 31, 36) for spinal injuries in AS and aseptic spondylodiscitis (Andersson lesions). In contrast to common fractures and spondylodiscitis, however, the stabilization should be long rather than short because of the risk of a secondary kyphotic deformity, implant failure and non-union. The degree of instability in AS determines the use of long instrumentation over a minimum of two vertebral bodies above and below the lesion [59]. Laminectomy is indicated when defective positions or bony hypertrophy leads to constriction or stenosis of the spinal canal or in the presence of epidural hematoma. Operative fracture stabilization is preferred to allow for early mobilization of the patient. However, treatment of spinal fracture causing paralysis is difficult and controversial and is associated with a high risk of complications [4, 10, 34, 42, 77, 78, 109]. Surgical management

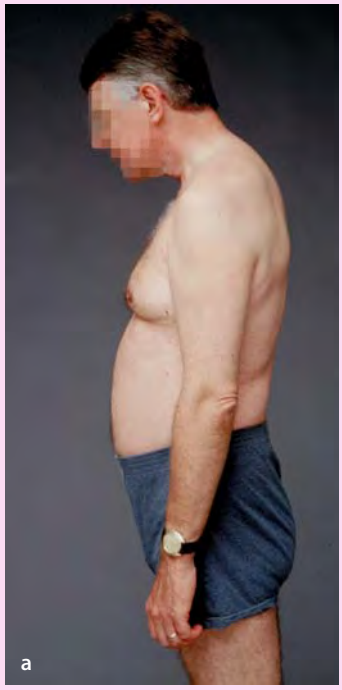
a

b

c

## Case Study 1

A 58-year-old male was diagnosed with ankylosing spondylitis, which had been present for over 20 years. The patient was severely handicapped by his inability to look straight ahead (a). The standing lateral radiograph demonstrated a sagittal well balanced spine with the deformity located at the cervicothoracic junction (b, c). A cervical opening wedge osteotomy at C7 was done (d). The spine was stabilized with facet joint screws at C4 and C5 and pedicle screw fixation at T1 (e). In a second stage, an anterior intercorporal fusion and plate/screw fixation was added to close the gap and additionally stabilize the spine (f). Postoperative photograph (g) shows an excellent correction of the position of the head.

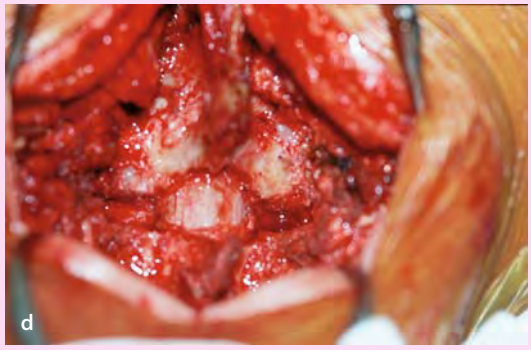
d

e

f

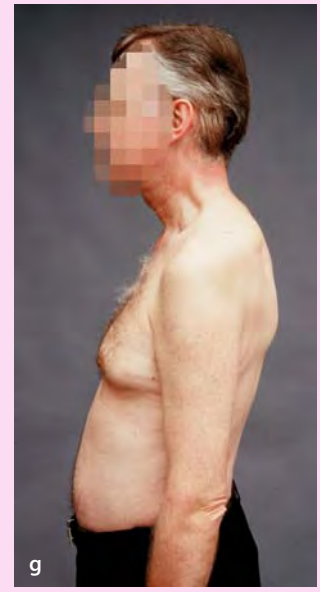
g

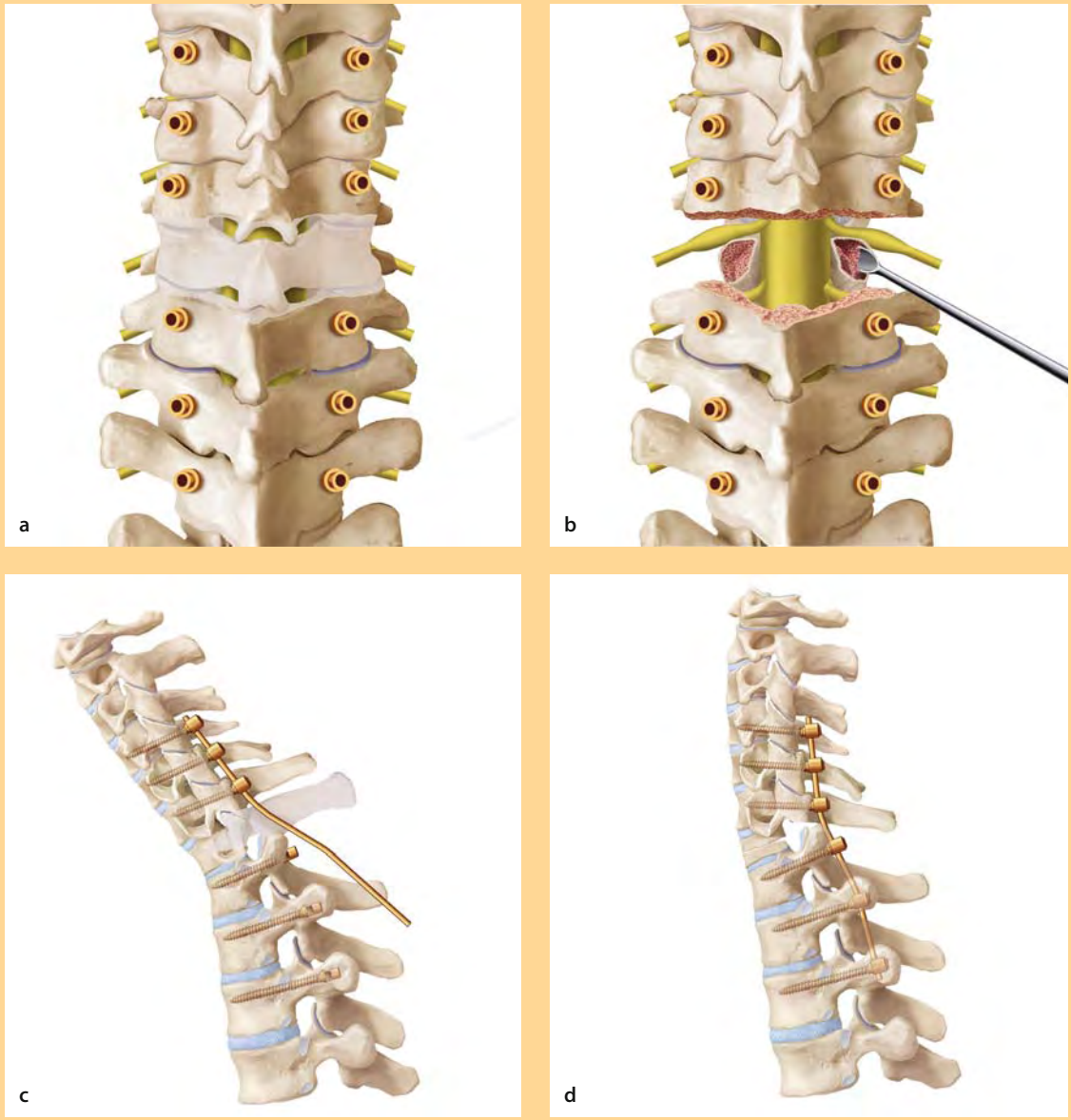


**Figure 6. Cervical closing wedge osteotomy**

For this osteotomy the patient is positioned prone within a Mayfield headrest. Sensorimotor potentials should be obtained prior to surgery as a baseline measurement. **a** The spine is exposed from C4 to T3. Pedicle screws are inserted three levels above and below the osteotomy. In the cervical spine, facet joint screws can be used as an alternative to pedicle screws because of a lower risk of neurovascular injuries. The lamina of C7 and the hemilaminae of C6 and T1 are resected. Care has to be taken to completely liberate the nerve roots C6–8. **b** The articular processes of C7 are completely removed including the C7 pedicles. The vertebral body of C7 is decancellated with curettes and the posterior wall osteomized with a Kerrison rongeur. **c** Both rods are inserted and locked in the cervical screws. **d** The Mayfield headrest is loosened by an assistant who continues to manually hold the head during the correction. The rods are slowly levered to the thoracic screws and locked. Great care has to be taken that the head extension does not result in a compromise of the nerve roots. A posterior spinal fusion completes the operation.

of fractures or lesions in AS should be done in specialized interdisciplinary clinics. The reasons are the high rate of complications (e.g., neurological failure, loss of fixation, wound infections, respiratory failure) and mortality postoperatively.

Treatment of fracture causing paralysis is associated with a high risk of complications

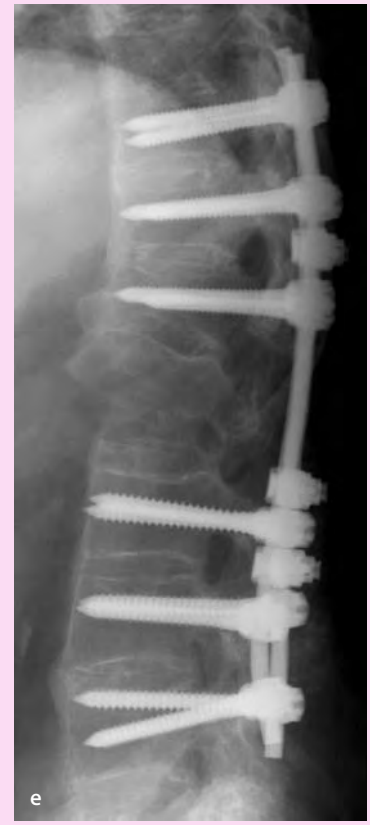


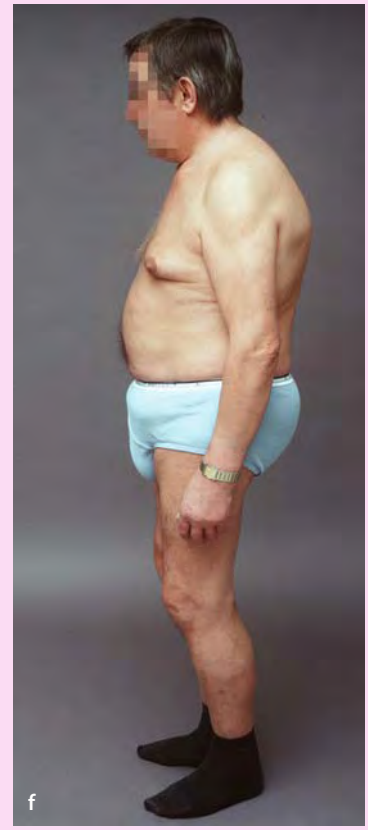


## Case Study 2

a A 59-year-old male who had suffered from ankylosing spondylitis for three decades was well adapted to his disease. He sustained a fall on the stairs and complained of weakness in his legs. At hospital admission the patient had a mild paraparesis sub-L1 with decreased sensation and mild weakness in both legs (MRC Grade 4). CT reformatted image (b) shows a luxation fracture at L1 with significant posterior angulation of the spine. T1 and T2W MRI scans (c, d) demonstrate the luxation fracture and significant canal enchroachment. The previously ankylosed kyphotic spine corrected at the level of the fracture. After decompression of the spinal canal, the patient was instrumented with a pedicle screw system in the corrected position. Fusion was added at the site of the fracture (e). At one year follow-up visit, the patient had completely recovered and was very satisfied with the correction of the trunk position, which had bothered him for many years prior to his fracture (f).

**Table 7.** Surgical results of correction osteotomies

| Author | Cases | Localization | Design | Technique | Complications/outcome | Conclusions |
|---|---|---|---|---|---|---|
| Langeloo et al. (2006) [60] | 16 | cervical | retrospective | C7 correction osteotomy (OT) with internal fixation from C2–C6 to T1–T6 | 9 transient paresthesia<br>1 irreversible neurological complication<br>2 deep wound infection<br>2 major general complication | C7 correction osteotomy is a reliable technique. At the cervical level neuromonitoring (TES-MEP) is mandatory |
| McMaster et al. (1997) [70] | 15 | cervical | retrospective | C7/T1 extension OT with ($n=3$) and without ($n=12$) internal fixation | 2 transient paresthesia<br>2 irreversible neurological complication<br>1 deep wound infection<br>4 subluxation<br>1 major general complication | cervical osteotomies are difficult techniques. Subluxation at the osteotomy site is associated with non-union |
| Willems et al. (2005) [108] | 105 | cervical-thoracic and lumbar | retrospective | cervical-thoracic OT ($n=22$), lumbar closing-wedge OT ($n=62$), polysegmental lumbar OT ($n=20$), anterior-posterior lumbar OT ($n=11$) | 8 transient paresthesia<br>9 irreversible neurological complication<br>11 deep wound infection<br>12 major general complication | correction osteotomies in AS show high complication rates. Reasons are a difficult surgery and a complex disease. AS surgery should be carried out in specialized interdisciplinary centers |
| Danisa et al. (2000) [33] | 11 | thoracic and thoracolumbar | retrospective | "eggshell" osteotomy | 5 transient paresthesia<br>0 irreversible neurological complication<br>0 deep wound infection<br>1 major general complication | an "eggshell" osteotomy shows lower complication rates than with open wedge osteotomies. Main goal of this procedure is to restore sagittal balance |
| Van Royen et al. (1998) [98] | 21 | thoracic and thoracolumbar | retrospective | polysegmental lumbar OT | 4 transient paresthesia<br>0 irreversible neurological complication<br>7 deep wound infection<br>2 major general complication | polysegmental lumbar osteotomies are associated with high complication rates. Only in the mild phase of AS should a polysegmental lumbar osteotomy be used |
| Hehne et al. (1990) [47] | 177 | thoracic and thoracolumbar | retrospective | polysegmental lumbar OT | 19 transient paresthesia<br>4 irreversible neurological complication<br>6 deep wound infection<br>4 major general complication | the technique results in a harmonious spinal correction. And reduces the potential of severe complications. Most patients are pain free after polysegmental lumbar OT |
| Bradford et al. (1987) [14] | 21 | thoracic and thoracolumbar | retrospective | open wedge OT ($n=8$), two stage osteotomy (anterior and posterior) ($n=8$) | 2 transient paresthesia<br>0 irreversible neurological complication<br>0 deep wound infection<br>0 major general complication | a neurological monitoring with a wake-up test is necessary. A correction of sagittal balance seems to be associated with decreased risk of loss of correction |
| Lazennec et al. (1997) [63] | 31 | lumbar | retrospective | open wedge OT ($n=19$) vs. close wedge OT ($n=12$) | 4 transient paresthesia<br>2 irreversible neurological complication<br>3 reoperations (non-union)<br>vs.<br>3 transient paresthesia<br>0 irreversible neurological complication<br>1 reoperation (non-union) | the level of lumbar osteotomy is very important, because sagittal translation is a basic mechanism for correcting sagittal imbalance |

## Complications

Surgical interventions for AS most often represent major surgery and are technically demanding. Not infrequently patients exhibit malnutrition and are prone to infections. The morbidity and mortality rate can be decreased by careful surgical planning, new operating techniques, new implants and improved intensive care [26, 28, 29, 47, 60, 63, 72, 82, 86, 92, 100]. **Complications** after ankylosing surgery **include** [28, 60, 98, 100, 108]:

- transient paresthesia (0–45%)
- postoperative infections (0–33%)
- implant failure (2–33%)
- loss of correction (5–40°)
- irreversible neurological deterioration (0–10%)
- major general complications (0–10%)
- non-unions (<5%)

Surgery for AS is prone to complications

These interventions are related to a long operative time, high loss of blood and a high rate of peri- and postoperative complications. Therefore, indications need to be discussed on an individual basis and patients have to be consulted extensively.

## Recapitulation

**Epidemiology.** Ankylosing spondylitis (AS) is a systemic **seronegative** inflammatory rheumatic disorder belonging to the group of **spondyloarthritis**. AS is associated with sacroiliitis and **inflammatory alteration** at the axial skeleton. The male:female ratio is about 2–7:1. Prevalence estimates vary between 0.2 and 1.2/100 000. The peak age of onset is 15–35 years. The diagnosis is delayed by up to 10 years, because of its insidious nature.

**Pathogenesis.** The pathogenesis is still unclear. There is increasing evidence that AS is **genetically determined**. AS has a strong association with *HLA-B27* and 90% of all patients are *HLA-B27* positive. However, 80–90% of all *HLA-B27* carriers do not develop AS. It is therefore widely assumed that additional genetic factors are involved. An infection-triggered onset has recently been added to the existing hypothesis. This concept involves a preceding bacterial infection with subsequent autoimmune responses. The pathological changes of the vertebral column due to AS occur in three consecutive stages: **inflammation, proliferation and ankylosis**.

**Clinical presentation.** Patient complaints are nonspecific and difficult to distinguish from general chronic back pain. Cardinal symptoms are **inflammatory back pain**, typical arthritis pain (pain at night and stiffness in the morning), **progressive spinal stiffness** and the inability to look straight ahead. Additional symptoms are enthesis, uveitis, pulmonary, cardial and bowel inflammation as well as reduced chest expansion.

**Diagnostic work-up.** Early diagnosis of AS can be difficult due to unspecific symptoms and diagnostic findings of the spinal column. In the case of suspicion of AS, the diagnosis should be enforced. The diagnostic work-up includes a thorough clinical examination, **laboratory investigations** (infection parameter, *HLA-B27*) and imaging studies. The goal is to detect AS in the early disease so as to commence therapy in good time. In the early disease stage, **MRI** is the state-of-the-art diagnostic tool. Characteristic findings on MRI suggestive of AS are discitis, erosions with zones of subchondral sclerosis without increased signal after use of a contrast agent, periarticular fat accumulation and **syndesmophytes**. Alternatively, a bone scan can be of further diagnostic use. **Radiographs** and **computed tomography** are suitable tools for monitoring chronic inflammatory progression. Furthermore the CT can be utilized for preoperative planning. Following a trauma and suspicion of lesion or fracture radiographs, CT and MRI of the whole spine should be performed.

**Non-operative treatment.** The non-operative pharmacological therapy is the mainstay of care in conjunction with physical exercises. Goal of the treatment is the reduction of clinical symptoms, inflammation and delay of disease. The pharmacological therapy includes non-selective and selective cyclooxygenase (COX) inhibitors (NSAIDs), analgesics, disease modifying antirheumatic drugs (e.g. sulfasalazine, methotrexate) and TNF-α inhibitors. Physiotherapy and patient education are in parallel to medical treatment cornerstones of AS therapy.

**Operative treatment.** Surgery is of value when conservative therapy fails, i.e., in the case of massive kyphotic deformity or severe pain. **Absolute indications** for surgery are unstable spinal fractures, kyphosis-related **progressive myelopathy** and **progressive spondylodiscitis**. Surgical correction in AS patients is prone to a high peri- and postoperative complication rate (such as neurological deficits, deep wound infections, failure of implants). However, the morbidity and mortality rate can be decreased by **careful surgical planning**, new operating techniques, new implants and improved intensive care. An important aspect is the perioperative anesthesia. **Patient positioning and intubation** are often very difficult due to kyphotic deformation. Intraoperative neuromonitoring is nowadays regarded as indispensable for a safe deformity correction.

The ultimate goal of **surgical techniques of osteotomies** is to rebalance the spine and correct the chin-brow angle to an extent that the patient is again able to look straight ahead. The most common technique is a **closing wedge osteotomy** in the lumbar spine. The underlying concept is to achieve a monosegmental extension while keeping the anterior longitudinal ligament intact. The aim of **multisegmental posterior wedge osteotomy** is to address deformities predominantly located in the thoracic spine and to allow for a harmonic bending of the spine. Four to six thoracic or lumbar levels can osteotomized depending on the extent and location of the spinal deformity.

**Corrections at the level of the cervical spine** are performed at the C7/T1 level. The procedure of choice is a closing or opening wedge osteotomy in combination with an instrumented fusion. Cervical spine surgery in AS appears to have a fairly good clinical outcome, although it is a very demanding operational procedure with a potentially high risk of neurological injuries.

**Fractures in AS** patients can already appear after minimal trauma and are often overlooked. Most often, fractures appear in the thoracic spine and are frequently unstable because they involve the anterior and posterior spinal column. In 30–75 % of cases there is an association of severe neurological deficits. In contrast to common fractures, however, the stabilization should be long rather than short because of the risk of a secondary kyphotic deformity.

## Key Articles

**van Royen BJ (1995) Closing-wedge posterior osteotomy for ankylosing spondylitis. Partial corpectomy and transpedicular fixation in 22 cases. J Bone Joint Surg Br 77: 117–121**
This retrospective study with closing wedge osteotomy at lumbar level L4 shows that this surgical procedure is effective in addressing the kyphotic deformity.

**Murrey DB (2002) Transpedicular decompression and pedicle subtraction osteotomy (eggshell procedure): a retrospective review of 59 patients. Spine 27(21):2338–45**
The eggshell procedure was described and analyzed retrospectively in 59 patients with deformity ($n=37$) and tumor or infection ($n=22$). This surgical procedure is safe and predictable for complex spine deformities.

**Hehne HJ (1990) Polysegmental lumbar osteotomies and transpedicled fixation for correction of long-curved kyphotic deformities in ankylosing spondylitis. Report on 177 cases. Clin Orthop Relat Res 258:49–55**
This is a retrospective study with a high number of polysegmental lumbar osteotomies in patients with AS. The authors describe surgery procedure, correction of spine postoperatively up to 18 months follow-up and associated complications.

**Urist MR (1958) Osteotomy of the cervical spine; report of a case of ankylosing rheumatoid spondylitis. J Bone Joint Surg Am 40A:833–43**
Classic article on the cervical opening wedge osteotomy for AS.

**Smith-Petersen M, Larson C, Aufranc O (1945) Osteotomy of the spine for correction of flexion deformity in rheumatoid arthritis. J Bone Joint Surg Br 27:1 – 11**
Classic article on an opening wedge osteotomy in the thoracolumbar spine and V-shaped thoracic osteotomies for AS.

## References


1. Amor B, Santos RS, Nahal R, Listrat V, Dougados M (1994) Predictive factors for the long-term outcome of spondyloarthropathies. J Rheumatol 21:1883 – 7
2. Andersson O (1937) Röntgenbilden vid spondylarthritis ankylopoetica. Nord Med Tidskr 14:200
3. Appel H, Kuhne M, Spiekermann S, Ebhardt H, Grozdanovic Z, Kohler D, Dreimann M, Hempfing A, Rudwaleit M, Stein H, Metz-Stavenhagen P, Sieper J, Loddenkemper C (2006) Immunohistologic analysis of zygapophyseal joints in patients with ankylosing spondylitis. Arthritis Rheum 54:2845 – 51
4. Apple DF, Jr, Anson C (1995) Spinal cord injury occurring in patients with ankylosing spondylitis: a multicenter study. Orthopedics 18:1005 – 11
5. Aufdermaur M (1989) Pathogenesis of square bodies in ankylosing spondylitis. Ann Rheum Dis 48:628 – 31
6. Baek HJ, Kang SW, Lee YJ, Shin KC, Lee EB, Yoo CD, Song YW (2005) Osteopenia in men with mild and severe ankylosing spondylitis. Rheumatol Int 26:30 – 4
7. Baraliakos X, Hermann KG, Landewe R, Listing J, Golder W, Brandt J, Rudwaleit M, Bollow M, Sieper J, van der Heijde D, Braun J (2005) Assessment of acute spinal inflammation in patients with ankylosing spondylitis by magnetic resonance imaging: a comparison between contrast enhanced T1 and short tau inversion recovery (STIR) sequences. Ann Rheum Dis 64:1141 – 4
8. Baraliakos X, Landewe R, Hermann KG, Listing J, Golder W, Brandt J, Rudwaleit M, Bollow M, Sieper J, van der Heijde D, Braun J (2005) Inflammation in ankylosing spondylitis: a systematic description of the extent and frequency of acute spinal changes using magnetic resonance imaging. Ann Rheum Dis 64:730 – 4
9. Bechterew W (1893) Steifigkeit der Wirbelsäule und ihre Verkrümmung als besondere Erkankungsform. Neurol Centralblatt 12:426 – 434
10. Bernd L, Blasius K, Lukoschek M (1992) [Spinal fractures in ankylosing spondylitis]. Z Orthop Ihre Grenzgeb 130:59 – 63
11. Boachie-Adjei O (2006) Role and technique of eggshell osteotomies and vertebral column resections in the treatment of fixed sagittal imbalance. Instr Course Lect 55:583 – 9
12. Boonen A (2006) A review of work-participation, cost-of-illness and cost-effectiveness studies in ankylosing spondylitis. Nat Clin Pract Rheumatol 2:546 – 53
13. Boulos P, Dougados M, Macleod SM, Hunsche E (2005) Pharmacological treatment of ankylosing spondylitis: a systematic review. Drugs 65:2111 – 27
14. Bradford DS, Schumacher WL, Lonstein JE, Winter RB (1987) Ankylosing spondylitis: experience in surgical management of 21 patients. Spine 12:238 – 43
15. Braun J, Baraliakos X, Godolias G, Bohm H (2005) Therapy of ankylosing spondylitis – a review. Part I: Conventional medical treatment and surgical therapy. Scand J Rheumatol 34:97 – 108
16. Braun J, Baraliakos X, Golder W, Brandt J, Rudwaleit M, Listing J, Bollow M, Sieper J, Van Der Heijde D (2003) Magnetic resonance imaging examinations of the spine in patients with ankylosing spondylitis, before and after successful therapy with infliximab: evaluation of a new scoring system. Arthritis Rheum 48:1126 – 36
17. Braun J, Baraliakos X, Golder W, Hermann KG, Listing J, Brandt J, Rudwaleit M, Zuehlsdorf S, Bollow M, Sieper J, van der Heijde D (2004) Analysing chronic spinal changes in ankylosing spondylitis: a systematic comparison of conventional x rays with magnetic resonance imaging using established and new scoring systems. Ann Rheum Dis 63:1046 – 55
18. Braun J, Bollow M, Neure L, Seipelt E, Seyrekbasan F, Herbst H, Eggens U, Distler A, Sieper J (1995) Use of immunohistologic and in situ hybridization techniques in the examination of sacroiliac joint biopsy specimens from patients with ankylosing spondylitis. Arthritis Rheum 38:499 – 505
19. Braun J, Sieper J (2007) Ankylosing spondylitis. Lancet 369:1379 – 90
20. Braun J, van der Heijde D (2002) Imaging and scoring in ankylosing spondylitis. Best Pract Res Clin Rheumatol 16:573 – 604
21. Brophy S, Calin A (2001) Ankylosing spondylitis: interaction between genes, joints, age at onset, and disease expression. J Rheumatol 28:2283 – 8
22. Brophy S, Mackay K, Al-Saidi A, Taylor G, Calin A (2002) The natural history of ankylosing spondylitis as defined by radiological progression. J Rheumatol 29:1236 – 43

23. Brown MA, Edwards S, Hoyle E, Campbell S, Laval S, Daly AK, Pile KD, Calin A, Ebringer A, Weeks DE, Wordsworth BP (2000) Polymorphisms of the CYP2D6 gene increase susceptibility to ankylosing spondylitis. Hum Mol Genet 9:1563 – 6
24. Brown MA, Laval SH, Brophy S, Calin A (2000) Recurrence risk modelling of the genetic susceptibility to ankylosing spondylitis. Ann Rheum Dis 59:883 – 6
25. Calin A, Elswood J (1989) Retrospective analysis of 376 irradiated patients with ankylosing spondylitis and nonirradiated controls. J Rheumatol 16:1443 – 5
26. Camargo FP, Cordeiro EN, Napoli MM (1986) Corrective osteotomy of the spine in ankylosing spondylitis. Experience with 66 cases. Clin Orthop Relat Res:157 – 67
27. Cawley MI, Chalmers TM, Kellgren JH, Ball J (1972) Destructive lesions of vertebral bodies in ankylosing spondylitis. Ann Rheum Dis 31:345 – 58
28. Chang KW, Chen YY, Lin CC, Hsu HL, Pai KC (2005) Closing wedge osteotomy versus opening wedge osteotomy in ankylosing spondylitis with thoracolumbar kyphotic deformity. Spine 30:1584 – 93
29. Chang KW, Tu MY, Huang HH, Chen HC, Chen YY, Lin CC (2006) Posterior correction and fixation without anterior fusion for pseudoarthrosis with kyphotic deformity in ankylosing spondylitis. Spine 31:E408 – 13
30. Charlesworth CH, Savy LE, Stevens J, Twomey B, Mitchell R (1996) MRI demonstration of arachnoiditis in cauda equina syndrome of ankylosing spondylitis. Neuroradiology 38: 462 – 5
31. Dagfinrud H, Kvien TK, Hagen KB (2004) Physiotherapy interventions for ankylosing spondylitis. Cochrane Database Syst Rev:CD002822
32. Dagfinrud H, Kvien TK, Hagen KB (2005) The Cochrane review of physiotherapy interventions for ankylosing spondylitis. J Rheumatol 32:1899 – 906
33. Danisa OA, Turner D, Richardson WJ (2000) Surgical correction of lumbar kyphotic deformity: posterior reduction “eggshell” osteotomy. J Neurosurg 92:50 – 6
34. Detwiler KN, Loftus CM, Godersky JC, Menezes AH (1990) Management of cervical spine injuries in patients with ankylosing spondylitis. J Neurosurg 72:210 – 5
35. Dougados M, Gueguen A, Nakache JP, Velicitat P, Zeidler H, Veys E, Calin A (1999) Clinical relevance of C-reactive protein in axial involvement of ankylosing spondylitis. J Rheumatol 26:971 – 4
36. Dougados M, van der Heijde D (2002) Ankylosing spondylitis: how should the disease be assessed? Best Pract Res Clin Rheumatol 16:605 – 18
37. Eksioglu E, Bal A, Gulec B, Aydog E, Cakci A (2006) Assessment of shoulder involvement and disability in patients with ankylosing spondylitis. Rheumatol Int 27:169 – 73
38. Emery RJ, Ho EK, Leong JC (1991) The shoulder girdle in ankylosing spondylitis. J Bone Joint Surg Am 73:1526 – 31
39. Fang D, Leong JC, Ho EK, Chan FL, Chow SP (1988) Spinal pseudarthrosis in ankylosing spondylitis. Clinicopathological correlation and the results of anterior spinal fusion. J Bone Joint Surg Br 70:443 – 7
40. Feldtkeller E, Vosse D, Geusens P, van der Linden S (2006) Prevalence and annual incidence of vertebral fractures in patients with ankylosing spondylitis. Rheumatol Int 26:234 – 9
41. Frauendorf E, von Goessel H, May E, Marker-Hermann E (2003) HLA-B27-restricted T cells from patients with ankylosing spondylitis recognize peptides from B*2705 that are similar to bacteria-derived peptides. Clin Exp Immunol 134:351 – 9
42. Graham B, Van Peteghem PK (1989) Fractures of the spine in ankylosing spondylitis. Diagnosis, treatment, and complications. Spine 14:803 – 7
43. Gran JT, Skomsvoll JF (1997) The outcome of ankylosing spondylitis: a study of 100 patients. Br J Rheumatol 36:766 – 71
44. Grundy PL, Gill SS (1998) Odontoid process and C1-C2 corrective osteotomy through a posterior approach: technical case report. Neurosurgery 43:1483 – 6; discussion 1486 – 7
45. Halm H, Metz-Stavenhagen P, Zielke K (1995) Results of surgical correction of kyphotic deformities of the spine in ankylosing spondylitis on the basis of the modified arthritis impact measurement scales. Spine 20:1612 – 9
46. Harrop JS, Sharan A, Anderson G, Hillibrand AS, Albert TJ, Flanders A, Vaccaro AR (2005) Failure of standard imaging to detect a cervical fracture in a patient with ankylosing spondylitis. Spine 30:E417 – 9
47. Hehne HJ, Zielke K, Bohm H (1990) Polysegmental lumbar osteotomies and transpedicled fixation for correction of long-curved kyphotic deformities in ankylosing spondylitis. Report on 177 cases. Clin Orthop Relat Res:49 – 55
48. Inanc N, Atagunduz P, Sen F, Biren T, Turoglu HT, Direskeneli H (2005) The investigation of sacroiliitis with different imaging techniques in spondyloarthropathies. Rheumatol Int 25:591 – 4
49. Jaakkola E, Herzberg I, Laiho K, Barnardo MC, Pointon JJ, Kauppi M, Kaarela K, Tuomilehto-Wolf E, Tuomilehto J, Wordsworth BP, Brown MA (2006) Finnish HLA studies confirm the increased risk conferred by HLA-B27 homozygosity in ankylosing spondylitis. Ann Rheum Dis 65:775 – 80

50. Jaffray D, Becker V, Eisenstein S (1992) Closing wedge osteotomy with transpedicular fixation in ankylosing spondylitis. Clin Orthop Relat Res:122 – 6
51. Kawasaki T, Hukuda S, Katsuura A, Inoue K, Chano T (1996) Lumboperitoneal shunt for cauda equina syndrome in ankylosing spondylitis. J Spinal Disord 9:72 – 5
52. Kennedy LG, Edmunds L, Calin A (1993) The natural history of ankylosing spondylitis. Does it burn out? J Rheumatol 20:688 – 92
53. Kennedy LG, Will R, Calin A (1993) Sex ratio in the spondyloarthropathies and its relationship to phenotypic expression, mode of inheritance and age at onset. J Rheumatol 20: 1900 – 4
54. Khan MA (2000) HLA-B27 polymorphism and association with disease. J Rheumatol 27: 1110 – 4
55. Khan MA, Ball EJ (2002) Genetic aspects of ankylosing spondylitis. Best Pract Res Clin Rheumatol 16:675 – 90
56. Koh WH, Garrett SL, Calin A (1997) Cervical spine surgery in ankylosing spondylitis: is the outcome good? Clin Rheumatol 16:466 – 70
57. Koivikko MP, Kiuru MJ, Koskinen SK (2004) Multidetector computed tomography of cervical spine fractures in ankylosing spondylitis. Acta Radiol 45:751 – 9
58. Lambrecht V, Vanhoenacker FM, Van Dyck P, Gielen J, Parizel PM (2005) Ankylosing spondylitis: what remains of the standard radiography anno 2004? JBR-BTR 88:25 – 30
59. Lange U, Pape HC, Bastian L, Krettek C (2005) [Operative management of cervical spine injuries in patients with Bechterew's disease]. Unfallchirurg 108:63 – 8
60. Langeloo DD, Journee HL, Pavlov PW, de Kleuver M (2006) Cervical osteotomy in ankylosing spondylitis: evaluation of new developments. Eur Spine J 15:493 – 500
61. Langlois S, Cedoz JP, Lohse A, Toussirot E, Wendling D (2005) Aseptic discitis in patients with ankylosing spondylitis: a retrospective study of 14 cases. Joint Bone Spine 72:248 – 53
62. Laval SH, Timms A, Edwards S, Bradbury L, Brophy S, Milicic A, Rubin L, Siminovitch KA, Weeks DE, Calin A, Wordsworth BP, Brown MA (2001) Whole-genome screening in ankylosing spondylitis: evidence of non-MHC genetic-susceptibility loci. Am J Hum Genet 68:918 – 26
63. Lazennec JY, Saillant G, Saidi K, Arafati N, Barabas D, Benazet JP, Laville C, Roy-Camille R, Ramare S (1997) Surgery of the deformities in ankylosing spondylitis: our experience of lumbar osteotomies in 31 patients. Eur Spine J 6:222 – 32
64. Lee YS, Schlotzhauer T, Ott SM, van Vollenhoven RF, Hunter J, Shapiro J, Marcus R, McGuire JL (1997) Skeletal status of men with early and late ankylosing spondylitis. Am J Med 103:233 – 41
65. Maillefert JF, Aho LS, El Maghraoui A, Dougados M, Roux C (2001) Changes in bone density in patients with ankylosing spondylitis: a two-year follow-up study. Osteoporos Int 12:605 – 9
66. Marker-Hermann E, Frauendorf E, Zeidler H, Sieper J (2004) [Pathogenesis of ankylosing spondylitis – mechanisms of disease manifestation and chronicity]. Z Rheumatol 63:187 – 92
67. Martindale J, Smith J, Sutton CJ, Grennan D, Goodacre L, Goodacre JA (2006) Disease and psychological status in ankylosing spondylitis. Rheumatology (Oxford)
68. Mau W, Zeidler H, Mau R, Majewski A, Freyschmidt J, Stangel W, Deicher H (1988) Clinical features and prognosis of patients with possible ankylosing spondylitis. Results of a 10-year followup. J Rheumatol 15:1109 – 14
69. Mau W, Zeidler H, Mau R, Majewski A, Freyschmidt J, Stangel W, Deicher H (1990) Evaluation of early diagnostic criteria for ankylosing spondylitis in a 10 year follow-up. Z Rheumatol 49:82 – 7
70. McMaster MJ (1997) Osteotomy of the cervical spine in ankylosing spondylitis. J Bone Joint Surg Br 79:197 – 203
71. McVeigh CM, Cairns AP (2006) Diagnosis and management of ankylosing spondylitis. BMJ 333:581 – 5
72. Min K, Hahn F, Leonardi M (2007) Lumbar spinal osteotomy for kyphosis in ankylosing spondylitis: the significance of the whole body kyphosis angle. J Spinal Disord Tech 20:149 – 53
73. Mummaneni PV, Mummaneni VP, Haid RW, Jr, Rodts GE, Jr, Sasso RC (2003) Cervical osteotomy for the correction of chin-on-chest deformity in ankylosing spondylitis. Technical note. Neurosurg Focus 14:e9
74. Murrey DB, Brigham CD, Kiebzak GM, Finger F, Chewning SJ (2002) Transpedicular decompression and pedicle subtraction osteotomy (eggshell procedure): a retrospective review of 59 patients. Spine 27:2338 – 45
75. Nakstad PH, Server A, Josefsen R (2004) Traumatic cervical injuries in ankylosing spondylitis. Acta Radiol 45:222 – 6
76. Nikolaisen C, Nossent H (2005) Early histology in ankylosing spondylitis related spondylodiscitis supports its inflammatory origin. Scand J Rheumatol 34:396 – 8
77. Olerud C, Frost A, Bring J (1996) Spinal fractures in patients with ankylosing spondylitis. Eur Spine J 5:51 – 5

78. Payer M (2006) Surgical management of cervical fractures in ankylosing spondylitis using a combined posterior-anterior approach. J Clin Neurosci 13:73 – 7
79. Ramos-Remus C, Russell AS, Gomez-Vargas A, Hernandez-Chavez A, Maksymowych WP, Gamez-Nava JI, Gonzalez-Lopez L, Garcia-Hernandez A, Meono-Morales E, Burgos-Vargas R, Suarez-Almazor ME (1998) Ossification of the posterior longitudinal ligament in three geographically and genetically different populations of ankylosing spondylitis and other spondyloarthropathies. Ann Rheum Dis 57:429 – 33
80. Rudwaleit M, Metter A, Listing J, Sieper J, Braun J (2006) Inflammatory back pain in ankylosing spondylitis: a reassessment of the clinical history for application as classification and diagnostic criteria. Arthritis Rheum 54:569 – 78
81. Rudwaleit M, Sieper J (2005) [Early diagnosis of spondyloarthritis with special attention to the axial forms]. Z Rheumatol 64:524 – 30
82. Ruf M, Wagner R, Merk H, Harms J (2006) [Preoperative planning and computer assisted surgery in ankylosing spondylitis]. Z Orthop Ihre Grenzgeb 144:52 – 7
83. Ryan PJ, Fogelman I (1995) The bone scan: where are we now? Semin Nucl Med 25:76 – 91
84. Schroder J, Liljenqvist U, Greiner C, Wassmann H (2003) Complications of halo treatment for cervical spine injuries in patients with ankylosing spondylitis – report of three cases. Arch Orthop Trauma Surg 123:112 – 4
85. Schroder R, Urbach H, Zierz S (1994) Cauda equina syndrome with multiple lumbar diverticula complicating long-standing ankylosing spondylitis. Clin Investig 72:1056 – 9
86. Scudese VA, Calabro JJ (1963) Vertebral wedge osteotomy. Correction of rheumatoid (ankylosing) spondylitis. JAMA 186:627 – 31
87. Sieper J, Rudwaleit M, Khan MA, Braun J (2006) Concepts and epidemiology of spondyloarthritis. Best Pract Res Clin Rheumatol 20:401 – 17
88. Simmons EH (1977) Kyphotic deformity of the spine in ankylosing spondylitis. Clin Orthop Relat Res:65 – 77
89. Sims AM, Barnardo M, Herzberg I, Bradbury L, Calin A, Wordsworth BP, Darke C, Brown MA (2007) Non-B27 MHC associations of ankylosing spondylitis. Genes Immun 8:115 – 23
90. Smith-Petersen M, Larson C, Aufranc O (1945) Osteotomy of the spine for correction of flexion deformity in rheumatoid arthritis. J Bone Joint Surg Br 27:1 – 11
91. Sturzenbecher A, Braun J, Paris S, Biedermann T, Hamm B, Bollow M (2000) MR imaging of septic sacroiliitis. Skeletal Radiol 29:439 – 46
92. Suk KS, Kim KT, Lee SH, Kim JM (2003) Significance of chin-brow vertical angle in correction of kyphotic deformity of ankylosing spondylitis patients. Spine 28:2001 – 5
93. Timms AE, Crane AM, Sims AM, Cordell HJ, Bradbury LA, Abbott A, Coyne MR, Beynon O, Herzberg I, Duff GW, Calin A, Cardon LR, Wordsworth BP, Brown MA (2004) The interleukin 1 gene cluster contains a major susceptibility locus for ankylosing spondylitis. Am J Hum Genet 75:587 – 95
94. Toussirot E, Michel F, Wendling D (2001) Bone density, ultrasound measurements and body composition in early ankylosing spondylitis. Rheumatology (Oxford) 40:882 – 8
95. Urist MR (1958) Osteotomy of the cervical spine; report of a case of ankylosing rheumatoid spondylitis. J Bone Joint Surg Am 40-A:833 – 43
96. van der Heijden IM, Wilbrink B, Tchetverikov I, Schrijver IA, Schouls LM, Hazenberg MP, Breedveld FC, Tak PP (2000) Presence of bacterial DNA and bacterial peptidoglycans in joints of patients with rheumatoid arthritis and other arthritides. Arthritis Rheum 43: 593 – 8
97. van der Linden S, Valkenburg HA, Cats A (1984) Evaluation of diagnostic criteria for ankylosing spondylitis. A proposal for modification of the New York criteria. Arthritis Rheum 27:361 – 8
98. van Royen BJ, de Kleuver M, Slot GH (1998) Polysegmental lumbar posterior wedge osteotomies for correction of kyphosis in ankylosing spondylitis. Eur Spine J 7:104 – 10
99. Van Royen BJ, Kastelijns RC, Noske DP, Oner FC, Smit TH (2006) Transpedicular wedge resection osteotomy for the treatment of a kyphotic Andersson lesion-complicating ankylosing spondylitis. Eur Spine J 15:246 – 52
100. van Royen BJ, Slot GH (1995) Closing-wedge posterior osteotomy for ankylosing spondylitis. Partial corpectomy and transpedicular fixation in 22 cases. J Bone Joint Surg Br 77: 117 – 21
101. van Tubergen A, Hidding A (2002) Spa and exercise treatment in ankylosing spondylitis: fact or fancy? Best Pract Res Clin Rheumatol 16:653 – 66
102. Wanders A, Heijde D, Landewe R, Behier JM, Calin A, Olivieri I, Zeidler H, Dougados M (2005) Nonsteroidal antiinflammatory drugs reduce radiographic progression in patients with ankylosing spondylitis: a randomized clinical trial. Arthritis Rheum 52:1756 – 65
103. Wang YF, Teng MM, Chang CY, Wu HT, Wang ST (2005) Imaging manifestations of spinal fractures in ankylosing spondylitis. AJNR Am J Neuroradiol 26:2067 – 76
104. Webb JK (2006) Ankylosing spondylitis. In: Aebi M, Arlet V, Webb JK (eds) AO Spine Manual. Clinical applications, vol 2. Thieme, Stuttgart, pp 319 – 327
105. Weber U, Pfirrmann CW, Kissling RO, Hodler J, Zanetti M (2007) Whole body MR imaging

in ankylosing spondylitis: a descriptive pilot study in patients with suspected early and active confirmed ankylosing spondylitis. BMC Musculoskelet Disord 8:20
106. Wilkinson M, Bywaters EG (1958) Clinical features and course of ankylosing spondylitis; as seen in a follow-up of 222 hospital referred cases. Ann Rheum Dis 17:209 – 28
107. Will R, Palmer R, Bhalla AK, Ring F, Calin A (1989) Osteoporosis in early ankylosing spondylitis: a primary pathological event? Lancet 2:1483 – 5
108. Willems KF, Slot GH, Anderson PG, Pavlov PW, de Kleuver M (2005) Spinal osteotomy in patients with ankylosing spondylitis: complications during first postoperative year. Spine 30:101 – 7
109. Zdichavsky M, Blauth M, Knop C, Lange U, Krettek C, Bastian L (2005) [Ankylosing spondylitis. Therapy and complications of 34 spine fractures]. Chirurg 76:967 – 75
110. Zochling J, van der Heijde D, Burgos-Vargas R, Collantes E, Davis JC, Jr, Dijkmans B, Dougados M, Geher P, Inman RD, Khan MA, Kvien TK, Leirisalo-Repo M, Olivieri I, Pavelka K, Sieper J, Stucki G, Sturrock RD, van der Linden S, Wendling D, Bohm H, van Royen BJ, Braun J (2006) ASAS/EULAR recommendations for the management of ankylosing spondylitis. Ann Rheum Dis 65:442 – 52

# 39 Treatment of Postoperative Complications

Martin Krismer, Norbert Boos

## Core Messages

- ✔ The best treatment for complications is their avoidance by careful preoperative planning
- ✔ Neurological complications are no more frequent in spinal than in musculoskeletal surgery
- ✔ Check risk factors for complications such as intraspinal pathology, previous surgery, allergies, medications and malnutrition
- ✔ Use standardized postoperative protocols to monitor the patient with regard to neurological and cardiopulmonary function as well as vascular status (pulse oximetry)
- ✔ Try to stop bleeding from small lacerations of large veins by pressure and hemostatic agents
- ✔ Cover lacerations of the lungs with synthetic material
- ✔ Chylothorax is initially treated by parenteral nutrition
- ✔ Hypoliquorrhea syndrome usually occurs with tiny dural defects and not with large lacerations

## Frequency of Complications

The rate of complications with spinal procedures is dependent on the type of surgery, the spinal pathology, the experience of the surgeon and confounding factors such as age and comorbidities. These factors have to be taken into account in the discussion of complications.

### Cervical Spine Surgery

Postoperative deterioration must be anticipated in cases of preexisting myelopathy

In 450 cases of **anterior cervical discectomy**, worsening of the preexisting cervical myelopathy occurred in 3.3 % and infection in 1.6 %. Additional radiculopathy occurred in 1.6 %, recurrent nerve palsy in 1.3 %, and Horner's syndrome in 1.1 %. An epidural hematoma was seen in 0.9 %. Furthermore, single cases of pharyngeal lesion, meningitis due to a dural leak, and an epidural abscess were found [9]. In decompression for ossification of the posterior longitudinal ligament the neurological complication rate was 3.6 % [85]. In anterior fusion in 488 patients, a dural tear occurred in 0.2 %, dysphagia in 1.4 %, a fractured vertebra in 0.2 %, and vocal paresis in 0.8 % [48]. In a report on 185 **corpectomies**, the vertebral artery was injured in four patients [31].

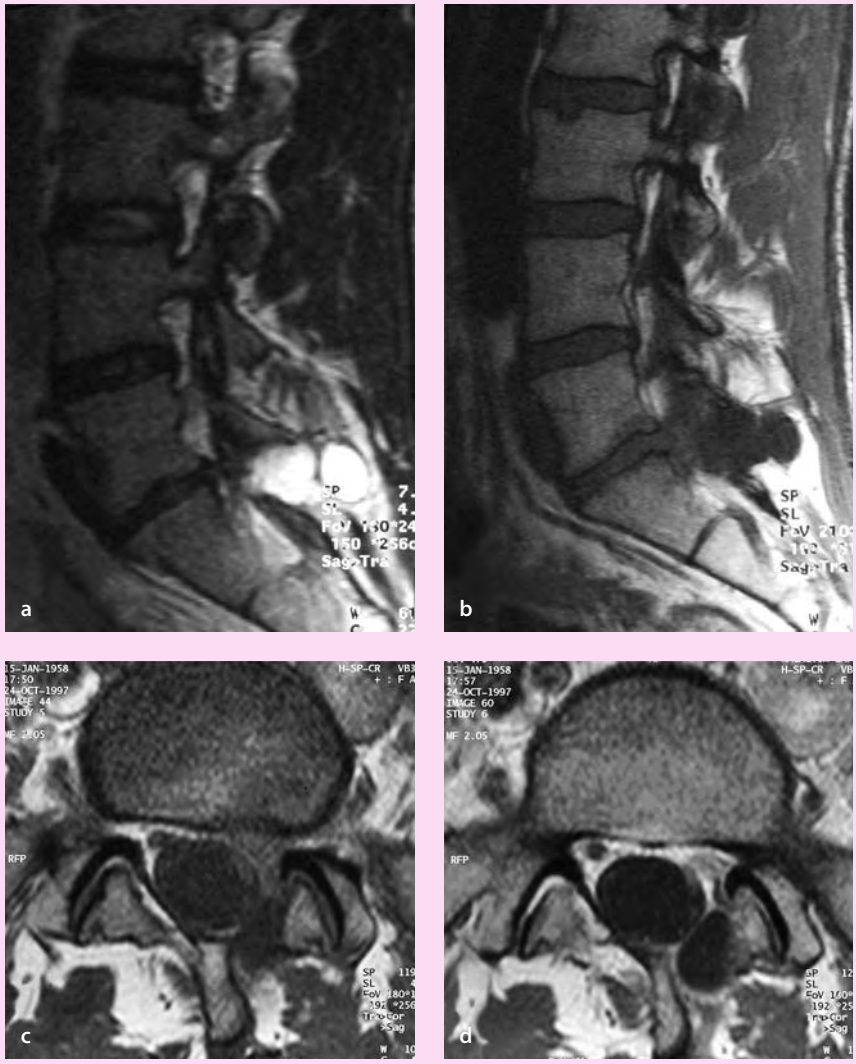


## Case Introduction

A 38-year-old male underwent lumbar discectomy at the level of L5/S1 for a left-sided radiculopathy with a sensory and motor (MRC Grade IV) deficit of the S1 nerve root. The microsurgical procedure was completed uneventfully. The patient reported immediately after surgery a substantial pain relief and improvement of the muscle force for plantar flexion of the left foot. At discharge, the patient felt well and was almost pain free. At 2 weeks postoperatively the patient consulted his family practitioner because of intermittent headache. The patient was treated symptomatically with NSAIDs. The symptoms increased and the patient again developed some minor leg pain for which he was referred again. On presentation, the patient complained of position-dependent headache which got worse after 15–20 min in the upright position. An MRI scan demonstrated a fluid collection at the level of surgery (a, b, d). A contrast-enhanced MR scan allowed the exclusion of a recurrent herniation (d). A hypoliquorrhea syndrome was suspected and the patient was reviewed. Intraoperatively, a medium size (5 cm) arachnoidal cyst was discovered which was opened. At the base of the cyst, a tiny dura lesion was discovered under the lamina of S1. It was assumed that the lesion only injured the dura but left the arachnoidea intact. This injury was obviously unnoticed intraoperatively because no CSF leak occurred. The cyst was resected. The dura lesion was sutured with 5-0 Prolene and covered with Dura-Gen and fibrin clue. The patient completely recovered and was symptom free at 2 months follow-up. This case demonstrates that a hypoliquorrhea syndrome is most often observed not with large but with a tiny dura lesion which forms a valve mechanism. We recommend repairing all iatrogenic arachnoidal cysts when noticed intraoperatively to avoid this complication.

## Anterior Spine Surgery

Serious complications are rare

In anterior approaches to the adult thoracic or lumbar spine, serious complications are relatively rare. In two large studies ($n = 1\,223$ [33], $n = 447$ [77]), the **major complications** were:

- death: 0.3 %, 0.4 %
- paraplegia: 0.2 %, 0.4 %
- deep wound infection: 0.6 %, 1.1 %

In a report on 205 disc prostheses enrolled in a prospective FDA study [11], the major complications were:

- death: 0.5 % (anesthesia related)
- neurological deficit: 0 %
- deep wound infection: 0 % (superficial 6.3 %)

The overall complication rate for idiopathic scoliosis was 5.2 % for anterior, 5.1 % for posterior, and **10.2 %** for **combined anterior and posterior procedures** according to a study by the Scoliosis Research Society [21] based on 6 334 cases submitted to the study in the years 2001, 2002, and 2003 (Table 1).

**Table 1.** Complications in adolescent idiopathic scoliosis surgery [21]

| | Anterior | Posterior | Combined |
|---|---|---|---|
| • pulmonary | 1.5 % | 1.0 % | 3.5 % |
| • wound infection | 0.2 % | 1.3 % | 1.4 % |
| • non-fatal hemorrhagic | 0.3 % | 0.1 % | 0.3 % |
| • implant related | 1.4 % | 0.6 % | 1.0 % |
| • neurological | 0.3 % | 0.2 % | 0.1 % |
| • dural tear | 0.3 % | 0.2 % | 0.1 % |
| • deep venous thrombosis | 0.0 % | 0.1 % | 0.0 % |

In a French deformity surgery cohort, 90 % scoliosis, 10 % kyphosis ($n = 3\,311$), the overall complication rate was 21.3 %. Infection occurred in 4.7 % and neurological complications in 1.8 % [43].

## Disc Herniation and Spinal Stenosis

Perioperative mortality depends on age and comorbidities

Several papers reported on complications in surgery for disc herniation [62], or posterior procedures, where decompression of disc herniation or of spinal stenosis contributed to 84 % of the cases, and where fractures, infections and malignant lesions were excluded [26]. In 27 576 and 18 122 operations death occurred in 0.5 % (within 30 days) and 0.07 %, respectively. Mortality depended strongly on age, being 0 % up to the age of 40 years, and 0.6 % at the age of 75 years and over [26]. Most **deaths occur in elderly patients** due to:

- cardiac infarction
- heart failure
- central nervous system complications
- septic shock

The incidence of an **iatrogenic neurological deficit** was cited as 1.0 % for disc herniation and 1.8 % for stenosis [85]. A dural leak occurred in 1.4 %. The incidence of a leak decreased with increasing surgical experience from 3.1 % (experience 1 – 6 years) to 1.1 % (> 15 years), whereas the surgeon's experience did not influence the rate of neurological complications.

## Lumbar Spinal Fusion

The overall early complication rate in a prospective randomized trial [38] on 211 patients was 6% in posterolateral fusion without instrumentation, 18% with posterior instrumentation, and 31% in circumferential fusion. The complications consisted of:

- infection rate: 3.6% (5 of 140 posterior fusions)
- injury to the sympathetic trunk: 3.7%
- injury to iliac veins: 3.7%
- new nerve root pain: 7.1%

## Comparison of Complications

Complications are no more frequent than in other musculoskeletal surgery

Spine surgery is no more prone to complications than other major orthopedic interventions. Lethal and even neurological complications occur more often in hip, knee and shoulder arthroplasty than in spine surgery (Table 2).

**Table 2.** Complications in musculoskeletal surgery

| | Death | Neurological lesions | Infection | References |
|---|---|---|---|---|
| • spinal surgery | 0.2% | 1.1% | 1.6% | Coe et al. (2006) [21] |
| • hip arthroplasty | 1.0% | 1.3% | 0.2% | Mahomed et al. (2003) [73]<br>Schmalzried et al. (1991) [102] |
| • knee arthroplasty | 0.6% | 1.3% | 0.4% | Katz et al. (2004)<br>Schnisky et al. (2001) [101] |
| • revision hip arthroplasty | 2.6% | 3.2% | 1.0% | Mahomed et al. (2003) [73]<br>Schmalzried et al. (1991) [102] |
| • surgery for anterior glenohumeral instability | – | 1–8% | – | Boardman et al. (1999) [12] |
| • rotator cuff repair | – | 1–2% | 1.8% | Boardman et al. (1999) [12]<br>Herrera et al. (2002) [54] |
| • shoulder arthroplasty | 0.2–0.6% | 1–4% | 1.1% | Boardman et al. (1999) [12]<br>Farmer et al. (2006) [35]<br>Sperling et al. (2001) [106] |

## Preventive Measures

Better avoid than treat complications

It is self-evident that it is better to avoid complications than to treat them. Complications cannot be avoided completely, but the best conditions can be created to obtain a low complication rate. This **goal is achieved by**:

- preoperative identification of risk factors
- patient referral to a larger center (in case of insufficient surgical experience)
- optimal patient preparation (e.g., correction of malnutrition)
- standardization of procedures
- postoperative checks to detect neurological, pulmonary, and cardiovascular deterioration

It is quite obvious that an experienced specialist will cause fewer complications. But to be clear, experience is what we get when complications occur which we have to manage. The experienced surgeon and much more so the surgeon's patients have to pay a price for this experience. The opportunity to gain experience must be weighed against the risk. This should be kept in mind when rare cases are selected for surgery.

## Screening of Risk Factors

A screening investigation of **major risk factors** (Table 3) is recommended in order to identify the population at risk. The screening should encompass a full medical examination.

**Table 3.** Risk factors for complications

| Complications | Risk factors |
|---|---|
| • excessive blood loss | • neuromuscular deformities (hypotonia, osteoporosis)<br>• neurofibromatosis (abnormal vascular anatomy)<br>• drugs (platelet inhibitors, anticoagulants)<br>• scar formations (previous surgery)<br>• arteriosclerosis (smoking) |
| • thromboembolic complications | • previous thromboembolic episodes<br>• malignant tumor |
| • paraplegia | • kyphosis<br>• congenital deformity<br>• preoperative neurological deficit<br>• spinal cord compression |
| • general complications | • malnutrition<br>• previous cardiac infarction or stroke<br>• neuromuscular diseases |

### Risk Factors for Vascular Complications

A detailed preoperative search for risk factors for vascular complications can help to minimize the surgical risk. The **preoperative assessment** should consider:

- previous surgery (e.g., of vessels, thorax, abdomen, spine, thyroid gland)
- history of coronary heart disease, high blood pressure, diabetes mellitus, transient ischemic attacks, thromboembolism [41, 98]
- claudication symptoms [2]
- clinical examination of pulses (leg, foot, carotid arteries)

Routine radiographs of the spine may show extensive arteriosclerosis which may caution one to perform mobilization and retraction of vessels. It is debatable whether **Doppler sonography** is routinely necessary but it is indispensable if the patient reports a previous history of transient ischemic attacks or a murmur.

Some situations should definitely be avoided, e.g., a bleeding vertebral artery with no information on the function of the contralateral artery, or the presence of an abdominal scar without knowledge of the type of the previous surgery (e.g., vascular prosthesis). It is not clear whether information on the circle of Willis is routinely necessary, which would require angiography (MR or conventional) in cervical spine cases. However, in the case of a stenotic vertebral artery this may be important information.

### Cardiovascular Risk Factors

Cardiac complications are mainly **myocardial infarction** and **heart failure**. Stroke is a rare complication. Most case reports of strokes in spinal surgery are related to iatrogenic vertebral artery injury. In a few, carotid occlusion occurred.

After previous myocardial infarction and after stroke, elective procedures should not be done within a period of 6 months if not imperative. For endoscopic procedures it was shown that complications from an intervention in the first 30 days were no higher than in those patients operated on 6 months after myocardial infarction [18]. No information is available with regard to major orthopedic procedures.

Elective surgery after a myocardial infarction should be postponed for 6 months

### Pulmonary Risk Factors

Inability to climb more than two floors increases the risk of pulmonary complications

Risk factors are chronic obstructive pulmonary disease (**COPD**), often caused by smoking, and restrictive lung disease especially in deformities. The ability to climb stairs may be a good indicator, e.g., the ability to climb three floors without interruption indicates a sufficiently good lung function. In COPD, it is important for the patient to sit upright postoperatively. Especially in muscular dystrophy (Duchenne's disease), respiratory muscle training may increase preoperative vital capacity. Nevertheless, the surgical intervention should not be delayed, and it was recently shown that the outcome is no different in patients with a vital capacity ≤ 30 % in comparison to those with vital capacity > 30 % [50].

### Malnutrition as Risk Factor

Malnutrition is a frequently underestimated risk factor. It is therefore necessary to routinely assess the nutritional status well in advance of elective major surgery. The assessment of **nutritional parameters** should include:

- albumin
- prealbumin
- total protein
- transferrin
- absolute lymphocyte count

It was shown in prospective randomized trials [59, 69] that parenteral nutrition after surgery can reduce postoperative infections such as pneumonia or urinary tract infections. Malnutrition is frequently present in:

Malnutrition is a frequently underestimated risk factor

- elderly people
- patients with neuromuscular diseases
- patients with malignant tumors
- staged operations [27]

A preoperative high protein diet may therefore be beneficial [69].

### Medication

Aspirin should be stopped 10 days prior to surgery

**Platelet aggregation inhibitors** such as acetylsalicylate and clopidogrel can considerably increase bleeding. They should be stopped 10 days before the planned intervention, or they should be replaced directly by low molecular weight heparin (LMWH). Non-steroid anti-inflammatory drugs (**NSAIDs**) may increase the effect of anticoagulants. If high doses of NSAIDs are taken, a preoperative change to paracetamol (in the absence of liver disease), tramadol or other opioids should be considered, in order to reduce the bleeding risk. Hormone replacement therapy in menopause and oral contraceptives both increase the risk of venous thrombosis. Metformin in therapy of diabetic patients may be related to a higher perioperative risk of lactic acidosis. Therapy should be changed 48 h prior to surgery.

### Intraspinal and Nerve Root Pathology

Nerve root anomalies are not uncommon

Conjoined nerve roots (two nerve roots in one foramen), and connecting roots may require decompression by foraminectomy or resection of a pedicle. In a recent study, the rate of conjoined nerve roots was found to be 5 % [104]. Coronal magnetic resonance imaging (MRI) is the best method to detect these abnormalities. Intraspinal malformations and tethered cord are not a risk per se. However, an intraspinal abnormality seen on MRI in combination with either an abnormal

neurological examination and/or abnormal evoked potentials at preoperative baseline spinal cord monitoring indicates a spinal cord at risk [72]. The most important pathological findings indicating unsuspected neurological disorders are asymmetric abdominal reflexes.

Always search for absent abdominal reflexes

The prevalence of **tethered cord** in a Turkish study on 5499 schoolchildren was 0.1% in all children, and 1.4% in enuretic children [4]. In juvenile scoliosis [29] and in cases of hemivertebrae [6], more than 20% of patients showed spinal cord abnormalities on MRI such as Arnold-Chiari malformation, syringomyelia, diastematomyelia, or a low conus. Enuresis, gait disturbances, dermatologic signs of dysraphism, spina bifida on plain X-rays, and congenital deformities are frequently associated with tethered cord and cord malformations. MRI is recommended in these cases, and also in left thoracic idiopathic scoliosis.

## Preoperative Planning

The operative strategy has to be clearly defined before the intervention, and is based on imaging. Surprising findings concerning the extent of a tumor, conjoined nerve roots, or vessels entrapped in a scar can be ruled out or can be confirmed in advance. Especially in deformities the direction of pedicle screws can be determined in advance with the help of a CT scan, if navigation is not available. The fusion level must be determined in advance. In this context, the landmarks to determine the **correct fusion levels** should be assessed, e.g.:

Anatomic structures are not reliable enough to determine the correct level

- Are there only 11 ribs?
- Is the C6 transverse process also prominent?
- Are there 6 lumbar vertebrae?

Especial caution is necessary if the indication is based only on MRI findings in the upper lumbar or thoracic spine, such as endplate (Modic) changes, which cannot be seen in the image intensifier. Perioperative measures (Table 4) are helpful to prevent complications.

**Table 4.** Perioperative measures to prevent complications

| | Cervical anterior | Thoracic anterior | Lumbar anterior | Posterior | Deformity surgery |
|---|---|---|---|---|---|
| • identify population at risk | ✔ | ✔ | ✔ | ✔ | ✔ |
| • sufficient imaging | ✔ | ✔ | ✔ | ✔ | ✔ |
| • somatosensory and motor evoked potentials | ~ | ~ | ~ | ~ | ✔ |
| • pulse oximeter left leg | – | – | ✔ | ~ | ~ |
| • positioning avoiding compression of the vena cava | – | – | – | ✔ | ✔ |
| • cell saver technique | ~ | ~ | ~ | ✔ | ✔ |
| • autologous blood donation | – | ~ | ~ | ~ | ~ |

Note: ✔ in any case; ~ in selected cases

### Timing of Surgery

A same day anterior and posterior procedure saves time and the nutrition status is better. However, the longer the operation, the more tired the surgeon and the higher the blood loss. A **staged procedure** may have advantages in the case of:

- myelopathy [114]
- anticipated excessive blood loss (coagulation disorders)
- very long surgeries (exceeding the patient's or surgeon's tolerance)

Otherwise, simultaneous surgery (two surgeons operating on two approaches at the same time) [25] or same day anterior and posterior [119] procedures are

reported to be superior to a staged procedure. In a staged operation, the main decision must be made whether the condition of the patient will allow the operation to be continued the next day. This offers the advantage that the monitoring devices like pulmonary artery or peripheral artery catheters can be left in place. The main problems are **coagulation disorders** requiring a longer period of time between the two interventions. Complication rates, costs (hospital stay) and patients' preference are in favor of single day interventions when compared to staged procedures.

Single stage surgery is generally advantageous but in elderly patients caution is warranted

### Pitfalls and Salvage Strategies

Be prepared for typical pitfalls

A knowledge of the **typical pitfalls** of an operation, and of strategies to cope with them, is necessary before starting. Pitfalls are either approach related or instrumentation related. Instrumentation-related pitfalls often require special instruments or implants. For example, unexpected pull-out of screws or hooks may require special implants which should be available (e.g., thicker screw, bigger hook, or bone cement augmentation).

### Embolization

Consider preoperative embolization for highly vascularized tumors

Bleeding from a metastasis in the case of intralesional resection may be devastating. Preoperative angiographic embolization should be considered, especially in renal carcinoma and thyroid cancer.

## Profound Knowledge of Anatomy

This is as simple as it is obvious. Nevertheless, it should be stressed that a thorough knowledge of the anatomy and a clear vizualization of the surrounding structures are crucial if complications are to be avoided.

## Patient Positioning

### Blood Loss

Prone position with a free abdomen reduces blood loss

Excessive diffuse blood loss can be prevented in posterior procedures by adequate positioning (see Chapter 13) of the patient prone on a Relton Hall frame or other devices with a pendulous abdomen [70], which facilitates the draining of the epidural vessels. **Excessive epidural bleeding** can be **minimized by**:

- positioning of the patient with a hanging abdomen
- avoiding exploring the posterior surface of the vertebra (if not necessary)
- pushing aside epidural veins with the retractor before entering the disc space
- cauterization of veins which cannot be kept away [68]

### Postoperative Blindness

Check the headrest to avoid pressure on the eyes

There are numerous case reports of spinal surgeries which ended with unilateral or bilateral visual loss [3, 65, 81, 112]. The main cause is **retinal artery occlusion** due to pressure on the eye globe by the headrest, ischemic optic neuropathy, and cerebral ischemia. Most cases underwent posterior instrumentation with a long operation time [81]. All precautions to avoid ocular compression must be taken.

## Neuromonitoring

Paraplegia cannot be fully avoided, but any preventive measure with some likelihood of reducing the incidence must be undertaken, including:

Define your workflow on perioperative changes of evoked potentials

- intraoperative spinal cord monitoring [24, 108]
- thorough control of fluid volume, blood loss, and blood pressure

If evoked potentials show increasing potential latency or decreasing amplitude, immediate reaction is required. Somatosensory evoked potentials (SSEPs) usually have a delay in the response, so that a clear association with a certain operative step may not be obvious. Motor evoked potentials (MEPs) are more sensitive [90] so that reaction by either reducing correction or by removing a screw or a hook can be done. In the case of any doubt, a **wake-up test** is necessary. If the wake-up test indicates a neurological deficit, implant removal is required. There are no good comparative studies on the effect of implant removal after pathological potentials and a pathological wake-up test have taken place. In view of the lack of clear evidence in the literature, implant removal is recommended, and also in the light of medicolegal issues. In some specific cases, however, there are clear arguments for leaving the implants in place, for example in the case of resection of vertebra where implant removal will cause the situation to deteriorate.

Motor evoked potentials are more sensitive

In cases with iatrogenic neurologic deficit, complete implant removal is counterproductive if a floating spine will result

## Approach-Related Complications

There is some overlap in procedure and approach related complications. In general, the anterior approach (Table 5) is more prone to serious complications than

**Table 5.** Incidence of complications in anterior thoracolumbar surgery

| Category | Complication | Rate | Sample size | Intervention | Author |
|---|---|---|---|---|---|
| Anterior lumbar interbody fusion | • mortality | 0.15 % | 684 | mini-open anterior lumbar | Brau (2002) [15] |
| | | 1.0 % | 207 | anterior thoracolumbar | Oskouian (2002) [88] |
| | • direct vascular injuries | 3.4 % | 207 | anterior thoracolumbar | Oskouian (2002) [88] |
| | • arterial injuries | 0.8 % | 684 | mini-open anterior lumbar | Brau (2002) [15] |
| | | 0.08 % | 1 223 | anterior fusion | Faciszewski (1995) [33] |
| | • venous injuries | 0.8 % | 684 | mini-open anterior lumbar | Brau (2002) [15] |
| | • deep venous thrombosis | 2.4 % | 207 | anterior thoracolumbar | Oskouian (2002) |
| | | 1.0 % | 684 | mini-open anterior lumbar | Brau (2002) [15] |
| | | 0.3 % | 318 | "major" | Dearborn (1999) [23] |
| | • pulmonary embolism | 2.2 % | 318 | "major" | Dearborn (1999) [23] |
| | • retrograde ejaculation | 0.1 % | 684 | mini-open anterior lumbar | Brau (2002) [15] |
| | | 1.7 % | 116 male | retroperitoneal | Sasso (2003) [99] |
| | | 8 % | 50 male | retroperitoneal | Christensen (1997) |
| | | 13.3 % | 30 male | transperitoneal | Sasso (2003) [99] |
| | | 17.5 % | 40 male | transabdominal | Tiusanen (1995) |
| | • ileus > 3 days | 0.6 % | 684 | mini-open anterior lumbar | Brau (2002) [15] |
| | • superficial infection | 1.0 % | 1 223 | anterior fusion | Faciszewski (1995) [33] |
| | • deep infection | 0.6 % | 1 223 | anterior fusion | Faciszewski (1995) [33] |
| Anterior spinal deformity surgery | • pulmonary complications | 4.9 % (2.2 %) | 447 | miscellaneous, deformities | McDonnell [77] |
| | • related to chest tube | 1.8 % (2.7 %) | 447 | miscellaneous, deformities | McDonnell [77] |
| | • gastroenterological | 1.1 % (2.9 %) | 447 | miscellaneous, deformities | McDonnell [77] |
| | • related to wound | 1.1 % (2.7 %) | 447 | miscellaneous, deformities | McDonnell [77] |
| | • hematological | 0.9 % (0.2 %) | 447 | miscellaneous, deformities | McDonnell [77] |
| | • operative | 0.7 % (1.1 %) | 447 | miscellaneous, deformities | McDonnell [77] |
| | • neurological | 0.7 % (1.8 %) | 447 | miscellaneous, deformities | McDonnell [77] |
| | • genitourinary | 0.4 % (11.6 %) | 447 | miscellaneous, deformities | McDonnell [77] |
| | • cardiac | 0.4 % (0.9 %) | 447 | miscellaneous, deformities | McDonnell [77] |
| | • death | 0.4 % | 447 | miscellaneous, deformities | McDonnell [77] |

Note: When two rates are quoted, the first refers to major, and the second (in brackets) to minor, complications

the posterior one, and some occur more often in the lumbar spine, others in the cervical spine. For the purpose of this chapter, the complications are described where they occur most frequently.

## Anteromedial Cervical Approach

### Vessel Lacerations

Arterial lacerations and venous lacerations are rare, and the same treatment methods as mentioned in the chapter on lumbar vessel laceration can be applied. The internal jugular vein may be ligated unilaterally. Thrombosis of the internal jugular vein frequently occurs associated with hemodialysis catheters, and without important sequelae [116]. Vertebral artery injury occurs in 0.3 – 0.5 % of anteromedial interventions, especially in:

- complete corpectomy with resection of the lateral vertebral wall
- injuries by a burr
- lateral placement of an instrument
- excessive lateral disc removal
- intraoperative loss of the midline landmarks

An anomalous medial course of the artery is described and was found in an anatomic study in 2.7 % of patients. Therefore, preoperative imaging is mandatory [61].

### Superior Laryngeal Nerve Lesion

The superior laryngeal nerve (SLN) originates from the middle of the nodose ganglion of the vagus nerve and divides after an average of 15 mm into an internal and external branch. Caution is extremely important if the contralateral side was operated on for **thyroid surgery** or **neck surgery**, or was **irradiated**. A bilateral lesion interrupts the afferent part of the cough reflex and can cause life-threatening aspiration [78]. The external branch (ESLN) courses distally posterior to the superior thyroid artery, and innervates the cricothyroid muscle, which is responsible for regulating the tension of the vocal cords by rotating the cricoid cartilage. A lesion causes slight hoarseness, voice fatigue, loss of high tonalities, and decrease in voice volume. Therefore, prudence is particularly indicated in singers, teachers and professional speakers. Treatment is not possible. Caution is necessary in any cervical spine operation rostral to C4 [60].

### Recurrent Laryngeal Nerve Lesion

Check larynx function in case of previous surgery or radiation

In a study of 328 cases of anterior cervical spine surgeries, incidence of a lesion was 2.7 %, and lesions occurred with the same rate in right and left sided approaches [10]. The main symptom of a unilateral lesion is hoarseness. A bilateral lesion can cause severe problems to breath, but is assumed to be extremely rare in cervical spine surgery. Continuous laryngeal nerve integrity monitoring did not decrease recurrent laryngeal nerve (RLN) complications in non-randomized controlled studies regarding thyroidectomy. Many false negative cases occurred during monitoring [97, 121]. Spontaneous recovery occurs in about one-third of cases. In the case of previous surgery on the contralateral side, in neurological disorders or after irradiation, preoperative laryngoscopy is necessary to avoid a bilateral lesion.

### Hypoglossal Nerve Lesion

The hypoglossal nerve can be damaged in anterior approaches to the upper cervical spine, and C1/C2 Magerl screws (Case Study 1) penetrating the anterior cortex of the atlas. A lesion causes tongue deviation to the ipsilateral side. Treatment is not possible but spontaneous recovery is frequent.

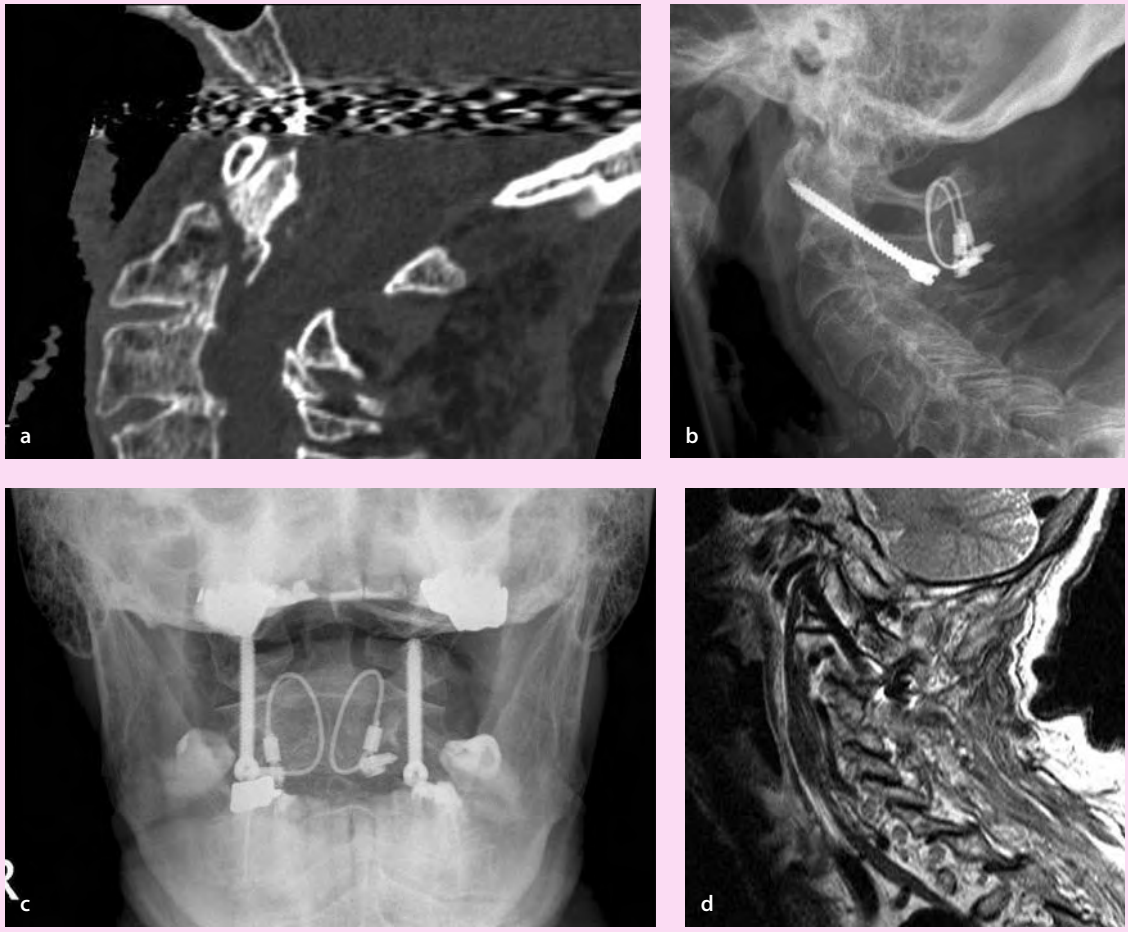


**Case Study 1**

A 79-year-old female presented with severe neck pain 5 months after a fall. The radiologic assessment (a) revealed a dense non-union. Non-operative measures failed and surgery was indicated based on a very painful atlantoaxial instability. A posterior atlantoaxial screw fixation was done with a 5-cm incision at the C1/2 level and a percutaneous screw insertion under biplanar image intensifier control. The skin entry points for the transarticular screws were at the level of T2/3 and the screw trajectory could not be angled more steeply because of the upper thoracic kyphosis with compensatory cervical hyperlordosis. The screw placement and Gallie fusion with a titanium cerclage were carried out uneventfully (b, c). The patient recovered from the surgery without any obvious neurological deficit. However, on the second postoperative day, a deviation of the tongue was noticed. A thorough neurological examination was otherwise unremarkable. An MRI scan was done to rule out any central lesion or bleeding. The T2-weighted MRI scan (d) demonstrated a perforation of the anterior cortex which was done intentionally to increase screw purchase in an osteopenic bone. However, the screw had irritated the hypoglosseus nerve which runs in front of the axis. The tongue deviation recovered spontaneously. This case indicates that the anterior cortex should not be perforated with transarticular screws.

## Anterior Approach to the Cervicothoracic Junction

Lesions to the RLN and Horner's syndrome are described in some case reports. Lesions of large vessels can occur and care must be taken that the surgery can cope with this potentially life-threatening complication [13]. The availability of a vascular surgeon should be clarified preoperatively.

## Thoracotomy

### Lung Lacerations

Suturing the lung is not easy because the suture tends to cut out

A laceration of the lung can be created during blunt dissection of pleural adhesions or by direct trauma with an instrument. Air will exit and can be made visible by irrigation fluid. Treatment includes local closure of the leak and a chest tube. The pleura can be sutured using a 4/0 continuous suture, or synthetic material (Table 6). Fibrin sealant can be injected afterwards to make the lesion airtight. In order to avoid sutures cutting through the lung tissue, the suture has to be placed with a perpendicular, grasping a larger piece of lung tissue to avoid cutting out.

**Table 6.** Synthetic hemostatic materials

| Name | Company | Material | Indications | Extended indications |
|---|---|---|---|---|
| FloSeal | Baxter | bovine derived gelatine and thrombin with mixing accessories and syringe | when control of bleeding by ligature is ineffective | epidural bleeding, lung laceration |
| TachoSil | Nycomed | collagen sponge coated with human fibrinogen and thrombin | for supportive treatment of hemostasis where standard techniques are insufficient | pleural defects |
| Gelfoam | Pfizer | water-insoluble porous product from purified pork skin gelatine. Hemostatic mechanism not fully understood | as a hemostatic device, when other procedures are either ineffective or impractical | |
| Avitene | Davol Inc., Cranston, RI, USA | a microfibrillar collagen product | apply pressure with a dry sponge. the period of time may range from a minute for capillary bleeding to 3–5 min for brisk bleeding or arterial leaks | in neurosurgery apply with a moist sponge. For control of oozing from bone, it should be firmly packed into the spongy bone surface |

Note: Extended indications are not quoted here! The product description of the company has been shortened. For full details see the company description!

Use two chest tubes in case of a hematopneumothorax

In the case of broad pleura adhesions, a large area of the pleura can be destroyed. This area can be covered with Tachosil (Table 6). Air exiting from alveoli will not cause a problem. It can be drained by the chest tube, and the lung will heal. Air exiting from bronchi requires closure of the leak. This is beyond the scope of an orthopedic surgeon, and a thoracic surgeon must be involved. In any case, a chest tube has to be placed where the air is expected to accumulate, usually anterior to the lungs, if the patient is lying in the supine position.

### Lacerations of the Thoracic Vessels

Do not try to repair pulmonary artery lesions – compress them until help arrives!

The azygos or the hemiazygos veins are most likely to be injured, and can be ligated, as well as the segmental vessels. The risk of anterior spinal artery syndrome increases with bilateral ligation of segmental arteries. If this is planned, clamping and neuromonitoring is required. The aorta can be sutured as

described below. A **lesion of a pulmonary artery** requires the most experienced thoracic/vascular surgeon available.

### Pneumothorax

If air in the thorax is detected postoperatively, a chest tube is placed with local anesthesia. A trocar guided chest tube insertion is regarded as dangerous. We prefer a direct tube insertion after **mini-thoracotomy** (3–4 cm incision). In the supine position, the drain must be beneath the anterior chest wall. **Tension pneumothorax** may occur, if not drained. Findings are respiratory distress, tachypnea, unilaterally decreased or absent respiration, tachycardia, and hypotension as the key signs of tension pneumothorax.

A trocar guided chest tube insertion is dangerous

### Hematothorax

If bleeding is expected, a chest tube has to be placed where blood is likely to accumulate, usually lateral to the spine and posterior in a patient lying in the supine position. The chest tube will be removed after criteria established by the department. Some surgeons remove the tube after 24 h, others, if less than 200 ml per day is collected. There is no evidence in the literature on the best way. If **more than 600 ml blood per hour** is lost, revision thoracotomy must be considered. If hematothorax occurs after chest tube removal, ultrasound guided puncture may be sufficient for minor bleedings.

Place the chest tube anteriorly to drain air and posteriorly to drain blood

### Chylothorax

The chyle in the thoracic duct is a **milky fluid**. In anterior approaches to the thoracic spine, especially in trauma or deformities, the thoracic duct may be injured. Ligation is possible, but the vessel is usually hard to find. Therefore, it is better to cover the area, where the leak is suspected, with synthetic material, e.g., Tachosil (Table 6). A chest tube has to be placed posteriorly. The loss of chyle may be considerable and can range up to 6 L/day (average production is 40 ml/kg body weight). Treatment is normally non-surgical with either total parenteral nutrition or enteral low fat solid food or an enteral elemental diet supplemented with intravenous lipid emulsion, until the lymph leak heals, which takes an average of 30 days. Lymphocytopenia and hyponatremia are frequently seen [84].

Postoperative chylothorax is treated by parenteral nutrition and chest tube

### Pleural Abscess

The stage of the disease decides the required procedure. In early cases with liquid pus, chest tube drainage is sufficient. Failure to evacuate the pleural space or persistent signs of infection should prompt surgical intervention by open thoracotomy or thoracoscopic evacuation. In late cases with lung entrapment, **decortication** (resection of the visceral pleura) may be necessary.

### Insufficient Postoperative Oxygenation

Insufficient postoperative respiration can occur in patients with deformities and severely impaired lung function, and in neuromuscular diseases such as Duchenne's disease. An approach through the diaphragm (Hodgson approach) causes a reduction of vital capacity of about 20 % for one year. A rib hump resection may cause a decreased lung volume [71]. Both measures can cause a borderline sufficient respiration to deteriorate. On the other hand, if correction does not reduce lung volume, corrections can be performed even in patients with a vital

A thoraco-phrenico-lumbotomy decreases vital capacity by about 20 %

capacity of less than 40 %. Recently, Wazeka et al. reported on deformity correction in 21 patients with a mean predicted vital capacity of 32 %, who needed postoperative supplemental oxygen for 0 – 90 days. Two developed pneumonia, two pleural effusions, and atelectasis was found four times. There were no mortalities or adverse neurological outcomes [115]. Tracheotomy may be required if the patient is not able to breath sufficiently for days. Exercises can increase the vital capacity as well. In rare cases with no recovery, there is a need for a continuous oxygen supply via a transportable oxygen bottle.

## Thoracolumbar Approach

The same lesions as with the thoracic and lumbar anterior approaches can occur but the liver and the spleen are at risk during this approach.

### Liver Lesion

Repair of a bleeding liver lesion requires a specialized surgeon

A subcapsular hematoma does not require an intervention. Open bleeding from the liver requires a specialized surgeon. Postoperative suspicions should be investigated with ultrasonography.

### Splenic Injury

There are few case reports of accidental splenic injury during anterior spine approaches [20] especially the left sided approach to L1/L2. In other interventions like esophagectomy, the mortality and sepsis rate increase with splenectomy. Therefore, preservation of the spleen should be the aim of treatment whenever a splenic injury occurs. Observation or hemostatic agents can be used for grade 1 and 2 (subcapsular hematoma < 50 % of surface) [79]. Reconstruction or resection is the treatment of choice in grades 3 (> 50 %) to 5 (shattered spleen).

## Anterior Lumbar and Lumbosacral Approach

Due to the high rate of anterior lumbar interventions and the proximity of vessels, the lumbar spine is the most common location of vessel lacerations.

### Arterial Laceration

After suturing an artery, check for thrombosis and monitor vascularization by pulse oximetry

An intraoperative open arterial bleeding is usually caused by sharp dissection of the artery. This can occur accidentally with a sharp instrument, or during dissection in scar tissue. A temporary vessel loop may facilitate the repair (Fig. 1). However, the inexperienced surgeon is at risk of increasing the problem when trying to prepare for the insertion of the vessel loop. It is recommended that the less experienced surgeon is better to wait for the help of a vascular surgeon. A simple incision of the artery can be sutured with 3-0 monofilament double ended sutures for the aorta and 4-0 for thicker vessels like the common iliac artery (Fig. 2). It is important to suture the entire wall of the artery including the intima; otherwise the intima can occlude the vessel (Fig. 3). Occlusion of the vessel adjacent to the laceration by vessel loops is mandatory. Thrombectomy with a Fogarty catheter has to be done first, and intravascular heparin (5 000 IU) is administered before final closure. Just before the last knot is made, some blood is allowed to escape, in order to get the air out of the vessel. To make the suture tight, synthetic hemostatic material (Table 6) may be administered. Due to the risk of postoperative arterial thrombosis, it is recommended to consult a vascular surgeon in any case. Postoperative monitoring of the blood circulation of the leg is required using a pulse oximeter.

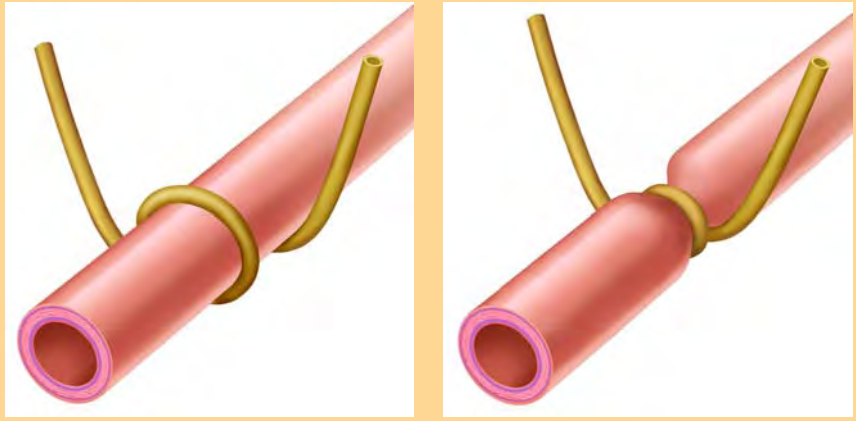

**Figure 1. Vessel loop**

A vessel loop is put twice around the artery. With this technique the artery can be closed by pulling on both ends.

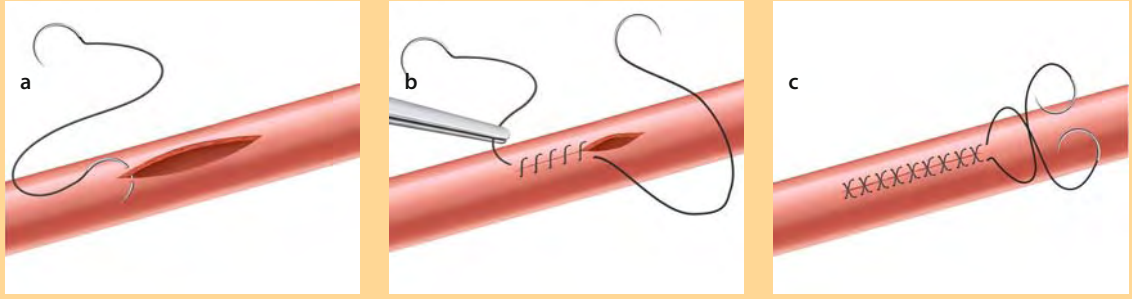


**Figure 2. Suture of a tear in a vessel**

A monofilament double ended atraumatic suture is used. One end of the suture is fixed, and then a continuous suture is made with the first needle, and consecutively with the second needle. In small children, single knots are better, because a continuous unresorbable suture cannot grow. This suture technique can also be used to repair a dural leak.

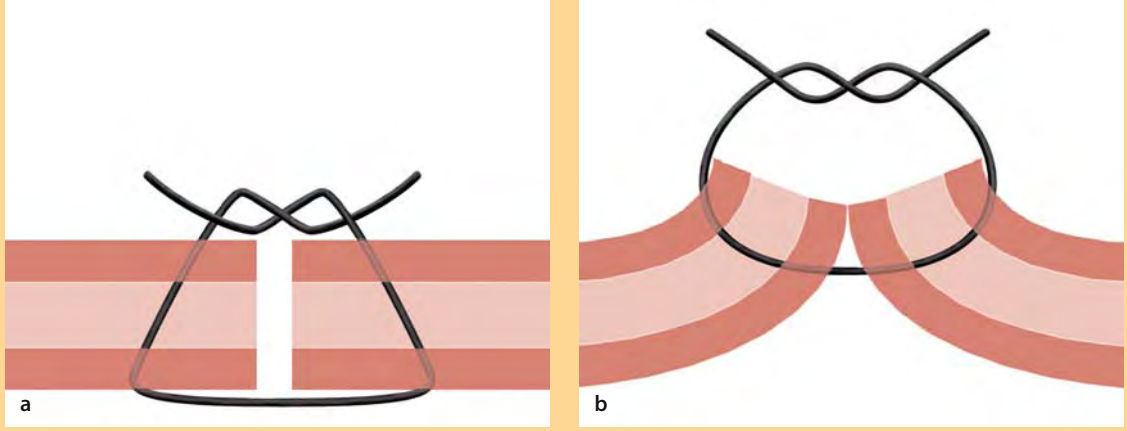


**Figure 3. Suture of a tear in an artery**

The suture canal should be oblique. The intima is perforated further away from the tear than the serosa, in order to create eversion of the vessel wall, and to avoid the intima occluding the vessel.

### Arterial Thrombosis

Avoid pressure on lumbar arteries by sharp-edged retractors or pins

The rate of arterial thrombosis was 0.45 % in 1 315 consecutive cases undergoing anterior lumbar surgery at various levels from L2 to S1 [16]. The main causes are either a tear in the intima, or compression of more than 50 % of the lumen. Atherosclerotic plaques increase the risk. A cautious surgical technique can reduce the incidence of arterial thrombosis. The pressure of **sharp-edged retractors** or of pins should be avoided [66] and artery and veins should not be separated in order to keep the lymph vessels and crossing blood vessels intact. Even in posterior fusion, direct pressure on the inguinal region may cause occlusion [1].

Do not postpone treatment by planning angiography or ultrasound

Late symptoms are paralysis and sensory impairment usually of the left leg, and cyanosis of the toes. Delayed thrombectomy after wound closure and angiography will cause severe residual symptoms due to **compartment syndrome** [19, 47, 66, 74, 94]. Therefore, arterial thrombosis must be detected before symptoms occur. Similarly to arterial laceration, postoperative monitoring with a pulse oximeter is essential.

### Venous Laceration

Major vein lacerations are usually detected during surgery. If a vein is compressed, a stab wound can be caused by a pin. In anterior lumbar interbody fusion, the left ascending iliolumbar vein is recommended to be ligated in advance, because avulsion may be difficult to treat. There are several opportunities for treatment:

#### *Suture*

Usually, a 5-0 double ended monofilament suture is used (Fig. 2). Direct repair is chosen if the defect is easily accessible, and if the resulting stenosis is expected to be less than 50 % of the lumen. Some stenosis can be accepted, and may be even beneficial, causing a higher speed of blood flow which may reduce thrombosis rate. Postoperatively, heparin treatment for 5 – 7 days or during hospital stay is recommended followed by LMWH or other vitamin K antagonist treatment for 4 – 6 weeks, in order to prevent rethrombosis. Heparin treatment can be performed for example with enoxaparin (Lovenox) starting 4 h after surgery (1 mg/kg two times per day). Postoperative monitoring for thrombosis is also essential. The recurrent thrombosis rate is 20 %. Doppler sonography studies are recommended in the case of clinical suspicion.

#### *Compression and Hemostatic Agent*

Most small venous lesions are sealed by pressure only

The maintenance of pressure for about 5 min is essential, and is usually performed with the help of a collagen sponge. **Hemostatic agents** (Table 6) are chosen either if the tear size is less than 5 mm or if the tear is difficult to access.

#### *Ligation*

Ligation is the method of choice in catastrophic situations. Before ligation of a large vessel, a vascular surgeon should be consulted. Other measures including end-to-end anastomosis as well as interposition grafts or patches must be considered. The common iliac vein can be ligated in a life-threatening situation. Even the inferior vena cava can be ligated below the renal veins, and sequelae like permanent edema of the legs are rare [111].

In a recent study [86], 18 % of patients with iatrogenic injuries to major abdominal or pelvic veins died due to:

The mortality from major abdominal vessel injuries is high

- uncontrollable bleeding
- multisystem organ failure
- pulmonary embolism

The blood loss ranged from 500 ml to 20 000 ml. Therefore, any attempt must be undertaken to avoid venous lacerations.

### Bowel Perforations

These are rare and usually occur during anterior procedures. There are also some case reports of perforations during microdiscectomy [42, 55, 58]. A laceration of the serosa can be sutured superficially. A perforation will require continuous two-layer stitches, through the periphery of the mucosa and the entire muscle. If a part of the bowel is destroyed, resection will be necessary. The likelihood of contamination and consequently of the formation of abscesses increases from proximal to distal, with almost no danger of contamination in the small intestine, and a high danger in the sigmoid colon. Postoperative antibiotic treatment is required.

Bowel perforations must be repaired

### Ureteral Injury

Some cases were reported which occurred during anterior lumbar surgery, especially in laparoscopic surgery [44] and disc prosthesis [39]. The diagnosis is often made postoperatively, and the main reasons are misplaced stitches or clips to stop bleeding. Treatment is an end-to-end anastomosis or implantation of the rest of the ureter into the urinary bladder performed by a **urologist**. A short-lasting contusion by a stitch or a hemostat usually does not require surgical treatment, but requires postoperative observation including ultrasonography of the kidney [49].

### Urinary Bladder Injury

The incidence is rare. The urinary bladder is sutured with two sutures. After suturing the muscularis and mucosa with continuous atraumatic 3-0 stitches, the peritoneum is separately sutured. A urethra or suprapubic catheter is applied for 10 days, and antibiotics are administered during this time [49].

## Posterior Approach to the Cervical Spine

### Postoperative Kyphosis

Failed reattachment of the semispinalis during laminoplasty may lead to postoperative kyphosis. Reattachment should be performed, but anatomic variation has to be considered [110]. Resection of the C2 spinous process should be avoided in order to prevent kyphosis.

Postoperative kyphosis results can result from inappropriate technique

### Vertebral Artery Injury

The lesion is rare and occurs in 4.1 % of transarticular (C1/2) screw fixations [120]. Biplanar imaging guidance has decreased the incidence. Most patients remain asymptomatic after the incidence. The risk of neurological deficit from vertebral artery injury was 0.2 % per patient or 0.1 % per screw, and the mortality rate was 0.1 % [120]. Devastating complications may occur in lesions of a unilateral artery, or in the case of a contralateral artery with thin lumen. Preoperative

imaging is mandatory in order to determine salvage strategies in advance. Hemostasis may be achieved by **compression and packing**. If the lesion occurred during drilling, a screw in the drill hole is a good option. The screw at the opposite side, if not in place, should be skipped, and a salvage Gallie procedure can be performed instead of using Magerl screws. Pseudoaneurysm and arteriovenous fistulae are rare sequelae [61]. Stenting may be efficacious.

### Posterior Approaches to the Thoracic and Lumbar Spine

Approach-related intraoperative complications are rare. Excessive bleeding can occur. The risk is reduced by adequate patient positioning and change of platelet inhibitors and anticoagulants to other drugs preoperatively. Very rarely, lesions of anterior structures occur due to direct accidental stab trauma. Relatively rare is an accidental lesion of the dural sac or of the spinal cord during preparation of the approach. It is mandatory to use imaging to determine whether the posterior vertebral elements are intact; otherwise, preparation has to be conducted with more caution.

## Procedure Related Complications

### Decompressive Cervical and Lumbar Surgery

Check preoperative X-rays for bony defects

Decompressive surgery in the cervical and lumbar spine is the most frequently performed intervention but also prompts the need for revisions and surgery of the adjacent segments. In some cases, complications can be avoided if the preoperative radiograph is checked for bony defects. In primary cases, this precaution helps to avoid unintended dural lacerations (e.g., in spina bifida occulta).

#### Epidural Vein Bleeding

The blood loss may be considerable and can substantially reduce visualization, compromising surgical success. Epidural bleeding usually stops after wound closure and turning the patient into the supine position. Reports on cauda equina syndrome caused by postoperative continued epidural bleeding are rare [52]. Severe bleeding from epidural veins occurs in 3.5 % in the hands of very experienced surgeons, and in 7 % in the hands of experienced surgeons [68].

If severe bleeding occurs, it is sometimes better to continue removing the disc herniation rather than attempting to coagulate the bleeding epidural vessels. Bleeding often stops after removal of the disc herniation and facilitates exploration of the bleeding vein. Compression of the vessel with a neurosponge allows the bleeding to be controlled in the vast majority of cases. Generally, bipolar cauterization may be necessary but should be limited because of postoperative scarring. Floseal is a very efficient material to stop epidural bleeding. Usually, this agent increases its volume, so that application in the vertebral canal requires caution. Removal of the agent by irrigation is recommended when the bleeding has stopped.

Wash out Floseal after epidural vein bleeding has stopped

#### Nerve Root Injuries

A nerve root may be damaged by:

- malpositioning of a pedicle screw (Fig. 4)
- direct pressure or traction during decompression (e.g., PLIF procedures)
- sharp instrumentation (high speed burrs)
- cauterization (heat)

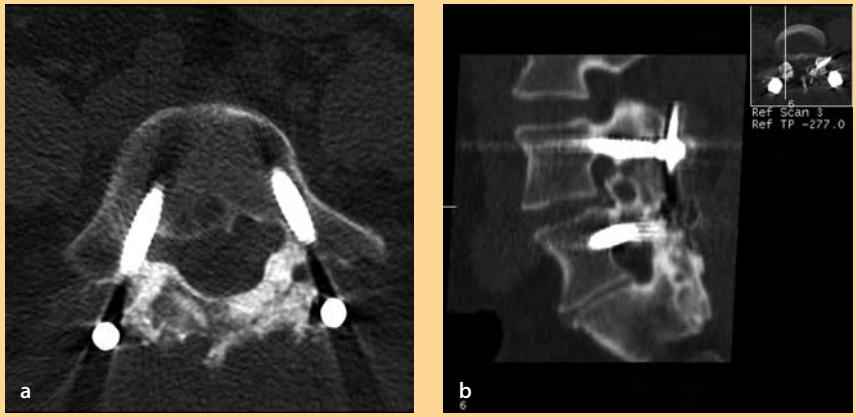


**Figure 4. Malpositioning of a lumbar pedicle**

a The axial CT scan shows that the pedicle screw has perforated the medial pedicle wall because of a far lateral recess. b CT reformation of the images demonstrates that the screw has perforated the inferior medial aspect of the pedicle, which has led to a nerve root irritation. The pedicle was still intact after screw hole preparation with a blunt pedicle finder (4 mm). However, the pedicle screw (7 mm) perforated the pedicle cortex, which was not noticed. In questionable cases, it is recommended to again remove the screw after it has passed the pedicle and entered the vertebral body. However, do not completely insert the screw if you want to remove it again to probe the pedicle because of the limited bony purchase with screw reinsertion.

Poor visualization due to bleeding, perineural fibrosis, or congenital vertebral (e.g., dysplastic pedicle) or neural abnormalities (conjoined nerve roots) increases the risk of damage. The most vulnerable area for a lesion is the axilla of the nerve root. Therefore, a good preventive principle is to stay lateral to the nerve root when removing disc material [68]. Herniating root fibers have to be reduced, and the defect has to be closed. However, a suture of the dura is very difficult and can cause stenosis. A fat or collagen pad or an artificial dura (e.g., TissueDura) with fibrin sealant is recommended to close the leak.

### Cauda Equina Syndrome

There are several reports on postoperative cauda equina syndrome after discectomy for lumbar disc herniation [28, 52]. A frequent cause is extraction of a large disc fragment through a small flavum window (microsurgical approach). The syndrome is caused by direct pressure or by postoperative hematoma. A further cause may be venous congestion in the presence of preexisting lumbar spinal stenosis [52]. Extended decompression as soon as possible is recommended but recovery is often only partial.

### Unintended Durotomy

The risk of unintended durotomy and cerebrospinal fluid (CSF) leaks can be reduced with increasing surgical experience. However, sometimes minor tears may become symptomatic only days or weeks after surgery (Case Introduction). In severe spinal stenosis, which often presents with adhesions, dural tears occur even in the hands of experienced surgeons. Closure of the defect is generally recommended. The following treatment options are available:

Dural tears should be repaired (if possible)

#### *Suture*

The leak should be covered with a neurosponge until the repair is performed. The leak can be sutured with non-resorbable 5-0 suture (interrupted or running) and should be watertight. But care must be taken not to create a stenosis or suture in a root fiber. It is debatable whether a small arachnoidal cyst should be opened prior to the repair. In this setting, Gehri et al. [40] have reported a case in which the suture of an arachnoidal cyst injured a small dural vessel and created a subdural hematoma. It is advisable to control the tightness of the dural repair before closing the wound. This is done either by tilting the table to increase the pressure within the dura, or by **high pressure respiration** (increased PEEP). The muscle fascia of the back muscles and the skin should be sutured so they are watertight.

#### *Patch*

If the dura is extremely thin or a large defect was created, the defect can be covered with fascia, muscle, fat, or synthetic material such as Tissue-Dura (Baxter), Durepair (Medronic) or DuraGen (Integra). A fibrin sealant (e.g., Tissucol) can be used to improve the closure. In complicated cases, however, a formal plastic repair is necessary. In complicated cases, an external CSF drainage is necessary.

#### *Leave It Open*

Small CSF leaks often cause more problems than large defects

If there is no way to close the leak, it can be left open. In this case, it is absolutely necessary to avoid formation of a CSF fistula, i.e., the wound closure must be watertight. A pseudo-meningocele sometimes develops but usually does not harm the patient. The CSF is very pervasive and will find its way out of the body. A drainage (as overflow) is therefore recommended until the skin has healed.

Repair the dural defect whenever possible

Antibiotic prophylaxis is recommended as long as there is drainage from the wound or a drain is in-situ. In cases with adequate dural repair, bedrest is usually not required. NSAIDs are administered for headache.

### Lesions of Anterior Structures

Some case reports exist of intra-abdominal vascular or bowel injuries during lumbar disc surgery [42, 44, 113]. Frequently, the stab wound is caused by a sharp instrument or a rongeur (perforating the anterior anulus fibrosus). When using a sharp instrument (e.g., chisel), the instrument has to be held tight to counteract forces exerted by the hammer. The surgeon must always be aware that a structure can suddenly break or is released jeopardizing underlying structures.

Anterior vessel injury by a posterior approach is a life-threatening complication

In the devastating situation of a **major bleeding from an anterior vessel**, the patient has to be turned supine after compressing the wound with sponges as effectively as possible. The posterior wound should be closed provisionally with large stitches. The patient should immediately be positioned supine for an anterior approach. Vessel repair must be done by the most experienced (vascular) surgeon available.

## Deformity Correction

### Spinal Cord Injury

Spinal cord injury is the most serious complication and most frequently occurs in deformity correction. There may be several reasons for spinal cord injury:

### *Direct Spinal Cord Injury*

Direct injury may occur by improper placement of screws, hooks, sublaminar wires, or may result from a fracture of the lamina, pedicle or posterior wall of the vertebral body during correction maneuvers. Postoperative MRI may reveal bleeding or ischemia in the spinal cord. Even delayed spinal cord injury can occur due to compression by an implant in a narrow spinal canal [64]. For legal reasons, the proportion of paraplegia caused by direct injury is not known. However, reports on neuromonitoring, where evoked potentials were restored after implant removal, suggest that these cases exist.

Direct spinal cord injury can occur by implants, instruments or bony spurs

### *Distraction*

Distraction may cause paraplegia especially in rigid angular curves, and in the presence of malformations like diastematomyelia, where distraction of the spinal cord can move the cord along a bony or fibrous spur in the cord. In more than half of the cases of diastematomyelia combined with congenital scoliosis, a neurological deficit can be found preoperatively [56].

Distraction leading to spinal cord injury is an avoidable complication

### *Anterior Spinal Artery Syndrome*

Anterior spinal artery syndrome is a **devastating complication**. Somatosensory evoked potentials are likely to be false negative at the onset of the syndrome [7, 83], but motor evoked potentials will show the lesion immediately. It may be caused by several mechanisms:

- distraction
- hypotensive anesthesia
- vessel ligation
- unknown causes

The blood flow in the anterior spinal artery can be decreased during distraction. At least 65 % of baseline blood flow is required to maintain spinal cord integrity [83]. Hypotensive anesthesia or a sudden decrease of blood pressure may interrupt sufficient oxygen supply of the motor fibers. In this condition, deformity correction should be avoided until blood pressure and volume have been corrected.

Avoid spinal deformity correction in severe hypotensive and hypovolemic anesthesia

**Vessel ligation** can cause anterior spinal artery syndrome in vascular surgery for aortic aneurysm. However, it is very unlikely to cause paraplegia in orthopedic cases, because in deformity surgery it is done unilaterally and on the convexity of the curve. Nevertheless, it is recommended to provisionally clamp vessels (control the effect with MEPs), ligate vessels only at the midvertebral level (collateral supply), and to avoid hypotensive anesthesia.

In a large study, not a single case of paraplegia was found in more than 1 000 anterior operations [118]. In tumor resection, bilateral artery ligation may be required, and there are some reports of the syndrome in these cases [30]. Paraplegia especially due to anterior spinal artery syndrome can occur up to 3 days after surgery [107]. In cases with large deformity corrections, low postoperative hemoglobin and hypotension should be avoided to allow for an adequate vascularization of the spinal cord, which may be compromised by the correction [51].

Avoid low postoperative hemoglobin and hypotension after large deformity correction

## Reduction of High-Grade Spondylolisthesis

### Neural Injuries

In high-grade spondylolisthesis (see Chapter 27), particularly the L5 nerve root is at risk. The incidence depends on the surgical technique and may be higher than 50 % if full reduction is attempted [14]. More than 50 % of the lesions resolve with time. The nerve root lesion can become clinically apparent even hours after the completion of the operation. Neural compromise can occur by **three mechanisms**:

- cauda equina compression
- foraminal impingement
- nerve root stretching

Avoid complete correction of high-grade spondylolisthesis

A cauda equina syndrome can occur as a result of a **compression over the posterior edge** of the sacral dome after in situ arthrodesis with or without decompression [75]. Immediate decompression including resection of the dorsoapical rim of the sacral dome is recommended [103]. **Foraminal stenosis** is a frequent finding in high-grade spondylolisthesis [63]. Correction of the lumbosacral kyphosis reduces the foramen even more. Sagittal translation of the slipped vertebra causes a **non-linear nerve root stretch** (70 % of the stretch occurs after a reduction of more than 50 %) [91]. It is therefore recommended to avoid a correction of more than 50 %.

Complete corpectomy in high-grade spondylolisthesis may lead to life-threatening uncontrollable bleeding

### Major Bleeding

In **Gaines procedures** (complete corpectomy of the slipped vertebra), life-threatening bleeding can occur from the **pre-sacral venous plexus**. Sponges and hemostatic agents (Table 6) can be used to control bleeding.

## Corpectomy/Osteotomy

### Excessive Bleeding from Bone

Blood loss during corpectomy and osteotomy can be excessive and can rapidly cause hemodynamic problems. Control of bleeding by compression with sponges is the first method which creates time for further planning. If the bleeding is from cancellous bone, bone wax and hemostatic agents are helpful (Table 6). In cases of arterial or venous injuries from major vessels, the outline recommendations above apply.

### Excessive Tumor Bleeding

Always prepare the instrumentation prior to tumor removal

The optimal way to prevent bleeding is by preoperative embolization [45, 82, 87]. However, this is not always possible. Resection should always start in areas not affected by the tumor (e.g., the intervertebral disc), and instrumentation (e.g., screw placement and unilateral rod implantation) should be prepared to allow for a rapid determination of the surgery in the case of hemodynamically relevant bleeding. If bleeding occurs, a practical approach is to remove the tumor as quickly as possible, and then to control the bleeding. However, this must be planned and coordinated with the anesthetist. It is not wise to start tumor removal when the patient is hemodynamically unstable.

## Postoperative Complications

Surgery does not end with skin closure

Postoperative management is a decisive factor for the success of the surgery. It must be structured and a close communication between the involved specialists is mandatory.

**Postoperative monitoring** should follow a protocol with regard to:

- blood loss
- required laboratory analyses
- neurological examinations
- vascular examinations

Threshold values for action must be defined (blood loss per hour), as well as pathways for examination in the case of bleeding or a neurological deficit.

## Homeostasis Related Complications

### Postoperative Bleeding

The amount of blood loss varies considerably with the surgical intervention. In the case of significant or unexpected blood loss detected either by loss through a drainage system or a decrease of hemoglobin concentration, a vital level of hemoglobin has to be maintained, and the cause of bleeding must be assessed. The **minimal accepted hemoglobin concentration** depends on age, comorbidity and type of surgery. As a rule, 6 – 7 g/dl can be accepted in children and 8 – 10 g/dl in elderly people without comorbidity. However, it is important to individually define the minimally accepted hemoglobin concentration based on the patient's general condition and type of procedure (e.g., deformity correction). In elderly people, the individual risk of stroke, cardiac failure and renal failure must be considered.

A **threshold amount** (e.g., 600 ml/h) **of blood loss** from a chest tube or suction drain is difficult to define and depends on:

The indications for when to revise depend on the patient and type of surgery

- body weight
- age
- homeostasis
- hemoglobin
- confounding diseases
- availability of blood
- surgical situation

A **coagulopathy** or bleeding from a large, perhaps tumor infiltrated wound area cannot be controlled by surgery alone. An **unexpected major bleeding**, not caused by a coagulopathy, **requires imaging**, i.e.:

- angiography
- contrast CT

**Angiography** is the best choice, because interventional closure of a vessel can be performed. Segmental vessels of the spine and vessels supplying a tumor can be occluded by subsequent coil embolization or stent implantation. Contrast CT scan is less time consuming than angiography, and also provides information about the bleeding site. This method is preferred if bleeding from a large vessel in the pelvis is suspected, and if the cardiovascular status of the patient allows a delay.

### Postoperative Hematoma

In posterior approaches, hematomas normally do not cause major problems. The patient is usually lying supine in the early postoperative course, and the pressure of body weight on the posterior wound does not allow large hematomas to develop. The rate of infection in large hematomas is not established, so that clear guidelines of when to evacuate a hematoma cannot be drawn up. Even evidence to use or not to use a closed suction drain is lacking [89].

### Retroperitoneal Hematoma

The retroperitoneal space can contain 3-4 L of blood, and can cause an ileus, which can usually be treated conservatively. If bleeding has stopped, evacuation will be necessary only in rare cases.

### Epidural Hematoma with Neurological Deterioration

Epidural hematoma causing cauda equina compression requires urgent decompression

Extradural hematomas can be seen relatively often in MRI scans after decompressive surgery but seldom cause compression. Immediate decompression is required in case of a cauda equina syndrome. In elderly patients with extensive decompression, thromboembolic prophylaxis should be started postoperatively instead of preoperatively as a preventive measure (although not evidence based).

## Neurological Complications

A thorough postoperative neurological examination is a must

It is self-evident that a thorough neurological examination must be performed as soon as the patient is fully awake. Neuromonitoring helps but cannot completely avoid neurological complications.

### Nerve Root Injury

If a nerve root injury is discovered postoperatively, analysis is preferably done by MRI scan. A CT scan can show the position of pedicle screws more precisely than MRI. Malpositioning of a pedicle screw must be corrected as soon as possible.

### Spinal Cord Compromise

In the SRS Morbidity and Mortality Report 2003, the incidence of developing a complete paraplegia was 0.1 % related to all spinal operations, and 0.2 % for incomplete paraplegia. Delayed paraplegia developing in the first three postoperative days is rare but does occur [107]. Hypotension, hypovolemia and anemia should be avoided in patients who have undergone major corrective surgery. In case of a spinal cord syndrome, rapid assessment of potential causes is self-evident. Spinal cord compression can occur due to an epidural hematoma, implants (hooks, malpositioning of pedicle screws), bone cement after vertebroplasty, and homeostatic material (Table 6). In case of deformity correction, the correction must be released but it remains a matter of debate whether all implants must be removed.

## Postoperative Wound Problems

In case of postoperative fever, rule out wound, lung, urinary tract and catheter infection

The prevailing symptom of a wound infection in the immediate postoperative period is:

- fever

However, an elevated temperature (< 39 °C) up to the third postoperative day is not worrisome and is most often related to a hematoma resorption or postoperative aggression syndrome, although infection parameters should be determined as a baseline and allow the further course to be judged.

According to the CDC (Center for Disease Control and Prevention) classification, superficial and deep infections are differentiated. A **superficial infection** is located in the skin and subcutis, and a deep infection below the muscle fascia. Wound erysipelas is a special form of superficial cutaneous infection, e.g., streptococci spread by the lymphatic system. **Deep infections** may be dependent on the presence of an implant [57]. Ultrasonography with needle aspiration can be helpful to distinguish between deep and superficial infection [67]. CT scans with contrast media or MRI scans are often used to demonstrate infections, but there is no evidence on the sensitivity or specificity available. There is also a lack of published data on the ability of imaging methods to distinguish between hematoma and infected hematoma. There is a considerable variation in the number of surgeons applying CDC categories [117]. It is also not possible to recommend either exploration of the entire wound in every infection or to treat an infection as a superficial infection until direct proof of a deep infection. The probatory inspection may bring bacteria into contact with an implant if the infection was in reality suprafacial, and in other cases proper treatment of a deep infection may be postponed.

The differentiation of superficial and deep spinal infections is arbitrary

In equivocal cases always explore and debride the entire field of surgery

### Superficial Infection

This may cause prolonged wound healing, and occurs in 2–3 % of cases in lumbar discectomy [93], 0.9 % in lumbar fusion [38] and in more than 5 % in pediatric patients with deformities due to cerebral palsy [109]. In the study by Szoke et al. [109], all superficial infections were treated successfully by antibiotics and local wound care. To prevent a superficial infection, pressure to the skin must be avoided, and also the use of electrocoagulation for skin dissection may increase the risk. Before systemic antibiotic administration, a **culture** should be taken by a swab or better a **deep biopsy**. Treatment depends on the cause. A widespread infection, especially erysipelas, is treated by antibiotic administration. Frequently, excision of the wound, mobilization of the skin and re-sutures are the best way to achieve early healing.

Deep biopsies provide a more reliable result than a swab

### Deep Infection

Deep infections occur in 2.4 % of spinal fusions [38], and more than 4 % in pediatric patients with deformities due to cerebral palsy [109], and are treated by debridement, irrigation or hardware removal. Early debridement is especially recommended after instrumented fusion, when clear signs of deep infection are found. Otherwise, **biofilm-forming bacteria** (staphylococci) can only be eliminated by implant removal. Implant removal of long posterior instrumentations and subsequent use of a brace causes loss of correction [92]. Reinstrumentation in a single stage intervention reduces this risk [80]. Titanium implants appear to be less susceptible to infection than stainless steel implants and can remain in place if a radical debridement of the wound is performed.

Titanium implants are less susceptible to infections and can be left in situ after debridement

### Spondylodiscitis

Spondylodiscitis may occur after discography and intradiscal procedures. A dural abscess may develop. Fever and severe back pain or neck pain can arise in the first postoperative days. Persistent or increasing back pain after intradiscal

procedures with or without increased infectious parameters should prompt the suspicion of a discitis. Incidence is less than 1 % [46, 53, 96, 98]. MRI is the imaging modality of choice. Subsequent to a biopsy to determine the germ, systemic antibiotic treatment is usually sufficient. Even an epidural abscess without neurological symptoms can be treated this way. A psoas abscess or a paraspinal abscess can be drained after percutaneous puncture either under ultrasound or CT guidance. Outcome is usually good but about 50 % progress to spontaneous interbody fusion [76]. Open surgical treatment follows the rules outlined in Chapter 36.

### Persistent Wound Drainage

Rule out infection in case of persistent wound drainage

The cause of this is either infection or a seroma. Ultrasound or other imaging methods can be used for differentiation. **Low serum albumin** concentration can contribute as well but it is debatable whether substitution of albumin is helpful. Treatment options for postoperative seromas and persistent drainage include observation for spontaneous resolution, external compression by bandages, and wound revision with the aim of closing an empty space. Frequent wound disinfection and proper wound dressing diminish the risk of secondary infection.

## Cerebrospinal Fluid Fistula

Small leaks often cause more problems than large defects

In the case of wound drainage, a CSF leak must be excluded. The diagnosis of a CSF leakage does not cause diagnostic problems if a clear fluid drainage is seen. In unclear cases, the glucose concentration can be determined (50 – 80 mg/100 ml), which is much higher than in a seroma. The CSF production is about 500 ml/day and drainage can therefore be considerable. Intermittent CSF loss causes neck stiffness (in 83 %), headache (87 %), nausea, and dizziness. Headache will get worse in the upright position, and is ameliorated in the supine position. This so-called **hypoliquorrhea syndrome** (Case Introduction) is most often observed in small lesions which form a valve mechanism and hardly ever occur with large defects.

The principles of treatment have been outlined above. In uncomplicated cases, a simple stitch over the part of the wound where the CSF is leaking suffices. Prophylaxis with antibiotics which pass the blood-brain barrier are recommended until wound secretion has stopped and all drains are removed.

## Vascular Complications

Postoperatively or after angiographic interventions, the arteries have to be monitored. In arteries supplying the legs, a pulse oximeter can be used for monitoring, and the leg compartments have to be controlled as well. **Arterial thrombosis** should be managed as an **absolute emergency case**.

### Postoperative Venous Thrombosis

In a recent review by Baron and Albert [5], the rate ranged between 0.3 % and 1 % with the exception of a single study on a small sample size. In a Japanese study containing 3 499 patients, it was only 0.1 % [85]. In neurosurgical procedures in 2 643 patients and by use of duplex ultrasound scanning, the rate was 6 %, 8 % in craniotomy and 1.5 % in cervical and lumbar spine procedures. Of these, 90 % had malignant neoplasms, and 70 % had lower-extremity neuromotor dysfunction [36]. Epstein [32] concluded that low molecular weight heparin should be recommended for prevention, but its use must be weighed against the risk of

hemorrhage. The duration of prophylaxis remains unclear. Our recommendation is to administer a thromboembolic prophylaxis during the hospital stay and in high risk patients (tumors, paralysis). If a venous thrombosis is suspected (swollen leg, pain), duplex ultrasound is recommended. Treatment is the administration of LMWH and compression stockings for at least 3 months.

## Pulmonary Problems

### Pulmonary Embolism

The rate of fatal lung embolism after spinal surgery is very low

Fatal long embolism is extremely rare. According to the Morbidity and Mortality Report of the Scoliosis Research Society [21], the rate of fatal pulmonary embolism (PE) is **0.02** %. The true rate of non-fatal PE may be underestimated because of a subclinical course. The rate may vary between 0.5 % (posterior surgery) and 6 % (combined anterior/posterior surgery) for adult spinal surgery [23]. **Typical signs of PE** are:

- chest pain
- pulse acceleration
- insufficient oxygenation

Diagnosis of central pulmonary embolism is made by multi-slice CT scan, and treatment is usually by high dose low molecular weight heparin.

### Pneumonia

The incidence of pneumonia after spinal interventions for adult spinal deformity correction ranges between 1 % and 3.6 % [5]. Antibiotic treatment is usually sufficient. Overdosage of opioids in elderly patients can result in aspiration pneumonia. A progression of pneumonia to an adult respiratory distress syndrome (ARDS) is very rare but can be lethal.

## Gastrointestinal Problems

### Postoperative Bowel Atonia

A large retroperitoneal hematoma increases the risk of a paralytic ileus

Bowel atonia is a common problem after anterior lumbar approaches and usually lasts for 3 – 5 days. A large retroperitoneal hematoma and a low serum potassium level increase the risk of paralytic ileus. Symptoms are abdominal pain and vomiting. Prevention includes minimal invasiveness of the intervention, early oral feeding [95, 100], peroral fluids on the day of surgery, restriction of intravenous fluid substitution to 2 000 ml, and **early mobilization** of the patient. There is no evidence that feeding has to be stopped until bowel movement has started. Treatment is by replacing opioid treatment by NSAIDs. Colon stimulating laxatives based on bisacodyl and magnesium are recommended, but there are no prospective trials to support this recommendation. The intravenous administration of metoclopramide or cholinesterase inhibitors (distigmine bromide, pyridostigmine bromide) has shown no effect on reducing the duration of postoperative ileus in any of the prospective studies [17].

### Cast Syndrome/Superior Mesenteric Artery Syndrome

Cast syndrome may result from kyphosis correction and must not be missed

After correction of a deformity, especially after correction of kyphosis, the ascending duodenum may be compressed between the stretched aorta and the superior mesenteric artery. The patient vomits after swallowing food. Under-

weight patients are at higher risk [22, 105]. Causal treatment is reduction of the correction. This is usually not required. The symptoms will ameliorate within weeks and with intravenous hyperalimentation. In rare cases, duodenojejunostomy will be required.

## Urogenital Complications

### Urinary Tract Infection

Check for bladder residual urine

The most frequent urogenital complication is a simple urinary tract infection (UTI), which can occur in up to 9% of patients [5]. Ascending infection with pyelonephritis or sepsis is rare. These complications can be minimized when perioperative catheterization is used only when absolutely indicated. On the other hand, incomplete bladder emptying also increases the risk of infection. Ultrasonography is very helpful in estimating the residual urine amount, which should be less than 100 cc.

### Postoperative Anuresis

Check perianal sensation in postoperative anuresis

In the immediate postoperative period, patients often have difficulty in urinating. The most frequent cause is the inability to empty the bladder in a lying position. However, anal tone and sensation must be controlled to rule out a cauda equina syndrome. Early mobilization solves this problem. If this is not possible, catheterization is necessary to avoid bladder overdistension.

### Urinary Bladder Dysfunction

After anterior surgery, a bladder dysfunction can result from an injury to the parasympathetic presacral nerves especially at the level of L5/S1. This complication can perhaps be reduced by a retroperitoneal approach, where the sympathetic and parasympathetic fibers located close to the peritoneum in the bifurcation of the vessels are left intact [34].

## Retrograde Ejaculation

Initial reports have perhaps underestimated the problem. A survey of 20 surgeons in 1984 reported **0.42% retrograde ejaculation** and 0.44% impotence following anterior lumbar spine fusion [37]. The more thoroughly studies were undertaken, the higher (2–4%) was the reported incidence [8, 11, 99]. It seems that the problem is mainly approach related, with the incidence being much higher in transperitoneal than in retroperitoneal approaches to the lumbar spine. Recently, in anterior lumbar interbody fusion the rate was 2% in retroperitoneal and 13% in transperitoneal cases [99]. A lesion of the hypogastric plexus must be avoided during approaches to the lumbar spine. The plexus is located in front of the vessel bifurcation, close to the peritoneum. In transperitoneal approaches, the plexus is split directly under the peritoneum. Retroperitoneal approaches allow for preparation behind the vessels, so the plexus can be preserved. The restrictive use of bipolar cauterization may reduce the risk.

This complication is most likely more common than reported

## Recapitulation

**Frequency of complications.** Complication rates of spinal procedures are dependent on the type of surgery, spinal pathology, the experience of the surgeon and confounding factors such as **age** and **comorbidities**. The most frequent complications of cervical surgery are infection (1.6%) and Horner's syndrome (1.1%) as well as neurologic deterioration (3.3 %) in cervical myelopathy. In anterior spinal surgery, death and paraplegia are encountered in 0.3 – 0.4 % and 0.2 – 0.4 %, respectively. The overall complication rate for posterolateral fusion is about 6% and is dependent on the age of the patient. **Implant related neurological compromise** and **postoperative wound infection** are among the most frequent complications.

**Preventive measures.** The best treatment for complications is their avoidance. Important measures to prevent complications are the screening for risk factors such as **past history** of **thromboembolic complications**, **previous postsurgical infections**, **previous surgery**, **malnutrition**, **cardiovascular disease**, **COPD**, **smoking**, and medications (e.g., NSAIDs). Detailed preoperative planning including potential salvage strategies is mandatory to minimize the risk of complications. A profound knowledge of the **surgical anatomy** is indispensable. Correct patient positioning reduces blood loss. **Neuromonitoring** is a must in cases in which deformity correction is attempted.

**Approach-related complications.** The **superior and recurrent laryngeal nerve** and the cervical arteries are at risk when performing an anteromedial cervical approach. **Lung lacerations** and injuries to the thoracic vessels may occur when a thoracotomy is done. **Pulmonary artery lesions** are very challenging to repair even for very experienced thoracic surgeons. **Postoperative pneumothorax** and **hematothorax** can be avoided by proper drainage. A **chylothorax** can become a life-threatening problem and requires temporary parenteral nutrition. A thoraco-lumbar approach may jeopardize the liver and spleen. Venous and arterial injuries may occur with abdominal approaches and require adequate repair and aftertreatment. **Bowel** and **urethral injuries** are rare but must not be overlooked.

**Procedure-related complications.** **Excessive epidural bleeding** is a frequently encountered problem during posterior decompressive surgery and can be reduced with **correct patient positioning**. Nerve root injuries subsequent to posterior Instrumentation can be minimized with proper training and experience. **Unintended durotomy** is not infrequent in cases with severe spinal canal stenosis, and **direct repair is recommended** whenever possible. **Distraction during deformity correction** is prone to neurological compromise and must be avoided. Hypotensive surgery should be avoided when correcting severe spinal deformity. **Reduction of high-grade spondylolisthesis** jeopardizes the L5 nerve root and complete reduction should therefore be avoided.

**Postoperative complications.** Postoperative monitoring must include blood loss, neurological and vascular status. **Continuous postoperative bleeding** is a frequent problem particularly after posterior revision surgery and spinal osteotomies. This problem can be minimized with proper intraoperative hemostasis and timely blood and factor substitution. **Persistent wound drainage** is indicative of infection or malnutrition. A **hypoliquorrhea syndrome** only occurs with tiny leaks not discovered intraoperatively and which most often need to be repaired. **Postoperative vascular complications** are rare but may be detrimental if overlooked, particularly large vessel injuries with continuous bleeding or arterial thrombosis. **Pulmonary complications** can be minimized with proper preoperative respiratory treatment. The duration of **postoperative bowel atonia** can be reduced by avoiding extensive opioid treatment and alternatively using postoperative peridural anesthesia. **Urinary tract infections** are not infrequent and routine catherization for short surgeries should be avoided. The rate of retrograde ejaculation (2–13%) is more frequent than assumed and can be reduced by avoidance of cauterization of the pre-discal vessels.

## Key Articles

**Baron EM, Albert TJ (2006) Medical complications of surgical treatment of adult spinal deformity and how to avoid them. Spine 31:S106 – 18**
Recent extensive review of complications in adult spinal surgery.

**Bungard TJ, Kale-Pradhan PB (1999) Prokinetic agents for the treatment of postoperative ileus in adults: a review of the literature. Pharmacotherapy 19:416 – 423**
A good description of how to treat postoperative bowel atonia. The different pharmaceutical options are discussed.

**Coe JD, Arlet V, Donaldson W, Berven S, Hanson DS, Mudiyam R, Perra JH, Shaffrey CI (2006) Complications in spinal fusion for adolescent idiopathic scoliosis in the new millennium. A report of the Scoliosis Research Society Morbidity and Mortality Committee. Spine 31:345 – 9**
Review of complications in 6 334 patients undergoing surgery for adolescent idiopathic scoliosis.

**Flinn WR, Sandager GP, Silva MB Jr, Benjamin ME, Cerullo LJ, Taylor M (1996) Prospective surveillance for perioperative venous thrombosis. Experience in 2 643 patients. Arch Surg 131:472 – 480**
An excellent study of all aspects of thrombosis and pulmonary embolism in spine surgery. The article demonstrates the relatively low risk of venous thrombosis in comparison to orthopedic procedures like arthroplasty of large joints.

**Faciszewski T, Winter RB, Lonstein JE, Denis F, Johnson L (1995) The surgical and medical complications of anterior spinal fusion surgery in the thoracic and lumbar spine in adults. A review of 1 223 procedures. Spine 20:1592 – 1599**
This article is a good overview of the incidence of complications of anterior deformity surgery. The overall estimation of the risk is perhaps too optimistic. Therefore the article by Leung and Grevitt (2005) cited below is recommended in addition to achieve a more balanced view.

**Fritzell P, Hagg O, Nordwall A; Swedish Lumbar Spine Study Group (2003) Complications in lumbar fusion surgery for chronic low back pain: comparison of three surgical techniques used in a prospective randomized study. A report from the Swedish Lumbar Spine Study Group. Eur Spine J 12:178 – 189**
An overview of all aspects of complications in lumbar fusion, showing a high increase of complications with instrumentation and further with 360° fusion. In the further course, several articles were published by the same authors, showing fewer complications like pseudoarthrosis in the midterm with instrumented 360° fusion.

**Inamasu J, Guiot BH (2005) Iatrogenic vertebral artery injury. Acta Neurol Scand 112:349 – 357**
This article describes all iatrogenic causes of vertebral artery lesions, including percutaneous puncture, treatment options and outcome.

**Jansson KA, Nemeth G, Granath F, Blomqvist P (2004) Surgery for herniation of a lumbar disc in Sweden between 1987 and 1999. An analysis of 27 576 operations. J Bone Joint Surg Br 86:841 – 847**
This is the best casuistry on complications of surgery for disc herniation. A remarkable mortality of 0.5 % was found in the first 30 days after surgery, which was clearly associated with increased age.

**Kraemer R, Wild A, Haak H, Herdmann J, Krauspe R, Kraemer J (2003) Classification and management of early complications in open lumbar microdiscectomy. Eur Spine J 12:239 – 246**
This review article gives a good overview of complications after lumbar microdiscectomy, with recommendations on treatment.

**Lapp MA, Bridwell KH, Lenke LG, Baldus C, Blanke K, Iffrig TM (2001) Prospective randomization of parenteral hyperalimentation for long fusions with spinal deformity: its effect on complications and recovery from postoperative malnutrition. Spine 26:809 – 817**
This paper emphasizes the importance of sufficient alimentation in avoiding perioperative spinal complications.

## Key Articles

**Leung YL, Grevitt M, Henderson L, Smith J (2005) Cord monitoring changes and segmental vessel ligation in the "at risk" cord during anterior spinal deformity surgery. Spine 30:1870 – 1874**
A valuable article for identification of patients at risk of paraplegia.

**Timberlake GA, Kerstein MD (1995) Venous injury: to repair or ligate, the dilemma revisited. Am Surg 61:139 – 145**
An article on 322 venous lesions, treatment options and the sequelae.

**Oderich GS, Panneton JM, Hofer J, Bower TC, Cherry KJ Jr, Sullivan T, Noel AA, Kalra M, Gloviczki P (2004) Iatrogenic operative injuries of abdominal and pelvic veins: a potentially lethal complication. J Vasc Surg 39:931 – 936**
This article reports a high mortality rate after venous lesions and should be read in conjunction with the article by Timberlake et al.

## References


1. Akagi S, Yoshida Y, Kato I, Sasai K, Saito T, Imamura A, Ogawa R (1999) External iliac artery occlusion in posterior spinal surgery. Spine 24:823 – 5
2. Andersen T, Christensen FB, Laursen M, Hoy K, Hansen ES, Bunger C (2001) Smoking as a predictor of negative outcome in lumbar spinal fusion. Spine 26:2623 – 8
3. Anonymous (2006) Practice advisory for perioperative visual loss associated with spine surgery: A report by the American Society of Anesthesiologists Task Force on Perioperative Blindness. Anesthesiology 104:1319 – 28
4. Bademci G, Saygun M, Batay F, Cakmak A, Basar H, Anbarci H, Unal B (2006) Prevalence of primary tethered cord syndrome associated with occult spinal dysraphism in primary school children in Turkey. Pediatr Neurosurg 42:4 – 13
5. Baron EM, Albert TJ (2006) Medical complications of surgical treatment of adult spinal deformity and how to avoid them. Spine 31:S106 – 18
6. Belmont PJ, Jr, Kuklo TR, Taylor KF, Freedman BA, Prahinski JR, Kruse RW (2004) Intraspinal anomalies associated with isolated congenital hemivertebra: the role of routine magnetic resonance imaging. J Bone Joint Surg Am 86A:1704 – 10
7. Ben-David B, Haller G, Taylor P (1987) Anterior spinal fusion complicated by paraplegia. A case report of a false-negative somatosensory-evoked potential. Spine 12:536 – 9
8. Bertagnoli R, Yue JJ, Shah RV, Nanieva R, Pfeiffer F, Fenk-Mayer A, Kershaw T, Husted DS (2005) The treatment of disabling single-level lumbar discogenic low back pain with total disc arthroplasty utilizing the Prodisc prosthesis: a prospective study with 2-year minimum follow-up. Spine 30:2230 – 6
9. Bertalanffy H, Eggert HR (1989) Complications of anterior cervical discectomy without fusion in 450 consecutive patients. Acta Neurochir (Wien) 99:41 – 50
10. Beutler WJ, Sweeney CA, Connolly PJ (2001) Recurrent laryngeal nerve injury with anterior cervical spine surgery – risk with laterality of surgical approach. Spine 26:1337 – 42
11. Blumenthal S, McAfee PC, Guyer RD, Hochschuler SH, Geisler FH, Holt RT, Garcia R, Jr, Regan JJ, Ohnmeiss DD (2005) A prospective, randomized, multicenter Food and Drug Administration investigational device exemptions study of lumbar total disc replacement with the Charite artificial disc versus lumbar fusion: part I: evaluation of clinical outcomes. Spine 30:1565 – 75; discussion E387 – 91
12. Boardman ND, 3rd, Cofield RH (1999) Neurologic complications of shoulder surgery. Clin Orthop Relat Res 368:44 – 53
13. Boockvar JA, Philips MF, Telfeian AE, O'Rourke DM, Marcotte PJ (2001) Results and risk factors for anterior cervicothoracic junction surgery. J Neurosurg 94:12 – 7
14. Boos N, Marchesi D, Zuber K, Aebi M (1993) Treatment of severe spondylolisthesis by reduction and pedicular fixation. A 4 – 6-year follow-up study. Spine 18:1655 – 61
15. Brau SA (2002) Mini-open approach to the spine for anterior lumbar interbody fusion: description of the procedure, results and complications. Spine J 2:216 – 23
16. Brau SA, Delamarter RB, Schiffman ML, Williams LA, Watkins RG (2004) Vascular injury during anterior lumbar surgery. Spine J 4:409 – 12
17. Bungard TJ, Kale-Pradhan PB (1999) Prokinetic agents for the treatment of postoperative ileus in adults: a review of the literature. Pharmacotherapy 19:416 – 23
18. Cappell MS, Iacovone FM, Jr (1996) The safety and efficacy of percutaneous endoscopic gastrostomy after recent myocardial infarction: a study of 28 patients and 40 controls at four university teaching hospitals. Am J Gastroenterol 91:1599 – 603

19. Chang YS, Guyer RD, Ohnmeiss DD, Moore S (2003) Case report: intraoperative left common iliac occlusion in a scheduled 360-degree spinal fusion. Spine 28:E316 – 9
20. Christodoulou AG, Ploumis A, Terzidis IP, Timiliotou K, Gerogianni N, Spyridis C (2004) Spleen rupture after surgery in Marfan syndrome scoliosis. J Pediatr Orthop 24:537 – 40
21. Coe JD, Arlet V, Donaldson W, Berven S, Hanson DS, Mudiyam R, Perra JH, Shaffrey CI (2006) Complications in spinal fusion for adolescent idiopathic scoliosis in the new millennium. A report of the Scoliosis Research Society Morbidity and Mortality Committee. Spine 31:345 – 9
22. Crowther MA, Webb PJ, Eyre-Brook IA (2002) Superior mesenteric artery syndrome following surgery for scoliosis. Spine 27:E528 – 33
23. Dearborn JT, Hu SS, Tribus CB, Bradford DS (1999) Thromboembolic complications after major thoracolumbar spine surgery. Spine 24:1471 – 6
24. Delank KS, Delank HW, Konig DP, Popken F, Furderer S, Eysel P (2005) Iatrogenic paraplegia in spinal surgery. Arch Orthop Trauma Surg 125:33 – 41
25. Deutsch L, Testiauti M, Borman T (2001) Simultaneous anterior-posterior thoracolumbar spine surgery. J Spinal Disord 14:378 – 84
26. Deyo RA, Cherkin DC, Loeser JD, Bigos SJ, Ciol MA (1992) Morbidity and mortality in association with operations on the lumbar spine. The influence of age, diagnosis, and procedure. J Bone Joint Surg Am 74:536 – 43
27. Dick J, Boachie-Adjei O, Wilson M (1992) One-stage versus two-stage anterior and posterior spinal reconstruction in adults. Comparison of outcomes including nutritional status, complication rates, hospital costs, and other factors. Spine 17:S310 – 6
28. Dimopoulos V, Fountas KN, Machinis TG, Feltes C, Chung I, Johnston K, Robinson JS, Grigorian A (2005) Postoperative cauda equina syndrome in patients undergoing single-level lumbar microdiscectomy. Report of two cases. Neurosurg Focus 19:E11
29. Dobbs MB, Lenke LG, Szymanski DA, Morcuende JA, Weinstein SL, Bridwell KH, Sponseller PD (2002) Prevalence of neural axis abnormalities in patients with infantile idiopathic scoliosis. J Bone Joint Surg Am 84A:2230 – 4
30. Doita M, Marui T, Nishida K, Kurosaka M, Yoshiya S, Sha N (2002) Anterior spinal artery syndrome after total spondylectomy of T10, T11, and T12. Clin Orthop Relat Res:175 – 81
31. Eleraky MA, Llanos C, Sonntag VK (1999) Cervical corpectomy: report of 185 cases and review of the literature. J Neurosurg 90:35 – 41
32. Epstein NE (2005) A review of the risks and benefits of differing prophylaxis regimens for the treatment of deep venous thrombosis and pulmonary embolism in neurosurgery. Surg Neurol 64:295 – 301
33. Faciszewski T, Winter RB, Lonstein JE, Denis F, Johnson L (1995) The surgical and medical perioperative complications of anterior spinal fusion surgery in the thoracic and lumbar spine in adults. A review of 1 223 procedures. Spine 20:1592 – 9
34. Faraj AA, Webb JK, Lemberger RJ (1996) Urinary bladder dysfunction following anterior lumbosacral spine fusion: case report and review of the literature. Eur Spine J 5:121 – 4
35. Farmer KW, Hammond JW, Queale WS, Keyurapan E, McFarland EG (2007) Shoulder arthroplasty versus hip and knee arthroplasties: A comparison of outcomes. Clin Orthop Relat Res 455:183 – 189
36. Flinn WR, Sandager GP, Silva MB, Jr, Benjamin ME, Cerullo LJ, Taylor M (1996) Prospective surveillance for perioperative venous thrombosis. Experience in 2 643 patients. Arch Surg 131:472 – 80
37. Flynn JC, Price CT (1984) Sexual complications of anterior fusion of the lumbar spine. Spine 9:489 – 92
38. Fritzell P, Hagg O, Nordwall A (2003) Complications in lumbar fusion surgery for chronic low back pain: comparison of three surgical techniques used in a prospective randomized study. A report from the Swedish Lumbar Spine Study Group. Eur Spine J 12:178 – 89
39. Gayer G, Caspi I, Garniek A, Hertz M, Apter S (2002) Perirectal urinoma from ureteral injury incurred during spinal surgery mimicking rectal perforation on computed tomography scan. Spine 27:E451 – 3
40. Gehri R, Zanetti M, Boos N (2000) Subacute subdural haematoma complicating lumbar microdiscectomy. J Bone Joint Surg Br 82:1042 – 5
41. Glassman SD, Alegre G, Carreon L, Dimar JR, Johnson JR (2003) Perioperative complications of lumbar instrumentation and fusion in patients with diabetes mellitus. Spine J 3:496 – 501
42. Goodkin R, Laska LL (1998) Vascular and visceral injuries associated with lumbar disc surgery: medicolegal implications. Surg Neurol 49:358 – 70; discussion 370 – 2
43. Guigui P, Blamoutier A (2005) [Complications of surgical treatment of spinal deformities: a prospective multicentric study of 3 311 patients]. Rev Chir Orthop Reparatrice Appar Mot 91:314 – 27
44. Guingrich JA, McDermott JC (2000) Ureteral injury during laparoscopy-assisted anterior lumbar fusion. Spine 25:1586 – 8
45. Guzman R, Dubach-Schwizer S, Heini P, Lovblad KO, Kalbermatten D, Schroth G, Remonda

L (2005) Preoperative transarterial embolization of vertebral metastases. Eur Spine J 14:263 – 8
46. Haaker RG, Senkal M, Kielich T, Kramer J (1997) Percutaneous lumbar discectomy in the treatment of lumbar discitis. Eur Spine J 6:98 – 101
47. Hackenberg L, Liljenqvist U, Halm H, Winkelmann W (2001) Occlusion of the left common iliac artery and consecutive thromboembolism of the left popliteal artery following anterior lumbar interbody fusion. J Spinal Disord 14:365 – 8
48. Hacker RJ, Cauthen JC, Gilbert TJ, Griffith SL (2000) A prospective randomized multicenter clinical evaluation of an anterior cervical fusion cage. Spine 25:2646 – 54; discussion 2655
49. Hänggi W, Schwaller K, Mueller MD (1997) Intra- und postoperative Komplikationen bei der Sectio caesarea. Gynäkologe 30:762 – 768
50. Harper CM, Ambler G, Edge G (2004) The prognostic value of pre-operative predicted forced vital capacity in corrective spinal surgery for Duchenne's muscular dystrophy. Anaesthesia 59:1160 – 2
51. Hausmann O, Min K, Boni T, Erni T, Dietz V, Curt A (2003) SSEP analysis in surgery of idiopathic scoliosis: the influence of spine deformity and surgical approach. Eur Spine J 12:117 – 23
52. Henriques T, Olerud C, Petren-Mallmin M, Ahl T (2001) Cauda equina syndrome as a postoperative complication in five patients operated for lumbar disc herniation. Spine 26:293 – 7
53. Hermantin FU, Peters T, Quartararo L, Kambin P (1999) A prospective, randomized study comparing the results of open discectomy with those of video-assisted arthroscopic microdiscectomy. J Bone Joint Surg Am 81:958 – 65
54. Herrera MF, Bauer G, Reynolds F, Wilk RM, Bigliani LU, Levine WN (2002) Infection after mini-open rotator cuff repair. J Shoulder Elbow Surg 11:605 – 8
55. Hoff-Olsen P, Wiberg J (2001) Small bowel perforation as a complication of microsurgical lumbar diskectomy. A case report and brief review of the literature. Am J Forensic Med Pathol 22:319 – 21
56. Hood RW, Riseborough EJ, Nehme AM, Micheli LJ, Strand RD, Neuhauser EB (1980) Diastematomyelia and structural spinal deformities. J Bone Joint Surg Am 62:520 – 8
57. Horan TC, Gaynes RP, Martone WJ, Jarvis WR, Emori TG (1992) CDC definitions of nosocomial surgical site infections, 1992: a modification of CDC definitions of surgical wound infections. Am J Infect Control 20:271 – 4
58. Houten JK, Frempong-Boadu AK, Arkovitz MS (2004) Bowel injury as a complication of microdiscectomy: case report and literature review. J Spinal Disord Tech 17:248 – 50
59. Hu SS, Fontaine F, Kelly B, Bradford DS (1998) Nutritional depletion in staged spinal reconstructive surgery. The effect of total parenteral nutrition. Spine 23:1401 – 5
60. Hurtado-Lopez LM, Zaldivar-Ramirez FR (2002) Risk of injury to the external branch of the superior laryngeal nerve in thyroidectomy. Laryngoscope 112:626 – 9
61. Inamasu J, Guiot BH (2005) Iatrogenic vertebral artery injury. Acta Neurol Scand 112:349 – 57
62. Jansson KA, Nemeth G, Granath F, Blomqvist P (2004) Surgery for herniation of a lumbar disc in Sweden between 1987 and 1999. An analysis of 27 576 operations. J Bone Joint Surg Br 86:841 – 7
63. Jinkins JR, Rauch A (1994) Magnetic resonance imaging of entrapment of lumbar nerve roots in spondylolytic spondylolisthesis. J Bone Joint Surg Am 76:1643 – 8
64. Johnston CE, 2nd, Happel LT, Jr, Norris R, Burke SW, King AG, Roberts JM (1986) Delayed paraplegia complicating sublaminar segmental spinal instrumentation. J Bone Joint Surg Am 68:556 – 63
65. Kamming D, Clarke S (2005) Postoperative visual loss following prone spinal surgery. Br J Anaesth 95:257 – 60
66. Khazim R, Boos N, Webb JK (1998) Progressive thrombotic occlusion of the left common iliac artery after anterior lumbar interbody fusion. Eur Spine J 7:239 – 41
67. Korge A, Fischer R, Kluger P, Puhl W (1994) The importance of sonography in the diagnosis of septic complications following spinal surgery. Eur Spine J 3:303 – 7
68. Kraemer R, Wild A, Haak H, Herdmann J, Krauspe R, Kraemer J (2003) Classification and management of early complications in open lumbar microdiscectomy. Eur Spine J 12:239 – 46
69. Lapp MA, Bridwell KH, Lenke LG, Baldus C, Blanke K, Iffrig TM (2001) Prospective randomization of parenteral hyperalimentation for long fusions with spinal deformity: its effect on complications and recovery from postoperative malnutrition. Spine 26:809 – 17; discussion 817
70. Lee TC, Yang LC, Chen HJ (1998) Effect of patient position and hypotensive anesthesia on inferior vena caval pressure. Spine 23:941 – 7; discussion 947 – 8
71. Lenke LG, Bridwell KH, Blanke K, Baldus C (1995) Analysis of pulmonary function and chest cage dimension changes after thoracoplasty in idiopathic scoliosis. Spine 20:1343 – 50
72. Leung YL, Grevitt M, Henderson L, Smith J (2005) Cord monitoring changes and segmental vessel ligation in the "at risk" cord during anterior spinal deformity surgery. Spine 30:1870 – 4

73. Mahomed NN, Barrett JA, Katz JN, Phillips CB, Losina E, Lew RA, Guadagnoli E, Harris WH, Poss R, Baron JA (2003) Rates and outcomes of primary and revision total hip replacement in the United States medicare population. J Bone Joint Surg Am 85A:27 – 32
74. Marsicano J, Mirovsky Y, Remer S, Bloom N, Neuwirth M (1994) Thrombotic occlusion of the left common iliac artery after an anterior retroperitoneal approach to the lumbar spine. Spine 19:357 – 9
75. Maurice HD, Morley TR (1989) Cauda equina lesions following fusion in situ and decompressive laminectomy for severe spondylolisthesis. Four case reports. Spine 14:214 – 6
76. McCulloch J, Young PH (1998) Essentials of spinal microsurgery. Lippincott-Raven, Philadelphia
77. McDonnell MF, Glassman SD, Dimar JR, 2nd, Puno RM, Johnson JR (1996) Perioperative complications of anterior procedures on the spine. J Bone Joint Surg Am 78:839 – 47
78. Melamed H, Harris MB, Awasthi D (2002) Anatomic considerations of superior laryngeal nerve during anterior cervical spine procedures. Spine 27:E83 – 6
79. Moore FA, Moore EE, Moore GE, Millikan JS (1984) Risk of splenic salvage after trauma. Analysis of 200 adults. Am J Surg 148:800 – 5
80. Muschik M, Luck W, Schlenzka D (2004) Implant removal for late-developing infection after instrumented posterior spinal fusion for scoliosis: reinstrumentation reduces loss of correction. A retrospective analysis of 45 cases. Eur Spine J 13:645 – 51
81. Myers MA, Hamilton SR, Bogosian AJ, Smith CH, Wagner TA (1997) Visual loss as a complication of spine surgery. A review of 37 cases. Spine 22:1325 – 9
82. Nader R, Alford BT, Nauta HJ, Crow W, vanSonnenberg E, Hadjepavlou AG (2002) Preoperative embolization and intraoperative cryocoagulation as adjuncts in resection of hypervascular lesions of the thoracolumbar spine. J Neurosurg 97:294 – 300
83. Naito M, Owen JH, Bridwell KH, Sugioka Y (1992) Effects of distraction on physiologic integrity of the spinal cord, spinal cord blood flow, and clinical status. Spine 17:1154 – 8
84. Nguyen DM, Shum-Tim D, Dobell AR, Tchervenkov CI (1995) The management of chylothorax/chylopericardium following pediatric cardiac surgery: a 10-year experience. J Card Surg 10:302 – 8
85. Nohara Y, Taneichi H, Ueyama K, Kawahara N, Shiba K, Tokuhashi Y, Tani T, Nakahara S, Iida T (2004) Nationwide survey on complications of spine surgery in Japan. J Orthop Sci 9:424 – 33
86. Oderich GS, Panneton JM, Hofer J, Bower TC, Cherry KJ, Jr, Sullivan T, Noel AA, Kalra M, Gloviczki P (2004) Iatrogenic operative injuries of abdominal and pelvic veins: a potentially lethal complication. J Vasc Surg 39:931 – 6
87. Olerud C, Jonsson H, Jr, Lofberg AM, Lorelius LE, Sjostrom L (1993) Embolization of spinal metastases reduces peroperative blood loss. 21 patients operated on for renal cell carcinoma. Acta Orthop Scand 64:9 – 12
88. Oskouian RJ, Jr, Johnson JP (2002) Vascular complications in anterior thoracolumbar spinal reconstruction. J Neurosurg 96:1 – 5
89. Parker MJ, Roberts C (2001) Closed suction surgical wound drainage after orthopaedic surgery. Cochrane Database Syst Rev:CD001825
90. Pelosi L, Lamb J, Grevitt M, Mehdian SM, Webb JK, Blumhardt LD (2002) Combined monitoring of motor and somatosensory evoked potentials in orthopaedic spinal surgery. Clin Neurophysiol 113:1082 – 91
91. Petraco DM, Spivak JM, Cappadona JG, Kummer FJ, Neuwirth MG (1996) An anatomic evaluation of L5 nerve stretch in spondylolisthesis reduction. Spine 21:1133 – 8; discussion 1139
92. Potter BK, Kirk KL, Shah SA, Kuklo TR (2006) Loss of coronal correction following instrumentation removal in adolescent idiopathic scoliosis. Spine 31:67 – 72
93. Ramirez LF, Thisted R (1989) Complications and demographic characteristics of patients undergoing lumbar discectomy in community hospitals. Neurosurgery 25:226 – 30; discussion 230 – 1
94. Raskas DS, Delamarter RB (1997) Occlusion of the left iliac artery after retroperitoneal exposure of the spine. Clin Orthop Relat Res:86 – 9
95. Reissman P, Teoh TA, Cohen SM, Weiss EG, Nogueras JJ, Wexner SD (1995) Is early oral feeding safe after elective colorectal surgery? A prospective randomized trial. Ann Surg 222:73 – 7
96. Roberts MP (1988) Complications of lumbar disc surgery. Spinal Surg 2:13 – 19
97. Robertson ML, Steward DL, Gluckman JL, Welge J (2004) Continuous laryngeal nerve integrity monitoring during thyroidectomy: does it reduce risk of injury? Otolaryngol Head Neck Surg 131:596 – 600
98. Rompe JD, Eysel P, Zollner J, Heine J (1999) [Intra- and postoperative risk analysis after lumbar intervertebral disk operation]. Z Orthop Ihre Grenzgeb 137:201 – 5
99. Sasso RC, Kenneth Burkus J, LeHuec JC (2003) Retrograde ejaculation after anterior lumbar interbody fusion: transperitoneal versus retroperitoneal exposure. Spine 28:1023 – 6
100. Schilder JM, Hurteau JA, Look KY, Moore DH, Raff G, Stehman FB, Sutton GP (1997) A pro-

spective controlled trial of early postoperative oral intake following major abdominal gynecologic surgery. Gynecol Oncol 67:235 – 40
101. Schinsky MF, Macaulay W, Parks ML, Kiernan H, Nercessian OA (2001) Nerve injury after primary total knee arthroplasty. J Arthroplasty 16:1048 – 54
102. Schmalzried TP, Amstutz HC, Dorey FJ (1991) Nerve palsy associated with total hip replacement. Risk factors and prognosis. J Bone Joint Surg Am 73:1074 – 80
103. Schoenecker PL, Cole HO, Herring JA, Capelli AM, Bradford DS (1990) Cauda equina syndrome after in situ arthrodesis for severe spondylolisthesis at the lumbosacral junction. J Bone Joint Surg Am 72:369 – 77
104. Scuderi GJ, Vaccaro AR, Brusovanik GV, Kwon BK, Berta SC (2004) Conjoined lumbar nerve roots: a frequently underappreciated congenital abnormality. J Spinal Disord Tech 17:86 – 93
105. Shah MA, Albright MB, Vogt MT, Moreland MS (2003) Superior mesenteric artery syndrome in scoliosis surgery: weight percentile for height as an indicator of risk. J Pediatr Orthop 23:665 – 8
106. Sperling JW, Kozak TK, Hanssen AD, Cofield RH (2001) Infection after shoulder arthroplasty. Clin Orthop Relat Res:206 – 16
107. Stockl B, Wimmer C, Innerhofer P, Kofler M, Behensky H (2005) Delayed anterior spinal artery syndrome following posterior scoliosis correction. Eur Spine J 14:906 – 9
108. Strahm C, Min K, Boos N, Ruetsch Y, Curt A (2003) Reliability of perioperative SSEP recordings in spine surgery. Spinal Cord 41:483 – 9
109. Szoke G, Lipton G, Miller F, Dabney K (1998) Wound infection after spinal fusion in children with cerebral palsy. J Pediatr Orthop 18:727 – 33
110. Takeuchi K, Yokoyama T, Aburakawa S, Itabashi T, Toh S (2005) Anatomic study of the semispinalis cervicis for reattachment during laminoplasty. Clin Orthop Relat Res:126 – 31
111. Timberlake GA, Kerstein MD (1995) Venous injury: to repair or ligate, the dilemma revisited. Am Surg 61:139 – 45
112. Torossian A, Schmidt J, Schaffartzik W, Wulf H (2006) Loss of vision after non-ophthalmic surgery: Systematic review of the literature on incidence, pathogenesis, treatment and prevention. Anaesthesist 55:457 – 464
113. Tsai YD, Yu PC, Lee TC, Chen HS, Wang SH, Kuo YL (2001) Superior rectal artery injury following lumbar disc surgery. Case report. J Neurosurg 95:108 – 10
114. Tsuzuki N, Hirabayashi S, Abe R, Saiki K (2001) Staged spinal cord decompression through posterior approach for thoracic myelopathy caused by ossification of posterior longitudinal ligament. Spine 26:1623 – 30
115. Wazeka AN, DiMaio MF, Boachie-Adjei O (2004) Outcome of pediatric patients with severe restrictive lung disease following reconstructive spine surgery. Spine 29:528 – 34; discussion 535
116. Wilkin TD, Kraus MA, Lane KA, Trerotola SO (2003) Internal jugular vein thrombosis associated with hemodialysis catheters. Radiology 228:697 – 700
117. Wilson AP, Gibbons C, Reeves BC, Hodgson B, Liu M, Plummer D, Krukowski ZH, Bruce J, Wilson J, Pearson A (2004) Surgical wound infection as a performance indicator: agreement of common definitions of wound infection in 4773 patients. BMJ 329:720
118. Winter RB, Lonstein JE, Denis F, Leonard AS, Garamella JJ (1996) Paraplegia resulting from vessel ligation. Spine 21:1232 – 3; discussion 1233 – 4
119. Wright N (2005) Single-surgeon simultaneous versus staged anterior and posterior spinal reconstruction: a comparative study. J Spinal Disord Tech 18 Suppl:S48 – 57
120. Wright NM, Lauryssen C (1998) Vertebral artery injury in C1 – 2 transarticular screw fixation: results of a survey of the AANS/CNS section on disorders of the spine and peripheral nerves. American Association of Neurological Surgeons/Congress of Neurological Surgeons. J Neurosurg 88:634 – 40
121. Yarbrough DE, Thompson GB, Kasperbauer JL, Harper CM, Grant CS (2004) Intraoperative electromyographic monitoring of the recurrent laryngeal nerve in reoperative thyroid and parathyroid surgery. Surgery 136:1107 – 15

# 40 Outcome Assessment in Spinal Surgery

Mathias Haefeli, Norbert Boos

## Core Messages

- ✔ The evaluation of treatment modalities for spinal disorders by self-administered questionnaires has entered into clinical practice
- ✔ Functional and psychosocial aspects often exhibit a closer correlation with fair or poor outcome after spinal surgery than organ-specific symptoms and morphological alterations and must therefore be evaluated in outcome research
- ✔ The main subjects addressed by outcome tools are pain, disability, health-related quality of life and work status
- ✔ For more thorough investigations, psychosocial aspects, work-related parameters and fear avoidance behavior should additionally be assessed
- ✔ There are several standardized and validated questionnaires available
- ✔ Current research is trying to facilitate data assessment by developing short but reliable instruments

## General Concepts of Outcome Assessment

The evaluation of treatment modalities in spinal orders by self-administered assessment tools has become standard in most institutions. In many fields of medicine and particularly in spinal surgery, it has become evident that treatment outcome is influenced by a large variety of non-morphological factors [100]. Psychosocial aspects and work-related factors often exhibit a higher predictive value than pathomorphological and surgical aspects [47]. Therefore, it has become apparent that a meaningful outcome assessment should consider most of these confounding variables, which, however, is not always possible to achieve in a busy clinical practice. The **minimal data set** that should be collected consists of:

- pain
- disability
- quality of life
- work status

Several criteria should be considered when data assessment is performed by **self-rating questionnaires:**

- comparability
- validity
- availability
- scale characteristics

When a comparison between treatment groups is chosen in a study, the criteria of comparability of a questionnaire must be defined. If the results are to be com-

pared with a control group out of the literature, an identical questionnaire must be used.

Validity [2] is the degree to which an instrument measures what it is intended to measure. It is the most important quality of a questionnaire and there are different types of validity. A **questionnaire ideally should fulfill:**

- **content validity**, i.e. the extent to which the instruments include the domain of the target phenomenon
- **criterion validity**, i.e. extent of agreement when comparing with a "gold standard"
- **construct validity**, i.e. extent to which the instrument corresponds to theoretical concepts of the target phenomenon

Most of the questionnaires are developed for the English language. If these tools are used in non-English speaking countries, these versions should ideally be translated and validated first for the used language (availability). Several rules should be considered in this process of **cross-cultural adaptation** [13]. According to this, such a process should start with at least two forward translations into the target language. In a second step a synthesis of the two translations should be done before performing at least two back translations in the next step. After a consolidation of all versions of the instruments resulting from the first three

**Table 1.** Outcome tools in spinal surgery

| Topic | Tool | Available languages (validated versions only) |
|---|---|---|
| **Pain** | **VAS/GRS/NRS/VRS** | |
| **Disability** | **RMDQ** | **English [131]**<br>French [38]<br>German [156]<br>Greek [24]<br>Portuguese [115]<br>Spanish [88]<br>Swedish [82]<br>Turkish [90] |
| | ODI | English [50]<br>Finnish [63]<br>French [157]<br>German [11, 101, 102]<br>Greek [24] |
| | NASS-Q | English [39]<br>German [123]<br>Italian [119] |
| | FAQH | German [86] |
| | NDI | English [145]<br>French [157]<br>Swedish [3] |
| | NPDI | English [154]<br>French [157]<br>Turkish [20] |
| **Quality of life** | **WHOQOL-100/-Bref** | **www.who.int** |
| | SF-36/-12/-8 | www.sf36.com |
| | EQ-5D | www.euroqol.org |
| | SRS-22/-30 | English: www.srs.org<br>Spanish [10] |
| **Fear avoidance behavior** | **FABQ** | **English [149]**<br>German [121, 138] |
| **Core item tools** | **Low back pain** | **English [41]**<br>German [99] |
| | Neck pain | English [155] |

steps by an expert committee, a testing of the instrument and further refinements have to be done.

Since there are many aspects influencing outcome of spinal surgery, a well designed questionnaire will include different standardized and validated tools to cover these different fields (scale characteristics).

A questionnaire should be comparable, valid and comprehensive

A broad range of outcome tools are available (Table 1), of which only a limited number are frequently used. In the following, the most important questionnaires in the field of spinal surgery are briefly discussed including pain assessment, disability, quality of life and work assessment. Presented in regard to their strengths and weaknesses and their best feasible clinical setting, this survey should enable the best possible decision when searching for a self-administered assessment tool in spinal surgery.

## Pain

### General Aspects

Back pain is one of the most frequent reasons for spinal surgery and therefore pain relief is the major aim in the vast majority of cases. Pre- and postoperative assessment of pain and pain relief serves to evaluate the effectiveness of a specific therapy [68]. However, some important findings of the past two decades of research have to be kept in mind when the gathering and interpreting of such data is intended. As perception of pain may differ within a time period, recent studies have mentioned that it is more valuable to ask patients to rate their "usual" pain on average over a past short period of time, e.g. 1 week, than to ask for "current" pain at the specific time of completion of the questionnaire [21, 22, 147]. Posing such questions relies on the assumption that patients are able to accurately recall their pain levels in a past period of time. Whether or not this is reliable is controversial. Whereas some studies find it unreliable to assess pain retrospectively [40, 94–96], others report acceptable levels of validity up to a 3 months recall period [21, 139, 146]. It has been found that pain is usually overestimated when the actual intensity of pain is higher and underestimated when it is lower [30, 45, 94–96]. Moreover, Haas et al. [66] found that pain and disability recall became more and more influenced by present pain and disability during a period of 1 year while the influence of actual relief and pain and disability reporting at the initial consultation decreased. On the other hand, Von Korff et al. [146] stated that recall of chronic pain in terms of its average intensity, interference with activities (disability due to pain), number of days with pain and number of days with activity limitation, leads to acceptable validity levels.

The objective assessment of pain for outcome research remains controversial

When assessing pain in the context of a spinal intervention, it is necessary to use some kind of pain recall when not using "current pain" as the test parameter as discussed above. Based on the literature, it is justifiable to use short time periods of pain and disability recall for comparison of patients' pain status. The interpretation of whether or not a statistically significant change in pain corresponds to a significant clinical change remains challenging and requires further research [12]. Similarly, the definition of a threshold for a significant clinical change needs to be explored.

Short time periods of pain recall are superior to current pain assessment

#### Pain Duration

There are different definitions of chronic back pain. Nachemson et al. [112] defined it in 1984 as a period of at least 3 months with persistent pain. Von Korff et al. [147] defined it in 1996 as back pain which has to be present on at least half of the days during 1 year. Raspe et al. [127] investigated 40 epidemiological/ther-

apeutic studies between 1998 and 2000 with regard to the definitions of chronic back pain that were used. Finding periods between 4 weeks and more than 1 year of persistent pain, he showed that there is no consensus about this definition.

### Pain Affect

The experience of pain is subjective, complicating an objective assessment

Pain can be described in terms of the intensity but also in terms of its effect on the individual. Pain intensity describes **how much** a patient is in pain, whereas **pain affect** describes the "degree of emotional arousal or changes in action readiness caused by the sensory experience of pain" [146]. It has been shown that pain intensity may quite easily be described by most patients and that different methods of measuring pain intensity showed high intercorrelation [80, 81]. Contrary to these findings, alternative methods of pain affect assessment did not intercorrelate as highly as those of pain intensity, making the utilization of this part of pain characterization more complicated [109, 110].

## Instruments

### Visual Analogue Scale (VAS)/Graphic Rating Scale (GRS)

A visual analogue scale (VAS) consists of a straight line with endpoints

The VAS consists of a straight line with the endpoints defining extreme limits such as "no pain at all" and "pain as bad as it could be" (Fig. 1) [2]. The patient is asked to mark his or her pain level on the line between the two endpoints, the distance between "no pain at all" and the mark defining the subject's pain. This tool was first used in psychology by Freyd in 1923 [56].

A graphic rating scale (GRS) adds descriptive terms or a numerical scale

A GRS additionally uses descriptive terms such as "mild", "moderate", "severe" or a numerical scale (Fig. 2) [2]. A line length of 10 or 15 cm showed the smallest measurement error compared to 5 and 20 cm versions and seems to be most convenient for respondents [135].

Scott and Huskisson demonstrated that the configuration of a graphic rating scale may influence the distribution pattern of the answers [134]. Moreover, they showed that the experience of patients with this tool influenced the outcome. While patients who had no experience with a graphic rating scale with numbers of 1 – 20 underneath the line showed a preference for the numbers 10 and 15, sub-

**Figure 1.** Visual analogue scale (VAS)

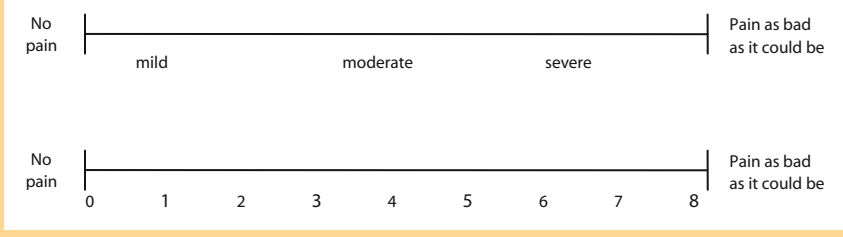


**Figure 2.** Examples of graphic rating scales (GRS)

jects who were experienced in the use ignored the numbered scale and showed no preferences and, therefore, a nearly uniform distribution of the answers. Analogue observations were made with descriptive terms. In several studies, VAS and GRS have demonstrated to be sensitive to treatment effects [80, 83, 89, 135]. They were found to correlate positively with other self-reporting measures of pain intensity [80, 89]. In addition, differences in pain intensity measured at two different points of time by VAS represent the real difference in magnitude of pain, which seems to be the major advantage of this tool compared to the others [125, 126].

VAS indicate real differences between measurements at two points of time

As the distance between "no pain" and the patient-made mark has to be measured, scoring is more time consuming and susceptible to measurement errors than a rating scale for example. Hence, a mechanical VAS has been developed where subjects position a slider on a linear pain-scale instead of marking a cross on a drawn line. Several studies have shown this system to be strongly associated with the original VAS [36, 62]. Moreover, it has been shown that a mechanical VAS exhibits a good test-retest reliability and appears to have ratio qualities [146].

Mechanical visual analogue scales are easy to handle

Besides the disadvantage mentioned above, the VAS seems to be more difficult to understand than other measurement methods and, hence, more susceptible to misinterpretations or "zero values". This is particularly true in elderly patients [37, 80, 89]. In conclusion, the VAS, mechanical VAS and GRS are valuable instruments for assessment of pain intensity and changes due to therapy when respondents are given good instructions and one bears in mind the limitations [37, 134].

### Numerical Rating Scale (NRS)

When using an NRS, patients are asked to circle the number between 0 – 10, 0 – 20 or 0 – 100 that best fits their pain intensity [2]. Zero usually represents "no pain at all" whereas the upper limit represents "the worst pain ever possible". In contrast to the VAS/GRS, only the numbers are valuable answers, meaning that there are only 11 possible answers in a 0 – 10, 21 in a 0 – 21 and 101 in a 0 – 100 point NRS. The NRS allows a less subtle distinction of pain levels compared to VAS/GRS, where there is theoretically an unlimited number of possible answers.

The NRS allows less subtle distinction of pain levels compared to VAS and GRS

The NRS has shown high correlations with other pain assessment tools in several studies [80, 89]. The feasibility of its use and good compliance have also been proven [37, 52]. As it is easily possible to administer NRS verbally, it can be used in **telephone interviews** [146]. On the other hand, results cannot necessarily be treated as ratio data as is possible in VAS/GRS [124].

### Verbal Rating Scale (VRS)

In a verbal rating scale, **adjectives** are used to **describe** different levels of **pain** [2]. The respondent is asked to mark the adjective which fits best to the pain intensity. Also in the VAS two endpoints such as "no pain at all" and "extremely intense pain" should be defined. Between these extremes different adjectives are placed which describe different pain intensity levels. Mostly, 4- to 6-point VRS are used in clinical trials. A different form of VRS is the behavioral rating scale, where different pain levels are described by sentences including behavioral parameters [32].

As well as VAS, VRS have been shown to strongly correlate with other pain assessment tools [80, 89, 118]. Compared to other instruments, respondent's compliance is often as good or even better even though subjects must be familiar with reading the entire list before answering [37, 80]. However, due to the limited number of possible response categories some patients may have problems defin-

Verbal rating scales are less suited to assessing changes in pain intensity and interindividual comparisons

ing which answer fits best to their pain situation. Moreover, the intervals between different adjectives describing pain may not be equal or may be interpreted differently by respondents. Thus, interpretation of a VRS does not allow conclusions to be drawn on the magnitude of a change in pain intensity between two assessments, for example, pre- and postoperatively, and interrespondent comparison is problematic.

## Disability

### General Aspects

Back and neck problems often lead to disability in daily activities due to pain or deformity. Several tools have been developed in respect of this aspect of spinal disorders. In the field of low back pain the most commonly used questionnaires are the **Roland & Morris Disability Questionnaire** (RMDQ) and the **Oswestry Disability Index** (ODI). Both are available in several languages and have proven good internal consistency and test-retest reliability [76, 130, 141]. The North American Spine Society Lumbar Spine Outcome Assessment Instrument (NASS LSO) and the Hannover Functional Ability Questionnaire (HFAQ) are two other disability questionnaires, the latter only existing for the German language. In the field of neck pain the **Neck Disability Index** (NDI) [145] and the **Neck Pain and Disability Index** (NPDI) [154] are the most commonly used tools.

### Instruments

#### Roland & Morris Disability Questionnaire (RMDQ)

This tool was developed by Roland and Morris in 1983 [131]. It is frequently used and has been validated for the English, French [38], Swedish [82], German [49, 156], Turkish [90], Spanish [88], Portuguese [115], Japanese [142], Norwegian [64] and Greek [24] languages. Twenty-four questions from the Sickness Impact Profile (SIP) [17] were selected and added with the phrase "because of my back", leaving it open whether an impairment is due to pain or disability. The answering possibilities are **dichotomous** (yes/no) and, therefore, filling in the questionnaire requires little time and is easy to do. On the other hand, this might leave subtle changes in the abilities unrecognized. In contrast to the ODI, sex life is not included, and similar to the ODI neurological leg deficits are not addressed.

The RMDQ is more sensitive than the ODI in detecting changes over time

Compared to the ODI, the RMDQ is regarded as being more sensitive in detecting changes over time [19, 76, 140]. This is especially true in patients with minor disabilities. For patients with severe disabilities the RMDQ seems to perform worse than the ODI [19, 130]. Internal consistency has been shown to be equal [91, 129] or slightly superior to the ODI [76, 87].

#### Oswestry Disability Index (ODI)

This tool was developed by Fairbank et al. [50] in 1980. It is used frequently and has been validated in English, German [11, 101, 102], Danish [98], Finnish [63], Norwegian [64], French [43], and Greek [24]. It contains ten items about pain level and interference with physical activities, sleeping, self-care, sex life, social life and traveling. Each question offers six answers, which allows the assessment of subtle differences of disability.

The ODI performs better in patients with severe back-related disability than the RMDQ

In contrast to the RMDQ, respondents are only given an introduction, which points out that the questionnaire is about back pain, instead of being reminded in every question about the main topic. This might lead to misunderstanding if

patients are suffering from pain of different origin. Other differences between the ODI and the RMDQ are described above.

### NASS Questionnaire

This questionnaire was designed by the North American Spine Society in the early 1990s [39]. Validated German [123] and Italian [119] versions are available. It is based on the ODI, from which a selection of items was adopted and adapted. Questions from the SF-36 and the Health Survey Questionnaire were added to allow the assessment of a broad patient profile.

The NASS is based on the ODI, the SF-36 and the Health Survey Questionnaire

### Hannover Functional Ability Questionnaire (HFAQ)

The back pain version of the HFAQ belongs to a series of self-administered questionnaires about **functional limitations in the daily life** of patients suffering from musculoskeletal disorders [86]. It consists of 12 questions about abilities in daily activities such as lifting a heavy item. Each ability must be graded by "yes", "yes, but with trouble" or "no, or only with help". The HFAQ has been frequently used in German-speaking areas.

The HFAQ has been compared with different other disability questionnaires. Roese et al. [129] found it to be as feasible, practicable, valid and reliable as the RMDQ. Haase et al. [67] compared it with the physical functioning domain of the MOS SF-36 in a rehabilitation collective. In 4.3 % of all respondents, they found confusion with positive and negative ratings in the SF-36 subscale, while no similar problems could be detected in the HFAQ, and it was argued that the SF-36 seems to be more valuable for use in the ambulant medical sectors than in a rehabilitation setting. Finally, Schochat et al. [133] compared it with the NASS questionnaire in a rehabilitation collective and found high correlations indicating high concurrent validity. However, both questionnaires were not able to detect changes in the "impairment" domains after a 3-week period, again indicating that these instruments might be more suitable in short-term outcome research than in the field of rehabilitation.

The HFAQ is more applicable for short-term outcome research

### Neck Disability Index (NDI)

The NDI is a ten-item questionnaire derived from the ODI [145]. It is designed to assess **neck pain and disability** and consists of ten six-point Likert scales covering the following ten sections: Pain intensity, Personal care (washing, dressing, etc.), Lifting, Reading, Headaches, Concentration, Work, Driving, Sleeping, Recreation. Each question is rated from zero to five points, allowing a maximum of 50 points. The score achieved by the patient is divided by the maximum possible and multiplied by 100 to get a percentage score of the possible total. If one section is missed, the maximum score of 50 points is reduced by 5 points.

The NDI has been used in different populations and has been validated against multiple measures of function and pain [122]. Besides the original English version, a validated form for the French [157] and Swedish [3] languages is available.

The NDI assesses neck pain and related disability by ten six-point Likert scales

### Neck Pain and Disability Index (NPDI)

The NPDI was introduced in 1999 and consists of 20 VAS items assessing **neck pain and linked disability** [154]. Each VAS ranges from zero (normal function) to five (worst possible situation). It is divided into four sections: Neck problems, Pain intensity, Effect of neck pain on emotional and cognitive status, Interference of neck pain with daily activities.

The NPDI responds well to changes in neck pain and disability

It was found to show high internal consistency [154] and proved to have high test-retest reliability and a good response to changes in pain perception following treatment [61]. Besides the original validated English version, validated Turkish [20] and French [157] forms are available.

## Quality of Life

### General Aspects

The assessment of quality of life is related to health

The Constitution of the World Health Organization (WHO) defines quality of life as:

> "individuals' perception of their position in life in the context of the culture and value systems in which they live and in relation to their goals, expectations, standards and concerns. It is a broad ranging concept affected in a complex way by the person's physical health, psychological state, level of independence, social relationships, personal beliefs and their relationship to salient features of their environment".

Consequently, not only the WHOQOL questionnaires but also the MOS SF-36/-12/-8 and the EuroQol questionnaires cover these general aspects, usually integrating them into a physical and mental health score without addressing disease specific parameters. In the field of spinal surgery, these tools are mainly used in combination with disease-specific pain and disability questionnaires.

Julious et al. [84] and Roset et al. [132] stated that sample sizes should always be calculated to allow the opportunity to detect changes at a pre-set level of statistical significance when planning a trial with health related quality of life (HRQL) instruments. However, only a small amount data is to be found in the literature on this topic. They published guidelines for calculating sample sizes for the use with the SF-36 [84] and for the use with the EQ-5D [132], respectively.

The Psychological General Well Being Index (PGWBI) focuses on psychological and psychosocial aspects and therefore may not be considered to be an all-embracing tool to assess quality of life. However, as psychological aspects comprise an important part of the quality of life, it will be described in this section.

### Instruments

#### WHOQOL-100/WHOQOL-Bref

The WHO Quality of Life instruments have been developed with the intention of creating questionnaires that allow **quality of life** to be assessed as outlined above. Moreover, the aim was to evolve an international tool in several culturally diverse settings to simplify cross-cultural comparisons. To achieve this, 15 so-called Field Centers all over the world were involved in every stage of instrument development and further centers participated in the field testing [65].

The WHOQOL instruments assess health-related quality of life

The WHOQOL-100 consists of 100 questions referring to six domains [65]: Physical domain, Psychological domain, Level of independence, Social relationships, Environment, Spirituality/religion.

Each question has a **five-point answering scale**. For each domain a separate score is computed and transformed to a scale with a maximum of 100 points. It is obvious that such an extensive questionnaire is not practicable in a clinical setting where quality of life is only one part beside the more disease specific ones to be assessed. The evaluation of the data gathered with the WHOQOL-100 showed that the six domains may be grouped into four domains: Physical domain, Psychological domain, Social relationships, Environment.

Consequently, a core questionnaire consisting of 24 items was built and field tested in 17 centers with approximately 300 respondents each [1]. It was con-

cluded that this WHOQOL-Bref questionnaire showed validity and reliability and, thus, would be interesting for use in clinical trials. Meanwhile, the WHOQOL-Bref has been translated into and validated for further languages [53, 72, 79, 108, 114, 158]. It has been used in several recent studies in different fields of medicine: psychiatric disease [6, 42, 75, 85, 93, 113, 144, 150], geriatrics [60, 79], cancer [77, 159], liver disease [116] and HIV infection [35, 51]. In the field of musculoskeletal disorders it has been used in three studies [25, 69, 111]. The extensive validation procedures and translation into nearly 20 languages make the WHOQOL-Bref an interesting instrument for the future. Further detailed information is available from www.who.int.

### MOS SF-36/SF-12/SF-8

The SF-36 is widely used for the assessment of health-related quality of life

The SF-36 was developed in 1992 by Stewart and Ware as a short form of the questionnaires used in the Medical Outcomes Study (MOS) [152]. It consists of 36 items, most of which have their roots in established instruments such as the General Psychological Well-Being Index (PGWBI) [44], the Health Perceptions Questionnaire [153] and other tools which have proved to be useful during the Health Insurance Experiment (HIE) [27]. **Eight scales** are built to **describe quality of life**: Physical functioning, Physical role (problems with work or other daily activities due to physical health), Bodily pain, General health, Vitality, Social functioning, Emotional role (problems with work or other daily activities due to emotional problems), Mental health.

The results of these scales are then grouped into two **summary measures**:

- **Physical health** (scales 1 – 4)
- **Mental health** (scales 5 – 8)

The SF-36 sensitively detects changes over time

The SF-36 is the most commonly used self-assessed generic quality of life instrument [59]. The mean internal consistency and test-retest validity of the first version has been shown to exceed 0.80 in several studies [71, 105, 106]. In 1996, the second version, SF-36v2, was introduced offering several improvements based on experience with the first version: Instructions and questionnaire items were shortened and simplified. The layout was adapted to reduce missing responses. Some dichotomous response choices were replaced by five-point scales whereas others were shortened from six- to five-point scales as well. These adaptations led to a decrease in standard deviation and percentage of ceiling and floor scoring. Today the SF-36 is available in a 4-week (standard) and a 1-week (acute) recall version. Compared to other generic health status instruments, it has shown several advantages [48, 97]. It was found to be most sensitive to detecting changes over time and showed the highest levels of internal consistency.

Peto et al. [120] compared the mental health subscale with the PGWB questionnaire in a sample of patients with amyotrophic lateral sclerosis and found good internal reliability and high correlations for both the PGWB and the SF-36 subscale. They stated that the mental health subscale provided comparable psychometric performance and, thus, may be used to measure and compare mental health in defined groups.

The SF-12 and SF-8 are short forms of the SF-36 with good validity

In 1994 the development of a 12-item questionnaire began which led to the SF-12, a subset of the SF-36, that is now available in the second version [151]. Though improving efficiency and practicability in the clinical setting, one has to accept some restrictions leading to less information about health status compared to the SF-36. Finally, an 8-item subset of the SF-36 has been developed. The SF-8 assesses every domain described in the SF-36 by only one item each. Besides a 24-h recall version there is a 4-week and a 1-week recall version available. It has been translated and validated for more than 30 countries [99].

In conclusion, the SF questionnaires represent **valuable tools for the assessment of general quality of life**. Their widespread use in clinical trials leads to broad possible comparisons. It is recommended to use these instruments in combination with disease-specific questionnaires to obtain an all-embracing picture of the respondents. Extensive information about the use, validity and norm-based scoring and interpretation is available on the SF internet homepage (www.sf36.com) and in the SF manuals.

### EuroQol 5D

This tool was developed by the EuroQol Group, which started in 1987 with the intention of constructing an instrument for the assessment of standardized **non-disease-specific health-related quality of life**. It was thought to complement other tools such as the SF-36. The EuroQol Group is a multi-country, multi-center and multi-disciplinary group and, thus, the developed instrument should more easily allow cross-cultural comparisons to be performed.

The EuroQol exhibits validity comparable to the SF-36

The EQ-5D is a self-completion tool consisting of four components [28]. The first two parts address HRQL whereas the latter parts address further background information such as occupation, activity, age, sex, education and so on. In the first part HRQL is assessed by five statements about **mobility, self-care, usual activities, pain/discomfort and anxiety/depression**, which are divided into three degrees of severity. The respondents are asked to sign the one statement fitting best to their situation. This leads to a score of one to three in each statement. The second part consists of a Graphic Rating Scale ranging from zero to 100 in which respondents are asked to indicate their actual state of health today. Several studies were made to compare the EQ-5D with other quality of life tools, for example the SF-36. Generally, it was found to be a valuable instrument, simple to use by the patients and showing clinically relevant correlations with other condition-specific tools [26, 78]. Nevertheless, Brazier et al. [26] found it to be less sensitive and more susceptible to ceiling effects than the SF-36, preferring the latter for detecting changes over time. Further, detailed information is available on www.euroqol.org.

### Psychological General Well-Being Index (PGWBI)

This questionnaire was developed by Dupuy in 1969 and first published after modification in 1984 [44]. It consists of 22 questions on the following **six** domains: **Anxiety, Depression, Well-being, Self-control, and Health vitality**.

Each domain consists of three to five questions which have to be rated on a six-point Likert scale. Every answer is validated by zero to five points. This results in a maximum score of 110. Revicki et al. [128] developed the PGWB into a version suitable for use in telephone interviews and successfully validated it for an American population.

The PGWB is a reliable tool with which to assess psychological distress

The PGWB has been extensively validated and has been used in many clinical studies, for example in the field of chronic pain, often in combination with other general health state questionnaires such as the SF-36 [14–16, 143].

### Scoliosis Research Society Questionnaires: SRS-22/-24/-30

The **Scoliosis Research Society (SRS)** developed instruments to evaluate and monitor patients with **idiopathic scoliosis**. In 1999, the initial 24-item SRS-24 questionnaire was developed based on several previously validated questionnaires [70]. It is divided into seven equally weighted domains: Pain, General self-image, Post-operative self image, General function, Overall level of activity, Post-operative function and satisfaction.

This initial version was found to be reliable for postoperative outcome in scoliosis surgery as well as for dynamic monitoring in patients as they become adults. Nevertheless, some concerns about low internal consistency for some domains and some questions led to the creation of the current SRS-22.

This questionnaire is divided into five domains: Pain, Function/activity, Self-image/appearance, Mental health, Satisfaction about previous treatment.

The SRS-22/-30 questionnaires are specifically designed for scoliosis patients

As the SRS-22 no longer integrates specific questions about the postoperative status of the patients, the SRS-30 was developed. This version includes all questions of the 22-item tool and the postoperative questions of the 24-item tool. While the SRS-22 is validated for the English and Spanish [10] languages, the SRS-30 has not been validated so far. The SRS-22 was shown to be reliable with internal consistency and reproducibility comparable to the SF-36 [8, 18]. Moreover, it was found to be responsive to changes postoperatively [9] and to discriminate well between patients with no, moderate and severe scoliosis [7]. In one study it was even found to be useful in choosing non-surgical treatment in borderline cases [7]. The questionnaires and more information on scoring are available on the Scoliosis Research Society website (www.srs.org).

## Psychosocial Aspects, Work Situation and Fear Avoidance Beliefs

### General Aspects

In the past two decades, psychosocial and work-related aspects as well as the potential influence of behavior patterns have attracted interest in research on the development and course of chronic back pain [4, 33, 55, 57, 73, 149]. In this context, some instruments have been developed to assess these important aspects.

### Instruments

#### Assessment of Occupational Status

As a minimum data set the extent of work incapacity should be assessed preoperatively and at follow-up as it is easy to assess and of great societal relevance [5]. Bombardier [23] proposed a categorization including the following:

- employed at usual job
- on light duty or some restricted work assignment
- paid leave/sick leave
- unpaid leave
- unemployed because of health problems
- unemployed because of other reasons
- student, keeping house/homemaker
- retired
- disability

Occupational status and sickness absence should be assessed preoperatively and at follow-up

Besides the occupational status, sickness absence is quite easily accessible too and is also of economic relevance. Hensing et al. [74] proposed five measures for sick leave assessment. Nevertheless, it has become apparent that age, gender, cultural factors, economic and health policy factors, job satisfaction, psychosocial job factors and factors not related to work at all influence work status and sickness absence [46]. Therefore, **multivariate methods** must be used to control these confounding parameters when work status is analyzed [148], and additional measures of work-related outcome such as work ability, **job-related resignation** and **job satisfaction** should be used.

### Job Satisfaction and Job-Related Resignation

General job satisfaction and job-related resignation can be assessed by four 5-point Likert scales each. The items for the two scales are derived from a larger set of items developed by Oegerli [117] on the basis of the concept of "different forms of job satisfaction" by Bruggemann [29] (English description [34]). The two scales have been found to be reliable in several investigations.

### Fear-Avoidance Beliefs Questionnaire (FABQ)

The FABQ predicts treatment outcome in subacute and chronic low back pain

Lethem and Slade [92, 136] first mentioned in 1983 that an avoidance behavior may result in an exaggerated pain perception and in 1993 Waddell et al. [149] introduced the FABQ, which consists of 16 items and is designed as a self-reporting tool. The questions are pain-specific and divided into one part assessing **fear-avoidance beliefs about work** and another part assessing **fear-avoidance beliefs about physical activities**. It has been shown to be a valid and reliable questionnaire and several studies have found it to be useful in predicting treatment outcome in subacute and chronic low back pain [31, 54, 58, 138].

Validated German and Swiss-German versions are available [121, 138]. McCracken et al. [103] compared the FABQ with three other validated instruments for the assessment of anxiety and fear in chronic pain patients: (1) the Spielberger Trait Anxiety Inventory (STAI) with more general response tendencies [137]; (2) the Fear of Pain Questionnaire (FPQ) [107] with more general response tendencies in addition; and (3) the Pain Anxiety Symptoms Scale (PASS) with more pain-specific response tendencies [104]. The FABQ and the PASS as more pain-specific questionnaires were found to be better predictors than the less pain-specific ones. However, it was recommended to use these tools in combination with general emotional distress measures in a clinical setting to achieve valuable information about the influence of pain avoidance beliefs and other psychosocial stressors on the course of chronic pain situations.

## Clinical Feasibility and Practicability

Data completeness is mandatory for valid and reliable outcome assessment

As in most questionnaires a total score or several subscores are computed with the data from a small number of questions, and it is mandatory that questionnaires are filled in completely. Often, lacking the answer from only one or two questions makes analysis of the score impossible.

It is therefore important to inform patients about the importance of thorough questionnaire completion. Possible consequences of the planned investigation on future treatment modalities should be explained to the participants to increase their understanding. The patients' health and social condition have a significant impact on the willingness to participate in a study.

Short, valid reliable and easy to handle questionnaires are needed to increase questionnaire response and participation

It is desirable to use simple and short questionnaires in a clinical setting. This would not only minimize the patients' effort but also analysis of data by the health professionals. Therefore different groups are endeavoring to develop short, valuable, standardized outcome assessment tools. Deyo et al. [41] proposed a six-item core set of questions measuring several dimensions of outcome, each with a single item which has been studied and validated elsewhere. This short set of questions covering the core dimensions pain, function, well-being, disability (work), disability (social) and satisfaction post-treatment could be used as a basic battery for checking treatment outcome or developing quality improvements. A more detailed data assessment, for example within the scope of clinical trials with specific problems addressed, could easily be achieved by add-

ing further items in one of the core dimensions without necessarily expanding the whole questionnaire and therefore increasing the effort for respondents and analysts.

Mannion et al. [99] evaluated a modified German version of the standardized short core-measure tool proposed by Deyo and found it to be simple, practical, reliable and valid. Cronbach's alpha (internal consistency) for each core measure was between 0.41 and 0.78. Composing an index from all the core measures, Cronbach's alpha increased to 0.85. Test-retest reliability was moderate to excellent. There were floor and ceiling effects notable in the function domain whereas the disability dimension showed floor effects at follow-up. The correlations between the single items and their corresponding reference questionnaire were 0.60 – 0.79. The Sensitivity to Change was a little bit lower than in the reference questionnaires. Recently, White et al. [155] adapted the Deyo core questions to the neck pain setting and tested them on 104 patients. This first evaluation demonstrated a good repeatability and validity with absent floor or ceiling effects. These promising findings provide motivation for further research because the standardized use of such an instrument in future clinical trials would improve outcome assessment. It would improve the comparability between clinical studies and therefore build a better basis for treatment improvements in spinal surgery.

## Recapitulation

For the evaluation of spinal interventions **self-administered assessment tools** are widely used. An instrument must be comparable, translated into and validated for the corresponding language and must embrace at least **pain**, **disability**, **health-related quality of life** and **work status**. For more thorough investigations, psychosocial aspects, **work-related parameters** and **fear avoidance behavior** should additionally be assessed. For these purposes an array of well validated standardized questionnaires are available.

**Pain.** As the predominant complaint in patients with spinal disorders, the evaluation of pain is one of the pillars of outcome assessment. Pain assessment seems to be most reliable when asking for an average pain level during a short recall period of time from 1 week to 4 weeks. Pain experience is very individual, complicating an interindividual comparison. In well informed patients **visual analogue** (VAS) and **graphic rating scales** (GRS) are valuable instruments for assessment of pain intensity and changes due to therapy. Some restrictions have to be taken into account when using these tools in an elderly population as they may be misunderstood and misinterpreted. NRS and VRS are other methods in pain assessment. Although well understandable and easy to handle (also in telephone interviews), they are not as appropriate for detecting changes over time as are VAS and GRS.

**Disability.** Neck- or back-related disability is another predominant complaint. The **Roland and Morris Disability Questionnaire** and **Oswestry Disability Index** are by far the most used instruments for assessment of disability in back patients. While the former seems to be more sensitive in detecting changes over time, the latter seems to be more useful in patients with severe disability. The North American Spine Society Questionnaire and the Hannover Functional Ability Questionnaire are also valuable tools though less frequently used.

**Quality of life.** Besides disease-specific tools, questionnaires on health-related quality of life are widely used in medicine. Several instruments have been developed and broadly tested in terms of reliability and validity. The most commonly used questionnaire is the **SF-36**, but also the WHO has edited a valuable tool (**WHOQOL-Bref**). The third well explored and frequently used instrument is the Euro-Qol **EQ-5D**. The **PGWB** concentrates on psychological general well-being as an important part of quality of life and is a valuable questionnaire in more thorough investigations. For the special setting in scoliosis patients, the **Scoliosis Research Society** introduced the SRS-22 and SRS-30 questionnaires. They include pain, disability, quality of life and satisfaction with treatment and allow a pre- and postoperative evaluation of these patients.

## Recapitulation

**Psychosocial aspects.** It has been realized that psychosocial aspects and work situation are related to back pain. They may figure as risk factors or even predictors in subacute and chronic back pain. One aspect in this context is **fear avoidance behavior**, which can negatively influence outcome in spinal surgery. The most frequently used questionnaire in this field is the FABQ.

**Work situation.** As a minimum the work situation should be assessed by occupational status measures and sick absence measures. Because of the shortcomings of these simple methods additional instruments on job satisfaction and job-related resignation should be used for a more comprehensive assessment.

**Feasibility/practicability.** As in most questionnaires a total score or several subscores are computed with the data from a small number of questions, it is mandatory that questionnaires are filled in completely. Nevertheless, the patient's compliance is often insufficient for various reasons. Recent research is thus attempting to develop short and easily understandable tools which allow the gathering of enough data for meaningful conclusions.

## Key Articles

**Bombardier C (ed) (2000) Spine Focus Issue: Outcome assessments in the evaluation of treatment of spinal disorders. Spine 25:3097 – 3199**

**Boos N (ed) (2006) Outcome assessment and documentation. Eur Spine J 15 Suppl 1: S1 – 123**

These two special journal issues summarize the state of the art in outcome assessment, research, and documentation in the treatment of spinal disorders and are a source for further reading.

## References


1. (1998) Development of the World Health Organization WHOQOL-BREF quality of life assessment. The WHOQOL Group. Psychol Med 28:551 – 558
2. (2000) Glossary. Spine 25:3200 – 3202
3. Ackelman BH, Lindgren U (2002) Validity and reliability of a modified version of the neck disability index. J Rehabil Med 34:284 – 287
4. Al-Obaidi SM, Nelson RM, Al-Awadhi S, Al-Shuwaie N (2000) The role of anticipation and fear of pain in the persistence of avoidance behavior in patients with chronic low back pain. Spine 25:1126 – 1131
5. Amick BC, 3rd, Lerner D, Rogers WH, Rooney T, Katz JN (2000) A review of health-related work outcome measures and their uses, and recommended measures. Spine 25:3152 – 3160
6. Amir M, Lev-Wiesel R (2003) Time does not heal all wounds: quality of life and psychological distress of people who survived the holocaust as children 55 years later. J Trauma Stress 16:295 – 299
7. Asher M, Min Lai S, Burton D, Manna B (2003) Discrimination validity of the scoliosis research society-22 patient questionnaire: relationship to idiopathic scoliosis curve pattern and curve size. Spine 28:74 – 78
8. Asher M, Min Lai S, Burton D, Manna B (2003) The reliability and concurrent validity of the scoliosis research society-22 patient questionnaire for idiopathic scoliosis. Spine 28:63 – 69
9. Asher M, Min Lai S, Burton D, Manna B (2003) Scoliosis research society-22 patient questionnaire: responsiveness to change associated with surgical treatment. Spine 28:70 – 73
10. Bago J, Climent JM, Ey A, Perez-Grueso FJ, Izquierdo E (2004) The Spanish version of the SRS-22 patient questionnaire for idiopathic scoliosis: transcultural adaptation and reliability analysis. Spine 29:1676 – 1680
11. Basler HD, Jakle C, Kroner-Herwig B (1997) Incorporation of cognitive-behavioral treatment into the medical care of chronic low back patients: a controlled randomized study in German pain treatment centers. Patient Educ Couns 31:113 – 124
12. Beaton DE (2000) Understanding the relevance of measured change through studies of responsiveness. Spine 25:3192 – 3199

13. Beaton DE, Bombardier C, Guillemin F, Ferraz MB (2000) Guidelines for the process of cross-cultural adaptation of self-report measures. Spine 25:3186 – 3191
14. Becker N, Bondegaard Thomsen A, Olsen AK, Sjogren P, Bech P, Eriksen J (1997) Pain epidemiology and health related quality of life in chronic non-malignant pain patients referred to a Danish multidisciplinary pain center. Pain 73:393 – 400
15. Becker N, Hojsted J, Sjogren P, Eriksen J (1998) Sociodemographic predictors of treatment outcome in chronic non-malignant pain patients. Do patients receiving or applying for disability pension benefit from multidisciplinary pain treatment? Pain 77:279 – 287
16. Becker N, Sjogren P, Bech P, Olsen AK, Eriksen J (2000) Treatment outcome of chronic non-malignant pain patients managed in a Danish multidisciplinary pain centre compared to general practice: a randomised controlled trial. Pain 84:203 – 211
17. Bergner M, Bobbitt RA, Carter WB, Gilson BS (1981) The Sickness Impact Profile: development and final revision of a health status measure. Med Care 19:787 – 805
18. Berven S, Deviren V, Demir-Deviren S, Hu SS, Bradford DS (2003) Studies in the modified scoliosis research society outcomes instrument in adults: validation, reliability, and discriminatory capacity. Spine 28:2164 – 2169; discussion 2169
19. Beurskens AJ, de Vet HC, Koke AJ (1996) Responsiveness of functional status in low back pain: a comparison of different instruments. Pain 65:71 – 76
20. Bicer A, Yazici A, Camdeviren H, Erdogan C (2004) Assessment of pain and disability in patients with chronic neck pain: reliability and construct validity of the Turkish version of the neck pain and disability scale. Disabil Rehabil 26:959 – 962
21. Bolton JE (1999) Accuracy of recall of usual pain intensity in back pain patients. Pain 83: 533 – 539
22. Bolton JE, Wilkinson RC (1998) Responsiveness of pain scales: a comparison of three pain intensity measures in chiropractic patients. J Manipulative Physiol Ther 21:1 – 7
23. Bombardier C (2000) Outcome assessments in the evaluation of treatment of spinal disorders: summary and general recommendations. Spine 25:3100 – 3103
24. Boscainos PJ, Sapkas G, Stilianessi E, Prouskas K, Papadakis SA (2003) Greek versions of the Oswestry and Roland-Morris Disability Questionnaires. Clin Orthop:40 – 53
25. Bowman SJ, Booth DA, Platts RG (2004) Measurement of fatigue and discomfort in primary Sjögren's syndrome using a new questionnaire tool. Rheumatology 43:758 – 764
26. Brazier J, Jones N, Kind P (1993) Testing the validity of the Euroqol and comparing it with the SF-36 health survey questionnaire. Qual Life Res 2:169 – 180
27. Brook R, Ware J, Davies-Avery A, Stewart A, Donald C, Rogers W, Williams K, Johnston S (1979) Overview of adult health status measures fielded in RAND's Health Insurance Study. Med Care 17:1 – 131
28. Brooks R (1996) EuroQol: the current state of play. Health Policy 37:53 – 72
29. Bruggemann A (1974) Zur Unterscheidung verschiedener Formen von 'Arbeitszufriedenheit'. Arbeit und Leistung 28:281 – 284
30. Bryant RA (1993) Memory for pain and affect in chronic pain patients. Pain 54:347 – 351
31. Buchbinder R, Jolley D, Wyatt M (2001) 2001 Volvo Award Winner in Clinical Studies: Effects of a media campaign on back pain beliefs and its potential influence on management of low back pain in general practice. Spine 26:2535 – 2542
32. Budzynski TH, Stoyva JM, Adler CS, Mullaney DJ (1973) EMG biofeedback and tension headache: a controlled outcome study. Psychosom Med 35:484 – 496
33. Buer N, Linton SJ (2002) Fear-avoidance beliefs and catastrophizing: occurrence and risk factor in back pain and ADL in the general population. Pain 99:485 – 491
34. Buessing A (1992) A dynamic view of job satisfaction in psychiatric nurses in Germany. Work Stress 6:239 – 259
35. Chandra PS, Deepthivarma S, Jairam KR, Thomas T (2003) Relationship of psychological morbidity and quality of life to illness-related disclosure among HIV-infected persons. J Psychosom Res 54:199 – 203
36. Choiniere M, Amsel R (1996) A visual analogue thermometer for measuring pain intensity. J Pain Symptom Manage 11:299 – 311
37. Closs SJ, Barr B, Briggs M, Cash K, Seers K (2004) A comparison of five pain assessment scales for nursing home residents with varying degrees of cognitive impairment. J Pain Symptom Manage 27:196 – 205
38. Coste J, Le Parc JM, Berge E, Delecoeuillerie G, Paolaggi JB (1993) [French validation of a disability rating scale for the evaluation of low back pain (EIFEL questionnaire)]. Rev Rhum Ed Fr 60:335 – 341
39. Daltroy LH, Cats-Baril WL, Katz JN, Fossel AH, Liang MH (1996) The North American Spine Society Lumbar Spine Outcome Assessment Instrument: reliability and validity tests. Spine 21:741 – 749
40. Dawson EG, Kanim LE, Sra P, Dorey FJ, Goldstein TB, Delamarter RB, Sandhu HS (2002) Low back pain recollection versus concurrent accounts: outcomes analysis. Spine 27:984 – 993; discussion 994
41. Deyo RA, Battie M, Beurskens AJ, Bombardier C, Croft P, Koes B, Malmivaara A, Roland M,

Von Korff M, Waddell G (1998) Outcome measures for low back pain research. A proposal for standardized use. Spine 23:2003 – 2013
42. Dogan S, Dogan O, Tel H, Coker F, Polatoz O, Dogan FB (2004) Psychosocial approaches in outpatients with schizophrenia. Psychiatr Rehabil J 27:279 – 282
43. Dropsy R, Marty M (1994) [Indices of quality of life for evaluating lumbago]. Rev Rhum Ed Fr 61:44S–48S
44. Dupuy H (1984) The Psychological General Well-Being (PGWB) Index. Assessment of quality of life in clinical trials of cardiovascular therapies. New York: Le Jacq:170 – 183
45. Eich E, Reeves JL, Jaeger B, Graff-Radford SB (1985) Memory for pain: relation between past and present pain intensity. Pain 23:375 – 380
46. Elfering A (2006) Work-related outcome assessment instruments. Eur Spine J 15 Suppl 1: S32 – 43
47. Elfering A, Semmer NK, Schade V, Grund S, Boos N (2002) Supportive colleague, unsupportive supervisor: the role of provider-specific constellations of social support at work in the development of low back pain. J Occup Health Psychol 7:130 – 140
48. Essink-Bot ML, Krabbe PF, Bonsel GJ, Aaronson NK (1997) An empirical comparison of four generic health status measures. The Nottingham Health Profile, the Medical Outcomes Study 36-item Short-Form Health Survey, the COOP/WONCA charts, and the EuroQol instrument. Med Care 35:522 – 537
49. Exner V, Keel P (2000) [Measuring disability of patients with low-back pain – validation of a German version of the Roland & Morris disability questionnaire]. Schmerz 14:392 – 400
50. Fairbank JC, Couper J, Davies JB, O'Brien JP (1980) The Oswestry low back pain disability questionnaire. Physiotherapy 66:271 – 273
51. Fang CT, Hsiung PC, Yu CF, Chen MY, Wang JD (2002) Validation of the World Health Organization quality of life instrument in patients with HIV infection. Qual Life Res 11:753 – 762
52. Farrar JT, Young JP, Jr., LaMoreaux L, Werth JL, Poole RM (2001) Clinical importance of changes in chronic pain intensity measured on an 11-point numerical pain rating scale. Pain 94:149 – 158
53. Fleck MP, Louzada S, Xavier M, Chachamovich E, Vieira G, Santos L, Pinzon V (2000) [Application of the Portuguese version of the abbreviated instrument of quality life WHOQOL-bref]. Rev Saude Publica 34:178 – 183
54. Flynn T, Fritz J, Whitman J, Wainner R, Magel J, Rendeiro D, Butler B, Garber M, Allison S (2002) A clinical prediction rule for classifying patients with low back pain who demonstrate short-term improvement with spinal manipulation. Spine 27:2835 – 2843
55. Fordyce WE, Shelton JL, Dundore DE (1982) The modification of avoidance learning pain behaviors. J Behav Med 5:405 – 414
56. Freyd M (1923) The graphic rating scale. J Educ Psychol 43:83 – 102
57. Fritz JM, George SZ (2002) Identifying psychosocial variables in patients with acute work-related low back pain: the importance of fear-avoidance beliefs. Phys Ther 82:973 – 983
58. Fritz JM, George SZ, Delitto A (2001) The role of fear-avoidance beliefs in acute low back pain: relationships with current and future disability and work status. Pain 94:7 – 15
59. Garratt A, Schmidt L, Mackintosh A, Fitzpatrick R (2002) Quality of life measurement: bibliographic study of patient assessed health outcome measures. BMJ 324:1417
60. Golimbet V, Trubnikov V (2001) Evaluation of the dementia carers situation in Russia. Int J Geriatr Psychiatry 16:94 – 99
61. Goolkasian P, Wheeler AH, Gretz SS (2002) The neck pain and disability scale: test-retest reliability and construct validity. Clin J Pain 18:245 – 250
62. Gracely RH, McGrath P, Dubner R (1978) Validity and sensitivity of ratio scales of sensory and affective verbal pain descriptors: manipulation of affect by diazepam. Pain 5:19 – 29
63. Gronblad M, Hupli M, Wennerstrand P, Jarvinen E, Lukinmaa A, Kouri JP, Karaharju EO (1993) Intercorrelation and test-retest reliability of the Pain Disability Index (PDI) and the Oswestry Disability Questionnaire (ODQ) and their correlation with pain intensity in low back pain patients. Clin J Pain 9:189 – 195
64. Grotle M, Brox JI, Vollestad NK (2003) Cross-cultural adaptation of the Norwegian versions of the Roland-Morris Disability Questionnaire and the Oswestry Disability Index. J Rehabil Med 35:241 – 247
65. Group W (1994) Development of the WHOQOL: Rationale and Current Status. Int J Ment Health 23:24 – 56
66. Haas M, Nyiendo J, Aickin M (2002) One-year trend in pain and disability relief recall in acute and chronic ambulatory low back pain patients. Pain 95:83 – 91
67. Haase I, Schwarz A, Burger A, Kladny B (2001) [Comparison of Hannover Functional Ability Questionnaire (FFbH) and the SF-36 subscale "Physical Functioning"]. Rehabilitation (Stuttg) 40:40 – 42
68. Haefeli M, Elfering A (2006) Pain assessment. Eur Spine J 15 Suppl 1:S17 – 24
69. Haefeli M, Elfering A, Kilian R, Min K, Boos N (2006) Nonoperative treatment for adolescent idiopathic scoliosis: a 10- to 60-year follow-up with special reference to health-related quality of life. Spine 31:355 – 366; discussion 367

70. Haher TR, Gorup JM, Shin TM, Homel P, Merola AA, Grogan DP, Pugh L, Lowe TG, Murray M (1999) Results of the Scoliosis Research Society instrument for evaluation of surgical outcome in adolescent idiopathic scoliosis. A multicenter study of 244 patients. Spine 24:1435 – 1440
71. Haley SM, McHorney CA, Ware JE, Jr. (1994) Evaluation of the MOS SF-36 physical functioning scale (PF-10): I. Unidimensionality and reproducibility of the Rasch item scale. J Clin Epidemiol 47:671 – 684
72. Hasanah CI, Naing L, Rahman AR (2003) World Health Organization Quality of Life Assessment: brief version in Bahasa Malaysia. Med J Malaysia 58:79 – 88
73. Hasenbring M, Hallner D, Klasen B (2001) [Psychological mechanisms in the transition from acute to chronic pain: over- or underrated?]. Schmerz 15:442 – 447
74. Hensing G, Alexanderson K, Allebeck P, Bjurulf P (1998) How to measure sickness absence? Literature review and suggestion of five basic measures. Scand J Soc Med 26:133 – 144
75. Herrman H, Hawthorne G, Thomas R (2002) Quality of life assessment in people living with psychosis. Soc Psychiatry Psychiatr Epidemiol 37:510 – 518
76. Hsieh CY, Phillips RB, Adams AH, Pope MH (1992) Functional outcomes of low back pain: comparison of four treatment groups in a randomized controlled trial. J Manipulative Physiol Ther 15:4 – 9
77. Hsu C, Wang JD, Hwang JS, Tien HF, Chang SM, Cheng AL, Chen YC, Tang JL (2003) Survival-weighted health profile for long-term survivors of acute myelogenous leukemia. Qual Life Res 12:503 – 517
78. Hurst NP, Jobanputra P, Hunter M, Lambert M, Lochhead A, Brown H (1994) Validity of Euroqol – a generic health status instrument – in patients with rheumatoid arthritis. Economic and Health Outcomes Research Group. Br J Rheumatol 33:655 – 662
79. Hwang HF, Liang WM, Chiu YN, Lin MR (2003) Suitability of the WHOQOL-BREF for community-dwelling older people in Taiwan. Age Ageing 32:593 – 600
80. Jensen MP, Karoly P, Braver S (1986) The measurement of clinical pain intensity: a comparison of six methods. Pain 27:117 – 126
81. Jensen MP, Karoly P, O'Riordan EF, Bland F, Jr., Burns RS (1989) The subjective experience of acute pain. An assessment of the utility of 10 indices. Clin J Pain 5:153 – 159
82. Johansson E, Lindberg P (1998) Subacute and chronic low back pain. Reliability and validity of a Swedish version of the Roland and Morris Disability Questionnaire. Scand J Rehabil Med 30:139 – 143
83. Joyce CR, Zutshi DW, Hrubes V, Mason RM (1975) Comparison of fixed interval and visual analogue scales for rating chronic pain. Eur J Clin Pharmacol 8:415 – 420
84. Julious SA, George S, Campbell MJ (1995) Sample sizes for studies using the short form 36 (SF-36). J Epidemiol Community Health 49:642 – 644
85. Kilian R, Matschinger H, Loeffler W, Roick C, Angermeyer MC (2002) A comparison of methods to handle skew distributed cost variables in the analysis of the resource consumption in schizophrenia treatment. J Ment Health Policy Econ 5:21 – 31
86. Kohlmann T, Raspe H (1996) [Hannover Functional Questionnaire in ambulatory diagnosis of functional disability caused by backache]. Rehabilitation (Stuttg) 35:I–VIII
87. Kovacs FM, Abraira V, Zamora J, Teresa Gil del Real M, Llobera J, Fernandez C, Bauza JR, Bauza K, Coll J, Cuadri M, Duro E, Gili J, Gestoso M, Gomez M, Gonzalez J, Ibanez P, Jover A, Lazaro P, Llinas M, Mateu C, Mufraggi N, Muriel A, Nicolau C, Olivera MA, Pascual P, Perello L, Pozo F, Revuelta T, Reyes V, Ribot S, Ripoll J, Rodriguez E (2004) Correlation between pain, disability, and quality of life in patients with common low back pain. Spine 29:206 – 210
88. Kovacs FM, Llobera J, Gil Del Real MT, Abraira V, Gestoso M, Fernandez C, Primaria Group KA (2002) Validation of the Spanish version of the Roland-Morris questionnaire. Spine 27:538 – 542
89. Kremer E, Atkinson JH, Ignelzi RJ (1981) Measurement of pain: patient preference does not confound pain measurement. Pain 10:241 – 248
90. Kucukdeveci AA, Tennant A, Elhan AH, Niyazoglu H (2001) Validation of the Turkish version of the Roland-Morris Disability Questionnaire for use in low back pain. Spine 26:2738 – 2743
91. Leclaire R, Blier F, Fortin L, Proulx R (1997) A cross-sectional study comparing the Oswestry and Roland-Morris Functional Disability scales in two populations of patients with low back pain of different levels of severity. Spine 22:68 – 71
92. Lethem J, Slade PD, Troup JD, Bentley G (1983) Outline of a Fear-Avoidance Model of exaggerated pain perception – I. Behav Res Ther 21:401 – 408
93. Lin MR, Huang W, Huang C, Hwang HF, Tsai LW, Chiu YN (2002) The impact of the Chi-Chi earthquake on quality of life among elderly survivors in Taiwan – a before and after study. Qual Life Res 11:379 – 388
94. Linton SJ (1991) Memory for chronic pain intensity: correlates of accuracy. Percept Mot Skills 72:1091 – 1095
95. Linton SJ, Gotestam KG (1983) A clinical comparison of two pain scales: correlation, remembering chronic pain, and a measure of compliance. Pain 17:57 – 65

96. Linton SJ, Melin L (1982) The accuracy of remembering chronic pain. Pain 13:281 – 285
97. Lurie J (2000) A review of generic health status measures in patients with low back pain. Spine 25:3125 – 3129
98. Manniche C, Asmussen K, Lauritsen B, Vinterberg H, Kreiner S, Jordan A (1994) Low Back Pain Rating scale: validation of a tool for assessment of low back pain. Pain 57:317 – 326
99. Mannion AF, Elfering A Outcome assessment in low back pain: how low can you go? Eur Spine J 14(10):1014 – 1026
100. Mannion AF, Elfering A (2006) Predictors of surgical outcome and their assessment. Eur Spine J 15 Suppl 1:S93-S108
101. Mannion AF, Junge A, Fairbank JC, Dvorak J, Grob D (2006) Development of a German version of the Oswestry Disability Index. Part 1: cross-cultural adaptation, reliability, and validity. Eur Spine J 15:55 – 65
102. Mannion AF, Junge A, Grob D, Dvorak J, Fairbank JC (2006) Development of a German version of the Oswestry Disability Index. Part 2: sensitivity to change after spinal surgery. Eur Spine J 15:66 – 73
103. McCracken LM, Gross RT, Aikens J, Carnrike CL, Jr. (1996) The assessment of anxiety and fear in persons with chronic pain: a comparison of instruments. Behav Res Ther 34: 927 – 933
104. McCracken LM, Zayfert C, Gross RT (1992) The Pain Anxiety Symptoms Scale: development and validation of a scale to measure fear of pain. Pain 50:67 – 73
105. McHorney CA, Ware JE, Jr., Lu JF, Sherbourne CD (1994) The MOS 36-item Short-Form Health Survey (SF-36): III. Tests of data quality, scaling assumptions, and reliability across diverse patient groups. Med Care 32:40 – 66
106. McHorney CA, Ware JE, Jr., Raczek AE (1993) The MOS 36-Item Short-Form Health Survey (SF-36): II. Psychometric and clinical tests of validity in measuring physical and mental health constructs. Med Care 31:247 – 263
107. McNeil D, Rainwater A, Al-jazireh L (1986) Development of a methodology to measure fear of pain. Paper presented at the annual meeting of the Association for Advancement of Behavior Therapy, Chicago
108. Min SK, Kim KI, Lee CI, Jung YC, Suh SY, Kim DK (2002) Development of the Korean versions of WHO Quality of Life scale and WHOQOL-BREF. Qual Life Res 11:593 – 600
109. Morley S (1989) The dimensionality of verbal descriptors in Tursky's pain perception profile. Pain 37:41 – 49
110. Morley S, Pallin V (1995) Scaling the affective domain of pain: a study of the dimensionality of verbal descriptors. Pain 62:39 – 49
111. Muller K, Schwesig R, Leuchte S, Riede D (2001) [Coordinative treatment and quality of life – a randomised trial of nurses with back pain]. Gesundheitswesen 63:609 – 618
112. Nachemson A, Bigos SJ (1984) The low back. In: Cruess J, Rennie WRJ (eds) Adult orthopedics. New York: Churchill-Livingstone, pp 843 – 937
113. Nasermoaddeli A, Sekine M, Hamanishi S, Kagamimori S (2003) Associations between sense of coherence and psychological work characteristics with changes in quality of life in Japanese civil servants: a 1-year follow-up study. Ind Health 41:236 – 241
114. Norholm V, Bech P (2001) The WHO Quality of Life (WHOQOL) Questionnaire: Danish validation study. Nord J Psychiatry 55:229 – 235
115. Nusbaum L, Natour J, Ferraz MB, Goldenberg J (2001) Translation, adaptation and validation of the Roland-Morris questionnaire – Brazil Roland-Morris. Braz J Med Biol Res 34:203 – 210
116. O'Carroll RE, Smith K, Couston M, Cossar JA, Hayes PC (2000) A comparison of the WHOQOL-100 and the WHOQOL-BREF in detecting change in quality of life following liver transplantation. Qual Life Res 9:121 – 124
117. Oegerli K (1984) Arbeitszufriedenheit. Versuch einer quantitativen Bestimmung. Paul Buetiger AG, Biberist
118. Ohnhaus EE, Adler R (1975) Methodological problems in the measurement of pain: a comparison between the verbal rating scale and the visual analogue scale. Pain 1:379 – 384
119. Padua R, Padua L, Ceccarelli E, Romanini E, Bondi R, Zanoli G, Campi A (2001) Cross-cultural adaptation of the lumbar North American Spine Society questionnaire for Italian-speaking patients with lumbar spinal disease. Spine 26:E344 – 347
120. Peto V, Jenkinson C, Fitzpatrick R, Swash M (2001) Measuring mental health in amyotrophic lateral sclerosis (ALS): a comparison of the SF-36 Mental Health Index with the Psychological General Well-Being Index. Amyotroph Lateral Scler Other Motor Neuron Disord 2:197 – 201
121. Pfingsten M, Kroner-Herwig B, Leibing E, Kronshage U, Hildebrandt J (2000) Validation of the German version of the Fear-Avoidance Beliefs Questionnaire (FABQ). Eur J Pain 4: 259 – 266
122. Pietrobon R, Coeytaux RR, Carey TS, Richardson WJ, DeVellis RF (2002) Standard scales for measurement of functional outcome for cervical pain or dysfunction: a systematic review. Spine 27:515 – 522

123. Pose B, Sangha O, Peters A, Wildner M (1999) [Validation of the North American Spine Society Instrument for assessment of health status in patients with chronic backache]. Z Orthop Ihre Grenzgeb 137:437 – 441
124. Price DD, Bush FM, Long S, Harkins SW (1994) A comparison of pain measurement characteristics of mechanical visual analogue and simple numerical rating scales. Pain 56:217 – 226
125. Price DD, Harkins SW, Baker C (1987) Sensory-affective relationships among different types of clinical and experimental pain. Pain 28:297 – 307
126. Price DD, McGrath PA, Rafii A, Buckingham B (1983) The validation of visual analogue scales as ratio scale measures for chronic and experimental pain. Pain 17:45 – 56
127. Raspe H, Huppe A, Matthis C (2003) [Theories and models of chronicity: on the way to a broader definition of chronic back pain]. Schmerz 17:359 – 366
128. Revicki DA, Leidy NK, Howland L (1996) Evaluating the psychometric characteristics of the Psychological General Well-Being Index with a new response scale. Qual Life Res 5:419 – 425
129. Roese I, Kohlmann T, Raspe H (1996) [Measuring functional capacity in backache patients in rehabilitation: a comparison of standardized questionnaires]. Rehabilitation (Stuttg) 35:103 – 108
130. Roland M, Fairbank J (2000) The Roland-Morris Disability Questionnaire and the Oswestry Disability Questionnaire. Spine 25:3115 – 3124
131. Roland M, Morris R (1983) A study of the natural history of back pain. Part I: development of a reliable and sensitive measure of disability in low-back pain. Spine 8:141 – 144
132. Roset M, Badia X, Mayo NE (1999) Sample size calculations in studies using the EuroQol 5D. Qual Life Res 8:539 – 549
133. Schochat T, Rehberg W, von Kempis J, Stucki G, Jackel WH (2000) [The North American Spine Society Lumbar Spine Outcome Assessment Instrument: translation and psychometric analysis of the German version in rehabilitation patients with chronic back pain]. Z Rheumatol 59:303 – 313
134. Scott J, Huskisson EC (1976) Graphic representation of pain. Pain 2:175 – 184
135. Seymour RA, Simpson JM, Charlton JE, Phillips ME (1985) An evaluation of length and end-phrase of visual analogue scales in dental pain. Pain 21:177 – 185
136. Slade PD, Troup JD, Lethem J, Bentley G (1983) The Fear-Avoidance Model of exaggerated pain perception – II. Behav Res Ther 21:409 – 416
137. Spielberger C, Gorsuch R, Lushene P, Vagg P, Jacobs G (1983) Manual for the State-Trait Anxiety Inventory (Form Y). Palo Alto, CA: Consulting Psychologists Press
138. Staerkle R, Mannion AF, Elfering A, Junge A, Semmer NK, Jacobshagen N, Grob D, Dvorak J, Boos N (2004) Longitudinal validation of the Fear-Avoidance Beliefs Questionnaire (FABQ) in a Swiss-German sample of low back pain patients. Eur Spine J 13:332 – 340
139. Stewart WF, Lipton RB, Simon D, Liberman J, Von Korff M (1999) Validity of an illness severity measure for headache in a population sample of migraine sufferers. Pain 79:291 – 301
140. Stratford PW, Binkley J, Solomon P, Gill C, Finch E (1994) Assessing change over time in patients with low back pain. Phys Ther 74:528 – 533
141. Stratford PW, Binkley JM, Riddle DL (2000) Development and initial validation of the back pain functional scale. Spine 25:2095 – 2102
142. Suzukamo Y, Fukuhara S, Kikuchi S, Konno S, Roland M, Iwamoto Y, Nakamura T (2003) Validation of the Japanese version of the Roland-Morris Disability Questionnaire. J Orthop Sci 8:543 – 548
143. Thomsen AB, Sorensen J, Sjogren P, Eriksen J (2002) Chronic non-malignant pain patients and health economic consequences. Eur J Pain 6:341 – 352
144. Umansky R, Amir M, Fridmann M, Zidon E, Chen D, Nemetz B (2003) Was it a good move? Improvement in quality of life among chronic mental patients moving from a mental hospital to a hostel in the community. Isr J Psychiatry Relat Sci 40:248 – 257
145. Vernon H, Mior S (1991) The Neck Disability Index: a study of reliability and validity. J Manipulative Physiol Ther 14:409 – 415
146. Von Korff M, Jensen MP, Karoly P (2000) Assessing global pain severity by self-report in clinical and health services research. Spine 25:3140 – 3151
147. Von Korff M, Saunders K (1996) The course of back pain in primary care. Spine 21:2833 – 2837; discussion 2838 – 2839
148. Waddell G, Burton AK, Main CJ (2003) Screening to identify people at risk of long-term incapacity for work. A conceptual and scientific review. Royal Society of Medicine Press, London
149. Waddell G, Newton M, Henderson I, Somerville D, Main CJ (1993) A Fear-Avoidance Beliefs Questionnaire (FABQ) and the role of fear-avoidance beliefs in chronic low back pain and disability. Pain 52:157 – 168
150. Wang X, Gao L, Zhang H, Zhao C, Shen Y, Shinfuku N (2000) Post-earthquake quality of life and psychological well-being: longitudinal evaluation in a rural community sample in northern China. Psychiatry Clin Neurosci 54:427 – 433

151. Ware J, Jr., Kosinski M, Keller SD (1996) A 12-Item Short-Form Health Survey: construction of scales and preliminary tests of reliability and validity. Med Care 34:220 – 233
152. Ware J, Sherbourne C (1992) The MOS 36-item short-form health survey (SF-36). I. Conceptual framework and item selection. Med Care 30:473 – 483
153. Ware JE, Jr. (1976) Scales for measuring general health perceptions. Health Serv Res 11:396 – 415
154. Wheeler AH, Goolkasian P, Baird AC, Darden BV, 2nd (1999) Development of the Neck Pain and Disability Scale. Item analysis, face, and criterion-related validity. Spine 24: 1290 – 1294
155. White P, Lewith G, Prescott P (2004) The core outcomes for neck pain: validation of a new outcome measure. Spine 29:1923 – 1930
156. Wiesinger GF, Nuhr M, Quittan M, Ebenbichler G, Wolfl G, Fialka-Moser V (1999) Cross-cultural adaptation of the Roland-Morris questionnaire for German-speaking patients with low back pain. Spine 24:1099 – 1103
157. Wlodyka-Demaille S, Poiraudeau S, Catanzariti JF, Rannou F, Fermanian J, Revel M (2002) French translation and validation of 3 functional disability scales for neck pain. Arch Phys Med Rehabil 83:376 – 382
158. Yao G, Chung CW, Yu CF, Wang JD (2002) Development and verification of validity and reliability of the WHOQOL-BREF Taiwan version. J Formos Med Assoc 101:342 – 351
159. Yu CL, Fielding R, Chan CL, Tse VK, Choi PH, Lau WH, Choy DT, O SK, Lee AW, Sham JS (2000) Measuring quality of life of Chinese cancer patients: A validation of the Chinese version of the Functional Assessment of Cancer Therapy-General (FACT-G) scale. Cancer 88:1715 – 1727

# Subject Index


Aβ fiber 130
abdominal wall reflex 630
abscess 23
– drainage 24
– enucleation 24
acceleration and deceleration training 614
ACDF, see anterior cervical discectomy and fusion
ACE inhibitor 379
acetaminophen 141, 409, 421, 591, 595
acetylsalicylic acid 591
Achilles tendon reflex 310
achondroplasia 513, 518
actin 626
activity of daily living (ADL) 437, 609
acute
– anterior uveitis (AAU) 1062
– pain 126
– trauma 249
Aδ fiber 130
ADAMTS-4/5 104
adenosine triphosphate 626
ADI, see anterior atlantoaxial interval
adjacent segment degeneration 80, 455, 566
adjuvant drug 142
ADL, see activity of daily living
Adson's test 217
adult
– respiratory distress syndrome (ARDS) 1113
– scoliosis 629
advanced trauma life support (ATLS) 898
aerobic conditioning 614
agenesis 809
aggrecan 103
aggrecanase 104
air myelography 8
airway management 376
algesia 304
alkaline phosphatase 935
allodynia 127, 135, 333, 486
allograft bone 556
alpha-motoneuron 320, 324
– lesion 331
ALS, see amyotrophic lateral sclerosis
AMPA (alpha-amino-3-hydroxy-5-methyl-4-isoxazolepropionic acid) receptor 133, 136
amyotrophic lateral sclerosis (ALS) 312, 333
anesthesia 6
anal reflex 303
Andersson lesion 1075
aneurysmal bone cyst 963, 966
angiogenesis 955
angioma, cavernous 1005, 1008, 1016
angular motion 545
ankylosing spondylitis (AS) 24, 25, 255, 1057
– bone scan 1066
– complications 1080
– fractures 1075
– history 1061
– HLA-B27 gene 1060
– imaging studies 1063
– infection-based pathogenesis 1060
– natural history 1067
– non-operative treatment 1067
– operative treatment 1070
– pharmacological therapy 1068
– physical findings 1062
– physiotherapy 1069
– surgical techniques 1072
annular tear 232
anoikis 954
anterior
– atlantoaxial interval (ADI) 699
– cervical discectomy 1087
– – and fusion (ACDF) 449
– cord syndrome 305
– instrumentation 74
– lumbar interbody fusion (ALIF) 75, 560, 563, 726, 753
– lumbar retroperitoneal approach 355
– neural compression 449
– retroperitoneal approach 357
– spinal artery syndrome 1107
– spinal cord syndrome 434
– spinal surgery, complications 1089
– tension band technique 85
anterolateral implantation technique 76
anteromedial approach 338
– skin incision 340
– surgical anatomy 340
antibiotic 6
– prophylaxis 394
anticonvulsant 143
antidepressant, tricyclic 142
antihypertensive drug therapy 379
antisepsis 6
anulus fibrosus 44, 95, 97, 101, 542
anuresis, postoperative 1114
AOD, see atlanto-occipital dislocation
aortitis 1062
apoptosis 92
aprotinin 403
arachnodactyly 629
arachnoidal cyst 1106
arachnoidopathy 1015
arm pain 436
Arnold-Chiari malformation 635
arterial
– laceration 1100
– thrombosis 1102
arteriosclerosis 1091
arthritic pain 125, 1080

arthrodesis 186, 564
arthroplasty 567
– in the spine 80
– total disc 455
ascending tonic-clonic seizure 245
ASD, see atrial septal defect
aseptic
– discitis 1060, 1066
– spondylodiscitis 1075
Ashworth score 306
ASIA
– impairment scale 297
– protocol 894
assessment
– of occupational status 1133
– tool 1123
astrocytes 137
astrocytoma 997, 1003, 1008, 1015
asymmetric loading 715
atelectasis 377
atlantoaxial
– instability 830, 853, 872
– joint 829, 841
– – rotatory injuries 854
– stabilization 1050
atlantodental interval (ADI) 1049
atlanto-occipital dislocation (AOD) 836, 840, 846, 851, 872
atlas fracture 852, 863, 872
ATLS, see advanced trauma life support
atrial septal defect (ASD) 378
atrophy of the interosseous muscles 438
autologous bone graft 454
automated percutaneous lumbar disectomy 498
autonomic dysreflexia 385
awake fiberoptic intubation 376
axial compression 885
axis/axial
– fracture 863
– loading 885
– of motion 81
– of rotation 81
– pain 155, 156, 204, 222
axonal
– damage 321
– transport capacity 322
azathioprine 380

Babinski sign 300, 673
back pain, see also pain 15, 93, 125, 156, 274, 514, 541, 1125
– acute 590
– bed rest 164
– chronic 587
– classification 587
– clinical assessment 203
– discogenic 542, 543, 570
– geographical variation 164
– isolated 545
– lifetime prevalence 201
– lumbar lordosis 718
– lumbar spondylosis 539
– non-specific (NSLBP) 585, 587
– one-in-five rule of thumb 159
– persistence 154
– predominant
– – magnetic resonance imaging 549
– – standard radiographs 549
– prevalence 585
– psychosocial factors 162
– recurrence 154
– reproducibility of history 221
– risk factors
– – morphological 162
– – occupational physical 163
– – occupational physiological 163
– specific 587
– spinal tumor 957
– spondylolisthesis 737
bacterial infection 1030
BAK cage 562
bamboo spine 1061
Barsony projection 228, 253
BDNF, see brain-derived neurotrophic factor
Becker's muscular dystrophy 666, 678
bed rest 164
benign cavernous hemangioma 959
benzodiazepine 143, 406
beta-blocking agent, cardioselective 379
betamethasone 495
biceps tendon reflex (BTR) 310
bicycle test 524
bifurcation 356
biopsy
– excisional 964
– open incisional 964
– transpharyngeal stereotactic 964
BIS, see bispectral index
bisegmental instrumentation 71
bispectral index (BIS) 400
bladder
– catheter 399
– dysfunction 303, 305, 486
block vertebra 696
blood
– blood gas analysis 377
– predeposit 402
– product 400
– transfusion 401, 403
blunt trauma 827, 839
– to the neck 842
BMD, see bone mineral density
BMP, see bone morphogenetic protein
body cast 916
Böhler's fracture treatment 901, 915
bone/bony
– allograft 556
– aneurysmal cyst 963, 966
– ankylosis 111
– canal compromise 531
– computed tomography (CT) 241
– densitometry 929
– density 43
– giant cell tumor 966
– grafting 990, 1033
– – substitutes 556, 557
– – allogenic 905
– – in situ 74
– – transpedicular 905, 908
– metastatic carcinoma 977
– mineral density (BMD) 928
– – DEXA 241
– morphogenetic protein (BMP) 556
– nerve root entrapment 489
– promoter 558
– scintigraphy 244, 254
– spurs 93
– tumor, see there
Boston lumbar orthosis 781
bowel
– and bladder dysfunction 505
– atonia 1113

– disease 1062
– perforation 1103
bracing 689
– adolescent idiopathic scoliosis 640
– infantile and juvenile idiopathic scoliosis 639
– neuromuscular scoliosis 678
bradycardia 384
brain-derived neurotrophic factor (BDNF) 136
broadband ultrasonic attenuation (BUA) 242
Brodie abscess 29
bronchodilating agent 380
bronchogenic cyst 809
Brooks fusion 854
Brown-Séquard syndrome 304, 1005
BTR, see biceps tendon reflex
BUA, see broadband ultrasonic attenuation
Buck's fusion 748
bulbocavernosus reflex 303
bupivacaine 495
burst fracture 831, 871, 885, 888, 904, 909
buttress plate 78

C type fiber 130
cage
– designs 451
– filling 452
– fusion 462, 466
– insertion 563
– materials 451
calcitonin 525
calcium phosphate 557
calmodulin 626
Calvé-Perthes disease 767
Canadian C-spine rule 837
cancer cell 953
carbolization 8
cardiac dysfunction 397
carpal tunnel syndrome (CTS) 293, 323, 332, 333, 444
cartilage endplate 101, 107
– age-related changes 114
cast syndrome 1113
cauda equina
– lesion 323, 482, 491
– syndrome 18, 165, 203, 221, 222, 249, 486, 493, 496, 505, 1071, 1105, 1108
caudal
– block 283
– – indications 267
– epidural block
– – complications 268
– – technique 268
– regression 798, 800, 809, 811
cavernous angioma 1005, 1008, 1016
Cavitron ultrasound aspirator (CUSA) 1009
cefazolin 394
cellular senescence 92
central
– cord syndrome 304
– nervous system (CNS) tumor 997
– sensitization 136
– spinal stenosis 515
– venous pressure (CVP) 397
– vertical sacral line (CVSL) 632
CEP, see cortical evoked potential
cerebral palsy 383
cerebrospinal fluid fistula 1112
cervical
– closing wedge osteotomy 1075
– collar 446
– disc herniation
– – spontaneous resorption 445
– disc rupture 831
– discography 273, 275
– disorder
– – non-specific 435
– – specific 435
– epidural block
– – therapeutic efficacy 270
– facet dislocation injury 848
– facet joint block 278
– – complications 277
– injury
– – history 834
– – treatment 844
– instability 838
– lordosis 213, 445
– myelopathy 331, 332, 438
– – neurological deficit 291
– nerve root block 263
– – complications 265
– radiculopathy 431
– – differential diagnoses 444
– – surgery 448
– spine 294
– – degenerative alterations 430
– – functional testing 216
– – hyperextension 833
– – normal anatomy 828
– – physical risk factors 163
– – radiographs 229
– – surgery 418, 1087
– – trauma 839
– spine injury 825
– – imaging studies 836
– – neurological examination 894
– – physical findings 835
– spondylosis 430, 833
– spondylotic myelopathy (CSM) 430, 432, 464
– – dynamic compression 434
– spondylotic radiculopathy (CSR) 430, 449
– tumor 1006
cervicothoracic
– block
– – complications 268
– – technique 268
– kyphotic deformity 1075
CHA, see controlled hypotensive anesthesia
Chance fracture 909, 914
Charcot-Marie-Tooth disease 666, 670, 673
chemonucleolysis 20, 497, 505
Chiari malformation 699, 803, 804
chin-brow to vertical angle (CBVA) 1071
chloroform 6
chondrosarcoma 970
chordoma 957
chronic
– back pain, see there
– obstructive pulmonary disease (COPD) 1092
– pain, see there
chylothorax 1099
chymopapain 20, 497
circumferential fusion 563, 564
claudication 718, 724, 749, 931
clonus/clonal 463
– expansion theory 956
closing wedge osteotomy 1072
– cervical 1075
Cloward technique 449, 461
CMAP, see compound muscle action potential
coagulopathy 405

Cobb
– angle 9, 632, 635, 649, 679, 680, 682, 698, 709, 782, 788
– measurement 634
– raspatory 344
cocaine 6
Cock-Robin position 835
collagen 96
– fiber 95, 107
– gene polymorphisms 435
color Doppler sonography 247
compartment syndrome 1102
complications, postoperative
– anterior spinal surgery 1089
– approach-related 1095, 1115
– arterial laceration 1100
– bowel perforation 1103
– cardiovascular risk factors 1091
– cerebrospinal fluid leaks 1105
– disc herniation 1089
– embolization 1094
– epidural vein bleeding 1104
– homeostasis-related 1109
– idiopathic scoliosis 1089
– insufficient postoperative respiration 1099
– liver lesion 1100
– lumbar spinal fusion 1090
– malnutrition 1092
– medication 1092
– nerve root injuries 1104, 1110
– neural injuries 1108
– neurological complications 1110
– paraplegia 1095, 1110
– patient positioning 1094
– postoperative bleeding 1109
– postoperative kyphosis 1103
– postoperative venous thrombosis 1112
– preoperative planning 1093
– preventive measures 1090, 1115
– procedure-related complications 1115
– pulmonary embolism 1113
– pulmonary risk factors 1092
– spinal cord compromise 1110
– spinal cord injury 1106
– spinal stenosis 1089
– splenic injury 1100
– unintended durotomy 1105
– ureteral injury 1103
– urinary bladder injury 1103
– urogenital complications 1114
– vascular complications 1112
– vascular risk factors 1091
– vertebral artery injury 1103
– vessel laceration 1096
– wound infection 1110
compound muscle action potential (CMAP) 323
compression
– forces 69
– fracture 831, 905
– maneuver 704
– syndrome 496
– – cervical 295
– – of the spinal cord 295
computed tomography (CT) 8, 256
– artifacts 244
– contraindications 244
– fluoroscopy 241
– imaging protocol 242
– indications 243
– myelography 255, 443
– peripheral quantitative 242
– side effects 244
– spiral CT 241
concomitant non-spinal injury 893
conduction 130
congenital
– myopathy 671
– scoliosis 693
controlled hypotensive anesthesia (CHA) 398, 401
conus medullaris 808
– lesion 323, 482
– syndrome 305
convergent screw trajectory 71
coronal
– balance 630, 632
– imbalance 647
– plane curvature 693
coronary heart disease 378
corpectomy 71, 78, 85, 342, 355, 452, 462, 466, 681, 993
– blood loss 1108
– cervical region 78
– single level 78, 79
– three-level 79
cortical evoked potential (CEP) 406
costotransversectomy 964, 1010, 1035
Cotrel-Dubousset instrumentation system 562
Cotugno syndrome 16
cranial neuropathy 851
craniocervical junction 345
craniotomy 1112
crankshaft phenomenon 642, 644, 685, 702
Cronbach's alpha 1135
cross-over sign 220
cryoprecipitate 404
CSM, see cervical spondylotic myelopathy
C-spine rule 844
CSR, see cervical spondylotic radiculopathy
CSVL, see sacral vertical line
CT, see computed tomography
CTS, see carpal tunnel syndrome
curve
– flexibility 685
– progression 638
CVP, see central venous pressure
CVSL, see central vertical sacral line
cyclooxygenase (COX) inhibition 142, 421
cytokine 105
– proinflammatory 433, 485, 570

Dallas
– discogram description 272
– pain index 188
data assessment 1134
DCT, see deep vein thrombosis
DEBIT 248
decompression
– laminectomy 527, 987
– – reoperation 530
– of the subaxial spine 1051
– of the upper cervical spine 1051
– sickness 312
deep vein thrombosis (DVT) 420, 981
deformity surgery 346
degenerating spondylosis 93
degeneration/degenerative 293
– disorder 293
– lumbar spondylosis 539
– motion segment 433
– of the adjacent segment 80
– scoliosis 113, 521, 713
– spondylolisthesis 514, 515, 520, 521, 1043

degenerin 129
delayed decompression 905
demineralized bone matrix 557
Denis classification 888
dens fracture 830, 854, 860, 871
densitometry 934
dermal sinus 808
dermatomal sensory loss 520
dermatome 18, 218, 332, 420
dermoid tumor 808
desmopressin 403
desoxypyridinoline 935
detrusor sphincter dyssynergia 303
DEXA, see dual-energy X-ray absorptiometry
dexamethasone 985, 1009
diabetes mellitus 418
diabetic peripheral neuropathy 333
diagnostic triage 156
diaphragmatic breathing 609
diastematomyelia 806, 809, 1107
diathermy knife 343, 347
DIC, see disseminated intravascular coagulopathy
diclofenac 591
DICOM 227
diffusion imaging 239
diplomyelia 809
disability 158, 191, 210
– in daily activities 1128
disc
– arthroplasty 80, 85
– bulging 45, 432, 492
– degeneration 161, 162
– – etiology 106
– – genetic predisposition 137
– – grading 232
– extrusion 233
– herniation 17, 83, 107, 162, 184, 208, 252, 293, 449, 481
– – asymptomatic 489
– – cardinal symptoms 486
– – cervical radiculopathy 432
– – classification 491
– – complications 1089
– – computed tomography 490
– – contained 491
– – CT diagnosis 243
– – injection studies 490
– – lateral 491
– – lumbar intervertebral 483
– – magnetic resonance imaging (MRI) 488
– – natural history 494
– – neurophysiologic studies 490
– – non-contained 491
– – non-operative treatment 493
– – recurrence 500, 504
– – risk factors 483
– – thoracic 487, 502
– – traumatic 483
– intervertebral 44
– microscopic alterations during aging 99
– migration 445
– neovascularization 542
– prolapse 20
– prosthesis 566
– – displacement-controlled protocol 81
– – histocompatibility 81
– – stability 81
– protrusion 17, 18, 233, 330, 431, 483, 489, 515
– space curettement 502
– surgery 18
discectomy 18, 70, 77, 185, 190, 342, 399, 459, 495, 498, 502, 753, 1105
– automated percutaneous 498
– complications 504, 1087
– depression 188
– microscopic 501
– sciatic pain 504
– without fusion 452
discitis 273, 1060, 1066, 1112
discogenic
– back pain, see there
– pain syndrome 546, 548
discography 283, 443, 461
– cervical 273, 275
– lumbar 272
– provocative 271, 551
– thoracic 273, 274
discoligamentous injury 846
discovertebral kyphosis 1059
disinhibition of dorsal horn neurons 137
disorder of the autonomic system 303
displacement 856
disseminated intravascular coagulopathy (DIC) 404
dissociated sensory deficit 299
distraction
– compression 77
– injury 869
– segmental 77
distress and risk assessment method (DRAM) 188
DMD, see Duchenne muscular dystrophy
dobutamine stress echocardiography 378
dorsal
– horn cytoarchitecture 130
– pain 125
double major curve 650
Down's syndrome 376
DRAM, see distress and risk assessment method
drop metastasis 997
dual energy X-ray absorptiometry (DEXA) 241, 928, 935
– scan 942
Duchenne muscular dystrophy (DMD) 376–378, 397, 383, 664, 666, 667, 679, 1092, 1099
Dunn-McCarthy rod 688
duodenojejunostomy 1114
duplex sonography 247
durotomy, unintended 1105
dynamic
– fixation 571
– loading 60
– neutralization system 83
– stabilization 568
Dynesys 83
– stabilization 558
– system 568
dysesthesia 333
dysfunction of the bowel 303
dysphagia 342, 463, 466
dysplasia 737
dysrhythmias 383

early decompression 905
*Edwin Smith Surgical Papyrus* 2, 27
Effendi's classification 861
eggshell procedure 1072
elastin 111
– fiber 95, 515
electrocoagulation for skin dissection 1111
electromyography (EMG) 319
– indications 321
– technique 321

electrotherapy 448
embolization 1094
EMG, see electromyography
enchondroma 18
endotracheal tube 342
endplate
– calcification 108
– change 236
– – MR imaging 251
– fractures 109
– ossification 108
English swing 12
entrapment syndrome 293, 333
ependymoma 1005, 1007, 1008, 1014
– myxopapillary 1002
– of the filum terminale 997, 1000
epidemiology 153, 167
epidermoid tumor 808
epidural
– bleeding 235
– block 283
– indications 267
– fibrosis 505
– hematoma 897, 1075
– lipomatosis 235
– steroid block
– – therapeutic efficacy 268
– steroid injection 270, 495
– vein bleeding 1104
epinephrine 626
erector spinae 53
erythropoietin 402
esthesia 304
European myelopathy score 439
EuroQol 5D 1132
Ewing's sarcoma 966
excisional biopsy 964
excitatory mechanism 133
exhibitory mechanism 124
expansive open-door laminoplasty 459
external oblique muscle 353
extracellular matrix, molecular changes during aging 103
extrapedicular screw trajectory 73
extravasation 955

facet
– arthropathy 80, 280
– asymmetry 46
– block 721
– hypertrophy 742
– infiltration 1048
– joint, see also zygapophyseal joint 41, 46, 73, 109
– – age-related changes 109, 114
– – block 275, 283, 284, 461, 637
– – cervical block 277, 279
– – dislocation 869
– – indications 275
– – injections 247, 552
– – lumbar block 276, 278
– – malorientation 109
– – MR imaging 251
– – osteoarthritis (OA) 109, 262, 275, 278, 437, 542, 543, 549, 552, 567, 570
– – spontaneous fusion 544
– – syndrome 275, 544, 546, 570
– – synovial cyst 298
– – unloading 84
– osteoarthritis 521
– syndrome 21, 548
facetectomy 56, 527
facioscapulohumeral dystrophy 666
failed back syndrome 504, 812
fear avoidance belief 188
Fear-Avoidance Beliefs Questionnaire (FABQ) 1134
femoral stretch test 221
FFP, see fresh frozen plasma
fibrolipoma 808
fibula strut allograft 452
filar lipoma 808
filum terminale
– ependymoma 997, 1000, 1010
– fibrolipomatous 809
– hypertrophic 809
– lipoma 807
finger-floor distance 213
finger-to-nose test 302
fistula, epithelium-lined 808
fixateur interne 67, 71, 941
fixation system 30
flaccid paralysis/paresis 306, 833
flag system 588, 589
flat back syndrome 647, 650, 769
flavetomy 499
flexibility 55
flexion-distraction injury 886
fluid doctrine 16, 123
Foley catheter 399
folic acid antagonist 801
foramen magnum tumor 1006
foraminal stenosis 516, 522, 527, 729, 746, 1108
foraminotomy 455, 498
– Frykholm 458
fracture type 913
Frankel score 904, 909
free-body diagram 58
French open-door laminoplasty 459
fresh
– frozen plasma (FFP) 403
– pars defect 742
Friedrich's ataxia 378
Froin's syndrome 1008
FSU, see functional spinal unit
functional
– impairment 210
– pain 128
– spinal unit (FSU) 541
fusion surgery 186
– cages 450
F-wave recording 324

GABA, see gamma-aminobutyric acid
gabapentin 390
GAD, see glutamic acid decarboxylase
Gaines procedure 754, 1108
gait disorder 301, 438
Gallie fusion 854
gamma irradiation 556
gamma-aminobutyric acid (GABA) 132, 137
Gardner-Wells
– extension 339
– tong 846
gastric distension 385
gastrulation 800
gene polymorphism 465
giant cell tumor of bone 966
gibbus 23
Gill's procedure 748
Glasgow
– coma scale (GCS) score 827
– Illness Model 158

glioblastoma multiforme 1003
glioma
– intramedullary 1009
– malignant 1003
Glisson swing 12
glutamate 136, 435
glutamic acid decarboxylase (GAD) 137
glycine 132, 137
Gordon sign 300
Gower test 673
Graf ligamentoplasty 83, 558, 568
granuloma 997
graphic rating scale (GRS) 1126
gray matter 294
Grisel syndrome 853
growth factor 105
GTP cyclohydrolase gene 137

HA, see hydroxyapatite
halo
– fixator 74, 847
– traction 707
– vest 848, 853, 856, 866
halo-femoral traction 787
hamstring tightness 783, 784, 791
handicap 210
hangman's fracture 860, 861, 872
Hannover Functional Ability Questionnaire (HFAQ) 1129
hard herniation 433
Harrington
– compression rod 784
– distraction rod 647
– instrumentation 13
– operation 642
– principle 680
HDS, see histological degeneration score
health
– behavior 187
– condition 605
Health Insurance Experiment (HIE) 1131
heart failure 1091
heel-to-knee test 302
Heister's cross 12
helical axis of motion 81
hemangioblastoma 998, 1003, 1007, 1008, 1016
hemangioma 962, 965, 967
– benign cavernous 959
hemangiosarcoma 963
hematoma
– epidural 1075
– – with neurological deterioration 1110
– postoperative 1110
– retroperitoneal 1110
– retropharyngeal 851
hematothorax 1099
hemiarthrodesis 703
hemicord syndrome 1005
hemiepiphysiodesis 702, 703
hemilaminectomy 724, 1010, 1012
hemivertebra 695, 701, 703, 708
– cervical 699
– resection 705, 706
hemoglobin concentration 1109
hemorrhage 419
hemorrhagic shock 384
hemothorax 419
Hensen's node 809
heparin treatment 1102
hereditary motor sensory neuropathy (HMSN) 666
herniated nucleus pulposus (HNP) 481
herpes zoster infection 312
hidrosis 303
high-energy trauma 893
hip
– contracture 672
– pathology 220
Hippocratic bench 11
histological degeneration score (HDS) 99
HLA-B27 gene 1060, 1063
HMSN, see hereditary motor sensory neuropathy
HNP, see herniated nucleus pulposus
Hodgson approach 1099
Hoffman's sign 300, 673
Hohman retractor 347
Horner's syndrome 341, 342, 1006, 1087, 1098, 1115
host-graft interface 452
H-reflex recording 325
human spine 61
hyaluronan 103
hydrocephalus 804
hydromyelia 803, 818, 999
hydroxyapatite (HA) 557
hyperalgesia 127, 135, 486
hypercapnia 382
hyperextension
– casting 914
– injury 869, 886
hyperglycemia 418
hyperkalemia 405
hyperkyphosis 774
– hamstring tightness 783
– thoracic 765, 783
– thoracolumbar 765
hyperlordosis 670, 677, 751
hypocalcemia 405
hypoglossal nerve 341
– lesion 1097
hypokyphosis 645
hyponatremia 1099
hypotension 894
hypothermia 399
hypovolemia 894

ibuprofen 591
ICF classification 605
idiopathic roundback 774
idiopathic scoliosis, see scoliosis, idiopathic
iliolumbar ligament 735
imaging 8
– acute trauma 249
– bone scintigraphy 244
– claustrophobia 240
– computed radiology (CR) systems 227
– computed tomography (CT) 241
– contraindications 239
– digital radiography (DR) systems 227
– fat-suppressed 239
– indications 247, 256
– MR protocol 230
– myelography 245
– positron emission tomography 245
– postoperative 251
– short tau inversion-recovery (STIR) sequences 239
– spinal cord lesions 251
– standard radiographs 227
– susceptibility artifacts 240
– ultrasonography 247
– contrast enhanced MR 237
immunodeficiency syndrome 1021

implant
– stability 68
– safety zone 68
incisional biopsy 964
infantile scoliosis, see scoliosis, infantile
infection of the spine 22, 238, 687, 1021, 1111, 1021
– antituberculous chemotherapy 1031
– biopsy 1028
– debridement 1032
– drainage 1032
– history 1024
– imaging studies 1026
– inflammation markers 1025
– non-operative treatment 1029
– non-specific 1023
– operative treatment 1031
– radionuclide studies 1028
– specific 1023
– spinal instrumentation 1033
inferior laryngeal nerve 341
inflammatory
– disorder 312
– pain 126
– pannus 1043
infrared laser 448
inhibitory mechanism 124, 132
innervation, age-related changes 102
in-situ bone grafting 74
instability syndrome 546, 546, 570
instantaneous axis of rotation 81
instrumentation
– anterior 74
– bisegmenal 71
– posterior 71
instrumented fusion 569
insufficient postoperative respiration 1099
insulin resistance 418
intent-to-treat analysis 503
interbody
– cage 77
– fusion 530, 559, 908, 914
– – adjacent segment degeneration 566
– – anterior lumbar 560
– – cage augmented 562
– – device 82
– – laparoscopic techniques 565
– – mini-open anterior approach 565
– – patient selection 565
– – posterior lumbar 560
– – revision surgery 565
– – technique 75, 84
interleukin
– -1 (IL-1) 105
– -1β (IL-1β) 137
intermittent pneumatic compression (IPS) 381
interspinous
– implant 568
– process distraction technique 83
intervertebral
– disc 5, 44, 61, 95, 101
– – age-related changes 102, 114, 432
– – burned-out 102
– – preserve 455
– foramina 21
– ligament 41
intradiscal pressure 79
intradural-extramedullary tumor 999
intradural-intramedullary tumor 1002
intramedullary glioma 1009
intraneural edema 484
intraocular pressure (IOP) 396
intraoperative neuromonitoring 329
intraspinal tumor 234
intravasation 955
in-vivo telemetry 69
ion channel 129
IOP, see intraocular pressure
IPS, see intermittent pneumatic compression
ischemic optic neuropathy 396
*iscias nervosa*
– *antica* 16
– *postica* 16
isthmic spondylolisthesis 516, 521

Jackson table 395
Jefferson fracture 830, 852
Jendrassik maneuver 326
JOA score 439
job
– heaviness 189
– satisfaction 1134
job-related resignation 1134
juvenile kyphosis 13, 765, 776
– classification 771
– complications 790
– correction 788
– definition 771
– genetic predisposition 773
– history 773
– imaging studies 775
– lung function 777
– non-operative treatment 779
– operative treatment 782

Kaneda device 910
Karnofsky performance status 984
Kerrison rongeur 500
ketamine 406, 407, 422, 423
kinesiophobia 617
King classification 627
Klippel-Feil syndrome 699, 809
kyphectomy 686, 687
kyphoplasty 941
kyphoscoliosis 666, 689, 693
– collapsing 667
– neurogenic 676
– neuromuscular 682, 687
kyphosis/kyphotic 3, 12, 79, 184, 397, 434, 452, 670, 675, 688, 899, 912, 1057
– congenital 693, 777
– correction 784
– deformity 681, 688, 896, 914
– discovertebral 1059
– fracture
– – functional bracing 902
– – functional treatment 902
– laminoplasty 459
– partial correction 916
– postoperative 1103
– post-traumatic 68
– segmental 84
– thoracic 768
– vertebral 1059

laceration
– arterial 1100
– of the lung 1098
– of the thoracic vessels 1098
– venous 1102
lacunae 95

laminectomy 14, 20, 29, 185, 382, 457, 459, 502, 526, 531, 724, 748, 1009, 1010, 1075
– compression 457
– decompressive 29, 987
laminoplasty 466, 1103
– expansive open-door 459
– French open-door 459, 464
– techniques 460
laminotomy 499, 526, 528, 531, 724
– osteoplastic 1009
Langerhans cell histiocytosis 967
laryngoscopy 391, 464
Lasègue sign 184, 220, 487, 488
– reversed 221
laser disectomy 498
late whiplash syndrome 828, 834, 871
lateral
– recess stenosis 515
– swimmer's view 229
laughing gas 6
LBP, see (lower) back pain
LDUH, see low dose unfractioned heparin
leg
– length discrepancy 629, 698
– pain 266
*Lehrlingskyphose* 765
Lenke classification 627
leukotaxis 485
leukotriene 135
Lhermitte sign 220, 1045
lidocaine 265, 278, 447
lifting
– forces 59
– technique 59
ligament
– age-related changes 114
– capsular 47
– interspinous 47
– of the spine 47
ligamentoplasty 82
ligamentotaxis 899, 907
ligamentous injury 830
ligamentum flavum 47, 111, 515, 735
light touch 218
limb asymmetry 629
lipid peroxidation 435
lipoma 806
lipomyelomeningocele 806, 809, 812
lipomyeloschisis 806
liver lesion 1100
LMWH, see low molecular weight heparin
load
– during lifting 59
– sharing 69, 84
loading 84
– disorder 613
lobar collapse 377
locked-in syndrome 836
lordoplasty 941
lordoscoliosis, congenital 693
lordosis 3, 82
– congenital 693
loss of muscle mass 113
low
– back pain, see back pain
– dose unfractioned heparin (LDUH) 381
– molecular weight heparin (LMWH) 381
lumbar
– arthrodesis
– – posterolateral fusion 559
– block
– – complications 268
– – technique 268
– catch 548
– disc herniation
– – conservative and surgical treatment 503
– discectomy 190, 504
– discography 272
– – complications 273
– – diagnostic efficacy 273
– epidural block
– – therapeutic efficacy 270
– facet joint block 276, 278
– fusion 569
– – mini-open anterior approach 565
– – patient selection 565
– lordosis 519, 645, 716, 735, 768, 769, 776, 791
– multifidus 53
– nerve root block 263
– – complications 265
– postdiscectomy syndrome 505
– puncture 1008
– spinal canal stenosis 331
– – neurological deficit 291
– spinal fusion 24
– – adjacent segment degeneration 566
– – complication rate 1090
– spinal stenosis 513, 942
– – surgery 526
– spine
– – motion 213
– – standard radiographs 228
– – thoracic spine 228
– spondylosis 539
– – complications 569
– – computed tomography 550
– – discography 551
– – indications for surgery 554
– – magnetic resonance imaging 549
– – pain management 553
– – physical exercises 553
– – psychological intervention 553
– – spinal fusion 554
– – standard radiographs 549
– stabilization 561
– stenosis 22
– – classification 517
– – congenital 517
– surgery 505
lumberjack fracture-dislocation 886
lumbosacral fusion 726
lumbotomy 643
lung
– cancer 978
– laceration 1098
Luque-Galveston fixation 682, 683
lymphocytopenia 1099

macroscopic disc alteration 98
magnetic resonance imaging (MRI) 8, 229, 255
– contrast agents 237
– fat-suppressed images 237
– metastatic lesions 982
– open MR systems 230
major histocompatibility complex (MHC) 1060
malignant
– disease
– – of the vertebral column 384
– – spinal cord 384
– glioma 1003

malnutrition 1092
Mantoux test 1025
MAP, see mean arterial pressure
Marchetti classification 736
Marfan syndrome 378, 383, 625
mastoidectomy 853
matrix
– degradation 542
– metalloproteinase (MMP) 98, 104
– – tissue inhibitors 104
Mayfield head clamp 342
McNab's test 216
mean arterial pressure (MAP) 396, 401
mechanical compression 485
median nerve palsy 219
Medical Outcome Study (MOS)
– SF-8 1131
– SF-12 1131
– SF-36 1131
melatonin 626
meningioma 999, 1008
meningocele 804
– anterior sacral 807
– repair 812
Mennel test 215, 220, 1062
metabolic bone disease 927
metamizol 410
metastasis 956, 967, 977
– arteriography 983
– biopsy 983
– classification 984
– history 980
– imaging studies 981
– in the vertebral body 979
– Karnofsky performance status 984
– neurologic examination 980
– non-operative treatment 985
– operative treatment 986
– pain 980
– radiation therapy 985
– radionucleotide bone scan 983
– Tokuhashi scoring system 984
methotrexate 380
methylprednisolone 278, 447, 485, 849, 872
microdiscectomy 20, 373, 498, 500, 502, 506
microglia 137
midazolam 240, 407
Milwaukee brace 12, 781
Minerva
– cast 853, 856, 866
– cervical brace 845
– jacket 74
mini-thoracotomy 649
Minnesota **m**ultiphasic **p**ersonality **i**nventory (MMPI) 187
MMD, see myotonic muscular dystrophy
MMP, see matrix metalloproteinase
MMPI, see Minnesota **m**ultiphasic **p**ersonality **i**nventory
modic change 549, 570
modulation 130
– nociceptive impulses 132
monitoring
– depth of anesthesia 400
– intraoperative 397
– nerve root 408
– spinal cord 405
monoaminoxidase 380
mononeuropathy 333
monoparesis 299
monosegmental instability 71
morbus Bechterew 27, 1069
morcellized rib 787
motion segment 42, 61, 93
– degeneration 433
– stiffness 48
motion-preserving surgery 566
motor
– deficit 299
– nerve fiber 329
motor-evoked potential (MEP) 319, 328, 391, 444, 523, 722, 842, 1095
– anesthetic effects 407
movement disorder 613
MRC spine stabilization trial 569
MRI, see magnetic resonance imaging
multidimensional short core measure 182
multimodal analgesia 409
multiple myeloma 967, 998
multireceptorial neuron 131
multisegmental
– posterior wedge osteotomy (MPWO) 1073
– stabilization 909
muscle/muscular 62
– activity 52
– – extension 54
– – flexion 54
– – rotation 54
– age-related changes 114
– atrophy 113, 213, 305, 320
– – painless 299
– dystrophy 333
– fiber
– – atrophy 113
– – distribution 625
– – fast twitch 112
– – motor unit 112
– – slow twitch 112
– forces 69
– of the trunk 48
– relaxant 143, 391
– spasm 211, 220, 383
– spatial distribution 48
– splitting approach 358
– tendon reflex 299
musculoskeletal
– disorder
– – psychosocial risk factors 163
– – total costs 160
– impairment 93
– pain 125
– system, age-related changes 91
– tumor 953
MW fixation 683, 684
*Mycobacterium tuberculosis* 23, 1025
myelocele 797, 802, 804, 818
myelocystocele 805
myelodysplasia 672
myelography 245, 273, 490
– computed tomogaphy (CT) 443
– MR 246
myelomeningocele 672, 674, 685, 686, 797, 798, 802, 804, 812, 818
– prenatal diagnosis 814
myelon
– compression 1046, 1051
– distension 1007
myelopathic syndrome 436, 465
myelopathy 463, 994
– cervical spondylosis 433, 462
– differential diagnoses 444
– magnetic resonance imaging (MRI) 439

– radiography 439
myeloschisis 804
myelotomy 1009, 1013
myocardial infarction 1091
myopathy 673
– congenital 333
– scoliosis 676
myosin 626
myotome 332, 436
myotomy 13
myotonic muscular dystrophy (MMD) 666

$Na^+$ channel 435
narcotic 6
Nash/Moe method 635
NASS Questionnaire 1129
natural coralline 557
NCS, see nerve conduction study
Neck Disability Index (NDI) 439, 1129
Neck Pain and Disability Questionnaire 439
neck pain, see also pain 157, 430, 461
– acupuncture 448
– clinical assessment 203
– conservative treatment 446
– electrotherapy 448
– individual risk factors 161
– infrared laser therapy 448
– lifetime prevalence 201
– massage 447
– neck and shoulder disorder (NSD) 157
– non-specific 432, 445, 446, 464
– pain source 443
– radiofrequency denervation 448
– spondylosis related 446
– transforaminal injections 447
neoplasm in the vertebra 958
neovascularization 955
nerve
– compression syndrome 1048
– conduction study (NCS) 322, 323
– conduction velocity 523
– entrapment syndrome 333, 436
– growth factor (NGF) 136
– – mechanical deformation 433
– root
– – block 247, 263, 265, 490, 495, 637, 744
– – chemical irritation 433
– – compression 262, 267, 485, 492, 517, 587, 744, 843
– – compromise by mechanical deformation 484
– – dermatome 519
– – infiltration 1048
– – injury 1104, 1110
– – mechanical compression 531
– – monitoring 408
– – paresis 756
– – pathology 1092
– – tumor 998
– sheath
– – tumor 1000, 1008, 1010
neural
– compression syndrome 933, 980, 1025
– compromise 267
– inflammation 263
– plasticity 124
– tube defect 818
neurilemoma 1000
neurinoma 997, 1000, 1011
neurodegenerative disorder 312
neuroectodermal appendage 811
neuroenteric cyst 809
neurofibroma 1000, 1011
neurofibromatosis 211, 670, 998
neurofibrome 997
neurogenic
– claudication 513, 517, 519, 531
– – differential diagnosis 524
– – selective decompression 526
– shock 835
– spine deformity 333
neurological
– assessment 218
– deterioration 419
– syndrome 298
neuromonitoring 349, 1095
neuromuscular
– disorder (NMD) 663
– feedback system 545
– relaxant drug (NMB) 397, 408
– scoliosis, see there
neuromyotonia 333
neuron
– multireceptorial 131
– nociceptive-specific 131
– non-nociceptive 131
– wide-dynamic range 131
neuropathic pain 127, 138
– chronic constriction injury (CCI) model 137
– clinical examination 140
– pharmacological tests 140
neuropathy 333
neurophysiologic study 490
neuroplasticity 135, 145
neuropraxia 754
neurosponge 1104, 1106
neurovascular disorder 311
neurulation 800
neutral vertebrae 632
NEXUS study 837, 844
NGF, see nerve growth factor
nicotine 187
nitric oxide (NO) 6, 406
– synthase 133
NMB, see neuromuscular relaxant drug
NMD, see neuromuscular disorder
NMDA antagonist 142
*N*-methyl-D-aspartate (NMDA) receptor 133, 422
nociceptive pain 126, 138
nociceptive-specific (NS) neuron 131
nociception 129
non-nociceptive (N-NOC) neuron 131
non-opioid analgesic 421
non-specific low back pain (NSLBP)
– acute 596
– chronic 595, 596
– electrotherapy 592
– exercise therapy 592
– management 590
– medical pain management 591, 594
– psychological intervention 594
– spinal manipulation 592
– subacute 592, 596
– work conditioning programs 594
non-steroidal anti-inflammatory drug (NSAID) 209, 396, 410, 421
– non-selective 142, 421
norepinephrine 132
nosocomial infection 401
NSAID, see non-steroidal anti-inflammatory drug
NSD, see neck and shoulder disorder
NSLBP, see non-specific low back pain

nucleoplasty 82
nucleotomy 20, 498
nucleus pulposus 44, 95, 97, 101, 103, 108, 485
– herniated 495
numerical rating scale (NRS) 1127

obesity 162
oblique abdominus 53
obliquity
– infrapelvic 672
– intrapelvic 672
– suprapelvic 672
occipital condyle fracture (OCF) 850
occipitocervical
– fixation 74, 84
– fusion 1051
occupational
– injury risk 166
– therapy 609
OCF, see occipital condyle fracture
ocular perfusion pressure (OPP) 396
odontoid fracture 827, 855, 863, 872
– elderly patient 860
– screw fixation 860
oligodendrocyte 435
olisthesis 73
olisthetic vertebra 516, 743
open incisional biopsy 964
opioid 142, 421
OPLL, see ossification of the posterior longitudinal ligament
OPP, see ocular perfusion pressure
Oppenheim sign 300
oral antihyperglycemic drug 380
orotracheal tube 391, 392
orthosis 916, 1031
os odontoideum 830
ossification of the posterior longitudinal ligament (OPLL) 432, 435
osteitis 1061
osteoarthritis 93, 109, 461, 544
– of the facet joints 541
– of the hip joint 520
osteoarthrosis 531
osteoblastic lesion 979
osteoblastoma 234, 957, 959
osteocalcin 935
osteochondroma 965
osteochondrosis juvenilis lumbalis 771
osteoconduction 555
osteodensitometry 722
osteogenesis imperfecta 739
osteoidosteoma 209, 952, 957, 959, 966, 970
osteoinduction 556
osteolytic lesion 979
osteomyelitis
– of long bones 1029, 1031
– vertebral 1021, 1025
osteopenia 929
osteophyte 515
osteophytectomy 452, 459, 498
osteophytes 93, 109, 432, 544, 715, 1065
osteoplastic laminotomy 1009
osteoporosis/osteoporotic 110, 450, 926, 929, 942
– compression 925
– dual-energy X-ray absorptiometry 935
– fracture 925
– – imaging studies 933
– mechanical back pain 931
– medical treatment 936
osteosarcoma 967
osteosynthesis 748, 857
osteotomy 568, 687, 688, 1071
– blood loss 1108
– pedicle subtraction 705
– Smith-Peterson 705
– transpedicular reduction 725
Oswestry Disability Index (ODI) 182, 188, 503, 564, 907, 1128
outcome assessment 1123
overexertion 163
oxidative stress 92
oxygen saturation 609

PACS 228
pain, see also back/neck pain 261
– acute 126
– affect 1126
– arthritic 125
– assessment 1125
– axial 155, 156, 204, 222
– behavior 188, 189
– behavioral treatments 144
– biopsychosocial model 588
– character 205
– chronic 125, 126
– chronification 554
– classification 126, 144
– clinical assessment 138
– cognitive-behavioral treatments 144
– definition 125
– degenerative cervical disorders 436
– differentiation 204
– disability 157, 190
– discogenic 272
– dorsal 125
– duration 1125
– epidemiology 144
– family reinforcement 189
– functional 128
– generator model 588
– girdle-like 311
– historical background 123
– hypersensitivity 132, 136
– impairment 157
– inflammatory 126
– intensity 208
– lifetime prevalence 156
– management 420
– mechanical loading model 588
– medication 209
– modulation 133, 208
– motor control model 588
– musculoskeletal 125
– neuropathic 127, 138, 140, 333
– neurophysiological model 588
– neuroplasticity 145
– nociceptive 126, 138
– non-pharmacological treatment 143
– of the low back, see back pain
– onset 208
– pathophysiology 204
– pathways 128, 144
– perception 134
– peripheral 588
– persistent 135
– pharmacological treatment 141, 553
– point prevalence 154
– postoperative 409
– – relief 190
– projection 133

– provocation 271, 546
– radiation 204
– radicular 156, 204, 222
– reduction 265, 267
– referred 156, 204
– relief 1125
– – ladder 141
– sciatic 156, 482
– subacute 126
– surgical treatment 144
– syndrome 208, 222, 282, 291
– theories 123, 124
– transmission 133
– treatment 139
– – concepts 145
painless atrophy 299
palpation
– of bony landmarks 216
– of the paravertebral muscles 216
pantaloon cast 552
PAP, see pulmonary artery pressure
papilledema 1006
paracetamol 141, 591
paraganglioma 997, 1000
paralysis of the quadriceps muscle 296
paralytic
– bowel dysfunction 420
– ileus 385, 422, 1113
paraparesis 487
paraplegia 18, 22, 23, 293, 297, 498, 503, 835, 1095, 1107, 1110
– non-traumatic acute 311
parasitic infection 1030
paraspinal
– abscess 1112
– muscle 605
– – fat deposits 113
paravertebral muscle 605
paresis 203, 222, 493
– flaccid 306
– of foot elevation 310
– spastic 306
parietal pleura 349, 351
Paris cast 899
Parkinson's syndrome 333
partial thromboplastin time (PTT) 403
patient
– assessment 374
– positioning 1094
patient-controlled analgesia (PCA) 410, 421
Patrick test 215, 220
Pavlov index 440
PCA, see patient-controlled analgesia
PCU, see polycarbonate urethane
PE, see pulmonary embolism
pedicle
– screw 907
– – fixation 530, 561, 645
– – system 71
– – technique 84
– subtraction osteotomy 1072
pelvic incidence 769
penicillamine 380
penicillin 8
percutaneous
– debridement 1032
– posterolateral nucleotomy 498
Perdriolle method 635
peripheral
– nerve lesion 332
– neuropathy 524
persistent pain 135
$PGE_1$, see prostaglandin $E_1$
Phalen-Dixon sign 738, 747, 757
Philadelphia collar 845, 866
physical
– examination 212, 223
– – standing 211
– – walking 211
– fitness 187
– impairment 210
– rehabilitation training
– – acceleration/deceleration training 614
– – proprioception 614
– – strength endurance 614
– therapy 609
physiotherapy, scoliosis 639
pin prick 218
pincer
– effect 434
– type 913
placode 803, 816
plasma cell dyscrasia 935
plasmocytoma 961
plate fixation 867
– anterior 450
– multilevel fusion 450
platelet transfusion 404
plethysmography of the toe 398
pleural abscess 1099
PLIF, see posterior lumbar interbody fusion
PLL, see posterior longitudinal ligament
pneumonia 377, 1113
pneumothorax 1099
poliomyelitis 847
polycarbonate urethane (PCU) 83
polyethylene terephthalate (PET) 83
polyneuritis 295
polyneuropathy 293, 302, 332
polysynaptic reflex 301
polytrauma 826, 841, 892, 896, 909, 918
positron emission tomography (PET) 245
posterior
– approach to the thoracolumbar spine 358
– bisegmental reduction 907
– cervical approach
– – surgical anatomy 344
– cord syndrome 305
– decompression surgery 337
– dynamic stabilization system 82, 85
– instrumentation 71
– longitudinal ligament (PLL) 888
– lumbar interbody fusion (PLIF) 71, 75, 560, 563, 726, 753, 1104
– thoracolumbar approach
– – surgical anatomy 360
– transpedicular vertebrectomy 990
posterolateral
– corner 76
– fusion 559, 908
– vertebrectomy 992
postirradiation sarcoma 967
postoperative
– anuresis 1114
– bleeding 418, 1109
– bowel atonia 1113
– care 417, 423
– complications, see there
– extubation 418
– morbidity 417

– pain management 420, 423
– rehabilitation 603
– – goals 607
– – principles 607, 618
– ventilation 418
post-thoracotomy pain syndrome 910
Pott's
– disease 22, 75
– trias 23
predominant back pain
– magnetic resonance imaging 549
– standard radiographs 549
premedication 380
preoperative
– cardiac testing 375
– laboratory studies 375
– patient assessment 390
– physical examination 375
primary sensory neuron 129
progressive lumbar kyphosis 113
promontorium 366
propofol 406
proprioception 130, 218, 302, 614
prostaglandin 137, 142
– $E_1$ ($PGE_1$) 401
prostate cancer 978
proteoglycan 44, 96, 97, 106, 767
proteolytic matrix destruction 104
prothrombin time (PT) 403
proton ($^1$H)-spectroscopy 239
protoplasm 112
provocative discography 284, 551, 637
– indications 271
pseudarthrosis 79, 565, 566, 750, 909
pseudo-Lasègue sign 220, 223
pseudo-meningocele 1106
psoas 53
– abscess 1112
– muscle 351, 355
psychogenic back pain score 187
Psychological General Well-Being Index (PGWBI) 1132
PT, see prothrombin time
pulmonary
– artery pressure (PAP) 398
– care 419
– disease 382
– edema 384
– embolism (PE) 380, 1113
pulse oximeter 1100

quality of life 1130
Queckenstedt's sign 1008
questionnaire
– availability 1124
– pain assessment 1125
– validity 1124

radial nerve palsy 219
radicular
– claudication 519
– leg pain 488, 505
– pain 156, 204, 222, 436
– syndrome 204, 491
radiculopathy 208, 261, 293, 309, 310, 320, 332, 437, 483, 488, 494, 519, 1087
– C5 464
– – spondylotic 431
– cervical 461, 464, 465
– EMG recordings 330
– herniated disc 484
– magnetic resonance imaging (MRI) 439
– manipulative therapy 447
– radiography 439
radiograph 255
– cervical spine 229
– lateral bending 229
– lumbar spine 228
– oblique 441
– thoracic spine 228
– whole spine 229
railway spine 28
rear-end collision 834
receiver operating characteristics (ROC) 181
recombinant erythropoietin (rEPO) 402
recreational activity 616
rectus abdominus 53
recurrent laryngeal nerve (RLN)
– lesion 1096
– palsy 464
referred pain 156, 204
reflex deficit 299
regression analysis 184
rehabilitation
– aftercare period 614
– biopsychosocial model 606
– home exercise program 609
– physical training 614
– preoperative assessment 608
– preventive strategy 604
– program 605
– protocol 608
– psychosocial obstacles 617
– rehabilitative strategy 604
– treatment strategy 604
– work-related obstacles 617
relaxation training 594
Relton Hall frame 1094
renal cell tumor 992
repetitive motion 163
rEPO, see recombinant erythropoietin
residual paraplegia 381
respiratory failure 385
retraction frame 565
retractor system 910
retrograde ejaculation 358, 1114
retrolisthesis 541
return to work 614
reversed angle technique 228
revised cardiac risk index 378
rFVIIa 404
rheumatoid arthritis (RA) 376, 1041
– history 1045
– imaging studies 1045
– injection studies 1048
– non-operative treatment 1048
– operative treatment 1048
– physical findings 1045
– Ranawat classification 1044
– surgical techniques 1050
Rhomberg test 211, 438
rib
– cage deformity 648
– expander 707
rib-vertebral angle (RVA) 635
rigid collar 853
Ringer's lactate solution 399
Risser sign 9, 632, 633, 776, 781
Robinson-Smith technique 449, 452
ROC, see receiver operating characteristics
Roland & Morris Disability Questionnaire (RMDQ) 1128

Romanus lesion 255
Romberg's test 302, 673
Roos test 217
Rossolimo sign 300
rotational fracture dislocation 886
rotatory atlantoaxial instability 854
roundback 774, 777
RVA, see rib-vertebral angle

sacral
– agenesis 799
– dome osteotomy 754
– sulcus 280
– tumor 957
– vertical line 627
sacrococcygeal fistula 814
sacroiliac joint 48, 220, 253
– block 280, 284
– imaging 248
– scintigraphy 1066
– syndrome 548
– – non-inflammatory 281
sacroiliitis 1065, 1066
safe triangle 263
sagittal
– balance 769
– plane deformity 693
– thoracic modifier (STM) 627
saline or balanced solution 399
salvage Gallie procedure 1104
SAPHO 237
sarcopenia 113
sarcoplasm 112
SB-Charité prosthesis 566
Scheuermann's disease 14, 275, 765
– bracing 780
– casting 780
– correction 785
– fusion 785
– non-operative treatment 779
– posterior release 785
Schmorl's node 14, 43, 771, 791
Schober test 213, 1062
Schwann cell damage 485
schwannoma 1000
SCI, see spinal cord injury
sciatic pain 156
sciatica 3, 15, 18, 164, 184, 188, 262, 270, 481, 483, 738, 931
– chemical irritation 485
– natural history 494
sclerosis 110
sclerotome 207, 436
SCM, see split cord malformation
scoliosis 1, 8, 175, 320, 382, 383, 394, 397, 401, 422
– back pain 718
– complications
– – neurological injury 651
– – surgery 651
– congenital 693
– – classification 695
– – curve progression 700
– – history 696
– – imaging studies 698
– – non-operative treatment 700
– – operative treatment 701
– curve assessment 630
– degenerative 713
– – classification 716
– – curve progression 719
– – decompression 724
– – history 717
– – imaging studies 720
– – operative treatment 723
– etiology 679
– idiopathic 377, 623, 697, 779, 957
– – complication rate 1089
– – adolescent 638
– – assessment of physical maturity 630
– – classification 626
– – complication rate 1089
– – etiology 625
– – genetic factors 625
– – history 627
– – imaging studies 632
– – infantile 637
– – injection studies 637
– – intraoperative neuromonitoring 641
– – juvenile 638
– – neurological assessment 630
– – neurophysiologic evaluation 637
– – non-operative options 639
– – operative treatment 641
– – surgical approach 642
– – surgical decision-making 647
– – treatment 637
– infantile 637
– lumbar 717
– natural history 638
– neuromuscular 663
– – bone grafting 685
– – bracing 678
– – classification 667
– – history 669
– – imaging studies 675
– – medical assessment 673
– – non-operative treatment 677
– – operative treatment 678
– – sacral and pelvic fixation 682
– – spinal cord monitoring 688
– – spinal fixation 682
– pathogenesis 9
– surgery 13, 398, 410
– thoracic 719
– thoracolumbar 719
– treatment 9, 13
Scoliosis Research Society Questionnaire 1132
Scotch cast 846
screw
– fixation 79
– – anterior atlantoaxial 362, 858
– – anterior odontoid 857
– – atlantoaxial pedicle 362
– – Galveston technique 368
– – iliac 366
– – lateral mass 363, 457
– – lower cervical spine pedicle 364
– – lumbar spine pedicle 364
– – Magerl technique 363
– – MW sacropelvic 368
– – of the occiput 361
– – pedicle 458, 561
– – posterior atlantoaxial transarticular 361
– – posterior atlantoaxial transaxial 860
– – Roy-Camille method 364
– – sacral 366
– – thoracic spine pedicle 365
– – translaminar 562, 565
– trajectory
– – convergent 71
– – extrapedicular 73

– transarticular 73, 84
– translaminar 73, 84
screw-rod fixation system 562, 868
segment moyen 887
segmental
– distraction 77
– hypermobility 542
– instability 544
– – temporary stabilization 552
– kyphosis 84
– motion 79, 570
– – preservation 80
SEH, see spinal epidural hematoma
selective
– nerve root block (SNRB) 283, 490, 721
– – complications 265
– – indications 262
– – pain reduction 265
– serotonin reuptake inhibitor 143
sensorimotor integration 302
SEP, see somatosensory evoked potential
septic sacroiliitis 1065, 1066
sequestrectomy 498, 502
seroma 239
serotonin (5-HT) 132
serratus muscle 347
SF-36 564, 639, 915
Sharpey's fibers 1065
shear force 887
shoulder
– depression test 217
– pain 431
shuttle walking test 520
SIDH, see syndrome of inappropriate secretion of antidiuretic hormone
silhouette radiograph 635
skeletal
– dysplasia 777
– metastasis, see there
– muscle, age-related changes 112
– scintigraphy 898
skin stigmata 697
slipped apophysis 496 491
slow twitch 48
SMA, see spinal muscular atrophy
smoking 187
SMT, see spinal manipulative therapy
SNRB, see selective nerve root block
sodium valproate 801
soft
– collar 845
– herniation 432
somatosensory
– cortex 134
– evoked potential (SSEP) 326, 391, 444, 523, 637, 1095
– – recording 407
spastic
– diplegia 673
– paresis 306
spasticity 463
spectroscopy 239
spina
– bifida 696, 737, 814
– – aperta 802
– – cystica 802
– – occulta 211, 798, 802, 1104
– luxata 12, 22
spinal cord
– anatomy 5
– anomalies, risk factors 801
– blood flow (SCBF) 401
– blood supply 434
– compression 220, 249, 419, 457, 463, 776, 980, 1110
– – differential diagnosis 311
– – magnetic resonance imaging 441
– decompression 462, 782, 849, 904
– deformation 489
– disease 255
– distraction 832
– edema 985
– embryological development 800
– hyperexcitability 833
– injury (SCI) 304, 330, 384, 832, 848, 871, 885, 1106
– – non-operative treatment 899
– – steroid treatment 849, 899
– – traumatic 297
– ischemia 434, 652
– lesion 29, 250
– malformations 797
– – classification 802
– – diagnostic tests 815
– – treatment 815
– monitoring 405, 688
– signal intensity 442
– somatotopic organization 294, 320
– syndrome 304
– tumor, intrinsic resection 1012
– glial changes 137
spine/spinal
– age-related changes 111
– anatomy 4
– angiography 963
– artery syndrome 419
– arthrodesis 555, 679
– balance 650
– canal 440
– – narrowing 513
– – size 434
– – stenosis 246, 332, 463, 513
– – trefoil shape 515
– claudication 203, 204, 517
– column, resection 705
– cord, see there
– decompression 531
– deformity 27, 210, 222, 382, 419, 666, 687, 1058
– disorder 545
– – acute 155
– – bowl and bladder disorder 303
– – central (CNS) nervous system 295
– – chronic 155
– – classification 155, 167, 295
– – economic costs 159
– – epidemiology 153
– – etiology 155
– – flag system 165, 203
– – history 1
– – imaging 184
– – MR imaging 229
– – neurological assessment 298
– – neurological deficit 291
– – non-specific 155, 203
– – non-traumatic 291, 295
– – operative procedure 175
– – outcome of common surgical procedures 182
– – pain 204
– – peripheral nervous system (PNS) 295
– – physical examination 211
– – risk factors 153, 165, 167
– – specific 155, 203
– – subacute 155

– – traumatic 293
– dysraphism 797
– – history 812
– – in utero treatment 816
– – surgery 816
– epidural hematoma (SEH) 381
– extension 54
– fixation 682
– flexion 54
– fracture 27, 830
– – complications 917
– – CT diagnosis 243
– – lumbar 918
– – thoracic 918
– functional unit 42, 93
– fusion 529, 554, 568, 570, 702
– – allograft 450
– – biology 555, 571
– – bone grafts 556
– – instrumented 560
– – motion preservation 566
– – non-instrumented 559
– – osteoconduction 555
– – osteogenesis 555
– – osteoinduction 555
– hemisyndrome 304
– hemorrhage 295
– hypersensitivity 833
– imaging, see there
– infection, see there
– injection 261, 551
– – contraindications 281
– – rationale 262
– injury 27, 892
– – Denis classification 888
– – traumatic 384
– instability 57, 58, 546, 887
– instrumentation 67, 69, 84, 560, 563, 573, 636, 641
– ischemia 312
– kinematics 54, 62
– ligament 6, 47, 61, 111
– lipoma 806
– loading 58, 62
– manipulative therapy (SMT) 447, 465, 592
– metastasis, see there
– motion segment 55
– muscle 52
– muscular atrophy (SMA) 666
– osteoarthritis 93
– pain, see there
– pathology, flag system 588
– physiology 4
– principal functions 41
– rehabilitation 606
– shock 304, 325, 384, 833, 836, 894
– stability 52, 887
– stabilization 67
– stenosis, see there
– surgery, see there
– thoracic 41
– trauma 563, 929
– – imaging studies 895
– tuberculosis 9, 22, 350
– tumor, see there
– whole spine radiographs 229
splenic injury 1100
split
– cord malformation (SCM) 809
– notochord syndrome 809
spondylarthritis 715
spondylectomy 970, 993
spondyloarthropathy (SPA) 1057, 1067
spondylodesis 67, 69, 78, 79, 175
spondylodiscitis
– after discography 1111
– aseptic 1075
spondylolisthesis 3, 46, 75, 162, 175, 358, 441, 515, 516, 528, 541, 545, 715, 733, 734
– acquired 757
– acute pain 745
– classification 735
– degenerative 738, 745, 1043
– developmental 754, 757
– high-grade 747
– history 736
– imaging 739
– interbody fusion 750
– isthmic 748
– low-grade 746
– lumbosacral 743
– non-operative treatment 745
– of the axis 860, 872
– operative treatment 747
– pathogenesis 735
– postsurgical 745
– sacral dome osteotomy 754
– slip reduction 750
– surgery 14, 752
– traumatic 871
spondylolysis 162, 175, 733
– block 276, 279, 283
– decompression 748
– fusion 748
– repair 748
spondylophytes 3
spondyloptosis 739, 756
– vertebrectomy 754
spondylosis 93, 715
– cervical radiculopathy 431
spondylotic
– pain 437
– syndrome 436, 438, 465
spoon test 303
SPORT trial 503
Spurling's test 217, 437
SSEP, see somatosensory evoked potential
stabilization of the subaxial cervical spine 1051
stabilizing exercise 613
standard
– limited laminotomy 501
– radiograph 227
*Staphylococcus*
– *aureus* 393
– – methicillin-resistant 394
– *epidermidis* 393
static loading 58
stem cell, oncogenic mutation 956
stenosis 21, 110, 111, 262, 293, 327, 515, 531, 1043, 1102
– cardinal symptoms 519
– complications 1089
– computed tomography 522
– CT myelography 522
– diagnosis 520
– foraminal 1108
– instrumented fusion 529
– laminectomy 526
– lumbar 520
– magnetic resonance imaging (MRI) 522
– natural history 525
– neurogenic claudication 519

– of the carotid artery 379
– of the spinal canal 246, 513
– physical findings 520
– surgical decompression 528
sterilization 8
sternocleidomastoid muscle 339
sternocostal junction 346
sternotomy 990
stiffness 48, 71, 76
STM, see sagittal thoracic modifier
strength endurance 614
strengthening exercise 592, 612
stress
– profilometry 44
– shielding 74, 75, 79
stroke 1091
strut-grafting 910
subacute pain 126
subarachnoid hemorrhage 1005
subaxial injury
– classification 865
– vertebral 864
subcutaneous rod 707
substance P 136
sulfasalazine 1068
superficial infection 1111
superior
– laryngeal nerve 341
– – lesion 1096
– mesenteric artery syndrome 1113
suppression 237
surgery 4
– airway assessment 376
– airway control 391
– analgesia 421
– anesthesia 389, 411
– anterior lumbar retroperitoneal approach 355
– anterior medial approach 337
– anterior-lateral retroperitoneal approach to the lumbar spine 353
– antibiotic prophylaxis 393
– blood preserving techniques 400
– body temperature 399
– cell salvage 402
– comorbidities 417
– end of anesthesia 409
– endotracheal intubation 391
– high-risk patients 373
– indications 185
– local anesthetic 422
– lumbar disc herniation 482
– maintenance of anesthesia 396
– muscle detachment 605
– organ-specific assessment 385
– outcome 179
– – biological and demographic variables 186
– – measures 179, 192
– – predictors 183
– – psychological factors 187
– patient
– – assessment 374, 385
– – expectations 183
– – positioning 337, 394
– posterior approach
– – to the cervical spine 342
– – to the thoracolumbar spine 358
– postoperative
– – extubation 418
– – infections 393
– – pain management 409
– – rehabilitation 603
– – ventilation 418
– preanesthetic evaluation 373
– predictors of outcome 192
– prescreening tools 179
– reoperation 530
– screw insertion 361
– successful outcome 180
– thromboembolic disease 420
Swedish lumbar spine study 569
sympathectomy syndrome 358
symphysis 356
syndesmophytes 1065
syndrome of inappropriate secretion of antidiuretic hormone (SIADH) 384
synfix 77
SynFrame 910
syringomyelia 635, 636, 669, 673, 803, 999

Tachosil 1098, 1099
tachycardia 384
– perioperative 418
tarsal tunnel syndrome 293
TCP, see tricalcium phosphate
TDA, see total disc arthroplasty
TDH, see thoracic disc herniation
tear-drop
– fracture 831
– injury 869
technetium-99m bone scan 961
TEE, see transesophageal echocardiography
telomere 953
tendinopathy 1062
tendon reflex 218
tendon-tap reflex 325
tenotomy 13
tension band 78
test-retest reliability 1135
tethered cord 211, 629, 635, 1093
– cutaneous markers 813
– syndrome 799, 806, 811, 812
– – diagnostic tests 815
– – neurological findings 802
– – surgery 817
– – treatment 815
tetrahydrobiopterin synthesis 137
tetraparesis 444
tetraplegia 293, 297, 851
TGF-β 106
thalamus 134
thecal sac 527
thiopental 406
thoracic
– curve 648
– disc herniation (TDH) 502
– discography 274
– hypokyphosis 645
– kyphosis 213, 645, 768, 775, 776, 942
– lordosis 640
– outlet syndrome (TOS) 217, 293, 333
– spine 41, 228
– – injury 883
– – surgery 419
thoracolumbar
– fascia 360
– fracture 883, 907
– neurological examination 892
– non-operative treatment 899
– posterior stabilization 912
– treatment guidelines 912

– injury 895
– orthosis (TLO) 722
– spinal injury
– history 893
– operative treatment 903
– transition 885
thoracolumbosacral orthosis (TLSO) 722
thoraco-lumbotomy 643
thoraco-phrenico-lumbotomy 728
– left-sided 350
– surgical anatomy 352
thoracoplasty 647
thoracoscopy 649, 911
thoracotomy 345, 377, 643, 988
– complications 1098
– right-sided 346
– surgical anatomy 348
thorax trauma 909
three-joint complex 93, 542
thrombectomy 1100
thrombocytes
– abnormalities 626
– metallophilic 626
thrombocytopenia 404
thyroid tumor 992
tight filum terminale 807
titanium mesh cage 1036
TIVA, see total intravenous anesthesia
TKA, see total knee arthroplasty
TLIF, see transforaminal lumbar interbody fusion
TLO, see thoracolumbar orthosis
TLS, see translaminar screw
TLSO, see thoracolumbosacral orthosis
TMS, see transcranial magnetic stimulation
TNF-α, see tumor necrosis factor α
TOF, see train-of-four
Tokuhashi scoring system 984
tonsillectomy 853
torticollis 1006, 1024
TOS, see thoracic outlet syndrome
total
– disc arthroplasty (TDA) 455, 466, 566, 567, 571
– – ProDisc-L 568
– intravenous anesthesia (TIVA) 396
– joint replacement 568
– knee arthroplasty (TKA) 80
tracheotomy 418, 1100
traction table 11, 12, 29
train-of-four (TOF) 400
tramadol 142
tranexamic acid 403
transarticular screw 73, 84
transcranial magnetic stimulation (TMS) 319, 328
transduction 129
transesophageal echocardiography (TEE) 398
transforaminal
– lumbar interbody fusion (TLIF) 75, 563
– procedure 75
– steroid injection 447
transient receptor potential (TRP) channel 129
transitional vertebrae 541
translaminar screw (TLS) 68, 73, 84
– fixation 562
translation motion 545
transmission 130
transpedicular reduction osteotomy 725
transpharyngeal stereotactic needle biopsy 964
transverse
– abdominus 53
– alar ligament disruption 857
– incision 339
– myelitis 498
trauma 56
traumatic
– fracture at the thoracolumbar junction 883
– spondylolisthesis 830
– – of the axis 860
– sympathectomy 384
Traver's case 25
tricalcium phosphate (TCP) 557
Trömner sign 300
trophic hormone 92
trunk
– imbalance 213
– muscle 48
T-score 929
tuberculin skin test 1025
tuberculosis 9, 11, 13, 22, 350, 765, 1023, 1025, 1027, 1029, 1036
– gibbosity 12
tumor 295, 327
– adjuvant therapy 967, 973
– back pain 957
– benign 965
– biology 953, 973
– biopsy 964
– capsule 1014, 1016
– cervical 1006
– classification 973
– compression fracture 959
– curetage 968
– cyst 1003
– en-bloc resection 968, 970
– endovascular embolization 992
– excessive bleeding 1108
– genetic studies 998
– histology 956
– imaging studies 958
– intradural 997
– – cytology 1009
– – imaging studies 1007
– – non-surgical treatment 1009
– – surgical treatment 1009
– intradural-extramedullary 999
– – surgical techniques 1010
– intradural-intramedullary 1002
– intralesional resection 968, 969
– intramedullary 1005
– intraoperative neuromonitoring 329
– local recurrences 973
– malignant 966
– musculoskeletal 953
– necrosis 959
– non-operative treatment 967
– non-steroidal anti-inflammatory drugs 967
– of the central nervous system 997
– of the cervical spine 988
– of the foramen magnum 1006
– of the lumbar spine 992
– of the mediastinum 978
– of the retroperitoneum 978
– of the sacrum 970
– of the thoracic spine 988
– operative treatment 968
– poor-prognosis type 956
– reconstruction of the spine 970
– resection 988
– sacral 957
– spinal angiography 963
– spinal stabilization 988

– staging 964, 986
– technetium scan 961
– treatment 973
Tumor necrosis factor α (TNF-α) 105, 106, 1061, 1068
– exogenous 486
– inhibitor 1048

ulnar nerve
– lesion 310
– palsy 219
– syndrome 444
ultrasonography 247
umbilicus 356
Unterberger's stepping test 302
upper limb tension test (ULTT) 438
ureteral injury 1103
urinary
– bladder
– – dysfunction 1114
– – injury 1103
– tract infection 1114
uroflowmetry 491

vagal nerve 294
VAI, see vertebral artery insufficiency
Valsalva maneuver 217, 438
vanilloid receptor 129
variable screw system (VSP) 562
VAS, see Visual Analogue Scale
vascular
– compression theory 517, 531
– prosthesis 1091
vascularization, age-related changes 102
VBCF, see vertebral body compression fracture
venous
– congestion 517
– laceration 1102
– thromboembolism 380
VEPTR, see vertical expandable prosthetic titanium rib
Verbal Rating Scale (VRS) 1127
vertebra/vertebral 1
– angioma 987
– ankylosing 111
– artery
– – injury 1103
– – insufficiency (VAI) 842
– body 43, 61
– – age-related changes 110, 114
– – biomechanical function 42
– – compression fracture (VBCF) 925, 942
– – height 931
– – metastases 979
– – reconstruction 988
– – screw 642
– body compression fracture (VBCF)
– – bracing 936
– – cement reinforcement 939
– – operative treatment 937
– – restoration of lordosis 939
– – treatment 936
– – vertebroplasty 938
– column alteration 1065
– compression fracture 111
– fracture 898, 926, 1043
– – history 930
– geometry 43
– kyphosis 1059
– osteomyelitis 1021, 1025
– spine injury
– – classification 887
vertebrectomy 78, 687, 754, 970
– posterior transpedicular 990
– posterolateral 992
vertebrobasilar insufficiency 1045
vertebroplasty 938, 960, 987
– local cement leakage 940
vertical expandable prosthetic titanium rib (VEPTR) 648
vertobrectomy 681
vessel
– laceration 1096
– ligation 1107
vibration 218
videofluoroscopy 545
Visual Analogue Scale (VAS) 208, 915, 916, 1126
von Hippel-Lindau disease 998, 1003
von Willebrand's disease 404
VSP, see variable screw system

WAD, see whiplash-associated disorder
Waddell sign 221
waistline asymmetry 627, 629
wake-up test (WUT) 390, 395,408
Wallenburg's syndrome 842
wear and tear 539
wedge
– compression fracture 885
– osteotomy 725
– vertebra 695, 708
whiplash
– injury 28, 827, 871
– syndrome 157, 167
whiplash-associated disorder (WAD) 157, 208, 827, 833, 871
– classification 836
– radiograph 252
– treatment 844
WHO Quality of Life instruments 1130
wide-dynamic range (WDR) neuron 131
windshield wiper effect 368
windswept deformity 672
winking owl sign 959
work conditioning program 594
workers' compensation 189
wound
– erysipelas 1111
– healing 605
– infection 652, 1110
– persistent drainage 1112
WUT, see wake-up test

xanthochromia 1009
X-ray 8

zygapophyseal joint, see also facet joint 41

# The Editors

**Norbert Boos** was born in Germany in 1960 and is a Swiss citizen. He studied at the University of Saarland, Germany, and the University of Basle, Switzerland. He then received an international training as an orthopedic and spinal surgeon in Germany, Switzerland, the United States, Canada, and the United Kingdom. Since 1997 he has been Head of Spinal Surgery at the Orthopaedic University Hospital Balgrist, University of Zürich, Switzerland. He received his *venia legendi* at the University of Zürich in 1999 and was promoted to Titular Professor in 2005. Norbert Boos has a long track record in clinical and basic spinal research. He has published over 100 articles and book chapters in many areas of spinal disorders and has won numerous prestigious awards in the fields of spinal surgery and research. In 2002, he received a Master's degree in Business Administration from the University of Zürich and has developed a keen interest in health-care economics as well as health-care technology assessment and transfer. He is a founding member of AO Spine, a Deputy Editor of the *European Spine Journal*, and a board member of EuroSpine, the Spine Society of Europe.

**Max Aebi** was born in Switzerland in 1948 and is a Swiss/Canadian dual citizen. He studied at the University of Bern, became a board certified General and Orthopedic Surgeon (FMH and FRCSC), and did his spine fellowship training in Canada, the United States and the United Kingdom. From 1992 to 2002, he held the positions of Professor and Chair, Division of Orthopaedic Surgery, and Orthopaedic Surgeon-in-Chief, McGill University Health Center; and Adjunct Professor of Oncology, Department of Medicine, McGill University, Montreal, Canada. In 1999, he received an AMP diploma from INSEAD, Fontainebleau, and in 2002 was awarded an Honorary Doctorate from the Université de la Méditerranée, Marseilles, France. Since 2002, Max Aebi has been Professor and Co-Chair of the MEM Research Center, University of Bern, and Chief of Staff, Department of Orthopaedic Surgery, Hirslanden-Salem Hospital, Bern, Switzerland. Max Aebi is Co-Founder and Past Chairman of AO Spine, a member of the European Acadamy of Science, and the Founder and Editor-in-Chief of the *European Spine Journal*, the highest rated scientific journal in musculoskeletal medicine in Europe.

# The Medical Illustrator

**Alain Blank** is a scientific illustrator and graphic designer. He founded his agency for visual communication, Blankvisual, in 2001 after having acquired a vast experience as a freelance and scientific illustrator for many international agencies and companies. The specialities of illustration, photography, video, computer animation and interaction design are all part of his and Blankvisual's repertoire. Currently he is developing interactive e-learning programs on the locomotor apparatus for the Faculty of Medicine at the University of Zürich. The DVD *Anatomy of the Locomotor Apparatus* (Biomedia SA), for which Alain Blank supplied the anatomical illustrations, has been honored with Prix Möbius International and Worlddidac awards. Alain Blank is also regularly invited to lecture on visual communication and scientific visualization at the Zürich University of the Arts.

www.blankvisual.ch

# The Artist

**Arnaldo Ricciardi** was born in Italy in 1954. After finishing public school and attending high school in Zürich, he continued his training at the School of Art in Lugano. Apart from this school, contact with the painter Leo Maillet (1902 – 1990) was of great importance to the prospective artist's progress.

Working with Maillet, who had been a student of Max Beckmann in Germany, Ricciardi had the opportunity to extend his understanding of painting, which is clearly noticeable when considering his mastery in dealing with the painting medium.

In the course of his further development, the artist's point of view shifted increasingly from figure to color. He created works which speak for themselves without referring to objects. Rarely, in the form of fragments emerging between the different coats of color, indications of drawing were visible.

Ricciardi's style became more and more abstract over time. Today, he puts the main emphasis on colorfields – constructions "floating freely" and dominating the general impression of his work. Such colorfields can be built up in various ways but are usually intensely correlated. Some appear buoyant and transparent, others heavy and opaque. Carefully selected matched tones make a strong impression on the observer.

The characteristic tints arise during the painting process when color compositions are changed again and again. The doctrine of colors, to which Arnaldo dedicated himself during his academic years, now works to his advantage when dealing with color compositions. Fundamental to Ricciardi's compositions is that he keeps away from customary classifications within his paintings. There is neither a classic foreground nor background in his works. Spaces, provided that any occur in his paintings, result from the interaction of different colors forming fields which indicate distances between the different color levels, giving his paintings a strong expressiveness. His work is regularly exhibited at international art fairs.

www.arnaldo.ch info@arnaldo.ch

recipienti 34, 2007

spazio rosso 8, 2007

bluenote 13, 2008

bluenote 18, 2008